

Treatment with ^{90}Y - and ^{177}Lu -DOTATOC in patients with metastatic neuroendocrine tumors

Andrea Frilling, MD, PhD,^a Frank Weber, MD,^a Fuat Saner, MD,^a Andreas Bockisch, MD,^b Michael Hofmann, MD,^c Jan Mueller-Brand, MD,^d and Christoph E. Broelsch, MD, PhD,^a Essen, Germany; Bern, Switzerland; and Basel, Switzerland

Background. Treatment with ^{90}Y - or ^{177}Lu -DOTATOC has recently been introduced in the palliative treatment of somatostatin receptor-expressing neuroendocrine tumors (NETs). The aim of the study was to present clinical experience with ^{90}Y - and ^{177}Lu -DOTATOC therapy in the management of NET.

Methods. To prove suitability for treatment each patient underwent scanning with ^{111}In -DTPAOC or ^{68}Ga -DOTATOC positron emission tomography/computed tomography. All patients received [^{90}Y -DOTATOC] as initial treatment. In case of disease relapse the treatment was repeated. To avoid side effects of repeated [^{90}Y] applications, a switch to [^{177}Lu -DOTATOC] was carried out. Clinical, biochemical, and radioimaging responses were documented.

Results. Twenty patients with metastatic nonresectable NETs (15 pancreas NETs, 2 midgut NETs, 1 gastrinoma, 1 paraganglioma, 1 NET of unknown primary origin) were included. In 8 patients the treatment was repeated more than once (mean, 3 times; range, 2-5 times). After [^{90}Y] treatment moderate toxicity was observed in 8 patients. No serious adverse events were documentable. After restaging, a partial remission was found in 5 patients, stable disease in 11 patients, and tumor progression in 4 patients.

Conclusions. Peptide receptor-targeted radionuclide therapy is a promising, safe, and feasible approach in the palliative therapy of patients with NET. (Surgery 2006;140:968-77.)

From the Departments of General, Visceral and Transplantation Surgery^a and Nuclear Medicine,^b University Hospital Essen; the Department of Nuclear Medicine,^c University Hospital Bern; and the Department of Nuclear Medicine^d University Hospital Basel

MALIGNANT NEUROENDOCRINE TUMORS (NETs) frequently present with synchronous or metachronous metastases. Undoubtedly, aggressive surgical approach presents the first treatment of choice even in metastasized tumor stage. In the presence of nonresectable conditions, various palliative treatment modalities are available. The unique biologic behavior of NETs associated with favorable prognosis, even in the presence of metastases, justifies their implementation in the therapeutic concept.

Radiolabeled guanethidine analogue metaiodobenzylguanidine (^{131}I -MIBG), preferably assembled by the neuroadrenergic tissue was the initial targeting pharmaceutical used for radionuclide therapy of metastatic NETs other than thyroid carcinoma.¹

Somatostatin receptors (SSTs), expressed by a great variety of cell types, offered an alternative promising molecular target for radiopharmaceuticals such as [indium-111 (^{111}In)-diethylene-triamine-pentaacetic acid (DTPA)-D-Phe¹¹-octreotide (^{111}In -DTPAOC) (OctreoScan; Mallinckrodt, Inc., Petten, Switzerland) that have become routinely used either as standard scintigraphy or single photon emission computed tomography (SPECT) for initial detection and staging of NET, particularly those originating from the gut.² In spite of high sensitivity (60%-99%) and specificity (85%-98%), the technique is bounded by its poor geometric resolution in the presence of deep-seated smaller tumors.²

Presented at the 27th Annual Meeting of the American Association of Endocrine Surgeons, New York, New York, May, 2006.

Reprint requests: Andrea Frilling, MD, Professor of Surgery, Department of General, Visceral and Transplantation Surgery, University Hospital Essen, Hufelandstr 55, D-45122 Germany. E-mail: frilling@uni-essen.de.

0039-6060/\$ - see front matter

© 2006 Mosby, Inc. All rights reserved.

doi:10.1016/j.surg.2006.07.030

In 1996 the chelator somatostatin analogue 1,4,7,10-tetra-azacyclododecan-4,7,10-tricarboxy-methyl-1-yl-acetyl-D-Phe¹ Try³-octreotide (DOTATOC) with high affinity to SSTs and the option for stable labeling with β -emitting radioisotopes was developed. The labeling of hydrophilic peptide vector DOTATOC with the positron emitter gallium-68 (⁶⁸Ga) (⁶⁸Ga-DOTATOC) enables positron emission tomography (PET) imaging that provides diagnostic sensitivity 30% higher than that achieved by standard octreotide scanning.^{3,4} Precise fusion of functional ⁶⁸Ga-DOTATOC PET images with a morphologic image technique such as computed tomography (CT) (⁶⁸Ga-DOTATOC PET/CT) offers additional information.

It became evident, however, that, because of their short-range radiotoxicity, ¹¹¹In-coupled peptides might be more effectively used for diagnostic than for therapeutic purposes. Labeling of DOTATOC with β -emitters such as yttrium-90 (⁹⁰Y) or lutetium-177 (¹⁷⁷Lu) provided a more favorable agent for somatostatin receptor-targeted radionuclide therapy because of their high energy and longer range.⁵⁻⁹ In vitro studies confirmed very high binding affinity of ⁹⁰Y-DOTATOC for somatostatin receptor subtypes 2 and 5, and underlined its clinical value in the management of NET.^{10,11} In an initial phase II trial the overall response rate after ⁹⁰Y-DOTATOC treatment was 24% in a group of patients with NET originating from the gastroenteropancreatic or bronchopulmonary system.⁶ In this study further clinical experience with ⁹⁰Y- and ¹⁷⁷Lu-DOTATOC therapy in the palliative management of patients with advanced NET will be presented.

MATERIAL AND METHODS

Patients. All patients included in this analysis presented with advanced histologically or cytologically proven progressive metastatic NET not suitable for primary resection. In 2 patients (nos. 1 and 9), clinical symptoms caused by excessive hormonal secretion were evident. Nonresectability, due to either technical or oncologic reasons, was confirmed by 2 experienced surgeons. Further inclusion criteria were life expectancy >6 months and World Health Organization (WHO) status ≤ 2 . The findings of pretherapeutic SST scintigraphy were strongly positive in all patients. Besides tumor imaging, all patients underwent complete blood counts, blood chemistry, determination of chromogranin A level in serum, and specific hormonal evaluation in case of hormonally active tumors. None of the patients had been treated with the long-acting somatostatin analogues oct-

reotide or lanreotide during at least the last 6 weeks before receiving radiopeptide treatment or with short-acting octreotide during the last 3 days before therapy. Written informed consent was available for each patient. All patients were discussed between a surgeon and a therapist from a department of nuclear medicine before the decision for radiotherapy was made.

Tumor imaging. During the initial phase ¹¹¹In-DTPAOC (185-200 MBq) was carried out in planar and SPECT standard techniques.^{3,12} For ⁶⁸Ga-DOTATOC-based imaging introduced more recently, ⁶⁸Ga was produced on site by an optimized technique as described elsewhere. Patients were administered a bolus intravenous injection of 60-150 MBq ⁶⁸Ga-DOTATOC; then PET dynamic imaging was started immediately and continued for 84 minutes. Delayed static images were acquired from 90 minutes up to 180 minutes after injection at different bed positions. All scans were carried out on a dedicated multislice ring detector scanner system (ECAT Exact 922; Siemens/CTI, Knoxville, Tenn) in three-dimensional mode.^{3,6} For ⁶⁸Ga-DOTATOC PET/CT imaging, a dual-modality PET/CT (Siemens Medical Solutions, Hoffman Estates, Ill) composed of 2 components—a full ring PET tomography and a dual-slice CT scanner—was used.¹³

Radiotracer. The somatostatin analogue DOTATOC was synthesized as previously described.⁶ For radiolabeling, ⁹⁰YCl₃ or ¹⁷⁷LuCl₃ was added to DOTATOC lyophilized kits according to the protocol reported by Forrer et al¹⁴ and Waldherr et al.^{6,15}

Treatment. For each treatment session, the patients were hospitalized in the Department of Nuclear Medicine at the University Hospital Basel for 3 days in accordance with the legal requirements for radioactivity control. For the initial treatment, 2 applications of ⁹⁰Y-DOTATOC (cumulative dose of 7.4 GBq/m² ⁹⁰Y-DOTATOC) were used. During each ⁹⁰Y-DOTATOC application, 37 to 111 MBq of ¹¹¹In-DOTATOC was injected simultaneously with an aim to control the DOTATOC binding. Static images were acquired 1 hour, 24 hours, 48 hours and, in some cases, 72 hours after injection of the radionuclide. All patients received at least 2 treatment sessions. The treatments were repeated in intervals of 8 to 10 weeks. In case of the necessity of multiple treatments due to tumor relapse or for biophysical reasons (small size of the lesion), a switch to ¹⁷⁷Lu-DOTATOC (fixed activity, 7400 MBq of ¹⁷⁷Lu-DOTATOC) was attempted to avoid toxicity that can occur after treatment with ⁹⁰Y-DOTATOC. An infusion of 2000 mL of an amino

Table I. Patient characteristics

Patient no.	Gender	Age (y)	Primary tumor	History of tumor (mo)	Tumor manifestation		No. of ⁹⁰ Y-DOTATOC treatments
					before first ⁹⁰ Y-DOTATOC treatment	Previous therapy	
1	F	76	NET-ileum	15	L	S, RFA,TACE, Oct	2
2	F	45	NET-pancreas	72	L, LN	S	1
3	M	29	Paraganglioma-neck	70	L, M, PR	S	1
4	M	62	NET-pancreas	24	L, LN	S, Oct	2
5	M	52	NET-pancreas	26	L	S, TACE, Oct	2
6	M	47	NET-pancreas	18	L	Oct	2
7	M	65	NET-pancreas	26	L	TACE, Oct	1
8	F	54	NET-pancreas	49	L, LN, LU	LTX, Oct	2
9	M	42	Gastrinoma-pancreas	12	L	S, Oct	4
10	M	46	NET-unknown origin	15	L	TACE, Oct	2
11	F	58	NET-ileum	35	L, LN	TACE	2
12	M	63	NET-pancreas	60	L	CT, IFN	2
13	M	49	NET-pancreas	16	L	Oct	2
14	M	43	NET-pancreas	21	L, LN	S, CT	3
15	F	60	NET-pancreas	26	L	CT, IFN,Oct	2
16	M	58	NET-pancreas	18	L, LN	TACE, Oct	2
17	M	55	NET-pancreas	14	L, LN	S, CT, Oct	3
18	M	65	NET-pancreas	18	L	Oct	2
19	M	50	NET-pancreas	22	L	S, Oct	2
20	F	56	NET-pancreas	16	L	TACE, Oct	2

⁹⁰Y-DOTATOC, Yttrium-90 1,4,7,10-tetra-azacyclododecan-4,7,10-tricarboxy-methyl-1-yl-acetyl-D-Phe¹ Trp³-octreotide;

¹⁷⁷Lu-DOTATOC, lutetium-177 1,4,7,10-tetra-azacyclododecan-4,7,10-tricarboxy-methyl-1-yl-acetyl-D-Phe¹ Trp³-octreotide;

IFN, alpha-interferon; L, liver; LN, lymph nodes; LTX, liver transplantation; LU, lung; M, mediastinum; NET, neuroendocrine tumor;

Oct, octreotide; PR, paravertebral; RFA, radiofrequency ablation; S, surgery; TACE, transarterial chemoembolisation.

*After treatment initiation.

†No change in response 3 mo after last DOTATOC treatment.

acid solution (Ringer lactated Hartmann solution [Proteinsteryl; B. Braun Medical AG, Sempach, Germany], HEPA 8%, Mg 5-Sulfat [B. Braun Medical AG]) was given to inhibit tubular reabsorption of the radiopeptide started 30 minutes before administration of the radiopharmaceutical and continued until up to 4 hours after administration. Imaging and dosimetry were performed in accordance with the protocols as previously reported.^{14,15} After demission, complete blood cell and platelet counts were measured every 2 weeks for at least 8 weeks.

Evaluation of tumor response and measurement of quality of life. Eight to 12 weeks after radiopeptide therapy, response to treatment was assessed by CT. For evaluation of tumor growth, WHO standard criteria were used. Blood counts and chemistry, chromogranin A measurement, and tumor-specific hormonal examinations were additional parts of the evaluation protocol. Side effects of ⁹⁰Y-DOTATOC were documented according to the National Cancer Institutes (NIH) Cancer Clinical Trials Common Toxicity Criteria (CTC). For quality-of-life assessment, an SF-36 survey (SF-36 Health

Survey, version 2; IQOLA Project, Standard, Germany) for quality-of-life measurement was applied. After completion of treatment, follow-up examinations including ultrasonography took place every 3 months.

RESULTS

Twenty patients, 14 men and 6 women aged 29 to 76 years (median age, 53.8 years) referred to our center for treatment of neuroendocrine hepatic metastases were included in this study. Of these patients, 15 presented with NET of the pancreas, 2 with midgut NET, 1 with a sporadic gastrinoma, 1 with a paraganglioma, and 1 with a NET of unknown primary origin. Further patient characteristics are given in Table I.

Multiple bilobar liver lesions were demonstrable in ¹¹¹In-DTPAOC or ⁶⁸Ga-DOTATOC PET/CT in 19 patients. Additional extrahepatic metastatic spread, not documented in standard imaging techniques, was evident in 36.8% of the patients (Figs 1 and 2). In the patient with a paraganglioma (no. 3), in whom several resections for metastatic disease in various localizations had been carried out in

Table I. (Continued)

Total dose of ⁹⁰ Y-DOTATOC MBq	Toxicity grade after ⁹⁰ Y-DOTATOC treatment	No. of ¹⁷⁷ Lu-DOTATOC treatments	Total dose of ¹⁷⁷ Lu-DOTATOC MBq	Response 3 mo after last DOTATOC treatment	Follow-up (mo)*	Present status†
11,100	0			Stable disease	6	Alive
5550	1	2	14,800	Partial response	16	Alive
6475	1	2	12,950	Partial response	18	Alive
13,875	0			Stable disease	24	Alive
14,800	0			Progressive disease	36	Dead
15,540	0			Partial response	29	Alive
6475	1	2	9,546	Stable disease	8	Alive
10,730	3	2	12,950	Progressive disease	25	Dead
12,654	0			Stable disease	27	Alive
11,840	0			Partial response	19	Alive
15,170	0			Progressive disease	18	Alive
7400	0			Stable disease	12	Alive
7400	1			Partial response	15	Alive
11,100	0			Progressive disease	24	Dead
7400	1	2	14,800	Stable disease	21	Alive
7400	0			Stable disease	26	Alive
11,100	1	2	11,100	Stable disease	14	Alive
7400	0			Stable disease	20	Alive
11,100	0			Stable disease	24	Alive
9250	1			Stable disease	14	Alive

the past, ⁶⁸Ga-DOTATOC PET/CT disclosed recurrent metastatic bulk in the mediastinum, within the liver, and alongside the vertebral column (Fig 3 A and B). A preceded metaiodobenzylguanidine (¹²³I-MIBG) scintigraphy showed no uptake in any of these positions, whereas standard ¹¹¹In-DTPAOC scanning revealed the mediastinal lesion only.

Each patient underwent at least 2 treatment sessions. In 8 patients the therapy had to be repeated more than once (median, 3 times; range, 2-5 times). Whereas the treatment concept encompassed only ⁹⁰Y-DOTATOC in 14 (70%) patients, additional sessions with ¹⁷⁷Lu-DOTATOC took place in 6 individuals. In 5 of them, the switch to [¹⁷⁷Lu] was enforced because of tumor relapse, and in 1 patient because of the small size and multilocularity of the neoplastic lesions. After ⁹⁰Y-DOTATOC treatment, toxicity grade 1 concerning hemoglobin and/or creatinine was evident in 7 patients. In 1 additional patient (no. 8), who was under immunosuppressive therapy after liver transplantation (LTX), a decrease in hemoglobin level from 11.5 g/dL to 6.2 g/dL with requirement for administration of 4 units of blood was observed. No serious adverse events occurred, and the treatment did not have to be discontinued in any patient.

Concerning the tumor growth, partial response was documented in 5 (25%) patients and stable dis-

ease in 11 (55%) patients. Progressive disease was seen in 4 patients, 3 of whom died during the follow-up (Fig 4). Chromogranin A levels decreased post-therapeutically in the subgroup of patients who attained partial response; however, they remained unchanged in cases of stable disease (Table II). In both patients symptomatic before treatment, clinical improvement and decrease of specific hormones occurred. In the patient with a NET-ileum (no. 1), serotonin decreased from 450 to 186 μg/L (reference, 110-330 μg/L), and in the patient with a gastrinoma a decrease in the serum gastrin level from 288 to 177 ng/L (reference, < 115 ng/L) was documented. In the subgroup of patients with partial response or stable disease, 10 reported improvement in their quality of life (Table III).

During the follow-up since the last DOTATOC treatment session, 2 patients underwent further invasive interventions for their metastatic disease. In the patient with a paraganglioma (no. 3) a combined resection of a liver metastasis and of the paravertebral lesions was carried out (Fig 3 A and B). This strategy attributed to the unique behavior of the metastatic deposits with a very high uptake of the radionuclide within the mediastinal tumor and virtually no uptake below the diaphragma stellae. The second patient required a left hepatectomy because of upper abdominal discomfort caused by

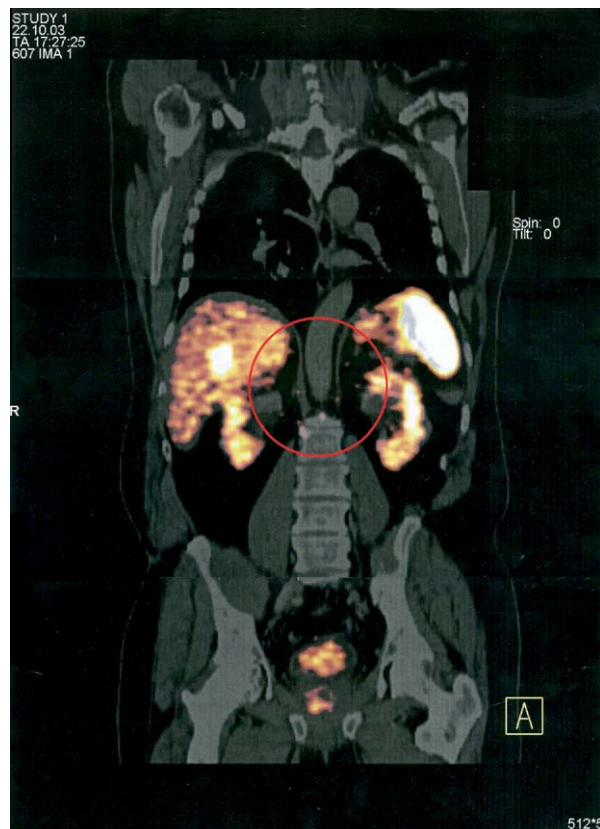


Fig 1. Anterior ^{68}Ga -DOTATOC PET/CT image (85 MBq) in a patient with multiple liver and abdominal lymph node metastases (*circle*) of a neuroendocrine pancreatic tumor.

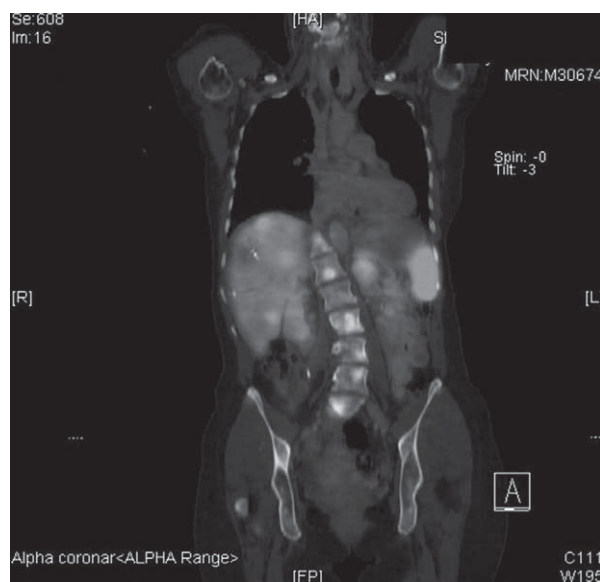

Fig 2. Anterior ^{68}Ga -DOTATOC PET/CT image (85 MBq) disclosing metastases of a neuroendocrine tumor of the ileum within the liver, bone, and upper abdominal lymph nodes.

significant tumor necrosis within the left liver lobe (Fig 5 A and B).

DISCUSSION

Advanced NETs lack a widely accepted rationale for treatment. The decision of which treatment option to choose is triggered by the subjective experience of the therapist and the local availability of the methodology rather than by evidence-based information.

After it has been shown that NETs can be visualized by targeting with specific radioisotopes, peptide receptor radionuclide therapy (PRRT) has been integrated into the treatment concept of metastasized NETs, mainly in those originating from the gastroenteropancreatic system.¹¹ In the initial studies on the effectiveness of ^{111}In -pentetreotide treatment, responses have been seen in 62% to 69% of patients.^{16,17} More recently, Pasiaka et al¹⁸ documented symptomatic benefit in 55% of the patients subjected to this treatment. While therapy with this radiopharmaceutical led to improvement of clinical symptoms in a significant portion of patients, tumor regression was rather uncommon.

For pretherapeutic tumor visualization traditionally ^{111}In -DTPAOC scintigraphy was used.² By binding of ^{111}In to DOTATOC or DOTA-1-Nal³ octreotide (DOTANOC), and most recently by labeling of DOTATOC or DOTANOC with ^{68}Ga , imaging results can be further improved in terms of detection of very small lesions or tumors with a low density of SSTs.^{3,4,8,12,19} During planning of endocrine surgery, particular attention should be given to ^{68}Ga -DOTATOC in connection with PET/CT because, apart from a very high tumor to physiologic background ratio, this technology offers bidimensional anatomic landmarking possibilities, thus enabling a focused strategic approach. Although in our experience, CT proved to be more sensitive than ^{111}In -DTPAOC and ^{68}Ga -DOTATOC PET in evaluation of neuroendocrine hepatic lesions, ^{111}In -DTPAOC and particularly ^{68}Ga -DOTATOC PET/CT provide excellent results in detecting extrahepatic tumor spread. As shown in this study, 40% of the patients exhibited with numerous extrahepatic somatostatin receptor-positive lesions not disclosed by standard imaging (Fig 1). The value of this new localization technique could be impressively shown in the patient with a paraganglioma (no. 3), in whom neither ^{123}I -MIBG nor standard ^{111}In -DTPAOC scintigraphy detected the lesions revealed by ^{68}Ga -DOTATOC. In addition, these results underline the hypothesis that, in the course of the disease, NETs can dedifferentiate and subsequently lose their primary character. Apart

Explore Litigation Insights

Docket Alarm provides insights to develop a more informed litigation strategy and the peace of mind of knowing you're on top of things.

Real-Time Litigation Alerts



Keep your litigation team up-to-date with **real-time alerts** and advanced team management tools built for the enterprise, all while greatly reducing PACER spend.

Our comprehensive service means we can handle Federal, State, and Administrative courts across the country.

Advanced Docket Research



With over 230 million records, Docket Alarm's cloud-native docket research platform finds what other services can't. Coverage includes Federal, State, plus PTAB, TTAB, ITC and NLRB decisions, all in one place.

Identify arguments that have been successful in the past with full text, pinpoint searching. Link to case law cited within any court document via Fastcase.

Analytics At Your Fingertips



Learn what happened the last time a particular judge, opposing counsel or company faced cases similar to yours.

Advanced out-of-the-box PTAB and TTAB analytics are always at your fingertips.

API

Docket Alarm offers a powerful API (application programming interface) to developers that want to integrate case filings into their apps.

LAW FIRMS

Build custom dashboards for your attorneys and clients with live data direct from the court.

Automate many repetitive legal tasks like conflict checks, document management, and marketing.

FINANCIAL INSTITUTIONS

Litigation and bankruptcy checks for companies and debtors.

E-DISCOVERY AND LEGAL VENDORS

Sync your system to PACER to automate legal marketing.