

# RISKS OF INTRAVITREOUS INJECTION: A COMPREHENSIVE REVIEW

RAMA D. JAGER, MD, MBA,\* LLOYD PAUL AIELLO, MD, PhD,\* SAMIR C. PATEL, MD,†  
EMMETT T. CUNNINGHAM, JR., MD, PhD, MPH‡

---

**Purpose:** To evaluate the prevalence of the most common serious adverse events associated with intravitreal (IVT) injection.

**Methods:** A systematic search of the literature via PubMed from 1966 to March 1, 2004, was conducted to identify studies evaluating the safety of IVT injection. Data submitted in New Drug Applications to the U.S. Food and Drug Administration for drugs administered into the vitreous were included where available. Serious adverse events reported in each study were recorded, and risk per eye and risk per injection were calculated for the following serious adverse events: endophthalmitis, retinal detachment, iritis/uveitis, intraocular hemorrhage, ocular hypertension, cataract, and hypotony. Rare complications also were noted.

**Results:** Data from 14,866 IVT injections in 4,382 eyes were analyzed. There were 38 cases of endophthalmitis (including those reported as pseudoendophthalmitis) for a prevalence of 0.3% per injection and 0.9% per eye. Excluding cases reported specifically as pseudoendophthalmitis, the prevalence of endophthalmitis was 0.2% per injection and 0.5% per eye. Retinal detachment, iritis/uveitis, ocular hypertension, cataract, intraocular hemorrhage, and hypotony were generally associated with IVT injection of specific compounds and were infrequently attributed by the investigators to the injection procedure itself. Retinal vascular occlusions were described rarely in patients after IVT injection, and it was unclear in most cases whether these represented true injection-related complications or chance associations.

**Conclusion:** The risk of serious adverse events reported after IVT injection is low. Nevertheless, careful attention to injection technique and appropriate postinjection monitoring are essential because uncommon injection-related complications may be associated with permanent vision loss.

RETINA 24:676–698, 2004

---

Over the last 2 decades, the use of intravitreal (IVT) injection has gained increasing acceptance in the therapeutic management of many intraocular

---

From \*the Beetham Eye Institute, Joslin Diabetes Center and Department of Ophthalmology, Harvard Medical School, Boston, Massachusetts; the †Department of Ophthalmology and Visual Science, University of Chicago, Chicago, Illinois; and the ‡Department of Ophthalmology, New York University School of Medicine, New York, New York.

Samir C. Patel and Emmett T. Cunningham, Jr., are employees of Eyetech Pharmaceuticals, Inc., New York, NY.

Although the term “intravitreal” is used colloquially quite often, we have used “intravitreal” as the grammatically correct and preferred term in this review.

Reprints: Dr. Emmett T. Cunningham, Jr., Eyetech Pharmaceuticals, Inc., 3 Times Square, 12th Floor, New York, NY 10036; e-mail: emmett.cunningham@eyetech.com

diseases, particularly disorders affecting the posterior segment. A highly effective and frequently used means of administering antiviral agents in the treatment of cytomegalovirus (CMV) retinitis, direct injection of antiviral agents into the vitreous of patients with acquired immunodeficiency syndrome maximizes intraocular drug levels while minimizing the risk of toxicity associated with systemic administration of these agents.<sup>1–11</sup> In addition, IVT injection of various gases has been used as a less-invasive alternative to scleral buckling for the management of retinal detachment in the setting of pneumatic retinopathy<sup>12–14</sup> and for the administration of tissue plasminogen activator ([TPA] Retavase; Centocor, Malvern, PA)<sup>15,16</sup> in the treatment of submacular hem-

orrhage and acute central retinal vein occlusion. Needle aspiration of the vitreous—procedurally similar to IVT injection—is used routinely to biopsy the vitreous. In addition to the long-standing practices of vitreous Gram staining, microbial culture, and sensitivity analysis in the setting of suspected endophthalmitis,<sup>17</sup> vitreous sampling may also be used to obtain DNA for polymerase chain reaction–based analyses for patients suspected of having necrotizing herpetic retinitis<sup>18–22</sup> or toxoplasmic retinochoroiditis.<sup>23</sup>

Recent investigations into the treatment of retinal neovascularization, retinal edema, and posterior segment inflammation have led to the development of new biologic and pharmacologic agents that are optimally administered directly into the vitreous. IVT injection of these compounds is being investigated, both as a method of achieving vitreous concentrations beyond those obtainable with systemic administration and as a means of avoiding potential systemic adverse effects. Several of these investigational agents, such as the therapeutic aptamer oligonucleotide pegaptanib sodium (Macugen; Eyetech Pharmaceuticals, New York, NY)<sup>24–26</sup> and the monoclonal antibody fragment ranibizumab (Lucentis; Genentech, San Francisco, CA),<sup>27,28</sup> are currently undergoing clinical evaluation for the treatment of neovascular age-related macular degeneration (AMD) and, in the case of pegaptanib sodium, for diabetic macular edema and retinal vein occlusion. In addition, the off-label use of IVT triamcinolone acetonide (Kenalog; Bristol-Myers Squibb, New York, NY) injection is under investigation for a number of disorders, including macular edema<sup>29,30</sup> and retinal neovascularization.<sup>31–34</sup>

Because the potential advantages of IVT injection have become more widely appreciated and the number of possible applications has grown, questions have arisen regarding risks associated with this route of administration. Several potential complications of IVT injection, such as endophthalmitis, retinal detachment, traumatic cataract, and intraocular hemorrhage, can be vision threatening. A sufficient body of literature now exists to support a thorough review of the risks associated with IVT injection in managing ocular diseases. To that end, as background, we present a brief historical overview of the use of IVT injection in humans over the last century and a synopsis of recently published studies on the pharmacokinetic properties of agents administered directly into the vitreous. We then present the results of a comprehensive, systematic review of the literature from which we calculated prevalence estimates for the most common complications associated with IVT injection.

The analyzed reports of IVT injection varied considerably in size, design, and indication, and in most

instances, the reported rates of the various complications were quite low. Although efforts were made to distinguish the risks associated with the specific agents being administered from the risks related to the IVT injection procedure per se, in some instances, such distinctions were difficult to make. Together, these factors limit to some extent the generalizability of cross-study comparisons and analyses. Despite these inherent shortcomings, to our knowledge, this review represents the most extensive assessment of the risks associated with IVT injection compiled to date.

### A Historical Perspective on the Use of IVT Injection

IVT injection has been used in the treatment of human ocular disease for nearly a century. Figure 1<sup>24,25,27,28,34–48</sup> presents a timeline of important advances in the use of this technique from its earliest therapeutic application through the present. Although this timeline is intended to highlight some of the major achievements in the development of IVT therapeutics, it is not meant to be an exhaustive compilation or to acknowledge the many excellent investigative studies that served as a foundation for these advances. Initially reported in 1911 by Ohm<sup>35</sup> as a means to introduce air for retinal tamponade and repair of detachment, the IVT administration of pharmaceutical agents was pioneered in the mid-1940s with the use of penicillin to treat endophthalmitis.<sup>36,37</sup> Unfortunately, at that time drug administration often was delayed for days or even weeks after the infection became established, making most of these early attempts unsuccessful. The technique was used infrequently, therefore.

During the 1950s and 1960s, the use of IVT injection still was limited to the administration of air<sup>38</sup> or silicone oil<sup>39</sup> in the treatment of retinal detachment. By the 1970s, the advent of newer antimicrobial agents, combined with the continued poor success of alternative treatment options, led to renewed interest in IVT therapy for endophthalmitis. Animal studies demonstrating the safety of this route of administration<sup>49,50</sup> were followed by the publication of two case series describing successful treatment of endophthalmitis using IVT injection in patients.<sup>40,41</sup> Although still considered experimental at that time,<sup>51</sup> wider use of IVT injection to treat endophthalmitis was being advocated due to the poor treatment outcomes reported with systemic administration of antibiotics, which generally produced suboptimal drug levels in the vitreous.<sup>52</sup>

The development of IVT injection for the treatment of ophthalmic conditions other than endophthalmitis and retinal detachment lagged even further behind,

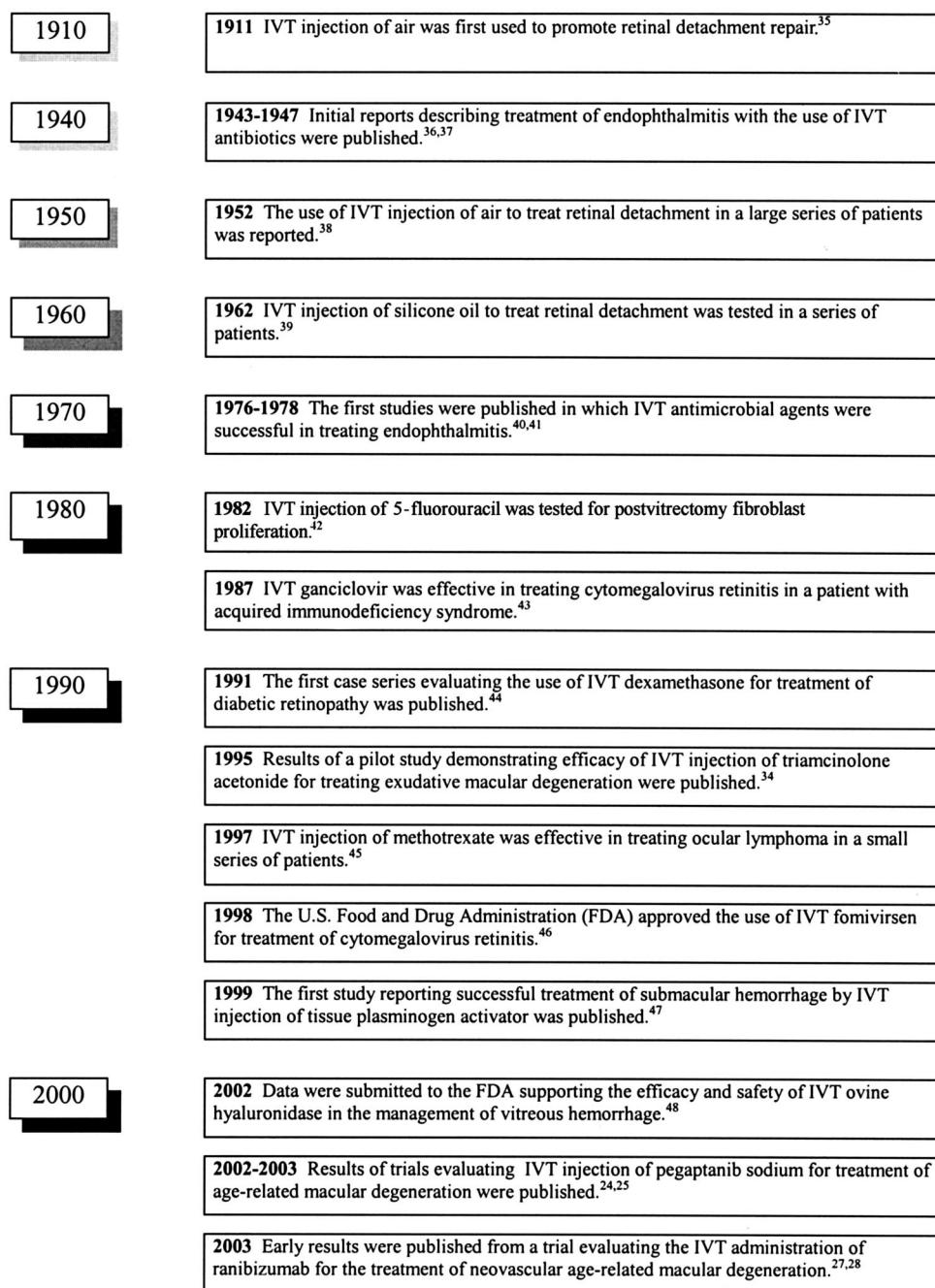


Fig. 1. A timeline of important advances in the use of intravitreal (IVT) injections to treat human ocular diseases.

perhaps because of perceived risks related to the procedure and because endophthalmitis and retinal detachment generally have the greatest likelihood for acute and irreversible vision loss. Although IVT injection of corticosteroids was evaluated in an animal model of ocular inflammation in the early 1980s,<sup>53,54</sup> there were no publications describing the use of IVT corticosteroids in humans until the 1990s. The first new application for IVT injection was not tried until

1982, when a pilot study assessing the efficacy and safety of 5-fluorouracil delivered as an IVT injection for the prevention of postvitrectomy fibroblast proliferation in patients with proliferative retinopathy was initiated.<sup>42</sup> This was followed in 1987 by the use of IVT ganciclovir sodium (Cytovine; Roche Pharmaceuticals, Nutley, NJ) in the treatment of CMV retinitis in a patient with acquired immunodeficiency syndrome.<sup>43</sup>

The gradually increasing confidence in the safety of IVT injection that emerged as a result of these studies led to the evaluation of IVT administration of a number of other agents throughout the 1990s. Blankenship<sup>44</sup> demonstrated in 1991 that dexamethasone was well tolerated but of no therapeutic value for postvitrectomy treatment of diabetic retinopathy. Penfold et al<sup>34</sup> in a pilot study demonstrated that triamcinolone acetonide, a longer-acting corticosteroid, was well tolerated in patients with exudative AMD. Other novel applications of IVT injection in the 1990s included the use of methotrexate for treatment of ocular lymphoma<sup>45</sup> and the injection of TPA for the management of submacular hemorrhage.<sup>47</sup> In 1998, fomivirsen sodium (Vitravene; Isis Pharmaceuticals, Carlsbad, CA), an antisense compound used to treat active CMV retinitis, was the first compound to be approved specifically for IVT injection by the U.S. Food and Drug Administration, representing a milestone achievement in the use of IVT therapy (Fig. 1).<sup>46</sup>

The pace of development of new applications for IVT injection continues to accelerate, with three new investigational drug products in clinical trials in the early 2000s. These include the vascular endothelial growth factor inhibitors ranibizumab<sup>27</sup> and pegaptanib sodium<sup>24–26</sup> for the treatment of neovascular AMD and ovine hyaluronidase (Vitrace; ISTA Pharmaceuticals, Irvine, CA),<sup>48</sup> which was recently approved by the U.S. Food and Drug Administration as a dispersion agent for other injected drugs and is still seeking approval for the treatment of vitreous hemorrhage.<sup>55</sup> The use of IVT injection as a method for localized adenovirus vector-mediated gene transfer to treat retinitis pigmentosa and AMD is also being explored.<sup>56,57</sup> With numerous novel ophthalmic therapies currently poised to enter into clinical trials, it is likely that the number of drugs under development for IVT injection will continue to increase rapidly.

### Pharmacokinetic Characteristics of Compounds Injected Into the Vitreous

Drug concentrations in the vitreous are determined not only by the amount of drug given but also by the distribution and clearance of such compounds.<sup>58,59</sup> As with other routes of drug administration, pharmacokinetic characteristics are dependent on both the anatomical and physiologic features at the site of administration<sup>58–60</sup> and the physicochemical properties of the agent administered.<sup>61,62</sup> Although several investigators have explored the pharmacokinetic properties of the IVT injection of selected compounds in animal models<sup>58–60,62,63</sup> and to a limited extent in hu-

mans<sup>64–66</sup> over the past 2 decades, this topic remains complex and incompletely understood.

The composition of the vitreous is unique in that it is a highly hydrated, avascular, gelatinous body containing 98% water. Vitreous structural elements composed of type II collagen and hyaluronic acid occupy <1% of the total volume.<sup>61</sup> The human eye contains 3 mL to 4 mL of vitreous humor.<sup>67</sup> The vitreous can move during eye motion, particularly in the elderly who normally have a more liquefied vitreous than younger individuals.<sup>61</sup> By 80 years of age, approximately one half of the vitreous in most people is estimated to exist in a liquid state.<sup>68</sup> Although little is known about the effect of age on the disposition of compounds administered directly into the vitreous, such age-related changes in vitreous characteristics merit consideration because many indications for IVT injection affect elderly patients disproportionately.

Although there is a relative barrier between the anterior and the posterior segments of the eye, injected substances move throughout the vitreous fairly readily by either diffusion or bulk flow. Whereas bulk flow tends to be the primary means of movement when the vitreous is formed, when the vitreous body is partly removed, degenerated, or collapsed, the exchange movement tends to be due largely to diffusion. Gradients exist in both directions between the vitreous and plasma. These gradients are a result of several mechanisms, including diffusion and bulk flow processes within the vitreous body as mentioned above, the presence of physiologic blood-ocular barriers vis-à-vis active and passive transport, and metabolism within the eye itself.<sup>69</sup>

Alterations of the normal anatomy and physiology of the eye and the size of the administered compound have been demonstrated to be factors that impact the distribution and elimination of drugs from the vitreous in animal studies. A history of vitrectomy, aphakia, or pseudophakia has been shown to increase the rate of distribution and clearance of amphotericin B, for example. Radiolabeled amphotericin B elimination from aphakic, vitrectomized rabbit eyes occurred in 1.8 days compared with 15.1 days for normal rabbit eyes.<sup>59</sup> A similarly rapid clearance of triamcinolone acetonide in aphakic, vitrectomized rabbit eyes (6.5 days) compared with clearance from aphakic, nonvitrectomized eyes (16.8 days) and normal, phakic, nonvitrectomized eyes (41 days) was reported by Schindler et al.<sup>60</sup> In this latter study, high-performance liquid chromatography was unable to detect the drug in 5 of 6 normal rabbit eyes at 21 days after IVT injection. Uptake of triamcinolone acetonide by ocular tissues is apparently quite slow, because <1% of the compound was found in the iris ciliary body, lens,

retina, pigment epithelium, and sclera at 72 hours after injection.<sup>63</sup>

The pharmacokinetic properties of compounds in the vitreous have been observed to change in the setting of inflammation or infection, such as endophthalmitis. Using a rabbit model, Coco et al<sup>58</sup> estimated that the half-life of vancomycin in normal, uninflamed eyes was  $\approx 62$  hours, compared with 14 hours in eyes in which endophthalmitis had been experimentally induced by injecting *Staphylococcus aureus* into the vitreous, a  $>4$ -fold increase. The reverse was true for plasma concentrations. These data led the investigators to suggest that the elimination of vancomycin was enhanced in the setting of inflammation or infection, most probably due to breakdown of the blood-retinal barrier, which when intact acts to limit drug clearance.<sup>58</sup>

The size of the administered compound has been shown to affect the half-life in the vitreous. Full-length radiolabeled humanized monoclonal antibodies (molecular weight,  $\approx 150$  kd) injected into the vitreous of rhesus macaques were found not to penetrate the inner limiting membrane of the retina, while Fab antibody fragments (molecular weight,  $\approx 50$  kd) diffused through the neural retina to the retinal pigment epithelial layer within 1 hour.<sup>62</sup> Consequently, the half-life in the vitreous was 5.6 days for the full-length antibody and 3.2 days for the Fab antibody fragment.<sup>62</sup>

Specific pharmacokinetic profiling of compounds administered into the vitreous in humans has been limited. Two studies have evaluated the duration of detectable concentrations of triamcinolone acetonide in aqueous humor samples.<sup>64,65</sup> Neither study attempted to identify the route of elimination of triamcinolone acetonide from the eye or the levels of compound that could be achieved in various ocular compartments after IVT injection. Pharmacokinetic studies of pegaptanib sodium injected into the vitreous humor of rhesus monkeys have shown that vitreous humor and plasma concentrations were linearly related to the dose administered with a half-life of  $\approx 4$  days. In addition, pegaptanib sodium sampled from the vitreous at 28 days was fully active.<sup>67</sup>

Recent computer simulations have suggested that both anterior and posterior routes of elimination may be important in the clearance of drugs from the vitreous.<sup>61</sup> Although the crystalline lens is highly impermeable to water and to many drugs, the anterior hyaloid membrane, which separates the vitreous from the aqueous, is thin and porous, offering little resistance to diffusion. Because aqueous turnover is very rapid, with a residence time in the eye of  $\approx 2.5$  hours,<sup>61</sup> in aphakic and pseudophakic patients aqueous clearance can represent a major route of elimination of compounds injected into the vitreous. In contrast, elimi-

nation by the posterior route is facilitated by active unidirectional drug transport at the posterior vitreous surface, as demonstrated by studies in which fluorescein movement through the vitreous was monitored.<sup>66</sup> The computer model predicts that a relatively small molecule will be quickly cleared from the vitreous by absorption through the retina or by release into the aqueous.<sup>61</sup> In contrast, a larger molecule would diffuse more slowly, relying on bulk flow to transverse the vitreous, and clearance will occur primarily through the retina and not the aqueous.<sup>61</sup> Although these findings are largely hypothetical in the absence of empirical data, they do suggest that the pharmacokinetic properties of compounds administered into the vitreous can be complex and influenced by a number of factors.

## Assessment of Complications Associated With the Use of IVT Injection

### Methods

A systematic review of the literature via PubMed from 1966 to March 1, 2004, using the search terms “intravitreous,” “intravitreal,” and “endophthalmitis” was conducted to identify studies and case series reporting the safety of IVT injection. The search was limited to primary reports published in English. Publications also were retrieved using the “related articles” function of PubMed, and bibliographies from all articles selected for analysis were reviewed to identify additional citations. More than 220 references were reviewed.

The following types of reports were included: (a) all randomized, controlled human clinical trials using IVT injection; (b) prospective or retrospective case series that included  $\geq 20$  eyes; and (c) safety data from U.S. Food and Drug Administration New Drug Applications for compounds not yet approved for use in the United States where adverse events related to IVT injection were reported. The following types were excluded: (a) reports in which compounds were administered into the vitreous through sclerotomy incisions during vitrectomy; (b) reports in which compounds were administered by IVT injection in conjunction with other ocular procedures, such as scleral buckling or vitrectomy; (c) reports in which IVT injections were administered in eyes as a treatment for endophthalmitis; and (d) reports that, in the opinion of the authors, lacked relevant data, provided data of unacceptable quality, or duplicated data sets found in more-comprehensive publications. There were no exclusions based on the length of the follow-up period.

# Explore Litigation Insights

Docket Alarm provides insights to develop a more informed litigation strategy and the peace of mind of knowing you're on top of things.

## Real-Time Litigation Alerts



Keep your litigation team up-to-date with **real-time alerts** and advanced team management tools built for the enterprise, all while greatly reducing PACER spend.

Our comprehensive service means we can handle Federal, State, and Administrative courts across the country.

## Advanced Docket Research



With over 230 million records, Docket Alarm's cloud-native docket research platform finds what other services can't. Coverage includes Federal, State, plus PTAB, TTAB, ITC and NLRB decisions, all in one place.

Identify arguments that have been successful in the past with full text, pinpoint searching. Link to case law cited within any court document via Fastcase.

## Analytics At Your Fingertips



Learn what happened the last time a particular judge, opposing counsel or company faced cases similar to yours.

Advanced out-of-the-box PTAB and TTAB analytics are always at your fingertips.

## API

Docket Alarm offers a powerful API (application programming interface) to developers that want to integrate case filings into their apps.

## LAW FIRMS

Build custom dashboards for your attorneys and clients with live data direct from the court.

Automate many repetitive legal tasks like conflict checks, document management, and marketing.

## FINANCIAL INSTITUTIONS

Litigation and bankruptcy checks for companies and debtors.

## E-DISCOVERY AND LEGAL VENDORS

Sync your system to PACER to automate legal marketing.