

# A Phase I Study of Intravitreal Vascular Endothelial Growth Factor Trap-Eye in Patients with Neovascular Age-Related Macular Degeneration

Quan Dong Nguyen, MD, MSc,<sup>1</sup> Syed Mahmood Shah, MBBS,<sup>1</sup> David J. Browning, MD,<sup>2</sup> Henry Hudson, MD,<sup>3</sup> Peter Sonkin, MD,<sup>4</sup> Seenu M. Hariprasad, MD,<sup>5</sup> Peter Kaiser, MD,<sup>6</sup> Jason S. Slakter, MD,<sup>7</sup> Julia Haller, MD,<sup>1</sup> Diana V. Do, MD,<sup>1</sup> William F. Mieler, MD,<sup>5</sup> Karen Chu, MS,<sup>8</sup> Ke Yang, PhD,<sup>8</sup> Avner Ingerman, MD,<sup>8</sup> Robert L. Vitti, MD, MBA,<sup>8</sup> Alyson J. Berliner, MD, PhD,<sup>8</sup> Jesse M. Cedarbaum, MD,<sup>8</sup> Peter A. Campochiaro, MD<sup>1</sup>

**Purpose:** To determine the safety, tolerability, maximum tolerated dose, and bioactivity of an intravitreal injection of vascular endothelial growth factor (VEGF) Trap-Eye, a fusion protein of binding domains from human VEGF receptors 1 and 2 with human immunoglobulin-G Fc that binds VEGF family members, in patients with neovascular age-related macular degeneration (AMD).

**Design:** Dose-escalation, multicenter, interventional clinical trial.

**Participants:** Twenty-one patients (13 female, 8 male) with neovascular AMD (NVAMD) and lesions  $\leq 12$  disc areas in size and  $\geq 50\%$  active choroidal neovascularization (CNV) with best-corrected visual acuity (BCVA)  $\leq 20/40$  received a single intraocular injection of 0.05 mg (n = 3), 0.15 mg (n = 3), 0.5 mg (n = 3), 1 mg (n = 6), 2 mg (n = 3), or 4 mg (n = 3) of VEGF Trap-Eye.

**Methods:** Safety assessments included eye examinations, vital signs, and laboratory tests. Measures of bioactivity included changes from baseline in BCVA, optical coherence tomography (OCT), and fluorescein angiography. The primary end point was 6 weeks and patients were followed up for 12 weeks.

**Main Outcome Measure:** Safety assessments.

**Results:** There were no serious adverse events and no identifiable intraocular inflammation. The mean decrease in excess foveal thickness for all patients was 104.5  $\mu\text{m}$  at 6 weeks, and the mean increase in visual acuity was 4.43 letters. In the 2 highest dose groups combined (2 and 4 mg), the mean increase in BCVA was 13.5 letters, with 3 of 6 patients demonstrating improvement of  $\geq 3$  lines and 3 patients requiring no adjunctive treatment of any type for 12 weeks. Some showed elimination of fluorescein leakage and reduction in area of CNV.

**Conclusions:** Intravitreal injection of up to 4 mg of VEGF Trap-Eye in patients with NVAMD was well tolerated with no evidence of ocular inflammation. Although the number of patients in each cohort was small, there was evidence of bioactivity, because several patients, especially those receiving 2 or 4 mg of VEGF Trap-Eye, showed substantial improvement in BCVA associated with reductions in foveal thickness. Phase III trials to investigate the efficacy of intraocular VEGF Trap-Eye in patients with NVAMD are under way.

**Financial Disclosure(s):** Proprietary or commercial disclosure may be found after the references. *Ophthalmology* 2009;116:2141–2148 © 2009 by the American Academy of Ophthalmology.



Age-related macular degeneration (AMD) is the most common cause of severe vision loss in patients aged more than 60 years in developed countries.<sup>1</sup> Patients with non-neovascular AMD are at risk for development of choroidal neovascularization (CNV) and thereby converting to neovascular AMD (NVAMD). Patients with NVAMD account for only approximately 10% of patients with AMD, but they account for the majority of severe vision loss.<sup>1</sup>

The pathogenic events underlying conversion from non-neovascular to NVAMD are uncertain, but studies in animal

models suggest that increased expression of vascular endothelial growth factor (VEGF) is likely to play a critical role. Inhibition of VEGF receptor signaling by systemic administration of kinase inhibitors<sup>2</sup> or blockade of VEGF by intraocular injection of an anti-VEGF antibody fragment<sup>3</sup> significantly suppresses CNV in animal models. These data suggest that VEGF is an important therapeutic target for treatment of CNV. This concept has been confirmed in clinical trials testing the effects of VEGF antagonists in patients with NVAMD. Intraocular injections of pegaptanib

(Macugen, OSI Pharmaceuticals, Melville, NY), an aptamer that specifically binds VEGF<sub>165</sub>, every 6 weeks for 1 year in patients with NVAMD reduced the percentage of patients who experienced severe loss of vision ( $\geq 15$  letters) from 45% in the sham injection group to 30% but did not lead to significant improvement in vision.<sup>4</sup> Monthly intraocular injections of ranibizumab (Lucentis, Genentech, San Francisco, CA), a Fab fragment of an antibody that binds all isoforms of VEGF-A, reduced the percentage of patients who had severe loss of vision to 5% and caused significant improvement in visual acuity (VA) in 34% to 40%.<sup>5,6</sup> It is not certain why ranibizumab is so superior to pegaptanib, but one possibility is that other isoforms of VEGF in addition to VEGF<sub>165</sub> play an important role in the pathogenesis of CNV.

There are a number of gene products that share homology with VEGF-A and have similar activities because they activate VEGF receptor 1 or 2. The genes that code for VEGF-A and these other proteins, VEGF-B, C, and D, and placental growth factors 1 and 2, constitute the VEGF gene family. The role of VEGF family members other than VEGF-A in ocular neovascularization has not been completely elucidated, but there is evidence to suggest that placental growth factor 1 participates.<sup>7</sup>

VEGF Trap is a recombinant protein in which the binding domains of VEGF receptors 1 and 2 are combined with the Fc portion of immunoglobulin-G. The receptor portion of the molecule has a high affinity for all VEGF-A isoforms ( $K_d < 1$  pM), placental growth factors 1 and 2, and VEGF-B.<sup>8</sup> Therefore, VEGF Trap is distinguished from ranibizumab by its higher binding affinity for all VEGF-A isoforms and its ability to inhibit other VEGF family members. A randomized, multicenter, placebo-controlled clinical trial investigating the effect of intravenous VEGF Trap in patients with NVAMD showed elimination of approximately 60% of excess retinal thickness after either single or multiple infusions.<sup>9</sup> The maximum tolerated dose of intravenous VEGF Trap in this study population was 1.0 mg/kg; at 3 mg/kg, hypertension and proteinuria, which are class effects of

systemic anti-VEGF therapy, were noted. Thus, alternative routes of delivery to increase therapeutic window and to decrease adverse events, were investigated.

Intravitreal administration of VEGF Trap strongly suppressed laser-induced CNV in mice<sup>10</sup> and primates (Wiegand et al. ARVO abstract 1411, 2005). These findings led to the development of a formulation for intraocular delivery, VEGF Trap-Eye, a formulation using ultra-purified VEGF Trap with a combination and concentration of buffers compatible with ocular tissues. In primate toxicology studies, there were no systemic safety signals after intraocular injections of VEGF Trap-Eye, and there was an excellent ocular safety profile based on ocular examinations, color photography, fluorescein angiography (FA), electroretinography, and postmortem microscopic examination of ocular tissues.<sup>11</sup> The only abnormality identified was mild, reversible inflammation in the anterior chamber and vitreous in some primates after intraocular injection, clearing the way for the Phase 1 clinical trial reported.

## Materials and Methods

### Study Design

The study was conducted at 5 study sites in compliance with the Declaration of Helsinki, US Code 21 of Federal Regulations, and the Harmonized Tripartite Guidelines for Good Clinical Practice (1996) and was reviewed and approved by the Western Institutional Review Board. A dose-escalation design was used to investigate 6 doses of VEGF Trap-Eye (0.05, 0.15, 0.5, 1, 2, and 4 mg) in patients with subfoveal CNV due to NVAMD. There was a 2-week waiting period after dosing the last patient in each cohort and dosing the first patient in the next cohort to watch for safety signals. Six weeks after injection of VEGF Trap-Eye, patients returned to standard care and were able to receive any treatment judged to be indicated by the investigator. Patients were monitored for 12 weeks after intravitreal VEGF Trap-Eye administration as part of the active phase of the study but were monitored for safety with eye examinations every 3 months for 1 year.

Table 2. Baseline Characteristics of the Study Population

Parameters	Mean	Range
Age	78 yrs	67–88 yrs
BCVA*	39.3	0–72
Snellen equivalent	~20/160	20/40 to >20/800
Foveal thickness <sup>†</sup> (automated, fast macular scans)	375 $\mu$ m	259–616 $\mu$ m (normal = 179 $\mu$ m)
Foveal + lesion thickness (manual, posterior pole scans)	552 $\mu$ m	332–1021 $\mu$ m (normal = 270 $\mu$ m)
No. of prior treatments in study eye (PDT $\pm$ steroids, pegaptanib, or investigational small interfering RNA)	None: 10 patients $\geq 1$ : 11 patients	
Lesion type	Classic: 3 (14%) Occult: 8 (38%) Minimally classic: 6 (29%) Predominantly classic: 4 (19%)	
Gender	13 female : 8 male	
Study eye	11 left : 10 right	

BCVA = best-corrected visual acuity; PDT = photodynamic therapy; VA = visual acuity.  
<sup>\*</sup>Early Treatment Diabetic Retinopathy Study letters read as measured by electronic VA.  
<sup>†</sup>Scans were gradable in 20 of 21 patients.

**Study Population**

The main inclusion criteria for the study were as follows: (1) male or female (any ethnicity), 50 years of age or older; (2) diagnosis of NVAMD in the study eye with leaking subfoveal CNV  $\leq 12$  disc areas (measured according to the protocol of the Macular Photocoagulation Study);<sup>12</sup> (3) best-corrected visual acuity (BCVA) of 20/40 or worse; and 4) central subfield thickness  $\geq 250$   $\mu\text{m}$  measured by optical coherence tomography (OCT). Other inclusion criteria and exclusion criteria are listed in Table 1 (available at <http://aaajournal.org>).

**Intravitreal Administration of Vascular Endothelial Growth Factor Trap-Eye and Study Activities**

A sterile lid speculum was inserted, topical anesthesia was applied, and the conjunctiva was irrigated with 5% povidone iodine. After additional local anesthesia, a 30-gauge needle was inserted through the pars plana and 100  $\mu\text{l}$  containing a prespecified amount of VEGF Trap-Eye was injected into the vitreous cavity. Funduscopy examination was done to confirm retinal perfusion, and the patients were observed for 1 hour or until intraocular pressure returned to

normal. Patients were closely monitored for safety and tolerability using the following assessments and procedures: BCVA; slit-lamp biomicroscopy; indirect ophthalmoscopy; tonometry; adverse events reporting; vital signs; physical examinations; serum electrolytes; creatinine; quantitative protein determination in 24-hour urine specimens; and measurement of serum neutralizing antibodies directed against VEGF Trap-Eye. Stereoscopic color fundus photographs and FA were performed at baseline and week 6. Optical coherence tomography was performed at each study visit.

**Optical Coherence Tomography**

The Digital Angiographic Reading Center (DARC, New York, NY) analyzed fluorescein angiograms, and the DARC/Digital OCT Reading Center (Cleveland, OH) analyzed OCT scans. All images were evaluated with the grader masked with respect to treatment group. Optical coherence tomography was performed using StratusOCT (Carl Zeiss Meditec, Dublin, CA). The Digital OCT Reading Center provided detailed instruction in the protocol for image acquisition. Standard protocol (6-mm fast macular thickness map and 6 $\times$ 6-mm cross-hair) was used. Foveal thickness (in micrometers, defined as the mean height of the neurosensory retina in a central 1-mm diameter area) and total macular volume (in

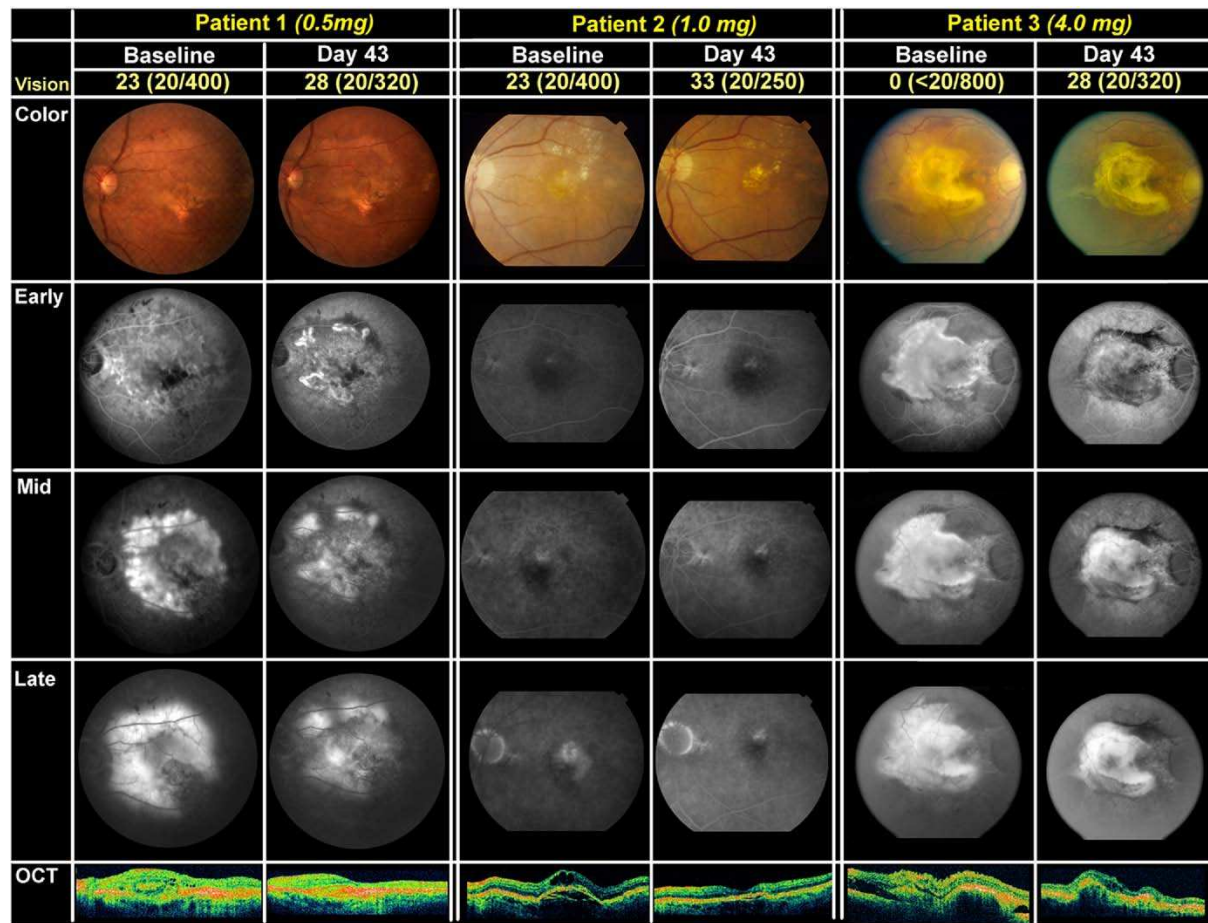


Figure 1. Color fundus photographs, fluorescein angiograms, and OCT at baseline and 6 weeks (Day 43) after intravitreal injection of 1 mg (Patient 1), 2 mg (Patient 2), or 4 mg (Patient 3) of vascular endothelial growth factor Trap-Eye. OCT = optical coherence tomography.

cubic millimeters) were automatically computed by the StratusOCT software version 4.0. The median baseline central retinal/lesion thickness was measured by masked graders.

### Fluorescein Angiography

High-resolution digital FA was performed using a Zeiss FF4 fundus camera (Carl Zeiss, Oberkochen, Germany) attached to a Medical Research Professionals (Boston, MA) capture station. A modified FA acquisition protocol was used for image acquisition, and compliance was monitored by a site visit. Digital images of FA were then sent to the DARC for analyses.

### Data Analysis

Analyses of biological activity included central retinal/lesion thickness, foveal thickness as assessed by OCT, CNV area and

total lesion size assessed by FA, and VA. The primary analyses included assessment of change from baseline in bioeffect variables at Day 43. Mean changes from baseline at each visit were displayed. Analyses were also performed by pooled dose groups of low (0.05, 0.15, and 0.5 mg), intermediate (1.0 mg), and high (2.0 and 4.0 mg) doses to show the bioeffect at different dose levels. The number of patients who needed additional treatments after the primary end point was determined and evaluated with regard to their bioeffect. All data including images were made available to the investigators.

### Results

The baseline characteristics of the 21 patients included in the study are listed in Table 2. Although the majority of the patients had

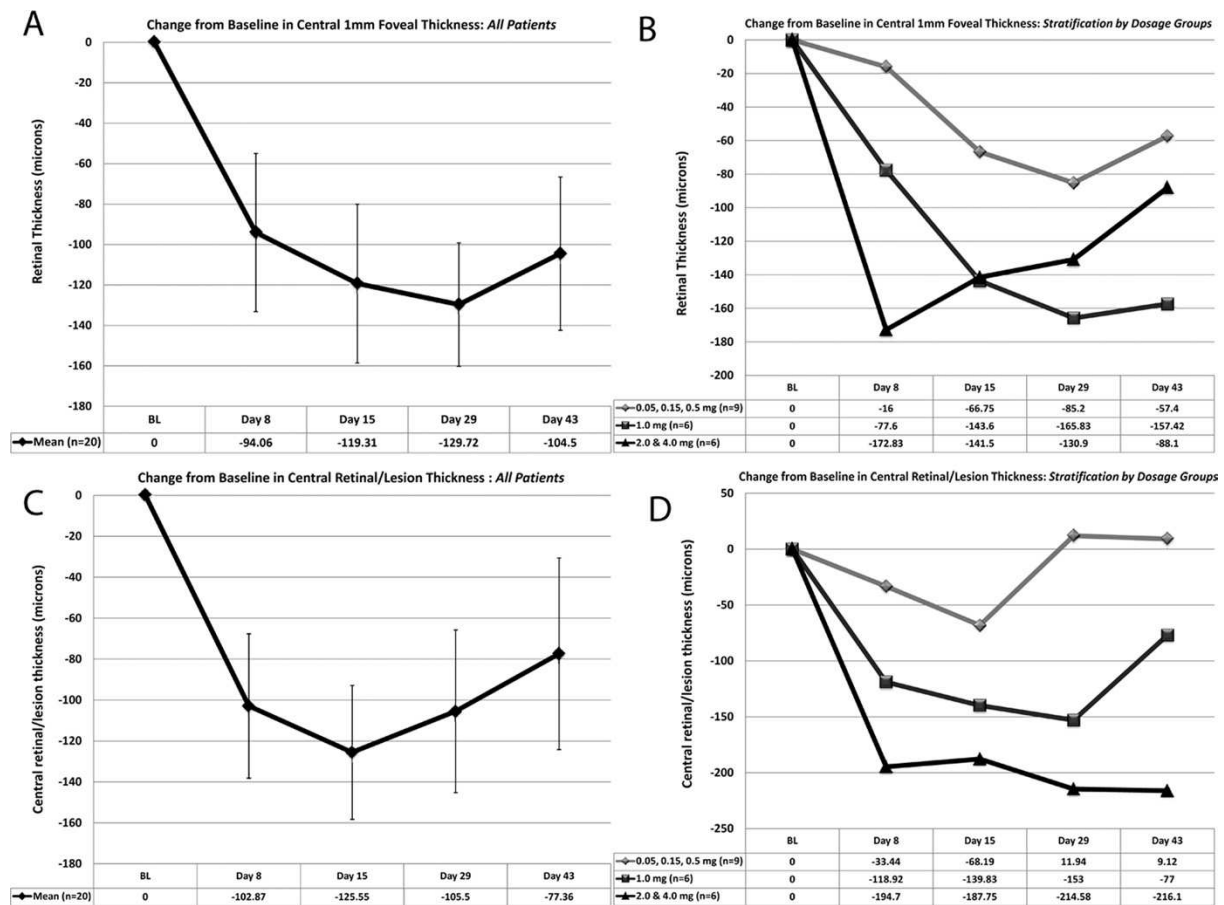


Figure 2. Changes in foveal thickness or combined foveal and lesion thickness after a single injection of VEGF Trap-Eye. Patients received a single intraocular injection of 1 of 6 doses of VEGF Trap-Eye and at several time points after injection had Fast Macular OCT scans to measure central subfield foveal thickness (A, B) and posterior pole scans to measure combined foveal and lesion thickness (C, D). Data are shown for 20 of 21 study patients who had gradable scans. The mean change from baseline in foveal thickness for all patients was substantially reduced 1 week (Day 8) after injection, was maximally reduced by 2 weeks (Day 15), and remained stable between 2 and 6 weeks (Day 43) (A). Stratification into low- (0.05, 0.15, and 0.5 mg), intermediate- (1.0 mg), and high- (2.0 and 4.0 mg) dose groups of VEGF Trap-Eye showed minimal effect in the low-dose group, whereas the intermediate and high-dose groups showed substantial and comparable reductions in foveal thickness (B). The mean change from baseline in combined foveal and lesion thickness was similar to that for foveal thickness between baseline and 2 weeks (Day 15) but regressed somewhat between 2 and 6 weeks (Day 43) (C). The mean reduction from baseline in lesion and foveal thickness was greater in the intermediate- and high-dose groups compared with the low-dose group (D). OCT = optical coherence tomography; VEGF = vascular endothelial growth factor.

received prior treatments for their NVAMD, an effort was made to determine the presence of classic or occult CNV within lesions.

### Safety

There were no ocular serious adverse events or evidence of inflammation. There were also no systemic serious adverse events or changes in laboratory values. There was no dose-limiting toxicity, and a maximum tolerated dose was not identified.

### Fluorescein Angiography and Optical Coherence Tomography

Many of the patients in this study had advanced disease with substantial subretinal fibrosis and a poor visual prognosis but had active CNV in addition to subretinal fibrosis, allowing some assessments of drug effects. Because of advanced disease, not all fluorescein angiograms were able to be assessed for changes in lesion characteristics or size. Figure 1 shows fluorescein angiograms and OCT scans at baseline and 6 weeks after intravitreal injection of VEGF Trap-Eye in 3 patients. One patient (Patient 1) had 20/400 vision due to a large CNV lesion that showed substantial leakage during the late phase of the angiogram and moderate thickening of the overlying retina on OCT (Fig 1, column 1). Six weeks after injection of 0.5 mg of VEGF Trap-Eye, BCVA was 20/320 and there was less filling of the CNV, as illustrated by areas of relative hypofluorescence, reduced leakage shown by less fuzziness of most regions of the lesion, and decreased macular thickening on OCT (Fig 1, column 2). Another patient (Patient 2) had BCVA of 20/400 and showed a small region of classic CNV associated with a larger temporal arc of occult CNV and substantial leakage, as illustrated by fuzziness during the late phase of the angiogram and a pocket of intraretinal fluid on OCT (Fig 1, column 3). Six weeks after injection of 1 mg of VEGF Trap-Eye, BCVA was 20/250, the small area of classic CNV stained but did not leak, and the occult CNV was indiscernible, suggesting possible regression (Fig 1, column 4). The pocket of intraretinal fluid seen on the baseline OCT scan was eliminated. At baseline, a third patient (Patient 3) had BCVA of 20/800 due to a large lesion containing central subretinal fibrosis surrounded by active CNV associated with subretinal hemorrhage (Fig 1, column 5). There was staining of the fibrosis and leakage from the surrounding CNV, which appeared fuzzy during the late phase of the angiogram, and the OCT showed subretinal and intraretinal fluid. Six weeks after injection of 4 mg of VEGF Trap-Eye, BCVA was 20/320, the subretinal fibrosis was more defined on the color photograph and still stained during FA, but the surrounding CNV was gone, suggesting regression or contraction. There was no leakage, and OCT showed resolution of subretinal fluid and minimal intraretinal fluid (Fig 1, column 6).

### Changes in Optical Coherence Tomography Measurements

The OCT scans from 20 patients were analyzed by the reading center; by mistake 1 patient did not receive an OCT at baseline and therefore could not be included in the analysis. The mean decrease in foveal thickness at 6 weeks for all patients across all 6 doses of VEGF Trap-Eye was 104.5 μm (Fig 2A). Patients were divided into those receiving low (0.05, 0.15, and 0.5 mg), intermediate (1.0 mg), and high (2.0 and 4.0 mg) doses of VEGF Trap-Eye. Patients injected with 1.0 mg or greater of VEGF Trap-Eye showed a substantially greater reduction in foveal thickness compared with those injected with 0.5 mg or less (Fig 2B).

Posterior pole scans measure thickness in the CNV complex, subretinal fluid, and retinal thickness. The reduction in this com-

bined measure of lesion and foveal thickness after injection of VEGF Trap-Eye was similar to but somewhat less than that for foveal thickness.

As was true for foveal thickness, the reduction in combined foveal and lesion thickness was greater for those patients injected with 1.0 mg or more of VEGF Trap-Eye compared with those injected with 0.5 mg or less (Fig 2D).

### Changes in Visual Acuity

Ninety-five percent of patients injected with any dose of VEGF Trap-Eye showed stable or improved vision at 6 weeks, and the mean increase in VA was 4.7 letters (Fig 3A). Only 1 patient showed a reduction in BCVA 6 weeks after injection of VEGF

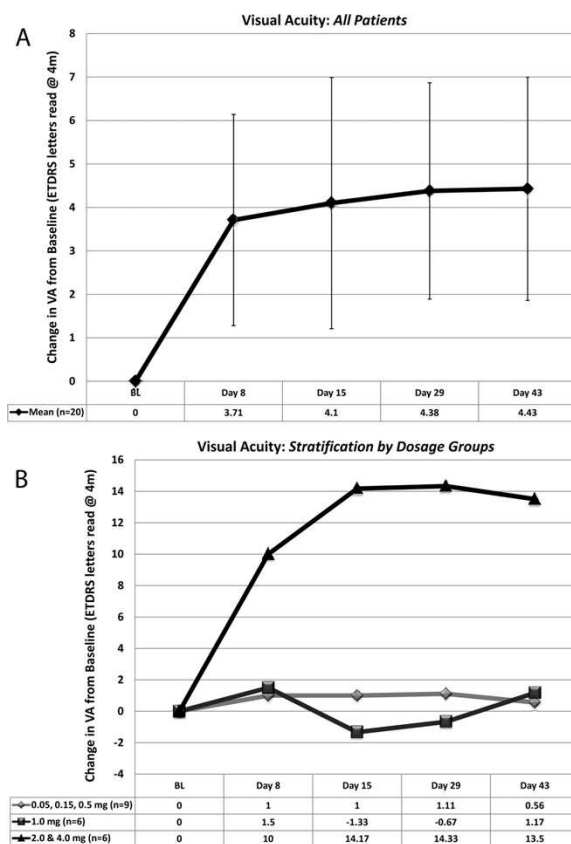


Figure 3. Change in BCVA from baseline after a single intraocular injection of VEGF Trap-Eye. Patients received a single intraocular injection of 1 of 6 doses of VEGF Trap-Eye and at several time points after injection had BCVA measured by the Early Treatment Diabetic Retinopathy Study protocol. A, The mean (± standard error of the mean) change in number of letters read at 4 m (not change in Early Treatment Diabetic Retinopathy Study VA score) for all patients showed an improvement of approximately 1 line at 6 weeks (Day 43). B, Stratification into low- (0.05, 0.15, and 0.5 mg), intermediate- (1.0 mg), and high- (2.0 and 4.0 mg) dose groups of VEGF Trap-Eye showed negligible change in the low-dose group, 1 letter in the intermediate and 13.5 letters in the high-dose group. BCVA = best-corrected visual acuity; ETDRS = Early Treatment Diabetic Retinopathy Study; VA = visual acuity; VEGF = vascular endothelial growth factor.

# Explore Litigation Insights

Docket Alarm provides insights to develop a more informed litigation strategy and the peace of mind of knowing you're on top of things.

## Real-Time Litigation Alerts



Keep your litigation team up-to-date with **real-time alerts** and advanced team management tools built for the enterprise, all while greatly reducing PACER spend.

Our comprehensive service means we can handle Federal, State, and Administrative courts across the country.

## Advanced Docket Research



With over 230 million records, Docket Alarm's cloud-native docket research platform finds what other services can't. Coverage includes Federal, State, plus PTAB, TTAB, ITC and NLRB decisions, all in one place.

Identify arguments that have been successful in the past with full text, pinpoint searching. Link to case law cited within any court document via Fastcase.

## Analytics At Your Fingertips



Learn what happened the last time a particular judge, opposing counsel or company faced cases similar to yours.

Advanced out-of-the-box PTAB and TTAB analytics are always at your fingertips.

## API

Docket Alarm offers a powerful API (application programming interface) to developers that want to integrate case filings into their apps.

## LAW FIRMS

Build custom dashboards for your attorneys and clients with live data direct from the court.

Automate many repetitive legal tasks like conflict checks, document management, and marketing.

## FINANCIAL INSTITUTIONS

Litigation and bankruptcy checks for companies and debtors.

## E-DISCOVERY AND LEGAL VENDORS

Sync your system to PACER to automate legal marketing.