

Steps for a Safe Intravitreal Injection Technique

A look at how European and American approaches compare

July 1, 2009

19

Steps for a Safe Intravitreal Injection Technique

A look at how European and American approaches compare.

CARSTEN H. MEYER, MD · ANNE FUNG, MD · SANDEEP SAXENA, MD · FRANK G. HOLZ, MD

In recent years, significant advances have been made in optimizing the delivery of drugs to target tissues within the eye and in maintaining effective drug doses within those tissues. However, retinal drug delivery is still a challenging area in the field of ophthalmic drug delivery.

A variety of approaches have been described for drug delivery into the vitreous cavity. Intravitreal injection was first reported by Ohm in 1911 as a technique to introduce air for retinal tamponade and repair of retinal detachment.¹ Intravitreal administration of pharmacotherapies dates to the mid-1940s with the use of penicillin to treat endophthalmitis. Since that time, use of the intravitreal injection technique has progressively increased, with its usage being focused primarily on the treatment of retinal detachment, endophthalmitis, and cytomegalovirus retinitis.

Carsten H. Meyer, MD, is professor of ophthalmology at the University of Bonn in Germany. Anne E. Fung, MD, is a medical retina consultant at Pacific Eye Associates in San Francisco. Sandeep Saxena, MD, is professor of ophthalmology at King George's Medical University in Lucknow, India. Frank G. Holz, MD, is professor and chair of ophthalmology at the Universitäts-Augenklinik mit Poliklinik in Bonn. Dr. Meyer reports minimal financial interest in Pfizer, Novartis, and GlaxoSmithKline. Drs. Fung, Holz, and Saxena report no financial interest in any products mentioned in this article. Dr. Meyer can be reached via e-mail at Meyer_eye@yahoo.com.

The increasing efficacy and safety of intravitreal injections, in conjunction with the development of pharmacotherapies, has led to a recent rapid increase in the use of this technique for the administration of various pharmacotherapies, including bevacizumab, ranibizumab, pegaptanib sodium, and intravitreal triamcinolone acetonide.² An intravitreal drug application has been suggested to achieve therapeutic levels locally, with prolonged effective concentrations (Figure 1).¹ Retinal specialists in Europe and the United States have varied approaches within their countries and between the continents. We will highlight consensus and differences in practices here.

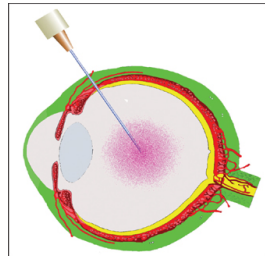


Figure 1. Intravitreal injections via the pars plana route into the mid-vitreous.

INTRAVITREAL DRUG DELIVERY

The advantage of intravitreal administrations is an immediate therapeutic effect at the intended tissue. With the widespread use of intravitreal injections, there has been an increased interest regarding the best application technique. Clinical experience with intravitreal injection has provided physicians with an outline of avoidable risks.

All injections should be performed under sterile conditions. While European countries recommend applying the injection in an operating room, other countries, including the United States and India, perform the injection in minor surgery or conventional examining rooms under sterile conditions.⁵

ANTICOAGULATION AND INTRAVITREAL INJECTIONS

A major concern associated with preoperative discontinuation of anticoagulation therapy is the increased risk of thromboembolic or cerebrovascular events.⁶ The ranibizumab study trials observed a low incidence of ocular hemorrhages in patients maintaining warfarin. In the MARINA trial, there were a total of 60 warfarin-treated participants, receiving a mean of 22.0 (SD, 3.6) injections.⁷ No ocular bleeding was observed during the 1318 consecutive injections. All the authors agree that intraocular injections in warfarin-treated patients are unlikely to cause ocular hemorrhages.

SURFACE PREPARATION WITH POVIDONE-IODINE

There is general agreement that the risk of infectious endophthalmitis following intravitreal injection is small. The role of topical antibiotics to prevent postinjection endophthalmitis remains controversial around the world. Topical antibiotics may be applied after the injection for a few days, as the break in the conjunctiva and sclera takes time to completely heal and water-seal. In addition, there may be a synergistic effect between topical antibiotics and povidone-iodine. However, Frank Holz, MD, emphasized that there is no study demonstrating that reduced conjunctival bacteria may result in a lower risk for endophthalmitis.⁸

Sandeep Saxena, MD, emphasized that treatment of any active external infection, including significant blepharitis, is mandatory prior to each intravitreal injection.^{4,9} The primary goal of any infectious prophylaxis is to minimize the present bacterial flora around the surgical entry site. This can be achieved with the topical application of povidone-iodine, eyelid hygiene, proper isolation of the surgical site, and optional postoperative antibiotics.³⁻¹¹

One key step to reducing the risk of endophthalmitis is a sufficient disinfection of the skin, eyelashes, and conjunctiva. The eyelids and lashes are usually disinfected with a povidone-iodine (10%) scrub. A sterile speculum is placed between the lids. Various methods of applying povidone-iodine preoperatively have been studied.

Most US sites apply 2 drops of 0.5% povidone-iodine placed on the ocular surface over the intended site of the injection. Some physicians place 3 drops of povidone-iodine (5%) 3 times, several minutes apart, over the ocular surface, preventing dessication and abrasion of the cornea with antibiotic eyedrops or sterile saline solution.

German investigators have advocated irrigating the conjunctival sac with 1% or 5% povidone-iodine to decrease conjunctival colonization; however, it remains unknown whether the application of povidone-iodine drops vs a flush is more effective in preventing endophthalmitis.

There is no consensus among the 4 authors as to whether topical antibiotics should be used preoperatively. Preinjection antibiotic drops may be applied according to the label of the applied drug, although there is no evidence supporting their use before intravitreal injections.

LOCAL TOPICAL ANESTHESIA

Satisfactory pain relief may be achieved with topical lidocaine. Local anesthesia may be induced by applying 3 to 4 sterile cotton swabs soaked in sterile 4% lidocaine to the injection area (for 30 seconds each).¹² Alternatively, lidocaine may be applied with 2% eyedrops, as a gel, or as a subconjunctival injection. The effective relief of pain with lidocaine for intravitreal injection seems to be independent of its mode of application (gel vs subconjunctival injection). However, topical applications of lidocaine cause less chemosis compared with subconjunctival anaesthesia. Most centers have stopped using gel on a regular basis, as topical eyedrops seem to induce a sufficient anesthesia.

THE INJECTION PROCEDURE AND RECOMMENDED TECHNIQUE

There is general agreement that the injection site should be located 3.5 to 4 mm posterior to the limbus. Dr. Saxena emphasizes that the injection site may differ in repeated injections by approximately 1 clock hour.^{4,13} This avoids a double penetration through the same site, inducing a persisting scleral hole with consecutive leaking or vitreous incarceration "vitreous wick."

The angle of the incision through the sclera may be directed in an oblique, tunneled fashion (Figures 2 and 3), as rectangular radial incisions may remain open, inducing vitreous or drug reflux under the conjunctiva, as well as severe chemosis and even hypotony in vitrectomized eyes.^{14,15} Dr. Meyer observes persistent unsealed scleromies following radial injections using a 30-gauge needle, requiring secondary suturing to seal the penetrating scleral wound.¹⁶ The depth of the insertion may vary between 5 to 7 mm according to Anne Fung, MD, so that the tip of the needle is placed in the mid-vitreous. The drug is then gently injected into the vitreous cavity.

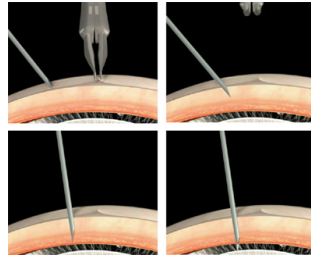


Figure 2. Schematic drawing of the injection procedure: The conjunctiva is moved upwards so that the conjunctival hole and the site of the scleral penetration are not on top of each other. After an initial lamellar penetration of the outer sclera, the needle is moved upwards for a full-thickness penetration.

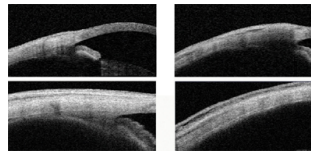


Figure 3. Examination of the injection site 15 minutes after the injection with the anterior-segment OCT scan (Visante): The radial injection remains open and visible, whereas the tangential oblique injection is not detected on OCT.

The needle diameter should be smaller than 27-gauge to reduce risk of wound leakage or injury. Injections with crystalline TA are frequently applied with 27-gauge needles, while most liquid injections use 30-gauge needles. The required force to penetrate the sclera is almost twice as much using 27-gauge needles compared with 30- or even 31-gauge.¹⁷ Dr. Holz explains that larger needles may not necessarily induce more pain to the patient; however, they may induce more reflux or subconjunctival hemorrhage. In addition, blunting of the needle tip, as found in some prefilled syringes, was observed to cause a deeper impouching and visible indentation of the eye wall during the injection that may have caused the patient more discomfort.^{18,19}

The injected volume should be limited up to 0.15 ml without a routine paracentesis releasing an elevated ocular pressure, according to Dr. Meyer's clinical experience. Administration of rTPA, anti-VEGF agents, and SF₆ gas as triple injection for the management of subretinal hemorrhage frequently require a paracentesis to release the elevated eye pressure.²⁰

OCULAR COMPLICATIONS

Dr. Fung published a survey on ocular complications reporting an overall prevalence for retinal detachments of 3.9% per eye or 0.9% per injection and a prevalence of endophthalmitis (including pseudo-endophthalmitis) of 0.3% per injection and 0.9% per eye.²

CONCLUSION

The rationale for intravitreal drug application is an immediate and increased therapeutic delivery to the targeted tissue. Some parts of the injection procedure (use of adequate anesthetics, povidone-iodine, and a lid speculum; not injecting patients with active eyelid or ocular infections; avoiding extensive massage of eyelid meibomian glands; avoiding prophylactic or postinjection paracentesis) are supported by consensus agreement in all countries, while other aspects have less agreement (eg, most investigators advocate gloves, most prefer povidone-iodine drops over flush, most use no sterile drape). There is no agreement regarding the use of pre- or postinjection topical antibiotics, as well as a specific intraocular pressure level that should not be exceeded before the injection. Intravitreal drug application is a safe and effective procedure. Side effects, eg, elevated IOP, cataract formation, and endophthalmitis, are limited. **RP**

REFERENCES

- Ohm J. Über die Behandlung der Netzhautablösung durch operative Entleerung der subretinalen Flüssigkeit und Einspritzen vom Luft in den Glaskörper. *Graefes Arch Klin Ophthalmol*. 1911;79:442-450.
- Fung AE, Rosenfeld PJ, Reichel E. The International Intravitreal Bevacizumab Safety Survey: using the internet to assess drug safety worldwide. *Br J Ophthalmol*. 2006;90:1344-1349.
- Kaiser PK, Brown DM, Zhang K, Hudson HL, Holz FG, Shapiro H, Schneider S, Acharya NR, Ranibizumab for predominantly classic neovascular age-related macular degeneration: subgroup analysis of first-year ANCHOR results. *Am J Ophthalmol*. 2007;144:850-857.
- Fung AE, Latwani GA, Rosenfeld PJ, Dubovy SR, Michels S, Feuer WJ, Pujalillo CA, et al. An optical coherence tomography-guided, variable dosing regimen with intravitreal ranibizumab (Lucentis) for neovascular age-related macular degeneration. *Am J Ophthalmol*. 2007;143:566-583.
- Schmidt-Erfurth UM, Richard G, Augustin A, Aylward WG, Bardello F, Corcobstegui B, Cunha-Vaz J, Gaudric A, Leys A, Schlingemann RO; European Society for Retina Specialists' Guidelines Committee (EURETINA). Guidance for the treatment of neovascular age-related macular degeneration. *Acta Ophthalmol Scand*. 2007;85:486-494.
- Meyer CH, Callizo J, Mennel S, Kussin A. Perioperative management of anticoagulated patients undergoing repeated intravitreal injections. *Arch Ophthalmol*. 2007;125:994.
- Charles S, Rosenfeld PJ, Gayner S. Medical consequences of stopping anticoagulant therapy before intraocular surgery or intravitreal injections. *Retina*. 2007;27:813-815.
- Scott IU, Flynn HW. Reducing the risk of endophthalmitis following intravitreal injections. *Retina*. 2007;27:10-12.
- Safar A, Dellimore MC. The effect of povidone iodine flush versus drops on conjunctival colonization before intravitreal injections. *Int Ophthalmol*. 2007;27:307-312.
- Meyer CH, Mennel S, Eter N. Incidence of endophthalmitis after intravitreal Avastin injection with and without postoperative topical antibiotic application. *Ophthalmology*. 2007;114:952-957.
- Ta CN, Egbert PR, Singh K, Shriver EM, Blumenkranz MS, Miño De Kaspar H. Prospective randomized comparison of 3-day versus 1-hour preoperative ofloxacin prophylaxis for cataract surgery. *Ophthalmology*. 2002;109:2036-2041.
- Kaderli B, Avci R. Comparison of topical and subconjunctival anesthesia in intravitreal injection administrations. *Eur J Ophthalmol*. 2006;16:718-721.
- Aiello LP, Brucker AJ, Chan S et al. Evolving guidelines for intravitreal injections. *Retina*. 2004;24:S3-19.
- Rodrigues EB, Meyer CH, Grumann A Jr, Shiroma H, Aguni JS, Farah ME. Tunneled scleral incision to prevent vitreal reflux after intravitreal injection. *Am J Ophthalmol*. 2007;143:1035-1037.
- Rodrigues EB, Meyer CH, Schmidt JC, Hörle S, Kroll P. Unsealed sclerotomy after intravitreal injection with a 30-gauge needle. *Retina*. 2004;24:810-812.
- Meyer CH, Rodrigues EB, Aguni JS, Farah ME. Scleral incisions evaluated by with anterior segment optical coherence tomography. *Am J Ophthalmol*. 2009 (in press)
- Pulido JS, Pulido CM, Bakri SJ, McCannel CA, Cameron JD. The use of 31-gauge needles and syringes for intraocular injections. *Eye*. 2007;21:829-830.
- Kozak I, Dean A, Clark TM, et al. Prefilled syringe needles versus standard removable needles for intravitreal injection. *Retina*. 2006;26:679-683.
- Hochman MN, Friedman MJ. An in vitro study of needle force penetration comparing a standard linear insertion to the new bidirectional rotation insertion technique. *Quintessence Int*. 2001;32:789-796.
- Meyer CH, Scholl HP, Eter N, Helb HM, Holz FG. Combined treatment of acute subretinal haemorrhages with intravitreal recombinant tissue plasminogen activator, expansile gas and bevacizumab: a retrospective pilot study. *Acta Ophthalmol*. 2008;86:490-494.

Retinal Physician, Issue: July / Aug 2009
Table of Contents
Archives