

Photodynamic Therapy of Subfoveal Choroidal Neovascularization in Age-related Macular Degeneration With Verteporfin

One-Year Results of 2 Randomized Clinical Trials—TAP Report 1

Treatment of Age-related Macular Degeneration With Photodynamic Therapy (TAP) Study Group

Objective: To determine if photodynamic therapy with verteporfin (Visudyne; CIBA Vision Corp, Duluth, Ga) can safely reduce the risk of vision loss in patients with subfoveal choroidal neovascularization (CNV) caused by age-related macular degeneration (AMD).

Design: Two multicenter, double-masked, placebo-controlled, randomized clinical trials.

Setting: Twenty-two ophthalmology practices in Europe and North America.

Participants: Patients with subfoveal CNV lesions caused by AMD measuring 5400 μm or less in greatest linear dimension with evidence of classic CNV and best-corrected visual acuity of approximately 20/40 to 20/200.

Methods: Six hundred nine patients were randomly assigned (2:1) to verteporfin (6 mg per square meter of body surface area) or placebo (5% dextrose in water) administered via intravenous infusion of 30 mL over 10 minutes. Fifteen minutes after the start of the infusion, a laser light at 689 nm delivered 50 J/cm² at an intensity of 600 mW/cm² over 83 seconds using a spot size with a diameter 1000 μm larger than the greatest linear dimension of the CNV lesion. At follow-up examinations every 3 months, retreatment with the same regimen was applied if angiography showed fluorescein leakage. The primary outcome was the proportion of eyes with fewer than 15 letters lost (approximately <3 lines of loss), adhering to an intent-to-treat analysis.

Results: In each group, 94% of patients completed the month 12 examination. Visual acuity, contrast sensitivity, and fluorescein angiographic outcomes were better in the verteporfin-treated eyes than in the placebo-treated eyes at every follow-up examination through the month 12 examination. At the month-12 examination, 246 (61%) of 402 eyes assigned to verteporfin compared with 96 (46%) of 207 eyes assigned to placebo had lost fewer than 15 letters of visual acuity from baseline ($P < .001$). In subgroup analyses, the visual acuity benefit (<15 letters lost) of verteporfin therapy was clearly demonstrated (67% vs 39%; $P < .001$) when the area of classic CNV occupied 50% or more of the area of the entire lesion (termed *predominantly classic CNV lesions*), especially when there was no occult CNV. No statistically significant differences in visual acuity were noted when the area of classic CNV was more than 0% but less than 50% of the area of the entire lesion. Few ocular or other systemic adverse events were associated with verteporfin treatment, compared with placebo, including transient visual disturbances (18% vs 12%), injection-site adverse events (13% vs 3%), transient photosensitivity reactions (3% vs 0%), and infusion-related low back pain (2% vs 0%).

Conclusions: Since verteporfin therapy of subfoveal CNV from AMD can safely reduce the risk of vision loss, we recommend verteporfin therapy for treatment of patients with predominantly classic CNV from AMD.

Arch Ophthalmol. 1999;117:1329-1345

A complete list of the participants in the Treatment of Age-Related Macular Degeneration With Photodynamic Therapy Study Group is available on pages 1343 and 1344.

AGE-RELATED macular degeneration (AMD) is a major cause of severe vision loss in people older than age 65 years in North America and Europe.^{1,2} The visual acuity loss usually results from choroidal neovascularization (CNV), the ingrowth of new vessels from the choriocapillaris.³ These new vessels are accompanied by fibrous tissue⁴ that can destroy central visual function over months to years.⁵⁻⁷ In a few selected situations, laser photoco-

agulation of CNV can reduce the risk of severe visual acuity loss compared with no treatment. Photocoagulation is considered when the lesion is subfoveal (extends under the center of the foveal

*For editorial comment
see page 1400*

avascular zone), has well-demarcated boundaries, has evidence of classic CNV, and is small⁵; or when the lesion does not

PATIENTS AND METHODS

The Clinical Study Protocol BPD OCR 002 (originally dated October 25, 1996) and 8 protocol amendments through November 20, 1998, are on file with regulatory agencies in the United States, Canada, and Europe. The highlights of the protocol are described below. Before patient enrollment at a center began, the design was reviewed by a study advisory group (members of the TAP Study Group who advise the study sponsors on the scientific aspects of the investigation), the institutional review board of the participating clinical center, and a data and safety monitoring committee (members are independent of the study sponsors and of the TAP Study Group). All investigators, clinic coordinators, photographers, and vision examiners participated in a certification process to optimize adherence to the protocol. Annual recertification of all vision examiners was performed by a central, experienced group of vision examiners from the Johns Hopkins Medical Institutions, Baltimore, Md. All photographs were graded by the Wilmer Photograph Reading Center at the Johns Hopkins Medical Institutions. Clinic monitors from the sponsors audited data approximately every 6 weeks at each clinical center. The Study Advisory Group discussed scientific aspects of the study by teleconference at least twice each year. An operations committee oversaw day-to-day operations of the protocol through teleconferences held approximately weekly. The Data and Safety Monitoring Committee reviewed safety approximately every 6 months after enrollment began.

PATIENT SELECTION AND ENTRY EVALUATIONS

Patients were enrolled into 1 of 2 trials from December 1996 through October 1997, when the target sample size was attained. Vision testing, color photographs, fluorescein angiography, medical histories and physical examinations were completed within 8 days prior to enrollment into the study.

Patient Selection

Patients had to fulfill eligibility criteria determined by an ophthalmologist certified to enroll and treat study participants. The principal eligibility criteria are shown in **Table 1**. The primary criteria included a best-corrected visual acuity on a retroilluminated Lighthouse for the Blind (New York, NY) distance visual acuity test chart (using modified Early Treatment Diabetic Retinopathy Study charts 1, 2, and R) of 73 to 34 letters, inclusive, correctly identified (visual acuity of approximately 20/40 to 20/200 at a test distance of 2 m) as determined by a certified visual acuity examiner following a protocol refraction and visual acuity determination used in other randomized clinical trials for patients with CNV from AMD (see the "Vision Testing" section below).²⁴

Fluorescein angiographic criteria, using definitions adapted from the Macular Photocoagulation Study (MPS) Group,²⁵ included evidence of CNV caused by AMD that extended under the geometric center of the foveal avascular zone. Furthermore, the lesion had to have some evidence of the fluorescein angiographic pattern, termed *classic CNV*. The lesion could include occult CNV or other

features that could obscure the identification of classic or occult CNV on fluorescein angiography, including blood, blocked fluorescence (hypofluorescence) not from blood, or a serous detachment of the retinal pigment epithelium.²⁵ If features that could obscure the identification of classic or occult CNV on fluorescein angiography were present, these features had to occupy an area less than 50% of the entire lesion's area. The greatest linear dimension of the entire lesion (classic CNV, any occult CNV, and any features that could obscure the identification of classic or occult CNV) had to be 5400 μm or less in greatest linear dimension on the retina as measured by the treating ophthalmologist within 1 week of randomization. During the first 7 months of enrollment, patients with subfoveal lesions eligible for laser treatment according to guidelines recommended by the MPS Group²⁵ were not eligible for participation in the TAP investigation. Beginning on July 4, 1997, the criteria were changed to allow such patients to enroll if they signed an additional written informed consent form indicating a willingness to forgo laser photocoagulation at study entry and an understanding that randomization to placebo or verteporfin treatment was being chosen over the risks and benefits of subfoveal laser photocoagulation.

Two Trials

Patients who were to participate in the investigation were recruited from referrals to 22 clinical centers. Two randomized clinical trials were designed to comply with regulatory agency requirements that 2 randomized clinical trials independently confirm a statistically significant benefit for the primary outcome. The study protocols for the 2 randomized clinical trials of the TAP investigation were identical and ran concurrently, except that 10 of the clinical centers from North America and Europe were assigned prospectively to study A and the other 12 clinical centers to study B. Since the investigation used the same organizational structure (for example, same photograph reading center and vision monitors) concurrently and since baseline characteristics, completeness of follow-up, and outcomes were similar for study A and study B, the Data and Safety Monitoring Committee recommended, with agreement by the TAP Study Group, that the scientific presentation of the results in peer-reviewed publications should use the combined data set in accordance with the design and primary goal of the investigation.

Vision Testing

At the baseline examination, a TAP-certified visual acuity examiner refracted both eyes and measured distance visual acuity and contrast threshold according to a protocol designed to encourage the patient to achieve the best identification of each letter. The distance visual acuity charts have 5 letters per line and a doubling of the minimum angle of resolution every 3 lines. Best-corrected visual acuity was scored based on the total number of correct letters identified at 2 m plus 15. If the patient read fewer than 20 letters at 2 m, the patient was tested on the top 3 lines at 1 m and the score was the total number of letters read at 2 m plus the total number of letters read at 1 m. Contrast threshold for large letters (with a Snellen visual acuity equivalent of approximately 20/750 or a target image of approximately

3° at a distance of approximately 1 m from the contrast chart) was measured using a Pelli-Robson chart.²⁶ For each of the 2 vision tests, the 2 eyes of a patient were tested using different charts.

Photographs

Stereoscopic color photographs of the macula and disc of each eye and a stereoscopic fluorescein angiogram with photographs of the macula of the study eye during the transit phase were taken on 35-mm film by a photographer certified by the Photograph Reading Center following the MPS protocol.²⁵ Adherence to photographic eligibility criteria was reviewed by the Photograph Reading Center at the Johns Hopkins Medical Institutions after randomization by assessment of fundus and angiographic features from the original baseline photographs and fluorescein angiograms. A drawing of the lesion, including all of its components, was made by projecting the film on a microfilm reader using techniques described previously.²⁵ Adherence to eligibility was judged and recorded by the graders without knowledge of the treatment assignment. All baseline gradings and drawings were confirmed by a senior ophthalmologist at the Photograph Reading Center. For cases enrolled by the clinical center at Johns Hopkins, gradings and drawings were confirmed by the principal investigator at Harvard Medical School. Patients judged by the graders not to adhere to photographic eligibility criteria remained in the data analysis.

Other Medical Aspects

Patients had a complete medical history, physical examination, electrocardiogram, and blood tests to screen for hematologic, renal, hepatic, and other major organ pathologic conditions. They also were questioned about the use of any medications and cigarette smoking history. Vital signs were measured prior to randomization.

Study Entry

After reviewing and signing a written informed consent form accompanied by an oral consent process with a certified investigator (ophthalmologist), patients who were judged by a TAP-certified enrolling ophthalmologist to satisfy all eligibility criteria were assigned to placebo or verteporfin infusion.

RANDOM ASSIGNMENTS

Random assignments were prepared by the statistical department of CIBA Vision Corp. Sealed envelopes with random assignments were prepared by the Quality Assurance Department within QLT PhotoTherapeutics Inc (Vancouver, British Columbia), which maintained independence from any other function of the trials. Patients were randomized in a ratio of 2:1 to verteporfin treatment or placebo, with only one eye of a patient to be randomized. For cases in which an enrolling ophthalmologist believed that both eyes of a patient were eligible, the patient and ophthalmologist made a subjective judgment as to which eye would be enrolled in the study. Randomization was stratified by clinical center and by baseline visual acuity (ie, 73 to 54 letters [visual acuity of approximately 20/40 to 20/80] and 53 to 34 letters [approximately 20/100 to

20/200]) using separate groups of color-coded envelopes. A study coordinator was instructed to open the sealed envelope only after a patient was judged to meet all of the eligibility criteria and only after the enrolling ophthalmologist and the patient agreed to have the patient participate. Treatment was to begin the same day that the treatment assignment was revealed by opening the envelope.

MASKING

The allocation of verteporfin therapy or placebo was recorded on a randomization log that was stored in a locked cabinet with both opened and unopened randomization envelopes at each clinical center. The study coordinator aware of the treatment assignment and anyone else who might assist in the setup of verteporfin or placebo solutions were trained to make every reasonable attempt to maintain masking of the ophthalmologist, patient, vision examiner, and Photograph Reading Center personnel. The verteporfin and placebo solutions were different colors (green vs colorless). All verteporfin and placebo solutions as well as the intravenous tubing were covered entirely with foil so that the patient and treating ophthalmologist were masked during the infusion. The ophthalmologist remained masked while administering the light since the fundus appearance during treatment does not change in any way to indicate verteporfin or placebo treatment. On the materials submitted to them, the Photograph Reading Center graders did not have any information to indicate that verteporfin or placebo was administered. The marked hypofluorescence within a treated area noted within 1 week after verteporfin therapy in phase 1 and 2 studies²¹⁻²³ is not readily apparent 3 months after treatment. Therefore, this hypofluorescence was not judged to be a likely source of potential unmasking of the graders evaluating photographs obtained at least 3 months after verteporfin therapy. Clinic monitors also had no access to information that would indicate treatment assignment. There were no known instances of unmasking of the vision examiners or Photograph Reading Center graders. Only 2 patients who noted a green solution following extravasation of drug were likely unmasked. Treating ophthalmologists, but not the patients, were unmasked in 4 additional cases. In 2 of these cases, fluorescein angiography was obtained within 1 week after treatment to evaluate severe visual acuity decrease and showed hypofluorescence typical for verteporfin therapy. In another case the ophthalmologist noted the green verteporfin leaking onto the cover over the intravenous solution, and in 1 additional case, the ophthalmologist became unmasked prior to a vitrectomy for a subretinal hemorrhage; the patient had been assigned to placebo.

VERTEPORFIN THERAPY

Preparation

Verteporfin therapy was performed in all clinical centers according to a standard protocol. A diode laser at 689 nm with a slitlamp delivery system (Coherent Inc, Palo Alto, Calif, or Zeiss Jena GmbH, Jena, Germany) was designed to deliver 50 J/cm² at an intensity of 600 mW/cm² over 83 seconds. Since the light application causes no visible changes

Continued on next page

on biomicroscopic examination during treatment, the treating ophthalmologists noted that they had no way of confirming that the power output settings on the laser console matched the power being delivered at the contact lens on the study eye during treatment. The power output at the slitlamp was confirmed prior to each treatment beginning in January 1998 using a handheld power meter (Laser Check; Coherent Inc). No major deviations in power output were subsequently identified. The treatment spot size was determined after measuring the greatest linear dimension of the entire CNV lesion using a transparency with a millimeter ruler placed on a fluorescein angiogram obtained with a fundus camera setting at $\times 2.5$ magnification. This dimension was divided by 2.5 to account for the magnification of the camera systems used, resulting in the approximate greatest linear dimension of the lesion in the fundus. An additional 1000 μm was added to this dimension to provide a 500- μm margin of additional treatment around the lesion. This increased the chance that the lesion would be treated in its entirety and would compensate for any slight movements of the study eye during light application. An unmasked nurse or physician not involved in any outcome assessments and trained in the importance of maintaining masking throughout the study prepared either 30 mL of placebo (5% dextrose in water) or verteporfin (6 mg per square meter of body surface area) after calculating the body surface area from a nomogram based on the height and weight of the patient on the day of treatment. The solution then was infused through intravenous access over a 10-minute period. Fifteen minutes after the start of the infusion, the laser light was applied for 83 seconds to the CNV lesion through a fundus contact lens of known magnification to result in a light exposure of 50 J/cm². Patients were instructed to avoid direct sunlight as much as possible and, while outdoors, to wear special sunglasses with a low (4%) transmittance of visible light for 48 hours after treatment.

PATIENT FOLLOW-UP

Patients were telephoned within 2 to 4 days after each treatment to determine if they noted any adverse events, such as new, significant visual acuity loss. If an adverse event was suspected, the patient was asked to return promptly for reexamination. All patients also were scheduled to return approximately 3 months after each treatment (within 2 weeks before or after that date). The patient was seen every 3 months and at any other time that the patient or treating ophthalmologist judged that a severe adverse ocular event might have occurred. At each regularly scheduled follow-up visit, a protocol refraction, best-corrected visual acuity measurement, contrast threshold measurement, ophthalmoscopic examination, stereoscopic color fundus photography, and fluorescein angiography were performed in both eyes before retreatment. Retreatments could

extend under the center of the foveal avascular zone (is juxtafoveal or extrafoveal) and has well-demarcated boundaries. Many of the juxtafoveal and extrafoveal cases will have subfoveal recurrences after laser photocoagulation treatment.^{6,7} For cases in which photocoagulation might be considered, the benefits of laser treatment are limited, especially for subfoveal CNV, because laser photocoagulation damages viable neurosensory retina

be considered if there were no serious adverse events judged likely to be associated with prior therapy. If the treating ophthalmologist noted any leakage from classic or occult CNV in the study eye on a fluorescein angiogram taken at a regularly scheduled follow-up visit every 3 months, retreatment with placebo or verteporfin (as assigned at the baseline examination) was recommended to the patient. A treatment spot size was chosen that was 1000 μm greater than the greatest linear dimension of any classic or occult CNV within or contiguous to an area of prior involvement by the lesion. Any hypofluorescence from blood contiguous with CNV or a serous detachment of the retinal pigment epithelium contiguous with CNV also was included within the greatest linear dimension to be retreated. Scar tissue that was stained with fluorescein but did not leak fluorescein at its boundaries and hypofluorescence not from visible blood were not included in the lesion to be retreated. If the area to be retreated included 2 or more non-contiguous areas of leakage from CNV, a greatest linear dimension was chosen that would cover all areas with one spot size. To qualify for retreatment, the leakage from CNV at follow-up was not required to be under the geometric center of the foveal avascular zone, and the greatest linear dimension did not have to be 5400 μm or less. In cases in which the greatest linear dimension to be retreated exceeded the maximum spot size (approximately 6000 μm), the treating ophthalmologist positioned the spot to encompass as much of the area of leakage as possible.

FLUORESCEIN ANGIOGRAPHIC ASSESSMENT AT FOLLOW-UP

At follow-up examinations, the extent of fluorescein leakage from classic CNV and then from occult CNV was graded at the Photograph Reading Center in a masked fashion with reference to the baseline photographs and drawings as follows: progression of leakage (CNV beyond the area of the entire CNV lesion noted at baseline, regardless of the amount of leakage noted within the area of lesion identified at baseline), moderate leakage (area of CNV occupying $\geq 50\%$ of the area of CNV noted at baseline, with no progression), minimal leakage (area of CNV occupying $< 50\%$ of the area of CNV noted at baseline, with no progression), and absence of leakage (no CNV within the area of the lesion noted at baseline, with no progression). These gradings were based only on lesion area, not other fluorescein features, such as the amount of fluorescence or the area of leakage extending beyond classic CNV or occult CNV. The Photograph Reading Center graders also evaluated color fundus photographs and fluorescein angiograms obtained at the month 3, 6, 9, and 12 follow-up examinations for any serious or potential adverse events that could be identified on photographs, including the development of any other fundus or optic nerve disease that could affect visual acuity. The Photograph Reading Center staff reviewed any

overlying the treated CNV. Subfoveal treatment usually results in immediate, significant visual acuity loss, especially when visual acuity is better than 20/200.⁸⁻¹⁰ Unfortunately, most patients with subfoveal CNV will not benefit from laser photocoagulation because the lesions are too large or they have relatively good visual acuity (better than 20/200), poorly demarcated boundaries, or no evidence of classic CNV.⁸⁻¹⁰

fluorescein angiograms obtained at interim visits at which a retinal adverse event was suspected by a treating ophthalmologist.

STATISTICAL METHODS

Sample Size Estimation

A minimum of 300 treated patients were needed to allow a 95% chance of detecting at least one adverse event that had a true occurrence of 1% or greater during the treatment period. Thus, 2 identically sized trials with at least 150 patients assigned to verteporfin therapy were needed. A randomization ratio of 2:1 would result in 75 patients in each trial assigned to placebo, with a total of 225 patients in each trial. If 50% of the patients given placebo were estimated to lose fewer than 15 letters at 1 year, with a 2-sided significance level (α) of .05, then 225 patients in each trial would provide 80% power to detect a difference from placebo of 20% (ie, 50% vs 70%). This difference was judged to be of adequate clinical relevance. The sample size estimate then was adjusted with the assumption that 17% of enrolled patients would not have data available at the end of the trial because of death, loss to follow-up, and gross ineligibility. Therefore, a target sample size of 270 patients in each trial or 540 patients for both trials was judged to be needed to enroll 225 evaluable patients in each trial.

Outcome Measurements

The primary efficacy outcome was the proportion of eyes that had fewer than 15 letters lost (approximately <3 lines of visual acuity loss) compared with the baseline examination at 1 year after study entry. Secondary efficacy outcomes included the proportion of eyes that had fewer than 30 letters lost (approximately <6 lines of visual acuity loss) compared with the baseline examination, mean changes in visual acuity, mean changes in contrast threshold, and angiographic outcomes (progression of CNV and size of lesion).

Statistical Analysis

The primary efficacy analyses were based on a strict intent-to-treat analysis; patients were analyzed within the group to which they were randomized. All 609 randomized patients were included in the primary efficacy analyses. Demographic and baseline characteristics were summarized and tested for treatment group comparability using a Fisher exact test for categorical variables and a Wilcoxon rank-sum test for continuous variables.^{27,28} The proportions of eyes that lost fewer than 15 letters and fewer than 30 letters from baseline to 1 year were analyzed using a Pearson χ^2 test. The frequency distributions of changes in visual acuity from baseline, visual acuity categories, and changes in contrast sensitivity from baseline were compared between

groups using a Wilcoxon rank-sum test. The times to a loss of 15 or more letters and separately for 30 or more letters were analyzed using the Kaplan-Meier method.²⁷ The loss only counted as an event if there was confirmation of the loss at the next visit or if the loss was observed at the patient's last included visit. The complements of the Kaplan-Meier estimates at each scheduled visit are displayed graphically using point estimates from each visit. Assessments of fluorescein leakage were compared between groups using a Pearson χ^2 test.²⁹ The intent-to-treat analysis included all patients who were randomized; missing values were imputed using the method of last observation carried forward. To test for interactions between treatment and subgroup variables, an analysis of variance model²⁸ was used for contrast sensitivity and a logistic regression model was used for all binary response variables.³⁰

DATA MONITORING AND REPORTING

Since visual acuity was both a primary outcome and a measure of safety, the Data and Safety Monitoring Committee semiannually reviewed accumulated visual acuity data unmasked by treatment assignment and independently analyzed by the Jaeb Center for Health Research, Tampa, Fla. Unmasked data were not shared with the study sponsors or any of the investigators. The emphasis of these reviews was on safety, so that patient participants, the TAP Study Group, and the study sponsors could be notified if there was a specific safety concern identified in this unmasked information. No safety concerns were voiced by the committee at its reviews on November 5, 1997, and June 27, 1998.

Twelve-month data analyzed by the sponsors were reviewed by the sponsors, the Data and Safety Monitoring Committee, the chair of the TAP Study Advisory Group, and the principal investigator of the Photograph Reading Center on December 30, 1998, to consider filing for regulatory approval of verteporfin therapy. An independent analysis of the month 12 efficacy analyses was conducted by the Jaeb Center to verify the accuracy of the sponsors' data analyses. Based on this review of the data, the sponsors concluded that the 1-year outcomes warranted filing for regulatory approval. To comply with Securities and Exchange Commission policies in Canada and the United States, this decision was shared with the public via a news release from the sponsors on January 5, 1999. The data on which this public announcement was based were then reviewed by the TAP Study Advisory Group and the TAP Study Group on January 30, 1999, and are presented in this report. In all instances, the results are given for both trials combined. The results of the individual trials show no significant differences with respect to baseline characteristics, completion of visits, visual acuity outcomes, secondary outcomes, or adverse events (data on file with regulatory agencies but not shown here). No prospectively defined stopping rules were employed.

Because of the limitations of laser photocoagulation for subfoveal CNV and because CNV in AMD is an important public health problem, other treatments are under evaluation in an effort to improve the outcome in this condition. One such treatment is photodynamic therapy with verteporfin (Visudyne; CIBA Vision Corp, Duluth, Ga). This treatment, termed *verteporfin therapy*, involves an intravenous injection of verteporfin, a photosensitizer, or light-

activated, drug. After infusion, the photosensitizer is activated focally by illumination with light from a laser source at a wavelength that corresponds to an absorption peak of the drug but is not strong enough to create any thermal (photocoagulation) damage. Researchers believe that the mechanism of action may be as follows: the excited photosensitizer generates singlet oxygen and reactive oxygen intermediates associated with damage to cellular compo-

Table 1. Principal Eligibility Criteria for the Treatment of Age-related Macular Degeneration With Photodynamic Therapy (TAP) Investigation

Inclusion Criteria	
Choroidal neovascularization (CNV) secondary to age-related macular degeneration	
CNV under the geometric center of the foveal avascular zone	
Evidence of classic CNV on fluorescein angiography	
Area of CNV at least 50% of the area of the total neovascular lesion	
Greatest linear dimension of lesion \leq 5400 μ m (not including any area of prior laser photocoagulation)	
Best-corrected TAP protocol visual acuity of 73 through 34 letters (Snellen equivalent, approximately 20/40 through 20/200)	
Age \geq 50 years	
Willing and able to provide written informed consent	
Exclusion Criteria	
Tear (rip) of retinal pigment epithelium	
Any significant ocular disease (other than CNV) that has compromised or could compromise vision in the study eye and confound analysis of the primary outcome	
Inability to obtain photographs to document CNV, including difficulty with venous access	
History of treatment for CNV in study eye other than nonfoveal confluent laser photocoagulation	
Participation in another ophthalmic clinical trial or use of any other investigational new drugs within 12 weeks prior to the start of study treatment	
Active hepatitis or clinically significant liver disease	
Porphyria or other porphyrin sensitivity	
Prior photodynamic therapy for CNV	
Intraocular surgery within last 2 months or capsulotomy within last month in study eye	

nents.^{11,12} Verteporfin has been demonstrated to be an effective photosensitizer both in vitro and in vivo.¹³⁻¹⁷ Pre-clinical studies showed that light-activated verteporfin could selectively occlude vessels of experimentally induced CNV in animal models with minimal effects on the surrounding and overlying retina and underlying choroid.¹⁸⁻²⁰

Based on these studies, a phase 1 and 2 investigation was designed to evaluate the safety of verteporfin therapy for the treatment of patients with CNV and to determine the effects of this therapy on fluorescein leakage from CNV.²¹⁻²³ A phase 1 and 2 single-treatment study showed that light-activated verteporfin could cause short-term (1-4 weeks) cessation of fluorescein leakage from CNV without angiographic damage to retinal blood vessels or loss of vision.^{21,23} The data suggested a maximum tolerated light dose less than 150 J/cm² (to avoid retinal vascular occlusion) and a minimum effective light dose greater than 25 J/cm². In almost all cases, leakage recurred by 12 weeks after the initial treatment, even in subjects who had received the maximum tolerated light dose. Therefore, the safety and effects of retreatment with verteporfin therapy were evaluated after multiple treatments.²² These evaluations suggested that repeated treatments could consistently cause short-term cessation of fluorescein leakage from CNV without angiographic damage to the retinal blood vessels or short-term visual acuity loss after each treatment.²² However, return of leakage from CNV typically was noted by 12 weeks after a retreatment (although often involving an area smaller than was noted prior to treatment), suggesting that periodic retreatment for an unknown time

Table 2. Baseline Characteristics by Treatment Group*

Characteristic	Verteporfin, No. (%)	Placebo, No. (%)	P†
Patients	402 (100)	207 (100)	...
Gender			
Women	214 (53.2)	130 (62.8)] .02
Men	188 (46.8)	77 (37.2)	
Race			
White	396 (98.5)	203 (98.1)] .74
Other	6 (1.5)	4 (1.9)	
Age, y			
50-64	39 (9.7)	10 (4.8)] .12
65-74	155 (38.6)	77 (37.2)	
75-84	179 (44.5)	100 (48.3)	
\geq 85	29 (7.2)	20 (9.7)	
Mean	74.9	76.0	
Definite hypertension‡	170 (42.3)	77 (37.2)	.26
No. of letters read (visual acuity§) in study eye			
73-54 (20/40-20/80)	203 (50.5)	101 (48.8)] .66
53-34 (20/100-20/200)	199 (49.5)	106 (51.2)	
Mean (20/80-2)	52.8 (20/80-2)	52.6 (20/80-2)	
No. of letters read (visual acuity§) in fellow eye			
>73 (>20/40)	146 (36.3)	79 (38.2)] .24
54-73 (20/40-20/80)	57 (14.2)	34 (16.4)	
34-53 (20/100-20/200)	44 (10.9)	23 (11.1)	
<34 (<20/200)	155 (38.6)	71 (34.3)	
Mean (20/100-1)	48.9 (20/100-1)	51.8 (20/100+2)	
Mean study eye contrast sensitivity, No. of letters	24.2	24.3	.74
Micronutrient supplement use	220 (54.7)	120 (58.0)	.49
Smoking history			
Never	135 (33.6)	90 (43.5)] .045
Previous	205 (51.0)	94 (45.4)	
Current	62 (15.4)	23 (11.1)	
Lesion area composed of CNV, %			
\geq 50	393 (97.8)	200 (96.6)] .55
>0 to <50	6 (1.5)	6 (2.9)	
0 or could not grade	3 (0.7)	1 (0.5)	
CNV location			
Subfoveal	358 (89.1)	187 (90.3)] .58
Probably subfoveal	24 (6.0)	9 (4.3)	
Not subfoveal	17 (4.2)	11 (5.3)	
Could not grade	3 (0.7)	0 (0.0)	
Lesion area composed of classic CNV, %			
\geq 50	160 (39.8)	84 (40.6)] >.99
>0 to <50	201 (50.0)	103 (49.8)	
0	38 (9.5)	19 (9.2)	
Could not grade	3 (0.7)	1 (0.5)	
Evidence of occult CNV			
Yes	305 (75.9)	157 (75.8)] >.99
No	94 (23.4)	49 (23.7)	
Could not grade	3 (0.7)	1 (0.5)	

Table 2. Baseline Characteristics by Treatment Group (cont)

Characteristic	Verteporfin, No. (%)	Placebo, No. (%)	P†
Evidence of prior laser photocoagulation			
Yes	59 (14.7)	23 (11.1)	.32
No	341 (84.8)	184 (88.9)	
Could not grade	2 (0.5)	0 (0.0)	
Lesion included blood			
Yes	133 (33.1)	87 (42.0)	.053
No	266 (66.2)	120 (58.0)	
Could not grade	3 (0.7)	0 (0.0)	
Lesion with blocked hypofluorescence not caused by visible blood			
Yes	156 (38.8)	85 (41.1)	.59
No	243 (60.4)	122 (58.9)	
Could not grade	3 (0.7)	0 (0.0)	
Serous pigment epithelial detachment			
Yes	1 (0.2)	0 (0.0)	.71
No	398 (99.0)	207 (100.0)	
Could not grade	3 (0.7)	0 (0.0)	
CNV cause			
AMD only	387 (96.3)	197 (95.2)	.70
Other cause, or AMD plus other cause	14 (3.5)	9 (4.3)	
Could not grade	1 (0.2)	1 (0.5)	
Area of lesion, MPS disc areas			
≤3	140 (34.8)	68 (32.9)	.95
>3 to ≤6	191 (47.5)	102 (49.3)	
>6 to ≤9	55 (13.7)	31 (15.0)	
>9	6 (1.5)	2 (1.0)	
Could not grade	10 (2.5)	4 (1.9)	
Greatest linear dimension, diameter of MPS disc area circle			
≤3	107 (26.6)	46 (22.2)	.26
>3 to ≤6	152 (37.8)	97 (46.9)	
>6 to ≤9	109 (27.1)	52 (25.1)	
>9	25 (6.2)	8 (3.9)	
Could not grade	9 (2.2)	4 (1.9)	
Eligible for laser photocoagulation‡			
New subfoveal CNV	20 (5.0)	13 (6.3)	.65
Recurrent subfoveal CNV	12 (3.0)	3 (1.4)	
No	367 (91.3)	190 (91.8)	
Could not determine	3 (0.7)	1 (0.5)	

*CNV indicates choroidal neovascularization; AMD, age-related macular degeneration; and MPS, Macular Photocoagulation Study.

†Fisher exact test for nominal categorical variables, Wilcoxon rank-sum test for continuous categorical variables.

‡Definite hypertension was defined as systolic blood pressure of 160 mm Hg or higher or of 140 to 159 mm Hg with a history of hypertension or use of antihypertension medications or diastolic blood pressure of 95 mm Hg or higher or of 90 to 94 mm Hg with a history of hypertension or use of antihypertension medications.

§Approximate Snellen equivalent.

||According to the MPS guidelines, new subfoveal CNV was judged eligible for laser photocoagulation when the lesion had well-demarcated boundaries, evidence of classic CNV, and size of 2 MPS disc areas or smaller; recurrent subfoveal CNV was judged eligible for laser photocoagulation when the lesion had well-demarcated boundaries, evidence of classic CNV, and a size (including area of prior laser treatment) of 6 MPS disc areas or smaller.

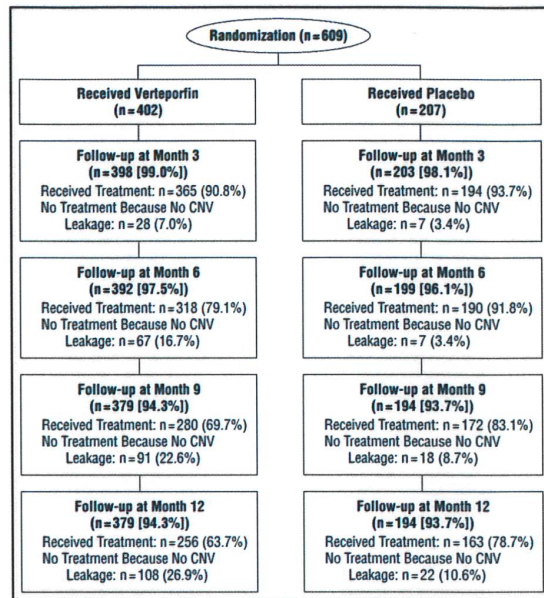


Figure 1. Profile of participants randomized, receiving treatment, and completing follow-up (at least a protocol visual acuity assessment) through 12 months.

would be required in further evaluations of verteporfin therapy for CNV in AMD.

Based on this phase 1 and 2 investigation, 2 phase 3 trials were begun in December 1996. Two identically designed randomized clinical trials (study A and study B), together called the Treatment of Age-Related Macular Degeneration With Photodynamic Therapy (TAP) Investigation, were initiated in North America and Europe to determine if verteporfin therapy could reduce the risk of vision loss compared with placebo in people with subfoveal CNV caused by AMD. This article describes findings regarding the effect of verteporfin therapy compared with placebo therapy through 1 year of follow-up based on all patient visits completed as of September 25, 1998.

RESULTS

Six hundred nine eyes in 609 patients were assigned randomly to verteporfin therapy (402 eyes) or placebo treatment (207 eyes). Four patients who were randomized according to the wrong visual acuity stratum by the clinical center coordinator at baseline were analyzed subsequently within the treatment group to which they were assigned originally. The baseline characteristics for these participants were statistically balanced (**Table 2**), except that there were more women assigned to placebo than verteporfin treatment, more past or current smokers assigned to verteporfin treatment, and more lesions with blood assigned to placebo treatment. Of the 57 eyes judged to have no evidence of classic CNV at baseline, 54 had occult CNV. The other 3 eyes had evidence of fluorescein staining of fibrovascular tissue from CNV but no fluorescein leakage to meet the criteria for classic or occult CNV. Ninety-four percent of patients in each group completed the month 12 follow-up examination (**Figure 1**). The

Table 3. Frequency Distribution of Changes in Visual Acuity From Baseline by Treatment and Visit

Change in Visual Acuity*	No. (%) of Patients			
	3-Month Follow-up		12-Month Follow-up	
	Verteporfin (n = 402)	Placebo (n = 207)	Verteporfin (n = 402)	Placebo (n = 207)
≥6-line increase	1 (0.2)	0 (0.0)	4 (1.0)	0 (0.0)
≥3-line to <6-line increase	8 (2.0)	3 (1.4)	20 (5.0)	5 (2.4)
≥1-line to <3-line increase	62 (15.4)	22 (10.6)	42 (10.4)	10 (4.8)
No change	132 (32.8)	67 (32.4)	87 (21.6)	34 (16.4)
≥1-line to <3-line decrease	126 (31.3)	55 (26.6)	93 (23.1)	47 (22.7)
≥3-line to <6-line decrease	55 (13.7)	37 (17.9)	97 (24.1)	62 (30.0)
≥6-line decrease	18 (4.5)	23 (11.1)	59 (14.7)	49 (23.7)
Mean	-1.2	-2.0	-2.2	-3.5

*Values are approximate; there are 5 letters per line.

†Wilcoxon rank sum test; the verteporfin-treated group had the better outcome.

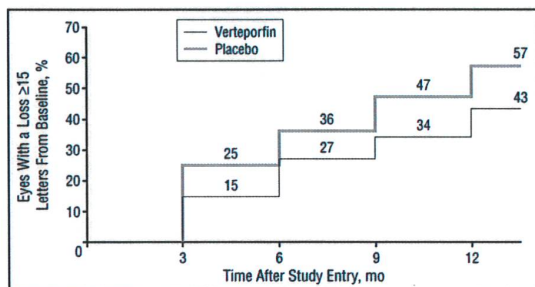


Figure 2. Kaplan-Meier estimates of the cumulative proportion of eyes treated with verteporfin or given placebo with moderate visual acuity loss (≥15 letters or approximately ≥3 lines) at each 3-month study visit over time.

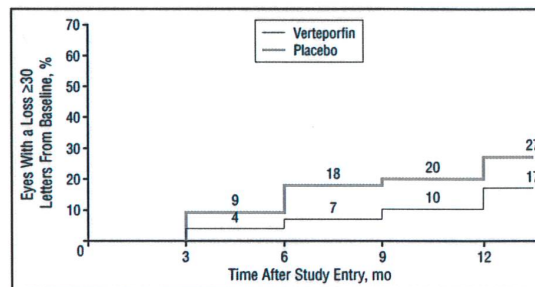


Figure 3. Kaplan-Meier estimates of the cumulative proportion of eyes treated with verteporfin or given placebo with severe visual acuity loss (≥30 letters or approximately ≥6 lines) at each 3-month study visit over time.

number of treatments administered at specific follow-up examinations is shown in Figure 1. By the month 12 examination, but prior to any retreatment at that visit, patients treated with verteporfin had received an average of 3.4 treatments per participant compared with 3.7 treatments per participant for patients given placebo.

VISION OUTCOMES

The change in visual acuity from baseline at the month 3 and month 12 examinations is shown in **Table 3**. Beneficial effects of verteporfin treatment compared with placebo with respect to change in visual acuity were noted starting with the month 3 examination. For the primary outcome at the month 12 examination, 61.2% of the eyes treated with verteporfin compared with 46.4% of the eyes given placebo had lost fewer than 15 letters or approximately less than 3 lines of visual acuity ($P < .001$). The entire change in visual acuity distribution differed by 1.3 lines, on average, in favor of the eyes treated with verteporfin 1 year after study entry. Eyes treated with verteporfin had more improvements of 1 or more lines of visual acuity (16% vs 7%) and were more likely to avoid a loss of 6 lines or more (85% vs 76%). Based on estimates from Kaplan-Meier rates at every follow-up examina-

tion after study entry through the month 12 examination, the proportion of eyes with a loss of 15 or more letters (approximately ≥3 lines) (**Figure 2**) or a loss of 30 or more letters (approximately ≥6 lines) (**Figure 3**) was lower in the verteporfin-treated group.

The level of visual acuity at the month 3 and month 12 examinations is shown in **Table 4**. Although both groups had a similar mean visual acuity at baseline (approximate Snellen equivalent of 20/80 - 2), by month 12 the mean visual acuity in eyes treated with verteporfin compared with eyes given placebo was 20/160 + 2 vs 20/200. The entire visual acuity distribution at this visit shifted in favor of the verteporfin-treated eyes, which were less likely to have a visual acuity worse than 20/200 and more likely to have a visual acuity better than 20/80. The mean number of contrast sensitivity letters lost (**Figure 4**) was approximately 1 in the eyes treated with verteporfin compared with approximately 3 to 5 in the eyes given placebo at every follow-up visit through the month 12 examination.

FLUORESCIN ANGIOGRAPHIC OUTCOMES

The proportion of eyes with progression of classic CNV beyond the area of the lesion identified at baseline is shown in **Figure 5** for the eyes with classic CNV at baseline.

Table 4. Visual Acuity Categories in Study Eyes by Treatment and Visit

Visual Acuity, No. of Letters (Approximate Snellen Equivalent)	No. of Patients			
	3-Month Follow-up		12-Month Follow-up	
	Verteporfin (n = 402)	Placebo (n = 207)	Verteporfin (n = 402)	Placebo (n = 207)
>73 (>20/40)	14 (3.5)	0 (0.0)	19 (4.7)	2 (1.0)
54-73 (20/40-20/80)	123 (30.6)	65 (31.4)	93 (23.1)	30 (14.5)
34-53 (20/100-20/200)	181 (45.0)	81 (39.1)	150 (37.3)	76 (36.7)
≤33 (<20/200)	84 (20.9)	61 (29.5)	140 (34.8)	99 (47.8)
Mean	47 (20/126+2)	43 (20/126-2)	42 (20/160+2)	35 (20/200)

*Wilcoxon rank sum test; the verteporfin-treated group had the better outcome.

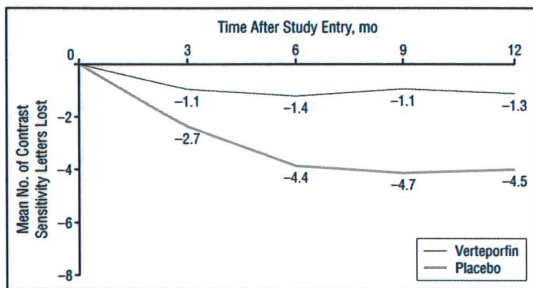


Figure 4. Mean number of letters of contrast sensitivity lost at each 3-month study visit over time for eyes assigned to verteporfin treatment or placebo.

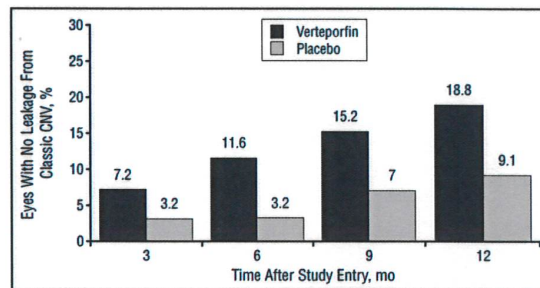


Figure 6. Percentage of eyes treated with verteporfin (n = 361) and eyes given placebo (n = 187) with complete absence of leakage from classic choroidal neovascularization (CNV) at each 3-month study visit over time when classic CNV was present at baseline.

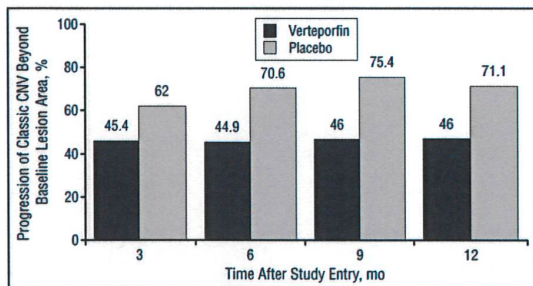


Figure 5. Percentage of eyes treated with verteporfin (n = 361) and eyes given placebo (n = 187) identified at baseline with classic choroidal neovascularization (CNV) with progression of classic CNV beyond the lesion's area at baseline at each 3-month study visit over time.

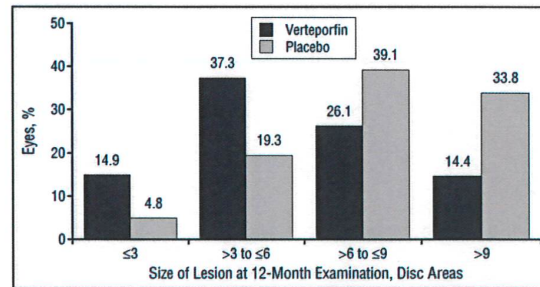


Figure 7. Distribution of lesion sizes at the month 12 examination for 402 eyes assigned to verteporfin treatment and 207 eyes assigned to placebo.

By the month-12 examination, 166 (46%) of 361 eyes treated with verteporfin that had classic CNV at baseline had progression compared with 133 (71%) of 187 eyes given placebo, and fluorescein leakage was absent in 68 (19%) of the eyes treated with verteporfin compared with 17 (9%) of the eyes given placebo (**Figure 6**).

For eyes without classic CNV at baseline, 12 (32%) of 38 eyes treated with verteporfin compared with 10 (53%) of 19 eyes given placebo had evidence of classic CNV identified on the fluorescein angiogram obtained at month 12. This classic CNV was classified as progression (extending beyond the area of the lesion identified at baseline) in 5 (13%) of the eyes treated with verteporfin compared with 9 (47%) of the eyes given placebo.

With respect to eyes with evidence of occult CNV at study entry, no major differences were noted between the verteporfin and placebo groups based on angiographic outcomes of occult CNV. Progression of occult CNV was noted in 72% of eyes treated with verteporfin compared with 80% of eyes given placebo by month 12.

The lesion size at the month 12 examination is reported in **Figure 7**. Beginning with the month 3 examination, the lesions had less growth in the verteporfin-treated group (**Figure 8**) compared with the placebo-treated group. By the month 12 examination, placebo-treated lesions were almost twice as likely as verteporfin-treated lesions to be 6 or more disc areas in size.

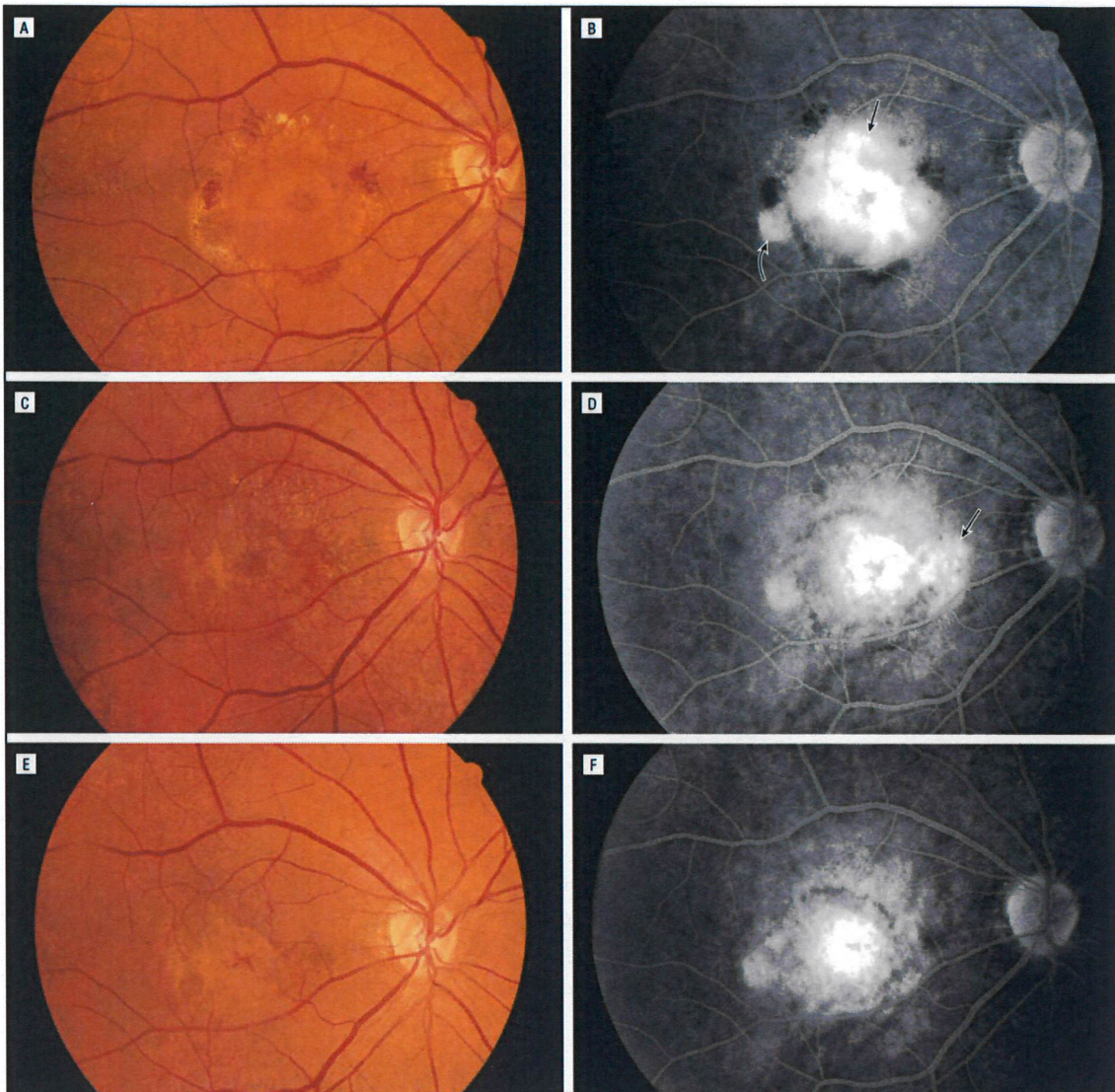


Figure 8. Example of verteporfin treatment of subfoveal choroidal neovascularization (CNV) in which no progression of classic CNV was noted by the month 12 examination beyond the area of the lesion identified at baseline. A, Color fundus photograph at baseline shows subretinal fluid under the center of the foveal avascular zone, with subretinal hemorrhage and lipid. B, Late-phase fluorescein angiogram at baseline shows leakage from classic (straight arrow) and occult (curved arrow) CNV. C, Color fundus photograph 3 months after initial treatment shows marked decrease in subretinal fluid, hemorrhage, and lipid. D, Late-phase fluorescein angiogram shows a decrease in the area of leakage within the area of the lesion identified at baseline, with some progression of leakage noted along the nasal aspect of the lesion (arrow). E, Color fundus photograph 12 months after initial treatment with retreatments applied at the 3-, 6-, and 9-month follow-up examinations shows complete resolution of the subretinal fluid, hemorrhage, and lipid, with small area of fibrosis within the area of the lesion identified at baseline. F, Late-phase fluorescein angiogram shows some staining and questionable leakage within the central area of the lesion identified at baseline and no progression of leakage from the CNV boundaries identified at baseline.

SUBGROUP ANALYSES

Subgroup analyses for the primary outcome at the month 12 examination (**Table 5**), based on the trial assignment (study A and study B) and selected lesion characteristics listed in Table 2, were undertaken to understand treatment effects in different subpopulations. No subgroups were identified in which eyes given placebo fared better than eyes treated with verteporfin to suggest any harmful effect. Only the lesion compo-

nents at baseline affected the magnitude of the treatment benefit to a statistically significant degree (Table 5) ($P_i \leq .05$ for the test of interaction). Specifically, subgroup analysis showed a large treatment benefit when the lesion was predominantly classic CNV (ie, the area of classic CNV occupied $\geq 50\%$ of the area of the entire lesion) at baseline, with 33% of the 159 eyes treated with verteporfin compared with 50 (61%) of the 84 eyes given placebo losing 15 or more letters at the month 12 examination.

Table 5. Eyes With a Loss of Less Than 15 Letters at Month 12 by Treatment Group and Baseline Characteristics*

Characteristic	Treatment Group	No. of Eyes	Loss <15 Letters, %	Difference, Percentage Points	P†	P‡
All eyes	V	402	61.2	14.8	<.001	NA
	P	207	46.4			
Trial						.84
Study A	V	204	59.8	14.0	.02	
	P	107	45.8			
Study B	V	198	62.6	15.6	.01	
	P	100	47.0			
Age, y						.09
<75	V	194	68.0	22.0	<.001	
	P	87	46.0			
≥75	V	208	54.8	8.1	.16	
	P	120	46.7			
Gender						.45
Men	V	188	58.5	19.5	.004	
	P	77	39.0			
Women	V	214	63.6	12.8	.02	
	P	130	50.8			
Systemic hypertension						.46
Definite§	V	170	60.6	19.0	.005	
	P	77	41.6			
Others	V	232	61.6	12.4	.02	
	P	130	49.2			
Smoking history						.75
Never	V	135	62.2	13.3	.048	
	P	90	48.9			
Past	V	205	59.5	18.0	.004	
	P	94	41.5			
Current	V	62	64.5	8.0	.50	
	P	23	56.5			
Initial No. of letters read (visual acuity) in study eye						.46
73-54 (20/40-20/80)	V	203	54.7	12.1	.047	
	P	101	42.6			
53-34 (20/100-20/200)	V	199	67.8	17.8	.002	
	P	106	50.0			
Greatest linear dimension, diameter of MPS disc area circle¶						.76
≤3	V	107	67.3	10.8	.20	
	P	46	56.5			
>3 to ≤6	V	152	62.5	17.1	.008	
	P	97	45.4			
>6 to ≤9	V	109	53.2	10.9	.20	
	P	52	42.3			
>9	V	25	56.0	31.0	.13	
	P	8	25.0			

Continued on next page

When the entire study population was subgrouped by absence or presence of occult CNV, the subgroup with no occult CNV also had a substantial treatment benefit. This latter finding, though, did not account for all of the treatment benefit noted for cases with predominantly classic CNV. Specifically, for the eyes with predominantly classic CNV and no occult CNV, 21 (23%) of the 90 patients treated with verteporfin compared with 32 (73%) of the 44 patients given placebo had lost 15 or more letters ($P < .001$); 9 (10%) of the 90 patients treated with verteporfin compared with 18 (41%) of the 44 patients given placebo had lost 30 or more letters ($P < .001$). For the eyes with predominantly classic CNV and occult CNV present, 31 (45%) of the 69 patients treated with verteporfin compared with 19 (47%) of the 40 patients given placebo had lost 15 or more letters ($P = .80$); 10 (14%)

of the 69 patients treated with verteporfin compared with 10 (25%) of the 40 patients given placebo had lost 30 or more letters ($P = .17$).

No appreciable difference was observed in the group of patients with lesions in which the area of classic CNV was greater than 0% but less than 50% of the area of the entire lesion at baseline. In contrast, the subgroup with no classic CNV had a large treatment benefit; however, the number of patients in this subgroup was small and did not meet the eligibility criteria for the trials according to the Photograph Reading Center's interpretation of the angiogram. In the subgroup with no classic CNV, all patients but 3 had occult CNV but no classic CNV. The other 3 patients were judged by the Photograph Reading Center to have fluorescein staining of a scar from CNV but no leakage pattern consistent with either classic or occult CNV.

Table 5. Eyes With a Loss of Less Than 15 Letters at Month 12 by Treatment Group and Baseline Characteristics* (cont)

Characteristic	Treatment Group	No. of Eyes	Loss <15 Letters, %	Difference, Percentage Points	P†	P‡
Lesion area composed of classic CNV, %#						.004
≥50	V	159	67.3	28.0	<.001	
	P	84	39.3			
>0 to <50	V	202	55.9	0.6	.92	
	P	103	55.3			
0	V	38	63.2	31.6	.02	
	P	19	31.6			
Evidence of occult CNV**						<.001
Yes	V	305	56.4	4.8	.33	
	P	157	51.6			
No	V	94	76.6	46.0	<.001	
	P	49	30.6			
Evidence of prior laser photocoagulation††						.31
Yes	V	59	59.3	2.8	.82	
	P	23	56.5			
No	V	341	61.3	16.2	<.001	
	P	184	45.1			
Area of lesion considered to be fibrosis, %‡‡						.53
0-25	V	313	60.1	14.3	.004	
	P	153	45.8			
26-50	V	44	56.8	6.8	.59	
	P	24	50.0			
>50	V	39	71.8	25.4	.04	
	P	28	46.4			
Lesion included blood§§						.22
Yes	V	133	63.9	21.4	.002	
	P	87	42.5			
No	V	266	59.8	10.6	.052	
	P	120	49.2			

*V indicates verteporfin-treated group; P, placebo-treated group; NA, not applicable; MPS, Macular Photocoagulation Study; and CNV, choroidal neovascularization.

† χ^2 test for treatment effect within subgroups.

‡Test of interaction between subgroups (logistic regression).

§Definite hypertension was defined as systolic blood pressure of 160 mm Hg or higher or of 140 to 159 mm Hg with a history of hypertension or use of antihypertension medications or diastolic blood pressure of 95 mm Hg or higher or of 90 to 94 mm Hg with a history of hypertension or use of antihypertension medications.

||Approximate Snellen equivalent.

¶Nine additional patients treated with verteporfin and 4 additional patients given placebo had a greatest linear dimension that could not be graded on photographs.

#Unknown for 3 additional patients treated with verteporfin and 1 patient given placebo.

**Unknown for 3 additional patients treated with verteporfin and 1 patient given placebo.

††Unknown for 2 additional patients treated with verteporfin.

‡‡Unknown for 6 additional patients treated with verteporfin and 2 patients given placebo.

§§Unknown for 3 additional patients treated with verteporfin.

To explore these subgroup findings further, visual acuity distributions (Figure 9), mean change in contrast sensitivity (Table 6), and angiographic outcomes (Table 6) at the month 12 examination were evaluated, based on lesion components noted at baseline. The lesion components at baseline affected the magnitude of the treatment benefit with respect to the visual acuity distributions. The lesion component also affected the magnitude of the treatment benefit with respect to mean change in contrast sensitivity to a significant degree ($P_1 = .02$ for the test of interaction), but did not affect the magnitude of the treatment benefit with respect to progression of classic CNV or lesion size greater than 6 disc areas.

SAFETY

An adverse event (irrespective of relationship to treatment) was reported in 333 patients treated with verte-

porfin (83%) and 178 patients given placebo (86%). Adverse events considered by the treating ophthalmologist to be associated with treatment were reported in 185 patients (46%) treated with verteporfin and 74 (36%) of those given placebo. Adverse events judged to be clinically relevant, listed in Table 7, were slightly more common in patients assigned to verteporfin treatment. For nonocular adverse events, there were increased incidences of adverse events related to injection site, including injection site pain, edema, hemorrhage, inflammation, or other events, in 13.4% of patients treated with verteporfin compared with 3.4% of patients given placebo. Photosensitivity reactions were noted only in 12 patients (3.0%) treated with verteporfin. In 2 of these patients, the reactions were judged not to be caused by verteporfin. The reactions were generally transient, mild to moderate sunburns caused by direct sunlight exposure shortly after drug administration, usually within 24 hours.

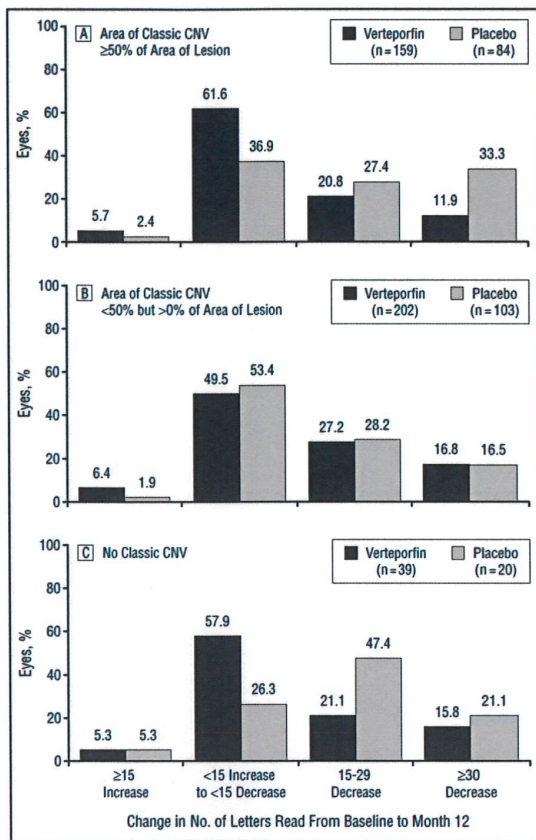


Figure 9. Distribution of change in visual acuity at the month 12 examination for eyes treated with verteporfin and eyes given placebo by lesion components at baseline.

There were 8 deaths (2.0%) among patients assigned to verteporfin treatment and 4 (1.9%) among those given placebo; none of these deaths were considered to be related to treatment. Seven patients (1.7%), all in the verteporfin-treated group, stopped treatment because of an adverse reaction that the treating ophthalmologist judged could have been related to study treatment. Events included 1 allergy to fluorescein dye, 1 subretinal hemorrhage, 1 gastrointestinal bleeding episode, 1 possible allergic reaction to treatment, 1 patient with severe back pain possibly related to the infusion, 1 suprachoroidal hemorrhage with retinal detachment and vitreous hemorrhage, and 1 injection site (drug extravasation) reaction.

An increase in subretinal or intraretinal hemorrhage as determined by the Photograph Reading Center at the month 3 examination was more likely in the eyes given placebo (93 [45%] of 207 eyes) compared with the eyes treated with verteporfin (116 [29%] of 402 eyes). At each subsequent 3-month follow-up examination, the proportion of eyes with increased subretinal or intraretinal hemorrhage compared with baseline was lower than at previous visits and always lower at a particular visit in the verteporfin-treated group compared with the placebo-treated group. The distribution of the size of the lesion plus any surrounding atrophy for each group was

not significantly different than the distribution of the size of the lesion without the inclusion of surrounding atrophy, suggesting that verteporfin-treated eyes developed no additional surrounding atrophy compared with placebo-treated eyes.

COMMENT

These 2 randomized clinical trials show that verteporfin therapy reduces the risk of vision loss compared with placebo for at least 1 year in some patients with AMD who also have subfoveal CNV. The visual acuity results were complemented by similar outcomes for contrast sensitivity evaluations. Fluorescein angiographic assessments at follow-up examinations suggested that verteporfin treatment reduced lesion growth, was associated with cessation of leakage from classic CNV, and decreased the progression of classic CNV. These angiographic outcomes support the identification of a beneficial effect on vision. The therapy was well tolerated, with few adverse events. The retinal arteriolar and venular non-perfusion that were noted at higher light doses in a phase 1 and 2 study²¹ were not noted at the light dose used in the present study. The overall beneficial results were noted in a broad group of patients with respect to a wide range of visual acuities and lesion sizes. Subgroup analyses, however, showed that the lesion composition affected the magnitude of the treatment benefit to a statistically significant degree. Predominantly classic CNV lesions (in which the area of classic CNV was $\geq 50\%$ of the area of the entire lesion at baseline) had a significant treatment benefit; lesions in which the area of classic CNV was greater than 0% but less than 50% of the area of the entire lesion at baseline had no visual acuity benefit with treatment (ie, no difference in the proportion of cases with a loss of ≥ 15 letters). Even after adjustment for possibly confounding effects of several baseline covariates (data not shown, but detailed descriptions of the methods and results are planned for future reports), the relationship remained for the baseline lesion components ($P < .001$).

The treatment benefit is highly unlikely to be due to chance because of consistent results across 2 identically designed studies at multiple sites, 2 vision outcome assessments (visual acuity and contrast sensitivity), and confirmatory information on fluorescein angiography. Bias is highly unlikely given the masking of the patients, treating ophthalmologists, vision examiners, and photograph graders. Differences in the baseline characteristics of the treatment groups do not seem to weaken the confidence in the study results. Specifically, the slight imbalance of more women, more lifetime nonsmokers, more lesions with blood, and more patients with no prior laser treatment at baseline assigned to placebo did not seem to diminish the magnitude of these positive results. The use of the last observation carried forward method to account for missing data had little impact on the overall results since the loss to follow-up was so small (6%) in each group at the month 12 examination. Analysis without the last observation carried forward resulted in the same conclusions (data not shown).

The angiographic outcomes for progression of classic CNV, absence of leakage from classic CNV, and size

Table 6. Secondary Outcomes at Month 12 Examination by Baseline Lesion Components*

Baseline Lesion Components	Treatment Group	No. of Eyes		P†	P‡
Mean No. of Contrast Sensitivity Letters Lost					
			No.	Difference, No.	
Classic CNV ≥50% of lesion	V	159	0.4	5.1	<.001
	P	84	5.5		
Classic CNV <50% of lesion	V	202	2.0	2.1	.008
	P	103	4.1		
No classic CNV	V	38	1.5	0.8	.65
	P	19	2.3		
Patients With Progression of Classic CNV					
			%	Difference, Percentage Points	
Classic CNV ≥50% of lesion	V	159	57.2	24.9	<.001
	P	84	82.1		
Classic CNV <50% of lesion	V	202	37.1	25.0	<.001
	P	103	62.1		
No classic CNV	V	38	13.2	34.2	.005
	P	19	47.4		
Patients With Lesion Size >6 Disc Areas					
			%	Difference, Percentage Points	
Classic CNV ≥50% of lesion	V	159	39.6	34.2	<.001
	P	84	73.8		
Classic CNV <50% of lesion	V	202	45.5	26.3	<.001
	P	103	71.8		
No classic CNV	V	38	21.1	52.6	<.001
	P	19	73.7		

*V indicates verteporfin-treated group; P, placebo-treated group; and CNV, choroidal neovascularization.

† χ^2 test for treatment effect within subgroups.

‡Test of interaction between treatment subgroup (analysis of variance for contrast sensitivity, logistic regression for progression of classic CNV and lesion size).

Table 7. Clinically Relevant Adverse Events Irrespective of Relationship to Treatment

Event	Verteporfin (n = 402), No. (%)	Placebo (n = 207), No. (%)
Visual disturbance*	71 (17.7)	24 (11.6)
Vitreous hemorrhage	4 (1.0)	1 (0.5)
Retinal capillary nonperfusion	1 (0.2)	2 (1.0)
Injection site adverse events†	54 (13.4)	7 (3.4)
Infusion-related back pain	9 (2.2)	0 (0.0)
Allergic reactions	5 (1.2)	7 (3.4)
Photosensitivity reactions	12 (3.0)	0 (0.0)

*Includes reports of abnormal vision, decreased vision, and visual field defect irrespective of judgment of relationship to study treatment.

†Includes edema and extravasation (12 patients treated with verteporfin [3.0%]), fibrosis, hemorrhage, hypersensitivity, inflammation, and pain (35 patients treated with verteporfin [8.7%] and 1 patient given placebo [0.5%]).

of the lesion provided an objective, masked confirmation of the vision results. Fluorescein angiographic assessment of leakage from occult CNV at all follow-up examinations showed little difference for eyes treated with verteporfin vs eyes given placebo with respect to progression of occult CNV. Nevertheless, the entire lesion size, which incorporates the total area of the fibrovascular lesion, including all classic and occult CNV, was more likely to be less than 6 disc areas at the 12-month examination for patients treated with verteporfin, regardless of the proportion of the lesion that was classic or oc-

cult CNV at baseline (Table 6). One possible explanation for these findings is that the treatment effect on classic CNV accounted for most of the treatment effect on lesion size. Another possibility was that the treatment effect (a 500- μ m margin of additional treatment surrounded the boundaries of the lesion) might have affected the retinal pigment epithelium immediately surrounding the lesion to create a fluorescein staining pattern that was impossible to differentiate from the fluorescein staining pattern of occult CNV, resulting in false-positive progression of occult CNV in some of the eyes treated with verteporfin. This possibility could result in absence of a treatment effect on progression of occult CNV despite a treatment effect that confined the lesion size for lesions that incorporated both classic and occult CNV.

Since patients were to be enrolled only if their lesions had evidence of classic CNV, and since the lesion components may have an impact on the treatment benefit, as suggested by the subgroup analyses reported, the ability to identify classic CNV may be important in verteporfin therapy. Furthermore, since the treatment involves identification of the entire area of a CNV lesion, including not only classic CNV, but also any occult CNV to determine the proportion of the lesion that is classic CNV, recognition of occult CNV is important in verteporfin therapy. Although the subgroup analyses showed beneficial visual acuity outcomes for lesions that were predominantly classic CNV at baseline, lesions with classic CNV that occupied less than 50% of the area of the lesion did fare better when assigned to verteporfin therapy with re-

Treatment of Age-related Macular Degeneration With Photodynamic Therapy (TAP) Study Group

Participating Clinics, Investigators (principal investigators are listed first), Clinic Coordinators, Vision Examiners, and Photographers in the TAP Study Group as of November 30, 1998.

Clinical Centers

Aberdeen Royal Infirmary Eye Outpatients, Aberdeen, Scotland: Jennifer Arnold, FRACO, Dara Kilmartin, FRCOphth, John Olson, MRCP(UK), Sean Neville, Karen Robinson, Allison Laird, Claire Richmond, Gary Evans, Alison Farrow, Sandra McKay.

The Wilmer Ophthalmological Institute, Johns Hopkins University, Baltimore, Md: Andrew P. Schachat, MD, Neil M. Bressler, MD, Susan B. Bressler, MD, Pat Nesbitt, RN, Tracey Porter, COT, Patricia Hawse, BLA, COMT, Mike Hartnett, COT, Judy Belt, Mark Herring, Jacquelyn McDonald, Dennis Cain, CRA, Terry George.

Instituto de Microcirugia Ocular de Barcelona, Barcelona, Spain: Jordi Monés, MD, Borja Corcóstegui, MD, Montse Gibert, MD, Nuria Duran, Maite Sisquella, Ana Nolla, Alfons Margalef.

Massachusetts Eye and Ear Infirmary, Harvard Medical School, Boston, Mass: Joan W. Miller, MD, Evangelos S. Gragoudas, MD, Anne Marie Lane, Amy E. Holbrook, Nicholas Emmanuel, Claudia Evans, OD, Ursula Szajta Lord, OD, David K. Walsh, Charlene D. Callahan, Jennifer L. DuBois. Past participating personnel: Alice George Kenney, Inge Milde, Jennifer Moy, Eric S. Platz.

Cole Eye Institute, The Cleveland Clinic Foundation, Cleveland, Ohio: Hilel Lewis, MD, Peter K. Kaiser, MD, Laura J. Holody, Erica Lesak, Susan Lichterman, RN, Joyce Conway, Helene Siegel, Anthony Fattori, Ginny Ambrose, Tami Fecko, Deborah Ross.

Retina Associates of Cleveland: Lawrence Singerman, MD, Hernando Zegarra, MD, Michael Novak, MD, Kimberly Tilocco, Michelle Bartel, Mary Iic, Stephanie Schura, Sheri Joyce (Mayes), Vivian Tanner, Pam Rowe, Sheila Smith-Brewer, Donna Kukula, Greg Greanof, Geraldine Daley, John Dubois, David Lehnhardt.

Texas Retina Associates, Dallas: Gary Fish, MD, Bradley Jost, MD, Rajiv Anand, MD, David Callanan, MD, Sally Arceneaux, COA, Penny Ellinich, John King, Bob Boleman, Karen Duignan, Cynthia Nork, Teresa Anderson.

Hôpital Cantonal Universitaire de Genève, Geneva, Switzerland: Constantin J. Pournaras, MD, Guy Donati, MD, Katty Cavalière, Anastasios D. Kapetanos, MD, S. Guney-Wagner, N. Gerber.

Hôpital Ophtalmique Universitaire, Lausanne, Switzerland: Michel Sickenberg, MD, Bertrand Piguet, MD, Valérie Sickenberg, MD, Alice Gans, Birgit Hosner, Alexandre Sbressa, Christoph Kozma, Marc Curchod, Simonetta Ardoni (Cancelli).

St Paul's Eye Unit, Royal Liverpool University Hospital, Liverpool, England: Simon Harding, FRCOphth, Yit Chiun Yang, FRCOphth, Michael Briggs, FRCS, Sandra Murphy, RGN, Valerie Tompkin, MCOptom, Andrew Tompkin, Ronnie Jackson, Stephen Pearson.

Medizinische Universität zu Lübeck, Klinik für Augenheilkunde, Lübeck, Germany: Ursula Schmidt-Erfurth, MD, Irene Barbazetto, MD, Regina Kupfer, Renate Bülow, Mathias Grote, Roswitha Gordes, MD, Birte Neppert, MD, Bernadette Glisovic, Tanja Bredfeldt.

Zweng Memorial Retinal Research Foundation, Menlo Park, Calif: Hunter Little, MD, Mark Blumenkranz, MD, Robert Jack, MD, Lenilyn Espiritu, Lora Jimenez, Christi Silvestri, Patti Mattio.

Bascom Palmer Eye Institute, University of Miami, Miami, Fla: Robert H. Rosa, Jr, MD, Philip J. Rosenfeld, MD, PhD, Mary Lou Lewis, MD, Beatriz Herrera, Belen Rodriguez, Arellys Torres, Nayla Muniz, Nidia Rodaso, Tulio Contreras, Michele Galvez, Ditte Hess, Tony Cubillas, Isabel Rams.

Vitreous-Retina-Macula Consultants of New York, New York, NY: Jason S. Slakter, MD, John A. Sorenson, MD, Jeanine Napoli, MPH, Pia Angeli Bruschi, MS, Katherine Burke, COMT, Elizabeth Schnipper, OD, Leandro Maranan, Michael Riff, Eugene Agresta.

Département d'Ophtalmologie, Hôpital Intercommunal de Créteil, Paris, France: Gisèle Soubrane, MD, Dagmar Kuhn, MD, Maddalena Quaranta, MD, Abla Benelhani, Aline Kunsch, Bruno Delhoste, Christophe Debibie, Marc Lasnier.

Retina Vitreous Consultants, Pittsburgh, Pa: Louis Lobes, MD, Karl Olsen, MD, Barbara Bahr, Nancy Worstell, Linda Wilcox, Lynn A. Wellman, Gary Vagstad, David Steinberg, Alan Campbell.

Devers Eye Institute, Portland, Ore: Colin Ma, MD, Richard Dreyer, MD, Brenda Williamson, Dana Graves, Kathryn Jelinek, Susan Pope, Rebecca Boone. Past participating personnel: Hiroko Anderson.

Associated Retinal Consultants, Royal Oak, Mich: Raymond R. Margherio, MD, George A. Williams, MD, Mary Zajechowski, Linda Vandell, Gina Regan, Patricia Manatrey, Cheryl Stanley, Tony Medina, Craig Bridges, Gary Huston, Patricia Streasick, Lynette Szdowski, Rachel Falk. Past participating personnel: Renee Fadel, Kristi Cumming, Beth Mitchel.

Service d'Ophtalmologie, Hôpital Bellevue, St Etienne, France: Françoise Koenig, MD, Martine Mauget, MD, Mustapha Benchaboune, MD, Khadidja Mezmate, MD, Sandrine Fontanay.

Eye Research Institute of Canada, University of Toronto, Ontario: Patricia Harvey, MD, Lisa Kaus, Doris Leuschner, Susan Bolychuk, Jeff Voyce, Ismay Hewitt.

Vancouver Hospital Eye Care Center, University of British Columbia: Michael Potter, MD, Bal Sahota, Sushma Rai, MD, Don Johnson, Laura Hall.

Allgemeines Krankenhaus, Klinik für Augenheilkunde und Optometrie, Vienna, Austria: Michael Stur, MD, Julius Lukas, MD, Michael Tittl, MD, Sabine Döcker, Karin Vogl.

Fundus Photograph Reading Center

The Wilmer Ophthalmological Institute, Baltimore: Susan B. Bressler, MD (principal investigator), Neil M. Bressler, MD, Dante J. Pieramici, MD, Kelly Manos, Rochelle Cooper, Yan Tian, Elaine Lowery, Debi Phillips, Stephanie Thibeault, Rita Denbow. Past participating personnel: Judith Alexander.

Treatment of Age-related Macular Degeneration With Photodynamic Therapy (TAP) Study Group (cont)

Medical Device/Laser Consultants

Reginald Birngruber, PhD, Joan W. Miller, MD, Hubert van den Berg, PhD.

Visual Acuity Monitors/Certifiers

The Wilmer Ophthalmological Institute, Baltimore: Mike Harnett, Patti Hawse, Peggy R. Orr.

Clinic Monitors

Ronald Alder, Susan Banasik, Sonja Bangerter, Nadine Black, Pilar Escartin, Danette Hartley, Pam Haworth, Renee Henriques (Endpoint Research Ltd, Mississauga, Ontario), Deborah Hiscock, Jan North, Beverly Norton, Cynthia H. Sawyer, Marjorie Sine (Endpoint Research Ltd), Tracy Stapleton, Ronald Taylor, Kerry Thomas.

CIBA Vision AG, Bülach, Switzerland

Gustave Huber, PhD (project leader), Jean-Yves Deslandes, MD, Mario Fsadni, MD, Indira Hess, Hervé de Pommerol.

CIBA Vision Corp, Duluth, Ga

Al Reaves, PhD, Susan Banasik, John Koester, Todd Gray, Kim Truett, Janice Baker.

QLT PhotoTherapeutics Inc, Vancouver, British Columbia

H. Andrew Strong, PhD (TAP clinical project director), Noël Buskard, MD, Ulrike Manjuris, PhD, Yong Hao, MD, PhD, Sonia Rychel, Heidi Biagi, Kate Thorne, Mohammad Azab, MD, Alexandra Mancini, Lee Anne Pilson.

Committees

Writing Committee: Jennifer Arnold, FRACO, Mark Blumenkranz, MD, Neil M. Bressler, MD, Susan B. Bressler, MD, Jean-Yves Deslandes, MD, Guy Donati, MD, Gary Fish, MD, Evangelos S. Gragoudas, MD, Patricia Harvey, MD, Gustave Huber, PhD, Peter K. Kaiser, MD, Lisa Kaus, Françoise Koenig, MD, John Koester, Hilel Lewis, MD, Louis Lobes, MD, Raymond R. Margherio, MD, Joan W. Miller, MD, Jordi Monés, MD, Sandra Murphy, RGN, Al Reaves, PhD, Philip J. Rosenfeld, MD, PhD, Andrew P. Schachat, MD, Ursula Schmidt-Erfurth, MD, Michel Sickenberg, MD, Lawrence Singerman, MD, Jason S. Slakler, MD, H. Andrew Strong, PhD, Michael Stur, MD, George A. Williams, MD.

Operations Committee: Neil M. Bressler, MD, Ulrike Manjuris, PhD, Al Reaves, PhD, H. Andrew Strong, PhD.

Data and Safety Monitoring Committee: Roy W. Beck, MD (chair), Alan C. Bird, MD, Gabriel Coscas, MD, August Deutman, MD, Lee Jampol, MD, Ronald Klein, MD, Maureen Maguire, PhD.

Study Advisory Group: Neil M. Bressler, MD (chair), Susan B. Bressler, MD, Gustave Huber, PhD, Ulrike Manjuris, PhD, Joan W. Miller, MD, Michel Sickenberg, MD, Ursula Schmidt-Erfurth, MD, Al Reaves, PhD, H. Andrew Strong, PhD. Rotating members: Guy Donati, MD, Lisa Kaus, Raymond R. Margherio, MD, Jordi Monés, MD, Jason Slakler, MD, Gisele Sourbrane, MD, PhD. Consultant: Raymond R. Margherio, MD. Administrative assistant: Pat Staffin.

spect to contrast sensitivity measurements, progression of classic CNV, and lesion growth. These findings may or may not become associated with a beneficial visual acuity outcome by the month 24 follow-up examination. It is difficult to compare the subgroup analysis by baseline lesion components in this investigation with similar subgroup analyses of laser photocoagulation. In the largest reported randomized clinical trial evaluating laser photocoagulation for subfoveal CNV from AMD,⁵ lesion composition did not affect the magnitude of treatment benefit, although there were only 21 treated eyes and 28 observed eyes that had both classic and occult CNV.

Although there was a small proportion of cases enrolled in this trial with no evidence of classic CNV as judged by the Photograph Reading Center graders, it is not known whether these cases represent the universe of occult CNV lesions without classic CNV in AMD since the enrolling ophthalmologist believed that these cases had some evidence of classic CNV. Even though a treatment benefit was noted for this subgroup of cases, the total number of cases was small, so that the effects of treatment for these cases remains imprecise. A companion phase 3b investigation, the Verteporfin in Photodynamic Therapy Trial, which includes a large proportion of subfoveal lesions in AMD with occult CNV but no classic CNV, should provide further understanding with respect to the benefits of this therapy in small and large lesions with occult CNV but no classic CNV.³¹

It is unknown at this time whether the overall beneficial outcomes noted in this report will remain the same,

increase, or decrease with a longer follow-up period. The TAP investigation has been designed to obtain follow-up within the group to which the patient was assigned for up to 2 years. The TAP Study Group anticipates reporting the results of further analyses, including the second year of follow-up examinations, in subsequent reports.

CONCLUSIONS

The significant reduction in risk of vision loss noted with verteporfin therapy in this investigation, coupled with the absence of any clinically significant risk of systemic or ocular harm through 1 year of follow-up, leads us to recommend, if the drug is approved by regulatory agencies for commercial availability, verteporfin therapy in the treatment of patients with predominantly classic subfoveal CNV caused by AMD, especially when the lesion has classic CNV and no occult CNV.

Accepted for publication June 24, 1999.

This study was sponsored by QLT PhotoTherapeutics Inc, Vancouver, British Columbia, and CIBA Vision AG, Bülach, Switzerland.

The Massachusetts Eye and Ear Infirmary has a proprietary interest in this technology as part of a patent and under a research agreement with Coherent Inc, Palo Alto, Calif. Drs Miller and Gragoudas are participants in this proprietary interest under the guidelines of Harvard Medical School, Boston, Mass.

We thank all of the patients who agreed to participate in this investigation, which would not have been possible without them.

Corresponding author: Neil M. Bressler, MD, Ninth Floor, 550 N Broadway, Baltimore, MD 21205-2010 (e-mail: pstafalin@jhmi.edu).

REFERENCES

1. Klein R, Klein BE, Linton KL. Prevalence of age-related maculopathy: the Beaver Dam Eye Study. *Ophthalmology*. 1992;99:933-943.
2. Vingerling JR, Dielemans I, Hofman A, et al. The prevalence of age-related maculopathy in the Rotterdam Study. *Ophthalmology*. 1995;102:205-210.
3. Bressler NM, Bressler SB, Fine SL. Age-related macular degeneration. *Surv Ophthalmol*. 1988;32:375-413.
4. Green WR, Enger C. Age-related macular degeneration histopathologic studies: the 1992 Lorenz E. Zimmerman Lecture. *Ophthalmology*. 1993;100:1519-1535.
5. Macular Photocoagulation Study Group. Laser photocoagulation of subfoveal neovascular lesions in age-related macular degeneration: results of a randomized clinical trial. *Arch Ophthalmol*. 1991;109:1220-1231.
6. Macular Photocoagulation Study Group. Argon laser photocoagulation for neovascular maculopathy: five-year results from randomized clinical trials. *Arch Ophthalmol*. 1991;109:1109-1114.
7. Macular Photocoagulation Study Group. Laser photocoagulation for juxtafoveal choroidal neovascularization: five-year results from randomized clinical trials. *Arch Ophthalmol*. 1994;112:500-509.
8. Macular Photocoagulation Study Group. Laser photocoagulation of subfoveal neovascular lesions of age-related macular degeneration: updated findings from two clinical trials. *Arch Ophthalmol*. 1993;111:1200-1209.
9. Macular Photocoagulation Study Group. Laser photocoagulation of subfoveal recurrent neovascular lesions in age-related macular degeneration: results of a randomized clinical trial. *Arch Ophthalmol*. 1991;109:1232-1241.
10. Macular Photocoagulation Study Group. Visual outcome after laser photocoagulation for subfoveal choroidal neovascularization secondary to age-related macular degeneration: the influence of initial lesion size and initial visual acuity. *Arch Ophthalmol*. 1994;112:480-488.
11. Weishaupt K, Gomer C, Dougherty T. Identification of singlet oxygen as the cytotoxic agent in photo-inactivation of murine tumor. *Cancer Res*. 1976;36:2326-2329.
12. Castellani A, Pace G, Conciolli M. Photodynamic effect of hematoporphyrin on blood microcirculation. *J Pathol Bacteriol*. 1963;86:99-102.
13. Schmidt-Erfurth U, Hasan T, Gragoudas E, Michaud N, Flotte TJ, Birngruber R. Vascular targeting in photodynamic occlusion of subretinal vessels. *Ophthalmology*. 1994;101:1953-1961.
14. Allison BA, Waterfield E, Richter AM, Levy JG. The effects of plasma lipoproteins on in vitro tumor cell killing and in vivo tumor photosensitization with benzoporphyrin derivative. *Photochem Photobiol*. 1991;54:709-715.
15. Schmidt-Erfurth U, Hasan T, Schomacker K, Flotte T, Birngruber R. In vivo uptake of liposomal benzoporphyrin derivative and photothrombosis in experimental corneal neovascularization. *Lasers Surg Med*. 1995;17:178-188.
16. Schmidt-Erfurth U, Banman W, Gragoudas ES, et al. Photodynamic therapy of experimental choroidal melanoma. *Ophthalmology*. 1994;101:89-99.
17. Young LH, Howard MA, Hu LK, Kim RY, Gragoudas ES. Photodynamic therapy of pigmented choroidal melanomas using a liposomal preparation of benzoporphyrin derivative. *Arch Ophthalmol*. 1996;114:186-192.
18. Miller JW, Walsh AW, Kramer M, et al. Photodynamic therapy of experimental choroidal neovascularization using lipoprotein-delivered benzoporphyrin. *Arch Ophthalmol*. 1995;113:810-818.
19. Kramer M, Miller JW, Michaud N, et al. Liposomal benzoporphyrin derivative verteporfin photodynamic therapy: selective treatment of choroidal neovascularization in monkeys. *Ophthalmology*. 1996;103:427-438.
20. Husain D, Miller JW, Michaud N, Connolly E, Flotte TJ, Gragoudas ES. Intravenous infusion of liposomal benzoporphyrin derivative for photodynamic therapy of experimental choroidal neovascularization. *Arch Ophthalmol*. 1996;114:978-985.
21. Miller JW, Schmidt-Erfurth U, Sickenberg M, et al. Photodynamic therapy with verteporfin for choroidal neovascularization caused by age-related macular degeneration: results of a single treatment in a phase 1 and 2 study. *Arch Ophthalmol*. 1999;117:1161-1173.
22. Schmidt-Erfurth U, Miller JW, Sickenberg M, et al. Photodynamic therapy with verteporfin for choroidal neovascularization caused by age-related macular degeneration: results of retreatments in a phase 1 and 2 study. *Arch Ophthalmol*. 1999;117:1177-1187.
23. Sickenberg M, Schmidt-Erfurth U, Miller JW, et al. Preliminary results of photodynamic therapy for choroidal neovascularization in pathologic myopia, ocular histoplasmosis syndrome and idiopathic causes within a phase I/II study. *Invest Ophthalmol Vis Sci*. 1997;38:S92.
24. Submacular Surgery Trials (SST) Research Group. *SST Manual of Procedures*. Springfield, Va: National Technical Information Services; 1997. Accession No. PB98 166648.
25. Macular Photocoagulation Study Group. Subfoveal neovascular lesions in age-related macular degeneration: guidelines for evaluation and treatment in the Macular Photocoagulation Study. *Arch Ophthalmol*. 1991;109:1242-1257.
26. Pelli DG, Robson JG, Wilkins AJ. The design of a new letter chart for measuring contrast sensitivity. *Clin Vis Sci*. 1988;2:187-199.
27. Lee ET. Nonparametric methods of estimating survival functions. In: *Statistical Methods for Survival Data Analysis*. 2nd ed. New York, NY: John Wiley & Sons Inc; 1992:66-78.
28. Chow SC, Lui JP. Analysis of continuous data. In: *Design and Analysis of Clinical Trials: Concepts and Methodologies*. New York, NY: John Wiley & Sons Inc; 1998:277-280, 286-290.
29. Chow SC, Lui JP. Analysis of categorical data. In: *Design and Analysis of Clinical Trials: Concepts and Methodologies*. New York, NY: John Wiley & Sons Inc; 1998:331-333.
30. Hosmer DW, Lemeshow S. Interpretation of the coefficients of the logistic regression model. In: *Applied Logistic Regression*. New York, NY: John Wiley & Sons Inc; 1989:63-68.
31. Mones J, for the VIP Study Group. Photodynamic therapy (PDT) with verteporfin of the subfoveal choroidal neovascularization in age-related macular degeneration: study design and baseline characteristics in the VIP randomized clinical trial. *Invest Ophthalmol Vis Sci*. 1999;40:S321.

7. Smith SD, Katz J, Quigley HA. Analysis of progressive change in automated visual fields in glaucoma. *Invest Ophthalmol Vis Sci.* 1996;37:1419-1428.
8. Mikelberg FS, Schulzer M, Drance SM, Lau W. The rate of progression of scotomas in glaucoma. *Am J Ophthalmol.* 1986;101:1-6.
9. O'Brien C, Schwartz B, Takamoto T, Wu DC. Intraocular pressure and the rate of visual field loss in chronic open-angle glaucoma. *Am J Ophthalmol.* 1991;111:491-500.
10. Smith RJH. The enigma of primary open-angle glaucoma. *Trans Ophthalmol Soc U.K.* 1986;105:618-633.
11. Flammer J, Drance SM, Augustiny L, Funkhouser A. Quantification of glaucomatous visual field defects with automated perimetry. *Invest Ophthalmol Vis Sci.* 1985;26:176-181.
12. Greve EL, Bakker D. Some possibilities of the Peritest automatic and semi-automatic perimeter. In: Greve EL, Heijl A, eds. *Fifth International Visual Field Symposium.* The Hague, the Netherlands: Dr W Junk Publishers; 1983:313-321.
13. Holmin C, Krakau CET. Visual field decay in normal subjects and in cases of chronic glaucoma. *Albrecht Von Graefes Arch Klin Exp Ophthalmol.* 1980;213:291-298.
14. Gramer E, Althaus G. Quantifizierung und Progredienz des Gesichtsfeldschadens bei Glaukom ohne Hochdruck, Glaucoma Simplex und Pigmentglaukom. *Klin Monatsbl Augenheilkd.* 1987;191:184-198.
15. Jay JL, Murdoch JR. The rate of visual field loss in untreated primary open-angle glaucoma. *Br J Ophthalmol.* 1993;77:176-178.
16. Quigley HA, Tielsch JM, Katz J, Sommer A. Rate of progression in open-angle glaucoma estimated from cross-sectional prevalence of visual field damage. *Am J Ophthalmol.* 1996;122:355-363.
17. Holmin C, Krakau CET. Regression analysis of the central visual field in chronic glaucoma cases: a follow-up study using automatic perimetry. *Acta Ophthalmol (Copenh).* 1982;60:267-274.
18. Greve EL, Dannheim F, Bakker D. The Peritest, a new automatic and semi-automatic perimeter. *Int Ophthalmol.* 1982;5:201-213.
19. Hotchkiss ML, Robin AL, Quigley HA, Pollack IP. A comparison of Peritest automated perimetry and Goldmann perimetry. *Arch Ophthalmol.* 1985;103:397-403.
20. Katz J, Gilbert D, Quigley HA, Sommer AS. Estimating progression of visual field loss in glaucoma. *Ophthalmology.* 1997;104:1017-1025.
21. Anderton SA, Coakes RC, Poinoswamy S, Clarke P, Hitchings RA. The nature of visual loss in low tension glaucoma. *Doc Ophthalmol.* 1985;42:383-386.
22. Hart WM, Becker B. The onset and evolution of glaucomatous visual field defects. *Ophthalmology.* 1982;89:268-279.
23. Drance SM. Disc hemorrhages in the glaucomas. *Surv Ophthalmol.* 1989;33:331-337.
24. Bengtsson B, Holmin C, Krakau CET. Disc haemorrhage and glaucoma. *Acta Ophthalmol (Copenh).* 1981;59:1-14.
25. Diehl DLC, Quigley HA, Miller NR, et al. Prevalence and significance of optic disc hemorrhage in a longitudinal study of glaucoma. *Arch Ophthalmol.* 1990;108:545-550.
26. Siegner SW, Netland PA. Optic disc hemorrhages and progression of glaucoma. *Ophthalmology.* 1996;103:1014-1024.
27. Heijl A, Bengtsson B. The effect of perimetric experience in patients with glaucoma. *Arch Ophthalmol.* 1996;114:19-22.
28. Werner EB, Adelson A, Krupin T. Effect of patient experience on the results of automated perimetry in clinically stable glaucoma patients. *Ophthalmology.* 1988;95:764-767.
29. Mikelberg FS, Drance SM. The mode of progression of visual field defects in glaucoma. *Am J Ophthalmol.* 1984;98:443-445.

Correction

Omission in Financial Disclosures. In the Clinical Sciences articles by Miller et al titled "Photodynamic Therapy With Verteporfin for Choroidal Neovascularization Caused by Age-related Macular Degeneration: Results of a Single Treatment in a Phase 1 and 2 Study," published in the September issue of the ARCHIVES (1999;117:1161-1173); by Schmidt-Erfurth et al titled "Photodynamic Therapy With Verteporfin for Choroidal Neovascularization Caused by Age-related Macular Degeneration: Results of Retreatments in a Phase 1 and 2 Study," published in the September issue of the ARCHIVES (1999;117:1177-1187); and by the Treatment of Age-related Macular Degeneration With Photodynamic Therapy (TAP) Study Group titled "Photodynamic Therapy of Subfoveal Choroidal Neovascularization in Age-related Macular Degeneration With Verteporfin: One-Year Results of 2 Randomized Clinical Trials—TAP Report 1," published in the October issue of the ARCHIVES (1999;117:1329-1345), journal omissions of financial disclosure, properly reported at the time of manuscript submission, occurred in the acknowledgment sections on pages 1172, 1187, and 1344, respectively. The following statement should have appeared in all 3 articles: "Drs Sickenberg and Bressler are consultants for CIBA Vision Inc, Duluth, Ga, and QLT Phototherapeutics Inc, Vancouver, British, Columbia." The journal regrets the errors.