

Expert Opinion

1. Introduction
2. Background
3. Conclusion
4. Expert opinion

VEGF Trap-Eye for the treatment of neovascular age-related macular degeneration

James A Dixon, Scott CN Oliver[†], Jeffrey L Olson & Naresh Mandava
*University of Colorado Denver, Rocky Mountain Lions Eye Institute, Department of Ophthalmology,
 1675 North Aurora Court, PO Box 6510, Mail Stop F-731, Aurora, CO 80045-2500, USA*

Background: Age-related macular degeneration (AMD) affects > 14 million individuals worldwide. Although 90% of patients with AMD have the dry form, neovascular AMD accounts for the vast majority of patients who develop legal blindness. Until recently, few treatment options existed for treatment of neovascular AMD. The advent of anti-VEGF therapy has significantly improved the safe and effective treatment of neovascular AMD. In addition to two anti-VEGF drugs currently in widespread use, ranibizumab and bevacizumab, a number of medications that interrupt angiogenesis are currently under investigation. One promising new drug is aflibercept (VEGF Trap-Eye), a fusion protein that blocks all isoforms of VEGF-A and placental growth factors-1 and -2. **Objective:** To review the current literature and clinical trial data regarding VEGF Trap-Eye for the treatment of neovascular AMD. **Methods:** Literature review. **Results/conclusion:** VEGF Trap-Eye is a novel anti-VEGF therapy, with Phase I and II trial data indicating safety, tolerability and efficacy for the treatment of neovascular AMD. Two Phase III clinical trials (VIEW-1 and VIEW-2) comparing VEGF Trap-Eye to ranibizumab are currently continuing and will provide vital insight into the clinical applicability of this drug.

Keywords: aflibercept, AMD, angiogenesis, neovascularization, VEGF, VEGF inhibition, VEGF Trap

Expert Opin. Investig. Drugs (2009) 18(10):1573-1580

1. Introduction

Age-related macular degeneration (AMD) affects > 1.75 million individuals in the US and it is estimated that by 2020 this number will increase to almost 3 million [1]. Worldwide, AMD is estimated to affect 14 million people [2]. While the vast majority of patients suffering from AMD have the dry form, ~ 80 – 90% of patients who develop severe vision loss have the neovascular or 'wet' form of the disease [3]. Until recently, healthcare professionals had few options when it came to treating neovascular AMD. For many years, subfoveal choroidal neovascularization (CNV) was treated with argon laser therapy according to guidelines from the Macular Photocoagulation Study [4-12]. This treatment, in the setting of subfoveal disease, was unsatisfactory for a number of reasons, including the limited benefits in visual stabilization and the high risk of inducing central vision deficits [13]. Treatment outcomes improved with the introduction of photodynamic therapy (PDT) which utilized a photosensitizing dye (verteporfin) to selectively target CNV. While more efficacious than previous treatments, patients receiving PDT failed to recover vision and continued to experience a decline in visual acuity [14] and the treatment was of questionable cost effectiveness [15].

The more recent development of agents that inhibit VEGF has largely supplanted these previous treatments. The pathogenesis of CNV in the setting of

informa
healthcare

AMD is complex; however, there is overwhelming evidence that VEGF is a predominant mediator in its genesis. VEGF receptors are expressed by a number of important cell types in the eye, including vascular endothelial cells, choroidal fibroblasts, retinal pigment epithelial cells and inflammatory cells attracted by hypoxia [16-19]. Higher levels of VEGF expression have been demonstrated in animal models [20,21] and human studies of eyes with AMD [17,22-24] and antagonism of VEGF in both settings have definitively demonstrated inhibition of neovascularization and vascular permeability. VEGF-A is the predominant member of the VEGF family targeted by drugs currently in widespread use; however, the group is also comprised of VEGF-B, VEGF-C, VEGF-D and placental growth factors-1 and -2.

Systemic administration of bevacizumab is effective against neovascular AMD; however, systemic complications limit its use [25]. Accordingly, all anti-VEGF agents for neovascular AMD are administered only by intravitreal injection. The two largest studies examining anti-VEGF therapy, the MARINA [26] and the ANCHOR [27,28] trials, were randomized, controlled, double-masked Phase III clinical trials that together evaluated monthly ranibizumab for the treatment of all types of neovascular AMD. In both trials, 94% of patients with neovascular AMD lost fewer than 15 letters of visual acuity at 12 and 24 months when treated with ranibizumab. Surprisingly, as many as 40% of patients in the two trials improved by > 15 letters from baseline at 2 years. Ranibizumab received the FDA approval for all types of neovascular AMD in 2006. Based on the results of these two landmark studies, anti-VEGF therapies for neovascular AMD have largely replaced previous treatment modalities.

2. Background

2.1 Overview of the market (unmet needs, competitor compounds/in clinical development)

By far the most commonly used anti-VEGF drugs currently in use for neovascular AMD are ranibizumab and bevacizumab. Pegaptanib was the first anti-VEGF drug approved by the FDA for the treatment of AMD; however, it proved less efficacious than current treatments [13] (possibly due to its selective binding of VEGF-165) and is no longer widely used in most countries. Ranibizumab is the only drug in widespread use currently approved by the FDA for treatment of neovascular AMD and is by far the most extensively studied [26,27,29,30]. It is a recombinant monoclonal antibody fragment with a high binding affinity for all isotypes of VEGF-A. Bevacizumab, currently being used off-label for the treatment of AMD in the US, is a humanized whole antibody to VEGF-A used in oncology regimens that also binds all isotypes of VEGF-A. Although ranibizumab has been shown to have a higher affinity for VEGF-A, it is not clear if ranibizumab has superior efficacy to bevacizumab. Retrospective and small randomized studies have suggested similar efficacy profiles [31,32]. The Comparisons of Age-Related

Macular Degeneration Treatment Trial (CATT) is a 2-year, multi-centered, randomized clinical trial comparing ranibizumab and bevacizumab for neovascular AMD. Enrollment began in February 2008. Despite the off-label status of bevacizumab, it continues to be a popular treatment choice in the US because of the significantly reduced price of treatment (\$ 50 – 100 for bevacizumab versus \$ 2000 for ranibizumab (2008 pricing)).

As previously mentioned, the MARINA [26] and the ANCHOR [27,28] trials examined the efficacy of ranibizumab when administered monthly. The time and financial burden of monthly injections has led to the initiation of studies to examine the efficacy of alternative dosing schedules. In the PIER study [30], patients initially received monthly injections of ranibizumab for 3 months followed by quarterly injections. Although patient visual acuities actually improved at 3 months, during the quarterly dosing segment visual acuity returned to baseline. The PrONTO study [29] looked at as needed (p.r.n.) dosing of ranibizumab after three consecutive monthly doses. The need for further injections was made on the basis of recurrent CNV as evidenced by worsening vision, retinal thickening on ocular coherence tomography (OCT) or abnormalities on fluorescein angiogram (FA). At 2 years of follow up, 78% of patients had maintained vision and vision had improved by > 3 lines in 43% of patients with an average of five injections a year. These later studies seem to indicate that quarterly dosing is associated with poorer outcomes but it may be possible to extend the time between injections if the patient is frequently monitored. However, even with the p.r.n. dosing utilized in the PrONTO study, patients are still required to make monthly visits to the office with frequent and expensive testing.

The development of new drugs for neovascular AMD has thus focused on both improving efficacy and extending duration of action. Most new compounds in development are targeted toward inhibition of various steps in the VEGF signaling pathway. There are a number of drugs in development that inhibit the downstream tyrosine kinase cascade activated by the binding of VEGF with its receptor (VEGFR). Vatalanib is an oral formulation that binds to all three VEGFRs and has recently completed Phase I/II study as adjuvant to PDT and ranibizumab [33]. Topical tyrosine kinase inhibitors currently undergoing Phase II clinical studies include pazopanib [34] and TG100801 [35]. Another approach utilizes siRNA to silence genes which express proteins involved in angiogenesis. Bevasiranib, an siRNA that targets VEGF-A mRNA, showed encouraging Phase I and II data, but the Phase III trial was halted in March 2009 for projected failure to meet the primary end point [36]. An extra antiangiogenic target being developed is pigment epithelium-derived factor (PEDF), a potent inhibitor of new vessel growth. AdGVPEDF.11D uses an adenovector to deliver the PEDF gene to target cells, resulting in the local production of PEDF in the treated eye. AdGVPEDF.11D has recently completed Phase I clinical trials [37]. Another

recently discovered alternative pathway for decreasing angiogenesis involves inhibition of nicotinic acetylcholine receptors. ATG3 (mecamylamine), a topical formulation that inhibits the nicotinic acetylcholine receptors, has shown promising results in animal and Phase I trials and is currently undergoing a Phase II study [25].

2.2 Introduction to compound

VEGF Trap-Eye is a novel anti-VEGF drug currently in commercial development for the treatment of neovascular AMD by Regeneron Pharmaceuticals, Inc. (Tarrytown, NY, USA) in the US and in collaboration with Bayer HealthCare (Leverkusen, Germany) in global markets. Structurally, VEGF Trap-Eye is a fusion protein of key binding domains of human VEGFR-1 and -2 combined with a human IgG Fc fragment (Figure 1). Functionally, VEGF Trap-Eye acts as a receptor decoy with high affinity for all VEGF isoforms, binding more tightly than their native receptors. Unlike anti-VEGF drugs currently in use, VEGF Trap-Eye is designed to inhibit placental growth factors-1 and -2 in addition to all isoforms of VEGF-A.

2.3 Chemistry

VEGF Trap-Eye and aflibercept (the oncology product) have the same molecular structure, but there are substantial differences between the preparation of the purified drug product and their formulations. Both aflibercept and VEGF Trap-Eye are manufactured in bioreactors from industry standard Chinese hamster ovary cells that overexpress the fusion protein. However, VEGF Trap-Eye undergoes further purification steps during manufacturing to minimize risk of irritation to the eye. VEGF Trap-Eye is also formulated with different buffers and at different concentrations (for buffers in common) suitable for the comfortable, non-irritating, direct injection into the eye.

2.4 Pharmacodynamics

The aflibercept dose that is administered in oncology settings is either 4 mg/kg every 2 weeks or 6 mg/kg every 3 weeks, which corresponds to 2 mg/(kg week) with either schedule. The highest intravitreal dose being used in pivotal trials for VEGF Trap-Eye is 2 mg/month, which corresponds to at least a 280-fold lower potential systemic exposure than in the oncology setting. Early trials with aflibercept administered intravenously for AMD indicated that doses of 0.3 mg/kg (21 mg total) were inadequate to fully capture systemic VEGF. Thus, the low intravitreal dose of 2 mg allows for extended blocking of VEGF in the eye, but would be predicted to give negligible systemic activity as it will be rapidly bound to VEGF and inactivated.

2.5 Pharmacokinetics and metabolism

Aflibercept is cleared from circulation through two pathways: by binding to VEGF to form an inactive VEGF–aflibercept complex and by Fc-receptor or pinocytotic mediated pathways

that end in proteolysis, which are presumed to be similar to pathways that metabolize antibodies. At very high doses, free aflibercept has a terminal half-life of ~ 17 days in the circulation. The half-life of human intravitreal doses is unknown. Intravitreal primate doses of ranibizumab have a half-life of ~ 3 days [38]. At low blood levels, clearance of free aflibercept is rapid as a result of binding to VEGF with picomolar affinity [39].

2.6 Clinical efficacy

2.6.1 Phase I

A Phase I, randomized, double-blind, placebo-controlled trial of intravenous aflibercept (oncology formulation) was completed in 25 patients with AMD. Although systemic aflibercept did demonstrate a dose-dependent decrease in retinal thickness, the study was halted due to concerns of dose-dependent toxicity when one patient developed hypertension and another proteinuria [40].

The safety, tolerability and biological activity of intravitreal VEGF Trap-Eye in treatment of neovascular AMD was evaluated in the two-part Clinical Evaluation of Anti-angiogenesis in the Retina-1 (CLEAR-IT-1) study [41]. The first part was a sequential cohort dose-escalation study in which 21 patients were monitored for safety, changes in foveal thickness on OCT, best corrected visual acuity (BCVA) and lesion size on FA for 6 weeks. No adverse systemic or ocular events were noted and visual acuity remained stable or improved ≥ 3 lines in 95% of patients with a mean increase in BCVA of 4.6 letters at 6 weeks [42]. Patients showed substantially decreased foveal thickness [41].

In the second part, 30 patients received a single intravitreal injection of either 0.5 or 4 mg of VEGF Trap-Eye and were followed for 8 weeks. All patients were evaluated for their rates of retreatment, changes in BCVA, foveal thickness as well as change in total lesion size and area of CNV. Patients had ETDRS (Early Treatment of Diabetic Retinopathy Study) BCVA ranging from 20/40 to 20/320 with any angiographic subtype of CNV at baseline. No serious adverse events or ocular inflammation was identified during the study. At 8 weeks, the mean decrease in retinal thickness in the low dose group was 63.7 μm compared to 175 μm for the high dose group. Of the first 24 patients to complete the study, 11 out of 12 patients in the 0.5 mg dose group required retreatment in a median of 64 days, compared with 4 out of 12 in the 4 mg dose group who required retreatment in a median of 69 days [43].

VEGF Trap-Eye has also undergone a small open-label safety study for the treatment of diabetic macular edema (DME) [44]. The drug was administered as a single 4 mg intravitreal injection to five patients with longstanding diabetes and several previous treatments for DME. The single injection resulted in a median decrease of central macular thickness measured by OCT of 79 μm . BCVA increased by 9 letters at 4 weeks and regressed to a 3 letter improvement at 6 weeks.

VEGF Trap-Eye

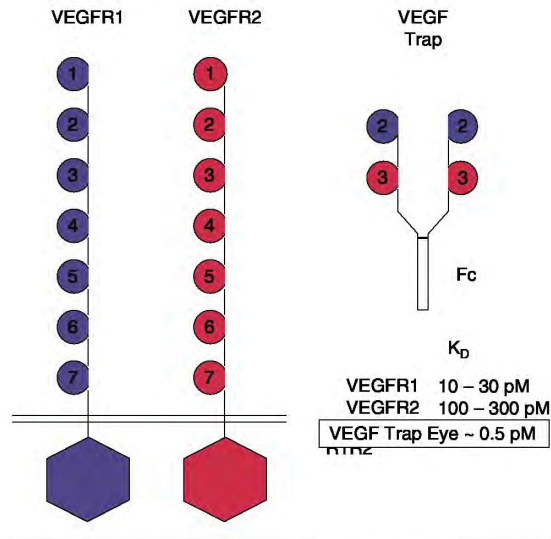


Figure 1. Schematic diagram of VEGF Trap-Eye, a fusion protein of binding domains of VEGF receptors-1 and -2 attached to the Fc fragment of human IgG.

2.6.2 Phase II

CLEAR-IT-2 trial [45] was a prospective, randomized, multi-center, controlled dose- and interval-ranging Phase II trial in which 157 patients were randomized to five dose groups and treated with VEGF Trap-Eye in one eye. The mean age of the group was 78.2 years and all angiographic subtypes of CNV were represented at baseline. The mean ETDRS BCVA in letters at baseline was 56. Two groups received monthly doses of either 0.5 or 2.0 mg for 12 weeks (at weeks 0, 4, 8 and 12) and three groups received quarterly doses of either 0.5, 2.0 or 4.0 mg for 12 weeks (at weeks 0 and 12). Following this fixed dosing period, patients were treated with the same dose of VEGF Trap-Eye on a p.r.n. basis. Criteria for re-dosing included an increase in central retinal thickness of $\geq 100 \mu\text{m}$ by OCT, a loss of ≥ 5 ETDRS letters in conjunction with recurrent fluid by OCT, persistent fluid as indicated by OCT, new onset classic neovascularization, new or persistent leak on FA or new macular subretinal hemorrhage.

Patients initially treated with 2.0 or 0.5 mg of VEGF Trap-Eye monthly achieved mean improvements of 9.0 ($p < 0.0001$) and 5.4 ($p < 0.085$) ETDRS letters with 29 and 19% gaining, respectively, ≥ 15 ETDRS letters at 52 weeks. During the p.r.n. dosing period, patients initially dosed on a 2.0 mg monthly schedule received an average of 1.6 more injections and those initially dosed on a 0.5 mg monthly schedule received an average of 2.5 injections. The median time to first reinjection in all groups was 110 days and 19% of patients required no more injections at week 52. Patients in these two monthly dosing groups also displayed mean decreases in

retinal thickness versus baseline of $143 \mu\text{m}$ ($p < 0.0001$) in the 2.0 mg group and $125 \mu\text{m}$ ($p < 0.0001$) in the 0.5 mg group at 52 weeks as measured by OCT [45].

Patients in the three quarterly dosing groups also showed mean improvements in BCVA and retinal thickness; however, they were generally not as profound as the monthly injection group [45].

2.6.3 Phase III

A two part Phase III trial of VEGF Trap-Eye was initiated in August of 2007. The first part, VIEW 1 (VEGF Trap: Investigation of Efficacy and safety in Wet age-related macular degeneration) [46] will enroll ~ 1200 patients with neovascular AMD in the US and Canada. This non-inferiority study will evaluate the safety and efficacy of intravitreal VEGF Trap-Eye at doses of 0.5 and 2.0 mg administered at 4-week dosing intervals and 2.0 mg at an 8 week dosing interval (following three monthly doses), compared with 0.5 mg of ranibizumab administered every 4 weeks. After the first year of the study, patients will enter a second year of p.r.n. dosing evaluation. The VIEW 2 [47] study has a similar study design and is currently enrolling patients in Europe, Asia Pacific, Japan and Latin America. In both trials, the primary outcome will be the proportion of patients who maintain vision at week 52 (defined as a loss of < 15 ETDRS letters).

2.7 Safety and tolerability

Based on Phase II study data, VEGF Trap-Eye seems to be generally well tolerated with no serious drug-related adverse events. In the 157 patients enrolled in CLEAR-IT 2 trial, there was one reported case of culture-negative endophthalmitis not deemed to be related to the study drug. There were also two deaths (one from pre-existing pulmonary hypertension and one from pancreatic carcinoma) and one arterial thromboembolic event (in a patient with a history of previous stroke) that occurred during the study period, but no serious systemic adverse events were deemed related to VEGF Trap-Eye administration. The most common adverse events reported in the study included conjunctival hemorrhage (38.2%), transient increased intraocular pressure (18.5%), refraction disorder (15.9%), retinal hemorrhage (14.6%), subjective visual acuity loss (13.4%), vitreous detachment (11.5%) and eye pain (9.6%) [45].

3. Conclusion

Anti-VEGF therapy has vastly improved the treatment of neovascular AMD in terms of both safety and efficacy. The ANCHOR [26] and MARINA [27,28] trials have established ranibizumab as an effective therapy when dosed monthly. It has been shown to stabilize vision in 94% of patients and in almost 40% of patients vision will actually improve by 3 or more lines. However, the monthly dosing schedules used in these trials present a financial and time burden to patients and healthcare practitioners. The more recent PIER [30] and

PrONTO [29] trials have shown that ranibizumab is less effective when dosed quarterly, but it may be possible to extend the time between injections when patients are followed closely with frequent examinations and ancillary testing. The most effective dosing regimen and monitoring program for anti-VEGF therapy has yet to be firmly established but new treatments are aimed at extending and improving on the efficacy of ranibizumab. VEGF Trap-Eye differs from established anti-VEGF therapies in its higher binding affinity for VEGF-A and its blockage of placental growth factors-1 and -2. Phase I data demonstrated acceptable safety and tolerability of VEGF Trap-Eye in the treatment of neovascular AMD. In Phase II study data, patients dosed in a similar fashion to the PrONTO trial demonstrated stabilization of their vision that was similar to previous studies of ranibizumab at 1 year. Of the greatest interest, patients dosed at 2.0 mg during the initial monthly dosing period required 1.6 injections on average during the p.r.n. dosing phase. While this number is difficult to compare directly to the number of injections required during the p.r.n. phase of the PrONTO ranibizumab study, it is promising. A direct comparison of the efficacy of VEGF Trap-Eye versus ranibizumab will be possible with the completion of two Phase III trials, the VIEW-1 and -2 studies.

4. Expert opinion

The advent of anti-VEGF therapy for treatment of neovascular AMD has revolutionized therapy for a common blinding disease. Before the development of pegaptanib, ranibizumab and bevacizumab, the diagnosis of neovascular AMD portended a prognosis of nearly universal decline in vision, and frequently loss of useful vision in the affected eye.

Current treatment regimens with either ranibizumab or bevacizumab now afford stabilization of vision in > 90% of patients, with significant vision gain in one-third of all patients treated. There have been no significant, proven adverse systemic effects with the intraocular use of either drug. However, limitations of current therapy include the need for frequent intraocular injections, as often as monthly, without a defined stopping point. Each injection subjects patients to risks of cataract, intraocular inflammation, retinal detachment and endophthalmitis. A significant time and financial burden falls on patients during their treatment course.

Desirable attributes for emerging therapies for neovascular AMD include higher visual improvement rates and decreased dosing intervals. For other indications, time-release delivery methods have met with some success, including the following agents: intraocular steroids, including polymeric fluocinolone and dexamethasone, lasting 3 years and 6 months, respectively [48-50], and for a single biologically active cytokine, ciliary neurotrophic factor, which is released for a period greater than 1 year by encapsulated, bioengineered, implanted cells [51]. While efforts are underway to develop

encapsulated cell technology for sustained-release anti-VEGF therapy, no investigational drugs or devices have progressed yet to clinical trial enrollment.

VEGF Trap-Eye represents the most promising anti-VEGF investigational drug that is currently in Phase III trial. VEGF Trap-Eye, a decoy VEGF receptor protein, binds all isoforms of free VEGF with high affinity, in addition to placental growth factor. In contrast to current anti-VEGF antibodies, which are rapidly cleared, the VEGF-VEGF Trap complex is relatively inert, and is degraded more slowly. Due to its high binding affinity and the ability to safely inject high doses into the eye, VEGF Trap-Eye may have longer duration of effect in the eye. Two Phase III studies in wet AMD, VIEW 1 and VIEW 2, are currently under way and seek to compare monthly ranibizumab to monthly or bimonthly VEGF Trap-Eye.

Data from the Phase II study with VEGF Trap-Eye were positive and the results from the non-inferiority Phase III trials will establish its efficacy versus ranibizumab. Its adoption into clinical practice will depend on efficacy at 4 and 8 week intervals. If effective at 4 week intervals only, VEGF Trap-Eye will be adopted into clinical practice if it offers a competitive price advantage over ranibizumab. If effective at 8 week intervals, VEGF Trap-Eye offers the opportunity to significantly reduce treatment burden on patients and physicians, and would probably find wide acceptance. The second p.r.n. dosing stage of the Phase III trial will also provide insight into whether VEGF Trap-Eye offers longer duration of treatment effectiveness than ranibizumab.

Data from the VIEW-1 and VIEW-2 trials will need to be interpreted by clinicians in the context of emerging adjuvant therapies that may extend the time between anti-VEGF therapy injections. Many clinicians now treat patients with anti-VEGF therapies in combination with verteporfin PDT. Randomized, open-label studies and one large retrospective case series database seem to indicate lower retreatment rates and improved visual outcomes when compared with monotherapy [52-55]. As a result, at least two prospective, randomized trials are currently underway to further examine combination verteporfin PDT and anti-VEGF treatments [56,57]. An extra combination treatment currently under study is the use of epiretinal brachytherapy with Strontium-90 combined with bevacizumab. A recently published small pilot study showed good safety and efficacy with a single application of epiretinal radiation and two bevacizumab injections after 12 months [58]. A larger, multi-center Phase III trial is underway [59].

Anti-VEGF agents are currently only approved for the treatment of exudative AMD. The multifactorial nature of DME, including non-VEGF mediated causes such as pericyte and endothelial cell damage and tractional mechanisms, has made treatment of this condition difficult using current modalities. Clinical studies are underway with anti-VEGF agents in DME and retinal vein occlusion. VEGF Trap-Eye is under Phase II investigation in DME and Phase III investigation in central retinal vein occlusion. The

FDA approval of VEGF Trap-Eye for these indications would significantly add to the ophthalmologists' armamentarium for treatment of retinal vascular disease.

Eventually, injectable agents targeting the VEGF pathway may be supplanted by implantable devices that deliver polymer-bound drug or manufacture the protein *in vivo*. Further therapies for neovascular AMD such as targeted radiation may confer extra treatment benefit. In the meantime, VEGF Trap-Eye is a

promising investigational drug that, if approved, will improve ophthalmologists' ability to treat neovascular AMD.

Declaration of interest

SCN Oliver is a clinical investigator for Genentech and Alcon. JL Olson and N Mandava are clinical investigators for Genentech, Regeneron and Alcon.

Bibliography

Papers of special note have been highlighted as either of interest (*) or of considerable interest (**)

1. Friedman DS, O'Colmain BJ, Munoz B, et al. Prevalence of age-related macular degeneration in the United States. *Arch Ophthalmol* 2004;122(4):564-72
2. Magnitude and causes of visual impairment [fact sheet no. 282]. Available from: <http://www.who.int/mediacentre/factsheets/fs282/en/> [Accessed 1 Sep 2008]
3. Congdon N, O'Colmain B, Klaver CC, et al. Causes and prevalence of visual impairment among adults in the United States. *Arch Ophthalmol* 2004;122(4):477-85
4. Argon laser photocoagulation for neovascular maculopathy. Three-year results from randomized clinical trials. Macular Photocoagulation Study Group. *Arch Ophthalmol* 1986;104(5):694-701
- **A seminal paper in its era, regarding the use of laser photocoagulation for neovascular AMD.**
5. Krypton laser photocoagulation for neovascular lesions of age-related macular degeneration. Results of a randomized clinical trial. Macular Photocoagulation Study Group. *Arch Ophthalmol* 1990;108(6):816-24
6. Subfoveal neovascular lesions in age-related macular degeneration. Guidelines for evaluation and treatment in the macular photocoagulation study. Macular Photocoagulation Study Group. *Arch Ophthalmol* 1991;109(9):1242-57
7. Laser photocoagulation of subfoveal recurrent neovascular lesions in age-related macular degeneration. Results of a randomized clinical trial. Macular Photocoagulation Study Group. *Arch Ophthalmol* 1991;109(9):1232-41
8. Laser photocoagulation of subfoveal neovascular lesions in age-related macular degeneration. Results of a randomized clinical trial. Macular Photocoagulation Study Group. *Arch Ophthalmol* 1991;109(9):1220-31
9. Laser photocoagulation of subfoveal neovascular lesions of age-related macular degeneration. Updated findings from two clinical trials. Macular Photocoagulation Study Group. *Arch Ophthalmol* 1993;111(9):1200-9
10. Laser photocoagulation for juxtafoveal choroidal neovascularization. Five-year results from randomized clinical trials. Macular Photocoagulation Study Group. *Arch Ophthalmol* 1994;112(4):500-9
11. Occult choroidal neovascularization. Influence on visual outcome in patients with age-related macular degeneration. Macular Photocoagulation Study Group. *Arch Ophthalmol* 1996;114(4):400-12
12. Fine SL, Hawkins B, Maguire M. Macular photocoagulation study. *Arch Ophthalmol* 1984;102(11):1583
13. D'Amico DJ, Masonson HN, Patel M, et al. Pegaptanib sodium for neovascular age-related macular degeneration: two-year safety results of the two prospective, multicenter, controlled clinical trials. *Ophthalmology* 2006;113(6):992-1001, e1006
- **The first anti-VEGF agent proven to be effective for neovascular AMD was pegaptanib.**
14. Kaiser PK. Verteporfin therapy of subfoveal choroidal neovascularization in age-related macular degeneration: 5-year results of two randomized clinical trials with an open-label extension: TAP report no. 8. *Graefes Arch Clin Exp Ophthalmol* 2006;244(9):1132-42
15. Wormald R, Evans J, Smeeth L, Henshaw K. Photodynamic therapy for neovascular age-related macular degeneration. *Cochrane Database Syst Rev* 2007;(3):CD002030
16. Kvant A. Ocular angiogenesis: the role of growth factors. *Acta Ophthalmol Scand* 2006;84(3):282-8
17. Shima DT, Adamis AP, Ferrara N, et al. Hypoxic induction of endothelial cell growth factors in retinal cells: identification and characterization of vascular endothelial growth factor (VEGF) as the mitogen. *Mol Med* 1995;1(2):182-93
18. Viores SA, Xiao WH, Aslam S, et al. Implication of the hypoxia response element of the Vegf promoter in mouse models of retinal and choroidal neovascularization, but not retinal vascular development. *J Cell Physiol* 2006;206(3):749-58
19. Zhou J, Pham L, Zhang N, et al. Neutrophils promote experimental choroidal neovascularization. *Mol Vis* 2005;11:414-24
20. Ishibashi T, Hata Y, Yoshikawa H, et al. Expression of vascular endothelial growth factor in experimental choroidal neovascularization. *Graefes Arch Clin Exp Ophthalmol* 1997;235(3):159-67
21. Krzystolik MG, Afshari MA, Adamis AP, et al. Prevention of experimental choroidal neovascularization with intravitreal anti-vascular endothelial growth factor antibody fragment. *Arch Ophthalmol* 2002;120(3):338-46
22. Frank RN, Amin RH, Elliott D, et al. Basic fibroblast growth factor and vascular endothelial growth factor are present in epiretinal and choroidal neovascular membranes. *Am J Ophthalmol* 1996;122(3):393-403
23. Kliffen M, Sharma HS, Mooy CM, et al. Increased expression of angiogenic growth factors in age-related maculopathy. *Br J Ophthalmol* 1997;81(2):154-62
24. Kvant A, Algvare PV, Berglin L, Seregard S. Subfoveal fibrovascular membranes in age-related macular degeneration express vascular endothelial growth factor. *Invest Ophthalmol Vis Sci* 1996;37(9):1929-34
25. Moshfeghi AA, Rosenfeld PJ, Puliafito CA, et al. Systemic bevacizumab (Avastin) therapy for neovascular age-related macular

- degeneration: twenty-four-week results of an uncontrolled open-label clinical study. *Ophthalmology* 2006;113(11):2002 e2001-12
- **Data from this publication heralded the advent of the bevacizumab versus ranibizumab era for treatment of neovascular AMD.**
26. Rosenfeld PJ, Brown DM, Heier JS, et al. Ranibizumab for neovascular age-related macular degeneration. *N Engl J Med* 2006;355(14):1419-31
 - **The MARINA study was a pivotal trial leading to the approval of ranibizumab for neovascular AMD.**
 27. Brown DM, Kaiser PK, Michels M, et al. Ranibizumab versus verteporfin for neovascular age-related macular degeneration. *N Engl J Med* 2006;355(14):1432-44
 - **The ANCHOR study was pivotal in obtaining the FDA approval of ranibizumab for neovascular AMD.**
 28. Brown DM, Michels M, Kaiser PK, et al. Ranibizumab versus verteporfin photodynamic therapy for neovascular age-related macular degeneration: two-year results of the ANCHOR study. *Ophthalmology* 2009;116(1):57-65, e55
 29. Fung AE, Lalwani GA, Rosenfeld PJ, et al. An optical coherence tomography-guided, variable dosing regimen with intravitreal ranibizumab (Lucentis) for neovascular age-related macular degeneration. *Am J Ophthalmol* 2007;143(4):566-83
 - **Variable dosing of ranibizumab for neovascular AMD is now the norm in many practices; this was the first large retrospective of a variable approach.**
 30. Regillo CD, Brown DM, Abraham R, et al. Randomized, double-masked, sham-controlled trial of ranibizumab for neovascular age-related macular degeneration: PIER Study year 1. *Am J Ophthalmol* 2008;145(2):239-48
 31. Ladas ID, Karagiannis DA, Rouvas AA, et al. Safety of repeat intravitreal injections of bevacizumab versus ranibizumab: our experience after 2,000 injections. *Retina* 2009;29(3):313-18
 32. Moreno SF, Paloma JB. Therapeutic anti-VEGF in age-related macular degeneration: ranibizumab and bevacizumab controversy. *Br J Ophthalmol* 2008;92(6):866-7
 33. Safety and Efficacy of Oral PTK787 in Patients with Subfoveal Choroidal Neovascularization Secondary to Age-Related Macular Degeneration (AMD) [ClinicalTrials.gov identifier: NCT00138632] *ClinicalTrials.gov* [online]. Available from: <http://clinicaltrials.gov/ct2/show/NCT00138632> [Accessed 19 Sep 2008]
 34. A study to evaluate to safety, tolerability and PK of pazopanib eye drops in healthy adult and elderly subjects. [ClinicalTrials.gov identifier: NCT00733304] *ClinicalTrials.gov* [online]. Available from: <http://clinicaltrials.gov/ct2/show/NCT00733304> [Accessed 19 Sep 2008]
 35. Open-Label, Pilot Study of TG100801 in Patients With Choroidal Neovascularization Due to AMD [ClinicalTrials.gov identifier: NCT00509548] *ClinicalTrials.gov* [online]. Available from: <http://clinicaltrials.gov/ct2/show/NCT00509548> [Accessed 19 Sep 2008]
 36. Safety & Efficacy Study Evaluating the Combination of Bevasiranib & Lucentis Therapy in Wet AMD (CARBON) [ClinicalTrials.gov identifier: NCT00557791] *ClinicalTrials.gov* [online]. Available from: <http://clinicaltrials.gov/ct2/show/NCT00557791> [Accessed 19 Sep 2008]
 37. Study of AdGVPEDE11D in Neovascular Age-Related Macular Degeneration (AMD) [ClinicalTrials.gov identifier: NCT00109499] *ClinicalTrials.gov* [online]. Available from: <http://clinicaltrials.gov/ct2/show/NCT00109499> [Accessed 19 Sep 2008]
 38. Gaudreault J, Fei D, Rusit J, et al. Preclinical pharmacokinetics of Ranibizumab (rhuFabV2) after a single intravitreal administration. *Invest Ophthalmol Vis Sci* 2005;46(2):726-33
 39. Rudge JS, Holash J, Hylton D, et al. Inaugural article: VEGF Trap complex formation measures production rates of VEGF providing a biomarker for predicting efficacious angiogenic blockade. *Proc Natl Acad Sci USA* 2007;104(47):18363-70
 40. Nguyen QD, Shah SM, Hafiz G, et al. A phase I trial of an IV-administered vascular endothelial growth factor trap for treatment in patients with choroidal neovascularization due to age-related macular degeneration. *Ophthalmology* 2006;113(9):1522 e1521-14
 41. Hariprasad S. Fluorescein angiographic and OCT outcomes of a phase I, dose-escalation, safety, tolerability and bioactivity study of intravitreal VEGF Trap in patients with neovascular AMD: The CLEAR-IT 1 Study. Paper presented at: Combined Meeting of the Club Jules Gonin and the Retina Society; Oct 15-20th, 2006; Cape Town, South Africa
 42. Nguyen Q, Hariprasad S, Browning D, et al. Interim results of a phase I, dose-escalation, safety, tolerability, and bioactivity study of intravitreal VEGF Trap in patients with neovascular AMD: The CLEAR-IT 1 Study [abstract no. E-2868]. Paper presented at: Combined Meeting of the Club Jules Gonin and the Retina Society; Oct 15-20th, 2006; Cape Town, South Africa
 43. Nguyen Q, for the CLEAR-IT 1 investigators. A randomized comparison of the safety, tolerability, and bioactivity study two dose levels of intravitreal VEGF trap in patients with neovascular age-related macular degeneration. Paper presented at: Retina Society Annual Scientific Meeting; Sep 27-30th, 2007; Boston, MA
 44. Do DV, Nguyen QD, Shah SM, et al. An exploratory study of the safety, tolerability and bioactivity of a single intravitreal injection of vascular endothelial growth factor Trap-Eye in patients with diabetic macular oedema. *Br J Ophthalmol* 2009;93(2):144-9
 45. VEGF Trap-Eye in Wet AMD. CLEAR-IT 2: Summary of One-Year Key Results. Paper presented at: Retinal Society Annual Scientific Meeting; Sep 28th, 2008; Scottsdale, AZ
 46. Double-Masked Study of Efficacy and Safety of IVT VEGF Trap-Eye in Subjects With Wet AMD (VIEW 1) [ClinicalTrials.gov identifier: NCT00509795] *ClinicalTrials.gov* [online]. Available from: <http://clinicaltrials.gov/ct2/show/NCT00509795> [Accessed 28 Sep 2008]
 47. VEGF Trap-Eye: Investigation of Efficacy and Safety in Wet AMD (VIEW 2). [ClinicalTrials.gov identifier: NCT00637377] *ClinicalTrials.gov* [online]. Available from: <http://clinicaltrials.gov/ct2/show/NCT00637377> [Accessed 28 Sep 2008]
 48. Jaffe GJ, Martin D, Callanan D, et al. Fluocinolone acetonide implant (Retisert) for noninfectious posterior uveitis: thirty-four-week results of a multicenter

- randomized clinical study. *Ophthalmology* 2006;113(6):1020-7
49. Kuppermann BD, Blumenkranz MS, Haller JA, et al. Randomized controlled study of an intravitreal dexamethasone drug delivery system in patients with persistent macular edema. *Arch Ophthalmol* 2007;125(3):309-17
 50. Williams GA, Haller JA, Kuppermann BD, et al. Dexamethasone posterior-segment drug delivery system in the treatment of macular edema resulting from uveitis or irvine-gass syndrome. *Am J Ophthalmol* 2009;147(6):1048-54, 1054.e1-2
 51. Sieving PA, Caruso RC, Tao W, et al. Ciliary neurotrophic factor (CNTF) for human retinal degeneration: phase I trial of CNTF delivered by encapsulated cell intraocular implants. *Proc Natl Acad Sci USA* 2006;103(10):3896-901
 52. Lazic R, Gabric N. Verteporfin therapy and intravitreal bevacizumab combined and alone in choroidal neovascularization due to age-related macular degeneration. *Ophthalmology* 2007;114:1179-85
 53. Gragoudas ES, Adamis AP, Cunningham ET, et al.; VEGF Inhibition Study in Ocular Neovascularization Clinical Trial Group. Pegaptanib for neovascular age-related macular degeneration. *N Engl J Med* 2004;351:2805-16
 54. Heier JS, Boyer DS, Ciulla TA, et al.; FOCUS Study Group. Ranibizumab combined with verteporfin photodynamic therapy in neovascular age-related macular degeneration: year 1 results of the FOCUS study. *Arch Ophthalmol* 2006;124:1532-42
 55. Kaiser PK; Registry of Visudyne AMD Therapy Writing Committee, Boyer DS, Garcia R, Hao Y, et al. Verteporfin photodynamic therapy combined with intravitreal bevacizumab for neovascular age-related macular degeneration. *Ophthalmology* 2009;116(4):747-55
 56. Efficacy/safety of verteporfin photodynamic therapy and ranibizumab compared with ranibizumab in patients with subfoveal choroidal neovascularization. [ClinicalTrials.gov identifier: NCT00436553] *ClinicalTrials.gov* [online]. Available from: <http://clinicaltrials.gov/ct2/show/NCT00436553> [Accessed 28 Sep 2008]
 57. Reduced Fluence Visudyne-Anti-VEGF-Dexamethasone In Combination for AMD Lesions (RADICAL) [ClinicalTrials.gov identifier: NCT00492284] *ClinicalTrials.gov* [online]. Available from: <http://clinicaltrials.gov/ct2/show/NCT00492284> [Accessed 28 Sep 2008]
 58. Avila MB, Farah ME, Santos A, et al. Twelve-month short-term safety and visual-acuity results from a multicentre prospective study of epiretinal strontium-90 brachytherapy with bevacizumab for the treatment of subfoveal choroidal neovascularisation secondary to age-related macular degeneration. *Br J Ophthalmol* 2009;93(3):305-9
 59. Study of Strontium90 Beta Radiation With Lucentis to Treat Age-Related Macular Degeneration (CABERNET) [ClinicalTrials.gov identifier: NCT00454389] *ClinicalTrials.gov* [online]. Available from: http://clinicaltrials.gov/ct2/show/study/NCT00454389?term=cabernet&rank=1&how_lsc=Y [Accessed 28 May 2009]

Affiliation

James A Dixon MD Resident in Ophthalmology,
 Scott CN Oliver[†] MD Assistant Professor of Ophthalmology,
 Jeffrey L Olson MD
 Assistant Professor of Ophthalmology &
 Naresh Mandava MD Professor and Chair of Ophthalmology
[†]Author for correspondence
 University of Colorado Denver,
 Rocky Mountain Lions Eye Institute,
 Department of Ophthalmology,
 1675 North Aurora Court, PO Box 6510,
 Mail Stop F-731, Aurora, CO 80045-2500, USA
 Tel: +1 720 848 5029; Fax: +1 720 848 5014;
 E-mail: scott.oliver@ucdenver.edu

Expert opinion on investigational drugs.
v. 18, no. 10 (Oct. 2009)
General Collection
W1 EX52M
2009-10-20 09:53:24

Expert Opinion

on Investigational Drugs

EDITORIAL

- Phospholipase A2 inhibitors in the treatment of atherosclerosis: a new approach moves forward in the clinic
Keith E Suckling

DISCONTINUED DRUGS PERSPECTIVE

- Discontinued psychiatric drugs in 2008
Victoria D Kirchhoff, Ha TT Nguyen, Joanna K Soczynska, Hanna O Woldeyohannes & Roger S McIntyre

REVIEWS

- Investigational drugs targeting FLT3 for leukemia
Celalettin Ustun, David L DeRemer, Anand P Jillella & Kapil N Bhatta
- Targeting IL-6 in the treatment of inflammatory and autoimmune diseases
Changhai Ding, Flavia Cicuttini, Jun Li & Graeme Jones
- Current data of targeted therapies for the treatment of triple-negative advanced breast cancer: empiricism or evidence-based?
Fausto Petrelli, Mary Cabiddu, Mara Ghilardi & Sandro Barni
- Current progress in the pharmacological therapy of fibromyalgia
Srinivas G Rao
- Glucose lowering and anti-atherogenic effects of incretin-based therapies: GLP-1 analogues and DPP-4-inhibitors
Manfredi Rizzo, Ali A Rizvi, Giatgen A Spinas, Giovam Battista Rini & Kaspar Bernis
- Emerging oligonucleotide therapies for asthma and chronic obstructive pulmonary disease
Rosanne M Séguin & Nicolay Ferrari
- Histamine H₂ and H₁ receptors as novel drug targets
Ekaterini Tilligada, Evangelia Zampeli, Kerstin Sander & Holger Stark

DRUG EVALUATIONS

- Agomelatine
Steven L Dubovsky & Calvert Warren
- AVE8062
Angelo Delmonte & Cristiana Sessa
- Cediranib
Jörg Dietrich, Daphne Wang & Tracy T Batchelor
- Clofarabine
Keeran Sampat, Hagop Kantarjian & Gautam Borthakur
- Fospropofol disodium
Jörg Fehner, Harald Ihmsen, Christian Jeleazcov & Jürgen Schüttler
- VEGF Trap-Eye
James A Dixon, Scott CN Oliver, Jeffrey L Olson & Naresh Mandava

Expert Opinion on Investigational Drugs is indexed by Chemical Abstracts (CODEN: EOIDER), Current Contents/Life Sciences, EMBASE/Excerpta Medica, Index Medicus/Medline, ISI Alerting Services and Science Citations Index-Expanded. 2008 ISI Impact Factor 4.058
This material is available at the NLM and may be subject to US Copyright Law.

PROPERTY OF THE
NATIONAL
LIBRARY OF
MEDICINE



informa
PHARMACEUTICAL SCIENCE