

# The NEW ENGLAND JOURNAL of MEDICINE

VOL. 365 NO. 8

ESTABLISHED IN 1812

AUGUST 25, 2011

NEJM.ORG



688 THIS WEEK AT NEJM.ORG

## PERSPECTIVE

- 681 Impossible? Outlawing State Safety Laws for Generic Drugs L.H. Glantz and G.J. Annas
- 683 The Effects of Medicaid Coverage — Learning from the Oregon Experiment K. Baicker and A. Finkelstein
- 685 HIV Surveillance, Public Health, and Clinical Medicine — Will the Walls Come Tumbling Down? A.L. Fairchild and R. Bayer

## ORIGINAL ARTICLES

- 689 Azithromycin for Prevention of Exacerbations of COPD R.K. Albert and Others
- 699 Apixaban with Antiplatelet Therapy after Acute Coronary Syndrome J.H. Alexander and Others
- 709 Origins of the *E. coli* Strain Causing an Outbreak of Hemolytic-Uremic Syndrome in Germany D.A. Rasko and Others
- 718 Brief Report: Open-Source Genomic Analysis of Shiga-Toxin–Producing *E. coli* O104:H4 H. Rohde and Others
- 725 Brief Report: Chimeric Antigen Receptor–Modified T Cells in Chronic Lymphoid Leukemia D.L. Porter and Others

## CLINICAL THERAPEUTICS

- 734 Thrombopoietin-Receptor Agonists for Primary Immune Thrombocytopenia P. Imbach and M. Crowther

Owned & published by the MASSACHUSETTS MEDICAL SOCIETY © 2011.  
All rights reserved. ISSN 0028-4793.

## IMAGES IN CLINICAL MEDICINE

- 742 Baló's Concentric Sclerosis O. Wengert and E. Siebert
- e16 Pneumatoxis Cystoides Intestinalis S.-S. Wu and H.-H. Yen

## CASE RECORDS OF THE MASSACHUSETTS GENERAL HOSPITAL

- 743 A Boy with a Complex Cyst in the Kidney E. Paul and Others

## EDITORIALS

- 753 Preventing Exacerbations of COPD — Advice from Hippocrates N.M. Siafakas
- 754 Redirecting T Cells W.J. Urba and D.L. Longo

## CLINICAL DECISIONS

- e17 Treatment of a 6-Year-Old Girl with Vesicoureteral Reflux — Polling Results D.J. Lamas, J.R. Ingelfinger, and L.S. Rosenbaum

## CLINICAL IMPLICATIONS OF BASIC RESEARCH

- 758 Systemic Lupus Erythematosus and the Neutrophil X. Bosch

## CORRESPONDENCE

- Transmission of Resistant Bacteria in Intensive Care
- Abiraterone and Increased Survival in Metastatic Prostate Cancer
- FOLFIRINOX versus Gemcitabine for Metastatic Pancreatic Cancer
- Selenium and the Course of Mild Graves' Orbitopathy
- gp100 Peptide Vaccine in Melanoma
- Childhood Diarrhea Deaths after Rotavirus

University of Southern California

**DOCKET**  
**ALARM**

Find authenticated court documents without watermarks at [docketalarm.com](http://docketalarm.com).

BRIEF REPORT

## Chimeric Antigen Receptor–Modified T Cells in Chronic Lymphoid Leukemia

David L. Porter, M.D., Bruce L. Levine, Ph.D., Michael Kalos, Ph.D., Adam Bagg, M.D., and Carl H. June, M.D.

### SUMMARY

We designed a lentiviral vector expressing a chimeric antigen receptor with specificity for the B-cell antigen CD19, coupled with CD137 (a costimulatory receptor in T cells [4-1BB]) and CD3-zeta (a signal-transduction component of the T-cell antigen receptor) signaling domains. A low dose (approximately  $1.5 \times 10^5$  cells per kilogram of body weight) of autologous chimeric antigen receptor–modified T cells reinfused into a patient with refractory chronic lymphocytic leukemia (CLL) expanded to a level that was more than 1000 times as high as the initial engraftment level in vivo, with delayed development of the tumor lysis syndrome and with complete remission. Apart from the tumor lysis syndrome, the only other grade 3/4 toxic effect related to chimeric antigen receptor T cells was lymphopenia. Engineered cells persisted at high levels for 6 months in the blood and bone marrow and continued to express the chimeric antigen receptor. A specific immune response was detected in the bone marrow, accompanied by loss of normal B cells and leukemia cells that express CD19. Remission was ongoing 10 months after treatment. Hypogammaglobulinemia was an expected chronic toxic effect.

**W**ITH THE USE OF GENE-TRANSFER TECHNIQUES, T CELLS CAN BE GENETICALLY modified to stably express antibodies on their surface, conferring new antigen specificity. Chimeric antigen receptors combine an antigen-recognition domain of a specific antibody with an intracellular domain of the CD3-zeta chain or Fc $\gamma$ RI protein into a single chimeric protein.<sup>1,2</sup> Although chimeric antigen receptors can trigger T-cell activation in a manner similar to that of endogenous T-cell receptors, a major impediment to the clinical application of this technique to date has been limited in vivo expansion of chimeric antigen receptor T cells and disappointing clinical activity.<sup>3,4</sup> Chimeric antigen receptor–mediated T-cell responses can be further enhanced with the addition of a costimulatory domain. In preclinical models, we found that inclusion of the CD137 (4-1BB) signaling domain significantly increases antitumor activity and in vivo persistence of chimeric antigen receptors as compared with inclusion of the CD3-zeta chain alone.<sup>5,6</sup>

In most cancers, tumor-specific antigens for targeting are not well defined, but in B-cell neoplasms, CD19 is an attractive target. Expression of CD19 is restricted to normal and malignant B cells and B-cell precursors.<sup>7</sup> We have initiated a pilot clinical trial of treatment with autologous T cells expressing an anti-CD19 chimeric antigen receptor (CART19); three patients have been treated. Here we report on the immunologic and clinical effects of in vivo T-cell treatment with chimeric antigen receptors

From the Abramson Cancer Center (D.L.P., B.L.L., M.K., A.B., C.H.J.), the Department of Medicine (D.L.P.), the Department of Pathology and Laboratory Medicine (B.L.L., M.K., A.B., C.H.J.), and the Abramson Family Cancer Research Institute (B.L.L., M.K., C.H.J.), Perelman School of Medicine, University of Pennsylvania, Philadelphia. Address reprint requests to Dr. Porter at the Division of Hematology and Oncology, University of Pennsylvania Medical Center, 3400 Civic Center Blvd., PCAM 2 West Pavilion, Philadelphia, PA 19104, or at david.porter@uphs.upenn.edu.

This article (10.1056/NEJMoa1103849) was published on August 10, 2011, at NEJM.org.

N Engl J Med 2011;365:725-33.  
Copyright © 2011 Massachusetts Medical Society.

## CASE REPORT

The patient received a diagnosis of stage I CLL in 1996. He first required treatment after 6 years of observation for progressive leukocytosis and adenopathy. In 2002, he was treated with two cycles of rituximab plus fludarabine; this treatment resulted in normalization of blood counts and partial resolution of adenopathy. In 2006, he received four cycles of rituximab and fludarabine for disease progression, again with normalization of blood counts and partial regression of adenopathy. This response was followed by a 20-month progression-free interval and a 2-year treatment-free interval. In February 2009, he had rapidly progressive leukocytosis and recurrent adenopathy. His bone marrow was extensively infiltrated with CLL. Cytogenetic analysis showed that 3 of 15 cells contained a deletion of chromosome 17p, and fluorescence in situ hybridization (FISH) testing showed that 170 of 200 cells had a deletion involving *TP53* on chromosome 17p. He received rituximab with bendamustine for one cycle and three additional cycles of bendamustine without rituximab (because of a severe allergic reaction). This treatment resulted in only transient improvement in lymphocytosis. Progressive adenopathy was documented by means of computed tomography (CT) after therapy.

In December 2009, autologous T cells were collected by means of leukapheresis and cryopreserved. The patient then received alemtuzumab (an anti-CD52, mature-lymphocyte, cell-surface antigen) for 11 weeks, with improved hematopoiesis and a partial resolution of adenopathy. Over the next 6 months, he had stable disease with persistent, extensive marrow involvement and diffuse adenopathy with multiple 1- to 3-cm lymph nodes. In July 2010, the patient was enrolled in a phase 1 clinical trial of chimeric antigen receptor–modified T cells.

## METHODS

## STUDY DESIGN

The trial (ClinicalTrials.gov number, NCT01029366) was designed to assess the safety and feasibility of infusing autologous CART19 T cells in patients with relapsed or refractory B-cell neoplasms. The trial was approved by the institutional review board at the University of Pennsylvania. The study was conducted in accordance with the protocol (available with the full text of this article at [NEJM.org](http://NEJM.org)).

## STUDY PROCEDURES

We designed a self-inactivating lentiviral vector (GeMCRIS 0607-793), which was subjected to pre-clinical safety testing, as reported previously.<sup>5</sup> Methods of T-cell preparation have also been described previously.<sup>8</sup> Quantitative polymerase-chain-reaction (PCR) analysis was performed to detect chimeric antigen receptor T cells in blood and bone marrow. The lower limit of quantification was determined from the standard curve; average values below the lower limit of quantification (i.e., reportable but not quantifiable) are considered approximate. The lower limit of quantification of the assay was 25 copies per microgram of genomic DNA.

Soluble-factor analysis was performed with the use of serum from whole blood and bone marrow that was separated into aliquots for single use and stored at  $-80^{\circ}\text{C}$ . Quantification of soluble cytokine factors was performed with the use of Luminex bead-array technology and reagents from Life Technologies.

## RESULTS

## CELL INFUSIONS

Autologous T cells from the patient were thawed and transduced with lentivirus to express the CD19-specific chimeric antigen receptor (Fig. 1A). Four days before cell infusion, the patient received chemotherapy designed for depletion of lymphocytes (pentostatin at a dose of 4 mg per square meter of body-surface area and cyclophosphamide at a dose of 600 mg per square meter) without rituximab.<sup>9</sup> Three days after chemotherapy but before cell infusion, the bone marrow was hypercellular with approximately 40% involvement by CLL. Leukemia cells expressed kappa light chain and CD5, CD19, CD20, and CD23. Cytogenetic analysis showed two separate clones, both resulting in loss of chromosome 17p and the *TP53* locus (46,XY,del(17)(p12)[5]/46,XY,der(17)t(17;21)(q10;q10)[5]/46,XY[14]). Four days after chemotherapy, the patient received a total of  $3 \times 10^8$  T cells, of which 5% were transduced, for a total of  $1.42 \times 10^7$  transduced cells ( $1.46 \times 10^5$  cells per kilogram) split into three consecutive daily intravenous infusions (10% on day 1, 30% on day 2, and 60% on day 3). No postinfusion cytokines were administered. No toxic effects of infusions were noted.

## CLINICAL RESPONSE AND EVALUATIONS

Response data from the first 3 infusions are shown in Table 1.

#### BRIEF REPORT

ated with grade 2 fatigue. Over the next 5 days, the chills intensified, and his temperature escalated to 39.2°C (102.5°F), associated with rigors, diaphoresis, anorexia, nausea, and diarrhea. He had no respiratory or cardiac symptoms. Because of the fevers, chest radiography and blood, urine, and stool cultures were performed, and were all negative or normal. The tumor lysis syndrome was diagnosed on day 22 after infusion (Fig. 1B). The uric acid level was 10.6 mg per deciliter (630.5  $\mu$ mol per liter), the phosphorus level was 4.7 mg per deciliter (1.5 mmol per liter) (normal range, 2.4 to 4.7 mg per deciliter [0.8 to 1.5 mmol per liter]), and the lactate dehydrogenase level was 1130 U per liter (normal range, 98 to 192). There was evidence of acute kidney injury, with a creatinine level of 2.60 mg per deciliter (229.8  $\mu$ mol per liter) (baseline level, <1.0 mg per deciliter [ $<88.4 \mu$ mol per liter]). The patient was hospitalized and treated with fluid resuscitation and rasburicase. The uric acid level returned to the normal range within 24 hours, and the creatinine level within 3 days; he was discharged on hospital day 4. The lactate dehydrogenase level decreased gradually, becoming normal over the following month.

By day 28 after CART19-cell infusion, adenopathy was no longer palpable, and on day 23, there was no evidence of CLL in the bone marrow (Fig. 1C). The karyotype was now normal in 15 of 15 cells (46,XY), and FISH testing was negative for deletion TP53 in 198 of 200 cells examined; this is considered to be within normal limits in negative controls. Flow-cytometric analysis showed no residual CLL, and B cells were not detectable (<1% of cells within the CD5+CD10–CD19+CD23+ lymphocyte gate). CT scanning performed on day 31 after infusion showed resolution of adenopathy (Fig. 1D).

Three and 6 months after CART19-cell infusion, the physical examination remained unremarkable, with no palpable adenopathy, and CT scanning performed 3 months after CART19-cell infusion showed sustained remission (Fig. 1D). Bone marrow studies at 3 and 6 months also showed no evidence of CLL by means of morphologic analysis, karyotype analysis (46,XY), or flow-cytometric analysis, with a continued lack of normal B cells as well. Remission had been sustained for 10 months as of this writing.

the grade 3 tumor lysis syndrome described above. The patient had grade 1 lymphopenia at baseline and grade 2 or 3 lymphopenia beginning on day 1 and continuing through the most recent follow-up visit, 10 months after therapy. Grade 4 lymphopenia, with an absolute lymphocyte count of 140 cells per cubic millimeter, was recorded on day 19, but from day 22 through the most recent follow-up visit, the absolute lymphocyte count ranged between 390 and 780 cells per cubic millimeter (grade 2 or 3 lymphopenia). The patient had transient grade 1 thrombocytopenia (platelet count, 98,000 to 131,000 per cubic millimeter) from day 19 through day 26 and grade 1 or 2 neutropenia (absolute neutrophil count, 1090 to 1630 per cubic millimeter) from day 17 through day 33. Other signs and symptoms that were probably related to the study treatment included grade 1 and 2 elevations in aminotransferase and alkaline phosphatase levels, which developed 17 days after the first infusion and resolved by day 33. Grade 1 and 2 constitutional symptoms consisted of fevers, chills, diaphoresis, myalgias, headache, and fatigue. Grade 2 hypogammaglobulinemia was corrected with infusions of intravenous immune globulin.

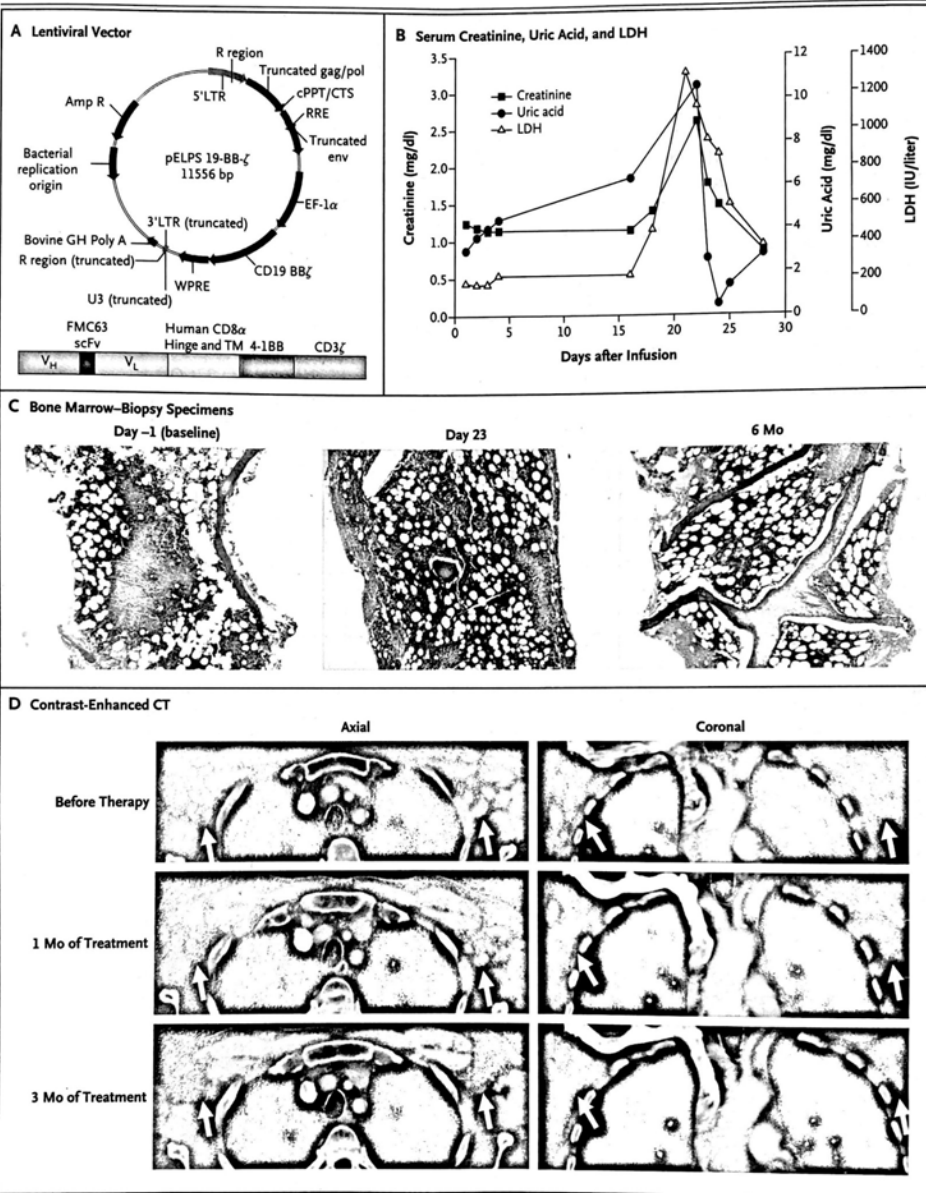
#### ANALYSIS OF SERUM AND BONE MARROW CYTOKINES

The patient's clinical response was accompanied by a delayed increase in levels of inflammatory cytokines (Fig. 2A through 2D), with levels of interferon- $\gamma$ , the interferon- $\gamma$ -responsive chemokines CXCL9 and CXCL10, and interleukin-6 that were 160 times as high as baseline levels. The temporal rise in cytokine levels paralleled the clinical symptoms, peaking 17 to 23 days after the first CART19-cell infusion.

The supernatants from serial bone marrow aspirates were measured for cytokines and showed evidence of immune activation (Fig. 2E). Significant increases in interferon- $\gamma$ , CXCL9, interleukin-6, and soluble interleukin-2 receptor were noted, as compared with the baseline levels on the day before T-cell infusion; the values peaked on day 23 after the first CART19-cell infusion. The increase in bone marrow cytokines coincided with the elimination of leukemia cells from the marrow. Serum and marrow tumor necrosis factor  $\alpha$  remained unchanged.

#### EXPANSION AND PERSISTENCE OF CHIMERIC ANTIGEN RECEPTOR T CELLS

TOXICITY OF CART19 CELLS



# Explore Litigation Insights

Docket Alarm provides insights to develop a more informed litigation strategy and the peace of mind of knowing you're on top of things.

## Real-Time Litigation Alerts



Keep your litigation team up-to-date with **real-time alerts** and advanced team management tools built for the enterprise, all while greatly reducing PACER spend.

Our comprehensive service means we can handle Federal, State, and Administrative courts across the country.

## Advanced Docket Research



With over 230 million records, Docket Alarm's cloud-native docket research platform finds what other services can't. Coverage includes Federal, State, plus PTAB, TTAB, ITC and NLRB decisions, all in one place.

Identify arguments that have been successful in the past with full text, pinpoint searching. Link to case law cited within any court document via Fastcase.

## Analytics At Your Fingertips



Learn what happened the last time a particular judge, opposing counsel or company faced cases similar to yours.

Advanced out-of-the-box PTAB and TTAB analytics are always at your fingertips.

## API

Docket Alarm offers a powerful API (application programming interface) to developers that want to integrate case filings into their apps.

## LAW FIRMS

Build custom dashboards for your attorneys and clients with live data direct from the court.

Automate many repetitive legal tasks like conflict checks, document management, and marketing.

## FINANCIAL INSTITUTIONS

Litigation and bankruptcy checks for companies and debtors.

## E-DISCOVERY AND LEGAL VENDORS

Sync your system to PACER to automate legal marketing.