

# EFFECT OF RANIBIZUMAB RETREATMENT FREQUENCY ON NEUROSENSORY RETINAL VOLUME IN NEOVASCULAR AMD

PEARSE A. KEANE, MRCOPHTH, MSc,\* KAREN T. CHANG, BS,\*  
SANDRA LIAKOPOULOS, MD,\*† RENU V. JIVRAJKA, BS,\*  
ALEXANDER C. WALSH, MD,\* SRINIVAS R. SADDA, MD\*

**Purpose:** To determine the characteristics of patients with neovascular age-related macular degeneration who show initial anatomic improvements on optical coherence tomography in response to treatment with ranibizumab, but who subsequently regress toward their anatomic baseline.

**Methods:** Data from 50 consecutive patients, receiving ranibizumab therapy for neovascular age-related macular degeneration, were collected. Raw StratusOCT images were analyzed using custom software ("OCTOR"). Changes in volume of neurosensory retina at months 1, 3, and 6 were calculated. Baseline demographic and morphologic characteristics were compared.

**Results:** Forty-two patients (84%) showed a reduction in total retinal volume 1 month after initial treatment with ranibizumab. Of the patients that initially showed a reduction, 16 (38%) maintained this reduction through month 6, whereas 26 patients (62%) demonstrated a subsequent increase in retinal volume. Patients who maintained a reduction in edema received  $3.75 \pm 1.18$  injections of ranibizumab versus  $2.96 \pm 1.34$  injections for patients who did not ( $P = 0.049$ ). Regression of initial anatomic improvements was associated with worsening of visual acuity ( $r = 0.599$ ,  $P = 0.002$ ).

**Conclusion:** Patients receiving fewer injections of ranibizumab appeared less likely to maintain anatomic improvements achieved following commencement of ranibizumab therapy; regression of these improvements was associated with deterioration in visual acuity.

RETINA 29:592–600, 2009

Ranibizumab (Lucentis; Genentech, Inc., San Francisco, CA), an antibody fragment that blocks all isoforms of vascular endothelial growth factor-A, is the first treatment for neovascular age-related macular degeneration (AMD) that has been shown to lead to significant improvements in visual acuity in Phase III clinical trials.<sup>1,2</sup> In the MARINA and ANCHOR trials,

patients received monthly injections of ranibizumab over a 2-year period—a retreatment regimen that has both practical and economic implications, particularly with the availability of inexpensive alternatives, such as bevacizumab (Avastin; Genentech).<sup>3,4</sup> As a result, much effort has focused on the development of alternative treatment regimens, which would reduce the number of injections required, while maintaining the efficacy demonstrated in the MARINA and ANCHOR studies.<sup>5,6</sup>

Optical coherence tomography (OCT) formed the basis for retreatment in the recently published PRONTO study,<sup>5</sup> and OCT-guided retreatment protocols have become widely adopted in clinical practice. Caution is required, however, when utilizing quantitative information from OCT in a clinical setting, as significant errors are known to occur in data obtained from the widely used StratusOCT analysis software.<sup>7</sup>

From the \*Doheny Image Reading Center, Doheny Eye Institute, Keck School of Medicine of the University of Southern California, Los Angeles, California; and †Department for Vitreoretinal Surgery, Center of Ophthalmology, University of Cologne, Germany.

Supported in part by NIH Grant EY03040 and NEI Grant R01 EY014375.

Drs. Walsh and Sadda are coinventors of Doheny intellectual property related to optical coherence tomography that has been licensed by Topcon Medical Systems. However, it is not related to the article's subject matter.

Reprint requests: Srinivas R. Sadda, MD, Doheny Eye Institute-DEI 3623, 1450 San Pablo Street, Los Angeles, CA 90033; e-mail: sadda@usc.edu

To address this issue, we have previously developed publicly available custom image-measurement software, entitled "OCTOR."<sup>8,9</sup> This software facilitates accurate and reproducible manual segmentation of OCT images and allows quantitative analysis of any area of interest in these images, e.g., retina, subretinal fluid, subretinal tissue, or pigment epithelium detachment (PED).

Quantitative OCT data derived from accurate segmentation of the neurosensory retina may facilitate retreatment decisions, although its precise role remains unresolved.<sup>5,10</sup> Using OCTOR, we have previously reported results from a cohort of patients treated with ranibizumab according to an OCT-guided retreatment regimen.<sup>11</sup> In this previous study, the effect of ranibizumab on the neurosensory retina appeared to be attenuated over time—a finding we speculated was secondary to treatment tachyphylaxis. In the present study, we aim to determine if there are differences in the characteristics of patients with neovascular AMD who show anatomic regression after initial response to therapy, versus those who maintain anatomic improvement, as determined by OCT.

## Materials and Methods

### Data Collection

For this retrospective study, we collected and reviewed data from all patients receiving their initial intravitreal injections of ranibizumab at the Doheny Eye Institute between July 2006 and September 2007. Approval for data collection and analysis was obtained from the institutional review board of the University of Southern California. The research adhered to the tenets set forth in the Declaration of Helsinki.

For inclusion in the study, eyes were required to have subfoveal choroidal neovascularization (CNV) secondary to AMD; StratusOCT imaging performed before their initial treatment with ranibizumab; and a total of 6 months of subsequent follow-up, with StratusOCT imaging at each visit. Any patient switched to an alternative treatment for neovascular AMD, during this follow-up period, was excluded from the study.

StratusOCT images were collected at baseline and at Months 1, 3, and 6 after initial treatment with ranibizumab. Images were obtained with a single StratusOCT machine using the Radial Lines protocol of six high-resolution B-scans. The Fast Macular Thickness protocol was used only when photographers were unable to obtain adequate high-resolution images, most commonly in patients with unstable fixation or poor cooperation. Data for each case were exported to disk

using the export feature available in the StratusOCT version 4.0 analysis software.

The number and type of any previous treatments for CNV secondary to AMD in the study eye were recorded. After their initial intravitreal injection, patients were treated at the discretion of the physician based on assessment of disease activity as determined by OCT and/or fluorescein angiography, and utilizing many of the criteria specified in the PrONTO study.<sup>5</sup> In the PrONTO study, ranibizumab retreatment was performed if one of the following changes was observed: a loss of five letters in conjunction with fluid in the macula as detected by OCT, an increase in OCT central retinal thickness of at least 100  $\mu\text{m}$ , new-onset classic CNV, new macular hemorrhage, or persistent macular fluid detected by OCT at least 1 month after the previous injection of ranibizumab. The number and timing of retreatments were recorded for each patient. Other data collected included patient age and gender, as well as best-corrected Snellen visual acuity at the time of initial ranibizumab injection. Fluorescein angiographic images taken for each patient at the time of initial treatment were also collected.

### Baseline Patient Characteristics

Fifty consecutive patients, receiving their initial intravitreal injections of ranibizumab at the Doheny Eye Institute, and meeting the inclusion criteria were included in this study. Two patients were excluded from consideration as they were switched to an alternative treatment (intravitreal bevacizumab) during the course of follow-up. Of the 50 patients included, 30 (60%) were women, whereas 20 (40%) were men. The mean age of patients was 80 years (SD = 7), whereas the median age was 81 years (range, 63–92 years). Mean visual acuity at time of initial treatment with ranibizumab was 20/123. Twenty-eight (56%) patients had undergone prior treatment for CNV in their study eye, consisting of photodynamic therapy with verteporfin, thermal laser photocoagulation, pegaptanib, or bevacizumab.

### Computer-Assisted Grading Software

The software used for OCT analysis (entitled "OCTOR") was written by Doheny Image Reading Center software engineers to facilitate viewing and manual grading. OCTOR is publicly accessible at <http://www.diesel.la> (accessed June 23rd, 2008) and has been described and validated in previous reports.<sup>8,9,11–13</sup> This software, which effectively operates as a painting program and calculator, imports data exported from the StratusOCT machine and allows the grader to use a

computer mouse to draw various boundaries in the retinal cross-sectional images.

After the grader draws the required layers in each of the 6 B-scans, the software calculates the distance in pixels between the manually drawn boundary lines for each of the various defined spaces. Using the dimensions of the B-scan image, the calculated pixels are converted into micrometers to yield a thickness measurement at each location. The thickness at all unsampled locations between the radial lines is then interpolated based on a polar approximation to yield a thickness map analogous to the StratusOCT output data. After interpolation, thickness values are converted into volumes ( $\text{mm}^3$ ) by multiplying the average thickness measurement by the sampled area. The interpolation algorithm, intergrader reliability, and intragrader reproducibility have previously been validated.<sup>8,9</sup>

Analogous to the StratusOCT software, OCTOR provides a report showing the calculated thickness/volume values for the nine Early Treatment Diabetic Retinopathy Study macular subfields. The means and standard deviations of the foveal center point thickness are also calculated. In contrast to the StratusOCT output, OCTOR provides separate maps for the various macular spaces of interest.

#### Grading Procedure

Optical coherence tomography scans were analyzed by certified OCT graders at the Doheny Image Reading Center (PAK, SL, KTC). Boundaries drawn in each of the six OCT B-scans included the internal limiting membrane, outer border of the photoreceptors, borders of subretinal fluid and subretinal tissue (if present), inner surface of the retinal pigment epithelium and estimated normal position of the retinal pigment epithelium layer (in cases of retinal pigment epithelium elevation). All boundaries were drawn in accordance with the standard OCT grading protocol of the Doheny Image Reading Center.<sup>8</sup> After completion of the grading, OCTOR was used to calculate output parameters for the various spaces: retina, subretinal fluid, subretinal tissue, and PED.

Angiographic CNV lesion type at baseline was determined by certified FA graders at the Doheny Image Reading Center (PAK, KTC) using the Treatment of Age-Related Macular Degeneration with Photodynamic Therapy Study grading protocol.<sup>14</sup> Disagreement regarding angiographic classification of CNV lesion type was resolved by open adjudication and consensus between graders, in accordance with standard reading center practices.

#### Data Analysis and Statistical Methods

The change from baseline in total retinal volume was determined for each patient at Month 1. Patients showing an initial reduction in total retinal volume by Month 1 were used to formulate two groups for the purposes of comparison. Patients who maintained, or had further reduction, in total retinal volume, between Month 1 and the final examination at Month 6 were included in the first group; patients demonstrating an increase in retinal volume from Month 1 to Month 6 were included in the second group (Figure 1).

Groups were compared for each of the following variables: age, gender, previous treatment for neovascular AMD, angiographic CNV lesion classification at baseline, visual acuity at baseline, and number of injections of ranibizumab received. OCTOR software was also used to compare the volumes of neurosensory retina, subretinal fluid, PED, and subretinal tissue, between the two groups at baseline and at each follow-up. For each comparison between groups, a *t*-test (2-tail distribution) was used in the case of normally distributed interval variables, whereas a chi-square test or Fisher's Exact Test was used in the case of categorical variables. For each group the mean change from baseline, in total volume of the neurosensory retina, was also calculated at each follow-up visit, and analyzed using a paired *t*-test. *P* values <0.05 were considered statistically significant. Statistical analysis was performed using commercially available software (Intercooled Stata for Windows, Version 9, Statacorp LP).

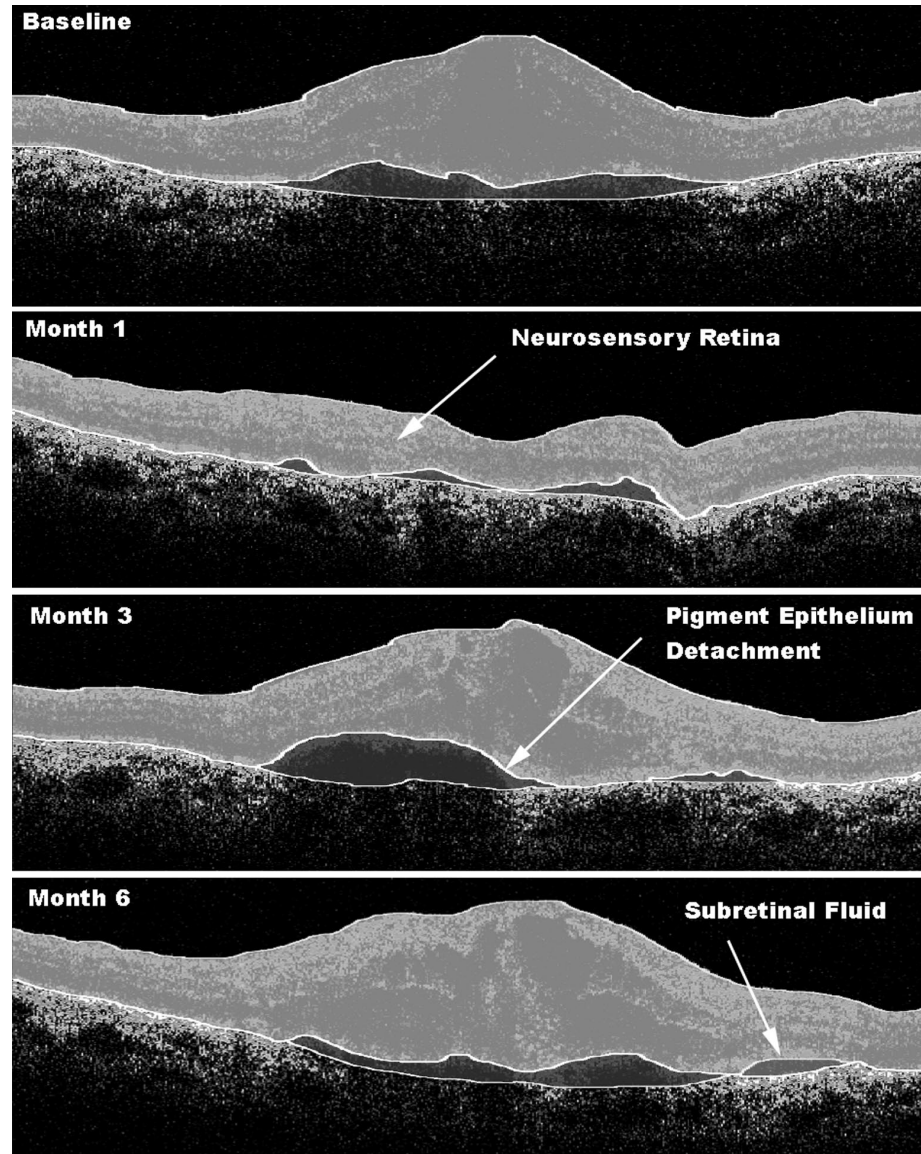
## Results

#### Baseline Morphologic Characteristics

At baseline, the neovascular lesions were categorized by fluorescein angiography as predominantly classic (10 eyes, 20%), as minimally classic (8 eyes, 16%) and as occult with no classic (32 eyes, 64%). The total area of visible classic CNV and occult CNV was considered the area of CNV leakage. The CNV lesion was defined as the area of CNV leakage plus any contiguous areas of thick hemorrhage, blocked fluorescence, staining scars or serous PED which could be obscuring the boundaries of the CNV. The mean total CNV lesion area was  $5.7 \pm 5.1$  Disk Areas, whereas the mean total area of CNV leakage was  $3.8 \pm 3.2$  Disk Areas. The mean greatest linear dimension (GLD) of CNV lesions was  $3.9 \pm 1.7$  mm, whereas the mean GLD of CNV leakage was  $3.5 \pm 1.6$  mm. The total volume of the neurosensory retina, measured using OCTOR, was  $7.35 \pm 0.65$   $\text{mm}^3$  for the entire cohort at baseline. The total volume of



**Fig. 1.** Optical coherence tomography B-scans (each at 90°) from a subject demonstrating initial anatomic improvements, with subsequent regression and associated decline in visual acuity. Baseline, Patient is newly diagnosed with neovascular age-related macular degeneration. Visual acuity is 20/40 and the patient is treated with intravitreal ranibizumab. Month 1, Treatment with ranibizumab leads to a significant reduction in total retinal volume. Visual acuity is 20/30, and patient is observed. Month 3, Regression of anatomic changes is clearly evident. Visual acuity is 20/80 and the patient is treated with a second intravitreal injection of ranibizumab. Month 6, Total retinal volume remains elevated. Visual acuity is 20/100, and patient receives third injection of ranibizumab.



subretinal fluid at baseline was  $0.34 \pm 0.58 \text{ mm}^3$ , whereas that of subretinal tissue was  $0.29 \pm 0.49 \text{ mm}^3$ . The total volume of PED was  $1.04 \pm 1.79 \text{ mm}^3$  for the entire cohort at baseline. The total volumes of subretinal fluid, PED, and subretinal tissue, at baseline and at each follow-up, are summarized in Table 1.

*Morphologic Outcomes—Baseline to Month 1*

Forty-two patients (84%) showed a reduction in total retinal volume 1 month after their initial treatment with ranibizumab—“Initial Responders.” Eight patients (16%) showed an increase in total retinal

volume at Month 1, despite treatment with intravitreal ranibizumab—“Initial Non-Responders” (Figure 2). Patients who demonstrated an initial anatomic response had a greater total retinal volume at baseline than those who failed to respond ( $7.45 \pm 0.61 \text{ mm}^3$  versus  $6.84 \pm 0.68 \text{ mm}^3$ ,  $P = 0.035$ ).

No statistically significant difference was found between “Initial Responders” and “Initial Non-Responders” in terms of age ( $P = 0.781$ ), baseline visual acuity ( $P = 0.115$ ), previous treatment for neovascular AMD ( $P = 0.277$ ), total CNV lesion area ( $P = 0.914$ ), total CNV leakage area ( $P = 0.541$ ), GLD of

Table 1. Additional Morphologic Outcomes Derived From "OCTOR" Analysis (Mean  $\pm$  Standard Deviation)

	Total (n = 50)	Sustained Responders (n = 16)	Regressors (n = 26)	P*
Subretinal fluid				
Baseline—total vol. (mm <sup>3</sup> )	0.36 $\pm$ 0.60	0.39 $\pm$ 0.71	0.34 $\pm$ 0.53	0.506
Month 1—total vol. (mm <sup>3</sup> )	0.09 $\pm$ 0.26	0.10 $\pm$ 0.21	0.09 $\pm$ 0.29	0.202
Month 3—total vol. (mm <sup>3</sup> )	0.11 $\pm$ 0.24	0.16 $\pm$ 0.32	0.08 $\pm$ 0.15	0.956
Month 6—total vol. (mm <sup>3</sup> )	0.09 $\pm$ 0.21	0.06 $\pm$ 0.16	0.12 $\pm$ 0.24	0.171
Pigment epithelium detachment				
Baseline—total vol. (mm <sup>3</sup> )	1.01 $\pm$ 1.76	0.52 $\pm$ 0.42	1.31 $\pm$ 2.17	0.490
Month 1—total vol. (mm <sup>3</sup> )	0.73 $\pm$ 1.51	0.61 $\pm$ 1.26	0.80 $\pm$ 1.67	0.804
Month 3—total vol. (mm <sup>3</sup> )	0.66 $\pm$ 1.02	0.93 $\pm$ 1.40	0.48 $\pm$ 0.67	0.546
Month 6—total vol. (mm <sup>3</sup> )	0.52 $\pm$ 0.79	0.52 $\pm$ 0.88	0.52 $\pm$ 0.75	0.659
Subretinal tissue				
Baseline—total vol. (mm <sup>3</sup> )	0.30 $\pm$ 0.52	0.43 $\pm$ 0.78	0.23 $\pm$ 0.25	0.141
Month 1—total vol. (mm <sup>3</sup> )	0.23 $\pm$ 0.34	0.21 $\pm$ 0.39	0.24 $\pm$ 0.31	0.310
Month 3—total vol. (mm <sup>3</sup> )	0.24 $\pm$ 0.40	0.26 $\pm$ 0.45	0.22 $\pm$ 0.37	0.671
Month 6—total vol. (mm <sup>3</sup> )	0.25 $\pm$ 0.33	0.21 $\pm$ 0.29	0.27 $\pm$ 0.35	0.611

\*Ranksum test.

lesion ( $P = 0.524$ ), GLD of leakage ( $P = 0.541$ ), or angiographic classification of CNV at baseline ( $P = 0.312$ ). Additional analysis with OCTOR software found no statistically significant difference between the groups in terms of baseline subretinal fluid volume ( $P = 0.665$ ), subretinal tissue volume ( $P = 0.207$ ), or PED volume ( $P = 0.761$ ).

#### Morphologic Outcomes—Month 1 to Month 6

Of the patients who initially responded, 16 (38%) maintained or had further reduction through to the final examination at Month 6—"Sustained Responders" (Figure 3). Of the 42 patients who initially showed a reduction in total retinal volume by Month 1,

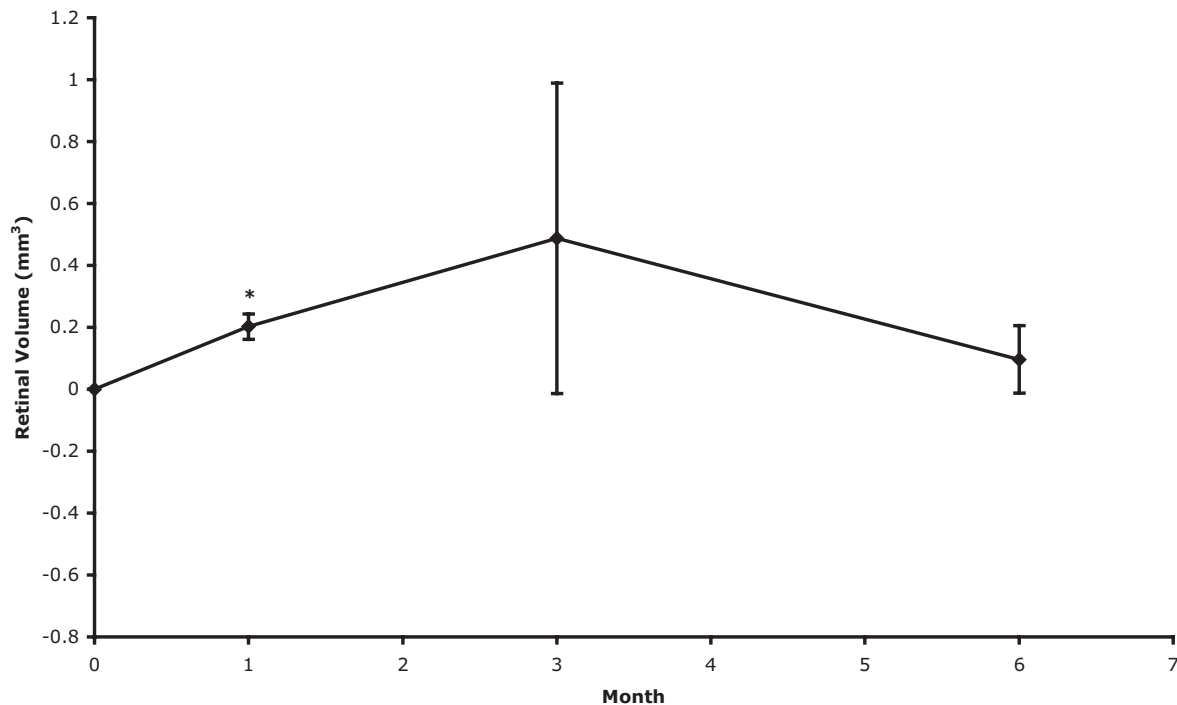


Fig. 2. Mean change from baseline in total volume of neurosensory retina—patients who failed to respond anatomically to initial treatment with intravitreal ranibizumab ("Initial Non-Responders"). Vertical lines, 1 standard error of the mean. \* $P < 0.05$ .

# Explore Litigation Insights

Docket Alarm provides insights to develop a more informed litigation strategy and the peace of mind of knowing you're on top of things.

## Real-Time Litigation Alerts



Keep your litigation team up-to-date with **real-time alerts** and advanced team management tools built for the enterprise, all while greatly reducing PACER spend.

Our comprehensive service means we can handle Federal, State, and Administrative courts across the country.

## Advanced Docket Research



With over 230 million records, Docket Alarm's cloud-native docket research platform finds what other services can't. Coverage includes Federal, State, plus PTAB, TTAB, ITC and NLRB decisions, all in one place.

Identify arguments that have been successful in the past with full text, pinpoint searching. Link to case law cited within any court document via Fastcase.

## Analytics At Your Fingertips



Learn what happened the last time a particular judge, opposing counsel or company faced cases similar to yours.

Advanced out-of-the-box PTAB and TTAB analytics are always at your fingertips.

## API

Docket Alarm offers a powerful API (application programming interface) to developers that want to integrate case filings into their apps.

## LAW FIRMS

Build custom dashboards for your attorneys and clients with live data direct from the court.

Automate many repetitive legal tasks like conflict checks, document management, and marketing.

## FINANCIAL INSTITUTIONS

Litigation and bankruptcy checks for companies and debtors.

## E-DISCOVERY AND LEGAL VENDORS

Sync your system to PACER to automate legal marketing.