

# A Variable-dosing Regimen with Intravitreal Ranibizumab for Neovascular Age-related Macular Degeneration: Year 2 of the PrONTO Study

GEETA A. LALWANI, PHILIP J. ROSENFELD, ANNE E. FUNG, SANDER R. DUBOVY, STEPHEN MICHELS, WILLIAM FEUER, JANET L. DAVIS, HARRY W. FLYNN, JR, AND MARIA ESQUIABRO

• **PURPOSE:** To assess the long-term efficacy of a variable-dosing regimen with ranibizumab in the Prospective Optical Coherence Tomography (OCT) Imaging of Patients with Neovascular Age-Related Macular Degeneration (AMD) Treated with intraOcular Ranibizumab (PrONTO) Study, patients were followed for 2 years.

• **DESIGN:** A 2-year prospective, uncontrolled, variable-dosing regimen with intravitreal ranibizumab based on OCT.

• **METHODS:** In this open-label, prospective, single-center, uncontrolled clinical study, AMD patients with neovascularization involving the central fovea and a central retinal thickness (CRT) of at least 300  $\mu\text{m}$  as measured by OCT were enrolled to receive 3 consecutive monthly intravitreal injections of ranibizumab (0.5 mg) [Lucentis; Genentech Inc, South San Francisco, California, USA]. During the first year, retreatment with ranibizumab was performed at each monthly visit if any criterion was fulfilled such as an increase in OCT-CRT of at least 100  $\mu\text{m}$  or a loss of 5 letters or more. During the second year, the retreatment criteria were amended to include retreatment if any qualitative increase in the amount of fluid was detected using OCT.

• **RESULTS:** Forty patients were enrolled and 37 completed the 2-year study. At month 24, the mean visual acuity (VA) improved by 11.1 letters ( $P < .001$ ) and the OCT-CRT decreased by 212  $\mu\text{m}$  ( $P < .001$ ). VA improved by 15 letters or more in 43% of patients. These VA and OCT outcomes were achieved with an average of 9.9 injections over 24 months.

• **CONCLUSIONS:** The PrONTO Study using an OCT-guided variable-dosing regimen with intravitreal ranibizumab resulted in VA outcomes comparable with the outcomes from the phase III clinical studies, but fewer

intravitreal injections were required. (Am J Ophthalmol 2009;148:43–58. © 2009 by Elsevier Inc. All rights reserved.)

**I**NHIBITION OF VASCULAR ENDOTHELIAL GROWTH FACTOR A (VEGF-A) is an effective and safe therapy for the treatment of neovascular age-related macular degeneration (AMD).<sup>1–6</sup> Intravitreal injections of ranibizumab (Lucentis; Genentech Inc, South San Francisco, California, USA), a recombinant, humanized, monoclonal antibody antigen-binding fragment that inhibits all the known biologically active forms of VEGF, were shown to improve mean visual acuity (VA) in eyes with neovascular AMD during the phase III clinical studies. In these studies, monthly ranibizumab injections over the course of 2 years were administered to eyes with minimally classic, occult, and predominantly classic neovascular lesions. On average, the VA letter scores improved and the outcomes were highly statistically significant.

While the phase III trials used monthly injections, it is unclear at this time if monthly dosing is the best dosing interval. Observations made after the earlier phase I/II studies with intravitreal ranibizumab suggested a role for optical coherence tomography (OCT) in determining the appropriate dosing interval for each patient. These observations came about at the completion of the phase I/II studies when subjects were enrolled in an open-label extension study that provided continued intravitreal injections of ranibizumab performed at the discretion of the investigator (Heier JS, et al. IOVS 2005;46:ARVO E-Abstract 1393). Some subjects enrolled in the extension study immediately on completion of the phase I/II trials, whereas others were delayed in their enrollment for up to 1 year after the completion of the phase I/II trials. During this period before enrollment and throughout the extension study, OCT was used to monitor the resolution and recurrence of fluid in eyes as ranibizumab therapy was started and stopped (Rosenfeld PJ, unpublished data, 2003). Patients in the extension trial usually were treated if there was evidence of recurrent leakage from choroidal neovascularization (CNV) as detected using fluorescein angiography (FA) or if there was recurrent fluid as detected using OCT imaging. This recurrence of leakage or fluid in the macula was observed either in the presence or absence

See accompanying Editorial on page 1.  
Accepted for publication Jan 27, 2009.

From the Bascom Palmer Eye Institute, University of Miami Miller School of Medicine, Miami, Florida.

Anne Fung is currently at the Pacific Eye Associates, California Pacific Medical Center, San Francisco, California. Stephen Michels is currently at the Department of Ophthalmology, University Hospital Zürich, Zürich, Switzerland.

Inquiries to Philip J. Rosenfeld, Bascom Palmer Eye Institute, University of Miami Miller School of Medicine, 900 NW 17th Street, Miami, FL 33136; e-mail: prosenfeld@med.miami.edu

0002-9394/09/\$36.00  
doi:10.1016/j.ajo.2009.01.024

© 2009 BY ELSEVIER INC. ALL RIGHTS RESERVED.

43

Mylan Exhibit 1035

**TABLE 1.** Major Eligibility Criteria for Enrollment into the PrONTO Study

<b>Inclusion criteria</b>
Age 50 years or older
Active primary or recurrent macular neovascularization secondary to AMD involving the central fovea in the study eye with evidence of disease progression
OCT central retinal thickness $\geq 300 \mu\text{m}$
Best-corrected visual acuity, using ETDRS charts, of 20/40 to 20/400 (Snellen equivalent) in the study eye
<b>Exclusion criteria</b>
More than 3 prior treatments with verteporfin photodynamic therapy
Previous participation in a clinical trial (for either eye) involving antiangiogenic drugs (pegaptanib, ranibizumab, anecortave acetate, protein kinase C inhibitors)
Previous subfoveal focal laser photocoagulation in the study eye
Laser photocoagulation (juxtafoveal or extrafoveal) in the study eye within 1 month preceding day 0
Subfoveal fibrosis or atrophy in the study eye
History of vitrectomy surgery in the study eye
Aphakia or absence of the posterior capsule in the study eye
History of idiopathic or autoimmune-associated uveitis in either eye

AMD = age-related macular degeneration; ETDRS = Early Treatment Diabetic Retinopathy Study; OCT= optical coherence tomography; PrONTO = Prospective OCT Imaging of Patients with Neovascular AMD Treated with intraOcular Ranibizumab.

of vision loss. It became apparent that the need for retreatment varied widely among the patients and that the need for retreatment was unpredictable. In addition, it was observed that OCT seemed to detect the earliest signs of reaccumulating fluid in the macula even before leakage could be detected reliably using FA.

These observations from the patients in the extension study served as the basis for investigating whether a variable-dosing OCT-guided regimen with ranibizumab could result in fewer injections and similar clinical outcomes when compared with the phase III regimen that used monthly injections. An investigator-sponsored, open-label, prospective clinical study was designed, known as the Prospective OCT Imaging of Patients with Neovascular AMD Treated with intraOcular Ranibizumab (PrONTO) Study. The 1-year results have been published,<sup>7</sup> and this article represents the full 2-year results of the PrONTO Study at the Bascom Palmer Eye Institute.

## METHODS

PrONTO WAS A 2-YEAR, OPEN-LABEL, PROSPECTIVE, SINGLE-center clinical study designed to investigate the efficacy,

**TABLE 2.** Timing of the Qualitative Change Retreatment Amendment in Year 2 (n = 39) of the PrONTO Study

First Visit When Amendment Active	No. of Patients
Month 17	5
Month 18	5
Month 19	3
Month 21	4
Month 22	4
Month 23	8
Month 24	5
Withdrew from study before amendment	1
Completed study before amendment	5
Total no. in study	40

PrONTO = Prospective Optical Coherence Tomography Imaging of Patients with Neovascular Age- Related Macular Degeneration Treated with intraOcular Ranibizumab.

durability, and safety of a variable-dosing regimen with intravitreal ranibizumab in patients with neovascular AMD. The PrONTO Study was an investigator-sponsored trial supported by Genentech Inc and performed after review by the Food and Drug Administration (FDA). Informed consent was obtained from all patients before determination of full eligibility.

The major efficacy endpoints were the change from baseline in VA and OCT measurements and the number of ranibizumab injections (0.5 mg) required over 2 years. At the start of the study, only 1 eye of a patient was determined to be eligible and was assigned as the study eye. The major eligibility criteria are shown in Table 1. The major inclusion criteria were the diagnosis of neovascular AMD with a baseline protocol VA letter score of 20 to 70 letters using the Early Treatment Diabetic Retinopathy Study (ETDRS) chart at 2 m (Snellen equivalent of 20/40 to 20/400)<sup>8</sup> and an OCT central retinal thickness (CRT) of at least 300  $\mu\text{m}$ . There were no exclusion criteria for preexisting cardiovascular, cerebrovascular, or peripheral vascular conditions. Of note, all FA lesion types and lesion sizes were eligible for the study.

Specifications for the digital fundus photography equipment and OCT equipment were described in the PrONTO year 1 report.<sup>7</sup> Angiographic lesion classification, including the diagnosis of retinal angiomatosis proliferation (RAP), was independently assessed and was confirmed by 3 study investigators as previously described.<sup>7</sup> All 6 high-resolution (512 A scans per B-scan) OCT diagonal scans were used to evaluate whether fluid was present in the macula and whether retreatment was needed. For the purposes of this study, fluid in the macula was identified as intraretinal fluid (cysts) or subretinal fluid, and a fluid-free macula was defined by the absence of retinal cysts and subretinal fluid as determined by OCT. Fluid under the retinal pigment epithelium (RPE), otherwise known as a pigment epithelial detachment (PED), was recorded as an

**TABLE 3.** Visual Acuity of Eyes with Neovascular Age-Related Macular Degeneration Treated with a Variable-Dosing Regimen of Ranibizumab through 24 Months

Study Eyes	Baseline VA Letters (Snellen Equivalent), n = 40	Month 12 VA Letters (Snellen Equivalent), n = 40	Month 24 VA Letters (Snellen Equivalent), n = 37	Change in VA Letter Scores from Baseline to Month 24, <sup>a</sup> n = 37
Mean (P value) <sup>b</sup>	56.2 (20/80 + 1)	65.5 (20/50; P < .001)	67.0 (20/50 + 1; P < .001)	11.1 (P < .001)
Median (P value) <sup>c</sup>	57 (20/80 + 2)	68 (20/40 - 2; P < .001)	68.0 (20/40 - 2; P < .001)	14.0 (P < .001)

VA = visual acuity.

<sup>a</sup>Change in letter scores compares the 37 patients who completed the study at month 24 with their baseline scores.

<sup>b</sup>Paired Student *t* test.

<sup>c</sup>Paired Wilcoxon signed-rank test.

**TABLE 4.** Central Retinal Thickness of Eyes with Neovascular Age-Related Macular Degeneration Treated with a Variable-Dosing Regimen of Ranibizumab through Month 24

Patient Study Eyes	Baseline CRT (μm), n = 40	Month 12 CRT (μm), n = 40	Month 24 CRT (μm), n = 37	Change in CRT (μm) from Baseline to Month 24, <sup>a</sup> n = 37
Mean (P value) <sup>b</sup>	393.9	216.1 (P < .001)	179.3 (P < .001)	-211.7
Median (P value) <sup>c</sup>	384.5	199.0 (P < .001)	171 (P < 0.001)	-209.0

CRT = central retinal thickness.

<sup>a</sup>Change in letter scores compares the 37 patients who completed the study at month 24 with their baseline scores.

<sup>b</sup>Paired Student *t* test.

<sup>c</sup>Paired Wilcoxon signed-rank test.

OCT finding in the macula, but was not included in any of the retreatment criteria during the first year.

Eligible patients underwent VA testing and ophthalmoscopic examination at baseline, days 14, 30, 45, and 60, and then monthly thereafter. Fundus photography and OCT imaging were performed at baseline and on days 1, 2, 4, 7, 14, and 30 after the first 2 injections, and then monthly thereafter. FA was performed at baseline, months 1, 2, and 3, and then every 3 months thereafter. All ophthalmic photographers and the single OCT technician involved in the study were previously certified to participate in FDA-approved clinical trials at the Bascom Palmer Eye Institute.

Intravitreal injections of ranibizumab were administered to all patients at baseline, month 1, and month 2. Additional reinjections were given if any of the following changes were observed by the evaluating physician during the first year of the study: 1) VA loss of at least 5 letters with OCT evidence of fluid in the macula, 2) an increase in OCT CRT of at least 100 μm, 3) new macular hemorrhage, 4) new area of classic CNV, or 5) evidence of persistent fluid on OCT 1 month after the previous injection. All criteria were based on comparisons with the previous month's examination or the last time a FA was performed. If any single criterion for reinjection was fulfilled, the intravitreal injection was performed using a standard protocol previously described.<sup>7</sup>

During the second year, an amendment to the study changed the retreatment criteria to include any qualitative change in the appearance of the OCT images that suggested recurrent fluid in the macula. These qualitative changes included the appearance of retinal cysts or subretinal fluid or an enlargement of a PED. Any of these qualitative changes alone was sufficient to permit retreatment. Since this amendment was approved after completion of the first year, the retreatment criteria were applied to patients at different time points in the study. Table 2 shows when the retreatment amendment was applied to the patients during the study. It is important to note that the amendment was in addition to the initial criteria, not in place of them.

At the completion of the study, an audit of drug shipments revealed that the vials in the first drug shipment received from Genentech Inc had a concentration of 6 mg/ml, equivalent to a dose of 0.3 mg in a volume of 0.05 ml. It was concluded that this lower dose, which was being used concurrently in the phase II and III clinical studies, mistakenly was shipped for use in the PrONTO Study. For this reason, the first 19 patients received some 0.3-mg doses rather than the per-protocol dose of 0.5 mg. The first 7 patients received 3 monthly 0.3-mg doses, the next 7 patients received 2 monthly 0.3-mg doses, and the next 5 patients received one 0.3-mg dose at baseline. All subse-

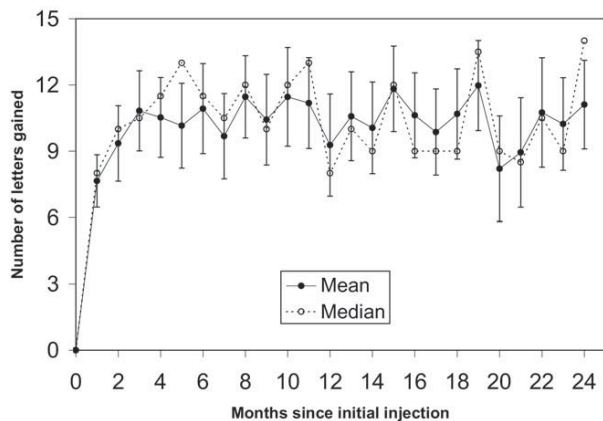


FIGURE 1. Graph showing the mean and median change in visual acuity (VA) through 24 months of eyes with neovascular age-related macular degeneration (AMD) treated with a variable-dosing intravitreal ranibizumab regimen. Vertical lines are 1 standard error (SE) of the means.

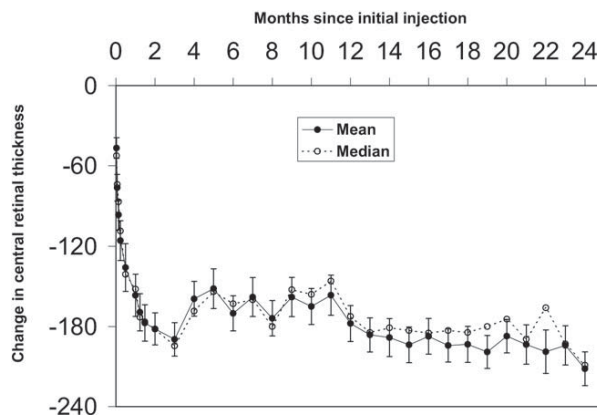


FIGURE 2. Graph showing the mean and median change in optical coherence tomography (OCT) central retinal thickness (CRT) through 24 months of eyes with neovascular AMD treated with a variable-dosing intravitreal ranibizumab regimen. Vertical lines are 1 SE of the means.

quent drug shipments and doses of drug were at the per-protocol concentration of 10 mg/ml, resulting in an intravitreal dose of 0.5 mg in 0.05 ml.

The major 2-year outcome measurements in the PrONTO Study included ETDRS VA letter scores, OCT CRT measurements, the change in VA letter scores and OCT measurements from baseline, and the total number of injections received by a patient during 2 years. For purposes of analysis, a loss of VA was defined as a drop of at least 5 letters between baseline and the 24-month time point. For the mean VA letter scores and CRT measurements, the data were compared statistically with mean baseline values using the paired Student *t* test. Median measurements were compared with median baseline values using the paired Wilcoxon signed-rank test. The influence of baseline FA lesion types on the number of injections over 24 months was assessed using a one-way analysis of variance and the Kruskal-Wallis test. The associations between the number of injections and VA outcomes and the associations between the change in CRT and VA outcomes at different time points during the study were assessed using the Pearson correlation analysis and Spearman nonparametric correlation analysis. Statistical significance was defined as  $P < .05$ .

## RESULTS

• **STUDY COMPLIANCE:** Patient demographics and enrollment at baseline were described previously.<sup>7</sup> Between August 23, 2004 and April 25, 2005, a total of 69 patients were screened for the study and 40 patients were enrolled. At baseline, the mean and median VA letter scores were 56 ( $20/80^{+1}$ ) and 57 ( $20/80^{+2}$ ), respectively (Table 3). Baseline mean and median OCT 1-mm CRT measure-

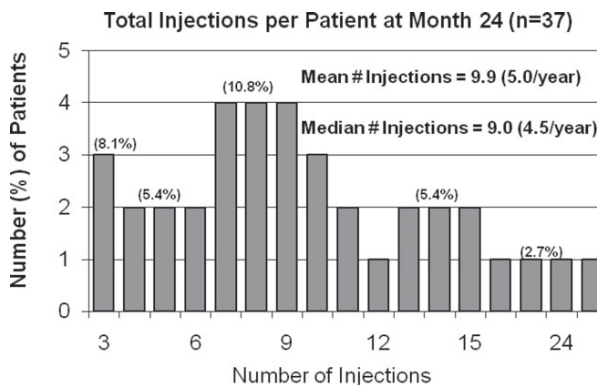


FIGURE 3. Bar graph showing the distribution of patients receiving a given number of ranibizumab injections through 24 months according to the retreatment criteria used in the Prospective OCT Imaging of Patients with Neovascular AMD Treated with intraOcular Ranibizumab (PrONTO) Study.

ments were 394 and 385  $\mu\text{m}$ , respectively (Table 4). The characteristics of the neovascular lesions were described previously. Of note, the study included occult with no classic lesions (10 eyes; 25%), minimally classic lesions (23 eyes; 57.5%), and predominantly classic lesions (7 eyes; 17.5%) as characterized by FA. Overall, 10 (25%) of the 40 lesions were categorized as RAP lesions.

During the second year, 3 patients withdrew from the study. One patient developed a tear of the RPE with a submacular hemorrhage and experienced a VA loss of 36 letters.<sup>3</sup> Submacular surgery was performed for removal of the hemorrhage and the patient withdrew from the study. The second patient was unable to travel attributable to complications after hip surgery and withdrew at month 20. The third patient died of Creutzfeldt-Jakob disease at

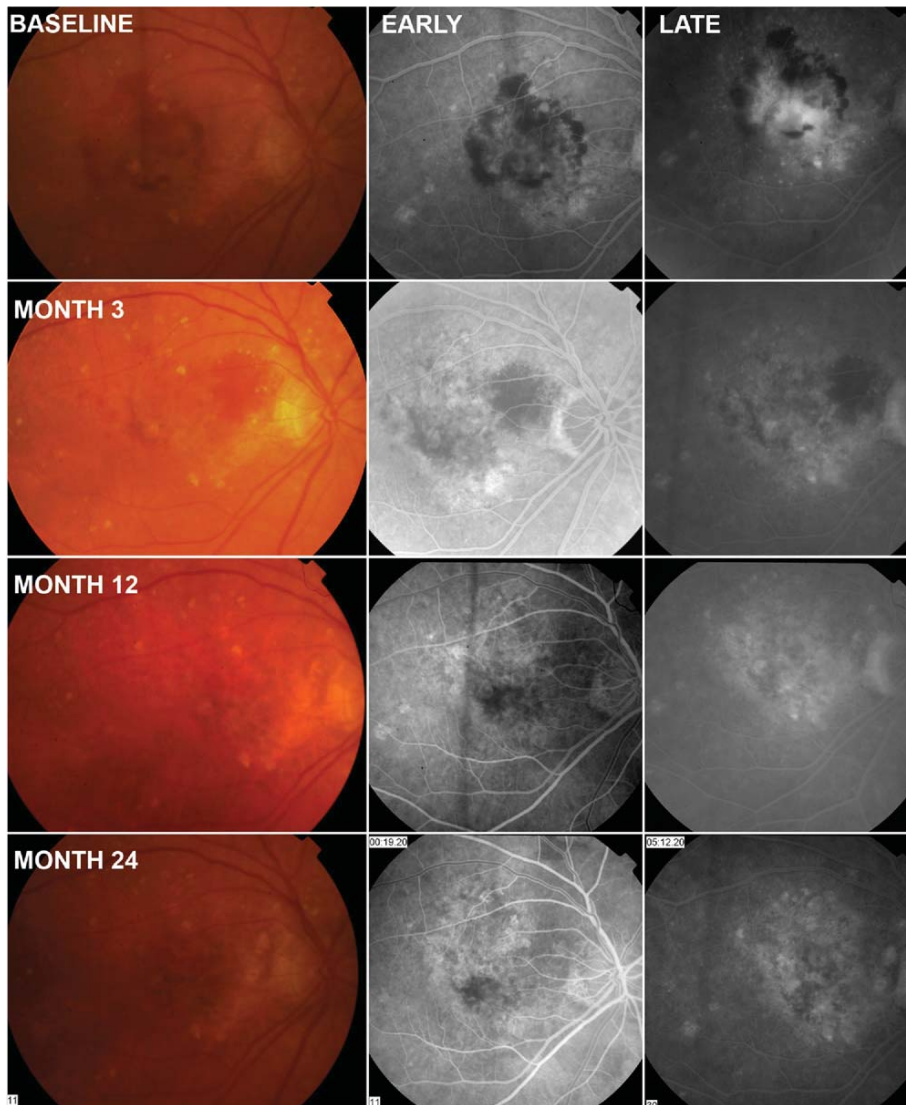


FIGURE 4. Case 1: A 74-year-old woman with neovascular AMD diagnosed with a minimally classic lesion in her right eye. She received only the first 3 required ranibizumab injections and then was followed up for 24 months. Color fundus images with early- and late-phase fluorescein angiographic (FA) images are shown at baseline, month 3 (1 month after the third injection), month 12, and month 24 without any additional injections of ranibizumab.

month 18. This death was not thought to be attributable to ranibizumab and the death was not deemed to be a drug-related adverse event. Data were analyzed from patients who completed the study (observed data set) as well from all the patients who were enrolled in the study by carrying forward their last obtained VA and OCT data before their withdrawal (last observation carried forward data set).

• **VISUAL ACUITY AND OPTICAL COHERENCE TOMOGRAPHY THROUGH 24 MONTHS:** The 1-year results of the PrONTO Study were reported previously.<sup>7</sup> Noteworthy outcomes included an improvement in VA detectable by

day 14 and increases in mean and median VA scores at month 3 of 10.8 letters ( $P < .001$ ) and 10.5 letters ( $P < .001$ ), respectively, after the first 3 monthly injections of ranibizumab. At month 12, the improvements in mean and median VA scores compared with baseline were 9.3 letters ( $P < .001$ ) and 11 letters ( $P < .001$ ), respectively (Table 3; Figure 1).

At month 24, the observed final mean and median VA scores for the remaining 37 patients compared with baseline improved by 11.1 letters (standard deviation [SD], 12.2; standard error, 2.0; 95% confidence interval [CI], 7.0 to 15.2;  $P < .001$ ) and 14 letters ( $P < .001$ ), respectively. Sixteen eyes (43%) gained at least 3 lines of vision (95% CI, 60% to

# Explore Litigation Insights

Docket Alarm provides insights to develop a more informed litigation strategy and the peace of mind of knowing you're on top of things.

## Real-Time Litigation Alerts



Keep your litigation team up-to-date with **real-time alerts** and advanced team management tools built for the enterprise, all while greatly reducing PACER spend.

Our comprehensive service means we can handle Federal, State, and Administrative courts across the country.

## Advanced Docket Research



With over 230 million records, Docket Alarm's cloud-native docket research platform finds what other services can't. Coverage includes Federal, State, plus PTAB, TTAB, ITC and NLRB decisions, all in one place.

Identify arguments that have been successful in the past with full text, pinpoint searching. Link to case law cited within any court document via Fastcase.

## Analytics At Your Fingertips



Learn what happened the last time a particular judge, opposing counsel or company faced cases similar to yours.

Advanced out-of-the-box PTAB and TTAB analytics are always at your fingertips.

## API

Docket Alarm offers a powerful API (application programming interface) to developers that want to integrate case filings into their apps.

## LAW FIRMS

Build custom dashboards for your attorneys and clients with live data direct from the court.

Automate many repetitive legal tasks like conflict checks, document management, and marketing.

## FINANCIAL INSTITUTIONS

Litigation and bankruptcy checks for companies and debtors.

## E-DISCOVERY AND LEGAL VENDORS

Sync your system to PACER to automate legal marketing.