

## CURRENT CONCEPTS IN THE MANAGEMENT OF DIABETIC MACULAR EDEMA\*

Ursula Schmidt-Erfurth, MD<sup>†</sup>

### ABSTRACT

Clinically, diabetic macular edema (DME) is characterized by retinal thickening and, with angiography, by pooled dye in edematous areas. For the patient, DME results in vision loss. To understand the current approaches to treating DME, it is helpful to understand the pathophysiologic changes that precipitate DME and the therapeutic mechanisms that target those changes. This article will focus on 3 pathophysiologic changes that are being targeted in treatment: vascular leakage into intraretinal layers, extravasation of plasma lipids, and ischemia-induced activation of cytokines (angiogenesis and inflammation). We now have several options for the treatment of DME: focal/grid laser photocoagulation, anti-vascular endothelial growth factor compounds, aflibercept, triamcinolone acetonide intravitreal injections, and steroid implants. All of these compounds show at least some benefit in DME. The challenge for clinicians is that none of the drugs is currently approved for use in DME, thus there are no formal recommendations for treatment regimens or changes to the current standard of care (focal/grid laser photocoagulation). (*Adv Stud Ophthalmol.* 2010;7(2):52-59)

For the patient, diabetic macular edema (DME) results in vision loss due to light scattering, impaired cell-to-cell interaction, and disturbances of normal ionic balances in the retina.<sup>1</sup> To understand the current treatment of DME, it is helpful to understand the pathophysiologic changes that underlie DME and the therapeutic mechanisms that target those changes.

### PATHOPHYSIOLOGIC CHANGES IN DME

A thorough review of DME pathophysiology is beyond the scope of this article, but current reviews are available.<sup>1</sup> This article will focus on the major pathophysiologic changes that are being targeted in treatment. In general, visual impairment with diabetes mellitus is most commonly due to DME, and DME causes vision loss through multiple mechanisms, including light scattering, impaired cell-to-cell interaction, and disturbances of normal ionic balances in the retina. Intraretinal fluid accumulates due to breakdown of the blood-retinal barrier (BRB), leading to extravasation of fluid into the intraretinal layers, which is rapidly reversible, and extravasation of plasma lipids from the intravascular lumen, which is less easily reversible. A recent study using optical coherence tomography (OCT) showed that hyperreflective foci found throughout the retinal layers represent extravasated lipoproteins and/or proteins. Confluent foci are seen as hard exudates clinically. Nonconfluent hyperreflective foci were detectable only by OCT; in general, their hyperreflectivity did not correspond with intraretinal hemorrhage nor the typical OCT findings seen with intraretinal aneurysms. As such, these foci may be a very early subclinical sign of BRB breakdown in DME.<sup>2</sup> During the progression of the disease, lipid foci migrate downwards and form confluent plaques.

\*Based on a presentation by Dr Schmidt-Erfurth at a roundtable symposium held in Fort Lauderdale, Florida, on April 30, 2010.

<sup>†</sup>Professor and Chair, Department of Ophthalmology, Medical University of Vienna, Vienna, Austria.

Address correspondence to: Ursula Schmidt-Erfurth, MD, Professor and Chair, Department of Ophthalmology, Medical University of Vienna, Waehringer Guertel 18-20, Vienna, Austria. E-mail: ursula.schmidterfurth@meduniwien.ac.at.

When lipid extravasation reaches the deep retinal layers—where photoreceptors reside—functional loss occurs. Comparing OCT as anatomical mapping and microperimetry as functional mapping, the relevant factors for visual function were giant cysts in the outer retinal layers at the fovea for serous detachment in the fovea and lipid exudates affecting the neurosensory layers in the fovea.<sup>3</sup>

On a biologic level, DME is considered to be a state of low-grade inflammation. As such numerous inflammatory cells, cytokines, factors, and processes are involved (Table).<sup>4</sup> Inflammatory cytokines are also known to interact with vascular endothelial growth factor (VEGF), which is a vascular permeability factor (with 50 000 times the potency of histamine).<sup>5</sup> VEGF causes vascular hyperpermeability by opening endothelial cell junctions and inducing fenestrations and vesiculo-vacuolar organelles. VEGF levels correlate with breakdown of the BRB.<sup>5,6</sup> VEGF levels are significantly elevated in eyes with exudative retinal disease, including those with DME, retinal vein occlusion, and choroidal neovascularization.<sup>4</sup>

**THERAPEUTIC MECHANISMS OF DME TREATMENTS**

The primary treatment target is to reduce retinal fluid and edema, which is measured by central retinal

thickness as seen on OCT. OCT is the preferred tool to measure therapeutic effects in clinical trials, but there is much debate regarding whether there is a direct relationship between this biomarker and visual acuity. The Diabetic Retinopathy Clinical Research (DRCR) Network studied this relationship in 1717 patients (2058 eyes) with DME.<sup>7</sup> The results showed a modest general correlation but not an interindividual association (0.52 at baseline and 0.44 3.5 months after laser treatment). However, the study did not address whether short-term changes on OCT are predictive of long-term visual acuity. Also, a wide range of visual acuity may be observed for a given degree of retinal edema, and the stage of disease and timing of an intervention varies widely. At this point, OCT therefore cannot be a surrogate end point for visual acuity in DME.

However, multiple changes in macular morphology are observed during the treatment of DME. When lipid exudates in the retina are examined, there is a typical pattern of therapeutic response after laser photocoagulation. In one study, during 4 months of follow-up after laser therapy, in addition to decreased retinal thickness, the hyperreflective foci either resolved completely or became confluent at the apical border of the outer nuclear layer. Upon further follow-up, clinically visible hard exudates formed. In areas of

**Table. Mean Concentrations (pg/mL) of Cytokines and Inflammatory Factors at Baseline in Patients with DME and Controls**

	CNV (n = 28)	Controls (n = 28)	P	RVO (n = 13)	Controls (n = 13)	P	DME (n = 10)	Controls (n = 10)	P
IL-1 $\alpha$				40.8	0	.09			
IL-6	53.8	22.4	NS	51.9	2.1	.01	46.5	5.3	.003
IL-8				63.9	1.8	.03	16.2	4.9	<.001
IP-10	367.1	299	NS	581.4	197.6	.01			
MCP-1	777.6	520.9	NS	1224.4	344.1	.003	1513.2	493.7	<.001
PDGF-AA	38	58.8	.04	63.4	39	.003			
VEGF	85.6	41.5	.03	513.3	38.2	.04	273.3	61.5	.001

Under detection limits: IL-1 $\beta$ , IL-2, IL-3, IL-4, IL-5, IL-10, IL-12(p40), IL-12(p70), IL-13, IL-15, Eotaxin, ICAM-1, IFN $\gamma$ , GM-CSF, RANTES, TNF- $\alpha$ , EGF, FGF-2, IL-7, MIP-1 $\alpha$ , Flt-3, PDGF- AB/BB

CNV = choroidal neovascularization; DME = diabetic macular edema; EGF = epidermal growth factor; FGF = fibroblast growth factor; Flt-3 = FMS-like tyrosine kinase 3; GM-CSF = granulocyte/macrophage colony stimulating factor; ICAM-1 = inter-cellular adhesion molecule 1; IFN = interferon; IL = interleukin; IP-10 = inducible protein-10; MCP-1 = monocyte chemotactic protein-1; MIP-1 $\alpha$  = macrophage inflammatory protein-1 $\alpha$ ; NS = not significant; PDGF = platelet-derived growth factor; RANTES = regulated upon activation, normal T cell expressed and secreted; RVO = retinal vein occlusion; TNF = tumor necrosis factor; VEGF = vascular endothelial growth factor.

Data from Funk et al.<sup>4</sup>

retinal thickening despite laser treatment, the hyperreflective foci maintained their distribution pattern throughout all retinal layers, and did not resolve. Thus, not only do hyperreflective foci seem to represent precursors or components of hard exudates, but retinal photocoagulation has a major impact on the density and distribution of intraretinal lipid deposits to obtain a therapeutic benefit.<sup>8</sup>

However, laser therapy also induces destructive changes in the retina. With high-resolution OCT during follow-up post laser treatment, marked focal damage to the outer retinal layers is observed, including the outer nuclear outer plexiform, the photoreceptor layers, and the retinal pigment epithelium. Thus, with laser therapy, there is a permanent destruction of photoreceptors and adjacent neurosensory elements. During the healing process over a few weeks, arcading scar formation throughout all retinal layers is observed, which leads to a decrease in retinal thickness due to atrophy, even if edema was not previously present. Thus, it is important to understand that laser therapy reduces retinal thickness, independent of fluid resolution. The same is true with laser therapy to the central retina in macular edema.<sup>8</sup> Due to subsequent atrophy of the retinal neurons following focal outer retinal thermonecrosis, shrinkage and atrophy show a radial pattern.

With anti-VEGF therapy, the process of macular fluid reduction and lipid migration proceeds much more rapidly than with laser,<sup>9</sup> which may explain why vision improvement with anti-VEGF therapy proceeds much faster than with laser therapy. VEGF has been a major target of DME treatment; however, in DME, VEGF therapy does not appear to affect other cytokines involved in the disease unlike in neovascular age-related macular edema (AMD). In a study involving monthly intravitreal injections with bevacizumab (Avastin; Genentech, Inc, South San Francisco, CA) in patients with DME, VEGF levels decreased to 0 by the first visit at 1 month and remained at those levels over 6 visits (ie, 6 months). Levels of other cytokines were either unaffected or mildly affected by anti-VEGF treatment, which explains the relatively slow and limited response of DME to anti-VEGF therapy compared to AMD.<sup>4</sup>

#### DME TREATMENTS

Although there are several approaches to treating

DME (ie, focal/grid laser photocoagulation, steroids, anti-VEGF compounds, or combination therapy), laser photocoagulation remains the “gold standard,” as long as drugs are not approved. However, such standard will change soon as the results of the RESTORE (Efficacy and Safety of Ranibizumab [Intravitreal Injections; Lucentis; Genentech, Inc, South San Francisco, CA] in Patients with Visual Impairment Due to DME) phase III study are already submitted to the authorities.

A common question regarding laser therapy is which approach to use. The DRCR Network, in a study of 263 subjects with DME, compared Early Treatment Diabetic Retinopathy Study (ETDRS; direct/grid or focal/grid) photocoagulation to mild macular grid (MMG) laser photocoagulation. After 12 months of follow-up, the MMG technique was less effective at reducing OCT-measured retinal thickening than the ETDRS focal/grid technique, but the visual acuity outcomes were not substantially different (change in visual acuity at 12 months: 0 letters, modified ETDRS group, -2 letters, MMG group,  $P = .10$ ).<sup>10</sup> Thus, it does not appear that the particular technique of laser therapy is as important as the application of laser therapy in general.

Steroids have an important role in DME management, particularly with reducing edema, but there are risks associated with their use that may not outweigh the benefits. The DRCR Network compared 2 doses of intravitreal triamcinolone acetonide injectable suspension (Trivaris; Allergan, Inc, Irvine, CA) to focal/grid laser photocoagulation in 840 eyes with DME. After 1 year of follow-up, there were no significant differences among the treatment groups in visual acuity, but by 2 years, the mean visual acuity was better in the laser therapy group compared to the 1-mg triamcinolone group and the 4-mg triamcinolone group. OCT results followed the same pattern. In addition, a 10-mm Hg increase in intraocular pressure (IOP) occurred much more frequently in those receiving triamcinolone (4% laser, 16% 1-mg triamcinolone, and 33% 4-mg triamcinolone) as did the need for cataract surgery (13%, 23%, and 51%, respectively).<sup>11</sup>

There are 2 anti-VEGF agents designed for treating DME, although none is yet US Food and Drug Administration (FDA) approved for DME. In the RESOLVE (Safety and Efficacy of Ranibizumab in DME with Center Involvement) study, a phase II study comparing 2 doses of ranibizumab to sham

injection (www.clinicaltrials.gov: NCT00284050), therapeutic benefit with ranibizumab was observed in terms of immediate (by month 1) and persistent reduced retinal thickening and improved visual acuity (mean of 8–10 ETDRS letters after 6 months, compared to -3 letters in those receiving sham). However, the study also showed that the improvement was not as rapid as that seen with ranibizumab treatment in patients with AMD.<sup>12</sup>

The DA VINCI (DME and VEGF Trap-Eye: INvestigation of Clinical Impact) study compared 4 different doses of aflibercept (VEGF Trap-Eye; Regeneron Pharmaceuticals, Inc, Tarrytown, NY)—a fusion protein of the key binding domains of the VEGF receptor-1 and -2 combined with a human immunoglobulin G Fc fragment—to laser therapy every 16 weeks as needed. Aflibercept blocks all isoforms of VEGF-A as well as placental growth factors-1 and -2.<sup>13</sup> Preliminary results after 24 weeks showed significant improvement in mean change in visual acuity (gain of 8–12 ETDRS letters) with several different dosing regimens, including bimonthly. The OCT results paralleled the visual acuity results.<sup>14</sup> The study will follow these patients for 52 weeks, and it will be interesting to see if the results suggest that the dosing frequency with anti-VEGF compounds can be reduced from monthly injections based on the results.

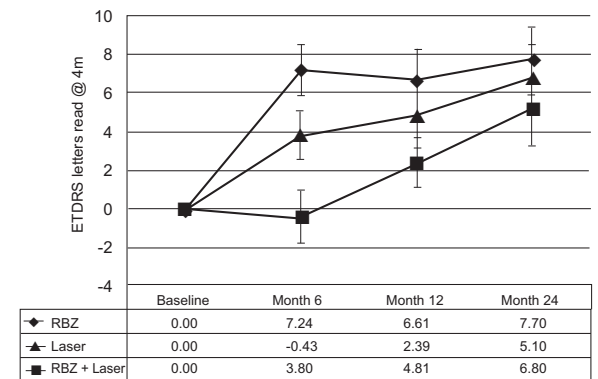
The READ-2 (Ranibizumab for Edema of the mAcula in Diabetes 2) study compared ranibizumab (0.5-mg ranibizumab at baseline and months 1, 3, and 5) with focal/grid laser (at baseline and month 3 if needed) or a combination of both (ranibizumab and focal/grid laser at baseline and month 3) in patients with DME. After 6 months, patients in both groups receiving ranibizumab gained, whereas those receiving laser therapy lost vision (Figure 1).<sup>15</sup> After 2 years, the 2 ranibizumab-receiving groups continued to fare better than those in the laser group, but the differences among groups were not as great as in the beginning (Figure 1).<sup>15,16</sup>

The RESTORE trial (phase III) is evaluating the efficacy and safety of ranibizumab (0.5 mg) as adjunctive therapy to laser photocoagulation and monotherapy in patients with visual impairment due to DME. The study primary outcome completion was January 2010.<sup>17</sup> Patients treated with ranibizumab, either as monotherapy or in combination with laser, experienced a rapid improvement that was sustained over the 12-month study period with a mean improvement of

6 letters. In contrast, laser-treated eyes did not improve in best corrected visual acuity (+0.8). Retinal edema resolved substantially and rapidly with anti-VEGF treatment, but little with laser therapy. Thirty-seven percent and 43% of patients in the ranibizumab groups improved by at least 2 lines compared to 15% in the laser arms and 22% versus 8% improved by at least 3 lines with ranibizumab. A mean of 7 treatments was required over 12 months. There was an equally good response in focal versus diffuse edema and patients pretreated or untreated with laser earlier. In general, eyes with more intensive edema responded better to therapy. Also, it was concluded that the results obtained with ranibizumab monotherapy were optimal and could not be improved with adjunct laser.

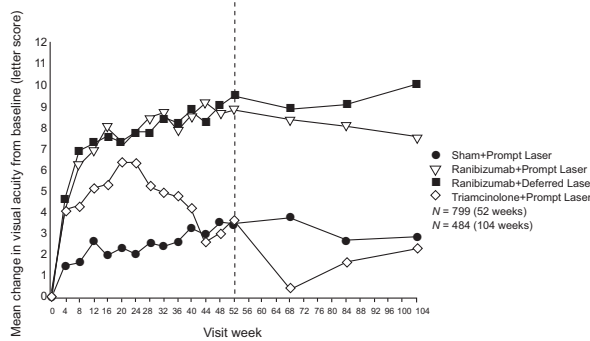
Finally, the DRCR Network compared intravitreal 0.5-mg ranibizumab or 4-mg triamcinolone acetonide injectable suspension combined with focal/grid laser to focal/grid laser alone for treatment of DME in 854 eyes. As expected, the clinical (Figure 2) and anatomic (Figure 3) benefit with both ranibizumab and triamcinolone was significant.<sup>18</sup> However, of particular interest is that the clinical benefit with triamcinolone seen

Figure 1. Ranibizumab vs Laser vs Combination, Mean Change in Visual Acuity from Baseline: Results from the READ-2 Study



At 6 months, the combination therapy group was not statistically different from the other 2 groups with regard to mean gain in best corrected visual acuity. ETDRS = Early Treatment Diabetic Retinopathy Study; RBZ = ranibizumab; READ-2 = Ranibizumab for Edema of the mAcula in Diabetes. Adapted with permission from Nguyen et al. *Ophthalmology*. 2010;117:2146-2151.<sup>15</sup>

**Figure 2. Ranibizumab + Laser or Triamcinolone + Laser, Mean Change in Visual Acuity: Results from the DRCR Network Protocol I Study**

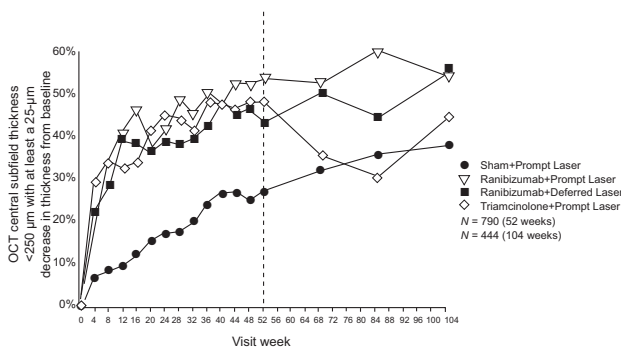


The 1-year and 2-year visit completion rates were 94% and 90%, respectively.

DRCR = Diabetic Retinopathy Clinical Research.

Reprinted with permission from Diabetic Retinopathy Clinical Research Network et al. *Ophthalmology*. 2010;117:1064-1077.<sup>18</sup>

**Figure 3. Ranibizumab + Laser or Triamcinolone + Laser, OCT Central Subfield Thickness <250 μm with at Least a 25-μm Decrease in Thickness from Baseline: Results from the DRCR Network Protocol I Study**



DRCR = Diabetic Retinopathy Clinical Research; OCT = optical coherence tomography.

Reprinted with permission from Diabetic Retinopathy Clinical Research Network et al. *Ophthalmology*. 2010;117:1064-1077.<sup>18</sup>

during the first 6 months of the study was lost during the last 6 months, and the anatomic benefit seen during the first year was lost during the second year of follow-up, suggesting a correlation between functional and anatomic changes with triamcinolone plus laser treatment, whereas, with ranibizumab + laser prompt and deferred there was a persistent decrease in central retinal thickness across the 2-year follow-up. In the subset of pseudophakic eyes at baseline ( $n = 273$ ), visual acuity improvement in the triamcinolone + prompt laser group appeared comparable to that in the ranibizumab groups. However, there were substantial safety issues with triamcinolone. An elevated IOP, which required treatment, occurred in approximately 27% of eyes and cataract surgery was required in approximately 50% of the phakic patients.<sup>18</sup>

**CONCLUSIONS**

There is a clear paradigm shift toward intravitreal drugs for the treatment of DME: anti-VEGF compounds (bevacizumab, ranibizumab), aflibercept, triamcinolone intravitreal injections, and steroid implants (dexamethasone, fluocinolone). All of these compounds show at least some benefit in DME. This article presents an overview of the current state of knowledge regarding treatment mechanisms and modalities under investigation for DME. None of the pharmacologic agents is currently approved by the FDA for the management of DME. Thus, the current

**Patient with DME with Poor Response to Panretinal Photocoagulation Treatment in the Left Eye – Harry W. Flynn, Jr, MD**

JM is a 60-year-old man with an 18-year history of non-insulin-dependent diabetes mellitus. He presents to the ophthalmologist with bilateral decreased vision: 20/60 OD (phakic) and 20/200 OS (pseudophakic). After laser photocoagulation was performed for the DME in the left eye, his vision remained poor at 20/200.

How would you treat his right eye? What are the best options when standard-of-care treatment fails? When is observation the best course? For further discussion of the challenges in managing this real-life situation, please go to [www.JHASIO.com/retinaldiseases](http://www.JHASIO.com/retinaldiseases).

# Explore Litigation Insights

Docket Alarm provides insights to develop a more informed litigation strategy and the peace of mind of knowing you're on top of things.

## Real-Time Litigation Alerts



Keep your litigation team up-to-date with **real-time alerts** and advanced team management tools built for the enterprise, all while greatly reducing PACER spend.

Our comprehensive service means we can handle Federal, State, and Administrative courts across the country.

## Advanced Docket Research



With over 230 million records, Docket Alarm's cloud-native docket research platform finds what other services can't. Coverage includes Federal, State, plus PTAB, TTAB, ITC and NLRB decisions, all in one place.

Identify arguments that have been successful in the past with full text, pinpoint searching. Link to case law cited within any court document via Fastcase.

## Analytics At Your Fingertips



Learn what happened the last time a particular judge, opposing counsel or company faced cases similar to yours.

Advanced out-of-the-box PTAB and TTAB analytics are always at your fingertips.

## API

Docket Alarm offers a powerful API (application programming interface) to developers that want to integrate case filings into their apps.

## LAW FIRMS

Build custom dashboards for your attorneys and clients with live data direct from the court.

Automate many repetitive legal tasks like conflict checks, document management, and marketing.

## FINANCIAL INSTITUTIONS

Litigation and bankruptcy checks for companies and debtors.

## E-DISCOVERY AND LEGAL VENDORS

Sync your system to PACER to automate legal marketing.