

# Anti-VEGF Agents in the Treatment of Neovascular Age-related Macular Degeneration: Applying Clinical Trial Results to the Treatment of Everyday Patients

DAVID M. BROWN AND CARL D. REGILLO

- **PURPOSE:** The vision gains reported with monthly intravitreal ranibizumab in the MARINA and ANCHOR trials led to an immediate paradigm shift in the treatment of neovascular AMD with retina physicians universally switching to the pan-VEGF blocking agents ranibizumab and bevacizumab, and patients expecting visual improvement. As these agents are primarily used on a pro re nata (PRN) dosing schedule (because neither patients nor physicians want monthly injections), the factors involved in making the treatment and retreatment decisions are very important in any attempt to maximize vision gain.
- **DESIGN:** Analysis of literature, ongoing clinical trials, and the clinical assessments that can aid clinicians in treatment and retreatment decisions.
- **METHODS:** Literature review and perspective.
- **RESULTS:** If a monthly injection protocol is not used, clinicians should use both functional and anatomic criteria to attempt to guide treatment and retreatment decisions. Qualitative optical coherence tomography (OCT) appears to be the most sensitive and practical assessment tool to determine anatomic response to treatment but should be used in conjunction with clinical examination.
- **CONCLUSIONS:** If monthly intravitreal injections are not performed, a combination of clinical examination (looking for new hemorrhage) and qualitative OCT (to assess response to treatment and early signs of recurrent leakage) can be used to guide anti-vascular endothelial growth factor (anti-VEGF), treatments with the goal of maintaining a “normal” retinal anatomy in an attempt to maximize the benefit (visual acuity gains) to risk (number of injections required) ratio. (*Am J Ophthalmol* 2007;144:627–637. © 2007 by Elsevier Inc. All rights reserved.)

**T**REATMENTS FOR NEOVASCULAR AGE-RELATED MACULAR degeneration (AMD) have improved dramatically since 1999 when the only treatment clinically available was Macular Photocoagulation Study (MPS)-style laser photocoagulation.<sup>1</sup> For subfoveal choroidal neovascularization (CNV), MPS guided laser photocoagulation leads to an

Accepted for publication Jun 20, 2007.

From the Vitreoretinal Consultants, Houston, Texas (D.M.B.); and the Wills Eye Institute, Philadelphia, Pennsylvania (C.D.R.).

Inquiries to David M. Brown, Vitreoretinal Consultants, Texas Medical Center Office, Scurlock Tower, 6560 Fannin, Suite 750, Houston, TX 77030; e-mail: dmbmd@houstonretina.com.

immediate, permanent loss of central vision with its aim to limit the spread of the uncontrollable disease analogous to surgical amputation in general surgery. Photodynamic therapy with verteporfin (vPDT) became available in 2000. Unlike laser photocoagulation, vPDT involves relatively selective photochemical damage to CNV, with less damage to the associated choroid and retina. vPDT decreased the rate of moderate and severe vision loss, demonstrated improved vision (a gain of  $\geq 15$  letters on the Early Treatment of Diabetic Retinopathy Study (ETDRS) chart in up to 6% of patients with subfoveal CNV secondary to AMD) (Table).<sup>2,3</sup> However, 30% to 40% of vPDT-treated patients still lost at least 15 letters from the pretreatment baseline visual acuity (VA). Furthermore, although PDT clinical trials showed consistent benefit when treating patients with subfoveal predominantly classic CNV, other CNV subtypes appeared to benefit only if the lesion was relatively small in size.<sup>2,3,7</sup> Combining vPDT treatment with intravitreal (ITV) injection of a corticosteroid was popularized by Spaide and associates.<sup>8</sup> This combination approach appeared to decrease the number of required vPDT treatments to achieve a nonleaking CNV, but has yet to demonstrate definitive, clinically significant, added visual benefit compared with vPDT alone.

## THE SEARCH FOR A MORE TARGETED TREATMENT

NEOVASCULAR AMD IS ASSOCIATED WITH INCREASED VASCULAR permeability as well as CNV infiltration. This increase in vascular permeability leads to abnormal fluid collection within or below the retina that causes visual dysfunction when it involves the center of the macula. For the past 50 years, researchers have attempted to determine the underlying mechanism of neovascularization and vascular leakage in the eye. In 1983, Senger and associates identified a “tumor vascular permeability factor” (VPF) that could induce vascular leakage.<sup>9</sup> In 1989, Ferrara and Henzel reported the isolation and sequencing of an endothelial cell mitogen dubbed vascular endothelial growth factor (VEGF),<sup>10</sup> which was later determined to be the same molecule as VPF. VEGF-A (also referred to as simply VEGF) is a vascular endothelial cell-specific growth factor

**TABLE.** Summary of Published Results for Several Neovascular Age-Related Macular Degeneration Studies Using 2-m Early Treatment of Diabetic Retinopathy Study Refracted Visual Acuities

| Study  | Study Design   | Study Arms | Efficacy Endpoints                          |                                |                                  |
|--|--|------------|---|--------------------------------|----------------------------------|
|  |  |            | Mean Change in letters of VA from Baseline* | ≥15 Letters Lost (% Patients)* | ≥15 Letters Gained (% Patients)* |
| TAP (12-month time point) <sup>2</sup>                       | PDT every 3 months for 24 months (n = 609)   | PDT        | -2.2  | 39*                            | 6                                |
|  |  | Placebo    | -3.5  | 54                             | 2                                |
| VISION (12-month time point) <sup>4</sup>                    | ITV pegaptanib every 6 weeks for 24 months (n = 1,186)                                       | 0.3 mg     | N/A   | 30*                            | 6                                |
|  |  | Sham       |   | 45                             | 2                                |
| MARINA (24-month time point) <sup>5</sup>                    | ITV ranibizumab monthly for 24 months (n = 716)  | 0.3 mg     | 5.4*  | 8*                             | 26*                              |
|  |  | 0.5 mg     | 6.6*  | 10*                            | 33*                              |
|  |  | Sham       | -14.9                                       | 47                             | 4                                |
| ANCHOR (12-month time point) <sup>6</sup>                    | ITV ranibizumab monthly for 24 months (n = 423)  | 0.3 mg     | 8.5*  | 6*                             | 36*                              |
|  |  | 0.5 mg     | 11.3*                                       | 4*                             | 40*                              |
| PIER (12-month time point) (Regillo et al, unpublished data) | ITV ranibizumab monthly for 3 months, then every 3 months for a total of 24 months (n = 184) | PDT        | -9.5  | 36                             | 6                                |
|  |  | 0.3 mg     | -1.6*                                       | 17*                            | 12                               |
|  |  | 0.5 mg     | -0.2*                                       | 10*                            | 13                               |
|  |  | Sham       | -16.3                                       | 51                             | 10                               |

ITV = intravitreal; N/A = not applicable (not directly reported in the article); PDT = photodynamic therapy; VA = visual acuity.  
\* $P \leq .001$  compared with the control arm.

and, within the VEGF family, is the most potent promoter of angiogenesis and inducer of vascular permeability.<sup>11</sup> In addition, VEGF-A is 50,000 times more potent as an enhancer of vascular permeability than is histamine.<sup>12</sup> VEGF-A has been shown to be involved in the development of ocular diseases such as neovascular AMD.<sup>13</sup>

The first ocular anti-VEGF agent was an aptomer-based therapeutic designed to target VEGF<sub>165</sub>, the most abundant isoform of VEGF-A in ocular disease. The VISION trials using this aptomer (Pegaptanib sodium, Macugen; OSI/Eyetech Pharmaceuticals, New York, New York, USA) demonstrated efficacy in all CNV subtypes secondary to AMD, and the number of pegaptanib-treated patients with all CNV subtypes who had 15-letter improvements was comparable to PDT-treated patients with predominantly classic CNV secondary to AMD in other studies (4% to 6%; Table).<sup>4</sup> The proportion of patients losing  $\geq 15$  letters from the pretreatment baseline VA, however, was still about 40% despite ITV pegaptanib injections every six weeks during the two-year trial. Nonetheless, because of the broad treatment effect with some visual benefit in all CNV subtypes secondary to AMD, along with the good safety profile, pegaptanib sodium was approved by the Food and Drug Administration in 2004 for the treatment of neovascular AMD.

Ranibizumab (Lucentis; Genentech, Inc, South San Francisco, California, USA) is an anti-VEGF agent that is Food and Drug Administration approved for the treatment of all subfoveal CNV subtypes secondary to AMD. Ranibi-

zumab is a humanized antigen-binding fragment that targets all VEGF-A isoforms and their biologically active degradation products, and it has been shown to bind and inhibit VEGF<sub>165</sub>, VEGF<sub>121</sub>, and VEGF<sub>110</sub>. Ranibizumab has been investigated in clinical trials in patients with neovascular AMD since 2000 (Table; Figure 1). MARINA was a randomized Phase III clinical trial of minimally classic or occult CNV secondary to AMD treated with monthly ITV ranibizumab (0.3 mg or 0.5 mg) or sham injections for 24 months. Anatomically, ranibizumab treatment was associated with arrested growth of and cessation of leakage from the CNV (including intense, progressive staining of the retinal pigment epithelium [RPE]). The mean change from baseline in each of the ranibizumab-treated groups differed significantly from the sham-injected group at 12 and 24 months ( $P < .001$ ). Mean retinal thickness on ocular coherence tomography (OCT) was reduced dramatically in the first week after initial treatment, and this reduction was associated with mean improvement in VA. With monthly injections, both the reduction in retinal thickness and the VA gains were maintained. At the end of the 24-month study, significantly more ranibizumab-treated patients had maintained or improved vision (lost  $< 15$  letters of VA) than sham-injected patients, with 92% and 90% of ranibizumab-treated patients (0.3 mg and 0.5 mg, respectively) losing fewer than 15 letters of VA, compared with 53% of sham-injected patients ( $P < .001$ ).<sup>5</sup> In addition, the mean change in VA from baseline was a gain of 5.4 and 6.6

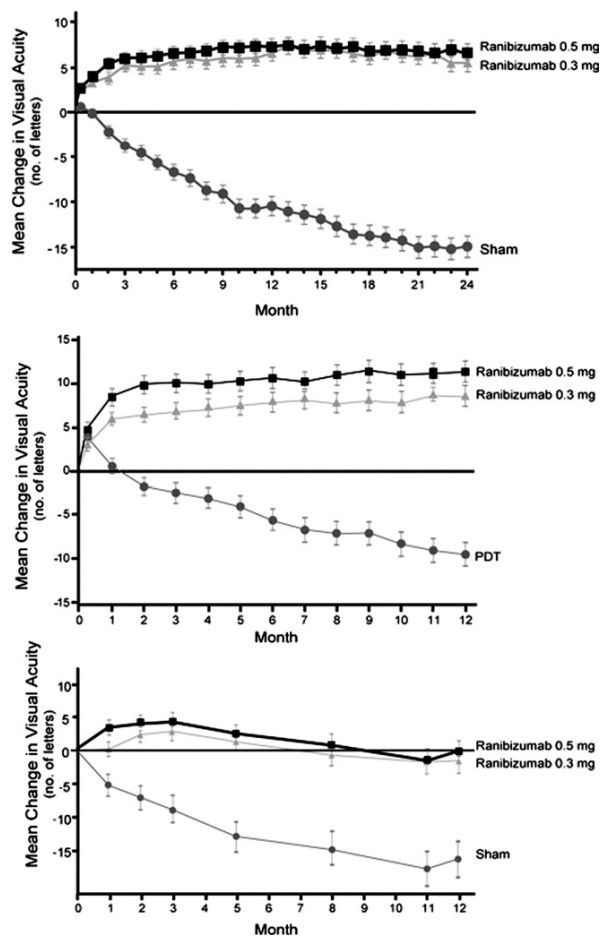


FIGURE 1. Visual acuity over time for the (Upper panel) MARINA, (Middle panel) ANCHOR, and (Lower panel) PIER Phase III trials. All three panels show the mean change from baseline in visual acuity [VA] (number of letters) over time (months). The black boxes represent the mean change in VA for the 0.5 mg ranibizumab group, the gray triangles represent the mean change in VA for the 0.3 mg group, and the gray circles represent the mean change in VA for the control group in each of the studies. Pairwise analysis of variance (ANOVA) adjusting for the VA score on day zero was used to analyze the mean change in VA from baseline at each monthly assessment. At each monthly assessment, there was a significant difference between the ranibizumab and control groups. (MARINA and ANCHOR panels are reproduced with permission from Rosenfeld and associates, *N Engl J Med* 2006;355:1419-1431 and Brown and associates, *N Engl J Med* 2006;355:1432-1444).

letters for ranibizumab-treated patients (0.3 mg and 0.5 mg, respectively), compared with a loss of 14.9 letters in sham-treated patients ( $P < .001$ ). After 24 months, 26% and 33% of ranibizumab-treated patients gained 15 or more letters of VA (0.3 and 0.5 mg, respectively), compared with 4% of sham-injected patients ( $P < .001$ ).<sup>5</sup>

ANCHOR was a randomized Phase III clinical trial of patients with predominantly classic CNV secondary to AMD treated with monthly ITV ranibizumab (0.3 mg or 0.5 mg) and sham PDT or sham injection and PDT for 24 months. Anatomically, fluorescein angiography (FA) at 12 months revealed a dramatic reduction of leakage from the CNV (and area of intense, progressive staining of the RPE) compared with baseline among ranibizumab-treated patients compared with an overall increase in leakage among PDT-treated patients ( $P < .01$ ). Analogous to the anatomic changes seen on OCT in the MARINA trial, retinal thickness was markedly reduced within a week of initial treatment, and this reduction was associated with commensurate gains in VA. Repeated injections maintained this anatomical improvement and allowed for unprecedented gains in VA at the primary endpoint at 12 months. At the 12-month time point, 94% and 96% of ranibizumab-treated patients (0.3 mg and 0.5 mg, respectively) had lost fewer than 15 letters of VA, compared with 64% of PDT-treated patients ( $P < .0001$ ).<sup>6</sup> In addition, the mean change in VA from baseline was a gain of 8.5 and 11.3 letters for ranibizumab-treated patients (0.3 mg and 0.5 mg, respectively), compared with a loss of 9.5 letters in PDT-treated patients ( $P < .001$ ).<sup>6</sup> After 12 months, 36% and 40% of ranibizumab-treated patients gained 15 or more letters of VA (0.3 and 0.5 mg, respectively), compared with 6% of PDT-treated patients ( $P < .001$ ).<sup>6</sup>

While ranibizumab is an anti-VEGF antibody fragment, bevacizumab is a related humanized, full-length anti-VEGF antibody that was also developed by Genentech. At the July 2005 American Society of Retina Specialists (ASRS) meeting in Montreal, Canada, Phillip Rosenfeld, MD, presented a small series of patients with neovascular AMD treated with off-label ITV bevacizumab (Food and Drug Administration approved for intravenous treatment of metastatic colon cancer in combination with chemotherapy). The preliminary results from this series demonstrated good short-term safety and efficacy similar to that seen in patients treated with ranibizumab.<sup>14</sup> Other investigators have since demonstrated comparable clinical results with larger but still short-term and uncontrolled series of patients with neovascular AMD treated with off-label ITV bevacizumab.<sup>15-17</sup> These reports resulted in a relatively quick and widespread adoption of off-label ITV bevacizumab by retina specialists before the clinical availability of ranibizumab. Bevacizumab use has continued around the world, and increasing pharmacokinetic, histopathology, and toxicity studies have subsequently been performed in RPE cell lines and bovine, rabbit, pig, and monkey models that demonstrate no evidence of ocular toxicity at the dose commonly administered.<sup>18-20</sup> Durability of effect of bevacizumab appears comparable to ranibizumab with apparent intravitreal concentrations up to one month after injection.<sup>21</sup> There are no data available to assess the relative efficacy and safety of off-label ITV bevacizumab but with support from the National Eye Institute, The

Comparison of Age-Related Macular Degeneration Treatments Trial (CATT) is being organized to determine the safety and efficacy of intravitreal bevacizumab compared with ranibizumab.<sup>22</sup> The trial will be a head-to-head, prospective, randomized, masked clinical trial of ranibizumab and off-label ITV bevacizumab in 1,200 patients. Monthly ranibizumab and bevacizumab injection regimens will be included as well as pro re nata (PRN) treatment regimens with both agents and is expected to begin this year. Direct comparisons of the efficacy and potential adverse events of off-label ITV bevacizumab and ranibizumab can only be made at the conclusion of such a head-to-head study.

### OCULAR RISKS AND POSSIBLE SYSTEMIC RISKS OF ANTI-VEGF THERAPY

THE OCULAR RISKS OF ANTI-VEGF INJECTIONS APPEAR TO be primarily related to the injection process itself. In the MARINA, ANCHOR, and PIER trials, ranibizumab treatment was associated with a 1.7% or lower rate of key serious ocular adverse events such as endophthalmitis, retinal detachment, and uveitis.<sup>5,6</sup> The theoretical risk exists that intraocular pan-VEGF suppression may cause choriocapillaris damage. However, these findings have not been collaborated by wide-field angiography looking for choriocapillaris damage in our patients who had more than 24 injections of ranibizumab (unpublished data). Because intravenous anti-VEGF blockade is known to be associated with increased rates of thromboembolic events, systemic absorption of these agents from intraocular injections may increase these rates in treated patients. In animal studies, ITV ranibizumab was cleared from the vitreous with a half-life of approximately three days.<sup>23</sup> After reaching a maximum at approximately one day, serum concentrations decline in parallel to vitreous concentrations with a systemic level <1000 times the vitreous concentrations. In human trials, serum ranibizumab levels ranged from 0.3 ng/ml to 2.36 ng/ml following monthly injections.<sup>24</sup> These levels were below the concentration of ranibizumab (11 ng/ml to 27 ng/ml) thought to be necessary to inhibit 50% of the biologic activity of VEGF-A. Systemic absorption of ITV bevacizumab has also been demonstrated in approximately 11.8% of patients (Csaky K, personal communication). This may be significant given bevacizumab's terminal half-life in the systemic circulation is approximately 20 days compared with 12 hours for ranibizumab. In the initial Phase III trials with ranibizumab, the actual key serious nonocular adverse events were not found to be significantly different than the corresponding control groups.<sup>5,6</sup> However, in January 2007, Genentech released data that showed in preliminary analysis of the SAILOR cohort (a Phase IIIb study with much larger sample size than the Phase III trials), that the 0.5 mg dose had a

significantly higher risk of stroke compared with the 0.3 mg dose (1.2% vs 0.3%;  $P = .02$ ).<sup>25</sup> Ongoing safety analysis is being performed in patients in the SAILOR trial as well as longer term follow-up in the HORIZON trial (the extension study of MARINA and ANCHOR). The CATT trial is also designed to provide systemic safety data for both ranibizumab and bevacizumab.

### ALTERNATIVE DOSING STRATEGIES FOR ANTI-VEGF AGENTS

BECAUSE OF BOTH OCULAR AND SYSTEMIC SAFETY CONCERNS, as well as cost and physician and patient convenience issues, ideally an alternative dosing strategy can be used to decrease the number of required injections for anti-VEGF agents. A recently completed Phase IIIb study, PIER, was a randomized, double-masked, sham-controlled clinical trial of patients with subfoveal CNV secondary to AMD treated with ITV ranibizumab monthly for the first three months, followed by mandated quarterly dosing for 24 months (Regillo et al, 2006, unpublished data). For the first three months, both the anatomic improvements on OCT and the VA gains mirrored the ANCHOR and MARINA trials. After this period, the average VA decreased to baseline levels, because quarterly injections were unable to maintain the anatomic improvements seen with monthly injections. This is thought to be directly related to the mandated quarterly dosing in PIER, with some patients requiring more frequent injections to maintain the anatomic and visual improvements achieved in the first three months of the study. At the 12-month time point, the mean change in VA from baseline was a loss of 1.6 and 0.2 letters for ranibizumab-treated patients (0.3 mg and 0.5 mg, respectively), compared with a loss of 16.3 letters for sham-treated patients ( $P < .0001$ ). In addition, 83% and 90% of ranibizumab-treated patients (0.3 and 0.5 mg, respectively) lost fewer than 15 letters of VA, compared with 49% of sham-injected patients. After 12 months, 12% and 13% of ranibizumab-treated patients gained 15 or more letters of VA (0.3 and 0.5 mg, respectively), compared with 10% of sham-injected patients. Although the PIER trial results are far superior to those seen with any previous agent in AMD trials, the high expectations of overall improvement in mean visual acuity demonstrated in the ANCHOR and MARINA trials were not achieved. These initial PIER study data show that treating patients with CNV secondary to AMD every three months is less effective than monthly dosing with ranibizumab.

Another small, uncontrolled, but very well-designed study exploring an alternate dosing strategy for ranibizumab is PrONTO, a prospective OCT imaging study of patients with all subtypes of CNV secondary to AMD treated with ITV ranibizumab monthly for the first two months (three injections), followed by PRN dosing there-



after.<sup>26</sup> OCT was used to evaluate quantitative retinal thickness, and retreatment decisions were based on these quantitative OCT measurements as well as on other criteria, such as visual loss associated with any edema observed on qualitative OCT, the presence of new classic CNV on FA, and the presence of new hemorrhage or persistent fluid on qualitative OCT. Of note, fluid was observed with qualitative OCT 100% of the time at the time of ITV injection, whereas retinal thickness increases greater than 100  $\mu\text{m}$  were observed with quantitative OCT and were the reason for injection only 16% of the time.<sup>26</sup> ITV injections were also administered for decreased vision with evidence of fluid on qualitative OCT 41% of the time, for persistent fluid 29% of the time, for new subretinal hemorrhage with concomitant fluid on qualitative OCT 7% of the time, and for new classic CNV observed on FA as well as fluid on qualitative OCT 6% of the time. Preliminary results from the 40 patients enrolled in the study show that mean VA from baseline improved by 9.3 letters in ranibizumab-treated patients ( $P < .001$ ) and mean central retinal thickness decreased by 178  $\mu\text{m}$  ( $P < .001$ ). At one month (one injection), 85% of ranibizumab-treated patients had resolution of intraretinal, subretinal edema and 77.5% had resolution of subretinal fluid. At two months (two injections), 92.5% of ranibizumab-treated patients had resolution of subretinal fluid and intraretinal cysts, and at three months (three injections), 97.5% had resolution of subretinal fluid, whereas 92.5% had resolution of intraretinal cysts.<sup>26</sup> At 12 months, the mean number of injections was 5.6, and 17.5% (7/40) of patients did not require retreatment after the initial three ITV injections of ranibizumab. This OCT-guided dosing strategy achieved results comparable to the MARINA and ANCHOR trials with less than half of the required monthly injections used in the Phase III trials.

### WHY DO PAN-VEGF BLOCKING AGENTS IMPROVE VA IN NEOVASCULAR AMD?

THERE ARE NUMEROUS EXAMPLES OF RETINAL DISEASES IN which the anatomy of the fovea must be restored before visual improvements can occur. Two examples are macula-off retinal detachments and Irvine-Gass cystoid macular edema, where VA improves only when the anatomic pathology is corrected. Conversely, irreversible visual loss from progressive intraretinal fibrosis or atrophy occurs when the retina is subjected to prolonged subretinal and intraretinal edema as in diffuse diabetic macular edema and chronic central serous retinopathy. The MARINA and ANCHOR trials demonstrated a marked reduction in leakage from CNV in ranibizumab-treated patients compared with increased leakage in the controls, with qualitative OCT images of the retina of ranibizumab-treated patients appearing completely dry in almost all patients

after 24 ITV injections. These anatomic changes were associated with overall visual improvement in ranibizumab-treated patients.

No previous treatment has been as efficacious as ranibizumab at eliminating the edema in the subretinal space and neurosensory retina in neovascular AMD. Pegaptanib sodium, which theoretically only blocks one isoform of VEGF-A in the eye, rarely eliminates all macular edema even with continued use. In contrast, most ranibizumab-treated patients (>70%) have resolution of all macular edema as seen by OCT within one month of their first injection, and more than 90% have resolution of all edema after three consecutive monthly injections.<sup>26</sup> The visual gains seen in the initial three months of therapy in the ANCHOR, MARINA, and PIER trials are very similar and demonstrate visual gains very quickly after initiation of therapy and resolution of retinal edema. The on-average return to baseline (loss of the improvement in VA achieved in the first three months) in the PIER trial is likely related to the inability of mandated quarterly ITV ranibizumab injections to eliminate CNV leakage for all patients; some patients likely required more frequent ITV injections, whereas others could have used less frequent ITV injections, as supported by OCT findings in the trial (Regillo et al, 2006, unpublished data). This suggests that greater control through a criteria-based retreatment strategy may be warranted.

#### • OCT AND THE MANAGEMENT OF OCULAR DISEASES:

OCT is a noninvasive diagnostic imaging tool that can perform high-resolution, micron-scale, cross-sectional, or tomographic imaging in tissue by measuring the echo time delay and intensity of backscattered light.<sup>27</sup> OCT allows real-time in situ imaging of tissue with resolution of up to 15  $\mu\text{m}$  and enables examination of the epiretinal, intraretinal, and subretinal morphology.<sup>27</sup> OCT uses several measures to generate its images, including the central subfield, center point thickness, automated retinal boundary lines, inner retinal surface, and the RPE band. In OCT images, bright colors such as red and white represent regions of high reflectivity such as the nerve fiber layer, the plexiform layers, or the RPE, whereas dark colors such as blue or black represent regions of low reflectivity, such as the nuclear layers and photoreceptor inner and outer segments. Only the hyporeflective photoreceptor layer is visible at the foveola, where the indentation of the foveal pit is at its maximum.

OCT has been used in the management of many retinal diseases, including macular holes,<sup>28</sup> macular edema,<sup>29,30</sup> and neovascular AMD.<sup>31</sup> In AMD, OCT is useful in evaluating and documenting retinal angiomatous proliferation (RAP) lesions before and after laser photocoagulation in patients with RAP lesions secondary to AMD.<sup>31</sup> The early stages of RAP are difficult to detect with both contact lens biomicroscopy and angiographic examinations, but typical intraretinal features can be observed with

# Explore Litigation Insights

Docket Alarm provides insights to develop a more informed litigation strategy and the peace of mind of knowing you're on top of things.

## Real-Time Litigation Alerts



Keep your litigation team up-to-date with **real-time alerts** and advanced team management tools built for the enterprise, all while greatly reducing PACER spend.

Our comprehensive service means we can handle Federal, State, and Administrative courts across the country.

## Advanced Docket Research



With over 230 million records, Docket Alarm's cloud-native docket research platform finds what other services can't. Coverage includes Federal, State, plus PTAB, TTAB, ITC and NLRB decisions, all in one place.

Identify arguments that have been successful in the past with full text, pinpoint searching. Link to case law cited within any court document via Fastcase.

## Analytics At Your Fingertips



Learn what happened the last time a particular judge, opposing counsel or company faced cases similar to yours.

Advanced out-of-the-box PTAB and TTAB analytics are always at your fingertips.

## API

Docket Alarm offers a powerful API (application programming interface) to developers that want to integrate case filings into their apps.

## LAW FIRMS

Build custom dashboards for your attorneys and clients with live data direct from the court.

Automate many repetitive legal tasks like conflict checks, document management, and marketing.

## FINANCIAL INSTITUTIONS

Litigation and bankruptcy checks for companies and debtors.

## E-DISCOVERY AND LEGAL VENDORS

Sync your system to PACER to automate legal marketing.