

Intravitreal Bevacizumab for the Management of Choroidal Neovascularization in Age-related Macular Degeneration

ZIAD F. BASHSHUR, MD, ALI BAZARBACHI, MD, ALEXANDRE SCHAKAL, MD,
ZEINA A. HADDAD, MD, CHRISTELLE P. EL HAIBI, MS,
AND BAHA' N. NOUREDDIN, MD

• **PURPOSE:** To investigate the efficacy and safety of intravitreal bevacizumab for managing choroidal neovascularization (CNV) due to age-related macular degeneration (AMD).

• **DESIGN:** Prospective interventional case series.

• **METHODS:** Seventeen eyes of 17 patients with subfoveal CNV due to AMD participated in this study at the American University of Beirut Ophthalmology Clinics. All patients had failed, refused, or were not eligible for photodynamic therapy. All eyes received a baseline eye examination, which included best-corrected visual acuity (BCVA), dilated fundus examination, ocular coherence tomography (OCT) imaging, and fluorescein angiography. An intravitreal injection of bevacizumab (2.5 mg/0.1 ml) was given at baseline and followed by two additional injections at four-week intervals. BCVA, OCT, and fluorescein angiography were repeated four weeks after each injection. Main outcome measures were improvement in BCVA and central retinal thickness (CRT).

• **RESULTS:** Mean baseline BCVA was 20/252 (median 20/200), and baseline CRT was 362 μm (median 350 μm). Improvement in VA and CRT occurred by the fourth week. At 12 weeks, mean BCVA was 20/76 ($P < .001$) and median BCVA was 20/50 ($P < .001$). Both mean and median CRT decreased to 211 μm ($P < .001$). Thirteen (76%) of 17 eyes had total resolution of subretinal fluid, and four eyes (24%) had BCVA better than 20/50. No systemic or ocular side effects were noted at any time.

• **CONCLUSION:** Eyes with CNV due to AMD treated with intravitreal bevacizumab had marked anatomic and

visual improvement. Further studies are necessary to confirm the long-term efficacy and safety of this treatment. (Am J Ophthalmol 2006;142:1-9. © 2006 by Elsevier Inc. All rights reserved.)

AGE-RELATED MACULAR DEGENERATION (AMD) IS A leading cause of legal blindness in the industrialized world.¹ Although neovascular AMD is less prevalent than atrophic AMD, it accounts for most cases with severe visual loss from AMD.¹⁻³ Vascular endothelial growth factor (VEGF) has been implicated in the choroidal neovascularization (CNV) of AMD.⁴ VEGF helps promote endothelial cell growth and increases vascular permeability.^{4,5}

Standard treatment options for CNV include argon laser photocoagulation and photodynamic therapy (PDT) using verteporfin. The Macular Photocoagulation Study showed that well-defined or "classic" subfoveal CNV was amenable to argon laser photocoagulation.⁶⁻⁹ However, this procedure results in irreversible photoreceptor injury that usually causes a central scotoma.⁹ Later, large multicenter studies showed that PDT was effective in decreasing the probability of moderate and severe visual loss from predominantly classic subfoveal CNV.¹⁰⁻¹² Although PDT was designed to minimize damage to the retina and retinal vessels, a patient may continue to lose vision before stabilizing.^{11,12}

In December 2004, the US Food and Drug Administration approved intravitreal injection of pegaptanib, a 28-base anti-VEGF aptamer, for the management of CNV. Although pegaptanib-treated eyes continued to lose vision during the first year of the trial, they fared better than controls.^{13,14} Another anti-VEGF agent currently in phase III clinical trials for neovascular AMD is ranibizumab, a chemically modified product of bevacizumab that is affinity-matured to have higher affinity for VEGF (Miller J, unpublished data, presented at American Society of Retina Specialists Annual Meeting, July 2005). Bevacizumab is a humanized monoclonal antibody that inhibits all isoforms

See accompanying Editorial on page 141.

Accepted for publication Feb 24, 2006.

From the Department of Ophthalmology (Z.F.B., Z.A.H., C.P.E., B.N.N.), and Department of Internal Medicine (A.B.), American University of Beirut, and Department of Ophthalmology, Hotel Dieu de France (St Joseph University) (A.S.), Beirut, Lebanon.

Inquiries to Ziad Bashshur, MD, American University of Beirut Medical Center, PO Box 11-0236/B11, Beirut, Lebanon; e-mail: zb00@aub.edu.lb

of VEGF and is approved for treatment of colorectal cancer.¹⁵ Recently, bevacizumab was used to treat CNV due to AMD. Michels and associates¹⁶ showed that intravenous bevacizumab administered in two or three infusions at a dose of 5 mg/kg every two weeks decreased central retinal thickness (CRT) and improved vision. Later, Rosenfeld and associates¹⁷ presented a case report of a single eye that had improved CRT and visual acuity four weeks after an intravitreal injection of 1.25 mg of bevacizumab.

We treated 17 eyes with CNV due to AMD with intravitreal bevacizumab. We report on the anatomic and visual acuity results after 12 weeks of follow-up.

METHODS

STARTING AUGUST 2005, EYES WITH SUBFOVEAL CNV DUE TO AMD were considered for intravitreal bevacizumab. Patients were offered this treatment if they were not eligible for PDT, refused PDT, or had not responded to PDT. Eyes not eligible for PDT were those with minimally classic CNV greater than four disk areas or those with CNV that is more than 50% obscured by blood. Nonresponse to PDT was considered if the subfoveal CNV continued to grow with loss of visual acuity after three sessions. Eyes with occult CNV were also considered for treatment if there was evidence of subretinal hemorrhages on fundus examination or the patient noted recent decrease in visual acuity over the past 12 weeks. The hospital administration at the American University of Beirut Medical Center gave permission for the use of intravitreal bevacizumab as a compassionate treatment in a situation that would otherwise result in severe visual loss. All patients who were considered for intravitreal bevacizumab treatment had a thorough discussion about the possible benefits and complications. All patients signed a consent form for the off-label intravitreal injection of bevacizumab. The study was in adherence to the tenets of the Declaration of Helsinki.

Initial examination included best-corrected visual acuity (BCVA) using Snellen acuity charts, slit-lamp examination of the anterior segment, dilated fundus examination, and fluorescein angiography. Eyes with better than 20/50 visual acuity were not considered for treatment. Baseline 1-mm CRT was measured for all eyes using ocular coherence tomography (OCT) macular retinal mapping (Stratus OCT, Carl Zeiss Meditec, Dublin, California, USA). This map was created from six consecutive slow diagonal 6-mm scans that intersected at the fovea. Retinal thickness was measured automatically by the OCT software, and this was the distance between the vitreoretinal interface and the anterior surface of the retinal pigment epithelium. Because AMD patients may have difficulty fixating, the fundus image generated by the OCT machine during the procedure was used to center the scan at the fovea for each

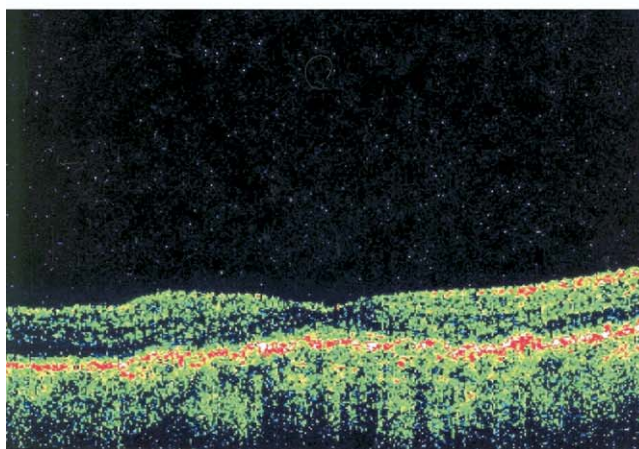
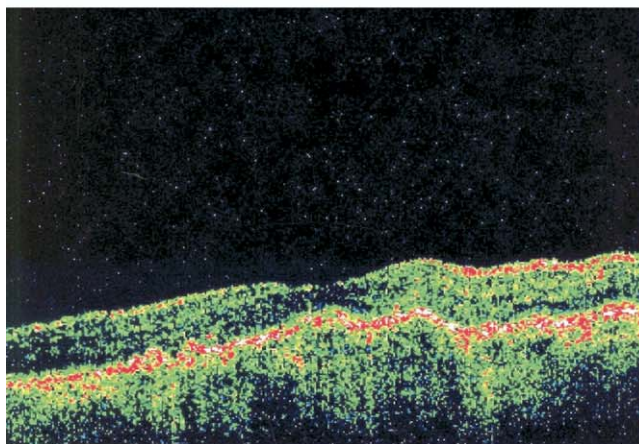
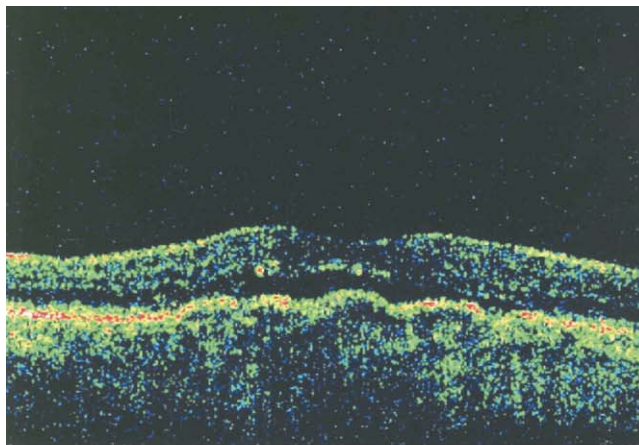


FIGURE 1. Ocular coherence tomography (OCT) scans and central retinal thickness (CRT) measurements for an eye with subfoveal choroidal neovascularization (CNV) due to age-related macular degeneration (AMD) that had complete resolution of subretinal fluid after the first intravitreal injection of bevacizumab. (Top) Baseline CRT is 236 μm with a visual acuity of 20/50. (Middle) One week after injection, CRT is 184 μm . (Bottom) Four weeks after injection, CRT is 187 μm with visual acuity of 20/50. OCT at eight and 12 weeks remained unchanged, but visual acuity was 20/40.

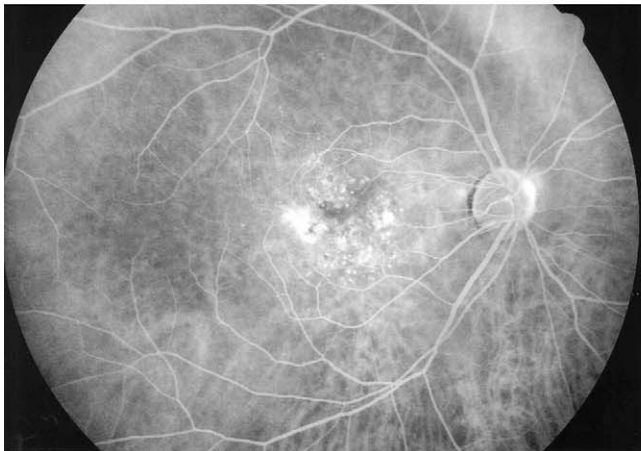
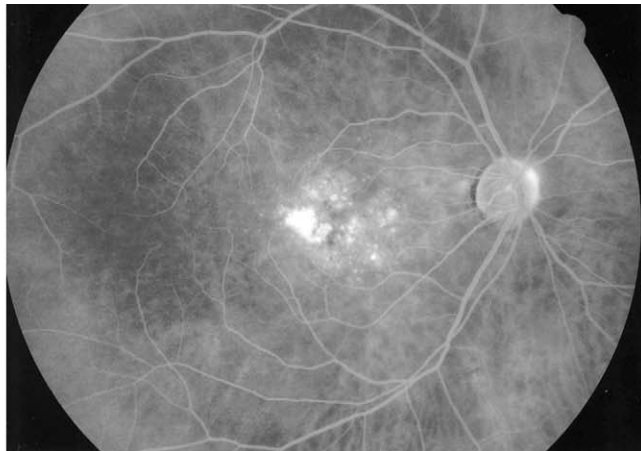
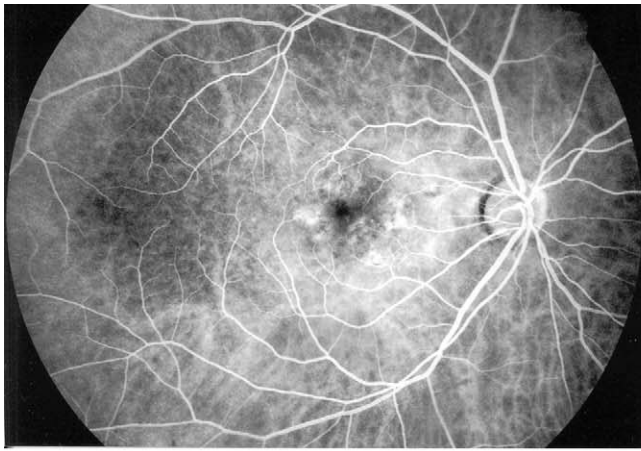


FIGURE 2. Fluorescein angiographic changes in choroidal neovascularization (CNV) for the eye in [Figure 1](#) after the first intravitreal injection of bevacizumab. Early-phase (Top left) and late-phase (Top right) angiograms before treatment show occult CNV. (Bottom) Late-phase angiogram four weeks after treatment with resolution of late leakage. Follow-up angiography at eight and 12 weeks continued to show no leakage.

examination. All OCT examinations at baseline and at follow-up were done by the same person (A.S.).

All patients had blood pressure measurements at every visit. They were also monitored for symptoms of possible thromboembolic events.

The hospital pharmacy divided a 100-mg (4-ml) vial of bevacizumab (Genentech Inc, San Francisco, California, USA) into 20 1-ml syringes using aseptic techniques and under a laminar flow hood. Therefore, each syringe contained 5 mg, or 0.2 ml, of bevacizumab. The syringes were stored at 4°C for no longer than 14 days. After that time, remaining syringes were discarded because sterility could not be considered without further sterility testing.¹⁸ No stability testing was done to determine if bevacizumab remained stable in polypropylene syringes during the 14-day period.

The eye to be treated was prepared with 5% povidone-iodine solution. Anesthesia was administered as a subconjunctival injection of lidocaine 2% in the inferotemporal quadrant approximately 3 to 4 mm from the limbus. Enough anesthetic was injected to form a small bleb in the area where the intravitreal injection was to be given. Using a 30-gauge needle, 0.1 ml (2.5 mg) bevacizumab was injected intravitreally through the pars plana 3.5 mm from the limbus. If the intraocular pressure was greater than 25 mm Hg or the optic nerve head was not adequately perfused 20 minutes after the injection, a paracentesis was performed. Tobra-

mycin eye ointment (Alcon, Puurs, Belgium) was instilled in the treated eye, and a light patch was applied. Patients were instructed to unpatch the eye the next day and use topical ciprofloxacin (Alcon, Puurs, Belgium) three times a day for three days.

A similar intravitreal injection of bevacizumab was administered to all eyes at four and eight weeks of follow-up even if there was total resolution of subretinal fluid and retinal pigment epithelial detachment.

Patients were examined at one week and four weeks after each injection. BCVA was measured at each visit along with slit-lamp examination of the anterior segment and dilated fundus examination. OCT and fluorescein angiography were repeated at least at the four-week follow-up. Ocular side effects that were monitored were decrease in vision, rise in intraocular pressure, cataract formation, inflammation, bacterial endophthalmitis, retinal detachment, vitreous hemorrhage, and changes on fundus examination or fluorescein angiography.

The main outcome measures were improvement in visual acuity and decrease in CRT. Snellen acuities were converted to the logarithm of the minimum angle of resolution (logMAR) to facilitate statistical analysis. The paired Student *t*-test was used to compare the mean visual acuity and CRT at weeks four to 12 after treatment with mean baseline measurements. Similarly, the paired Wil-

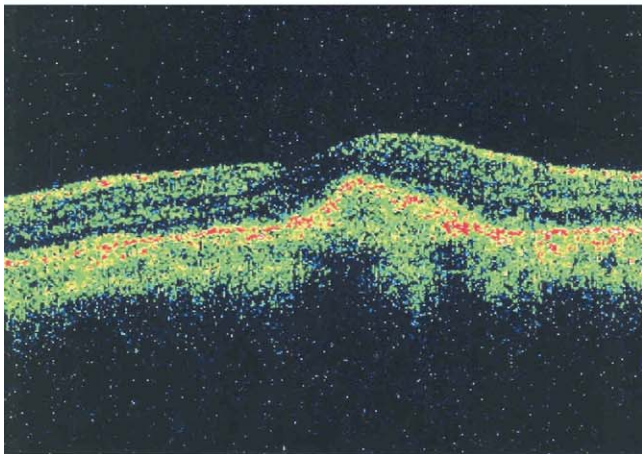
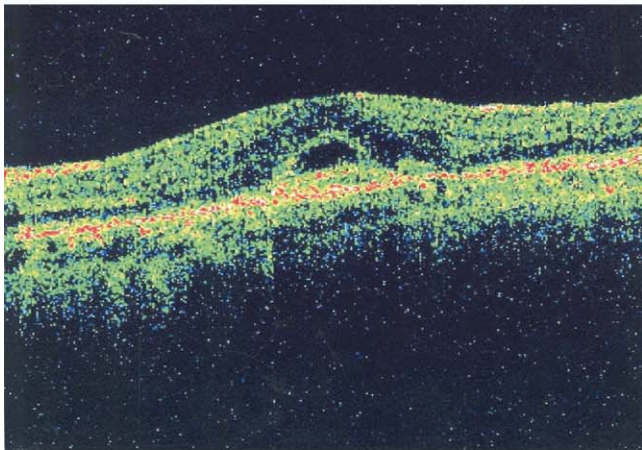
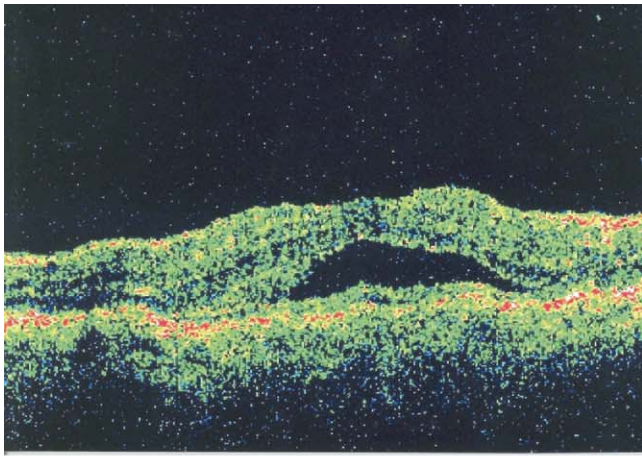


FIGURE 3. Ocular coherence tomography (OCT) scans and central retinal thickness (CRT) measurements for an eye with subfoveal choroidal neovascularization (CNV) due to age-related macular degeneration (AMD) that had complete resolution of subretinal fluid after the second intravitreal injection of bevacizumab. (Top) Baseline CRT is 328 μm with visual acuity of 20/200. (Middle) Four weeks after the first injection, CRT is 209 μm with visual acuity of 20/80. (Bottom) Four weeks after second injection or after eight weeks total follow-up, CRT is 181 μm with visual acuity of 20/40. Follow-up OCT at 12 weeks continued to show no subretinal fluid, and visual acuity remained 20/40.

coxon signed rank test was applied to compare the median visual acuity and CRT at weeks four to 12 with median baseline values. The level of statistical significance was set at $P < .05$ with a 95% confidence interval.

RESULTS

IN AUGUST 2005, 17 EYES OF 17 PATIENTS RECEIVED INTRAVITREAL bevacizumab. There were five women and 12 men. The average age was 68.3 years with a range of 59 to 78 years. All eyes had subfoveal CNV due to AMD. Four eyes had poor response to PDT. Four eyes were not eligible for PDT because a minimally classic CNV was greater than four disk areas, and two eyes had more than 50% of the CNV covered by subretinal blood. None of these eyes had blood covering the fovea. The remainder of the patients refused PDT.

All eyes tolerated the procedure with no complications. Mean baseline BCVA was 20/252 (median 20/200) and mean CRT was 362 μm (median 350 μm). At the four-week follow-up, mean and median BCVA improved to 20/105 ($P < .001$) and 20/80 ($P = .001$), respectively. Mean and median CRT at four weeks decreased to 279 μm ($P < .001$) and 282 μm ($P < .001$), respectively. Three (18%) of 17 eyes had complete resolution of subretinal fluid and retinal pigment epithelial detachment on OCT (Figures 1 and 2).

Mean BCVA at eight weeks (four weeks after the second injection) improved to 20/79 ($P < .001$), and median BCVA was 20/50 ($P < .001$). In addition, mean CRT decreased to 231 μm ($P < .001$), and median CRT decreased to 230 μm ($P < .001$). At the eighth week of follow-up, seven (41%) of 17 eyes had total resolution of SRF and PED on OCT (Figures 3 and 4). This included the three eyes that had such a response after the first injection.

Mean and median BCVA at 12 weeks (four weeks after the third injection) stabilized at 20/76 ($P < .001$) and 20/50 ($P < .001$), respectively. Both mean and median CRT at 12 weeks decreased further to 211 μm . This was statistically better than mean baseline CRT ($P < .001$) and median baseline CRT ($P < .001$). Thirteen (76%) of 17 eyes had total resolution of SRF and PED on OCT (Figures 5 and 6). Tables 1 and 2 summarize the visual acuity and CRT data over 12 weeks.

After 12 weeks, all 17 eyes had improvement in CRT (Figure 7), and eight (47%) of 17 eyes had CRT equal to or less than 200 μm . Fifteen (88%) of 17 eyes had better BCVA at 12 weeks than baseline, whereas two eyes did not improve (Figure 8). Four (24%) of 17 eyes ended with BCVA better than 20/50. All 17 eyes had marked reduction or absence of leakage from the CNV on angiography; however, the improvement on angiography did not occur as rapidly as that noted on OCT. We did not note any ocular side effects at any stage. There was no significant rise in intraocular pressure or progression of cataract.

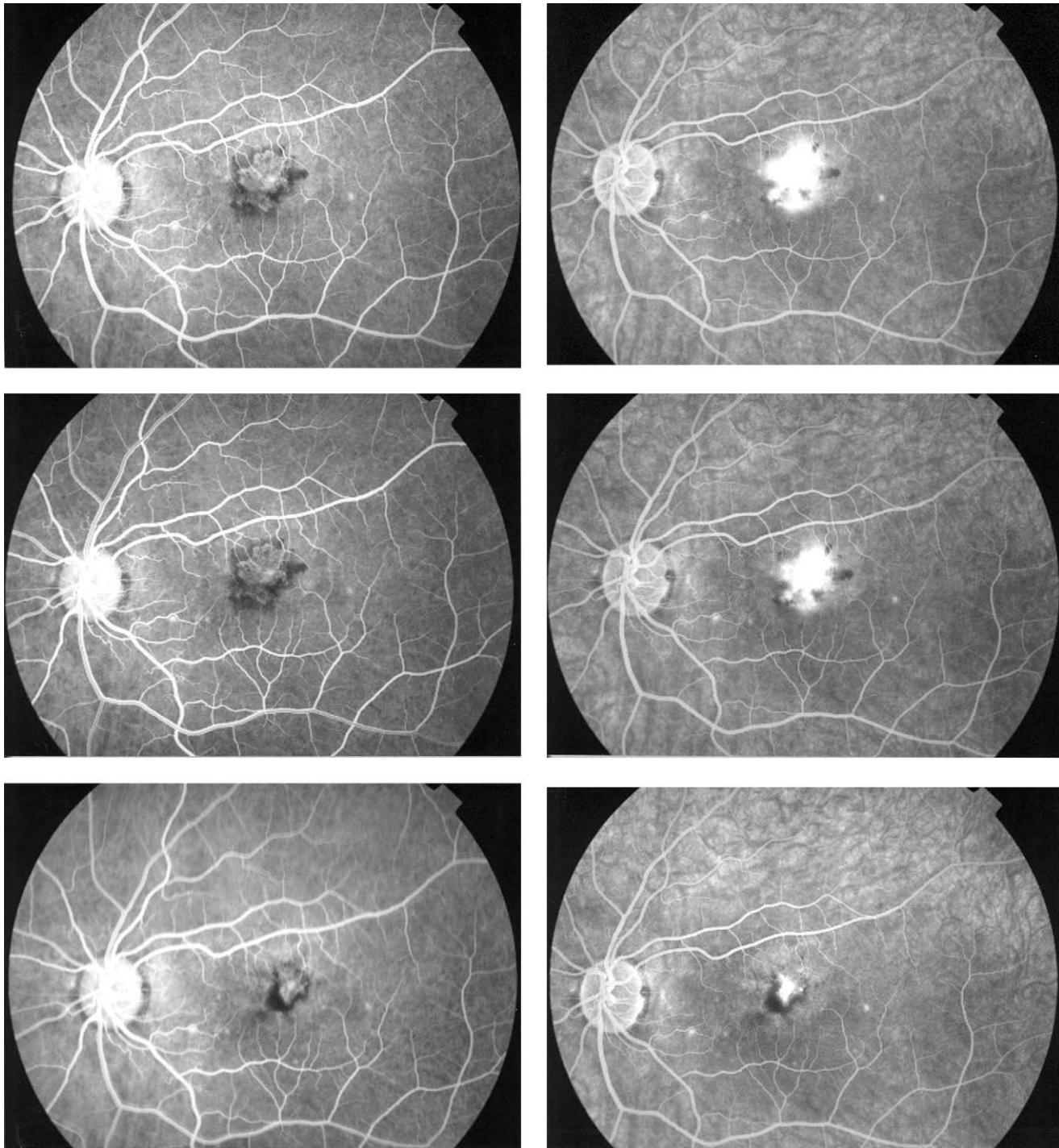


FIGURE 4. Fluorescein angiographic changes in choroidal neovascularization (CNV) for the eye in Figure 3 after two intravitreal injections of bevacizumab. Early-phase (Top left) and late-phase (Top right) angiograms at baseline show classic CNV. Four weeks after the first injection, there is no change in the early-phase (Middle left) and late-phase (Middle right) angiograms. Four weeks after the second injection or after eight weeks of follow-up, there is considerable decrease in the size of the CNV in the early phase (Bottom left) and decreased leakage in the late phase (Bottom right). Angiography at 12 weeks remained unchanged.

Mean baseline arterial blood pressure was 138/86. At no time during follow-up did the blood pressure rise noticeably above baseline. Also, no thromboembolic events were observed during the period of this study.

DISCUSSION

WE TREATED 17 EYES WITH CNV DUE TO AMD WITH INTRA-VITREAL BEVACIZUMAB. After 12 weeks of follow-up, these

Explore Litigation Insights

Docket Alarm provides insights to develop a more informed litigation strategy and the peace of mind of knowing you're on top of things.

Real-Time Litigation Alerts



Keep your litigation team up-to-date with **real-time alerts** and advanced team management tools built for the enterprise, all while greatly reducing PACER spend.

Our comprehensive service means we can handle Federal, State, and Administrative courts across the country.

Advanced Docket Research



With over 230 million records, Docket Alarm's cloud-native docket research platform finds what other services can't. Coverage includes Federal, State, plus PTAB, TTAB, ITC and NLRB decisions, all in one place.

Identify arguments that have been successful in the past with full text, pinpoint searching. Link to case law cited within any court document via Fastcase.

Analytics At Your Fingertips



Learn what happened the last time a particular judge, opposing counsel or company faced cases similar to yours.

Advanced out-of-the-box PTAB and TTAB analytics are always at your fingertips.

API

Docket Alarm offers a powerful API (application programming interface) to developers that want to integrate case filings into their apps.

LAW FIRMS

Build custom dashboards for your attorneys and clients with live data direct from the court.

Automate many repetitive legal tasks like conflict checks, document management, and marketing.

FINANCIAL INSTITUTIONS

Litigation and bankruptcy checks for companies and debtors.

E-DISCOVERY AND LEGAL VENDORS

Sync your system to PACER to automate legal marketing.