

Prospective Study of Intravitreal Ranibizumab as a Treatment for Decreased Visual Acuity Secondary to Central Retinal Vein Occlusion

RICHARD F. SPAIDE, LOUIS K. CHANG, JAMES M. KLANCNIK, LAWRENCE A. YANNUZZI, JOHN SORENSON, JASON S. SLAKTER, K. BAILEY FREUND, AND ROBERT KLEIN

- **PURPOSE:** To evaluate intravitreal injection of ranibizumab as a potential treatment for decreased visual acuity (VA) secondary to central retinal vein occlusion (CRVO).
- **DESIGN:** Prospective, interventional case series.
- **METHODS:** Patients with CRVO prospectively recruited from a practice were administered intravitreal ranibizumab 0.5 mg (Lucentis; Genentech Inc, South San Francisco, California, USA) at baseline and monthly for two additional doses. The patients were given additional ranibizumab if they had macular edema as determined by optical coherence tomography or any new intraretinal hemorrhage. Patients were evaluated for number of required injections, side effects, changes in VA, and macular thickness.
- **RESULTS:** There were 20 eyes of 20 patients who at baseline had a mean age of 72.1 years, a mean VA of 45.8 Early Treatment of Diabetic Retinopathy letters, and a mean central macular thickness of 574.6 μm . Of the 20 eyes, five previously had received intravitreal triamcinolone and 11 had received intravitreal bevacizumab (Avastin; Genentech Inc). At 12 months of follow-up, the mean VA improved to 64.3 letters and the central macular thickness decreased to 186 μm (both different than baseline values; $P < .001$) using a mean of 8.5 injections. The change in macular thickness was not correlated with the change in VA. In one patient with a history of transient ischemic attack, an ischemic stroke developed but no sequela resulted. In another patient, vitreomacular traction developed, but the patient had improved acuity as compared with baseline. There were no infections, retinal tears, or detachments.
- **CONCLUSIONS:** Intravitreal ranibizumab used over a period of one year improved mean VA, with low rates of adverse events, in patients with CRVO. (*Am J Ophthalmol* 2009; 147:298–306. © 2009 by Elsevier Inc. All rights reserved.)

CENTRAL RETINAL VEIN OCCLUSION (CRVO) IS A condition characterized by dilation and tortuosity of the retinal venules with hemorrhages in all four quadrants of the retina. Often there is concomitant optic

nerve swelling and macular edema, and there may be exudative detachment of the retina, neovascularization of the iris, and neovascular glaucoma. After diabetic retinopathy, CRVO is the second most common retinal vascular disease affecting the retina.^{1,2} Patients with CRVO report difficulty with many aspects of daily life and have decreased vision-related quality of life as measured by the 25-item National Eye Institute Visual Function Questionnaire.³

Intravitreal levels of vascular endothelial growth factor (VEGF) in CRVO are the highest of those measured in retinal vascular disease,⁴ and the severity of findings in CRVO is proportional to intravitreal VEGF levels.⁵ Retinal neovascularization is seen rarely in eyes with CRVO. Almost all of the features of CRVO can be induced in primate eyes by intravitreal injection of VEGF, including vascular dilation, tortuosity, intraretinal hemorrhage, and capillary nonperfusion.⁶ Intravitreal VEGF injections in primates cause little or no retinal neovascularization.⁶ Inhibiting VEGF would seem to be a rational strategy for treating CRVO. Intravitreal injection of anti-VEGF agents caused regression of iris neovascularization.^{7,8} CRVO was among the first diseases treated with intravitreal bevacizumab (Avastin; Genentech Inc, South San Francisco, California, USA),⁹ and subsequent case series showed a large proportion of patients having visual acuity (VA) improvement.^{10,11} Bevacizumab treatment early after the onset of CRVO was associated with a statistically significant reduction in venous dilation, tortuosity, optic disc swelling, and macular edema in addition to improvement of VA.¹² Ranibizumab (Lucentis; Genentech Inc) has potentially increased retinal penetration because of a smaller molecular size and a higher binding affinity for VEGF than does bevacizumab.¹³ Given these potential attributes, ranibizumab may be particularly suited as an agent to treat CRVO, a disease with manifestations that seem to be driven by VEGF. To gain preliminary information, we performed a prospective study of intravitreal ranibizumab injections as a treatment for decreased VA secondary to CRVO.

METHODS

THIS WAS A PROSPECTIVE, PHASE 1, OPEN-LABEL STUDY examining intravitreal injection of ranibizumab 0.5 mg as a treatment for decreased VA resulting from CRVO. The

Accepted for publication Aug 10, 2008.

From the Vitreous-Retina-Macula Consultants of New York and the LuEsther T. Mertz Retinal Research Center, Manhattan Eye, Ear, and Throat Hospital, New York, New York.

Inquiries to Richard F. Spaide, Vitreous, Retina, Macula Consultants of New York, 460 Park Avenue, 5th Floor, New York, NY 10022; e-mail: rickspaide@yahoo.com

study had Food and Drug Administration (FDA) Investigator Investigational New Drug number 100,240.

The patients with CRVO (as manifested by retinal hemorrhages and dilated retinal venules in all four quadrants of the fundus) underwent a comprehensive ophthalmologic examination that included VA assessment using Early Treatment of Diabetic Retinopathy (ETDRS) protocol refraction measured at 4 m, slit-lamp biomicroscopy, indirect ophthalmoscopy, color fundus photography, optical coherence tomography (OCT) using the Stratus OCT (Carl Zeiss Meditec, Dublin, California, USA), and fluorescein angiography (FA). The central macular thickness (CMT) was measured manually using the software calipers because of the known inaccuracies of the segmentation algorithm with the Stratus OCT software.¹⁴ Digital FA was performed with a Topcon TRC-50DX fundus camera with ImageNet software (Topcon USA; Paramus, New Jersey, USA). FA was performed by positioning the patient at the fundus camera, injecting 2 ml of a 25% solution of sodium fluorescein (Akorn Inc, Somerset, New Jersey, USA) as a bolus into the antecubital vein. The timer on the camera was started at the time of injection, and filling, mid-phase, and late-phase images were recorded. The angiograms were evaluated for what was termed *arm-to-early arterial filling*, which was the time in seconds from the injection to when the dye front within the superior and inferior temporal arcade arterioles both were seen to extend temporal to the retinal midline as defined by a vertical line extending through the geometric center of the fovea. Late-phase angiograms were evaluated for the presence of leakage and for the accumulation of dye within the retina.

Patients with decreased VA secondary to CRVO were eligible for the study if they were 18 years or older and had a VA score of 34 letters (20/200) or more and 73 letters (20/40) or less as determined by the ETDRS VA protocol. To be eligible for the study, the patients must have had macular edema with a thickness of more than 250 μm . Patients who were pregnant, had uncontrolled hypertension or diabetes, had greater than moderate nonproliferative diabetic retinopathy, uncontrolled glaucoma, OCT evidence of a vitreoretinal interface abnormality, or any other additional ocular diseases that could compromise irreversibly the VA of the study eye were excluded from the study. Additionally, patients were not eligible for the study if they had a history of vitreous surgery or intravitreal, peribulbar, or retrobulbar corticosteroids within six months, cataract surgery within six months, yttrium-aluminum-garnet capsulotomy within two months, intravitreal injection of pegaptanib sodium within 45 days, or intravitreal injection of bevacizumab within 30 days of enrollment in the study.

Enrolled patients were injected at baseline with 0.5 mg ranibizumab into the vitreous cavity on a monthly basis for the following two months and then were examined monthly. Patients were injected using aseptic technique as per the package labeling for ranibizumab, with the exception that no draping was used. Patients were examined within a

Ranibizumab for CRVO

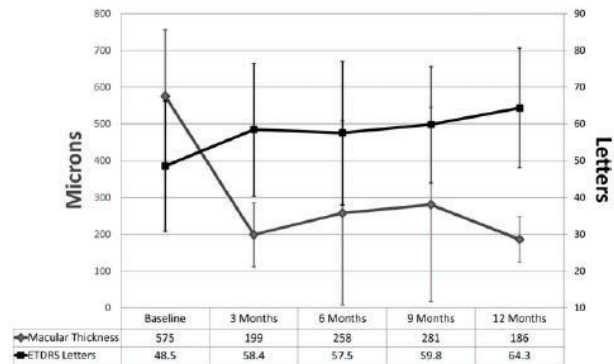


FIGURE 1. Graph showing the thickness of the central macula in micrometers and the visual acuity (VA) in Early Treatment of Diabetic Retinopathy Study letters. CRVO = central retinal vein occlusion.

period from three to seven days after injection at the beginning of the study, but this early examination was eliminated from the protocol after obtaining an exemption from the FDA approximately halfway through the study. Patients were examined on a monthly basis over the course of a one-year follow-up with ETDRS VA, slit-lamp biomicroscopy, indirect ophthalmoscopy, color fundus photography, OCT, and FA. Patients were reinjected with 0.5 mg ranibizumab if they had evidence of any hemorrhage in the retina, or macular edema as determined if there was the presence of a macular thickness of more than 250 μm or intraretinal cystoid spaces within the macular region.

• **STATISTICAL METHODS:** The data obtained were analyzed with frequency and descriptive statistics. Categorical analysis was performed using the Chi-square test. The Pearson correlation coefficient was calculated as a measure of the bivariate linear association between variables. Baseline VA as measured in ETDRS letters was compared with the measurements obtained at three and six months with a paired-samples t test. A P value of less than .05 was considered significant, except for the VA data, because two evaluations, one at three months and another at six months, were made. (The α was adjusted as per the Bonferroni technique.) There was case-wise deletion of missing data. Statistical analysis was performed with SPSS software version 16.01 (SPSS Inc, Chicago, Illinois, USA).

• **EARLY EXIT FROM STUDY:** Four patients exited the study before the 12-month follow-up. One patient found the travel necessary for the study visits too difficult, another patient moved to a different state for employment reasons and could not return for examinations. In one patient, focal vitreomacular traction developed and the patient underwent vitrectomy, and another patient was presumed to have a stroke, after which she did not want to receive any additional injections. The latter two patients are detailed in the Results. Exited

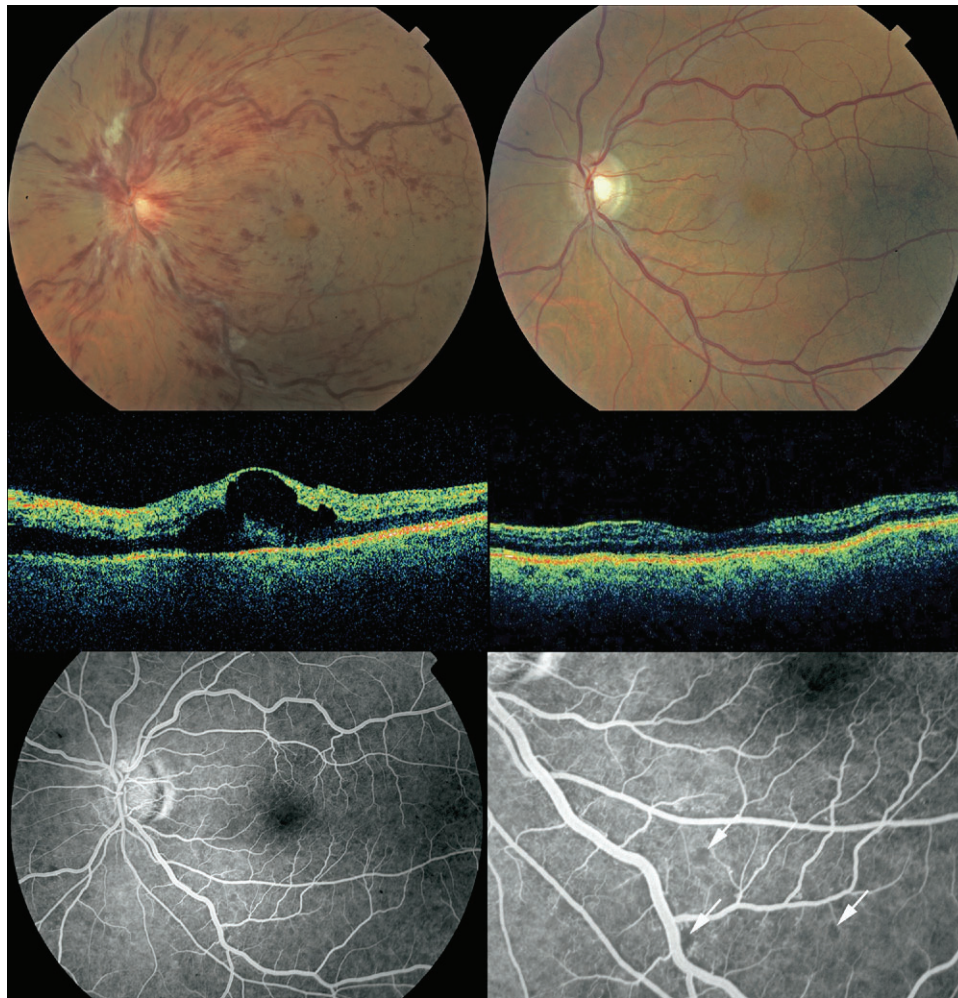

FIGURE 2. Images obtained from a 53-year-old male with a one-day history of CRVO. (Top left) Fundus photograph showing optic nerve head hyperemia and swelling, dilated tortuous veins, intraretinal hemorrhage, and foveal pseudocyst. (Top right) Fundus photograph obtained at the one-year follow-up showing the manifestations of the CRVO resolved. (Middle left and right) Optical coherence tomography (OCT) images obtained at baseline and at the one-year of follow-up showing dramatic resolution of the macular edema. (Bottom left) Midphase fluorescein angiogram (FA) showing a normal appearance grossly. (Bottom right) However on closer examination, there was a moth-eaten appearance of the capillary bed with very small areas of nonperfusion (arrows). The patient's VA improved 22 letters.

patients were not included in any calculations past the examinations they completed.

RESULTS

• **BASELINE CHARACTERISTICS:** There were 20 eyes of 20 patients who at baseline had a median age of 72.1 years (interquartile range, 60.2 to 80.1 years). Twelve of the patients were male. Of the 20 patients 14 (70%) had hypertension, two (10%) had diabetes mellitus, two (10%) had a history of myocardial infarction, one (5%) had a prior history of a transient ischemic attack, one (5%) was a current smoker, and seven (35%) were former smokers. The median duration of the CRVO on entry to the study was 34.6 weeks (interquartile range, six to 75.5 weeks). Of the 20 patients, 11

had previous treatment, five had previous intravitreal triamcinolone treatment, and 11 (including all of those who had intravitreal triamcinolone treatment) had intravitreal bevacizumab treatment. The median number of past injections for those who received intravitreal bevacizumab was six (interquartile range, 4 to 9; mean, 6.2), with the dose being either 1.25 or 2.5 mg. The median time from the last bevacizumab injection until entry into the study was 58 days (interquartile range, 36.8 to 89 days). The mean baseline VA was 45.8 ETDRS letters (± 17.7 [standard deviation (SD)]; median, 54 letters) and the mean CMT was 574.6 μm (± 181 [SD]; median, 581 μm). The baseline VA and CMT did not differ by previous history of bevacizumab injection ($P = .47$ and $P = .78$, respectively). The FAs showed an arm-to-early arterial filling time occurring at a mean of 28.1 seconds after injection (range, 18.7 to 51.9 seconds). Retinochoroidal

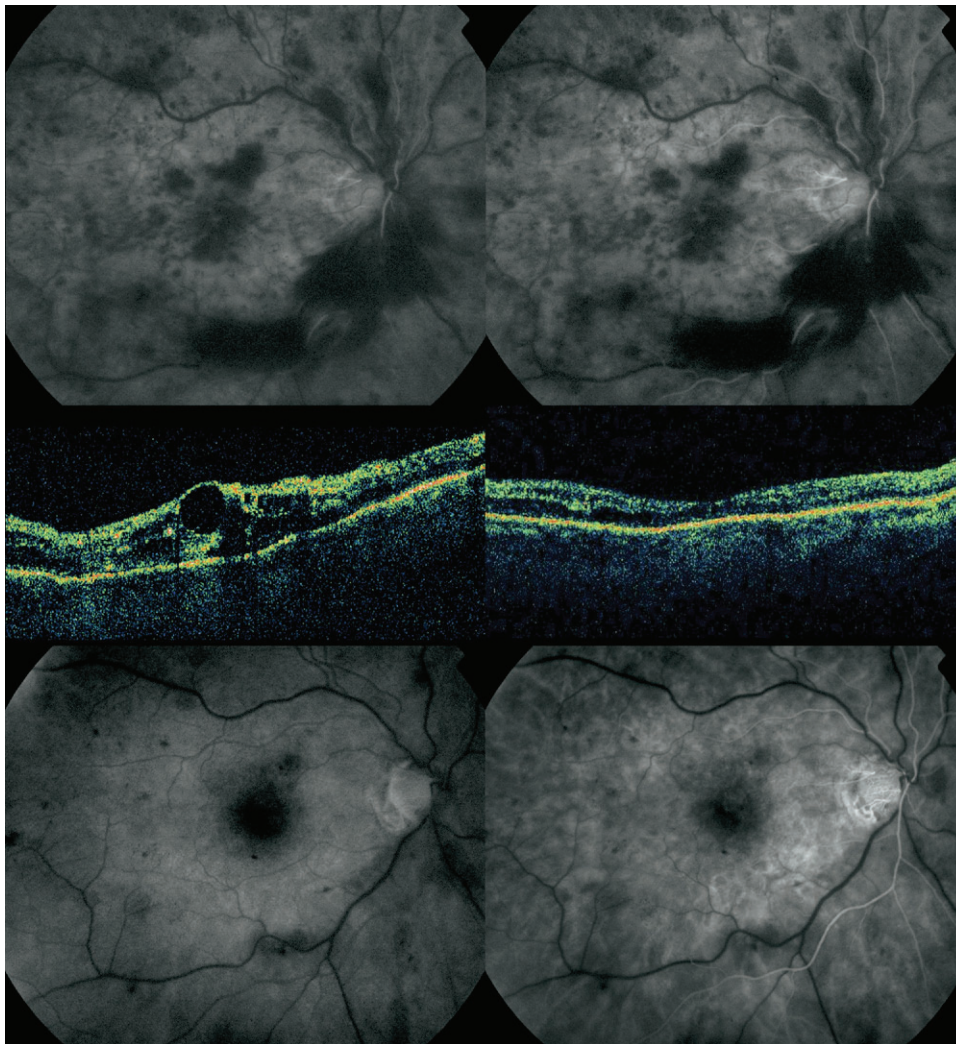


FIGURE 3. Images obtained from a 64-year-old man with a 52-week history of CRVO for which he had not received treatment. (Top left) FA obtained 32.5 seconds after an antecubital injection of fluorescein showing that the dye front is first becoming visible in the eye. (Top right) FA obtained at 33.9 seconds after dye injection showing that the dye front in both the inferior and superior arcade vessels has moved temporal to the midline through the center of the fovea. (Middle left) OCT image showing that the patient had macular edema at baseline. (Middle right) OCT image showing that at the 12-month follow-up, there was no macular edema. (Bottom left) FA obtained at the 12-month follow-up showing the dye front first becoming visible on the vessels on the nerve head at 32.3 seconds. (Bottom right) FA obtained at the 12-month follow-up showing that the dye front moved past the midline at 34.8 seconds after injection. The patient's VA improved 29 letters.

collateral vessels were seen in 11 eyes and were not seen in three eyes, and determination was not possible in six eyes because of hemorrhage on or around the nerve.

- **EARLY FOLLOW-UP:** In the follow-up during the first week after the first injection, the mean VA improved 8.3 letters ($P < .001$) and the CMT decreased by a mean of 349.2 to 225.4 μm of thickness ($P < .001$). The baseline fluorescein arm-to-early arterial filling time was correlated to change in VA at one week ($r = 0.59$; $P = .015$), but did not show a significant correlation with the change in CMT ($r = 0.27$; $P = .3$) at one week. At one month, the vision and thickness parameters regressed to a VA improvement

of 6.2 letters over baseline and a CMT of 273 μm ($P = .019$ and $P < .001$, respectively, as compared with baseline). One patient had a four-letter gain at one week, but an 18-letter loss at one month. He ultimately received nine injections over 12 months and had a 15-letter gain. At the three-month follow-up, the VA showed a mean improvement of 10.4 letters over baseline ($P = .001$), and there was a decrease of the CMT to 199 μm ($P < .001$).

- **TWELVE-MONTH FOLLOW-UP:** At 12 months of follow-up, the mean VA improved to 64.3 letters (median, 68.5 letters), and the CMT decreased to 186 μm (median, 170 μm ; $P < .001$ for each; Figure 1). The patients received a

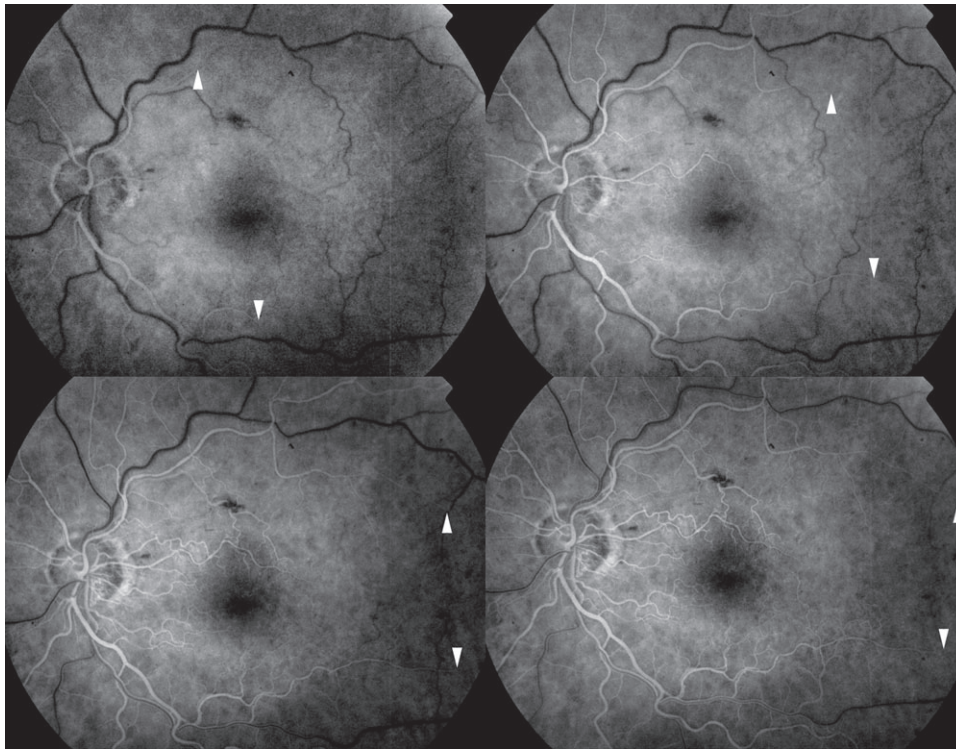


FIGURE 4. (Top left) FA obtained at the 12-month follow-up examination showing that the manifestations of the CRVO have resolved except for a small number of scattered intraretinal hemorrhages (arrows) in this 73-year-old male. At 35 seconds after the antecubital injection of fluorescein, the dye front is visible in the arterioles of the vascular arcade (arrowheads). (Top right) FA showing that the dye front has moved distally within the vessels (arrowheads) by 38.6 seconds. (Bottom left) FA showing that the dye front has moved distally within the vessels (arrowheads) by 43.6 seconds after injection. (Bottom right) FA showing that the dye front has nearly moved out of the frame (arrowheads) by 47.9 seconds after injection. The patient's VA improved six letters.

mean number of 8.5 injections (median, 10). Considering the patients who exited early from the study, the injection frequency was 0.85 per month over the total potential months in which injection was possible, with 47.3% of the injections given for edema and 52.7% given principally because of hemorrhage criteria. The change in VA was not correlated with the number of injections ($r = 0.39$; $P = .14$). Although both the VA and the CMT improved, the two measures were not correlated ($r = 0.24$; $P = .38$). There were nine (56.3%) eyes that had improvement of three lines or more, and two eyes (12.5%) that had an improvement of more than six lines of VA. The mean last observation carried forward acuity was 63 letters. There was one eye (6.3%) with a loss of three lines or more at 12 months (that eye had a 20-letter loss). This eye had recurrence of macular edema after one month without an injection of ranibizumab when the acuity was 21 letters better. As part of an extension study, this patient had an injection of ranibizumab at 12 months and had a return of vision during that study (data not shown).

The change in VA at one week was correlated with the change in acuity at 12 months ($r = 0.56$; $P = .029$), but the change at one month was not correlated with the change in acuity at 12 months ($r = 0.37$; $P = .16$). The change in CMT at one week was correlated with the change in macular

thickness at 12 months ($r = 0.94$; $P < .001$). The change in CMT at one month showed a smaller correlation with the change in CMT at 12 months ($r = 0.5$; $P = .047$). The change in VA at 12 months was not correlated with the arm-to-early arterial filling time at baseline ($r = 0.11$; $P = .69$). There was no difference in the VA change among those who had previous bevacizumab treatment vs those who did not ($P = .61$). In one patient, retinochoroidal collateral vessels developed, and in none of the patients with retinochoroidal collateral vessels at baseline did they disappear by 12 months. The mean arm-to-early arterial filling time at the final examination was 29.2 seconds, a change from baseline that was not significant ($P = .9$). Although not numerically quantified, cotton wool spots were seen to take many months to resolve in this series. At 12 months, examination of the FAs showed capillary network in the retina had a moth-eaten appearance with telangiectasis (Figures 2 through 5).

- **SAFETY:** There were a total of 170 intravitreal injections over the study period, and there were no retinal tears, detachments, or infections resulting from these injections. One 84-year-old hypertensive woman had a cerebral vascular accident, or what was thought to be an ischemic cerebral vascular accident. She had a past history of

Explore Litigation Insights

Docket Alarm provides insights to develop a more informed litigation strategy and the peace of mind of knowing you're on top of things.

Real-Time Litigation Alerts



Keep your litigation team up-to-date with **real-time alerts** and advanced team management tools built for the enterprise, all while greatly reducing PACER spend.

Our comprehensive service means we can handle Federal, State, and Administrative courts across the country.

Advanced Docket Research



With over 230 million records, Docket Alarm's cloud-native docket research platform finds what other services can't. Coverage includes Federal, State, plus PTAB, TTAB, ITC and NLRB decisions, all in one place.

Identify arguments that have been successful in the past with full text, pinpoint searching. Link to case law cited within any court document via Fastcase.

Analytics At Your Fingertips



Learn what happened the last time a particular judge, opposing counsel or company faced cases similar to yours.

Advanced out-of-the-box PTAB and TTAB analytics are always at your fingertips.

API

Docket Alarm offers a powerful API (application programming interface) to developers that want to integrate case filings into their apps.

LAW FIRMS

Build custom dashboards for your attorneys and clients with live data direct from the court.

Automate many repetitive legal tasks like conflict checks, document management, and marketing.

FINANCIAL INSTITUTIONS

Litigation and bankruptcy checks for companies and debtors.

E-DISCOVERY AND LEGAL VENDORS

Sync your system to PACER to automate legal marketing.