

# LONG-TERM FOLLOW-UP FOR TYPE 1 (SUBRETINAL PIGMENT EPITHELIUM) NEOVASCULARIZATION USING A MODIFIED “TREAT AND EXTEND” DOSING REGIMEN OF INTRAVITREAL ANTIVASCULAR ENDOTHELIAL GROWTH FACTOR THERAPY

MICHAEL ENGELBERT, MD, PhD,\*† SANDRINE A. ZWEIFEL, MD,†‡ K. BAILEY FREUND, MD\*†§

---

**Purpose:** The purpose of the study was to analyze long-term outcomes for the treatment of type 1 (subretinal pigment epithelium) neovascularization using a modified “treat and extend” antivascular endothelial growth factor dosing regimen.

**Methods:** We performed a retrospective, noncomparative analysis of visual acuity, funduscopy, and optical coherence tomography data for 18 eyes of 16 consecutive patients with newly diagnosed type 1 neovascularization treated with intravitreal bevacizumab and/or ranibizumab with at least 24-month follow-up. Three monthly injections were followed by continued treatment at intervals increasing by 2 weeks per visit to a maximum of 10 weeks. The interval was shortened if clinical or optical coherence tomography evidence of recurrent fluid at the foveola or increased extrafoveal fluid was detected.

**Results:** Median baseline logarithm of the minimum angle of resolution visual acuity was 0.53 (20/69 Snellen equivalent) and remained stable at 24 months (logarithm of the minimum angle of resolution 0.52,  $P = 0.84$ ) after an average of 12 injections (range, 8–19 injections) and at 36 months (logarithm of the minimum angle of resolution 0.52,  $P = 0.68$ ) after an average of 20 injections (range, 18–25 injections). Although most eyes (15 of 18 [83%]) continued to manifest extrafoveal subretinal fluid throughout the course of treatment, only 1 eye developed geographic atrophy overlying the areas of choroidal neovascularization. During a cumulative observation period of 540 months, no eyes developed a sight-threatening submacular hemorrhage.

**Conclusion:** A modified “treat and extend” dosing regimen of intravitreal antivascular endothelial growth factor therapy reduces the need for monthly visits and imaging and allows for stable long-term visual acuity in eyes with type 1 neovascularization.

RETINA 30:1368–1375, 2010

---

Type 1 neovascularization occurs as a subtype of neovascular age-related macular degeneration (AMD) in which the abnormal vessels are located between Bruch membrane and the basal surface of the retinal pigment epithelium (RPE). Type 1 neovascularization typically exhibits an occult pattern with fluorescein angiography and always manifests some degree of RPE elevation with optical coherence tomography (OCT). The type 1 pattern has a different natural course and treatment response from the type 2 (classic) and type 3 (retinal angiomatous proliferation)

neovascular patterns. For example, eyes with type 1 (occult) neovascularization presented with better visual acuity in the MARINA study<sup>1</sup> than eyes with type 2 (classic) neovascularization in the ANCHOR study.<sup>2</sup> In addition, in these trials, patients with type 1 neovascularization did not gain as many letters<sup>1</sup> as patients with type 2 neovascularization,<sup>2</sup> although they were treated with the same dosing regimen of continuous monthly intravitreal injections of ranibizumab during 24 months.

It has been hypothesized that the type 1 neovascular pattern may be a compensatory form of neovascular

growth occurring in response to an ischemic outer retina.<sup>3</sup> Type 1 vessels may represent a more mature form of neovascularization confined to the sub-RPE space and may be less responsive to antivascular endothelial growth factor (anti-VEGF therapy) than other neovascular patterns. In addition, by recapitulating the choriocapillaris, these vessels may provide nutritional support to the outer retina and could theoretically protect against the advent of geographic atrophy (GA).

Although a monthly dosing regimen of intravitreal ranibizumab has the greatest scientific support for efficacy, it may be difficult to sustain in the elderly population with AMD. In addition, by inhibiting a potentially compensatory neovascular response, GA could be accelerated in eyes treated with more aggressive anti-VEGF dosing regimens. However, the relatively infrequent dosing in the PIER trial,<sup>4</sup> in which patients received quarterly injections after an initial series of three monthly injections, resulted in inferior visual results when compared with the trials that were using monthly dosing.

The PrONTO Study<sup>5</sup> attempted to customize the dosing to the individual needs of the patient based on acuity decline, clinical findings, or OCT evidence of disease activity. The results from the 37 patients who completed this trial seemed to be favorable at both during 12- and 24-month period.<sup>5,6</sup> As a result, PrONTO-style dosing has become popular in the retina community. Nonetheless, this strategy does require monthly visits, clinical examinations, and OCTs, and patients are uncertain if or when they will need treatment. In addition, there have been more recent concerns that patients who are no longer receiving regular maintenance intravitreal anti-VEGF injections can occasionally experience sudden sight-threatening macular hemorrhages within days or weeks after a stable clinical examination and an OCT showing no apparent sub- or intraretinal fluid.<sup>7-9</sup>

The “treat and extend” dosing regimen is a strategy intended to resolve macular exudation and then maintain the macula in this “dry” state indefinitely with, when possible, fewer patient visits and treatments than monthly dosing.<sup>10</sup> We recently reported encouraging

long-term results using this regimen in eyes with type 3 neovascularization.<sup>11</sup> The dosing strategy consists of an initial induction or “loading” sequence of at least three initial monthly injections. If stable visual acuity, an absence of macular hemorrhage, and a dry OCT have been achieved at this point, patients continue to receive regular maintenance injections at increasing intervals. At 6 weeks after the last of the 3 initial monthly injections, visual acuity, clinical findings, and OCT changes are recorded again, and patients receive an injection regardless of the presence or absence of disease activity. However, the interval to the next visit (and scheduled injection) is based on an observed change in these parameters. If there are no changes, the next visit is scheduled for 8 weeks. If there is a change, the patient returns for another scheduled injection and examination after 4 weeks. The observation and scheduled treatment interval is extended (hence the phrase “treat and extend”). In our clinical experience, the risk of recurrent sight-threatening hemorrhages seems to increase because the interval between injections of anti-VEGF agents is extended. Because of this concern, 10 weeks was chosen as the longest interval between office visits and treatments in this and in our previous study of eyes with type 3 neovascularization.<sup>7-9,11</sup>

We now report on 18 eyes of 16 consecutive patients with newly diagnosed type 1 neovascularization treated with intravitreal bevacizumab and/or ranibizumab using a modified “treat and extend” dosing regimen and followed for at least 24 months.

## Materials and Methods

Waiver of authorization for use of protected health information for the referenced research and a waiver of consent for this retrospective chart review were obtained from the Institutional Review Board Committee of the Manhattan Eye Ear and Throat Hospital, New York, NY.

The diagnosis of type 1 neovascularization was performed by the treating physician (K.B.F.) based on the clinical, fluorescein angiographic, OCT, and, in some cases, indocyanine green angiographic findings. To be considered as having the type 1 neovascular pattern, eyes had to have clinical and OCT evidence of subretinal fluid and/or hemorrhage with an associated elevation of the RPE. Fluorescein angiography of these eyes exhibited late leakage and staining in an indistinct or “occult” pattern. When available, a well-delineated “plaque” found on indocyanine green angiography was correlated with the OCT finding of a vascularized pigment epithelial detachment (PED). Only patients with recent symptoms, hemorrhage, or evidence of recent disease progression were included in this

From the \*Edward S. Harkness Eye Institute, Columbia University College of Physicians and Surgeons, New York, New York; the †LuEsther T. Mertz Retinal Research Center, New York, New York; the ‡Department of Ophthalmology, University Hospital Zurich, Zurich, Switzerland; and the §Vitreous-Retina-Macula Consultants of New York, New York.

Supported by The Macula Foundation, Inc.

The authors have no conflicts of interest to disclose.

Reprint requests: K. Bailey Freund, MD, Vitreous Retina Macula Consultants of New York, 460 Park Avenue, 5th Floor, New York, NY 10022; e-mail: kbfnyf@aol.com

analysis. Patients treated previously with thermal laser, photodynamic therapy, or intravitreal pegaptanib (Macugen, Eyetech Pharmaceuticals Inc., Palm Beach Gardens, FL) or who presented with subfoveal fibrosis or atrophy, a history of vitrectomy, aphakia, a history of idiopathic or autoimmune-associated uveitis in either eye, or diabetic retinopathy more severe than mild nonproliferative stage were excluded from this study. Patients with preexisting cardiac or cerebrovascular conditions were not excluded from the study.

Patient characteristics, including age, sex, and presence or absence of disease in the contralateral eye, were recorded. Treatment consisted of intravitreal injection of 1.25 mg/0.05 mL bevacizumab or 0.5 mg/0.05 mL ranibizumab. For the purpose of this analysis, no distinction was made between the antiangiogenic drugs. Before intravitreal injection, topical anesthesia and surface disinfection with 5% povidone-iodine were performed. Intravitreal injections were administered at the time of diagnosis and subsequently following a protocol we have termed “treat and extend.” In contrast to a PrONTO-style regimen, patients did not have to return for monthly examinations. Instead, all the patients received at least 3 initial monthly injections followed by continued examination and treatment at intervals increasing by 2 weeks per visit once visual acuity was stable and clinical examination and OCT showed an absence of intra- and subretinal fluid at the foveola, resolution of all macular hemorrhage, and no further reduction in extrafoveal subretinal fluid. Because most eyes with the type 1 neovascular pattern continued to manifest PED and/or extrafoveal subretinal fluid after the initial 3 monthly injections, resolution of PEDs and/or extrafoveal subretinal fluid that was judged not to affect visual acuity was not required before the treatment intervals were lengthened. The treatment interval was extended to a maximum of 10 weeks “maintenance” unless clinical examination or OCT detected new hemorrhage, persistent/recurrent intra- or subretinal fluid at the foveola, or an increase in PED size and/or extrafoveal subretinal fluid. In those cases, the interval was shortened by 2 weeks and maintained at that duration provided this restored the clinical and OCT findings back to their previous level.

In this study, the main outcome measure was visual acuity after treatment. The number of injections needed and change in funduscopy or tomographic appearance were also assessed. Specifically, presence of a PED, subretinal fluid, sight-threatening submacular hemorrhage, defined as a subretinal hemorrhage of any size within 200  $\mu\text{m}$  of the foveal center or a subretinal hemorrhage of at least 2 disk areas within the temporal vascular arcades as well as presence and progression of GA were recorded.

Snellen visual acuity was measured by a certified ophthalmic technician. Snellen acuity was converted into logarithm of the minimum angle of resolution (logMAR) for statistical analysis at baseline and subsequently at 1, 2, 3, 24, and 36 months after injection of an antiangiogenic agent. Changes in logMAR-converted acuities were tested with a paired Student's *t*-test and accepted as significant if the *P* value was  $< 0.05$ .

Qualitative assessments of retinal thickness were initially made using Stratus OCT (Carl Zeiss Meditec, Dublin, CA). Later in the study, including at last follow-up visits, the Topcon OCT (Topcon 3D OCT-1000, Topcon Medical Systems, Paramus, NJ) or Spectralis HRA + OCT (Heidelberg Engineering, Inc., Heidelberg, Germany) was used.

Fundus photography, fluorescein angiograms, enface OCT scan images, and, where available, autofluorescence photography were examined for the presence and progression of GA overlying the areas of type 1 neovascularization.

## Results

Eighteen eyes of 16 consecutive patients with newly diagnosed type 1 neovascularization treated with intravitreal injections of bevacizumab and/or ranibizumab with at least 24-month follow-up were included in this study. Nine eyes completed 36-month follow-up.

Median patient age was 79 years (range, 67–90 years). Twelve of 16 patients were women. Four contralateral eyes had evidence of neovascular AMD and 2 of these eyes were treated with a “treat and extend” regimen and included in the study.

Median logMAR visual acuity at presentation was 0.53 (Snellen equivalent 20/69) and transiently improved to 0.41 (Snellen equivalent 20/51) at 1 month and maintained at this level during the next 2 months (Figure 1). The difference in logMAR-converted visual acuity was statistically significant at all early time points (paired 2-tailed *t*-test,  $P < 0.05$ ). At 24 months and after an average of 12 injections (range, 8–19), median logMAR visual acuity was 0.52, which was not statistically significantly different from baseline ( $P = 0.84$ ). For 9 eyes, 36-month follow-up data after an average of 20 injections (range, 18–25 injections) were available. Visual acuity remained stable compared with the 24-month time point with a logMAR of 0.52, which also was no different from the baseline visual acuity of 0.54 for these 9 eyes ( $P = 0.68$ ).

As mandated by our inclusion criteria, all eyes had serous or vascularized PEDs present at the initiation of anti-VEGF treatment. Ten of the 18 eyes had OCT evidence of intraretinal fluid on presentation, and 17 of

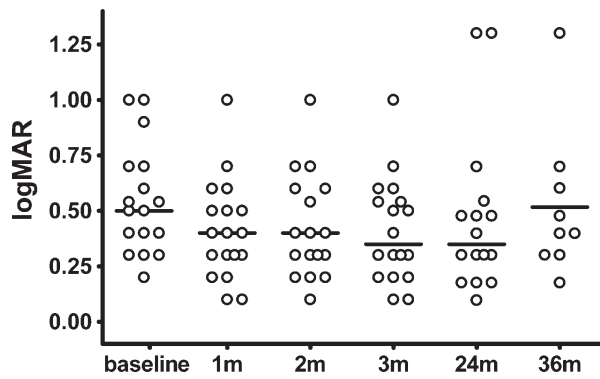


Fig. 1. Mean Snellen visual acuity of patients with type 1 choroidal neovascularization on a “treat and extend” regimen was assessed at baseline and 1, 2, 3, 24, and 36 months and plotted after conversion to logMAR. Horizontal lines represent the median.

18 eyes had subretinal fluid. In all these latter cases, the subretinal fluid involved the foveola. At the last follow-up examination, PEDs had resolved in only 3 of 18 eyes (17%). Most eyes (15 of 18 [83%]) continued to manifest extrafoveal subretinal fluid throughout the course of treatment. Of the 10 eyes with intraretinal fluid on presentation, complete resolution of this fluid occurred in only 3 eyes. In the remaining seven eyes, the intraretinal fluid resolved at the foveola but persisted elsewhere within the macula. Three eyes that initially presented without intraretinal fluid developed extrafoveal intraretinal fluid during the follow-up period. One eye developed a new PED while on the anti-VEGF treatment regimen.

Only 1 of 18 eyes developed GA overlying the areas of type 1 neovascularization. Accordingly, visual acuity decreased from 20/200 to 20/400 in this patient. During a cumulative observation period of 540 months, no eyes developed a sight-threatening submacular hemorrhage.

Figure 2 shows a representative case of a 75-year-old woman treated with the modified “treat and extend” dosing regimen (31 ranibizumab injections) during 36 months. The patient’s visual acuity remained stable despite persistent extrafoveal subretinal and intraretinal fluid.

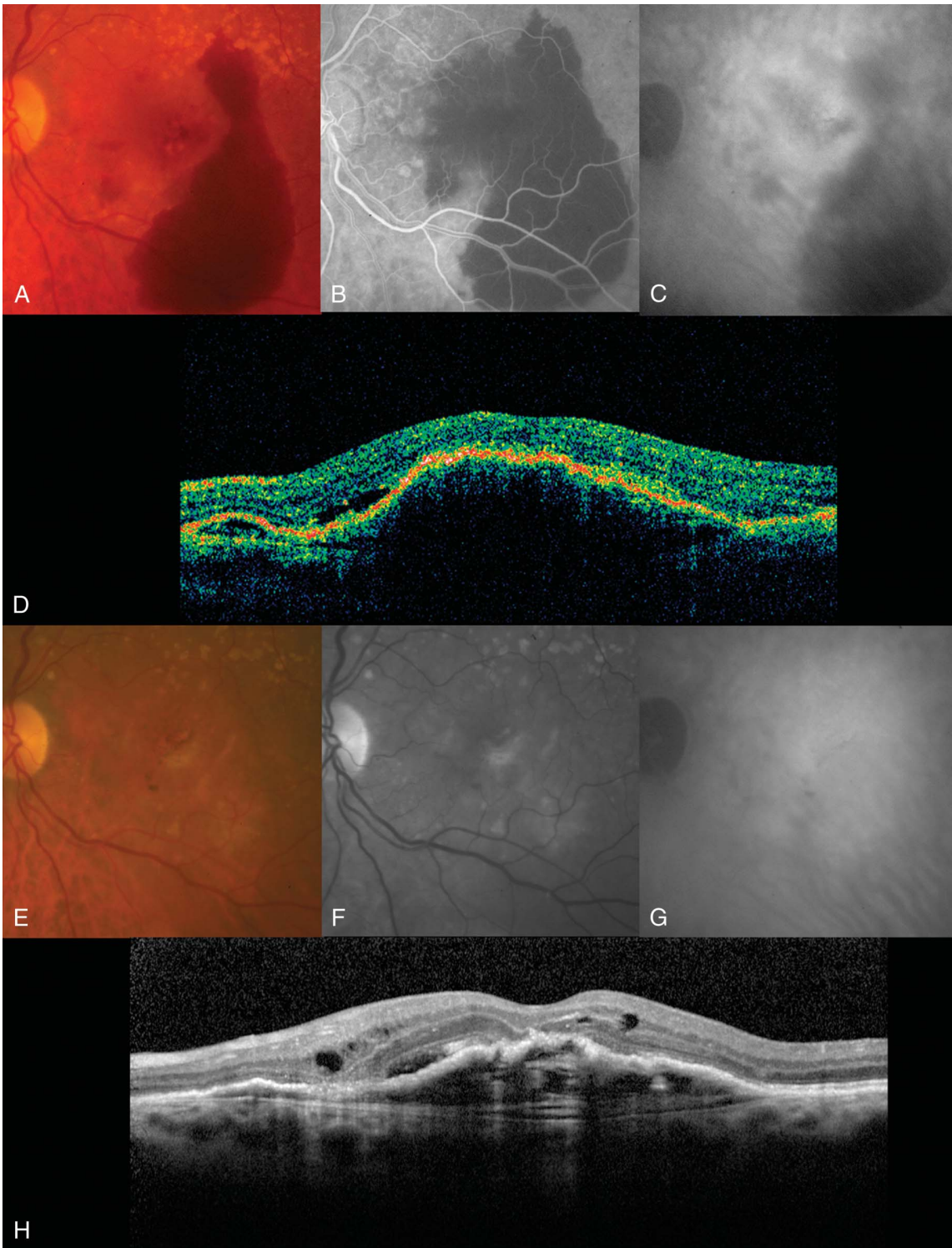
**Discussion**

Although intravitreal anti-VEGF therapy for neovascular AMD has produced visual outcomes superior to previous therapies, the optimal dosing regimen for these agents remains uncertain. Similarly, whether different neovascular patterns respond differently or require different dosing regimens remains unclear. Although monthly dosing of anti-VEGF agents gives visual outcomes superior to previous treatments,<sup>1,2</sup> it can place a tremendous burden on patients, retinal

practices, and the healthcare system as a whole. In addition, safety concerns about long-term monthly injections argue in favor of exploring alternative dosing regimens.

The only randomized, double-blind, sham-controlled trial investigating an alternative dosing scheme is the PIER study,<sup>4</sup> which showed that a regimen consisting of three initial monthly injections followed by mandated quarterly dosing gives inferior visual results compared with a monthly dosing regimen. Presumably, persistent and/or recurrent exudation occurring during the extended intervals between treatments was related to these inferior visual outcomes. The PrONTO study investigated a strategy intended to limit macular exudation in which three initial monthly injections were followed by dosing on an as-needed basis based on changes in visual acuity, clinical findings, and evaluation of OCT.<sup>5,6</sup> Although this open-label, nonrandomized study seemed to show that visual results similar to monthly dosing could be achieved with fewer injections, patients still required monthly visits, examinations, and OCTs. Furthermore, after the initial mandated series of three injections, fluid was allowed to reaccumulate at the foveola before the treatment was repeated, raising concerns regarding incremental long-term vision loss and the possibility of new hemorrhages occurring during long periods without VEGF inhibition.

Type 1 (occult) neovascularization tends to have a variable but often less aggressive natural course compared with type 2 (well-defined [classic]) neovascularization and type 3 (retinal angiomatous proliferation) neovascularization based on the presenting acuities and long-term natural history data. Patients with type 1 neovascularization who were enrolled in the MARINA study presented with a mean Early Treatment Diabetic Retinopathy Study letter score of 53 (Snellen equivalent 20/80<sup>-</sup>),<sup>1</sup> whereas patients with type 2 neovascularization enrolled in the ANCHOR study presented with only 45 letters (Snellen equivalent of 20/125).<sup>2</sup> It is well known that some patients who have evidence of type 1 (occult) neovascularization may never experience vision loss (often despite continued growth of the lesion),<sup>12</sup> or they may experience only a mild gradual visual decline. This benign natural course may relate to the theory that, in some eyes, the type 1 neovascular growth pattern may develop as a compensatory form of neovascularization providing nutritional support to an ischemic outer retina by recapitulating the normal choriocapillaris.<sup>3</sup> Our finding that only 1 of 18 eyes (6%) developed GA overlying the areas of type 1 neovascularization may support this hypothesis. However, in some eyes, the type 1 neovascular pattern



**Fig. 2.** Representative case. **A–D.** Left eye of a 75-year-old woman with 20/200 visual acuity at baseline. **A.** Color fundus photograph showing a large area of subretinal hemorrhage temporal to a vascularized PED. **B.** Fluorescein angiogram shows type 1 neovascularization nasal to blocked fluorescence resulting from sub-RPE and subretinal hemorrhage. **C.** Late indocyanine green angiogram shows a plaque of choroidal neovascularization representing type 1 neovascularization. **D.** Spectral domain OCT scan (Topcon 3D) shows a vascularized PED and subretinal fluid. **E–H.** Images at 36-month follow-up dosed according to the “treat and extend” protocol. Visual acuity is stable. **E.** Color fundus photograph. **F.** Red-free photograph shows resolution of the hemorrhage. **G.** Late indocyanine green angiogram shows a persistent plaque representing type 1 neovascularization. **H.** Spectral domain OCT scan (Heidelberg) shows persistent sub- and intraretinal fluid.

# Explore Litigation Insights

Docket Alarm provides insights to develop a more informed litigation strategy and the peace of mind of knowing you're on top of things.

## Real-Time Litigation Alerts



Keep your litigation team up-to-date with **real-time alerts** and advanced team management tools built for the enterprise, all while greatly reducing PACER spend.

Our comprehensive service means we can handle Federal, State, and Administrative courts across the country.

## Advanced Docket Research



With over 230 million records, Docket Alarm's cloud-native docket research platform finds what other services can't. Coverage includes Federal, State, plus PTAB, TTAB, ITC and NLRB decisions, all in one place.

Identify arguments that have been successful in the past with full text, pinpoint searching. Link to case law cited within any court document via Fastcase.

## Analytics At Your Fingertips



Learn what happened the last time a particular judge, opposing counsel or company faced cases similar to yours.

Advanced out-of-the-box PTAB and TTAB analytics are always at your fingertips.

## API

Docket Alarm offers a powerful API (application programming interface) to developers that want to integrate case filings into their apps.

## LAW FIRMS

Build custom dashboards for your attorneys and clients with live data direct from the court.

Automate many repetitive legal tasks like conflict checks, document management, and marketing.

## FINANCIAL INSTITUTIONS

Litigation and bankruptcy checks for companies and debtors.

## E-DISCOVERY AND LEGAL VENDORS

Sync your system to PACER to automate legal marketing.