

94/1

British Journal of
Ophthalmology



bjo.bmj.com

BMJ | Journals



Cover image: Undine and drop bottles.
Courtesy of Mr Richard Keeler, Curator,
Museum of the Royal College of
Ophthalmologists. See p 26.

Editors-in-Chief

Harminder S Dua (UK)
Arun D Singh (USA)

Website Editor

Robert Bhisitkul (USA)

Translation Editors

Evelyn Fu (USA)
José Gomes (Brazil)
Alvin Kwok (Hong Kong)
Merce Morral Palau (Spain)
David Pelayes (Argentina)
Daniel de Souza Pereira (Brazil)

Editorial Office

BMJ Publishing Group Ltd,
BMA House, Tavistock Square,
London WC1H 9JR, UK

T: +44 (0)20 7383 6170

F: +44 (0)20 7383 6668

E: bjo@bmjgroup.com

ISSN: 0007-1161 (print)

ISSN: 1468-2079 (online)

Impact factor: 2.859

Disclaimer: British Journal of Ophthalmology is owned and published by BMJ Publishing Group Ltd, a wholly owned subsidiary of the British Medical Association. The owner grants editorial freedom to the Editor of British Journal of Ophthalmology.

British Journal of Ophthalmology follows guidelines on editorial independence produced by the World Association of Medical Editors and the code on good publication practice of the Committee on Publication Ethics.

British Journal of Ophthalmology is intended for medical professionals and is provided without warranty, express or implied. Statements in the journal are the responsibility of their authors and advertisers and not authors' institutions, the BMJ Publishing Group Ltd or the BMA unless otherwise specified or determined by law. Acceptance of advertising does not imply endorsement.

To the fullest extent permitted by law, the BMJ Publishing Group Ltd shall not be liable for any loss, injury or damage resulting from the use of British Journal of Ophthalmology or any information in it whether based on contract, tort or otherwise. Readers are advised to verify any information they choose to rely on.

Copyright: © 2010 BMJ Publishing Group Ltd. All rights reserved; no part of this publication may be reproduced, stored in a retrieval system or transmitted in any form or by any means, electronic, mechanical, photocopying, recording or otherwise without the prior permission of British Journal of Ophthalmology.

British Journal of Ophthalmology is published by BMJ Publishing Group Ltd, typeset by The Charlesworth Group and printed in the UK on acid-free paper by Latimer Trend & Co Ltd, Plymouth.

British Journal of Ophthalmology (ISSN 0007-1161) is published monthly by BMJ Publishing Group and distributed in the US by Mercury International Ltd. Periodicals postage paid at Rahway, NJ. POSTMASTER: Send address changes to BJO, Mercury International Ltd, 365 Blair Road, Avenel, NJ 07001, USA

Editorial

- 1 Ocular anaesthesia and the never-ending story
P Athanasiov, T Henderson

Review

- 2 Ranibizumab (Lucentis) in neovascular age-related macular degeneration: evidence from clinical trials
P Mitchell, J-F Korobelnik, P Lanzetta, F G Holz, C Prunte, U Schmidt-Erfurth, Y Tano, S Wolf

Global issues

- 14 Mapping trachoma in Nasarawa and Plateau States, central Nigeria
J D King, N Jip, Y S Jugu, A Othman, A F Rodgers, D Y Dajom, E Miri, P M Emerson
- 20 Increased hyperopia with ageing based on cycloplegic refractions in adults: the Tehran Eye Study
H Hashemi, R Iribarren, I G Morgan, M Khabazkhoob, K Mohammad, A Fotouhi

Innovations

- 24 Computer simulation-assisted rotational autokeratoplasty with pupillary enlargement for management of cases with partial corneal opacification
T Agarwal, N Sharma, V Jhanji, R B Vajpayee

Cover illustration

- 26 All for a drop: Undines and drop bottles
R Keeler, A D Singh, H S Dua

Original articles

Clinical science

- 28 A novel Ocular Anaesthetic Scoring System, OASS, tool to measure both motor and sensory function following local anaesthesia
J Cehajic-Kapetanovic, P N Bishop, S Liyanage, T King, M Muldoon, I M Wearne
- 33 Intraocular pressures after ketamine and sevoflurane in children with glaucoma undergoing examination under anaesthesia
L Jones, V Sung, G Lascaratos, H Nagi, R Holder
- 36 A pilot randomised controlled trial comparing the post-operative pain experience following vitrectomy with a 20-gauge system and the 25-gauge transconjunctival system
L Wickham, C Bunce, A S Kwan, J Bainbridge, G W Aylward

- 41 Macular morphology and visual acuity after macular hole surgery with or without internal limiting membrane peeling
U C Christensen, K Kroyer, B Sander, T M Jorgensen, M Larsen, M la Cour
- 48 Subretinal coapplication of recombinant tissue plasminogen activator and bevacizumab for neovascular age-related macular degeneration with submacular haemorrhage
F Treumer, C Klatt, J Roider, J Hillenkamp
- 54 New patterns of retinal collateral circulation are exposed by a retinal functional imager (RFI)
G Landa, R B Rosen
- 59 Relationship between different fluorescein and indocyanine green angiography features in multiple evanescent white dot syndrome
R dell'Omo, R Wong, M Marino, K Konstantopoulou, C Pavesio
- 64 A comparison between microperimetry and standard achromatic perimetry of the central visual field in eyes with glaucomatous paracentral visual-field defects
V C Lima, T S Prata, C G V De Moraes, J Kim, W Seiple, R B Rosen, J M Liebmann, R Ritch
- 68 The sensitivity and specificity of Heidelberg Retina Tomograph parameters to glaucomatous progression in disc photographs
V Saarela, A Falck, P J Airaksinen, A Tuulonen
- 74 Efficacy and tolerability of bimatoprost versus travoprost in patients previously on latanoprost: a 3-month, randomised, masked-evaluator, multicentre study
J A Kammer, B Katzman, S L Ackerman, D A Hollander
- 80 Using diurnal intraocular pressure fluctuation to assess the efficacy of fixed-combination latanoprost/timolol versus latanoprost or timolol monotherapy
R Varma, L-J Hwang, J W Grunden, G W Bean

MORE CONTENTS ►



This article has been chosen by the Editor to be of special interest or importance and is freely available online.

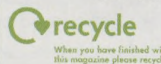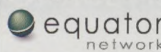


Articles carrying the Unlocked Logo are freely available online under the BMJ Journals unlocked scheme. See <http://bjo.bmj.com/info/unlocked.dtl>

COPE COMMITTEE ON PUBLICATION ETHICS

This journal is a member of and subscribes to the principles of the Committee on Publication Ethics

www.publicationethics.org.uk



- 85** The effect of socio-economic deprivation on severity of glaucoma at presentation
W S Ng, P K Agarwal, S Sidiki, L McKay, J Townend, A Azuara-Blanco
- 88** Visual training of cerebral blindness patients gradually enlarges the visual field
D P Bergsma, G van der Wildt
- 97** Scope of super-resolution in central vision
L Frisén
- 101** Evaluation of the impact of intracorneal ring segments implantation on the quality of life of patients with keratoconus using the NEI-RQL (National Eye Institute Refractive Error Quality of life) instrument
J de Freitas Santos Paranhos, M P Ávila, A Paranhos Jr, P Schor
- 106** Evaluation of the Lenstar LS 900 non-contact biometer
L P J Cruysberg, M Doors, F Verbakel, T T J M Berendschot, J De Brabander, R M M A Nuijts
- 111** Endophthalmitis following open globe injury
Y Zhang, M N Zhang, C H Jiang, Y Yao, K Zhang
- 115** Peripapillary retinal nerve fibre layer thickness profile in subjects with myopia measured using the Stratus optical coherence tomography
M J Kim, E J Lee, T-W Kim
- 121** Ophthalmological findings in children and young adults with genetically verified mitochondrial disease
M A Grönlund, A K Seyedi Honarvar, S Andersson, A R Moslemi, A Oldfors, E Holme, M Tulinius, N Darin
- 128** A prospective comparison of fine-needle aspiration cytopathology and histopathology in the diagnosis of orbital mass lesions
Z A Karcioğlu, J C Fleming, B G Haik

Education

- 131** Papilloedema and vision loss with elevated cerebrospinal fluid protein in a patient with systemic lupus erythematosus: diagnosis and management challenges
E K Deschler, N R Miller, P S Subramanian

PostScript

- 133** Letters
- 139** Mailbox



Take a closer look at the latest research

The British Journal of Ophthalmology keeps you right up to date with the clinical investigations and observations related to ophthalmology, so you'll want the guarantee of reading it every month.

Why not recommend the journal to your librarian or better still, obtain your own personal subscription? You will receive a paper copy every month as well as online access for just £169 a year (€228, \$330). Too much paper on your desk already? An online subscription is just £106 (€143, \$207).

Visit group.bmj.com/group/subs-sales - your subscription to this first class journal is just a few clicks away.

bjournal.bmj.com BMJ Journals

Ranibizumab (Lucentis) in neovascular age-related macular degeneration: evidence from clinical trials

P Mitchell,¹ J-F Korobelnik,² P Lanzetta,³ F G Holz,⁴ C Prunte,⁵ U Schmidt-Erfurth,⁵ Y Tano,⁶ S Wolf⁷

¹ Department of Ophthalmology, University of Sydney, Sydney, Australia; ² Department of Ophthalmology, Centre Hospitalier Universitaire de Bordeaux, Bordeaux, France; ³ Department of Ophthalmology, University of Udine, Udine, Italy; ⁴ Department of Ophthalmology, University of Bonn, Bonn, Germany; ⁵ Department of Ophthalmology and Optometry, Medical University of Vienna, Vienna, Austria; ⁶ Department of Ophthalmology, Osaka University Medical School, Osaka, Japan; ⁷ Department of Ophthalmology, Inselspital, University of Bern, Bern, Switzerland

Correspondence to: Professor P Mitchell, Eye Clinic (B4A), Westmead Hospital, Hawkesbury Road, Westmead, NSW, 2145, Australia; paul_mitchell@wmi.usyd.edu.au

Accepted 29 April 2009
Published Online First
20 May 2009

ABSTRACT

Background: Neovascular age-related macular degeneration (AMD) has a poor prognosis if left untreated, frequently resulting in legal blindness. Ranibizumab is approved for treating neovascular AMD. However, further guidance is needed to assist ophthalmologists in clinical practice to optimise treatment outcomes.

Methods: An international retina expert panel assessed evidence available from prospective, multicentre studies evaluating different ranibizumab treatment schedules (ANCHOR, MARINA, PIER, SAILOR, SUSTAIN and EXCITE) and a literature search to generate evidence-based and consensus recommendations for treatment indication and assessment, retreatment and monitoring.

Results: Ranibizumab is indicated for choroidal neovascular lesions with active disease, the clinical parameters of which are outlined. Treatment initiation with three consecutive monthly injections, followed by continued monthly injections, has provided the best visual-acuity outcomes in pivotal clinical trials. If continued monthly injections are not feasible after initiation, a flexible strategy appears viable, with monthly monitoring of lesion activity recommended. Initiation regimens of fewer than three injections have not been assessed. Continuous careful monitoring with flexible retreatment may help avoid vision loss recurring. Standardised biomarkers need to be determined.

Conclusion: Evidence-based guidelines will help to optimise treatment outcomes with ranibizumab in neovascular AMD.

Neovascular age-related macular degeneration (AMD) causes severe and irreversible vision loss, and frequently results in legal blindness, with resulting considerable economic burden.¹⁻⁵

Pharmacotherapies against vascular endothelial growth factor-A (VEGF-A), a key factor in the pathogenesis of choroidal neovascularisation (CNV), have been introduced to treat neovascular AMD.⁶⁻¹⁰ Pegaptanib sodium (Macugen, EyeTech, New York), a selective antagonist of the 165 isoform of VEGF-A,¹¹ was approved by the Food and Drug Administration (FDA) in December 2004. Ranibizumab (Lucentis, Novartis Pharma AG, Basel, Switzerland and Genentech, South San Francisco, California), a recombinant, humanised, monoclonal antibody Fab fragment that inhibits all biologically active VEGF-A isoforms, was approved by the FDA in June 2006 (monthly 0.5 mg intravitreal injection).¹²⁻¹⁴ Bevacizumab (Avastin, Genentech), a full-length monoclonal antibody against all VEGF-A isoforms, was approved by the FDA for colorectal cancer in 2004 and later used intravitreally off-label in neovascular AMD.¹⁵⁻¹⁶

Head-to-head ranibizumab and bevacizumab trials are under way but are not scheduled to report until 2010 (CATT (NCT00593450), VIBERA (NCT00559715), IVAN and GEFAL trials).

Although preliminary guidelines for anti-VEGF therapies exist,¹⁶⁻²² more comprehensive clinical practice guidelines on applying ranibizumab are needed to optimise patient outcomes. Ranibizumab Phase III clinical trials in neovascular AMD have studied different treatment schedules, doses and populations, and this review applies the trial evidence to ranibizumab use in clinical practice. We evaluated the licensed 0.5 mg of ranibizumab dose, shown to be more effective than 0.3 mg in pivotal trials,¹²⁻¹³⁻²³ and focused solely on ranibizumab because: pegaptanib showed less visual-acuity (VA) decline than sham injection, although on average treated patients continued to experience vision loss;¹¹ bevacizumab use in neovascular AMD currently remains off-label with relatively few reported clinical trial data and, to date, no completed large, prospective, randomised clinical trials.¹⁶

RANKING AND SOURCES OF EVIDENCE

Level I indicates strong evidence (eg, well-designed, randomised, controlled clinical trials that address the issue in question); level II indicates substantial evidence that lacks some qualities (eg, derived from randomised clinical trials but with flaws, such as absent control group or sufficiently long follow-up); level III indicates relatively weak evidence (eg, derived from non-comparative studies without controls, descriptive studies, panel consensus or expert opinion).

A PubMed literature search on 31 October 2008 (restricted to English literature; no date restriction) using the MeSH term macular degeneration (multi) and the words vascular endothelial growth factor, ranibizumab or Lucentis yielded 187 papers. The Cochrane Register of Controlled Trials and the Cochrane Database of Systematic Reviews were also searched, yielding 16 and four references, respectively. A total of 129 relevant articles were selected, from which 74 were selected for detailed assessment. Additional data from abstracts considered relevant to this manuscript were included in the analysis. From this detailed literature search, the primary sources of data were all level I evidence: the Phase III trials MARINA¹³ and ANCHOR,¹²⁻²⁴ including quality-of-life and subgroup analyses,²⁵⁻²⁸ and the Phase IIIb trials PIER,²³ SAILOR Cohort 1,²⁹ SUSTAIN (assigned level II evidence as only interim data currently available),³⁰ and EXCITE³¹. A small, open-label study

Table 1 Recommendations for treatment indication with ranibizumab

Parameters for recommended indication	Evidence	Level of evidence
Predominantly classic, minimally classic and occult (with no classic component) CNV*	All CNV types included in PIER, EXCITE, SUSTAIN, SAILOR and PrONTO; predominantly classic CNV in ANCHOR and minimally classic and occult (with no classic component) CNV in MARINA	Level I evidence (MARINA, ANCHOR, PIER, EXCITE and SAILOR), supported by level II (SUSTAIN) and III evidence (PrONTO)
Subfoveal (including juxtafoveal) lesions	Subfoveal CNV (defined as including the foveal centre within the boundaries of the CNV) was an inclusion criteria in all studies	Level I evidence (MARINA, ANCHOR, PIER, EXCITE and SAILOR), supported by level II (SUSTAIN) and III evidence (PrONTO)
Active disease	Active disease was an inclusion criteria in the MARINA and PIER studies†	Level I evidence (MARINA and PIER) and level III evidence
Abnormal retinal thickness with evidence of intraretinal or subretinal fluid by OCT		
Intraretinal or subretinal haemorrhage		
Enlargement of CNV size on FA unless solely due to dry, fibrotic staining		
New/persistent leakage on FA		
Any baseline VA	Baseline VA 20/40 to 20/320 was an inclusion criterion in all studies‡	Level I evidence (MARINA, ANCHOR, PIER and SAILOR), supported by level II evidence (SUSTAIN)
Efficacy was seen over the whole VA range studied in trials, so it is expected that benefit would occur independently of VA whenever progressive vision loss is expected due to an active lesion	Baseline VA better than 20/40 or worse than 20/320: no clinical data available, expert opinion based on extrapolation of clinical evidence	Level III evidence
Serous PED, RAP or PCV can be considered for ranibizumab treatment but might not respond as well as expected from average trial outcomes	No detailed clinical trial evidence currently available	Level III evidence

*In the MARINA and PIER studies, evidence of recent disease progression was required for eyes with minimally classic or occult (with no classic) CNV.

†Active disease was defined as meeting any of the following criteria: (1) $\geq 10\%$ increase in lesion size by comparing a fluorescein angiogram performed within 1 month preceding day 0, inclusive, compared with a fluorescein angiogram performed within 6 months preceding day 0, inclusive; (2) resulting in VA loss of >1 Snellen line (or equivalent) and occurring at any time within the prior 6 months; (3) subretinal haemorrhage associated with CNV within 1 month preceding day 0; or (4) (not included in MARINA criteria) classic CNV comprised $\geq 50\%$ of the CNV lesion area.

‡Snellen equivalent assessed by Early Treatment Diabetic Retinopathy Study charts; the PrONTO study included patients with baseline VA from 20/40 to 20/400.

CNV, choroidal neovascularisation; FA, fluorescein angiography; OCT, optical coherence tomography; PCV, polypoidal choroidal vasculopathy; PED, pigment epithelial detachment; RAP, retinal angiomatous proliferation; VA, visual acuity.

(PrONTO; level III evidence) also provided relevant information,³² and appropriate abstracts covering recent Phase III trial findings (unpublished) were included.

NATURAL HISTORY AND ASSESSMENT OF NEOVASCULAR AMD

What is the natural history or prognosis of untreated neovascular AMD?

A systematic review covering the period 1980 to 2005 assessed studies reporting disease progression outcomes for untreated patients with neovascular age-related macular degeneration (AMD), by using random effects meta-analyses.⁴ Of 53 studies included, there were 28 randomised clinical trials (RCTs), totalling 4362 patients with untreated neovascular AMD. The most recent RCTs of anti-vascular endothelial growth factor therapy (VISION,¹¹ MARINA¹³ and PIER²³) were not included. The systematic review found that, on average, one logarithm of the maximum angle of resolution (logMAR) line of visual acuity (VA) was lost by 3 months, three lines by 1 year and four lines by 2 years. This prognosis is relatively similar to that in MARINA, in which sham-treated eyes lost an average of two lines by 1 year and three lines by 2 years and in PIER, in which sham-treated eyes lost an average of three lines by 1 year. In this review, a doubling of the visual angle was found in the first year. At baseline, 20% of eyes already had a VA $<20/200$, but this proportion rose to 76% by 3 years.⁴

How should neovascular AMD be diagnosed?

Accurate diagnosis and classification of neovascular AMD using recommended criteria is critical. Assessment should include: history (duration and characteristics of visual symptoms); VA; stereoscopic biomicroscopic slit-lamp fundus examination (78 D

or similar lens); fluorescein angiography (FA); and, where possible, optical coherence tomography (OCT).

Logarithm of the minimum angle of resolution (logMAR) VA is preferable to Snellen VA due to its greater sensitivity, ordered progression of letter size (five equally readable letters per line), reproducibility and ability to compare with published trial data.³³ The Snellen chart has several limitations such as visual crowding and variable legibility of the letters. Non-geometric letter size progression and a variable number of letters per line also prevent Snellen outcomes from being easily equated to letters or lines of VA change.^{34, 35}

For initial diagnosis, FA is deemed mandatory to detect CNV, exclude non-AMD causes (eg, neovascularisation due to myopia, pseudo-xanthoma elasticum, birdshot choroidopathy, etc, which could respond differently to AMD neovascularisation) and determine CNV extent, type, size, location, degree of leakage and proportion of various lesion components.^{18, 36} OCT is also strongly recommended initially to define the extent of retinal thickening and both the localisation and qualitative pattern of extracellular fluid accumulation.^{37, 38} Indocyanine Green (ICG) angiography may also be useful in selected cases, eg, when polypoidal choroidal vasculopathy (PCV)^{4, 39, 40} or retinal angiomatous proliferation (RAP)⁴¹⁻⁴³ is suspected, or the extent of CNV in occult lesions is unclear.

RANIBIZUMAB THERAPY FOR NEOVASCULAR AMD: INDICATIONS AND CONTRAINDICATIONS

Which neovascular AMD lesions should be considered for ranibizumab treatment?

All three major CNV subtypes (predominantly classic, occult (with no classic component) and minimally classic) respond to ranibizumab^{12, 13} (table 1). Ranibizumab is primarily indicated

Explore Litigation Insights

Docket Alarm provides insights to develop a more informed litigation strategy and the peace of mind of knowing you're on top of things.

Real-Time Litigation Alerts



Keep your litigation team up-to-date with **real-time alerts** and advanced team management tools built for the enterprise, all while greatly reducing PACER spend.

Our comprehensive service means we can handle Federal, State, and Administrative courts across the country.

Advanced Docket Research



With over 230 million records, Docket Alarm's cloud-native docket research platform finds what other services can't. Coverage includes Federal, State, plus PTAB, TTAB, ITC and NLRB decisions, all in one place.

Identify arguments that have been successful in the past with full text, pinpoint searching. Link to case law cited within any court document via Fastcase.

Analytics At Your Fingertips



Learn what happened the last time a particular judge, opposing counsel or company faced cases similar to yours.

Advanced out-of-the-box PTAB and TTAB analytics are always at your fingertips.

API

Docket Alarm offers a powerful API (application programming interface) to developers that want to integrate case filings into their apps.

LAW FIRMS

Build custom dashboards for your attorneys and clients with live data direct from the court.

Automate many repetitive legal tasks like conflict checks, document management, and marketing.

FINANCIAL INSTITUTIONS

Litigation and bankruptcy checks for companies and debtors.

E-DISCOVERY AND LEGAL VENDORS

Sync your system to PACER to automate legal marketing.