

## Technique of "open" distal anastomosis for ascending and transverse arch resection

---

Denton A. Cooley, M.D., and James J. Livesay, M.D.

To ensure continuous cerebral perfusion during resection and graft replacement in most patients with lesions that involve the ascending and proximal aortic arch, surgical repair requires placement of the distal occluding clamp just proximal to the origin of the innominate artery. Often, however, the pathologic process extends into the arch or beyond and may involve the origin of the innominate, left carotid, and left subclavian arteries. This practice does not ensure the restoration of normal perfusion to arch vessels and may encourage cerebral embolization from atherosclerotic debris; for acute dissecting aneurysms, it may lead to further disruption and hemorrhage from friable dissected layers of the aorta. A solution to these technical problems may be provided by using circulatory arrest and by performing the distal anastomosis by an "open" technique.

### Method

After the median sternotomy is made, the extent of the aortic lesion appraised, and heparin administered, cannulation of a common femoral artery is performed. Selection of the site for the venous outflow cannula or cannulae depends upon the anatomic findings. The choices include the right atrium, the outflow tract of the right ventricle, and/or the inferior vena cava via a common femoral vein.

From the Division of Surgery, Texas Heart Institute of St. Luke's Episcopal and Texas Children's Hospitals, Houston, Texas

Address for reprints: Denton A. Cooley, M.D., Texas Heart Institute, P.O. Box 20345, Houston, Texas 77025

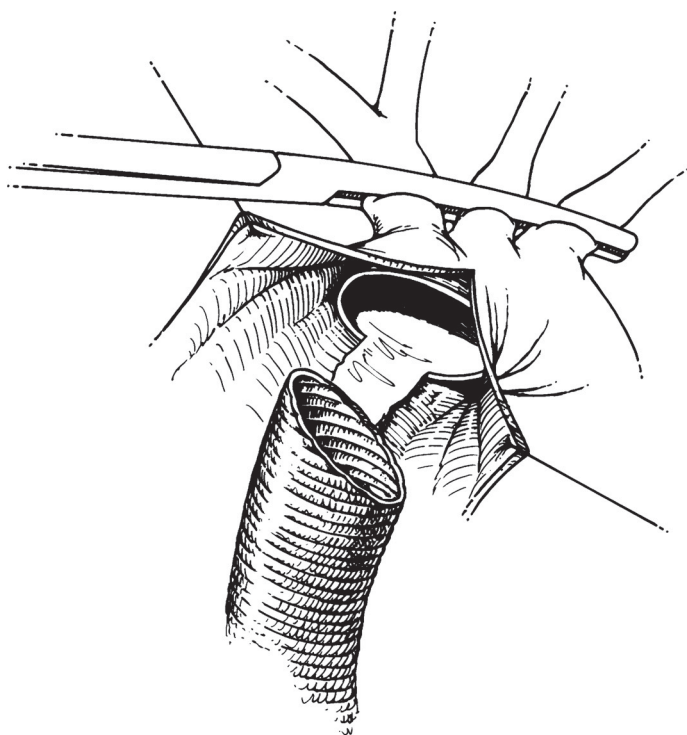
Cardiovascular Diseases, Bulletin of the Texas Heart Institute

Volume 8

Number 3

September 1981

421



**Fig. 1** During hypothermic circulatory arrest at 23 to 24°C and with the arch vessels clamped, the aneurysm is opened widely to expose the distal transverse arch. In the illustration, a dissecting aneurysm is depicted with the *true* and *false* lumens.

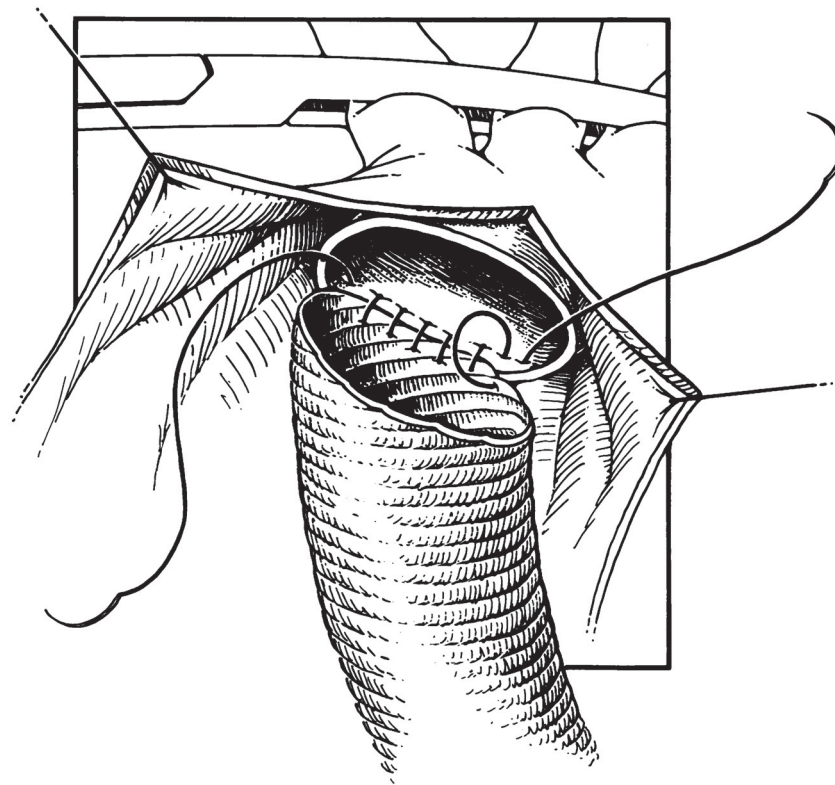
### Cooling

Cardiopulmonary bypass is started, and, using the heat exchanger, the patient's body temperature is lowered to 24°C. During this interval, the arch vessels are mobilized. At the appropriate time, the vessels are cross-clamped (Fig. 1). The arterial return pump is discontinued and the venous outflow is occluded.

### Excision and Repair

An incision is made in the ascending aorta and a suction tip is inserted to withdraw blood from the aorta and left ventricle. A left atrial sump may also be used to ensure a bloodless field around the aortic root. To accommodate the aspirated blood, additional reservoir space is needed in the extracorporeal circuit.

The ascending aorta is opened widely and the pathologic condition of the interior of the transverse arch and origin of the arch vessels is appraised (Fig. 1). For dissecting aneurysms, the definition of the true and



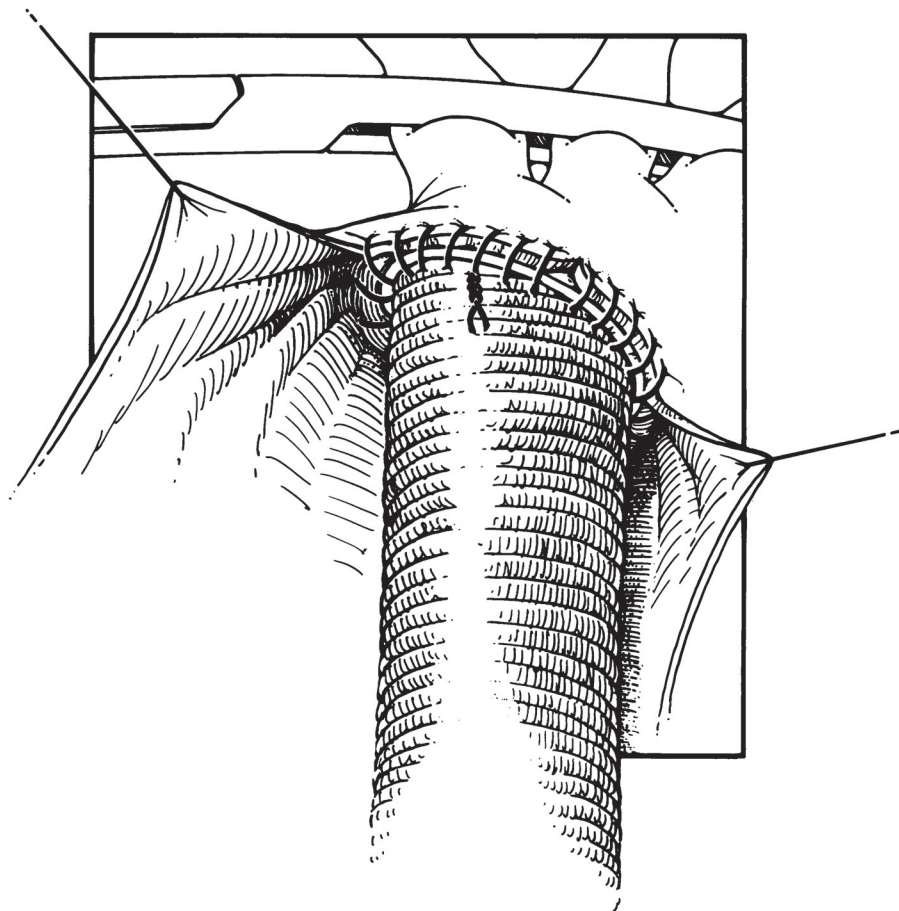
**Fig. 2** The "open" anastomosis facilitates proper management of the double lumen aorta. A continuous polypropylene suture closes the false lumen and directs the entire aortic flow into the true lumen.

the dissected false lumen must be established. Usually the origin of the arch tributaries is spared by the lesion whether it is of a dissecting or atherosclerotic type.

### **Graft**

A low porosity Veri-soft Woven Dacron Graft\* of appropriate size should already have been selected and prepared by preclotting. We use fresh autologous plasma to soak the graft and then place it in a steam autoclave for five minutes. This method ensures that bleeding through the interstices of the fabric will be minimal.

\*Meadox Medicals, Inc., Oakland, New Jersey, U.S.A.



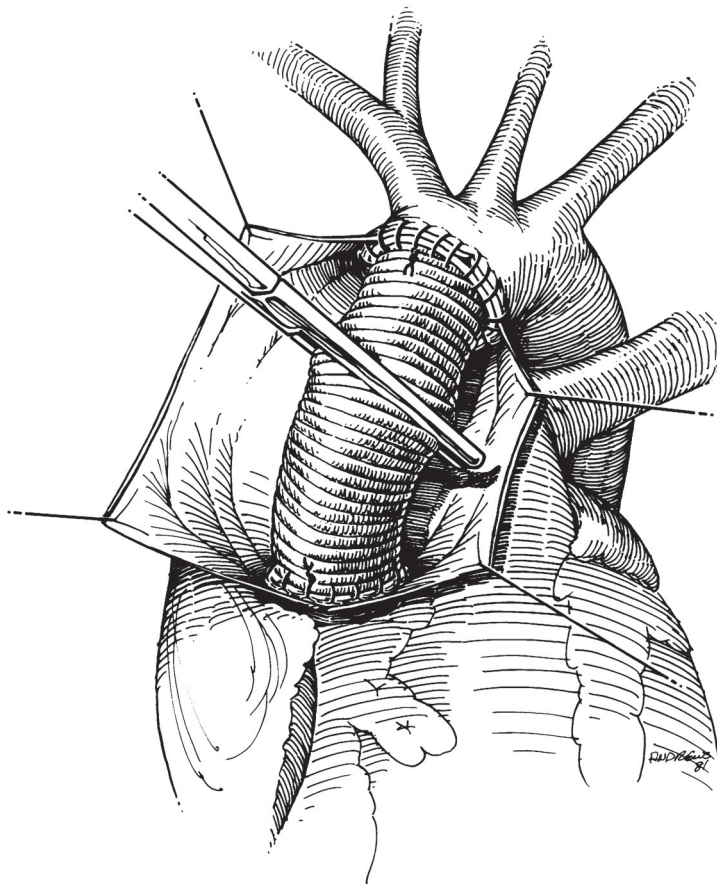
**Fig. 3** The distal anastomosis is completed and arterial return gradually fills the aorta and proximal segment of the fabric graft to eliminate entrapped air.

### **Anastomosis**

The distal anastomosis is performed with a 48-inch polypropylene suture of either 3-0 or 2-0 diameter, depending somewhat upon the firmness of the tissues. For dissecting aneurysms, the single suture line incorporates both the inner and outer layers of the aortic wall (Fig. 2). Particular attention is made to ensure that the *true* lumen of the aorta is in continuity with the lumen of the innominate and carotid arteries and that the false lumen is obliterated at the suture line. Invaginating or telescoping the graft inside the true lumen is advisable. The continuous suture completes the distal anastomosis (Fig. 3).

To eliminate air from the descending aorta and arch, when the blood level has reached the midportion of the graft, cardiopulmonary bypass is started slowly, and a clamp is placed across the graft as the arch vessels are unclamped (Fig. 4). The period of circulatory interruption is usually





**Fig. 4** A clamp is placed across the graft and the clamp is removed from the arch vessels. The proximal anastomosis is then performed while the patient is being rewarmed.

less than 10 minutes in our patients, but longer periods should be safe without producing anoxic changes in the central nervous system.

Rewarming continues as the proximal anastomosis is performed. If the patient has aortic valve pathology or annuloaortic ectasia, the valve or the entire aortic root may be replaced with a composite valve-containing conduit. Cardiopulmonary bypass is continued until the patient's temperature has risen to 36 or 37°C. After the venous cannulae are removed, the heparin is counteracted by Coumadin. Bleeding through the graft is minimal. When general hemostasis has been accomplished, the sternotomy incision is closed in the usual manner.

#### **Comment**

This technique of open anastomosis has been used in 18 patients without mortality and with only occasional transient neurologic complica-

# Explore Litigation Insights

Docket Alarm provides insights to develop a more informed litigation strategy and the peace of mind of knowing you're on top of things.

## Real-Time Litigation Alerts



Keep your litigation team up-to-date with **real-time alerts** and advanced team management tools built for the enterprise, all while greatly reducing PACER spend.

Our comprehensive service means we can handle Federal, State, and Administrative courts across the country.

## Advanced Docket Research



With over 230 million records, Docket Alarm's cloud-native docket research platform finds what other services can't. Coverage includes Federal, State, plus PTAB, TTAB, ITC and NLRB decisions, all in one place.

Identify arguments that have been successful in the past with full text, pinpoint searching. Link to case law cited within any court document via Fastcase.

## Analytics At Your Fingertips



Learn what happened the last time a particular judge, opposing counsel or company faced cases similar to yours.

Advanced out-of-the-box PTAB and TTAB analytics are always at your fingertips.

## API

Docket Alarm offers a powerful API (application programming interface) to developers that want to integrate case filings into their apps.

## LAW FIRMS

Build custom dashboards for your attorneys and clients with live data direct from the court.

Automate many repetitive legal tasks like conflict checks, document management, and marketing.

## FINANCIAL INSTITUTIONS

Litigation and bankruptcy checks for companies and debtors.

## E-DISCOVERY AND LEGAL VENDORS

Sync your system to PACER to automate legal marketing.