

Ranibizumab for Macular Edema Due to Retinal Vein Occlusions: Implication of VEGF as a Critical Stimulator

Peter A Campochiaro¹, Gulnar Hafiz¹, Syed Mahmood Shah¹, Quan Dong Nguyen¹, Howard Ying¹, Diana V Do¹, Edward Quinlan¹, Ingrid Zimmer-Galler¹, Julia A Haller¹, Sharon D Solomon¹, Jennifer U Sung¹, Yasmin Hadi¹, Kashif A Janjua¹, Nida Jawed¹, David F Choy² and Joseph R Arron²

¹Department of Ophthalmology, Johns Hopkins University School of Medicine, Baltimore, Maryland, USA; ²Immunology, Tissue Growth, and Repair Diagnostics and Biomarkers Genentech, Inc., South San Francisco, California, USA

Macular edema is a major cause of vision loss in patients with central retinal vein occlusion (CRVO) or branch retinal vein occlusion (BRVO). It is not clear how much of the edema is due to hydrodynamic changes from the obstruction and how much is due to chemical mediators. Patients with macular edema due to CRVO ($n = 20$) or BRVO ($n = 20$) were randomized to receive three monthly injections of 0.3 or 0.5 mg of ranibizumab. At the primary endpoint, month 3, the median improvement in letters read at 4m was 17 in the 0.3-mg group and 14 in the 0.5-mg group for CRVO, and 10 and 18, respectively for the BRVO group. Optical coherence tomography (OCT) showed that compared to injections of 0.3 mg, injections of 0.5 mg of ranibizumab tended to cause more rapid reductions of central retinal thickening that lasted longer between injections, but in 3 months, excess central retinal thickening which is a quantitative assessment of the macular edema, was reduced by ~90% in all four treatment groups. There was no correlation between the amount of improvement and duration of disease or patient age at baseline, but there was some correlation between the aqueous vascular endothelial growth factor (VEGF) level at baseline and amount of improvement. These data indicate that excess production of VEGF in the retinas of patients with CRVO or BRVO is a major contributor to macular edema and suggest that additional studies investigating the efficacy of intraocular injections of ranibizumab are needed.

Received 28 September 2007; accepted 7 January 2008; published online 5 February 2008. doi:10.1038/mt.2008.10

INTRODUCTION

The pathogenesis of central retinal vein occlusions (CRVOs) is poorly understood. In the early stages, there are scattered hemorrhages throughout the entire retina, cotton wool patches, a sign of retinal ischemia, and massive edema of the retina. Fluorescein angiography often shows delayed filling of retinal veins suggesting

reduced blood flow, staining of the walls of retinal veins, and leakage of dye into the retina. It has been concluded that this picture most likely occurs from thrombosis within the central retinal vein causing partial obstruction of blood flow from the eye, increased intraluminal pressure in the retinal veins, and increased transudation of blood and plasma into the retina. Histopathology has confirmed the presence of a thrombus in the central retinal vein in several cases.¹ The marked increase in interstitial fluid and protein increases interstitial pressure and is likely to be an impediment to capillary perfusion resulting in ischemia. The subacute stage varies among patients depending primarily upon the amount of retinal ischemia, and patients are classified as ischemic or nonischemic, although it is not an all or none dichotomy. In some patients ischemia increases over time and they are viewed as undergoing a transition from nonischemic to ischemic. Severe retinal ischemia can be complicated by retinal neovascularization, iris neovascularization, neovascular glaucoma, and a very poor visual outcome. Thus the amount of retinal ischemia is one of the major determinants of outcome.

Those patients classified as nonischemic still have retinal ischemia, as demonstrated by cotton wool patches and areas of capillary nonperfusion seen in fluorescein angiograms. These patients often enter a chronic stage in which they have severe macular edema that may last for many months and often years. Eventually the edema may resolve, presumably because there is resolution of the venous obstruction due to recanalization and/or formation of collateral vessels, but generally the visual outcome is poor due to damage to macular photoreceptors from the chronic edema, poor perfusion of perifoveal capillaries, or both.²

Hypertension is a major risk factor for branch retinal vein occlusions (BRVOs).³ Chronic hypertension leads to thickening of the walls of retinal arterioles and since retinal arterioles and veins share a common adventitia at crossings, this may cause constriction of retinal veins that can lead to occlusions.^{4,5} The complications of BRVOs are similar to those for CRVOs but more limited in scope, because only part of the retina is drained by the involved branch vein. There is increased luminal pressure distal to the obstruction resulting in increased transudation of blood and plasma, increased interstitial fluid pressure, and reduced

Correspondence: Peter A. Campochiaro, Maumenee 719, The Wilmer Eye Institute, The Johns Hopkins University School of Medicine, 600 North Wolfe Street, Baltimore, Maryland 21287-9277, USA. E-mail: pcampo@jhmi.edu

capillary perfusion causing ischemia. Since the area of ischemic retina tends to be much less than that in patients with CRVO, iris neovascularization and neovascular glaucoma are rare, but retinal neovascularization adjacent to the ischemic retina can occur and can cause vitreous hemorrhages necessitating scatter photocoagulation to the ischemic retina. The most common cause of reduced vision is macular edema, but nonperfusion of perifoveal capillaries can also be another contributing factor. Grid laser photocoagulation to the poorly perfused retina adjacent to the fovea can help to resolve macular edema and improve vision.⁶

Thus, in both CRVO and BRVO, retinal ischemia occurs and serves as an exacerbating factor. The ischemic retina releases vascular endothelial growth factor (VEGF) which underlies neovascular complications, but also causes excessive vascular permeability.^{7,8} Hence, the release of VEGF is likely to contribute to macular edema. In this study, we investigated the potential contribution of VEGF to macular edema in patients with CRVO and BRVO by testing the effects of intraocular injections of ranibizumab (Lucentis; Genentech, South San Francisco, CA), an Fab fragment that binds and neutralizes all isoforms of VEGF-A.⁹

RESULTS

Baseline characteristics of study patients

The baseline characteristics of patients are shown in [Table 1](#). For CRVO patients, the 0.5-mg group was somewhat older than the 0.3-mg group and had a longer duration of disease.

Effect of ranibizumab on central retinal (foveal) thickening

[Figure 1](#) shows optical coherence tomography (OCT) scans at all time points up to the primary endpoint for five randomly selected patients with CRVO randomized to each dose. Although the response varied somewhat among patients in each group, most patients showed substantial reduction in central retinal thickness over time. Within 7 days of the first injection, 8 out of 10 patients in the 0.3-mg group and 9 out of 10 in the 0.5-mg group had a substantial improvement in edema as assessed by OCT ([Figure 2a](#) and [b](#)). Four patients in the 0.3-mg group showed a worsening of the thickening between the time points of 1 week and 1 month but improved after the next two injections, while the other six showed persistent improvement 1 month after the first injection that improved further with subsequent injections ([Figure 2a](#)). All the patients in the 0.5-mg dose group showed the latter pattern of response ([Figure 2b](#)). [Figure 3](#) shows the OCT scans of the five randomly selected patients with BRVO randomized to each group. They tended to show rapid and sustained responses after the first injection of 0.3 or 0.5 mg of ranibizumab with further improvement after subsequent injections. Measurements of central retinal thickening confirmed that this was the case for most patients, but two in the 0.3-mg group and one in the 0.5-mg group showed slight worsening between the time points of 1 week and 1 month ([Figure 4](#)).

In patients with CRVO, the median excess foveal thickness was 340 μm at baseline in the 0.3-mg group and 7 days after the first injection it improved to 124 μm , thus eliminating 64% of the edema ([Figure 5a](#)). In the 0.5-mg group, the median excess foveal thickness improved from 309 μm at baseline to 53 μm 1 week after

Table 1 Baseline characteristics

	CRVO		BRVO	
	0.3 mg	0.5 mg	0.3 mg	0.5 mg
Age (years)				
Mean \pm SD	63 \pm 17	68 \pm 13	69 \pm 13	65 \pm 10
Median	69	70	68	65
Range	34–83	48–83	43–84	50–82
Duration of disease (months)				
Mean \pm SD	9 \pm 7	16 \pm 17	5 \pm 3	3 \pm 2
Median	7.4	13	5	3
Range	1–26	0.5–53	0.4–9	0.8–6
Systemic disease				
Diabetes	3	3	3	3
Hypertension	5	6	9	8
Hyperlipidemia	4	7	7	3
Elevated homocysteine	1	3	3	6
Ocular disease				
Glaucoma	1	3	0	1
Other	2	5	5	3
Prior treatment				
Bevacizumab	0	0	1	2
Steroids	1	2	2	2
Laser	1	3	4	3
Visual acuity (ETDRS letters read at 4 m)				
Mean \pm SD	16 \pm 13	23 \pm 15	26 \pm 12	20 \pm 14
Median	18	26	29	23
Excess foveal thickness (in μm)				
Mean \pm SD	346 \pm 88	297 \pm 126	252 \pm 104	288 \pm 101
Median	340	309	270	294

Abbreviations: BRVO, branch retinal vein occlusion; CRVO, central retinal vein occlusion; ETDRS, Early Treatment Diabetic Retinopathy Study.

the first injection, thus eliminating 83% of the edema ([Figure 5b](#)). At the primary endpoint of 3 months, excess foveal thickness was reduced to 25 μm (eliminating 93% of the edema) in the 0.3-mg group, and 35 μm (eliminating 89% of the edema), in the 0.5-mg group. Thus, in patients with CRVO, edema was reduced to a greater extent and the reduction was more sustained after a single injection of 0.5 mg of ranibizumab compared to 0.3 mg, but after three injections of either dose, most of the edema, *i.e.*, ~90%, had been eliminated.

In patients with macular edema due to BRVO, the median excess foveal thickness was 270 μm at baseline in the 0.3-mg group and 7 days after the first injection it improved to 48 μm , thus eliminating 82% of the edema ([Figure 5c](#)). In the 0.5-mg group, the median excess foveal thickness was 294 μm at baseline and 7 days after the first injection it improved to 51 μm , eliminating 83% of the edema ([Figure 5d](#)). At the primary endpoint, excess foveal thickness was essentially eliminated in each group.

The last injection was at the time point of month 2; by month 4 in some patients and month 6 in most patients there was recurrent edema in patients with CRVO and worsening of the edema




Figure 1 Cross sections through the fovea obtained by optical coherence tomography in patients with central retinal vein occlusion. The horizontal cross sections at baseline (BL), day 7 (D7), month 1 (M1), month 2 (M2), and month 3 (M3, primary endpoint) are shown for five randomly selected patients of the 10 patients treated with (a) 0.3 mg or (b) 0.5 mg of ranibizumab.

tended to occur sooner after the last injection in the 0.3-mg group compared to the 0.5-mg group. In the 0.3-mg/CRVO group, seven, and then five patients were given another treatment (usually an off-label injection of bevacizumab) at the time points of months 4 and 6, respectively. In the 0.5-mg/CRVO group, three, and then six patients received additional injections at the time points of months 4 and 6, respectively. In patients with BRVO, recurrent edema was somewhat less frequent than in patients with CRVO, but still occurred in several patients. In the 0.3-mg/BRVO group, one, and then two patients received additional injections at the time points of months 4 and 6, respectively, and in the 0.5-mg/BRVO group, four patients, and then one, received additional injections at time points of months 4 and 6, respectively.

Effect of ranibizumab on visual acuity

In the CRVO group at the primary endpoint, the change from baseline (in the median number of letters read on an Early Treatment Diabetic Retinopathy Study chart) at 4 m was 17 and 14 in patients treated with 0.3 or 0.5 mg of ranibizumab, respectively (Figure 5a and b). All the patients in the 0.3-mg group and eight patients in the 0.5-mg group showed improvement in vision at the primary endpoint compared to baseline. One of the patients showed a reduction of 16 letters at the endpoint of 3 months, that was back to baseline at 4 months. The other patient showed a reduction of 11 letters at the endpoint of 3 months that was judged to be due to progression of edema despite administration of ranibizumab; there was no evidence of ischemia or any other problem that could be attributed to the drug. The percentage of patients with

clinically significant visual improvement defined as an improvement of ≥ 15 letters was 70% in the 0.3-mg group and 40% in the 0.5-mg group.

At the primary endpoint in patients with macular edema due to BRVO, the median change in visual acuity (VA) from baseline was 10 letters in the 0.3-mg group, and 18 in the 0.5-mg dose group (Figure 5c and d). One patient in the 0.5-mg dose group showed a reduction in VA of three letters at the primary endpoint, but all other patients showed improved vision. The percentage of patients with clinically significant visual improvement defined as an improvement of ≥ 15 letters was 40% in the 0.3-mg group and 70% in the 0.5-mg group.

Effect of duration of disease and patient's age on visual outcome

Figure 6 shows scatter plots of change from baseline in VA versus the patient's age or duration of disease for patients with CRVO or BRVO treated with ranibizumab. There was no correlation between the amount of improvement in VA and duration of edema. There were four patients who had edema from CRVO for >2 years prior to starting injections of ranibizumab and three of them improved in VA by >15 letters. Three patients had edema from BRVO for >2 years at baseline and they showed improvements of 41, 21, and 14 letters in 3 months. Therefore, chronic edema from a vein occlusion does not preclude visual improvement as a result of intraocular injections of ranibizumab. There was no correlation between the patient's age and visual improvement; improvement in VA of >15 letters occurred in two out of

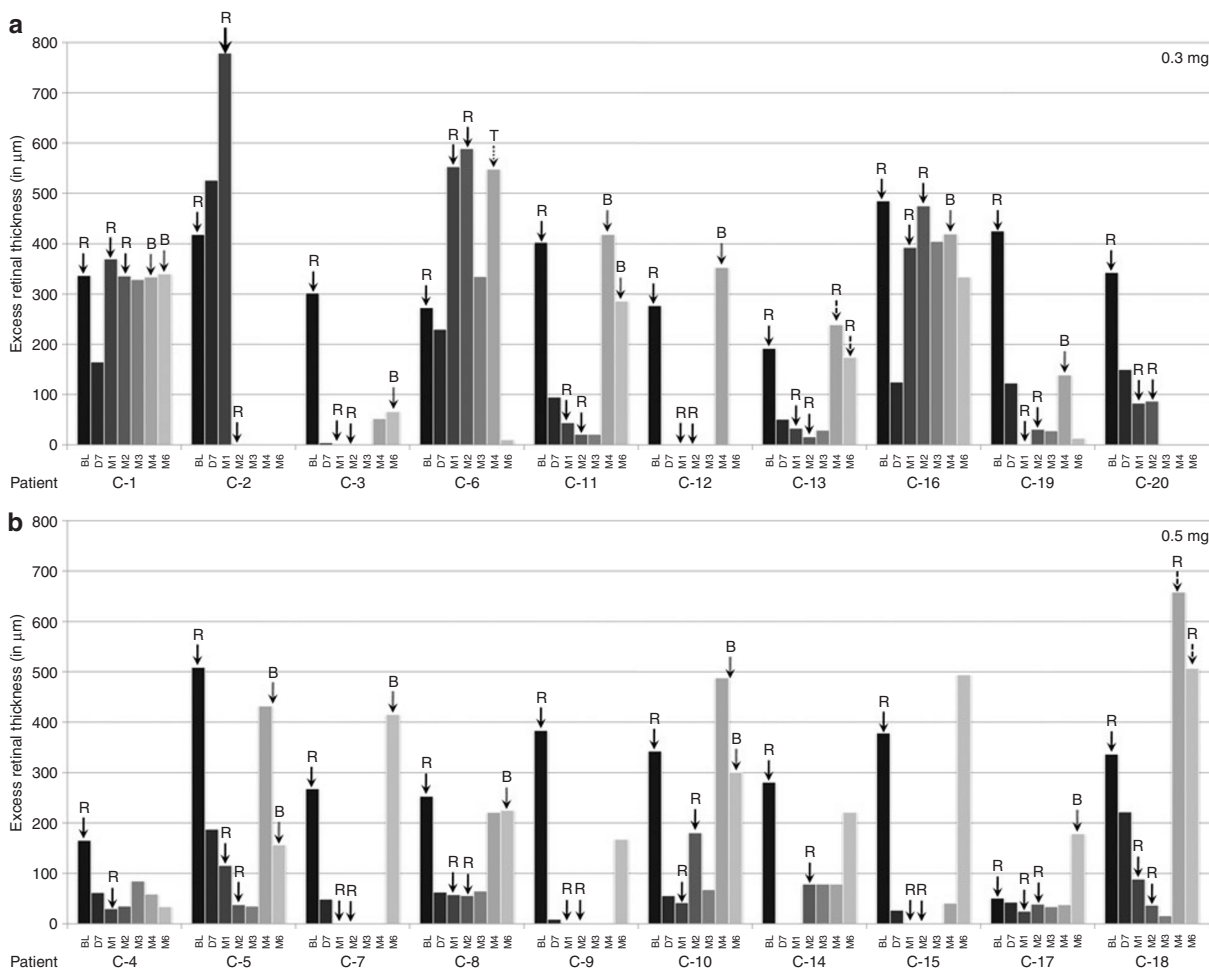


Figure 2 Excess foveal thickness at each visit from baseline (BL) to month 6 (M6) in patients with central retinal vein occlusion. The bars represent excess foveal thickness (central 1 mm retinal thickness—212μm), which is a measure of the amount of macular edema, at BL just prior to injection of ranibizumab, and at day 7 (D7) and months 1 (M1), 2 (M2), 3 (M3), 4 (M4), and 6 (M6) for patients that received three injections of (a) 0.3 mg or (b) 0.5 mg of ranibizumab. The arrows show when injections were done (R, ranibizumab; B, bevacizumab; T, triamcinolone). Fairly rapid improvement in excess foveal thickness occurred in essentially all patients in the 0.5-mg dose group and most patients in the 0.3-mg group, but a few patients in the latter group showed small and/or delayed responses. Most patients showed recurrent edema 1–3 months after the last injection.

three patients with CRVO and three out of four patients with BRVO who were >80 years at baseline.

VEGF levels in aqueous

The mean aqueous VEGF level at baseline was 39 pg/ml in 17 patients with BRVO and 380 pg/ml in the 18 patients with CRVO for which measurements could be performed, a difference that was statistically significant ($P = 0.001$). There was an inverse correlation between baseline aqueous VEGF level and visual outcome in CRVO patients considered alone ($P = 0.038$) and for CRVO and BRVO patients considered together ($P = 0.038$); although BRVO patients considered alone did not reach statistical significance (Figure 7). There was no correlation of VEGF levels with excess foveal thickness at baseline or change in excess foveal thickness after treatment with ranibizumab.

Safety

Intraocular injections of ranibizumab were tolerated well with no inflammation or other problems. None of the patients

showed elevation of blood pressure, thromboembolic events, or any other systemic problems. One patient, an 83-year-old male with a history of pre-existent heart disease, died from a myocardial infarction 6 months after the last injection of ranibizumab; this was judged to be unrelated to the ranibizumab. As noted above, 38 out of 40 subjects showed improvement in VA at the primary endpoint compared to baseline and in the other two patients the reduction in vision was not felt to be attributable to ranibizumab.

DISCUSSION

Although this is an uncontrolled, open-label trial involving a relatively small number of patients, the results were very consistent among patients and suggest that intraocular injections of ranibizumab have a substantial effect on macular edema due to CRVO or BRVO. In both patient populations, the results were good with either 0.3 or 0.5 mg of ranibizumab and no clear differences could be discerned between the doses except that more patients seemed to have rapid improvements in center subfield thickness and more

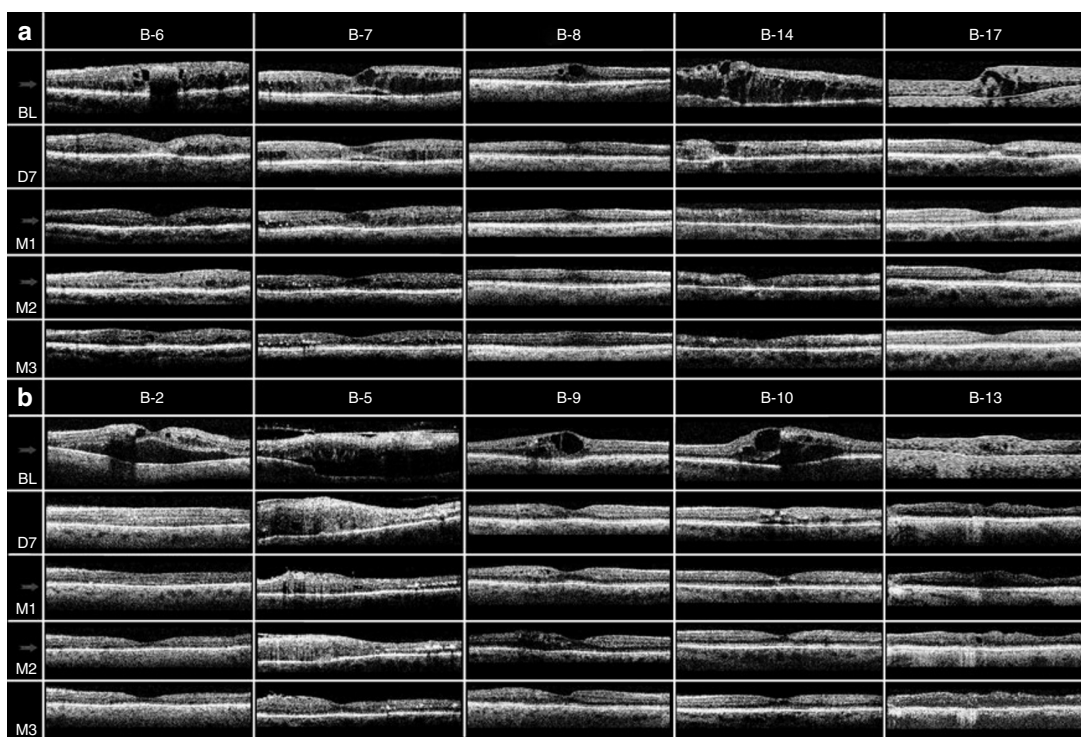


Figure 3 Cross sections through the fovea obtained by optical coherence tomography in patients with branch retinal vein occlusion. The horizontal cross sections at baseline (BL), day 7 (D7), month 1 (M1), month 2 (M2), and month 3 (M3, primary endpoint) are shown for five randomly selected patients of the ten patients treated with (a) 0.3 mg or (b) 0.5 mg of ranibizumab.

had improvements that lasted for a month after the initial injection in the 0.5-mg groups compared to the 0.3-mg groups. However, at the 3-month primary endpoint, 1 month after the third injection, ~90% of excess foveal thickness was eliminated in both patient populations with either dose. In addition, improvements from baseline in VA were large in both dose groups for patients with macular edema due to CRVO or BRVO. These results are very encouraging and strongly support the performance of larger, more definitive studies.

The Central Retinal Vein Occlusion Study was a large multicenter trial that investigated the effect of grid laser photocoagulation in patients with macular edema due to CRVO.¹⁰ Although 69% of patients in the treated group compared to 0% in the untreated group showed reduction of fluorescein leakage in the macula at the end of 1 year, there was no difference in the final VA (20/200 in treated patients versus 20/160 in untreated patients). It has been felt that a possible explanation is that chronic edema due to CRVO leads to permanent visual loss. Our data demonstrate that visual improvement is possible in some patients who have had edema for >1 year and in some cases several years. In fact, there was no inverse correlation between duration of edema at baseline and improvement in VA after three injections of ranibizumab, suggesting that patients with chronic edema should not be excluded from treatment based solely upon the duration of edema. Our data suggest that chronicity of edema and the relatively slow resolution of edema after grid laser therapy are not likely to explain the poor visual results after grid laser therapy. Our data also suggest that elderly patients with macular edema due to CRVO or BRVO should not be excluded from treatment with intravitreal

ranibizumab, because the patient's age being advanced at baseline did not negatively impact the outcome.

No drug-related adverse effects such as elevation of blood pressure, thromboembolic events, or any other systemic problems were observed. This provides some preliminary data, suggesting that intravitreal injections of ranibizumab are well-tolerated in patients with retinal vein occlusions just as they are in patients with neovascular age-related macular degeneration.^{11,12}

Measurement of VEGF levels in aqueous humor demonstrated a higher mean level in patients with CRVO compared to patients with BRVO. In patients with CRVO there was an inverse correlation with VEGF level at baseline and the visual outcome. Further work is needed to determine the predictive value of baseline aqueous levels of VEGF and to determine the range of VEGF levels that occur in other disease processes such as neovascular age-related macular degeneration and diabetic macular edema.

In addition to grid laser therapy, several treatments have been tried in patients with macular edema due to CRVO including the use of anticoagulants, fibrinolytics, steroids, acetazolamide, isovolemic hemodilution, surgically induced retinochoroidal anastomoses or laser-induced retinochoroidal anastomoses, and radial optic neurotomy. A recent meta-analysis of all published randomized clinical trials concluded that there is no convincing evidence that any of these treatments provide benefit.¹³ In contrast, grid laser therapy provides modest benefit in patients with macular edema due to BRVO;⁶ after 3 years, patients treated with grid laser photocoagulation improved by 1.33 lines from baseline compared to an improvement of 0.23 lines in the control group. There are several case series suggesting possible benefit

Explore Litigation Insights

Docket Alarm provides insights to develop a more informed litigation strategy and the peace of mind of knowing you're on top of things.

Real-Time Litigation Alerts



Keep your litigation team up-to-date with **real-time alerts** and advanced team management tools built for the enterprise, all while greatly reducing PACER spend.

Our comprehensive service means we can handle Federal, State, and Administrative courts across the country.

Advanced Docket Research



With over 230 million records, Docket Alarm's cloud-native docket research platform finds what other services can't. Coverage includes Federal, State, plus PTAB, TTAB, ITC and NLRB decisions, all in one place.

Identify arguments that have been successful in the past with full text, pinpoint searching. Link to case law cited within any court document via Fastcase.

Analytics At Your Fingertips



Learn what happened the last time a particular judge, opposing counsel or company faced cases similar to yours.

Advanced out-of-the-box PTAB and TTAB analytics are always at your fingertips.

API

Docket Alarm offers a powerful API (application programming interface) to developers that want to integrate case filings into their apps.

LAW FIRMS

Build custom dashboards for your attorneys and clients with live data direct from the court.

Automate many repetitive legal tasks like conflict checks, document management, and marketing.

FINANCIAL INSTITUTIONS

Litigation and bankruptcy checks for companies and debtors.

E-DISCOVERY AND LEGAL VENDORS

Sync your system to PACER to automate legal marketing.