

# An Optical Coherence Tomography-Guided, Variable Dosing Regimen with Intravitreal Ranibizumab (Lucentis) for Neovascular Age-related Macular Degeneration

ANNE E. FUNG, GEETA A. LALWANI, PHILIP J. ROSENFELD, SANDER R. DUBOVY, STEPHAN MICHELS, WILLIAM J. FEUER, CARMEN A. PULIAFITO, JANET L. DAVIS, HARRY W. FLYNN, JR, AND MARIA ESQUIABRO

- **PURPOSE:** To evaluate an optical coherence tomography (OCT)-guided, variable-dosing regimen with intravitreal ranibizumab for the treatment of patients with neovascular age-related macular degeneration (AMD).
- **DESIGN:** Open-label, prospective, single-center, non-randomized, investigator-sponsored clinical study.
- **METHODS:** In this two-year study, neovascular AMD patients with subfoveal choroidal neovascularization (CNV) ( $n = 40$ ) and a central retinal thickness of at least  $300 \mu\text{m}$  as measured by OCT were enrolled to receive three consecutive monthly intravitreal injections of ranibizumab (0.5 mg). Thereafter, retreatment with ranibizumab was performed if one of the following changes was observed between visits: a loss of five letters in conjunction with fluid in the macula as detected by OCT, an increase in OCT central retinal thickness of at least  $100 \mu\text{m}$ , new-onset classic CNV, new macular hemorrhage, or persistent macular fluid detected by OCT at least one month after the previous injection of ranibizumab.
- **RESULTS:** At month 12, the mean visual acuity improved by 9.3 letters ( $P < .001$ ) and the mean OCT central retinal thickness decreased by  $178 \mu\text{m}$  ( $P < .001$ ). Visual acuity improved 15 or more letters in 35% of patients. These visual acuity and OCT outcomes were achieved with an average of 5.6 injections over 12 months. After a fluid-free macula was achieved, the mean injection-free interval was 4.5 months before another reinjection was necessary.
- **CONCLUSION:** This OCT-guided, variable-dosing regimen with ranibizumab resulted in visual acuity outcomes similar to the Phase III clinical studies, but required fewer intravitreal injections. OCT appears useful for

determining when retreatment with ranibizumab is necessary. (Am J Ophthalmol 2007;143:566–583. © 2007 by Elsevier Inc. All rights reserved.)

**I**NHIBITION OF VASCULAR ENDOTHELIAL GROWTH FACTOR-A (VEGF) is an effective strategy for the treatment of neovascular age-related macular degeneration (AMD).<sup>1–4</sup> The most effective treatment uses ranibizumab (Lucentis, Genentech Inc, South San Francisco, California, USA), a recombinant, humanized, monoclonal antibody antigen-binding fragment (Fab) that neutralizes all biologically active forms of VEGF.<sup>5</sup> In the two Phase III clinical studies using intravitreal injections of ranibizumab, mean visual acuity improved over 24 and 12 months, respectively.<sup>2,3</sup> This was the first therapy for neovascular AMD to show any improvement in mean visual acuity. In these studies, statistically significant benefits were observed for all the primary and secondary efficacy endpoints when compared with control groups. To obtain these impressive results, investigators followed a fixed-dosing regimen requiring an injection of ranibizumab, 0.5 mg or 0.3 mg, every month for two years.

The first suggestion that frequent intravitreal injections of ranibizumab could result in improved visual acuity came from the earlier Phase I/II studies.<sup>6,7</sup> In these studies, ranibizumab was injected every two or four weeks into eyes of patients with neovascular AMD and these patients were followed for 140 days or 210 days. The number of ranibizumab injections ranged from five to nine depending on the study and the cohort within each study. Despite differences in the overall number of injections, the outcomes from these studies were very similar. Mean visual acuity improved and these improvements were associated with an absence of angiographic leakage from choroidal neovascularization (CNV) and an absence of fluid in the macula as assessed by optical coherence tomography (OCT) (Rosenfeld PJ, unpublished data, 2003).

After completion of these Phase I/II studies, most of the study participants enrolled in an open-label extension study to evaluate the safety and tolerability of long-term (up to four years) continued treatment with intravitreal

See accompanying Editorial on page 679.  
Accepted for publication Jan 13, 2007.

From the Bascom Palmer Eye Institute, University of Miami Miller School of Medicine, Miami, Florida (G.A.L., P.J.R., S.R.D., W.J.F., C.A.P., J.L.D., H.W.F., M.E.); Pacific Eye Associates, California Pacific Medical Center, San Francisco, California (A.E.F.); University Eye Hospital Vienna, Austria (S.M.).

Inquiries to Philip J. Rosenfeld, Bascom Palmer Eye Institute, University of Miami Miller School of Medicine, 900 N.W. 17th Street, Miami, FL 33136; e-mail: prosenfeld@med.miami.edu

injections of ranibizumab (Heier JS and associates. ARVO 2005, E-Abstract 1393). Although the extension study initially required monthly injections of ranibizumab after the patient was enrolled, the study was subsequently amended to permit reinjection only if needed as determined by the treating physician. As a result of retreatment being offered at the discretion of the investigator, some patients received monthly injections with ranibizumab to maintain their visual acuity, whereas others were reinjected less frequently or not at all. During this extension study at the Bascom Palmer Eye Institute, OCT imaging was used to follow many of these patients in conjunction with fluorescein angiography, and OCT appeared to detect the earliest signs of fluid reaccumulating in the macula even before leakage could be detected by fluorescein angiography (Rosenfeld PJ, unpublished data, 2003).

Based on these observations from the Phase I/II and extension studies, an investigator sponsored trial known as the Prospective Optical coherence tomography imaging of patients with Neovascular AMD Treated with intra-Ocular ranibizumab (Lucentis) [PrONTO] study was designed to investigate the role of OCT imaging in a variable dosing regimen with ranibizumab at the Bascom Palmer Eye Institute. This report describes the 12 month results of the PrONTO Study.

## METHODS

PRONTO IS A TWO-YEAR, OPEN-LABEL, PROSPECTIVE, SINGLE-center clinical study designed to investigate the efficacy, durability, and safety of a variable dosing regimen with intravitreal ranibizumab in patients with neovascular AMD. The PrONTO Study is an investigator sponsored trial supported by Genentech, Inc, and performed with the approval of the Food and Drug Administration. Before the initiation of the study, additional approval for the PrONTO study was obtained from the Institutional Review Board at the University of Miami Miller School of Medicine. Informed consent was obtained from all patients before determination of full eligibility, and the study was performed in accordance with the Health Insurance Portability and Accountability Act (HIPAA). The PrONTO Study is registered at [www.clinicaltrials.gov](http://www.clinicaltrials.gov), and the clinical trial accession number is NCT00344227.

The major efficacy end points were the change in visual acuity and OCT measurements from baseline and the number of ranibizumab injections required over two years. Other efficacy end points included the number of consecutive monthly injections required from baseline to achieve a fluid-free macula as determined by OCT. After a fluid-free macula was achieved, the durability of the treatment effect was determined by calculating the time until the next injection was needed because of fluid reaccumulating in the macula, otherwise known as the injection-free interval. Finally, after the injections resumed, we calcu-

**TABLE 1.** Major Eligibility Criteria for Enrollment into the PrONTO Study

<b>Inclusion criteria</b>	
Age	50 years or older.
Active primary or recurrent macular neovascularization	secondary to AMD involving the central fovea in the study eye with evidence of disease progression.
OCT central retinal thickness	$\geq 300$ microns.
Best-corrected visual acuity, using ETDRS charts, of 20/40 to 20/400 (Snellen equivalent) in the study eye.	
<b>Exclusion criteria</b>	
More than three prior treatments with verteporfin photodynamic therapy.	
Previous participation in a clinical trial (for either eye) involving antiangiogenic drugs (pegaptanib, ranibizumab, anecortave acetate, protein kinase C inhibitors).	
Previous subfoveal focal laser photocoagulation in the study eye.	
Laser photocoagulation (juxtafoveal or extrafoveal) in the study eye within one month preceding day 0.	
Subfoveal fibrosis or atrophy in the study eye.	
History of vitrectomy surgery in the study eye.	
Aphakia or absence of the posterior capsule in the study eye.	
History of idiopathic or autoimmune-associated uveitis in either eye.	

AMD = age-related macular degeneration; PrONTO = Prospective Optical coherence tomography imaging of patients with Neovascular AMD Treated with intra-Ocular ranibizumab study; OCT = optical coherence tomography; ETDRS = Early Treatment of Diabetic Retinopathy Study.

lated the follow-up number of reinjections required to once again achieve a fluid-free macula.

At the start of the study, only one eye of a patient was determined to be eligible and assigned as the study eye. The major eligibility criteria are shown in Table 1. The major inclusion criteria included a diagnosis of neovascular AMD with a baseline protocol visual acuity letter score from 20 to 70 letters using the Early Treatment Diabetic Retinopathy Study chart at two meters (Snellen equivalent of 20/40 to 20/400) obtained using a standard refraction protocol<sup>8</sup> and an OCT 1 mm central retinal thickness of at least 300  $\mu\text{m}$ . There were no exclusion criteria for preexisting cardiovascular, cerebrovascular, or peripheral vascular conditions. Of note, all fluorescein angiographic lesion types and lesion sizes were eligible for the study. The angiographic lesion types at baseline were independently assessed by three of the investigators (P.J.R., S.R.D., and G.A.L.) and agreement was reached on all interpretations. The diagnosis of retinal angiomatous proliferation (RAP) was independently assessed for each lesion using the characteristic features which included intraretinal hemorrhage, intraretinal vascular anastomoses, and the OCT appearance of a retinal pigment epithelial detachment

**TABLE 2.** The Number of Times Each Criterion was Used Alone or in Combination With Other Criteria to Retreat Neovascular AMD Patients With Ranibizumab After Month 2 Through Month 12

Retreatment criteria	Only one criterion observed for retreatment	Vision loss ( $\geq 5$ letters) associated with fluid detected by OCT	Increase in central retinal thickness $\geq 100$ microns	New-onset hemorrhage	New classic CNV
Vision loss ( $\geq 5$ letters) associated with fluid detected by OCT	31	—	4*	5*	0
Increase in central retinal thickness $\geq 100$ microns	12	4*	—	4*	0
New-onset hemorrhage	12	5*	4*	—	1
New classic CNV	7	0	0	1	—
Persistent fluid following last injection	30	—	—	—	—

AMD = age-related macular degeneration; OCT = optical coherence tomography; CNV = choroidal neovascularization.

Most patients fulfilled only one criterion for reinjection as listed in the second column, but some patients fulfilled two or more criteria and are listed in columns 3 to 6.

\*Two of these individuals had three criteria for reinjection: vision loss ( $\geq 5$  letters) associated with fluid detected by OCT, increase in central retinal thickness  $\geq 100$  microns, and new onset hemorrhage.

with overlying cystic changes in the retina. In calculating lesion areas, we assumed a standard disk diameter of 1.8 mm and a standard disk area (DA) of 2.54 mm<sup>2</sup>. All digital fundus photography was performed using Topcon TRC-50IX retinal cameras (Topcon America Corp (TAC), Paramus, New Jersey, USA) with a 35 degree viewing angle and the images were stored using the Topcon Imagenet software (version 2.14, Windows 2000 v.5.0; Paramus, New Jersey, USA). Images were then transferred to an OIS workstation (OIS Winstation XP 10 3000 Auto Import Capture version 10.2.59; Sacramento, California, USA) where the lesion areas were measured.

OCT (Stratus OCT, Carl Zeiss Meditec, Dublin, California, USA) quantitative assessments were obtained using six diagonal fast, low density scans (low resolution, 128 A-scans per diagonal). The central 1 mm central retinal thickness measurements were obtained from the macular thickness maps calculated from the six low-resolution fast scans after it was confirmed that the two boundaries delineated as the internal limiting membrane (inner boundary) and the retinal pigment epithelium (RPE) and the Bruch membrane (outer boundary) were appropriately identified by the validated internal algorithm. If boundaries were incorrectly identified, then the scans were repeated until the boundaries were accurately identified by the algorithm. The central retinal thickness was defined as the distance between these inner and outer boundaries and did not include any fluid under the RPE. Eligible patients were required to have a 1 mm central retinal thickness of at least 300  $\mu\text{m}$ . OCT qualitative assessments were performed using all six diagonal slow, high density scans (high resolution, 512 A-scans per diagonal). These high resolution diagonal scans were used to evaluate whether fluid was present in the macula and whether retreatment was needed. For the purposes of this study, fluid in the macula was identified as intraretinal fluid (cysts) and subretinal fluid, and a fluid-free macula was defined by the absence of retinal cysts and subretinal fluid as determined by OCT.

Fluid under the RPE, otherwise known as a pigment epithelial detachment (PED), was recorded as an OCT finding in the macula but not included in any of the retreatment criteria. The decision not to include a PED in the retreatment criteria was based on prior anecdotal observations from the Phase I/II extension study with ranibizumab. In the extension study, there appeared to be little correlation between the presence of a PED and visual acuity. In addition, PEDs could remain stable for months and resolution of fluid within the PED was thought to be a lagging indicator of VEGF activity. In contrast, macular cysts and subretinal fluid appeared to respond more rapidly to the presence or absence of VEGF.

During the screening process, patients underwent a complete physical exam with laboratory testing. Laboratory testing consisted of an electrocardiogram, complete blood count, and chemistry panel performed at baseline and at month 12. Blood pressure measurements were performed at every visit. Eligible patients underwent visual acuity testing and ophthalmoscopic examinations at baseline, day 14, day 30, day 45, day 60, and monthly thereafter. Fundus photography and OCT imaging were performed at baseline and on days one, two, four, seven, 14, and 30 after the first two monthly injections, and monthly thereafter. Fluorescein angiography was performed at baseline, month 1, month 2, month 3, and every three months thereafter. All ophthalmic photographers and OCT technicians involved in the study were previously certified to participate in Food and Drug Administration–approved clinical trials at the Bascom Palmer Eye Institute.

After determination of eligibility, patients received an intravitreal injection of ranibizumab (LUCENTIS, Genentech, Inc) using a standard protocol at the Bascom Palmer Eye Institute. The eye was topically anesthetized with sterile 4% lidocaine and a povidone-iodine (10%) scrub was performed on the lids and lashes. A sterile speculum was placed between the lids, and povidone-

**TABLE 3. Visual Acuity of Eyes With Neovascular AMD Treated With a Variable-Dosing Regimen of Ranibizumab Through 12 Months**

Patients' study eyes (n = 40)	Baseline visual acuity letters (Snellen equivalent)	Day 14 visual acuity letters (Snellen equivalent)	Month 1 visual acuity letters (Snellen equivalent)	Month 3 visual acuity letters (Snellen equivalent)	Month 12 visual acuity letters (Snellen equivalent)	Change in visual acuity letter scores from baseline to month 12 visual acuity letters (Snellen equivalent)
Mean (P value)*	56.2 20/80 <sup>+1</sup>	63.1 20/50 <sup>-2</sup> (P < .001)	63.9 20/50 <sup>-1</sup> (P < .001)	67.0 20/50 <sup>+2</sup> (P < .001)	65.5 20/50 (P < .001)	+9.3
Median (P value)†	57 20/80 <sup>+2</sup>	65.0 (20/50) (P < .001)	66.0 20/50 <sup>+1</sup> (P < .001)	71.0 20/40 <sup>+1</sup> (P < .001)	68 20/40 <sup>-2</sup> (P < .001)	+11.0

AMD = age-related macular degeneration.  
\*Paired the Student *t* test.  
†Paired the Wilcoxon signed-rank test.

**TABLE 4. OCT Central Retinal Thickness of Eyes With Neovascular AMD Treated With a Variable-Dosing Regimen of Ranibizumab Through 12 Months**

Patients' study eyes (n = 40)	Baseline central retinal thickness (μm)	Day 1 central retinal thickness (μm)	Month 1 central retinal thickness (μm)	Month 3 central retinal thickness (μm)	Month 12 central retinal thickness (μm)	Change in central retinal thickness (μm) from baseline to month 12
Mean (P value)*	393.9	347.1 (P < .001)	237.2 (P < .001)	204.3 (P < .001)	216.1 (P < .001)	-177.8
Median (P value)†	384.5	336.0 (P < .001)	203.5 (P < .001)	186.0 (P < .001)	199.0 (P < .001)	-185.5

OCT = optical coherence tomography; AMD = age-related macular degeneration.  
\*Paired the Student *t* test.  
†Paired the Wilcoxon signed-rank test.

**TABLE 5. Distribution of OCT Lesion Characteristics From Baseline Through Month 3 in Neovascular AMD Patients Treated With Ranibizumab at Day 0, Month 1, and Month 2**

OCT lesion characteristics (n = 40)	Day 0 n (%)	Day 7 n (%)	Day 14 n (%)	Month 1 n (%)	Month 2 n (%)	Month 3 n (%)
Retinal cysts	36 (90%)	7 (17.5%)	6 (15%)	6 (15%)	3 (7.5%)	3* (7.5%)
Subretinal fluid	30 (75%)	19 (47.5%)	15 (37.5%)	9 (22.5%)	3 (7.5%)	1* (2.5%)
RPE detachment	29 (72.5%)	27 (67.5%)	24 (60%)	23 (57.5%)	18 (45%)	15 (37.5%)
Epiretinal membrane	9 (22.5%)	9 (22.5%)	9 (22.5%)	9 (22.5%)	9 (22.5%)	9 (22.5%)
RPE tear	0	1 (2.5%)	1 (2.5%)	1 (2.5%)	1 (2.5%)	1 (2.5%)

OCT = optical coherence tomography; RPE = retinal pigment epithelium; AMD = age-related macular degeneration.  
\*One eye had both residual retinal cysts and subretinal fluid.

iodine (5%) drops were applied over the ocular surface three times over several minutes. Additional topical anesthesia was achieved by applying a sterile cotton swab soaked in sterile 4% lidocaine to the area designated for injection in the inferotemporal quadrant. Ranibizumab (0.05 ml, 0.5 mg) in a tuberculin syringe with a 30-gauge needle was injected through the pars plana into the vitreous cavity through the sclera 3 to 4 mm posterior to the limbus. Post-injection light perception was assessed and the intraocular pressure was monitored until it was lower than 30 mm Hg. The patient was instructed to apply

moxifloxacin antibiotic drops (vigamox 0.5% solution) to the study eye four times per day for three days. All patients received a call within 24 hours to assess their status and remind them to use their antibiotic drops.

Intravitreal injections of ranibizumab were administered to all patients at baseline, month 1, and month 2. Additional reinjections were given if any of the following changes were observed by the evaluating physician as shown in Table 2: (1) visual acuity loss of at least five letters with OCT evidence of fluid in the macula, (2) an increase in OCT central retinal thickness of at least 100



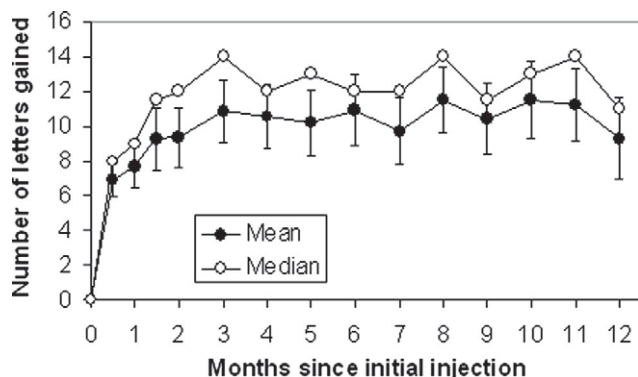


FIGURE 1. Mean and median change in visual acuity through 12 months of eyes with neovascular age-related macular degeneration (AMD) treated with a variable dosing intravitreal ranibizumab regimen. Vertical lines are 1 standard error of the means.

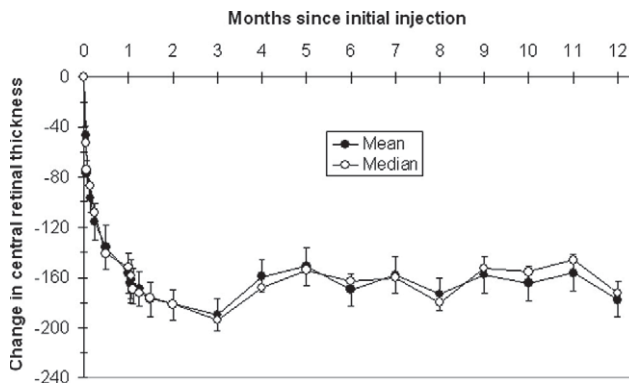


FIGURE 2. Mean and median change in the optical coherence tomography (OCT) central retinal thickness through 12 months of eyes with neovascular age-related macular degeneration (AMD) treated with a variable dosing intravitreal ranibizumab regimen. Vertical lines are 1 standard error of the means.

**TABLE 6.** Distribution of Visual Acuity Changes in Eyes With Neovascular AMD After 3 Doses of Ranibizumab at Month 3 and After a Variable-Dosing Regimen From Months 3 Through 12

Change in visual acuity from baseline through 12 months	Month 3 40 eyes n (%)	Month 12 40 eyes n (%)
≥6 line increase	2 (5%)	3 (7.5%)
≥3 line to <6 line increase	11 (27.5%)	11 (27.5%)
≥1 line to <3 line increase	20 (50%)	16 (40%)
No change	5 (12.5%)	5 (12.5%)
≥1 line to <3 line decrease	1 (2.5%)	3 (7.5%)
≥3 line decrease	1 (2.5%)	2 (5%)

AMD = age-related macular degeneration.

μm, (3) new macular hemorrhage, (4) new area of classic CNV, or (5) evidence of persistent fluid on OCT at least one month after the previous injection. All criteria were based on comparisons with the previously scheduled visit. If a reinjection was performed as part of an unscheduled visit, then the patient returned at the next scheduled visit for follow-up, but all subsequent reinjection decisions were postponed until the next scheduled visit at least one month after the injection. If any single criterion for reinjection was fulfilled, then the intravitreal injection was performed as previously described.

The major outcome measurements in the PrONTO study included Early Treatment Diabetic Retinopathy Study visual acuity letter scores, OCT central retinal

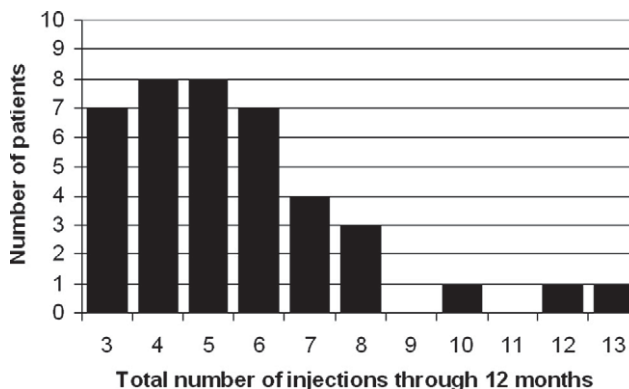


FIGURE 3. Distribution of the total number of injections of ranibizumab administered per neovascular age-related macular degeneration (AMD) patient through 12 months according to the Prospective Optical coherence tomography imaging of patients with Neovascular AMD Treated with intra-Ocular ranibizumab (PrONTO) study criteria.

thickness measurements, the change in visual acuity letter scores and OCT measurements from baseline, the consecutive number of injections required to achieve a fluid-free macula from baseline, the injection-free interval after a fluid-free macula was achieved, the number of consecutive reinjections required to achieve a fluid-free macula after the fluid started to reaccumulate and injections were

FIGURE 4. Case 1: A 100-year-old woman with neovascular age-related macular degeneration (AMD) diagnosed with predominantly classic choroidal neovascularization (CNV) in her left eye, given three ranibizumab injections, and then followed through month 12. Color fundus images with early and late phase fluorescein angiographic images are shown at baseline, at month 3 (one month after the third injection), and then at month 6, month 9, and month 12 without any additional injections of ranibizumab. At months 6 and 12, fundus photography was performed using a 50 degree viewing angle rather than the protocol 35 degree angle.

# Explore Litigation Insights

Docket Alarm provides insights to develop a more informed litigation strategy and the peace of mind of knowing you're on top of things.

## Real-Time Litigation Alerts



Keep your litigation team up-to-date with **real-time alerts** and advanced team management tools built for the enterprise, all while greatly reducing PACER spend.

Our comprehensive service means we can handle Federal, State, and Administrative courts across the country.

## Advanced Docket Research



With over 230 million records, Docket Alarm's cloud-native docket research platform finds what other services can't. Coverage includes Federal, State, plus PTAB, TTAB, ITC and NLRB decisions, all in one place.

Identify arguments that have been successful in the past with full text, pinpoint searching. Link to case law cited within any court document via Fastcase.

## Analytics At Your Fingertips



Learn what happened the last time a particular judge, opposing counsel or company faced cases similar to yours.

Advanced out-of-the-box PTAB and TTAB analytics are always at your fingertips.

## API

Docket Alarm offers a powerful API (application programming interface) to developers that want to integrate case filings into their apps.

## LAW FIRMS

Build custom dashboards for your attorneys and clients with live data direct from the court.

Automate many repetitive legal tasks like conflict checks, document management, and marketing.

## FINANCIAL INSTITUTIONS

Litigation and bankruptcy checks for companies and debtors.

## E-DISCOVERY AND LEGAL VENDORS

Sync your system to PACER to automate legal marketing.