

PHARMACOKINETIC STUDY OF INTRAVITREAL AFLIBERCEPT IN HUMANS WITH NEOVASCULAR AGE-RELATED MACULAR DEGENERATION

DIANA V. DO, MD,* WILLIAM RHOADES, MD,† QUAN DONG NGUYEN, MD, MSc*

Purpose: To investigate the half-life of aflibercept in aqueous humor after a single intravitreal injection in patients with neovascular age-related macular degeneration.

Methods: Prospective, noncomparative, interventional case series of five eyes with neovascular age-related macular degeneration naive to anti-vascular endothelial growth factor therapy were enrolled and treated with intravitreal aflibercept. At baseline, best-corrected visual acuity, optical coherence tomography imaging, and aqueous humor (treatment eye) and blood/plasma samples were taken. Patients underwent best-corrected visual acuity, optical coherence tomography imaging, and sampling of aqueous humor from the eye and blood/plasma at six additional post-treatment time points of 4 hours and Days 1, 3, 7, 14, and 28. Concentrations of aflibercept were quantified using an enzyme-linked immunosorbent assay.

Results: Median peak concentration (C_{max}) of free aflibercept in the aqueous was 122 mg/L. The median half-life of free aflibercept was 11 days in the eye. In plasma, the concentrations of free aflibercept were low and transient, reaching undetectable levels during the first week after injection, and undetectable in all patients at time points beyond 7 days.

Conclusion: The pharmacokinetic profile in the aqueous humor described here together with the previously reported affinity of aflibercept for vascular endothelial growth factor is consistent with and adds to our understanding for the duration of its clinical efficacy.

RETINA 00:1–5, 2019

Intravitreal antiangiogenic therapy is currently the primary treatment for neovascular age-related macular degeneration (AMD). Antiangiogenic agents used to treat neovascular AMD target vascular endothelial growth factor (VEGF), a positive regulator of angio-

genesis that has been implicated in the pathogenesis of neovascular AMD.^{1,2} Among the VEGF isoforms, VEGF-A is known to be most strongly linked to angiogenesis.³ Therapeutic VEGF-A inhibitors such as intravitreal aflibercept and intravitreal ranibizumab have been approved by the Food and Drug Administration (FDA) for use in neovascular AMD patients. In addition, bevacizumab, which is indicated for systemic therapy of colorectal cancer, is frequently compounded and prescribed off-label to treat choroidal neovascularization.^{4,5}

Information on the pharmacokinetics of intravitreal VEGF inhibitors is clinically useful and can be supportive in the understanding of dosing intervals in patients. Published studies have evaluated the pharmacokinetics of both ranibizumab and bevacizumab in humans.^{6,7} In these studies, eyes with both

From the *Byers Eye Institute, Stanford University School of Medicine, Palo Alto, California; and †Associated Retinal Consultants, Grand Rapids, Michigan.

Supported by Regeneron Pharmaceuticals through an investigator initiated study designed and conducted by D. V. Do.

D. V. Do reports consulting fees from Clearside Biomedical Inc, Genentech, Kodiak Sciences, Regeneron, and Santen; and research funding from Genentech, Regeneron, and Santen. Q. D. Nguyen reports advisory board fees from Regeneron.

Data from this study were presented in part at the Retina Subspecialty Day held in conjunction with the American Academy of Ophthalmology Annual Meeting, New Orleans, LA, 2017.

Reprint requests: Diana V. Do, MD, Byers Eye Institute, Stanford University School of Medicine, 2370 Watson Court, Suite 228, Palo Alto, CA 94303; e-mail: dianado@stanford.edu

macular edema and visually significant cataract were treated with either bevacizumab or ranibizumab. Then aqueous humor samples were obtained from each subject at a single time point during cataract surgery. Based on the varying distribution of time intervals between injection and aqueous harvest in the individual patients, the investigators, based on the totality of the data with only a single determination per patient, estimated a half-life of 7.19 days for ranibizumab and 9.82 days for bevacizumab.

Aflibercept is a fusion protein, which acts as a soluble decoy receptor that binds VEGF-A, VEGF-B, and placental growth factor (another member of the VEGF family).⁸ These two angiogenic factors have been found to stimulate endothelial cell proliferation and migration, as well as vascular permeability.⁹ Phase 3 clinical trials in neovascular AMD have demonstrated that every 8-week intravitreal dosing of 2-mg aflibercept (Eylea) injection is noninferior to both monthly dosing of 2-mg aflibercept (Eylea) and monthly dosing of 0.5-mg ranibizumab.¹⁰

Little information is known about the intraocular pharmacokinetics of aflibercept in human eyes. We conducted a pharmacokinetic study of aflibercept injection in nonvitrectomized eyes with wet AMD to characterize the intraocular and systemic concentrations of free and bound aflibercept in humans with neovascular AMD. We sampled aqueous at multiple times after injection in the treatment eye in each of the five patients, thus permitting characterization of the pharmacokinetics including half-life of free aflibercept in aqueous humor. This research will fill in these gaps in the knowledge base for intravitreal aflibercept injection.

Methods

This clinical research was approved by the Institutional Review Board and conducted at the University of Nebraska Medical Center. Eligible participants had a diagnosis of new-onset neovascular AMD without previous treatment in the study eye. In addition, no active neovascular AMD or anti-VEGF treatment could be present in the fellow eye. Subjects were followed for a 28-day period and had 6 study visits (baseline, Days 1, 3, 7, 14, and 28). All study eyes underwent the following procedures at baseline and at Day 28 measurement of best-corrected visual acuity (BCVA), dilated fundoscopic examination, fundus photograph, fluorescein angiography, and optical coherence tomography (OCT). In addition, anterior chamber paracentesis and a blood draw were performed at enrollment and before Eylea was given to

determine the concentrations of free and bound concentrations of aflibercept at baseline in aqueous humor and plasma. After baseline ocular and plasma samples were obtained, intravitreal aflibercept injection (2 mg) into the study eye was administered and considered to be Time 0. Four hours after intravitreal aflibercept injection, anterior chamber paracentesis and blood draw were repeated. These two procedures, as well as BCVA and OCT, were also performed on each study visit.

Aflibercept concentrations in aqueous humor and blood plasma samples were quantified in triplicate by enzyme-linked immunosorbent assay (ELISA).

Results

Five subjects provided informed consent and were enrolled, leading to five study eyes with new-onset wet AMD. The median age was 78 years. All patients were treatment-naïve and had no previous vitrectomy surgery. The median baseline BCVA was 68 letters (Snellen equivalent of 20/50). In addition, the mean OCT central subfield retinal thickness was 304 μm (using the Heidelberg Spectralis machine). Four of the five subjects completed all study visits. One subject did not have aqueous fluid collection at Day 28, and that missing data point was not included in the Day 28 analyses.

At baseline (before intravitreal aflibercept was administered), there were no detectable concentrations of free or bound aflibercept in the aqueous humor or plasma. Four hours after the aflibercept injection, the median peak concentration (C_{max}) of free aflibercept in the aqueous was 64.4 mg/L. At Days 1, 3, 7, 14, and 28, the median concentrations of free aflibercept in the aqueous were 51.9, 35.3, 36.9, 17.1, and 9.4 mg/L (Table 1). The half-life of free aflibercept in the aqueous humor, calculated from the median values at each time point, was approximately 11 days. Adjusted bound aflibercept in the aqueous was undetectable at all time points.

At the 4-hour mark, the median plasma concentration of free and adjusted bound aflibercept were 0 mg/L. At Days 1, 3, 7, 14, and 28, the median plasma concentrations of free aflibercept were 0.03, 0.01, and undetectable from Day 7 onward. Similarly, the median concentration of adjusted bound aflibercept in the plasma was 0, 0.08, 0.11, 0.17, and 0.18 mg/L at those respective time points (Table 2).

The median OCT retinal thickness decreased to 252 μm one day after aflibercept injection. Subsequently, the median OCT thickness was 235, 233, 218, and 218 μm at Days 3, 7, 14, and 28. Two of the subjects

Table 1. Concentrations of Free Aflibercept in Aqueous Humor by Time After a Single Intravitreal Injection of Aflibercept

Time (Days)	TE001	TE002	TE003	TE004	TE005	Median
0	0	0	0	0	0	0
0.166	104	24.8	222	18.3	129	64.4
1	122	38	65.9	24.5	106	51.95
3	88.5		15.4	35.3	67.6	35.3
7	42	44.6	10.8	31.9	42.9	36.95
14	12.9	28.6	4.46	20.3	29.1	17.15
28	0.793	8.770001	NA	9.92	13.1	9.4

Baseline treated as zero.
All concentrations reported as mg/L.
NA, not available.

had a more rapid decline in aflibercept levels in the aqueous, which was associated with a smaller reduction in their central subfield thickness measurement (Figure 1). The median BCVA was 74 letters, 72 letters, 71 letters, 73 letters, and 73 letters (Snellen equivalent of 20/32, 20/40, 20/40, 20/40, and 20/40, respectively) at the time points described above.

Discussion

This study provides novel information on the half-life of free aflibercept in the aqueous humor from patients with neovascular AMD. To the best of our knowledge, this research is the first study to investigate the pharmacokinetics of aflibercept in human eyes with serial intensive sampling. Our study estimated pharmacokinetic parameters for free aflibercept in the aqueous humor including the median half-life, which was estimated to be approximately 11 days, which is longer than the reported half-life of ranibizumab (7 days) and bevacizumab (9 days). In addition, the concentration of free aflibercept in the aqueous is 1,000-fold greater than observed in plasma.

The range of half-lives among the five subjects is interesting. Perhaps, the variability results from differential vitreal liquefaction in different eyes or the presence of additional exit paths in some eyes. We may speculate that variability in duration of treatment among patients may be related to persistence of high levels of aflibercept in some eyes and not others. However, these are speculations, and the mechanism and significance of this variability in half-lives are currently unknown and remain the subject for future investigation. It seems unlikely that the difference in half-lives among patients is due to difference in disease burden, that is, differential target-mediated clearance in the eye because some

Table 2. Concentrations of Free Aflibercept in Plasma by Time After a Single Intravitreal Injection of Aflibercept

Time (Days)	TE001	TE002	TE003	TE004	TE005	Median
0	0	0	0	0	0	0
0.166	0	0	0.0218	0	0	0
1	0.0342	0	0.064	0	0.0456	0.0342
3	0.0582	0	0.0195	0	0.0239	0.0195
7	0.0283	0	0	0	0	0
14	0	0	0	0	0	0
28	0	0	NA	0	0	0

All concentrations reported as mg/L.
Baseline is treated as 0.
NA, not available.

patients are producing so much more VEGF. If this were the case, we would see differential accumulation of VEGF-bound aflibercept in the aqueous correlated with half-life. In fact, levels of bound aflibercept in the aqueous are below the level of quantitation in all patients at all time points. It is also of interest to note that no free aflibercept at all was detected in the

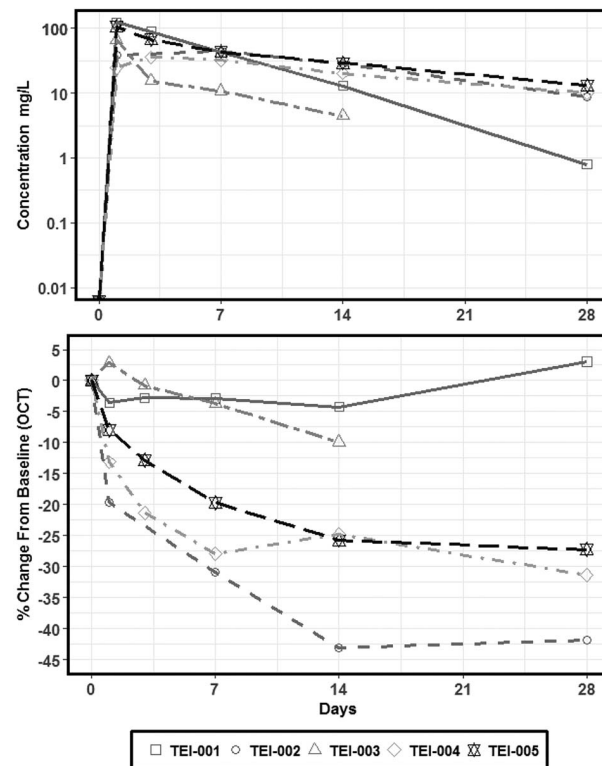


Fig. 1. The figure illustrates the concentration of free aflibercept (mg/L) in the aqueous humor over time for each of the five subjects after a single intravitreal injection of 2-mg aflibercept on Day 0. The lower figure illustrates the percent change in OCT central subfield thickness from baseline for each of the subjects. Two of the subjects had a more rapid decline in aflibercept levels in the aqueous, which was associated with a smaller reduction in their central subfield thickness measurements.

plasma of patients that never achieved aqueous C_{max} values of 100 mg/L. This may indicate that the primary exit route for aflibercept is through aqueous outflow, and detectable plasma levels are related to peak aqueous levels.

Concentrations of free aflibercept in the plasma were low and transient and were undetectable 1 week after administration. The extremely low and transient concentrations of free aflibercept in the plasma suggest that aflibercept is unlikely to bind to circulating VEGF to appreciable extent in the plasma. To date, clinical trials of intravitreal VEGF inhibitors have not been sufficiently powered to detect small differences in rare adverse events, such as arterial-thrombotic events. Although Avery et al suggested that monthly aflibercept or ranibizumab possibly increases the risk of death and cerebral vascular accidents in DME patients, other systematic reviews and clinical trials have not shown any increased risk of serious systemic adverse events associated with aflibercept, bevacizumab, or ranibizumab.^{11–13} Recently, Jampol et al¹³ in the Diabetic Retinopathy Clinical Research (DRCR) Network evaluated systemic VEGF levels in subjects treated with intravitreal VEGF blockers (aflibercept, ranibizumab, and bevacizumab) for diabetic macular edema and found no data to suggest that patients with lower VEGF blood levels were at an increased risk of systemic complications.

Changes in BCVA and OCT retinal thickness were variable among the five study eyes. The baseline median BCVA was of 68 letters (20/40), and retinal thickness (349 μ m) indicates that this new-onset choroidal neovascularization was detected early in these eyes. Some of the study eyes had more rapid reductions in retinal thickness, and there was a trend to suggest that eyes which had higher concentrations of free aflibercept in the aqueous had more robust reductions in OCT compared with eyes in which aflibercept exited the eye more rapidly. We hypothesize that a constant, high concentration of the drug in the eye likely provides more VEGF inhibition over a longer period, and leads to less fluid on the OCT.⁸ However, normal variability of drug levels in humans can also contribute to different anatomical responses on OCT, and larger sample sizes are necessary to truly confirm the correlation between aflibercept levels and OCT retinal thickness changes.

This study has several strengths. Serial samples of intraocular fluid and blood plasma were obtained from the same five subjects. In addition, high frequency of sampling (7 specimens) during a 28-day period provide for greater data points on the pharmacokinetics of aflibercept. This design

permitted the calculation of the half-life of the drug in the eye.

We recognize there are some limitations with this research. The sample size of five subjects is small. In addition, longer follow-up of subjects with additional data beyond 28 days would provide more long-term data on how free and bound aflibercept concentration changes after multiple intravitreal aflibercept injections. Systemic VEGF levels were not measured in this study, and we recognize that information on systemic VEGF levels could be helpful in identifying if aflibercept has any effect on systemic VEGF blockade.

This research provides useful information on the pharmacokinetics of aflibercept in patients with neovascular AMD. This new information complements the existing medical literature on intravitreal aflibercept and gives ophthalmologists new insights into the ocular half-life on this drug. Additional pharmacokinetic studies in subjects with different retinal diseases, such as diabetic macular edema and diabetic retinopathy, or with previous vitrectomy may be helpful in determining how aflibercept concentrations vary in patients with these ocular disorders.

Key words: age-related macular degeneration, pharmacokinetics, half-life, aflibercept, intravitreal VEGF inhibitors, VEGF.

References

1. Miller JW, Adamis AP, Aiello LP. Vascular endothelial growth factor in ocular neovascularization and proliferative diabetic retinopathy. *Diabetes Metab Rev* 1997;13:37–50.
2. Aiello LP, Avery RL, Arrigg PG, et al. Vascular endothelial growth factor in ocular fluid of patients with diabetic retinopathy and other retinal disorders. *N Engl J Med* 1994;331:1480–1487.
3. Bhisitkul RB. Vascular endothelial growth factor biology: clinical implications for ocular treatments. *Br J Ophthalmol* 2006;90:1542–1547.
4. Epstein P. Trials that matter: two faces of progress in the treatment of age-related macular degeneration. *Ann Intern Med* 2007;146:532–534.
5. Brechner RJ, Rosenfeld PJ, Babish JD, Caplan S. Pharmacotherapy for neovascular age-related macular degeneration: an analysis of the 100% 2008 medicare fee-for-service part B claims file. *Am J Ophthalmol* 2011;151:887–895.
6. Krohne TU, Eter N, Holz FG, Meyer CH. Intraocular pharmacokinetics of bevacizumab after a single intravitreal injection in humans. *Am J Ophthalmol* 2008;146:508–512.
7. Krohne TU, Liu Z, Holz FG, Meyer CH. Intraocular pharmacokinetics of bevacizumab after a single intravitreal injection in humans. *Am J Ophthalmol* 2012;154:682–686.
8. Stewart MW, Rosenfeld PJ. Predicted biological activity of intravitreal VEGF Trap. *Br J Ophthalmol* 2008;92:667–668.

9. Witmer AN, Vrensen GFJM, Van Noorden CJF, Schlingemann RO. Vascular endothelial growth factors and angiogenesis in eye disease. *Prog Retin Eye Res* 2003;22:1–29.
10. Stewart MW. Aflibercept (VEGF Trap-eye): the newest anti-VEGF drug. *Br J Ophthalmol* 2012;96:1157–1158.
11. Avery RL, Gordon GM. Systemic safety of prolonged monthly anti-vascular endothelial growth factor therapy for diabetic macular edema: a systematic review and meta-analysis. *JAMA Ophthalmol* 2016;134:21–29.
12. Kitchens JW, Do DV, Boyer DS, et al. Comprehensive review of ocular and systemic safety events with intravitreal aflibercept injection in randomized controlled trials. *Ophthalmology* 2016;123:1511–1520.
13. Jampol LM, Glassman AR, Liu D; DRRC Network. Plasma vascular endothelial growth factor concentrations after intravitreal anti-vascular endothelial growth factor therapy for diabetic macular edema. *Ophthalmology* 125:1054–1063.