

Intravitreal bevacizumab for myopic choroidal neovascularization: short-term and 1-year results

Article in Bulletin de la Société belge d'ophtalmologie · January 2009

Source: PubMed

CITATIONS

6

READS

86

2 authors, including:



[Leigh Spielberg](#)

AZ Sint-Jan Brugge-Oostende

24 PUBLICATIONS 226 CITATIONS

[SEE PROFILE](#)

All content following this page was uploaded by [Leigh Spielberg](#) on 26 May 2014.

The user has requested enhancement of the downloaded file.

INTRAVITREAL BEVACIZUMAB FOR MYOPIC CHOROIDAL NEOVASCULARIZATION: SHORT-TERM AND 1-YEAR RESULTS

SPIELBERG L., MD*, LEYS A., MD, PHD*

ABSTRACT

Purpose: To report three-month and one-year safety and efficacy results of intravitreal bevacizumab injection (IVB) for active choroidal neovascularization associated with pathological myopia (mCNV).

Methods

This retrospective interventional case series of 23 patients (23 eyes) was conducted at the medical retina center in the Leuven University Hospital Department of Ophthalmology, a referral center for macular diseases in Belgium. Charts were reviewed of all patients who received 1.25 mg IVB for active mCNV. If patients had two treated eyes, the eye with the longest follow-up was selected as the study eye. Injections were repeated as needed based on a decrease in visual acuity, an increase in central macular thickness (CMT) of $> 100\mu$ mm on optical coherence tomography (OCT), the recurrence of macular edema on OCT and/or leakage on fluorescein angiography (FA). For statistical analysis, patients were divided into two groups based on length of follow up: patients in Group 1 had a follow-up of ≥ 12 months, while those in Group 2 had < 12 months of follow-up. Changes in visual acuity (VA), as measured by the Early Treatment of Diabetic Retinopathy Study (ETDRS) protocol, and CMT were analyzed, as were safety considerations such as intraocular inflammation and endophthalmitis.

Results: Twenty-three eyes of 23 patients with ages ranging from 20 to 84 years (mean 57.7 years) were included. Mean best-corrected visual acuity (BCVA) at baseline for all patients ($n=23$) was 45 letters (Snellen equivalent: 20/120; 8 lines). At 3 months

after initial treatment, the mean BCVA improved significantly ($P < 0.05$) to 58 letters (20/60²; 10.5 lines). Eight patients had ≥ 12 months of follow-up (Group 1); 15 patients had ≥ 3 months of follow-up (Group 2). The mean BCVA for Group 1 improved significantly ($P < 0.05$) from 45 letters (20/120; 8 lines) to 60 letters (20/60; 11 lines), having received an average of 2.75 injections (range: 1-5) during this period and an average of one injection thereafter (mean follow-up after 12 months: 8 months). The mean BCVA for Group 2 improved significantly ($P < 0.05$) from 47 letters (20/120²⁺; 8 lines) to 61 letters (20/60¹⁺; 11 lines), having received an average of 1.3 injections. CMT for all patients decreased from a mean of 266 μ m at baseline to 201 μ m at 1 month, 181 μ m at 3 months and 192 μ m at 12 months (Group 1). Greater patient age was correlated with the need for more frequent injections. The oldest half of Group 1 (mean age 68.5 years) required an average of 3.75 injections, while the youngest half (mean age 39.5 years) required only 1.75. In Group 2, an inverse correlation between age and time between injections was observed. A total of 42 injections were administered. No peri- or post-injection ocular or systemic side effects were noted in either group.

Conclusion: Short-term and twelve-month results indicate that IVB is a safe and effective method to improve visual, reduce CMT and inhibit progression of mCNV.

KEYWORDS

anti-VEGF; Avastin; bevacizumab; choroidal neovascularization; myopia

.....

* Medical Retina Department, Department of Ophthalmology, University Hospitals Leuven, Belgium

Submitted: 14-05-09

Accepted: 18-07-09

Bull. Soc. belge Ophtalmol., 312, 17-27, 2009.

17

INTRODUCTION

Pathological myopia, defined as myopia with complications in the posterior segment, is a leading cause of legal blindness in many developed countries (1), affecting approximately 2% of the general population (2). Myopic choroidal neovascularization (mCNV) is a sight-threatening complication of pathological myopia and the second-leading cause of secondary neovascular maculopathy, after age-related macular degeneration (AMD). Myopic CNV develops in approximately 5% to 10% of highly myopic eyes (3), making this the most common vision-threatening complication of high myopia. Because of the subsequent atrophic changes, the disease has a poor prognosis, and mCNV thus leads to significant vision loss in patients who are often young and otherwise healthy. (4,5,6)

Different therapeutic approaches, including thermal laser photocoagulation (7), radiotherapy (8), surgery (9,10) and verteporfin photodynamic therapy (PDT), (11) with or without triamcinolone acetonide, have been reported, without significant success. This has prompted the search for more effective treatment modalities for mCNV. The current study used bevacizumab to treat mCNV. The goal of the study was to determine whether 1.25 mg IVB on an as-needed basis would be efficacious and safe in the treatment of myopic CNV. The primary endpoints were BCVA at 1, 3, 6, 9 and 12 months. Secondary endpoints were CMT at the same time points, and safety during the entire follow-up period.

METHODS

A retrospective chart review was performed of 23 eyes of 23 consecutive patients treated with 1.25 mg IVB for mCNV. Only eyes with confirmed presence of CNV on FA and pathologic myopia, defined as a refractive error (spherical equivalent) of -6.00 diopters (D) or more, and treated with 1.25 mg IVB, were included. Exclusion criteria were laser photocoagulation in the study eye; a history of triamcinolone acetonide sub-Tenon injection during the previous six months before the initial IVB; cataract surgery during follow-up; the presence of a seri-

ous posterior segment complication, such as retinal detachment or foveoschisis; and the presence of severe cataract in the study eye. Of the 23 eyes included in the review, 8 eyes had been followed up for 12 months or longer after the first injection (designated as Group 1) and 15 eyes with at least 3 months of follow-up (Group 2). Patients had been informed about the benefits, risks, off-label nature, and alternatives to treatment before treatment was initiated, as is standard in our department.

EXAMINATIONS

Each patient underwent complete ocular examination, including BCVA (Early Treatment of Diabetic Retinopathy protocol, ETDRS), OCT (Cirrus HD-OCT, Carl Zeiss Meditec, Jena, Germany) and FA at baseline. Each follow-up examination consisted of a complete dilated ocular examination, BCVA and OCT. The same examiner performed the BCVA and OCT examinations at each patient visit. Color fundus photographs were obtained and FA was performed using a conventional digitalized fundus camera (Topcon TRC-50DX Fundus Camera, Topcon, Itabashi, Tokyo, Japan) before the initial IVB and later based on a decrease in visual acuity, an increase in CMT of $> 100 \mu\text{m}$ on OCT, the recurrence of macular edema on OCT and/or leakage on FA.

INTRAVITREAL BEVACIZUMAB

Patients received 1.25 mg / 0.05 ml intravitreal bevacizumab injections (Avastin®, Roche, Basel, Switzerland) using the standard protocol of the medical retina department of the Department of Ophthalmology at Leuven University Hospital, following the instillation of topical anesthetic drops under sterile conditions. Povidone-iodine 10% solution (Braunol®, B. Braun Medical, Diegem, Belgium) was applied to the periocular area; povidone-iodine 5% (Iso-Betadine Ophta®, Meda Pharma, Solna, Sweden) solution was applied topically. Bevacizumab was injected into the vitreous cavity using a 30-gauge needle inserted through the inferotemporal pars plana 3.0 mm (pseudophakic) or 3.5 mm (phakic) posterior to the limbus. Patients were instructed to instill one drop of ofloxacin eye drops (Trafloxal®, Dr. Mann Phar-

ma, Berlin, Germany) into the injected eye three times daily for three days after the intravitreal injection.

All patients had undergone FA before the first IVB treatment. An "evaluate-and-extend" regimen was followed, in which patients were initially followed up at 4-week intervals after the first injection. This interval was gradually extended to a maximum of three months between visits. Retreatment was based on a decrease in visual acuity, an increase in CMT of $> 100 \mu\text{m}$ on OCT, the recurrence of macular edema on OCT and/or leakage on FA. Further, patients were advised to return to the clinic in between scheduled appointments for evaluation if they experienced a loss of vision or increased metamorphopsia.

For the purpose of analysis, ETDRS visual acuity data were converted into equivalent logarithms of the minimum angle of resolution (log MAR) values. Data were analyzed using the paired two-sample t-test for means. A p -value of less than 0.05 was considered to be statistically significant.

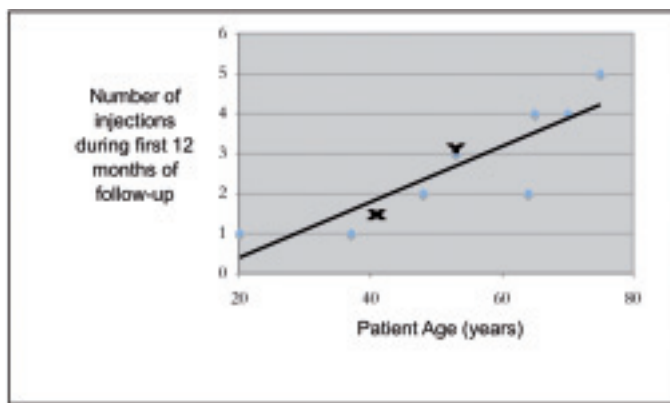


Fig. 1: Correlation between patient age and injection frequency in patients with 12-month follow-up (Group 1). X = data from Wu *et al.* (mean patient age = 41.5 years; mean injection frequency = 1.4); Y = data from Rhéaume *et al.* (mean patient age = 53.5 years; mean injection frequency = 3.1)

RESULTS

Fifteen women (65%) and eight men (35%) with a mean age of 57.7 years (range 20-84) were included in this study. Prior ocular treatment included photodynamic therapy in 10 patients (5 in Group 1 and 5 in Group 2) and intravitreal triamcinolone in 1 patient (Group 2). All treatments were performed at least 6 months prior to IVB. Three patients were pseudophakic. One patient had suffered a retinal detach-

Table 1: Mean visual acuity measurements at baseline each of the main time points after initial intravitreal bevacizumab treatment for myopic choroidal neovascularization

Patient group	BCVA					
	Baseline	1m	3m	6m	9m	12m
Group 1 (n = 8)	20 / 120	20 / 80 ⁻	20 / 80 ⁺	20 / 80	20 / 60 ⁺	20 / 60
Group 2 (n = 15)	20 / 120 ⁺⁺	20 / 80 ⁺	20 / 60 ⁼	/	/	/
All patients (n = 23)	20 / 120 ⁺	20 / 80	20 / 80 ⁺⁺	/	/	/

BCVA = best-corrected visual acuity; VA = visual acuity

Table 2: Central macular thickness at baseline, 1 and 3 months (all patients) and at 6, 9 and 12 months (Group 1).

Group	Central Macular Thickness (mm)					
	Baseline	1m	3m	6m	9m	12m
Group 1 (n=8)	361	307	276	261	270	262
Group 2 (n=15)	367	318	284	/	/	/
All patients (n=23)	365	314	281	/	/	/

μm = micrometers; m = months

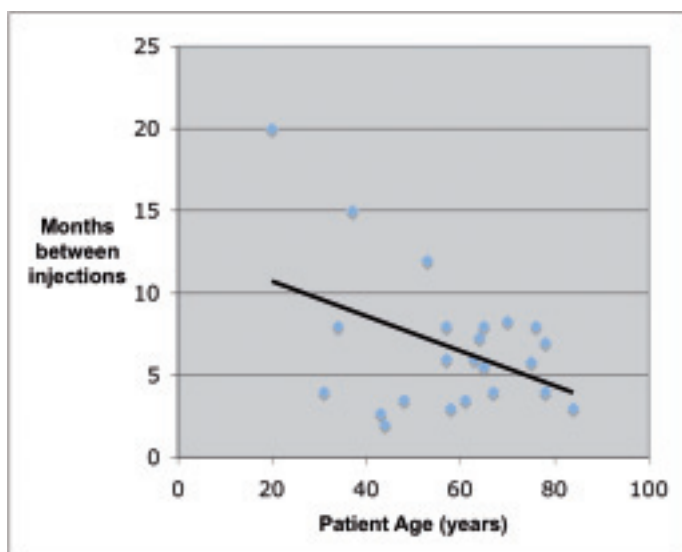


Fig. 2: Correlation between injection frequency (months between injections) and patient age for all patients (n=23).

ment in the study eye, which was treated with a scleral buckle 7 years prior to the first bevacizumab injection. All patients in Group 1 had at least 12 months of follow-up. An OCT scan was performed at each patient visit to the clinic. No ocular or systemic side effects were noted.

The mean log MAR BCVA for all patients (n=23) was 0.77 (Snellen equivalent: 20/120⁺; 8 ETDRS lines) at baseline, 0.60 (20/80; 10 lines) at 1 month and 0.55 (20/60²; 10.5 lines) at three months. In Group 1 (n=8), the mean BCVA was log MAR 0.80 (20/120; 8 lines) at baseline, 0.63 (20/80²; 9.5 lines) at 1 month, 0.58 (20/80⁺; 10 lines) at 3 months, 0.61 (20/80; 10 lines) at 6 months, 0.48 (20/60⁺;

11 lines) at 9 and 0.50 (20/60; 11 lines) at 12 months (Table 1). In Group 2 (n=15), the mean BCVA was log MAR 0.75 (20/120²; 8 lines) at baseline, 0.59 (20/80²; 9.5 lines) at 1 month and 0.54 (20/80⁺; 10 lines) at 3 months (Table 1). The mean differences in log MAR VA between baseline and each of the follow-up points for all patients and for both groups were statistically significant ($P < 0.05$).

Increased patient age was associated with the need for more frequent injections (Figures 1 and 2). Of the 8 patients with 12-month follow-up (Group 1), the oldest half (mean age: 68.5 years) required an average of 3.75 injections, while the youngest half (mean age: 39.5 years) required 1.75 (Table 3). In those patients with shorter follow up (Group 2), there was an inverse relationship between age and time between injections; older patients required more frequent injections (Figure 2). However, the mean visual acuity improvement was almost identical between older and younger patients, improving a mean of 3 lines in both the older and younger patients (Table 3). The mean CMT for all patients was 365 mm at baseline, 314 mm at 1 month and 281 mm at 3 months (Table 2; Figure 3). For Group 1, the mean CMT was 261 mm at 6 months; 270 mm at 9 months and 262 at 12 months (Table 2). The mean differences in CMT between baseline and each of the follow-up points were statistically significant ($P < 0.05$).

Table 3: Age, visual acuity and injection frequency in patients with 12-month follow-up (Group 1)

BCVA	Mean Age (years)	Baseline VA	Final VA	ETDRS lines gained	Injections
Older patients (n=4)	68.5	20 160 ⁺	20 / 80 ⁺	3	3.75
Younger patients (n=4)	39.5	20 / 100 ⁻	20 / 50 ⁻	3	1.75
All patients in current study (n=8)	54.0	20 / 120	20 / 60	3	2.75

BCVA = best corrected visual acuity; VA = visual acuity; * pro-rated from 2.6 injections over 10 months

Explore Litigation Insights

Docket Alarm provides insights to develop a more informed litigation strategy and the peace of mind of knowing you're on top of things.

Real-Time Litigation Alerts



Keep your litigation team up-to-date with **real-time alerts** and advanced team management tools built for the enterprise, all while greatly reducing PACER spend.

Our comprehensive service means we can handle Federal, State, and Administrative courts across the country.

Advanced Docket Research



With over 230 million records, Docket Alarm's cloud-native docket research platform finds what other services can't. Coverage includes Federal, State, plus PTAB, TTAB, ITC and NLRB decisions, all in one place.

Identify arguments that have been successful in the past with full text, pinpoint searching. Link to case law cited within any court document via Fastcase.

Analytics At Your Fingertips



Learn what happened the last time a particular judge, opposing counsel or company faced cases similar to yours.

Advanced out-of-the-box PTAB and TTAB analytics are always at your fingertips.

API

Docket Alarm offers a powerful API (application programming interface) to developers that want to integrate case filings into their apps.

LAW FIRMS

Build custom dashboards for your attorneys and clients with live data direct from the court.

Automate many repetitive legal tasks like conflict checks, document management, and marketing.

FINANCIAL INSTITUTIONS

Litigation and bankruptcy checks for companies and debtors.

E-DISCOVERY AND LEGAL VENDORS

Sync your system to PACER to automate legal marketing.