

# Controversies in the Long-term Management of Neovascular AMD

## The role of imaging in clinical decision making

January 1, 2010

0

---

## Controversies in Long-term AMD Management

The role of imaging in clinical decision making.

### SCOTT W. COUSINS, MD

Patients and retinal physicians are extraordinarily fortunate to live in an era where new therapies for neovascular AMD have revolutionized recovery of visual acuity. We are approaching the five-year anniversary of the introduction of anti-VEGF monotherapy, and the vast majority of patients with neovascular AMD demonstrate outstanding initial response. Unfortunately, it is clear that neovascular AMD does not disappear after two years of therapy. Further, the major pivotal studies, which followed patients for two years, focused predominantly on optimizing visual acuity.<sup>1</sup> However, in the real world, additional therapeutic goals come into play, including minimizing treatment burden and cost and maximizing both ocular and systemic safety. High-quality scientific data are lacking to provide guidance for successful long-term management on these issues.

Induction-maintenance has become the standard approach for most retinal physicians.<sup>2</sup> This idea was initially introduced based on the observation of a rapid gain of mean letters of visual acuity during the first three injections of ranibizumab (induction), followed by the sub-sequent stable plateau of visual acuity during the next 21 months (maintenance). Once induction has been achieved, then what? How is stable long-term visual acuity successfully maintained?

---

Scott W. Cousins, MD is the Robert Machemer Professor of Ophthalmology and Immunology at Duke University School of Medicine. He is also vice chair for research and director of the Duke Center for Macular Diseases. His research interests include the use of imaging technology to understand the biology of and develop new treatments for CNV resistant to anti-VEGF therapy. Dr. Cousins is a consultant for Heidelberg Engineering and Genentech. He can be reached at [scott.cousins@duke.edu](mailto:scott.cousins@duke.edu).

Three different long-term maintenance strategies have evolved: (1) scheduled injections (arbitrary injection interval based on theoretical pharmacokinetic data); (2) induce and observe (retreatment of recurrent leakage based on specific indications); or (3) induce and extend (gradual lengthening of intervals between injections until it recurs once; then a regular scheduled injection interval is chosen based on the previous interval before leakage occurred). Space limitations prevent a detailed analysis of strengths and weaknesses of the three choices. but

among retinal specialists, but intermittent treatment raises the very real possibility of under treatment. And what is an effective way to identify and treat eyes that fail to respond to induction, or eyes that develop recurrence while on maintenance therapy?

In the following article, we suggest that imaging technologies in addition to standard optical coherence tomography should continue to play a major role in monitoring the patient with neovascular AMD during the maintenance phase of anti-VEGF therapy. In particular, we identify four common clinical scenarios, with case examples providing anecdotal evidence that spectral-domain OCT, fluorescein angiography and high-speed indocyanine green angiography still play an important role in monitoring and treatment of patients in the anti-VEGF therapy era.

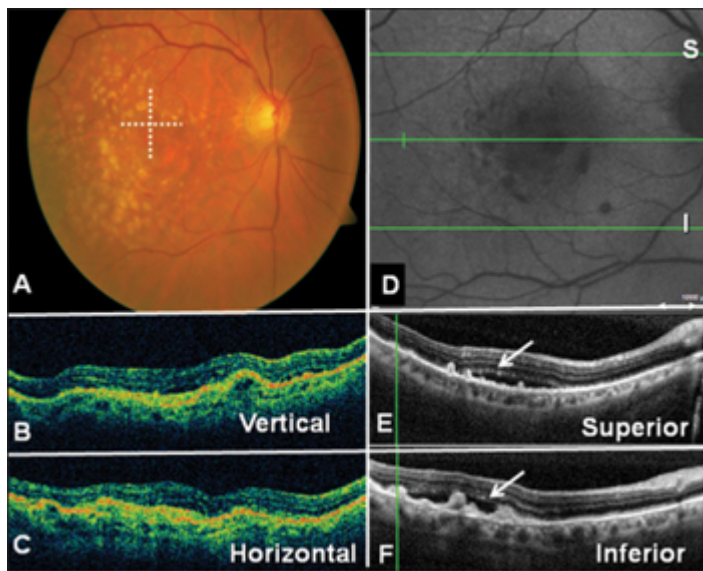
## REPEAT IMAGING AFTER SCHEDULED INDUCTION: WHAT IS A “SUCCESSFUL” INDUCTION?

Implicit in the induction-maintenance paradigm is the assumption that induction (ie, three monthly injections) is scientifically validated. Unfortunately, it is not. Further more, even an anatomic definition of induction (ie, continued monthly injections until evidence of all leakage has disappeared) is problematic because the meaning of “drying up leakage” is dependent on the imaging modality utilized. Nonetheless, we believe that the combined usage of both OCT (especially SD-OCT) and FA at the completion of three induction injections is very useful in planning the subsequent maintenance phase of therapy.

• **Role of OCT: Time-domain vs Spectral-domain OCT** Standard (time-domain) OCT has become the main imaging modality used in the long-term management of neovascular AMD by most retinal specialists. It has been extraordinarily useful in demonstrating the presence of sub-retinal fluid and intraretinal cystic changes that were not apparent upon clinical examination or fluorescein angiography. Importantly, OCT-based therapeutic decision making was not part of the original pivotal trials.<sup>1,2</sup>

In addition, the use of standard OCT to make retreatment decisions, either on the basis of “induce and observe” or “induce and extend,” is problematic because of under-sampling across the macula, as well as potential artifacts.<sup>3</sup> For instance, the standard Stratus map is based upon the use of six radial B scans (a relatively small sample of the total macula) to produce a map that is an interpolation. This scan strategy may fail to detect areas of subretinal or intraretinal fluid. In addition, because of errors in segmentation and other artifacts, the quantitative thickness measurements in standard OCT can be inaccurate and demonstrate artifactual intertest variability. Finally, there is a surprisingly poor correlation between OCT responsiveness and ultimate visual acuity. Therefore, there is no scientific evidence to indicate that using standard OCT based on traditional surface map, quantitative measures, or cross-section analysis is an effective way to determine maintenance intervals or retreatment.

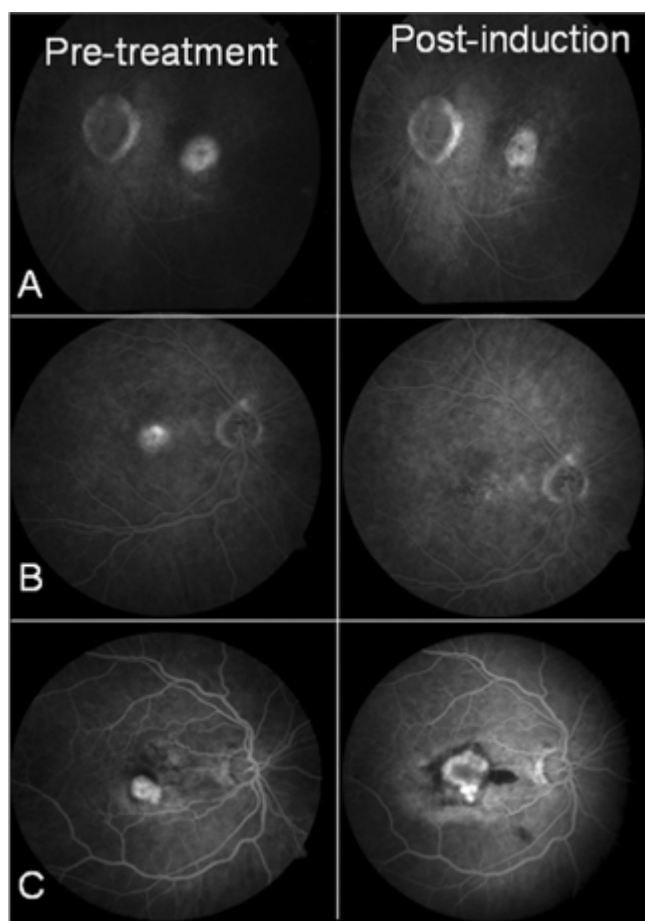
Spectral-domain OCT offers the potential advantages of a greater number of sampling scans across the macula. Some technologies (Spectralis, Heidelberg) have very robust image registration so that intertest variability is reduced. Anecdotal case reports demonstrate that fluid not detected by standard OCT can be imaged by SD-OCT. It is attractive to speculate that defining “induction success” by fluid resolution imaged by SD-OCT “full macula volume scan,” rather than by standard OCT, would result in better long-term success and fewer recurrences in the maintenance phase of therapy (See **Figure 1.**)



**Figure 1. Subretinal fluid detected by spectral-domain OCT but not standard OCT. An 81-year-old male with occult CNV underwent induction with three monthly injections of ranibizumab, gaining one line of vision. Clinical exam and standard OCT (panels A-C) indicated resolution of subfoveal fluid. However, SD-OCT (panels D-F) indicated persistence of significant extrafoveal subretinal fluid not imaged by standard OCT. Considered to be a partial response to induction, the patient continued on monthly injections until all fluid had disappeared.**

- **Fluorescein Angiography.** For 40 years, FA has been the gold standard for diagnosis and monitoring treatment responses in neovascular AMD.<sup>4</sup> Although it continues to remain crucial for diagnosis, its role in the long-term management of neovascular AMD has become less clear. As a small, highly charged molecule, fluorescein dye is ideally suited for the detection of leakage. Nonetheless, fluorescein leakage can be difficult to interpret in the era of digital FA, especially to distinguish fluorescein that remains extravascular but intralésional (ie, stain) vs subretinal fluid vs intraretinal fluid. This complexity has lowered the enthusiasm for use of FA for monitoring therapy.

More important than leakage detection, FA remains very useful for determining the size (ie, surface area) of CNV and whether area has remained stable, enlarged, or regressed. In a recent study, we observed that, in eyes with predominantly classic CNV, 16% demonstrated significant regression after induction with anti-VEGF monotherapy, but an equal percentage showed enlargement during treatment.<sup>5</sup> The majority of cases demonstrated only a modest reduction in the surface area, with residual staining of the entire CNV (see **Figure 2**).

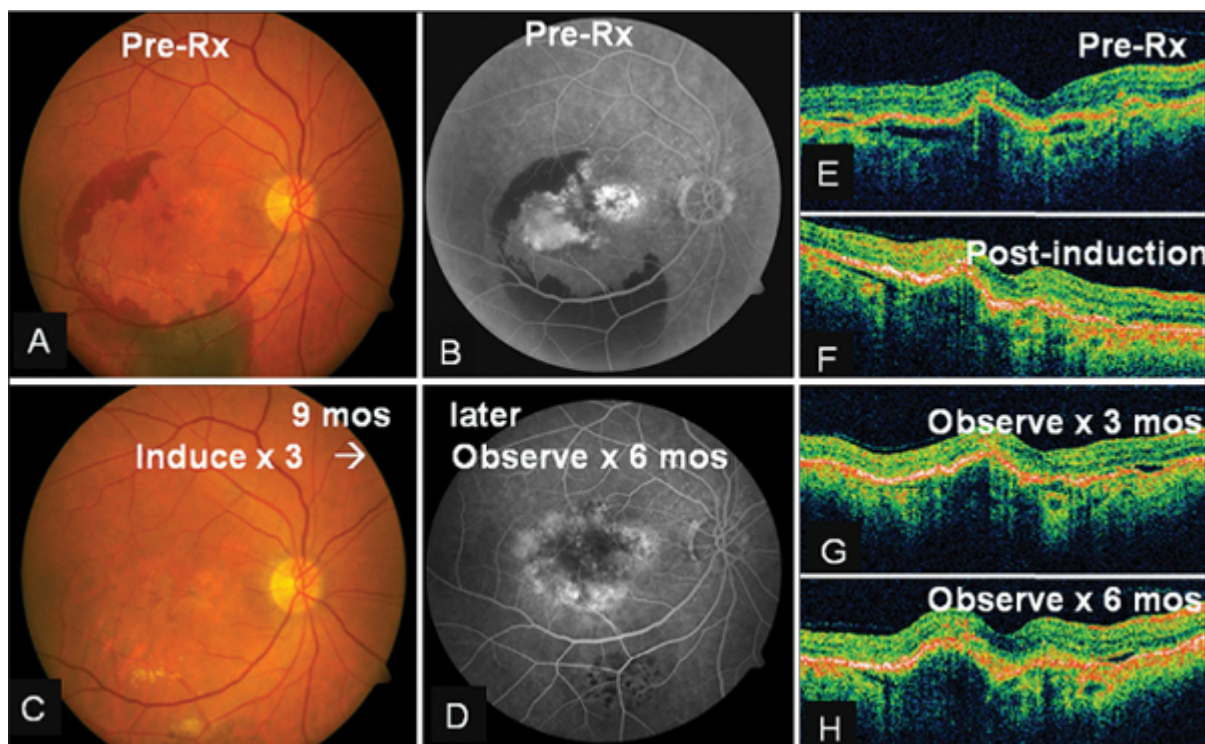


**Figure 2. Fluorescein angiograms demonstrating different treatment responses after anti-VEGF induction. Panel A (left and right) demonstrates inactive but stable CNV, with decreased leakage but persistent staining and unchanged area of the lesion. Panel B demonstrates CNV regression, with disappearance of both leakage and staining. Panel C demonstrates CNV progression with new hemorrhage and enlargement in area, despite receiving three monthly doses of ranibizumab.**

We use imaging to determine if the induction regimen has produced any CNV regression. Although speculative, it is attractive to postulate that those eyes that showed complete regression of CNV would be more likely to do well with extended treatment intervals, whereas those eyes without significant regression will require more frequent intervals of treatment. Conversely, CNV that progressed during induction is resistant to anti-VEGF therapy and requires a switch in therapy (see below).

## MAINTENANCE PHASE: WHEN TO REORDER IMAGING

The rationale for “induce and observe” with OCT-guided retreatment is based on an uncontrolled prospective study using monthly re-evaluation with standard OCT.<sup>6</sup> In this study, patients treated with this protocol were able to maintain the initial visual gains for two years. The interpretation of this study is complicated by the fact that the OCT retreatment criteria changed during the course of the study. In addition, reinjection criteria included monthly clinical examination, as well as five-letter change in best corrected visual acuity data (the most frequent criteria for reinjection). A prospective multicentered study (SAILOR) used similar criteria in a “real-world” setting. Unfortunately, this study failed to demonstrate maintenance of long-term visual gain over the subsequent observation period. Furthermore, no scientific data exist to support the treat-and-extend strategy. Bottom line: There is high risk for undertreatment of some eyes with “induce and observe” or “induce and extend” maintenance strategies. Therefore, we repeat fluorescein angiography every six to nine months to rule out enlargement of CNV area or other changes in fluorescein patterns (see **Figure 3**).



**Figure 3. Enlargement of CNV area in spite of stable OCT. A 67-year-old male with occult CNV associated with hemorrhagic PED (panels A, B and E) underwent induction with ranibizumab. Examination and OCT improved (panel F). The patient was observed during the subsequent six months, returning every six weeks for exam and standard OCT (Panels G and H). Clinical exam and vision remain unchanged (panel C). However, repeat fluorescein at six months postinduction demonstrated significant increase in CNV area (panel D), suggesting undertreatment.**

## RESISTANCE TO MONOTHERAPY: WHAT TO DO WHEN STANDARD THERAPY IS INEFFECTIVE?

Another controversy in the management of neovascular AMD is the idea of anti-VEGF therapy resistance. Anatomical resistance is defined as the failure to reverse leakage and/or normalize other morphological evidence of neovascularization after anti-VEGF induction. The anatomical definition can be based upon clinical examination or, more commonly based upon imaging criteria. We define anti-VEGF resistance after induction by FA and OCT as: subfoveal CNV that bled or increased in size by FA; subfoveal CNV that show persistent significant residual sub-retinal fluid and/or intraretinal cysts by OCT; or serous pigment epithelial detachments (PEDs) that fail to flatten by OCT.

Recently, we observed in our “real-world” retina practice (rather than well-defined cases as found in a trial) that about 25% of cases demonstrated some form of anatomic resistance.<sup>7</sup> Approximately 5% of eyes that were deemed resistant demonstrated fibrovascular PEDs or occult CNV that failed to resolve subretinal or intraretinal fluid. In addition, about 5% of all cases (and 15% of predominantly classic CNV) demonstrated increased size or developed new hemorrhage while on induction therapy. However, the majority of cases demonstrating resistance were serous PEDs (without RAP lesions) in which the PED failed to flatten.

- **Indocyanine Green Angiography.** ICGA is very useful in trying to explain and treat cases of anti-VEGF therapy resistance. Indocyanine green dye has the property of being predominantly protein bound and therefore tends to remain intravascular with less leakage than fluorescein dye.<sup>8</sup> Static ICGA which uses bright-flash illumination with images acquired every two to five seconds, typically evaluates hyperfluorescence (ie, leakage) at 15 and 30

# Explore Litigation Insights

Docket Alarm provides insights to develop a more informed litigation strategy and the peace of mind of knowing you're on top of things.

## Real-Time Litigation Alerts



Keep your litigation team up-to-date with **real-time alerts** and advanced team management tools built for the enterprise, all while greatly reducing PACER spend.

Our comprehensive service means we can handle Federal, State, and Administrative courts across the country.

## Advanced Docket Research



With over 230 million records, Docket Alarm's cloud-native docket research platform finds what other services can't. Coverage includes Federal, State, plus PTAB, TTAB, ITC and NLRB decisions, all in one place.

Identify arguments that have been successful in the past with full text, pinpoint searching. Link to case law cited within any court document via Fastcase.

## Analytics At Your Fingertips



Learn what happened the last time a particular judge, opposing counsel or company faced cases similar to yours.

Advanced out-of-the-box PTAB and TTAB analytics are always at your fingertips.

## API

Docket Alarm offers a powerful API (application programming interface) to developers that want to integrate case filings into their apps.

## LAW FIRMS

Build custom dashboards for your attorneys and clients with live data direct from the court.

Automate many repetitive legal tasks like conflict checks, document management, and marketing.

## FINANCIAL INSTITUTIONS

Litigation and bankruptcy checks for companies and debtors.

## E-DISCOVERY AND LEGAL VENDORS

Sync your system to PACER to automate legal marketing.