

Intravitreal Vancomycin

Retinal Toxicity, Clearance, and Interaction With Gentamicin

Stephen C. Pflugfelder, MD; Eleut Hernández; Steven J. Fliesler, PhD; Juana Álvarez; Maureen E. Pflugfelder, MT (ASCP); Richard K. Forster, MD

● Some of the gram-positive isolates from exogenous bacterial endophthalmitis cases treated at our institution have been found to be resistant to either cefazolin sodium, gentamicin sulfate, or both. However, all of these isolates have been sensitive to vancomycin. These findings prompted us to reevaluate the retinal toxicity and clearance of intravitreal vancomycin in pigmented rabbits. Doses up to 2 mg were found to be nontoxic in phakic and aphakic-vitreotomized eyes. Clearance was determined in phakic and aphakic-vitreotomized rabbit eyes with or without intact lens capsules. The antibiotic was cleared most slowly in phakic eyes. Aphakic-vitreotomized eyes without an intact lens capsule cleared antibiotic most rapidly, while aphakic-vitreotomized eyes with intact capsules exhibited an intermediate clearance rate. In addition, the interaction between vancomycin and gentamicin on gram-positive endophthalmitis isolates was found to be additive or synergistic depending on the bacterial species. Based on these data, we recommend the combination of vancomycin and an aminoglycoside as the initial antibiotic therapy for exogenous bacterial endophthalmitis.

(Arch Ophthalmol 1987;105:831-837)

Sixty-six percent of the exogenous endophthalmitis cases from our institution have been caused by gram-positive bacteria, and 25% have been caused by streptococcal species.¹⁻³ Antibiotic sensitivities for these isolates indicate that some of the orga-

nisms, particularly streptococci, are resistant to cefazolin sodium and gentamicin sulfate, the two antibiotics most often recommended for initial intravitreal therapy.^{4,5} Yet, 100% of the gram-positive endophthalmitis isolates (including *Streptococcus*, *Staphylococcus*, and *Bacillus* species) were sensitive to vancomycin.

Vancomycin has previously been evaluated for endophthalmitis therapy. In 1967, Pryor and colleagues⁶ found that therapeutic aqueous levels could be achieved after topical or subconjunctival administration of vancomycin; however, vitreous levels were negligible. Homer and associates⁷ examined the retinal toxicity and clearance of intravitreal vancomycin in rabbits and found that an intravitreal dose of 1 mg was nontoxic to the sensory retina. Prolonged therapeutic levels were achieved after a single intravitreal injection of 1 mg, and vancomycin was found to be effective in treating experimental methicillin-resistant *Staphylococcus aureus* endophthalmitis. Recently, Smith et al⁸ also reported success in treating experimental methicillin-resistant *Staphylococcus epidermidis* endophthalmitis with vancomycin. In that study, a 5-mg intravitreal dose of vancomycin hydrochloride was found to be nontoxic in phakic albino rabbits.

To recommend an intravitreal dose for the treatment of exogenous bacterial endophthalmitis, we reevaluated the retinal toxicity of intravitreal vancomycin in phakic and aphakic-vitreotomized pigmented rabbit eyes. We also examined the clearance of intravitreal vancomycin in phakic and aphakic-vitreotomized eyes both with and without intact lens capsules. Finally, because of the potential therapeutic efficacy of vancomycin in con-

junction with an aminoglycoside antibiotic, we evaluated the interaction of this combination on common endophthalmitis isolates by a microdilution checkerboard assay.

MATERIALS AND METHODS Toxicity

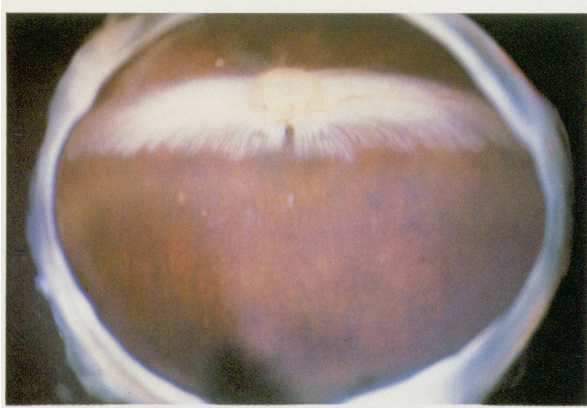All studies were performed using Dutch Belted pigmented rabbits (weight range, 2.5 to 3.5 kg) with an average vitreous volume of 1.4 mL. The toxicity of vancomycin was evaluated in both phakic and aphakic-vitreotomized eyes. The following doses were evaluated: in phakic eyes, 0.5, 1, 2, 3, and 5 mg; in aphakic-vitreotomized eyes, 1, 2, and 5 mg. Three or more eyes were examined for each antibiotic dose. All doses of antibiotics were prepared by a pharmacist in 0.1 mL of preservative-free sterile water. Antibiotics were administered into the vitreous cavity via the pars plana, 2 to 3 mm posterior to the limbus, using a 1-mL syringe with a 27-gauge needle. The injection was performed slowly with the bevel of the needle facing anteriorly. Antibiotic injection was performed only in the left eye of each animal; the right eye served as a control. Rabbits were anesthetized with a mixture of ketamine hydrochloride (14 mg/kg) and xylazine (7 mg/kg) prior to the injection. The rabbits were killed with a lethal intravenous injection of pentobarbital sodium.

Lensectomy was performed by a pars plana approach using an ultrasonic lens fragmentor.⁹ The anterior lens capsule was retained in some eyes for the toxicity and clearance portions of the study. Pars plana vitrectomy was performed using an automated vitreous suction-cutter.⁹ Eyes were treated with 1% atropine ointment once a day for two to four weeks after surgery before they were used to evaluate toxicity and clearance. Sensory retinal toxicity was evaluated by direct observation, electroretinography, and light and electron microscopy. Indirect ophthalmoscopy of the rabbit fundus after dilation was performed at the following times after intravitreal vancomycin injection: five minutes, 24 hours,

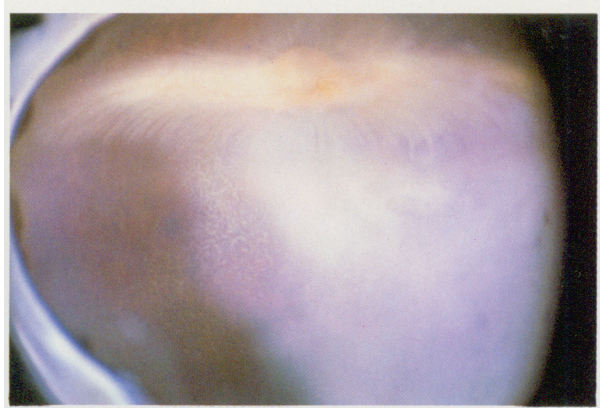Accepted for publication Feb 26, 1987.

From the Department of Ophthalmology, University of Miami School of Medicine.

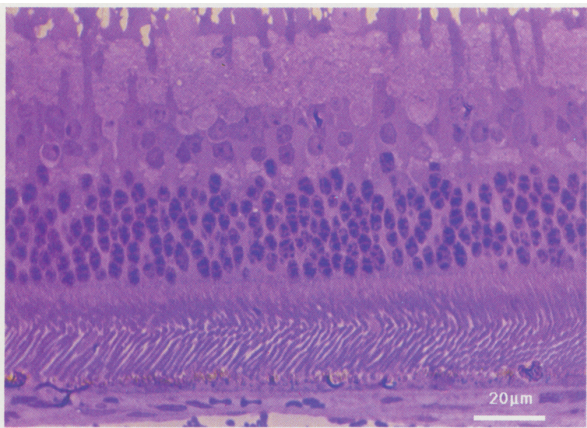
Reprint requests to Bascom Palmer Eye Institute, PO Box 016880, Miami, FL 33101 (Dr Pflugfelder).



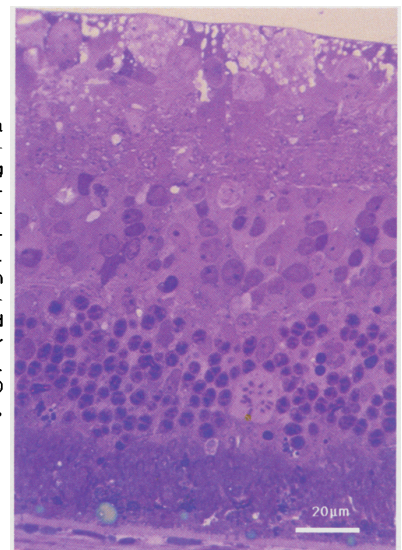
Color Fig 1.—Normal-appearing fundus three days after injection of 2 mg of vancomycin into vitreous cavity of phakic pigmented rabbit eye.



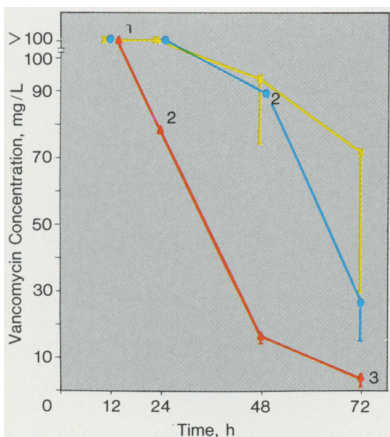
Color Fig 2.—Retinal opacification three days after injection of 5 mg of vancomycin into vitreous cavity of phakic pigmented rabbit eye.



Color Fig 3.—Normal-appearing retina and pigment epithelium of phakic pigmented rabbit eye after 2-mg intravitreal dose of vancomycin. Bar represents 20 μm (toluidine blue, X1000).

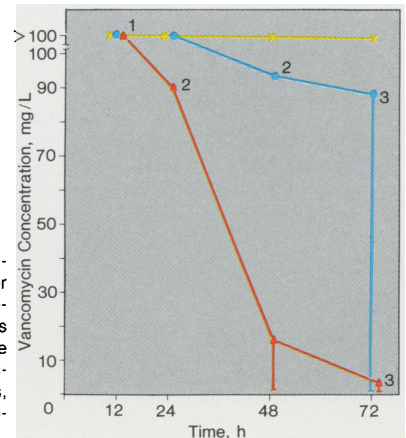


Color Fig 4.—Retina and pigmented epithelium after 5-mg intravitreal vancomycin dose in aphakic-vitreotomized pigmented rabbit eye. Note disorganization of photoreceptor inner segments and loss of photoreceptor outer segments. Bar represents 20 μm (toluidine blue, X1000).



Color Fig 5.—Aqueous vancomycin concentration after injection of 2 mg into anterior vitreous cavity of rabbit eye. Each point represents average value from two eyes; bars indicate lower confidence limit that could be calculated. 1 indicates that one aphakic-vitreotomized eye without lens capsule was evaluated at 12 hours; 2, that one of two eyes had aqueous (or vitreous) vancomycin concentration greater than 100 mg/L, with point representing mean of 100 and lower measured value; and 3, that lower confidence limit includes zero. Triangles indicate aphakic-vitreotomized eyes without lens capsule; ovals, aphakic-vitreotomized eyes with intact capsule; and x's, phakic eyes.

Color Fig 6.—Vitreous vancomycin concentration after injection of 2 mg into anterior vitreous cavity of rabbit eye. Each point represents average value from two eyes; bars indicate lower confidence limit that could be calculated. Triangles indicate aphakic-vitreotomized eyes without lens capsule; ovals, aphakic-vitreotomized eyes with intact capsule; and x's, phakic eyes.



48 hours, 72 hours, one week, and two weeks. Bright-flash electroretinography was performed binocularly on rabbits that had been dark-adapted for 30 minutes after pharmacologic mydriasis at 72 hours, one week, and two weeks following intravitreal vancomycin injection. Preinjection and postinjection beta-wave amplitudes were measured in microvolts. Each eye served as its own control. Additionally, the noninjected fellow eye and eyes injected intravitreally with a sterile balanced salt solution also served as controls.

Eyes were fixed for microscopic analysis using a mixture of 2% glutaraldehyde and 2% paraformaldehyde in 0.1 mol/L of sodium phosphate buffer (pH 7.4). This fixative was injected into the rabbit vitreous cavity immediately after death. The eyes were enucleated, the anterior segments were removed, and the posterior eyecups were immersed in fixative for 24 hours at 4°C. Specimens were postfixed in 1% aqueous osmium tetroxide, then dehydrated through a graded ethanol-water series, and finally embedded in epoxy resin. Thick sections (1 µm) were stained with toluidine blue for light microscopy; thin sections (silver-gray) were stained with uranyl acetate-lead citrate for electron microscopy. The photomicrographs shown herein are representative of a given antibiotic dosage and were chosen because they exhibited good photoreceptor alignment and illustrated several ultrastructural features in one field.

Intraocular Clearance

The clearance studies were performed on three groups of pigmented rabbit eyes: phakic, aphakic-vitreotomized with an intact lens capsule, and aphakic-vitreotomized without a lens capsule. Vancomycin hydrochloride (2 mg in 0.1 mL of preservative-free sterile water) was injected into the vitreous cavity, and the eyes were enucleated immediately following death at 12, 24, 48, and 72 hours postinjection. Two eyes were evaluated at each time point in each of the three groups. Aqueous specimens were collected from phakic and aphakic-vitreotomized eyes with an intact lens capsule by removing the fluid with a 25-gauge needle. Those eyes were then frozen in liquid nitrogen, and the vitreous cavity fluid was dissected en bloc by the technique described by Abel and Boyle.¹⁰ In aphakic eyes, the fluid in the aqueous and vitreous cavities was removed with a 25-gauge needle. All specimens were frozen in evaporation-proof containers.

The vancomycin concentration of the ocular fluid was determined by a fluorescent polarization immunoassay.¹¹ Controls consisted of specimens supplied by the manufacturer and undiluted rabbit vitreous mixed with a known concentration of vancomycin.

Combination Antibiotic Testing

Antibiotic sensitivity tests to vancomycin and gentamicin were performed on 14 endophthalmitis isolates from our ocular microbiology laboratory using a microdilution assay.¹² Some of these isolates had

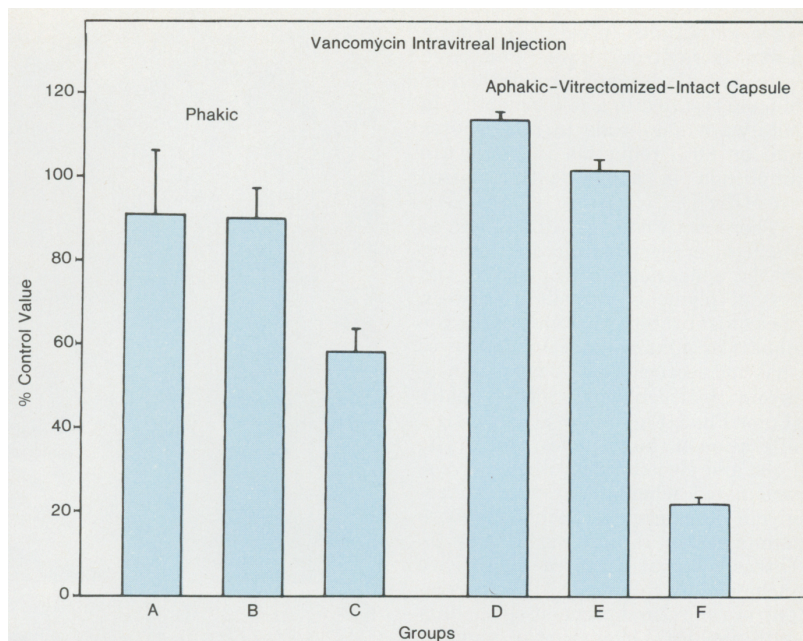


Fig 1.—Mean electroretinogram beta-wave amplitude (in microvolts) of six groups of pigmented rabbit eyes expressed as percentage of beta-wave amplitudes of the normal fellow eyes. Three eyes were evaluated in each group. Standard deviation is indicated by bracket. In phakic eyes, group A received intravitreal injection of saline (control); group B, 2 mg of vancomycin; and group C, 5 mg of vancomycin. In aphakic vitrectomized eyes, group D received intravitreal injection of saline one week postoperatively (control); group E, 2 mg of vancomycin; and group F, 5 mg of vancomycin.

previously been identified as gentamicin-resistant. The interaction of these isolates to a combination of vancomycin and gentamicin was determined by a microdilution checkerboard assay.¹³ The combined effect of the two antibiotics acting together was determined to be either synergistic, indifferent, or antagonistic based on the fractional inhibitory concentration (FIC) index or the appearance of an arithmetic plot of the minimal inhibitory concentrations of the two antibiotics in each well of the microdilution checkerboard plate.¹³ The combination was synergistic if the FIC index was less than 0.5; an FIC greater than 2.0 indicated an antagonistic combination. The FIC index was 1.0 if the effect of two antibiotics was the same as the sum of their individual effects (indifferent or additive).

RESULTS Toxicity

The vitreous and retina appeared normal by indirect ophthalmoscopy in both phakic and aphakic-vitreotomized eyes after injection of intravitreal vancomycin doses of up to 2 mg (Color Fig 1). In doses greater than 2 mg, there was immediate clouding of the vitreous after the injection, and within 24 hours, opacification of the retina was noted (Color Fig 2). By two weeks the retina cleared; however, the retinal pigment epithelium showed

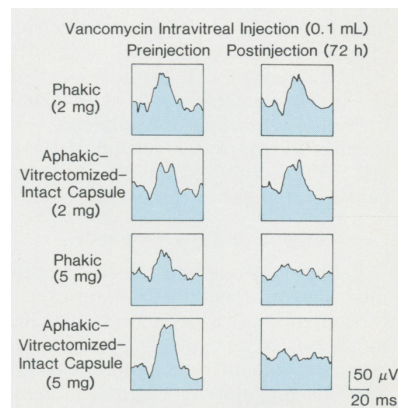


Fig 2.—Preinjection and postinjection electroretinograms of phakic and aphakic-vitreotomized pigmented rabbit eyes with intact capsule after 2- or 5-mg intravitreal injection of vancomycin (in 0.1 mL of preservative-free sterile water).

areas of pigment clumping and atrophy.

There was no electroretinographic evidence of toxicity between control eyes and eyes (phakic or aphakic-vitreotomized) receiving 2 mg of vancomycin intravitreally (Figs 1 and 2). There was marked reduction in the postinjection alpha-wave and beta-

wave amplitudes in eyes receiving a 5-mg intravitreal dose. Compared with control eyes, an intravitreal dose of 5 mg resulted in a 45% reduction in beta-wave amplitude in phakic eyes and an 80% reduction in beta-wave amplitude in aphakic-vitreotomized eyes (Fig 1).

There were no gross differences at the light or electron microscopic level in the appearance of the retina and retinal pigment epithelium between the control rabbit eyes and either the phakic or aphakic-vitreotomized eyes that had received 0.5 to 2 mg of vancomycin hydrochloride intravitreally (Color Fig 3; Figs 3 and 4). Pathologic alteration of these tissues, both at the light and electron microscopic levels, was noted when intravitreal vancomycin doses greater than 2 mg were administered (Color Fig 4; Fig 5). Ultrastructural features of toxicity included the following: (1) hypertrophy of the retinal pigment epithelium with abnormal clustering of pigment granules in the apical cytoplasm; (2) loss of photoreceptor outer segment-retinal pigment epithelium interdigitation due to retraction of apical microvilli of retinal pigment epithelium; (3) appearance of lucent vacuoles (100 to 200 nm in diameter) in the retinal pigment epithelium basal cytoplasm beneath the plasmalemma infoldings; (4) gross disorganization of the photoreceptor outer segments with distension and displacement of the inner segments past the external limiting membrane; (5) pyknosis (especially in the outer retinal layers); and (6) accumulation of cellular debris in the subretinal space.

Intraocular Drug Clearance

Rabbit aqueous and vitreous specimens (seven of each) with vancomycin concentrations ranging from 0 to 100 mg/L served as controls for the fluorescent polarization immunoassay. The vancomycin concentrations measured in the control specimens by this technique were found to differ by 0% to 13% (mean, 6%) from the expected vancomycin concentrations.

The ocular clearance of vancomycin after an intravitreal injection of 2 mg in the three groups of eyes (ie, phakic, and aphakic-vitreotomized with intact lens capsules, and aphakic-vitreotomized without lens capsules) was examined (Color Figs 5 and 6). Vancomycin was cleared most slowly in phakic eyes. At 72 hours postinjection, the average aqueous and vitreous concentrations exceeded 70 and 100 mg/L, respectively. Antibiotic clearance in aphakic-vitreotomized eyes with in-

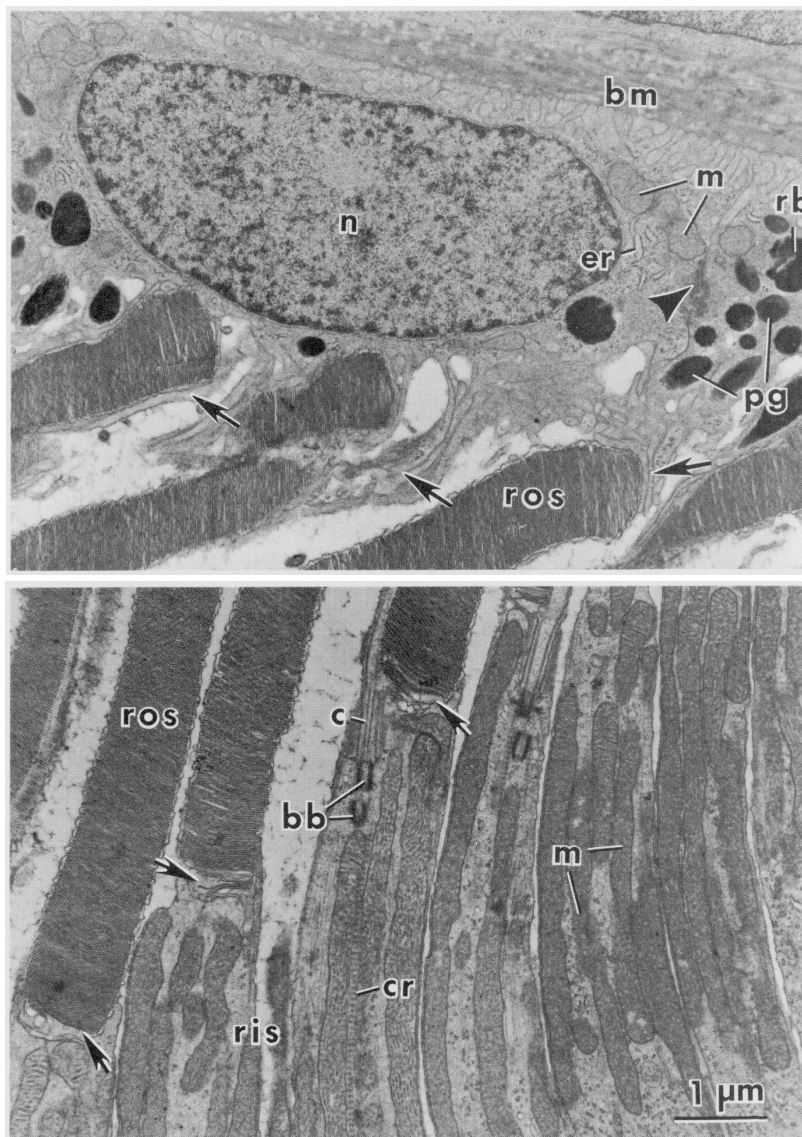


Fig 3.—Transmission electron micrograph of retinal pigment epithelium and photoreceptor cells from phakic pigmented rabbit eye three days after intravitreal injection of 2 mg of vancomycin. Top, Retinal pigment epithelial cell exhibits normal-appearing nucleus (n), endoplasmic reticulum (er), mitochondria (m), and pigment granules (pg). There is close apposition of apical microvilli (arrows) with distal rod outer segments (ros). Occasional residual bodies (rb) are observed in basal retinal pigment epithelial cytoplasm. Intact junctional complex (arrowhead) is shown on basolateral borders of two adjacent retinal pigment epithelial cells. Bruch's membrane (bm) appears normal. Bottom, Longitudinal view of apical rod inner segment (ris) and basal rod outer segment (ros) regions. Disc membranes, including basal "open" discs (arrows), are well aligned and nonvesiculated. Rod cell-connecting cilium (c), basal body (bb), ciliary rootlet (cr), and mitochondria (m) are intact and appear normal (original magnification, $\times 13\,500$).

tact lens capsules was more rapid than in the phakic eyes. The average aqueous and vitreous vancomycin concentrations in these eyes exceeded 25 and 85 mg/L, respectively, at 48 hours. Clearance was most rapid in aphakic-vitreotomized eyes without lens capsules.

Combination Antibiotic Testing

The results of individual and combination antibiotic sensitivity testing on 14 representative gram-positive endophthalmitis isolates from our institution were analyzed (Table). All organisms were found to be sensitive

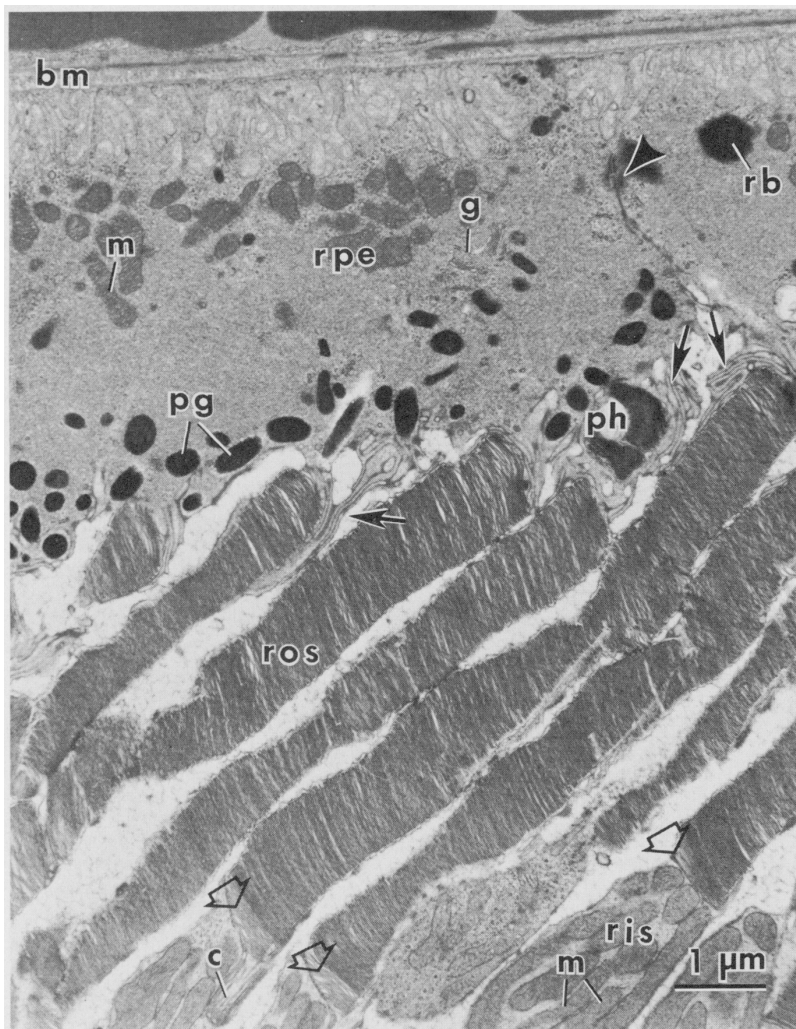


Fig 4.—Transmission electron micrograph of retinal pigment epithelium (rpe) and photoreceptor cells from aphakic-vitreotomized pigmented rabbit eye three days after intravitreal injection of 2 mg of vancomycin. Ultrastructure and distribution of rpe organelles appear normal. m indicates mitochondria; bm, Bruch's membrane; rb, residual bodies; pg, pigment granules; ris, basal rod inner segment; and c, rod cell-connecting cilium. Additional features include well-organized Golgi complex (g) and phagosome (ph). Alignment and ultrastructural features of rod cells appear normal. Note normal nonvesiculated "open" discs (open arrows) at base of rod outer segments (ros). Arrow indicates basal open disc; arrowhead, intact junctional complex (original magnification, $\times 13\,500$).

to vancomycin. *Staphylococcus epidermidis* and *Streptococcus* species were resistant to gentamicin. These organisms had an additive interaction to the combination of vancomycin and gentamicin. *Staphylococcus aureus* and *Bacillus cereus* were sensitive to gentamicin, and they had a synergistic response to the combination of vancomycin and gentamicin.

COMMENT

Forster et al.^{4,5} have recommended the combination of cefazolin and gentamicin as the initial intravitreal antibiotic therapy for bacterial en-

dophthalmitis. However, some of the endophthalmitis isolates at our institution, including an increasing number of coagulase-negative staphylococci and some streptococcal species, have been resistant to both of these antibiotics. All of our gram-positive endophthalmitis isolates have been sensitive to vancomycin.

Homer and associates⁷ evaluated the retinal toxicity of vancomycin in phakic albino rabbits by ophthalmoscopy, electroretinography, and light microscopy in 1975. They found intravitreal doses of 1 mg or less to be nontoxic. More recently, Smith et al.⁸

reported that intravitreal vancomycin hydrochloride doses of 5 mg were nontoxic in phakic albino rabbit eyes. In that study, posterior segment toxicity was evaluated by ophthalmoscopy and light microscopy; ultrastructure was examined in only one eye. In previous studies performed at our institution evaluating intraocular antibiotic toxicity in a rabbit model,^{14,15} visible and histologic toxicity noted in pigmented rabbit eyes was often not detected in albino rabbit eyes at the same intravitreal dosage. We felt it was necessary to reevaluate the sensory retinal toxicity of intravitreal vancomycin in both phakic and aphakic-vitreotomized pigmented rabbit eyes. We found that intravitreal administration of vancomycin in doses up to 2 mg to be nontoxic by all diagnostic criteria, including electron microscopy, in both of these groups. In pigmented rabbit eyes, a 5-mg intravitreal vancomycin dose, which was found to be nontoxic in albino rabbit eyes by Smith et al.,⁸ produced irreversible damage to the retina and retinal pigment epithelium.

We found that lensectomy and vitrectomy increased the intraocular clearance of vancomycin, but they did not alter the threshold for retinal toxicity produced by the antibiotic. A similar phenomenon was found with intravitreal aminoglycoside administration by Talamo et al.¹⁶ They proposed that toxicity is related to the peak concentration of the antibiotic, and not the duration of the contact, to which the retina is exposed shortly after intravitreal injection. Both studies indicate that the retina is exposed to the same peak antibiotic concentration after an injection into the vitreous cavity in both vitrectomized and nonvitrectomized eyes. Since the volume of the average human vitreous cavity is at least twice as great as that of the 3-kg pigmented rabbits used in this study,¹⁷ the peak vitreous vancomycin concentration after an intravitreal injection in a rabbit eye would be greater than in an adult human eye after injection of the same dose. Therefore, a 2-mg intravitreal dose in humans should be well below the toxic threshold if the toxic threshold of the sensory retina is the same in pigmented rabbits and humans.

All of our gram-positive endophthalmitis isolates had a mean inhibitory concentration (MIC) to vancomycin of 4 mg/L or less, with the majority having an MIC of 0.5 to 1.0 mg/L. Aqueous and vitreous vancomycin levels greatly exceeding the MIC of gram-positive organisms were

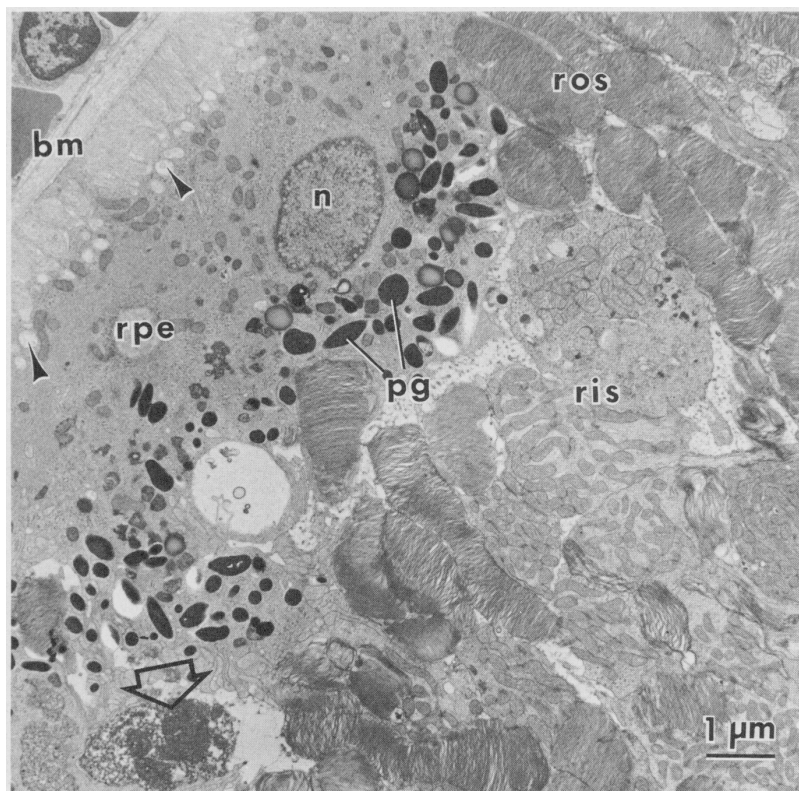


Fig 5.—Transmission electron micrograph of retinal pigment epithelium (rpe) and photoreceptor cells from aphakic-vitrectomized pigmented rabbit eye three days after intravitreal injection of 5 mg of vancomycin. The rpe appears hypertrophied and exhibits abnormal clustering of pigment granules in apical cytoplasm. Apical rpe microvilli are retracted, resulting in loss of photoreceptor interdigitation. The rpe nucleus (n) and Bruch's membrane (bm) appear normal. Although rpe mitochondria appear normal, their distribution within cytoplasm is abnormal. Row of lucent vacuoles (arrowheads), each 100 to 200 nm in diameter, is seen in basal cytoplasm just beneath rpe plasmalemma infoldings. Photoreceptor cell layer is grossly disorganized. Rod outer segments (ros) are poorly aligned, although discs appear normal. Rod inner segments (ris) are distended and displaced. The ris mitochondria are mostly normal in ultrastructural detail. Remnant of dead cell (open arrow) is seen in subretinal space. Pigment granules (pg) are also noticeable (original magnification, $\times 13,500$).

tions were present beyond 48 hours in aphakic-vitrectomized eyes with intact lens capsules; however, vitreous concentrations fell to subtherapeutic levels by 48 hours in aphakic-vitrectomized eyes without an intact lens capsule. Therefore, the timing of repeated intravitreal vancomycin injection, if it is clinically indicated, should depend on the surgical state of the eye. Intraocular vancomycin concentrations have previously been determined by a bioassay.^{7,8} In this study, we used a fluorescent polarization immunoassay to measure aqueous and vitreous antibiotic levels.¹¹ This technique has been found to be more accurate and reproducible for measuring serum antibiotic levels than a biological assay,¹⁸ and we found it to be acceptable for measuring the vancomycin concentration in intraocular fluid.

We routinely treat endophthalmitis with a combination of intravitreal antibiotics to provide coverage for both gram-positive and gram-negative causative bacteria. For this reason, we evaluated the interaction of vancomycin and an aminoglycoside (gentamicin) in the laboratory to ensure that this combination of antibiotics was not antagonistic. A microdilution checkerboard assay using common gram-positive endophthalmitis isolates, including *Staphylococcus*, *Streptococcus*, and *Bacillus* species, was used, and an additive or synergistic interaction was found in all cases.

Until recently, we reserved intravitreal vancomycin administration either for the treatment of endophthalmitis due to cefazolin- and gentamicin-resistant gram-positive organisms or for the treatment of late-onset endophthalmitis associated with filtering blebs because 57% of these cases were found to have been caused by a streptococcal species in a series reported by Mandelbaum and colleagues.² We are now treating all cases of bacterial endophthalmitis at our institution with the combination of vancomycin and an aminoglycoside. We found the intravitreal vancomycin dose of 1 mg recommended by Homer and associates⁷ to be clinically effective in the limited number of cases treated with vancomycin prior to this study, and this is the dosage currently used for the treatment of bacterial endophthalmitis in phakic and aphakic (pseudophakic) eyes with intact lens capsules at our institution. We recommend that a 2-mg intravitreal vancomycin dose be used for treatment of endophthalmitis in aphakic-

Antibiotic Sensitivity Testing			
Organism*	Mean Inhibitory Concentration, mg/L		Interaction†
	Gentamicin	Vancomycin	
<i>Streptococcus</i>			
<i>S faecalis</i> (4)	16	2	Indifferent
<i>S viridans</i> (1)	16	0.5	Indifferent
Group D (1)	16	0.5	Indifferent
<i>Staphylococcus</i>			
<i>S epidermidis</i> (4)	16	1	Indifferent
<i>S aureus</i> (2)	0.5	0.5	Synergistic
<i>Bacillus</i>			
<i>B cereus</i> (2)	1	0.5	Synergistic

*Numbers in parentheses indicate the number of isolates tested.

†Interaction of the combination of vancomycin and gentamicin was determined by a microdilution checkerboard assay.

found 72 hours after intravitreal injection in phakic rabbit eyes. This finding supports those of previous

reports of intraocular vancomycin clearance in phakic eyes.^{7,8} Therapeutic intraocular vancomycin concentra-

vitrectomized eyes without a lens capsule because of the more rapid antibiotic clearance.

The combination of vancomycin and an aminoglycoside is adequate to treat all gram-positive exogenous endophthalmitis isolates. This combination of antibiotics eliminates the need to select a different combination of antibiotics for each cause of exogenous endophthalmitis (postsurgical, filtering-bleb-associated, traumatic). *Bacillus cereus* is one of the most common isolates in traumatic endophthalmitis.^{3,19} Peyman et al²⁰ recommended that clindamycin and gentamicin be used as the initial intravitreal antibiotics in cases of traumatic endophthalmitis to treat infections caused by *B cereus* and other common bacteria. Our sensitivity tests show that *B cereus* is equally sensitive to vancomycin (MIC, < 0.5 mg/L) and clindamycin (MIC, < 0.5 mg/L). Similar sensitivities have also been reported by O'Day and colleagues.²¹ Based on our limited clinical experience and the present laboratory data, we feel that vanco-

mycin may be as appropriate as clindamycin for the treatment of traumatic endophthalmitis.

Vancomycin²² and the aminoglycoside²³ class of antibiotics have different modes of action on bacterial metabolism. However, both vancomycin^{24,26} and the aminoglycosides^{24,25,27} have been reported to cause nephrotoxicity and ototoxicity in the host. The exact biochemical mechanism of toxicity in host tissues is unknown for each of these classes of antibiotics, but the evidence suggests that it is different. Characteristic lamellar lysosomal inclusions have been noted ultrastructurally in tissues exposed to toxic concentrations of aminoglycosides.²⁷ These are felt to be accumulations of complex lipids within lysosomes due to a toxic effect on lysosomal enzymes involved in lipid metabolism.²⁷ To our knowledge, this type of inclusion has not been detected in any tissues exposed to toxic concentrations of vancomycin in this or any other study.^{26,28}

Nephrotoxicity and ototoxicity have

been found to be potentiated by the concurrent use of vancomycin and aminoglycosides^{29,33} in both clinical studies of humans and experiments with rats.²⁸ It is possible that retinal and pigment epithelial toxicity could also be potentiated by this combination of antibiotics. Thus far, we have not noted any clinically evident posterior segment toxicity when these two antibiotics are injected together in individually nontoxic doses. Nevertheless, we feel that the toxicity of this combination of antibiotics should be evaluated in an animal model.

This investigation was supported in part by US Public Health Service research grant 2R01EY06045 and core grant 5P30EY02180 (National Institutes of Health, National Eye Institute, Bethesda, Md); a center grant from the National Retinitis Pigmentosa Foundation Inc, Baltimore; and an unrestricted departmental grant from Research to Prevent Blindness Inc, New York.

We are appreciative of the assistance provided to us by William Feuer, MS, Department of Ophthalmology, University of Miami School of Medicine.

References

1. Driebe WT, Mandelbaum S, Forster RK, et al: Pseudophakic endophthalmitis. *Ophthalmology* 1986;93:442-448.
2. Mandelbaum S, Forster RK, Gelender H, et al: Late onset endophthalmitis associated with filtering blebs. *Ophthalmology* 1985;92:964-972.
3. Affeldt JC, Forster RK, Mandelbaum S, et al: Traumatic endophthalmitis. *Ophthalmology* 1985;92(suppl):81.
4. Forster RK, Abbott RL, Gelender H: Management of endophthalmitis. *Ophthalmology* 1980;87:313-319.
5. Forster RK: Endophthalmitis, in Duane TM (ed): *Clinical Ophthalmology*. New York, Harper & Row Publishers Inc, 1987, vol 4, chap 24.
6. Pryor JG, Apt L, Leopold IH: Intraocular penetration of vancomycin. *Arch Ophthalmol* 1962;67:608-611.
7. Homer P, Peyman GA, Koziol J, et al: Intravitreal injection of vancomycin in experimental staphylococcal endophthalmitis. *Acta Ophthalmol* 1975;53:311-320.
8. Smith MA, Sorenson JA, Lowy FD, et al: Treatment of experimental methicillin-resistant *Staphylococcus epidermidis* endophthalmitis with intravitreal vancomycin. *Ophthalmology* 1986;93:1328-1335.
9. Parel JM: 'Le System': A unified microsurgical center, in GW Blankenship, M Stirpe, M Gonvers, et al (eds): *Basic and Advanced Vitreous Surgery*. Padova, Italy, Liviana Press, 1986, pp 21-27.
10. Abel R, Boyle GL: Dissecting intraocular tissue for intraocular drug studies. *Invest Ophthalmol Vis Sci* 1976;15:216-217.
11. Principles of automated methods for diagnostic microbiology, in Fingold S, Baron EJ (eds): *Bailey and Scott's Diagnostic Microbiology*. St Louis, CV Mosby Co, 1986, pp 141-155.
12. Jones RN, Barry RI, Gavan TL, et al: Susceptibility tests: Microdilution and macrodilution broth procedures, in Lennette EH, Balows A, Hausler WJ, et al (eds): *Manual of Clinical Microbiology*. Washington, DC, American Society for Microbiology, 1985, pp 972-977.
13. Krogstad DJ, Moellering RC: Combinations of antibiotics, mechanisms of interaction against bacteria, in Lorian V (ed): *Antibiotics in Laboratory Medicine*. Baltimore, Williams & Wilkins, 1980, pp 298-341.
14. Zackery IG, Forster RK: Experimental intravitreal gentamicin. *Am J Ophthalmol* 1976;82:604-611.
15. Fischer JP, Civileto SE, Forster RK: Toxicity, efficacy, and clearance of intravitreally injected cephazolin. *Arch Ophthalmol* 1982;100:650-652.
16. Talamo JH, D'Amico DJ, Hamminen LA, et al: The influence of aphakia and vitrectomy on experimental retinal toxicity of aminoglycoside antibiotics. *Am J Ophthalmol* 1985;100:840-847.
17. Gloor BP: The vitreous, in Moses RA (ed): *Adler's Physiology of the Eye: Clinical Application*. St Louis, CV Mosby Co, 1981, pp 255-276.
18. Buchanan AG, Witwicki E, Albritton WL: Serum aminoglycoside monitoring by enzyme immunoassay, biological, and fluorescent immunoassay procedures. *Am J Med Technol* 1983;49:437-441.
19. Brinton GS, Topping TN, Hyndiuk RA, et al: Posttraumatic endophthalmitis. *Arch Ophthalmol* 1984;104:547-550.
20. Peyman GA, Carroll CP, Raichand M: Prevention and management of traumatic endophthalmitis. *Ophthalmology* 1980;87:320-324.
21. O'Day DM, Smith RS, Gregg CR, et al: The problem of *Bacillus* species infection with special emphasis on the virulence of *Bacillus cereus*. *Ophthalmology* 1981;88:833-838.
22. Barna JCJ, Williams DH: The structure and mode of action of glycopeptide antibiotics of the vancomycin group. *Annu Rev Microbiol* 1984;38:339-357.
23. Weisblum B, Davis J: Antibiotic inhibitors of the bacterial ribosome. *Bacteriol Rev* 1968;32:493-528.
24. Appel GP, Neu HC: The nephrotoxicity of antimicrobial agents. *N Engl J Med* 1977;296:722-728.
25. Brummett RE: Drug-induced ototoxicity. *Drugs* 1980;19:412.
26. Fekety R: Vancomycin. *Med Clin North Am* 1982;66:175-181.
27. D'Amico DJ, Caspers-Velu L, Libert J, et al: Comparative toxicity of intravitreal aminoglycoside antibiotics. *Am J Ophthalmol* 1985;100:264-275.
28. Wold JS, Turnipseed SA: Toxicity of vancomycin in laboratory animals. *Rev Infect Dis* 1981;3(suppl):224-229.
29. Faber BF, Moellering RC: Retrospective study of the toxicity of preparations of vancomycin from 1974 to 1981. *Antimicrob Agents Chemother* 1983;23:138-141.
30. Odio C, McCracken GH, Nelson JD: Nephrotoxicity associated with vancomycin-aminoglycoside therapy in four children. *J Pediatr* 1984;105:491-493.
31. Dean RP, Wagner DJ, Tolpin MD: Vancomycin-aminoglycoside nephrotoxicity. *J Pediatr* 1985;106:861-862.
32. Sorrell TC, Collignon PJ: A prospective study of adverse reactions associated with vancomycin therapy. *J Antimicrob Chemother* 1985;16:235-241.
33. Mellor JA, Kingdom J, Cafferkey M, et al: Vancomycin toxicity: A prospective study. *J Antimicrob Chemother* 1985;15:773-780.