

Letter to the Editor

Intravitreal silicone oil droplets following pegaptanib injection

Mehmet Selim Kocabora, Kemal Turgay Ozbilen and Kubra Serefoglu

Retina Unit, Vakif Gureba Education and Research Hospital, Ophthalmology Clinic, Istanbul, Turkey

doi: 10.1111/j.1755-3768.2008.01336.x

Editor,

Intravitreal injection has recently gained in popularity for the treatment of many retinal diseases. Pegaptanib is an agent used in intravitreal injection to treat choroidal neovascularizations by repeated injections administered every 6 weeks. Presumed intraocular migration of silicone oil droplets caused by intravitreal pegaptanib injections was reported previously (Freund et al. 2006).

We report three cases of intravitreal silicone oil droplets following pegaptanib injection for the treatment of subretinal choroidal neovascular membranes. In July 2007, pegaptanib became the first anti-vascular endothelial growth factor (anti-VEGF) agent to be approved for ocular use in Turkey. The medication is distributed in prefilled glass syringes containing 0.3 mg pegaptanib in 0.09 ml solution.

Of 22 eyes injected intravitreally with pegaptanib between October 2007 and April 2008, three were observed to contain presumed intravitreal silicone oil droplets. The droplets were firstly noticed occasionally during routine ophthalmological examination in one patient's eye. Consequently, we undertook a careful examination of all pegaptanib-injected patients and we found intravitreal oily droplets in two eyes of two other patients. None of the three patients with intravitreal oily droplets complained of floaters in their visual fields. The intravitreal droplets were small, spherical, translucent foreign bodies. Under biomicroscopic examination, the droplets resembled silicone




Fig. 1. Slit-lamp biomicroscopy demonstrating three oily droplets in the mid-vitreous cavity.

oil remnants such as those commonly observed in the vitreous cavity of vitrectomized eyes following silicone oil removal. By contrast with the vitrectomized eyes, the droplets in these three patients' eyes were embedded in the vitreous gel and changed position with vitreous after-movements (Fig. 1). These small oily bubbles were more easily detectable on ocular echography (Fig. 2) because of their apparently exaggerated echogenicity and size caused by the typical 'Rayleigh' scattering of ultrasound from the vitreous-oil interface, as reported by Spaide et al. (2005).

We used inductively coupled plasma mass spectrometry (ICP-MS) to test

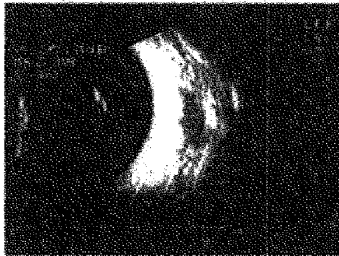


Fig. 2. B-scan ultrasonography of the same eye as in Fig. 1 demonstrates a typical scattering with three hyperechogenic opacities.

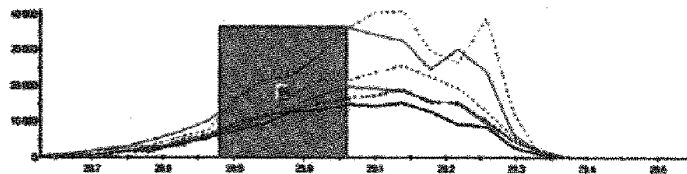


Fig. 3. Silicon (atomic weight 29 g/mol) shown by the continuous red line detected in trace amounts in the pegaptanib solution by inductively coupled plasma mass spectrometry analysis. (Other lines are blank.)

for the presence of silicon (Si) in two used and one unused pegaptanib-filled syringe. Inductively coupled plasma-MS is a highly sensitive method routinely used to determine trace elements. We demonstrated the presence of Si in used and unused syringes and also in the pegaptanib solution itself (Fig. 3). These findings support the hypothesis that oily intravitreal droplets following pegaptanib injection may be silicone oil that originated from syringes used to inject pegaptanib.

Siliconization of the inner syringe wall and outer plunger surface serve to decrease friction for piston movement and minimize protein absorption to prolong drug stability. Because silicone oil has a relatively low cohesiveness, it may migrate into the syringe and contaminate the drug. The release of silicone oil from disposable syringes during insulin expulsion has been reported to result from mechanical abrasion and flushing actions on the siliconized plastic surfaces of the syringe barrel and plunger (Chantelau et al. 1986). Almost all ophthalmic viscosurgical devices (OVDs) injected into the anterior chamber were found to contain small amounts of silicone oil, which is used as a lubricant for the prefilled OVD syringe (Ohrstrom et al. 2004).

Pegaptanib, ranibizumab and bevacizumab are the current anti-VEGF agents used intravitreally, but bevacizumab is not approved for intravitreal delivery and thus its use is off-label. Intravitreal injection of VEGF inhibitors as an invasive procedure carries the risk of blinding complications such as endophthalmitis and retinal detachment; moreover, potential systemic side-effects include arterial hypertension, thromboembolic events and gastrointestinal bleeding (la Cour 2007).

Eingegangen
16. OKT. 2015
Henkel, Breuer & Partner Amulfpark

In our experience with intravitreal bevacizumab injection over 2 years, we have not observed a single case of intravitreal silicone oil droplets. Ranibizumab is not yet approved or commercially available in Turkey and therefore we have no experience with it.

By contrast with pegaptanib, neither ranibizumab nor bevacizumab are stored in prefilled syringes. We think that intravitreal contamination by silicone oil droplets is most likely associated with the use of prefilled syringes.

The functional and clinical consequences of intravitreal silicone oil droplets are unknown, but their occurrence could be avoided by using new-generation prefilled syringes that do not have an internal silicone coating.

Acknowledgements

We thank Professor Ahmet Kasgoz from the Department of Chemical Engineering, University of Istanbul for providing inductively coupled plasma mass spectrometry analysis for this study.

References

- Chantelau E, Berger M & Böhken B (1986): Silicone oil released from disposable insulin syringes. *Diabetes Care* 9: 672-673.
- la Cour M (2007): Intravitreal VEGF-inhibitors: is Avastin a generic substitute for Lucentis? *Acta Ophthalmol Scand* 85: 2-4.
- Freund KB, Laud K, Eandi CM & Spaide RF (2006): Silicone oil droplets following intravitreal injection. *Retina* 26: 701-703.

- Ohrstrom A, Svensson B, Tegenfeldt S, Ceiker C & Lignell B (2004): Silicone oil content in ophthalmic viscosurgical devices. *J Cataract Refract Surg* 30: 1278-1280.
- Spaide RF, Chung JE & Fisher YL (2005): Ultrasound detection of silicone oil after its removal in retinal reattachment surgery. *Retina* 25: 943-945.

Correspondence:

M. Selim Kocabora
Sanatcilar Sitesi
27 E Blok Daire: 12
Tarabya-Sariyer
34457 Istanbul
Turkey
Tel: + 90 212 534 6900
Fax: + 90 212 621 7580
Email: kocabora@gmail.com



14446501248894944514