

Brief Report

NEOVASCULAR GROWTH FOLLOWING PHOTODYNAMIC THERAPY FOR CHOROIDAL HEMANGIOMA AND NEOVASCULAR REGRESSION AFTER INTRAVITREOUS INJECTION OF TRIAMCINOLONE

ANITA M. LEYS, MD,*
RUFINO SILVA, MD, MSc,†
WERNER INHOFFEN, PhD,‡
OLCAY TATAR, MD‡

*From the *Department of Ophthalmology, University Hospitals, Leuven, Belgium; the †Department of Ophthalmology, Hospital of the University of Coimbra and AIBILI/AIBILI—Association for the Institute of Biomedical Research on Light and Image, Coimbra, Portugal; and the ‡Department of Ophthalmology, Eberhard-Karls University, Tübingen, Germany.*

Retinal neovascularization rarely occurs in association with choroidal hemangioma.¹ Shields et al² studied the clinical manifestations of 200 consecutive cases of circumscribed choroidal hemangioma and observed a choroidal neovascular membrane in 3 cases and neovascularization of the iris in 2 cases, but they noted no retinal neovascularization. In 2000, photodynamic therapy (PDT) was introduced for symptomatic choroidal hemangioma,³ and at present, long-term results are available demonstrating that PDT is a most effective and safe treatment option even after repeated treatment.⁴ Moreover, numerous small series of PDT-treated choroidal hemangiomas have been reported without mention of ocular side effects. Recently, we observed subtle retinal neovascularization in three untreated eyes with circumscribed choroidal hemangioma and noted neovascular growth after PDT for the hemangioma. In two cases, the neovascularization re-

gressed after intravitreal injection of triamcinolone (4 mg) but recurred several months later. Repeated injection of triamcinolone resulted again in regression of the neovascularization. In the third case, a single intravitreal injection of triamcinolone (25 mg) induced regression of neovascularization, and no recurrence was observed during a 1-year follow-up.

Case Reports

Case 1

A 30-year-old man had vibrations in the peripheral field of the right eye for several months, and visual loss and distortion were recently noted. Visual acuity was 20/40 in the right eye and 20/20 in the left eye. Funduscopic examination, ultrasound analysis, fluorescein and indocyanine green angiography, and optical coherence tomography showed a voluminous temporomacular mass (7.0 × 7.0 × 4.8 mm) with characteristics of choroidal hemangioma and associated exudative detachment and macular edema. Subtle leakage of fluorescein from the disk and retinal neovascularization was present (Fig. 1, top left) but initially overlooked. After PDT (6 mg/m² body surface area verteporfin and a diode laser at 692 nm with a light dose of 50 J/cm² and light application 5 minutes after intravenous administration of verteporfin), the exudative detachment vanished, and vision improved; however, leakage from neovascularization increased (Fig. 1, top right and bottom left). Three months after the first PDT, interpretation of results was again difficult, and macular fluid was again present. A second and similar treatment was performed at 3 months after the first PDT, and a third course was given at 11 months, taking into account the 4-mm elevation of the hemangioma and decreased vision due to subtle fluid. Most interesting, the disk and retinal neovascularization increased progressively during follow-up, and 1 year after the first PDT, a small vitreous hemorrhage occurred (Fig. 1, bottom right).

Subsequently, a fourth PDT was performed to induce flattening of the hemangioma, and 4 mg of triamcinolone was injected in the vitreous with the aim to reduce macular edema and with the hope to diminish leakage from the neovascularization. Two months later, the neovascularization was clinically undetectable, and no leakage was noted by fluorescein angiography. The regression of new vessels was maintained 2 months later (Fig. 2, top left), but 10 months after the injection, recurrence was noted (Fig. 2, bottom). Visual acuity was 20/30 in the right eye. The hemangioma appeared atrophic and was not associated with exudative lesions; ultrasound analysis showed a 2.8-mm elevation. A second intravitreal injection of triamcinolone (4 mg) induced total regression of the neovascularization (Fig. 2, top right). However, recurrence of neovascularization was noted at 6 months, and at 9 months, a third intravitreal injection of triamcinolone (4 mg) was administered.

Presented in part at the 11th International Congress of Ocular Oncology; Hyderabad, India; January 23–27, 2004; and the Fluorescein Conference of the 27th Annual Meeting of the Macula Society; Las Vegas, NV; February 25–28, 2004.

Reprint requests: Anita M. Leys, Department of Ophthalmology, Kapucijnenvoer 33, B-3000 Leuven, Belgium.

RETINA[®], *The Journal of Retinal and Vitreous Diseases*, encourages authors to submit **Brief Reports** describing unusual findings, new techniques, and new instruments. Material submitted for consideration in this section of the journal is done so with the assumption that the data provided do not duplicate previously published material and that the material has not been submitted for consideration elsewhere. Each author must sign a disclosure to this effect (see Instructions to Authors for complete wording of transfer letter). Brief Reports submitted for this section of the journal may be subjected to the standard review process that is applied to other material submitted to **RETINA**[®]. Brief Reports should follow the requirements listed in the Instructions to Authors, with the following caveats: Brief Reports should not exceed 4 pages in length; no more than 5 references should be cited; and each Brief Report should include no more than 4 figures.

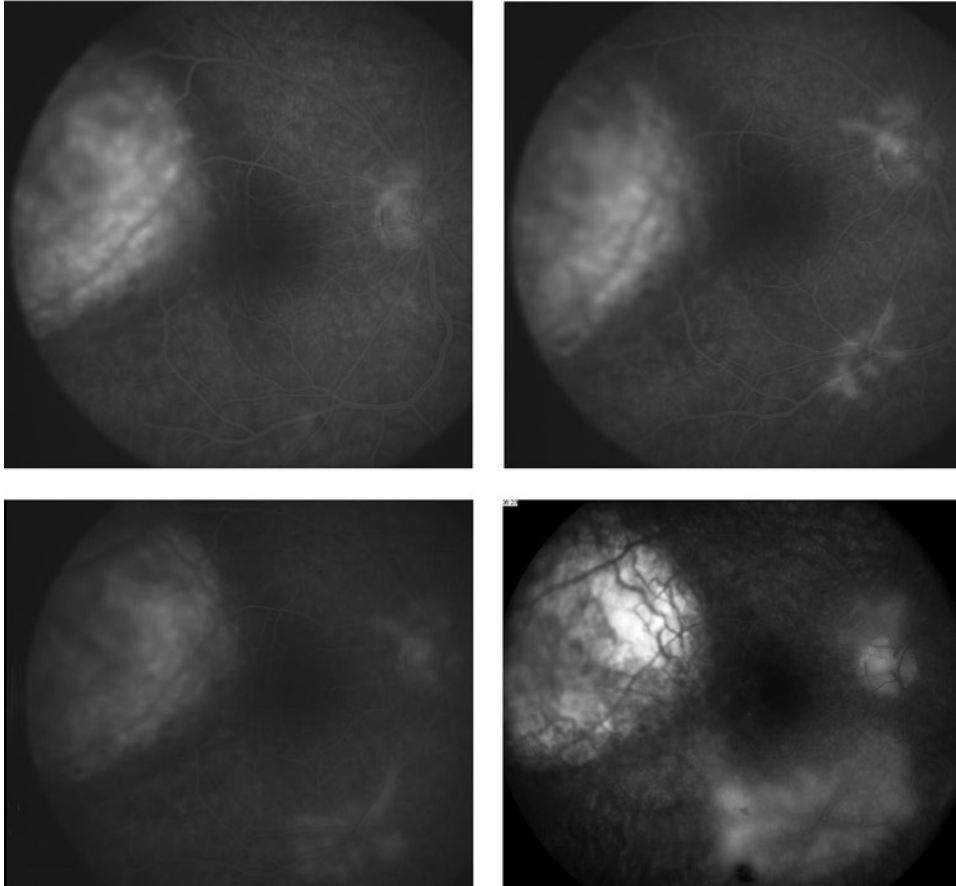


Fig. 1. Case 1. Fluorescein angiogram before the first photodynamic therapy (PDT) showing marked leakage from the temporomacular hemangioma and subtle leakage from neovascularization of the disk and along the inferior temporal vein (**top left**). Note growth of neovascularization and the increased leakage at 1 month (**top right**) and at 3 months after the first PDT (**bottom left**) and further progression and hemorrhage after repeated PDT (**bottom right**).

Another 10 months later (32 months after the first PDT), we observed mild neovascularization and no macular edema. Visual acuity was 20/70 with lens opacities and no other complications.

Case 2

A 20-year-old man had decreased vision in his left eye for 2 months. Visual acuity was 20/20 in the right eye and 20/32 in the left eye. Funduscopy examination of the left eye revealed a pink choroidal mass ($6.0 \times 6.0 \times 3.0$ mm) in the temporal region with overlying subretinal fluid affecting the foveal region. Fluorescein and indocyanine green angiography and ultrasound analysis confirmed the clinical diagnosis of exudative circumscribed choroidal hemangioma. Moreover, subtle disk neovascularization was present. Subsequently, PDT was applied in two courses at 3-month intervals using 6 mg/m^2 body surface area verteporfin and a diode laser at 692 nm with a light dose of 50 J/cm^2 and light application 15 minutes after the start of the infusion. Three months after the second PDT, neovascular growth was noted with neovascular tufts on and at the borders of the optic nerve head and nasal to the disk. Another 3 months later, extension of the neovascularization and a subhyaloidal hemorrhage were noted. Preexisting cystoid macular edema was more pronounced. The hemangioma had flattened, and most of the exudative detachment was resolved. Another 3 months later, a new focus of neovascularization was noted in the inferotemporal macular region, and a new subhyaloidal hemorrhage was noted. Visual acuity was still 20/32 in the left eye. On the basis of the experience in Case 1 with a possible benefit of triamcinolone

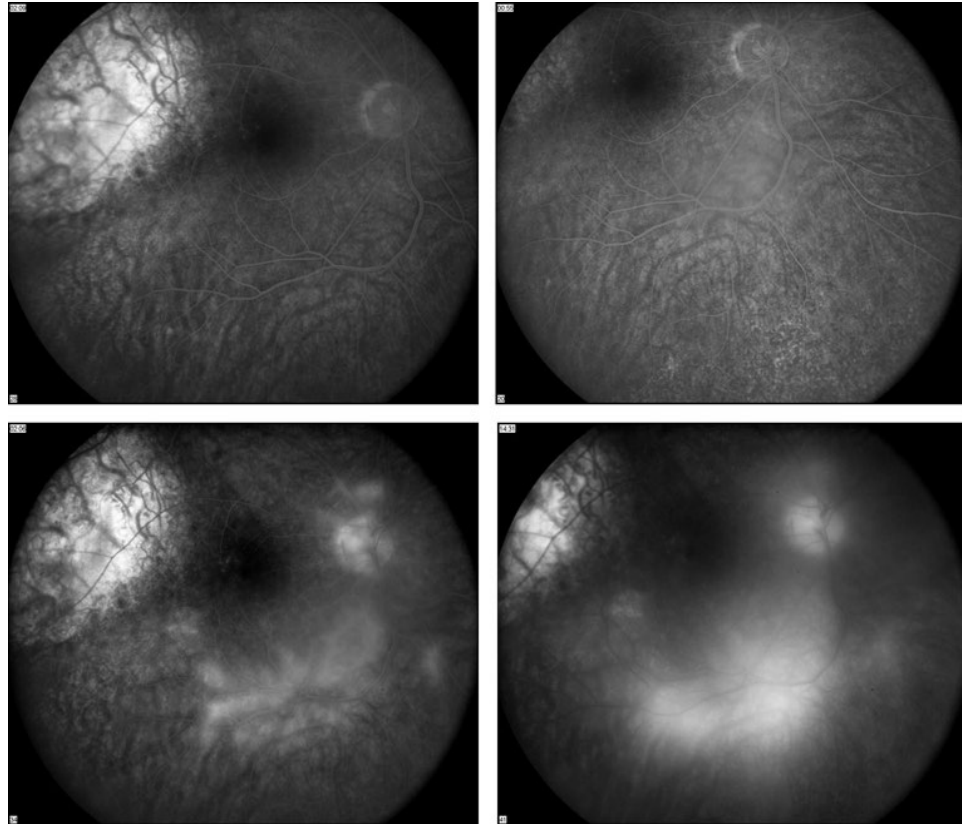
treatment, an intravitreal injection of 4 mg of triamcinolone was applied. Two months later, most of the neovascularization and leakage had disappeared, and visual acuity was 20/25.

However, 6 months after the injection, recurrence of the neovascularization was noted with a similar appearance as before the injection (Fig. 3). Visual acuity was still 20/25, the hemangioma remained flattened without exudative detachment, and ocular tension remained normal. A second injection of 4 mg of triamcinolone was applied to the left eye. Five weeks later, complete regression of the neovascularization was noted. However, recurrence was observed, and a third injection was administered at 9 months after the second injection. Five months later (37 months after the first PDT), visual acuity was 20/32 with mild lens opacities, chronic macular edema, and no new vessels. The hemangioma remained flattened without exudative detachment, and ocular tension remained normal.

Case 3

A 14-year-old boy had blurred vision in his left eye for two weeks. Visual acuity was 20/20 in the right eye and 20/40 in the left eye. Funduscopy examination revealed a temporomacular subretinal mass with associated exudative detachment. The clinical diagnosis of circumscribed choroidal hemangioma was confirmed with ultrasound analysis and fluorescein and indocyanine green angiography. Optical coherence tomography revealed a submacular neurosensory detachment. In addition, fluorescein angiography showed neovascularization with leakage on the left disk (Fig. 4, top

Fig. 2. Case 1. Regression of neovascularization and no leakage at 4 months after the first injection of triamcinolone (**top left**) and at 2 months after the second injection (**top right**). Recurrence of neovascularization and diffuse leakage were noted at 10 months after the first injection of triamcinolone and are shown on a 2-minute frame (**bottom left**) and a 15-minute frame (**bottom right**) of the fluorescein angiogram.



left). Six months after the initial diagnosis, the choroidal hemangioma ($4.8 \times 13 \times 11$ mm) with persisting submacular neurosensory detachment was treated with PDT (using 6 mg/m^2 body surface area verteporfin and a diode laser at 692 nm with a light dose of 100 J/cm^2 and light application for 166 seconds at 5 minutes after intravenous administration of verteporfin, using 2 spots). The associated exudative detachment and submacular neurosensory detachment regressed gradually and disappeared totally. Tumor thickness decreased (1.8 mm) progressively so that visual acuity of 20/20 and improvement in visual field was achieved at 8.5 months after PDT. However, neovascularization on the disk was more prominent (Fig. 4, top right) after PDT with increased leakage by fluorescein angiography (Fig. 4, bottom left). In the follow-up, the anatomical and functional improvement

was stable so that retreatment with PDT was not considered. However, 25 mg of triamcinolone was injected intravitreally to suppress leakage from the increased active neovascularization on the disk. Five weeks after triamcinolone injection, neovascularization was funduscopically undetectable. The patient had had a temporary intraocular pressure increase, which could be treated medically. Complete regression of neovascularization (Fig. 4, bottom right) with stable vision of 20/20 without macular edema was seen at the 1-year follow-up examination.

Discussion

Retinal and disk neovascularization may occur in eyes with a retinal or choroidal tumor without obvious

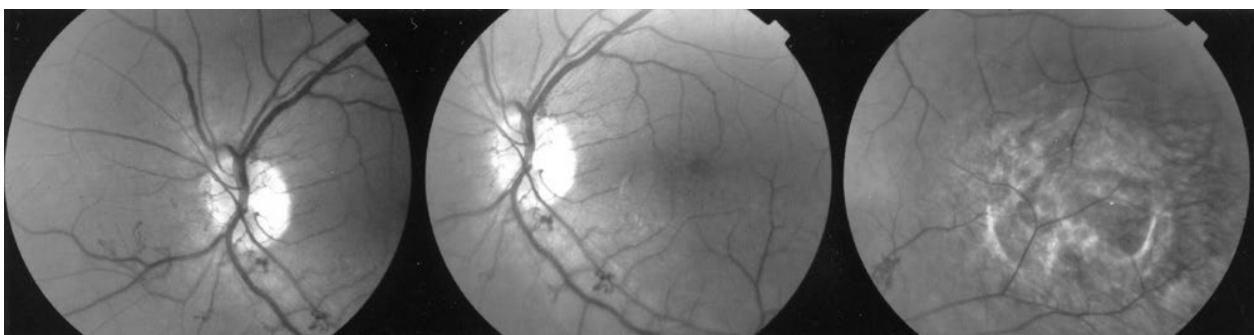


Fig. 3. Case 2. Red-free pictures showing neovascularization nasal on the disk (**left**), on and at the borders of the disk and inferior to the edematous macula (**center**), and in the inferotemporal region at the border of the hemangioma (**right**).

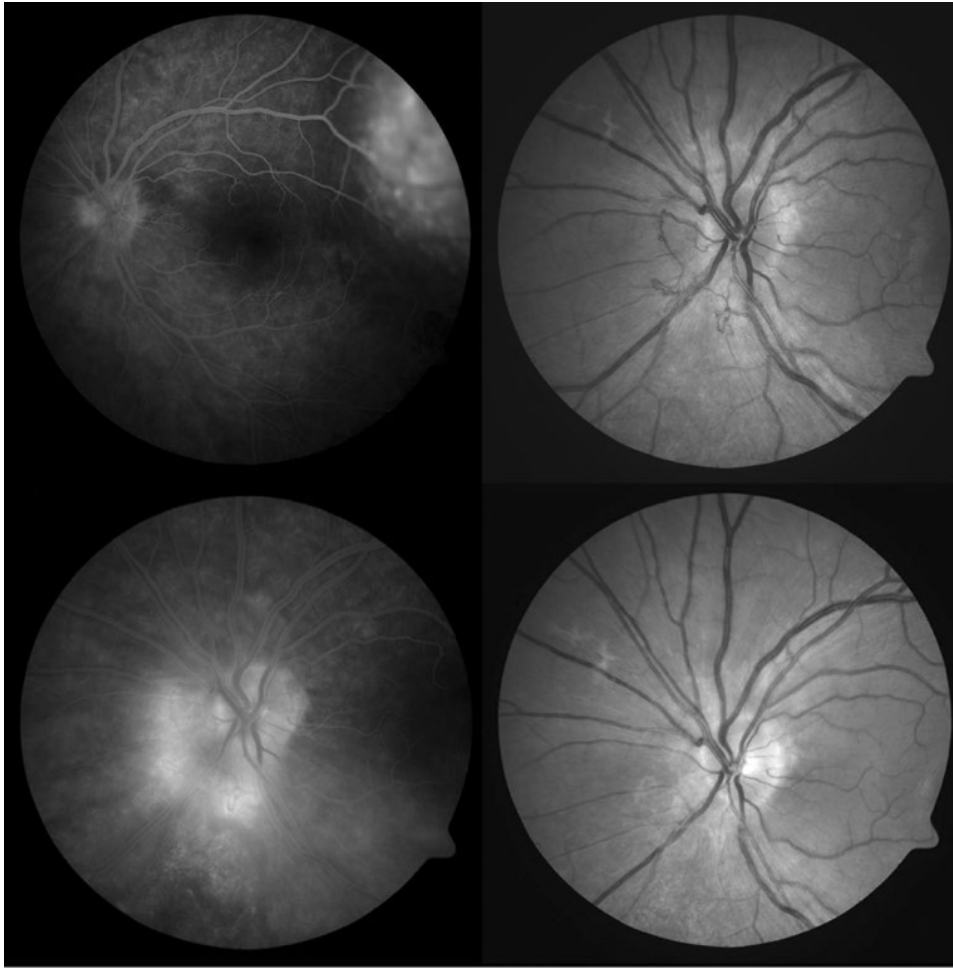


Fig. 4. Case 3. Early-phase fluorescein angiogram on the day of photodynamic therapy (PDT) shows hyperfluorescence of hemangioma as well as of neovascularization nasal to the optic disk (**top left**). After PDT, note increased neovascularization on the optic disk (red-free picture; **top right**) with corresponding intense leakage in the late phases of fluorescein angiography (**bottom left**). Regression of neovascularization (**bottom right**) was maintained 12 months after the single injection of triamcinolone (25 mg intravitreally).

triggering factors such as retinal artery or vein occlusion, capillary dropout, or inflammation. The association of retinal neovascularization with retinal angioma is well known and is easily understood in the context of von Hippel disease and the inherent stimulus for ocular angiogenesis. The association of choroidal melanoma with disk and retinal neovascularization has been reported by several investigators.⁵ Some of these eyes had no radiation therapy and showed no capillary dropout or inflammatory response. Possible triggers for neovascular growth in these eyes include subtle inflammation, chronic retinal detachment with secondary subtle chronic retinal ischemia, and release of tumor angiogenic factors. Similar triggers apply for disk and retinal neovascularization in eyes with a circumscribed choroidal hemangioma.¹

Optimal management of tumor-associated neovascularization is at present unknown. On the basis of our own experience and that of others, the spontaneous evolution is unfavorable mainly as a result of the nature and localization of the tumor and the associated

chronic serous detachment. In melanoma-associated neovascularization, regression of the neovascularization has been noted after scatter photocoagulation and/or plaque radiation therapy, but radiation-induced neovascular growth may occur in other cases. Destruction of a choroidal hemangioma by heavy xenon arc coagulation, which was a standard treatment some 40 years ago, may also induce regression of tumor-associated neovascularization (personal communication, Achim Wessing). To our knowledge, no retinal neovascularization has been induced by low dose irradiation of a circumscribed choroidal hemangioma, and this treatment option is still of benefit for large hemangiomas with retinal detachment. Laser photocoagulation and transpupillary thermotherapy have been used in the treatment of symptomatic choroidal hemangioma with relatively good functional results. However, in these treatments, large retinal vessels overlying the hemangioma are at risk to become occluded, which may result in visual loss and in neovascular growth. Recently, new treatment options have

become available for these complex cases, including PDT and antiangiogenic drugs, and experience is growing.

PDT is at present widely accepted as a safe and highly effective first-line treatment for symptomatic circumscribed choroidal hemangioma. Recently, a retrospective randomized study has been initiated by the Ophthalmic Oncology Task Force of the European Organization for Research and Treatment of Cancer, which is attempting to define the optimal guidelines comparing high with low dose PDT (bolus application of verteporfin and 100 J/cm² versus intravenous infusion and 50 J/cm²). As a rule, small choroidal hemangiomas require only a single application of a single laser spot. Larger hemangiomas may require use of a wide-field lens or application of two or more laser spots and repeated PDT, and in these cases, caution is warranted to avoid atrophic scars in the macular area. Increased retinal edema shortly after the laser application is another possible side effect of PDT for choroidal hemangioma. Edema causes visual loss and probably also enhances other stimuli for neovascular growth. Possible angiogenic stimuli are laser-induced necrosis of the tumor and release of vascular endothelial growth factor after application of PDT, as has been reported in other conditions.³

Intravitreal injection of triamcinolone has been used successfully in a range of ocular conditions associated with macular edema, and it seems to enhance the therapeutic effect of PDT for age-related neovascularization. In our cases of neovascularization associated with choroidal hemangioma, neovascular growth with increased leakage was demonstrated after PDT, and triamcinolone induced regression of neovascularization with absence of leakage. Recurrence of neovascularization with leakage was found in two of the patients and proved to be reversible with reinjection of triamcinolone.

In conclusion, we observed three patients who had choroidal hemangioma with retinal neovascularization that was present before PDT but increased after PDT. Triamcinolone injections induced regression of neovascularization and leakage in all three patients. Two patients had a recurrence of neovascularization after several months that proved to be reversible with reinjection of triamcinolone. These observations add evidence to the concept that triamcinolone may offer some protection when the angiogenic stimulus is high. The exact mechanism of action remains unknown.

Key words: choroidal hemangioma, neovascularization, photodynamic therapy, triamcinolone, vascular endothelial growth factor.

References

1. Leys AM, Bonnet S. Case report: associated retinal neovascularization and choroidal hemangioma. *Retina* 1993;132:22–25.
2. Shields CL, Honavar SG, Shields JA, et al. Circumscribed choroidal hemangioma. Clinical manifestations and factors predictive of visual outcome in 200 consecutive cases. *Ophthalmology* 2001;108:2237–2248.
3. Barbazetto I, Schmidt-Erfurth U. Photodynamic therapy of choroidal hemangioma: two case reports. *Graefes Arch Clin Exp Ophthalmol* 2000;238:214–221.
4. Michels S, Michels R, Simader C, Schmidt-Erfurth U. Verteporfin therapy for choroidal hemangioma: long-term follow-up. *Retina* 2005;25:697–703.
5. Keunen JE, Hooymans JM, Ulbig MW, Shields CL. Retinal neovascularization in choroidal melanoma without retinal ischemia. *Retina* 2002;22:371–374.

EASY AND EFFECTIVE WAY TO REMOVE RESIDUAL SILICONE OIL DROPLETS IN PHAKIC PATIENTS

DAVID G. TELANDER, MD, PhD,
CHRISTINE R. GONZALES, MD

From the Department of Ophthalmology, University of California at Los Angeles, Jules Stein Eye Institute, David Geffen School of Medicine, Los Angeles, California.

In 1962, Cibis first introduced the use of silicone oil for the repair of retinal detachments complicated by proliferative vitreoretinopathy. Silicone oil continues to be used in vitreoretinal surgery for complicated retinal detachment, proliferative diabetic retinopathy with tractional retinal detachment, and macular holes.¹

Silicone oil is usually removed at some point after retinal detachment surgery to allow adequate refraction and to avoid complications of silicone oil. Accurate refraction of a silicone-filled eye is difficult because the higher refractive index of silicone oil relative to vitreous or aqueous induces a hyperopic shift. In addition, silicone oil may cause distortion and limit the best-corrected visual acuity. Silicone oil complications, including elevated intraocular pressure, bullous keratopathy, silicone oil emulsification, subretinal deposition of oil, cataract, and lens capsule opacification, are not uncommon and can be vision threatening.¹ Silicone oil is generally removed when the tamponade is no longer necessary or when complications secondary to silicone oil are present.

The surgical removal of silicone oil has its own set

Reprint requests: Christine Gonzales, MD, University of California at Los Angeles, Jules Stein Eye Institute, 100 Stein Plaza, Los Angeles, CA 90095; e-mail: gonzales@jsei.ucla.edu

Explore Litigation Insights

Docket Alarm provides insights to develop a more informed litigation strategy and the peace of mind of knowing you're on top of things.

Real-Time Litigation Alerts



Keep your litigation team up-to-date with **real-time alerts** and advanced team management tools built for the enterprise, all while greatly reducing PACER spend.

Our comprehensive service means we can handle Federal, State, and Administrative courts across the country.

Advanced Docket Research



With over 230 million records, Docket Alarm's cloud-native docket research platform finds what other services can't. Coverage includes Federal, State, plus PTAB, TTAB, ITC and NLRB decisions, all in one place.

Identify arguments that have been successful in the past with full text, pinpoint searching. Link to case law cited within any court document via Fastcase.

Analytics At Your Fingertips



Learn what happened the last time a particular judge, opposing counsel or company faced cases similar to yours.

Advanced out-of-the-box PTAB and TTAB analytics are always at your fingertips.

API

Docket Alarm offers a powerful API (application programming interface) to developers that want to integrate case filings into their apps.

LAW FIRMS

Build custom dashboards for your attorneys and clients with live data direct from the court.

Automate many repetitive legal tasks like conflict checks, document management, and marketing.

FINANCIAL INSTITUTIONS

Litigation and bankruptcy checks for companies and debtors.

E-DISCOVERY AND LEGAL VENDORS

Sync your system to PACER to automate legal marketing.