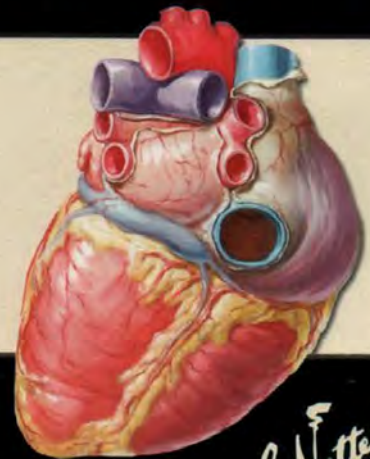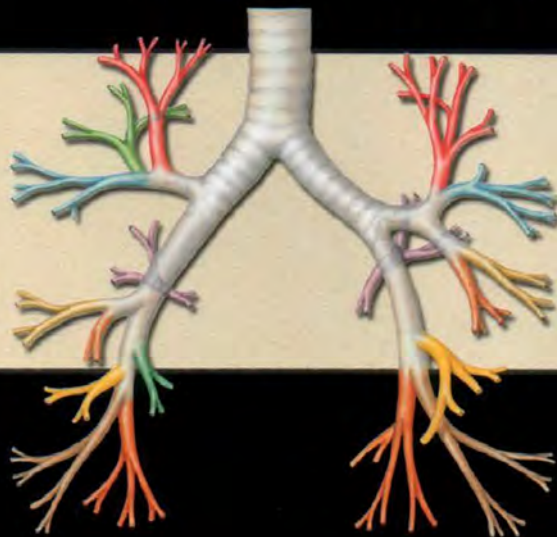

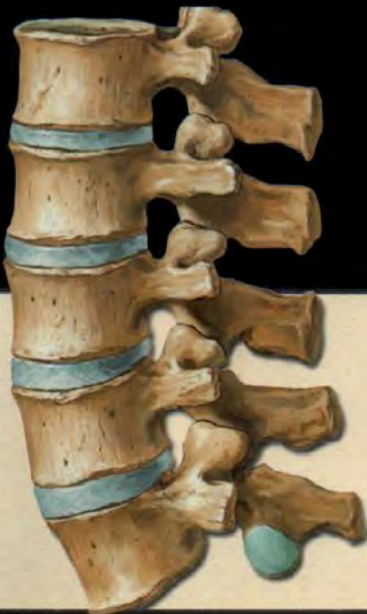
Atlas of Human Anatomy

Third Edition

Frank H. Netter, M.D.



*F. Netter
M.D.*

Atlas of Human Anatomy

*F. Netter
M.D.*

Atlas

Human

of

Anatomy

Third Edition

by Frank H. Netter, M.D.

John T. Hansen, Ph.D., *Consulting Editor*
University of Rochester School of Medicine and Dentistry
Rochester, New York

Icon Learning Systems • Teterboro, New Jersey



Copyright © 2003, 1997, 1989, ICON Learning Systems, LLC, a subsidiary of MediMedia USA, Inc.

First Edition, 1989

Second Edition, 1997

Third Edition, 2003

All rights reserved. No part of this book may be reproduced in any form or by any electronic or mechanical means, including information storage and retrieval systems, without permission in writing from the publisher. Requests for permission should be addressed to Permissions Editor, Icon Learning Systems, 295 North Street, Teterboro NJ 07608; or may be made at www.netterart.com/request_start.asp

NOTICE

Every effort has been taken to confirm the accuracy of the information presented. Neither the publisher nor the authors can be held responsible for errors or for any consequences arising from the use of the information contained herein, and make no warranty, expressed or implied, with respect to the contents of the publication.

Executive Editor: Paul Kelly

Editorial Director: Greg Otis

Managing Editor: Jennifer Surich

Art Director: Erika Gehringer

Print Production Manager: Mary Ellen Curry

10 9 8 7 6 5 4 3 2

ISBN 1-929007-11-6 (paperback)

ISBN 1-929007-15-9 (paperback/CD Combo)

ISBN 1-929007-21-3 (case bound/CD Combo)

Library of Congress Control No: 2002110663

Printed and bound in USA by RR Donnelley

100M-0703-RRD

To my dear wife, Vera

PREFACE TO THE FIRST EDITION

I have often said that my career as a medical artist for almost 50 years has been a sort of “command performance” in the sense that it has grown in response to the desires and requests of the medical profession. Over these many years, I have produced almost 4,000 illustrations, mostly for *The CIBA (now Netter) Collection of Medical Illustrations* but also for *Clinical Symposia*. These pictures have been concerned with the varied subdivisions of medical knowledge such as gross anatomy, histology, embryology, physiology, pathology, diagnostic modalities, surgical and therapeutic techniques and clinical manifestations of a multitude of diseases. As the years went by, however, there were more and more requests from physicians and students for me to produce an atlas purely of gross anatomy. Thus, this atlas has come about, not through any inspiration on my part but rather, like most of my previous works, as a fulfillment of the desires of the medical profession.

It involved going back over all the illustrations I had made over so many years, selecting those pertinent to gross anatomy, classifying them and organizing them by system and region, adapting them to page size and space and arranging them in logical sequence. Anatomy of course does not change, but our understanding of anatomy and its clinical significance does change, as do anatomical terminology and nomenclature. This therefore required much updating of many of the older pictures and even revision of a number of them in order to make them more pertinent to today’s ever-expanding scope of medical and surgical practice. In addition, I found that there were gaps in the portrayal of medical knowledge as pictorialized in the illustrations I had previously done, and this necessitated my making a number of new pictures that are included in this volume.

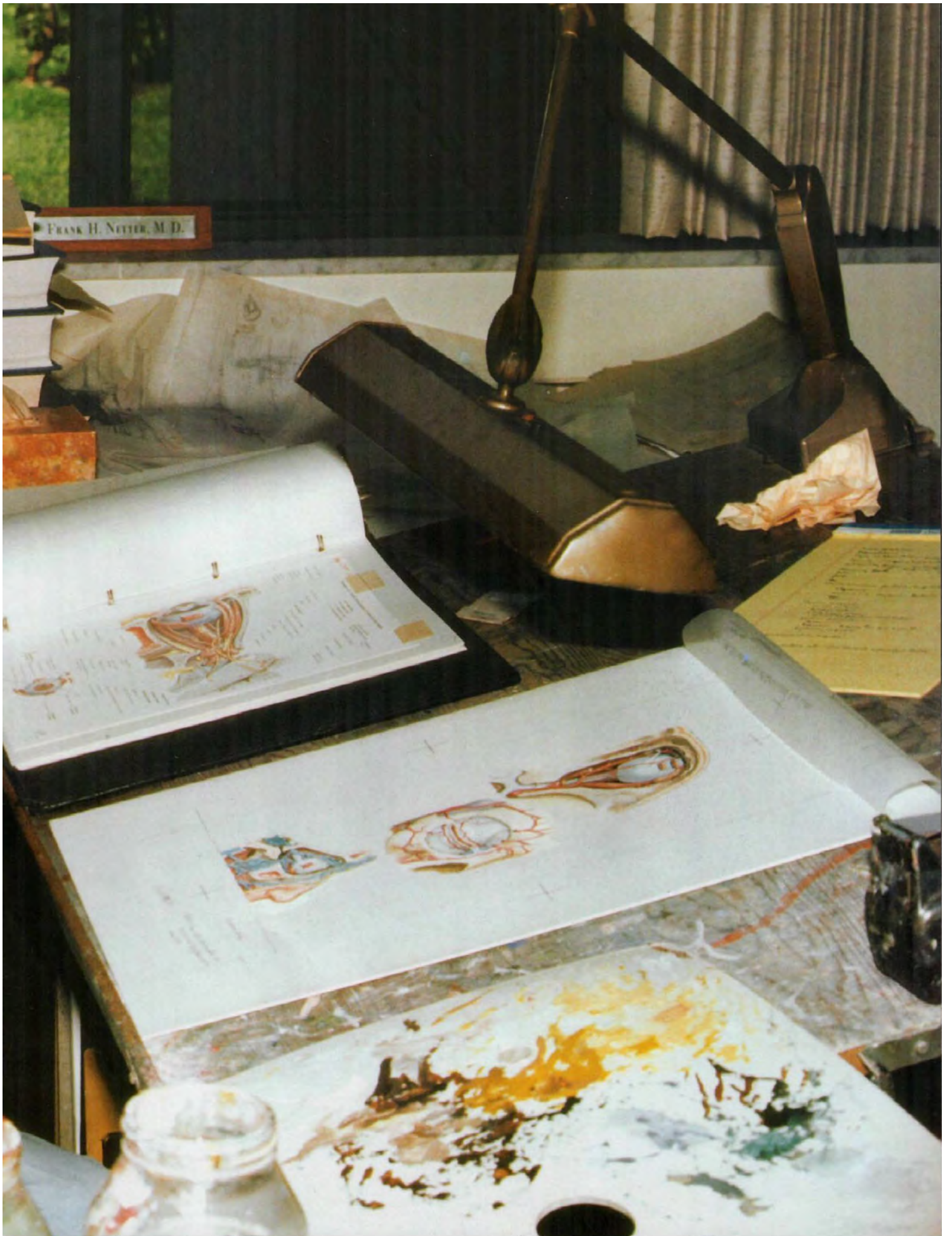
In creating an atlas such as this, it is important to achieve a happy medium between complexity and simplification. If the pictures are too complex, they may be difficult and confusing to read; if oversimplified, they may not be adequately definitive or may even be misleading. I have therefore striven for a middle course of realism without the clutter of confusing minutiae. I hope that the students and members of the medical and allied professions will find the illustrations readily understandable, yet instructive and useful.

At one point, the publisher and I thought it might be nice to include a foreword by a truly outstanding and renowned anatomist, but there are so many in that category that we could not make a choice. We did think of men like Vesalius, Leonardo da Vinci, William Hunter and Henry Gray, who of course are unfortunately unavailable, but I do wonder what their comments might have been about this atlas.

Frank H. Netter, M.D.
(1906–1991)



PHOTOGRAPH BY JAMES L. CLAYTON



FOREWORD

“The release in 1989 of the first edition of Dr. Frank Netter’s ‘personal Sistine Chapel’—the Atlas of Human Anatomy—was a major event in the history of the teaching and learning of anatomy. Almost instantly, the Atlas of Human Anatomy became the top-selling anatomical atlas in the world and clearly became the students’ choice universally.”

This quotation from the second edition of the *Atlas of Human Anatomy* still resonates today as the beautifully conceived and rendered artwork of Dr. Netter continues to capture the admiration of students and healthcare professionals.

The skillful editing and publishing teamwork of Novartis Medical Education, in consultation with many of the 20th century’s outstanding anatomists and physicians, have made the first and second editions of the *Atlas* the standard against which all other atlases are compared. This third edition owes much to the Consulting Editors of the earlier editions, Drs. Sharon Colacino (Oberg) (first edition) and Arthur F. Dalley II (second edition), who shepherded their editions with great skill and uncompromising professionalism and thus made my task significantly easier. I am honored to serve as the Consulting Editor of the third edition and to continue the Netter tradition in partnership with Icon Learning Systems as the *Atlas of Human Anatomy* enters the new century.

Perceptive student and faculty response to the earlier editions prompted greater attention to several concepts that are critical to the anatomical basis of clinical practice. Notably, each regional section now begins with a surface anatomy plate, skillfully drawn by Carlos A.G. Machado, M.D. These surface anatomy plates remind us of the value of careful observation in clinical medicine and draw attention to surface features that portend the underlying anatomy.

We also have included a significant number of normal radiographic images in this edition, reflecting the importance of diagnostic imaging in clinical anatomy and medicine. These new images are not meant to be comprehensive of the radiographic knowledge available to today’s clinicians, but rather are starting points for further exploration into the richness of anatomical detail that imaging can provide. I am grateful to Matthew Cham, M.D., and John Wandtke, M.D., of our Department of Radiology for selecting these images and permitting us to use them in this edition.

We balanced the addition of new surface and radiographic anatomy plates largely by eliminating several plates that contributed little to the quality of the *Atlas*. Several plates from *The Netter* (formerly *CIBA*) *Collection of Medical Illustrations* were added and several plates were altered slightly to correct anatomical errors consistent with our current knowledge. In sum, the third edition has grown by 30 images. Finally, the References and the Index have been updated.

The anatomical terminology is consistent throughout the *Atlas* and conforms to the International Anatomical Terminology (*Terminologia Anatomica*) approved in 1998 by the International Federation of Associations of Anatomists. Common eponyms are retained parenthetically, and the leader lines and labels have been checked and, where necessary, corrected to ensure their accuracy. For reviewing this material I thank Wojciech Pawlina, M.D., Leonard J. Cleary, Ph.D., Daniel O. Graney, Ph.D., and Brian R. MacPherson, Ph.D. Their meticulous examination of each plate has greatly enhanced the accuracy of this atlas.

For the proofreading, editing and designing, I am indebted to Jennifer Surich, Erika Gehringer and Greg Otis at Icon Learning Systems; their keen eyesight, dedication and professionalism buoyed me when I began to drift. A special thank you is reserved for Paul Kelly, Executive Editor, who continues to listen patiently and is a true believer in the power of the visual image to teach.

To all students, past, present and future, the legacy of Dr. Netter's artwork lives in you; his unique ability to "clarify rather than intimidate" is his gift to you. I am both privileged and humbled to have the opportunity to carry forward this tradition of excellence and to contribute to your understanding of human anatomy.

Finally, to my wife, Paula, thank you for giving me the freedom to write and the support to sustain me—in those respects, this book was co-edited.

John T. Hansen, Ph.D.
Professor of Neurobiology and Anatomy
University of Rochester School of Medicine and Dentistry
Rochester, New York

CONTENTS

Section I HEAD AND NECK

SURFACE ANATOMY	Plate 1
BONES AND LIGAMENTS	Plates 2–18
SUPERFICIAL FACE	Plates 19–22
NECK	Plates 23–31
NASAL REGION	Plates 32–46
ORAL REGION	Plates 47–58
PHARYNX	Plates 59–69
THYROID GLAND AND LARYNX	Plates 70–76
ORBIT AND CONTENTS	Plates 77–86
EAR	Plates 87–93
MENINGES AND BRAIN	Plates 94–109
CRANIAL AND CERVICAL NERVES	Plates 110–129
CEREBRAL VASCULATURE	Plates 130–141
REGIONAL SCANS	Plates 142–144

Section II BACK AND SPINAL CORD

SURFACE ANATOMY	Plate 145
BONES AND LIGAMENTS	Plates 146–152
SPINAL CORD	Plates 153–166
MUSCLES AND NERVES	Plates 167–173

Section III THORAX

SURFACE ANATOMY	Plate 174
MAMMARY GLAND	Plates 175–177
BODY WALL	Plates 178–191
LUNGS	Plates 192–206
HEART	Plates 207–225
MEDIASTINUM	Plates 226–237
REGIONAL SCANS	Plate 238

Section IV ABDOMEN

SURFACE ANATOMY	Plate 239
BODY WALL	Plates 240–259
PERITONEAL CAVITY	Plates 260–266
VISCERA (GUT)	Plates 267–277
VISCERA (ACCESSORY ORGANS)	Plates 278–289
VISCERAL VASCULATURE	Plates 290–307
INNERVATION	Plates 308–318
KIDNEYS AND SUPRARENAL GLANDS	Plates 319–334
ABDOMINAL SECTIONS	Plates 335–337
REGIONAL SCANS	Plate 338

Section V **PELVIS AND PERINEUM**

SURFACE ANATOMY	Plate 339
BONES AND LIGAMENTS	Plates 340–342
PELVIC FLOOR AND CONTENTS	Plates 343–353
FEMALE STRUCTURES	Plates 354–362
MALE STRUCTURES	Plates 363–371
RECTUM	Plates 372–377
VASCULATURE	Plates 378–388
INNERVATION	Plates 389–397
HOMOLOGUES OF GENITALIA	Plates 398–399
REGIONAL SCANS	Plate 400

Section VI **UPPER LIMB**

SURFACE ANATOMY	Plate 401
SHOULDER AND AXILLA	Plates 402–413
ARM	Plates 414–418
ELBOW AND FOREARM	Plates 419–434
WRIST AND HAND	Plates 435–454
NEUROVASCULATURE	Plates 455–466

Section VII **LOWER LIMB**

SURFACE ANATOMY	Plate 467
HIP AND THIGH	Plates 468–487
KNEE	Plates 488–494
LEG	Plates 495–504
ANKLE AND FOOT	Plates 505–519
NEUROVASCULATURE	Plates 520–528

Section VIII **CROSS-SECTIONAL ANATOMY**

CROSS-SECTION OVERVIEW	Plate 529
THORAX	Plates 530–533
ABDOMEN	Plates 534–539
MALE PELVIS	Plate 540
THORAX	Plates 541–542

REFERENCES
INDEX

Section VI

UPPER

LIMB

SURFACE ANATOMY

Plate 401

401. Upper Limb

SHOULDER AND AXILLA

Plates 402–413

402. Clavicle and Sternoclavicular Joint

403. Humerus and Scapula: Anterior Views

404. Humerus and Scapula:
Posterior Views

405. Shoulder: Anteroposterior Radiograph

406. Shoulder (Glenohumeral) Joint

407. Muscles of Shoulder

408. Muscles of Rotator Cuff

409. Scapulohumeral Dissection

410. Axillary Artery and
Anastomoses Around Scapula

411. Pectoral, Clavipectoral
and Axillary Fasciae

412. Axilla (Dissection): Anterior View

413. Brachial Plexus: Schema

ARM

Plates 414–418

414. Muscles of Arm: Anterior Views

415. Muscles of Arm: Posterior Views

416. Brachial Artery In Situ

417. Brachial Artery and Anastomoses
Around Elbow

418. Arm: Serial Cross Sections

ELBOW AND FOREARM

Plates 419–434

419. Bones of Elbow

420. Elbow: Radiographs

421. Ligaments of Elbow

422. Bones of Forearm

423. Individual Muscles of Forearm:
Rotators of Radius

424. Individual Muscles of Forearm:
Extensors of Wrist and Digits

425. Individual Muscles of Forearm:
Flexors of Wrist

- 426. Individual Muscles of Forearm:
Flexors of Digits
- 427. Muscles of Forearm (Superficial Layer): Posterior View
- 428. Muscles of Forearm (Deep Layer): Posterior View
- 429. Muscles of Forearm (Superficial Layer): Anterior View
- 430. Muscles of Forearm (Intermediate Layer): Anterior View
- 431. Muscles of Forearm (Deep Layer): Anterior View
- 432. Forearm: Serial Cross Sections
- 433. Attachments of Muscles of Forearm: Anterior View
- 434. Attachments of Muscles of Forearm: Posterior View

WRIST AND HAND

Plates 435–454

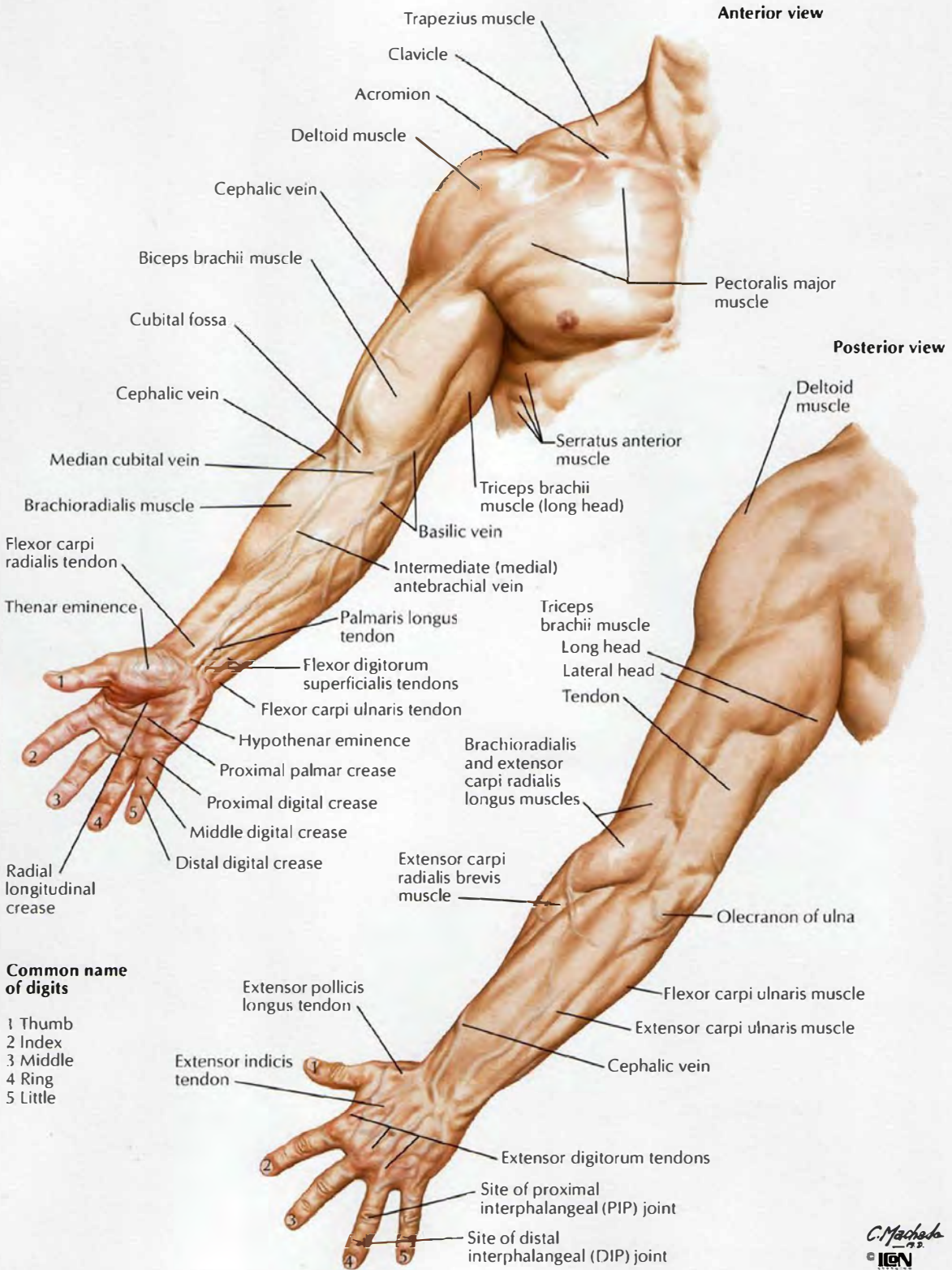
- 435. Carpal Bones
- 436. Movements of Wrist
- 437. Ligaments of Wrist
- 438. Ligaments of Wrist (*continued*)
- 439. Bones of Wrist and Hand
- 440. Wrist and Hand:
Anteroposterior Radiograph
- 441. Metacarpophalangeal and Interphalangeal Ligaments
- 442. Wrist and Hand: Superficial Palmar Dissections
- 443. Wrist and Hand: Deeper Palmar Dissections
- 444. Flexor Tendons, Arteries and Nerves at Wrist
- 445. Bursae, Spaces and Tendon Sheaths of Hand

- 446. Lumbrical Muscles and Bursae, Spaces and Sheaths: Schema
- 447. Flexor and Extensor Tendons in Fingers
- 448. Intrinsic Muscles of Hand
- 449. Arteries and Nerves of Hand: Palmar Views
- 450. Wrist and Hand: Superficial Radial Dissection
- 451. Wrist and Hand: Superficial Dorsal Dissection
- 452. Wrist and Hand: Deep Dorsal Dissection
- 453. Extensor Tendons at Wrist
- 454. Fingers

NEUROVASCULATURE

Plates 455–466

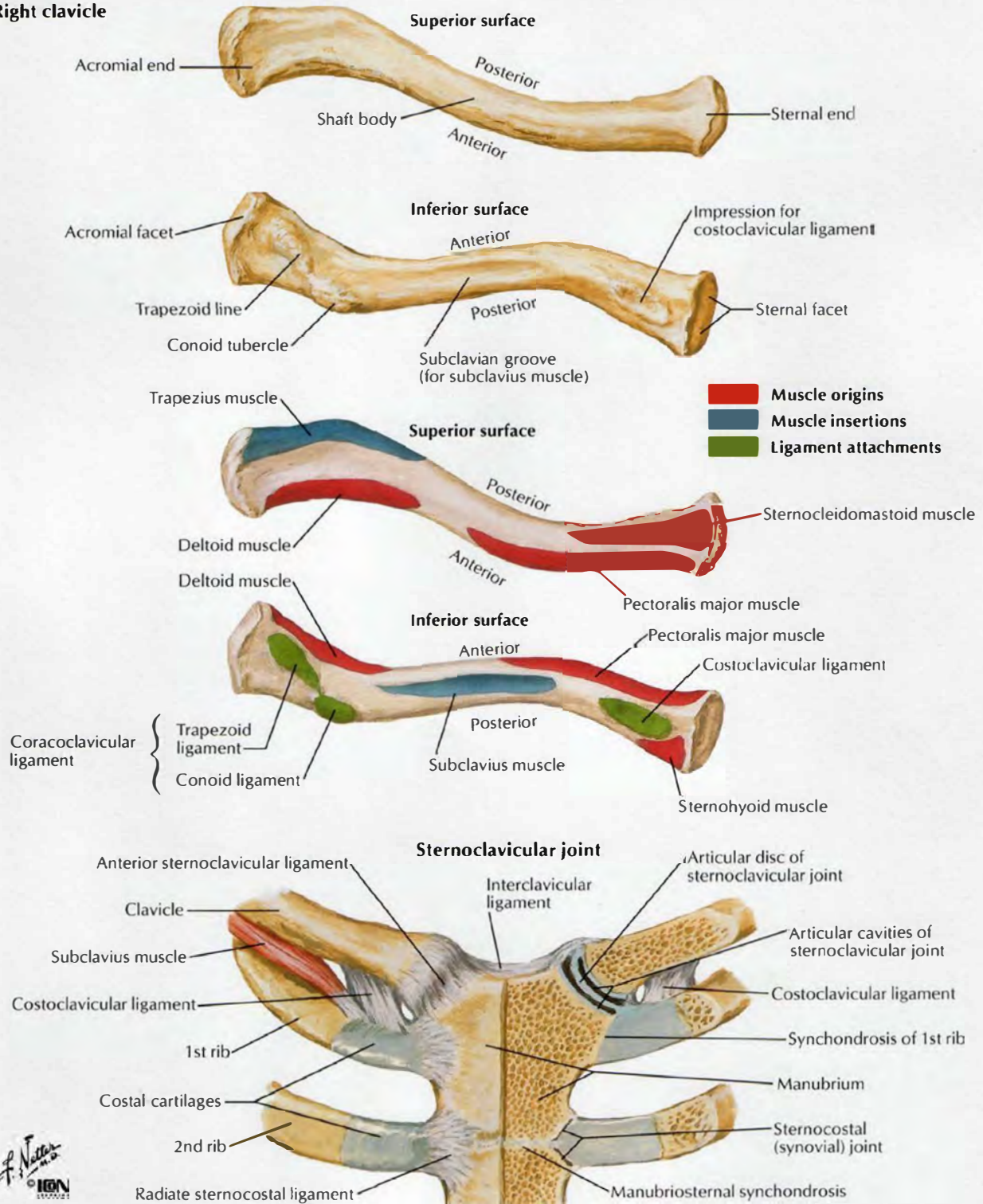
- 455. Cutaneous Innervation of Wrist and Hand
- 456. Arteries and Nerves of Upper Limb
- 457. Musculocutaneous Nerve
- 458. Median Nerve
- 459. Ulnar Nerve
- 460. Radial Nerve in Arm and Nerves of Posterior Shoulder
- 461. Radial Nerve in Forearm
- 462. Cutaneous Nerves and Superficial Veins of Shoulder and Arm
- 463. Cutaneous Nerves and Superficial Veins of Forearm
- 464. Cutaneous Innervation of Upper Limb
- 465. Dermatomes of Upper Limb
- 466. Lymph Vessels and Nodes of Upper Limb



C. Machado
 IGEN

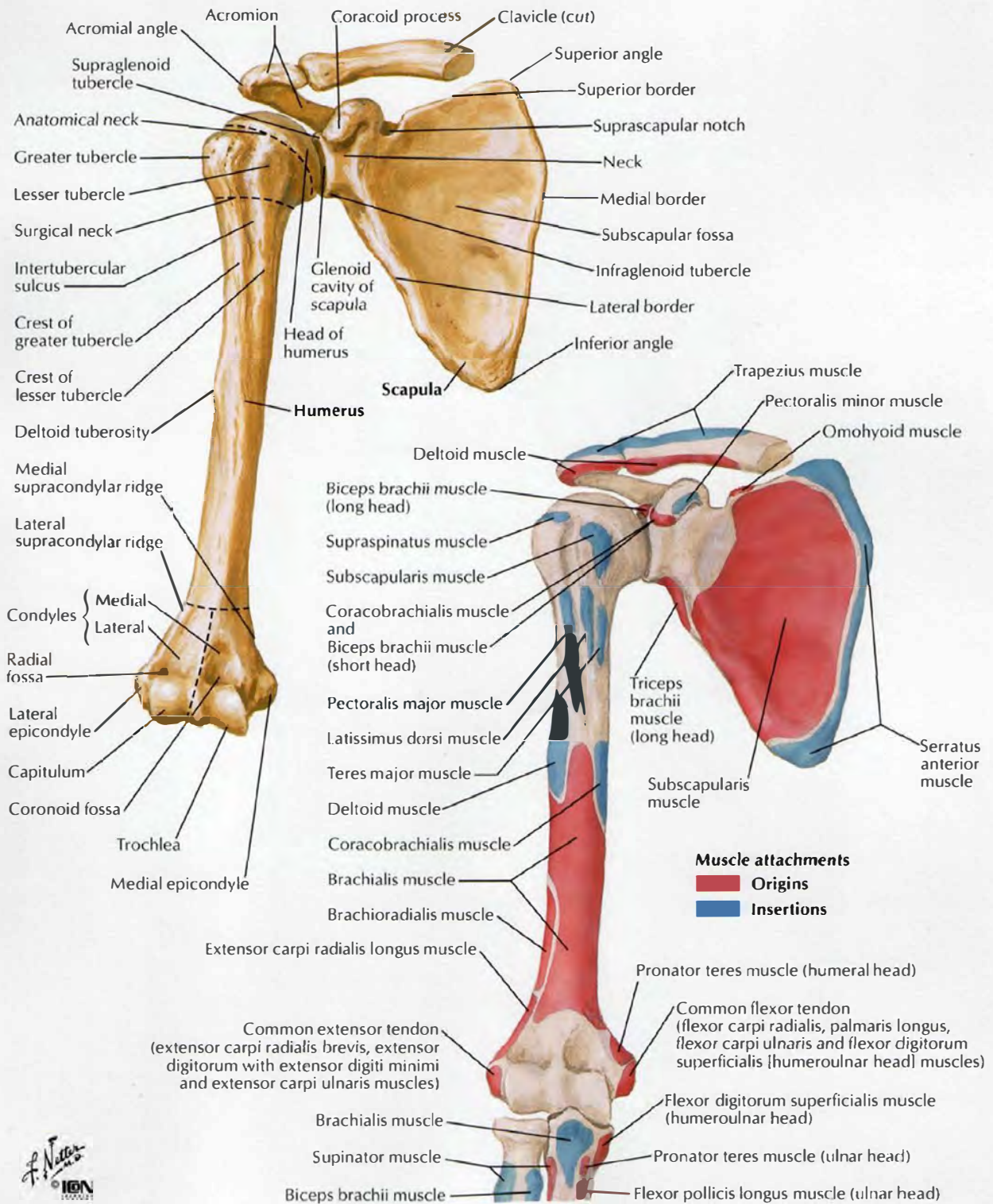
Clavicle and Sternoclavicular Joint

Right clavicle



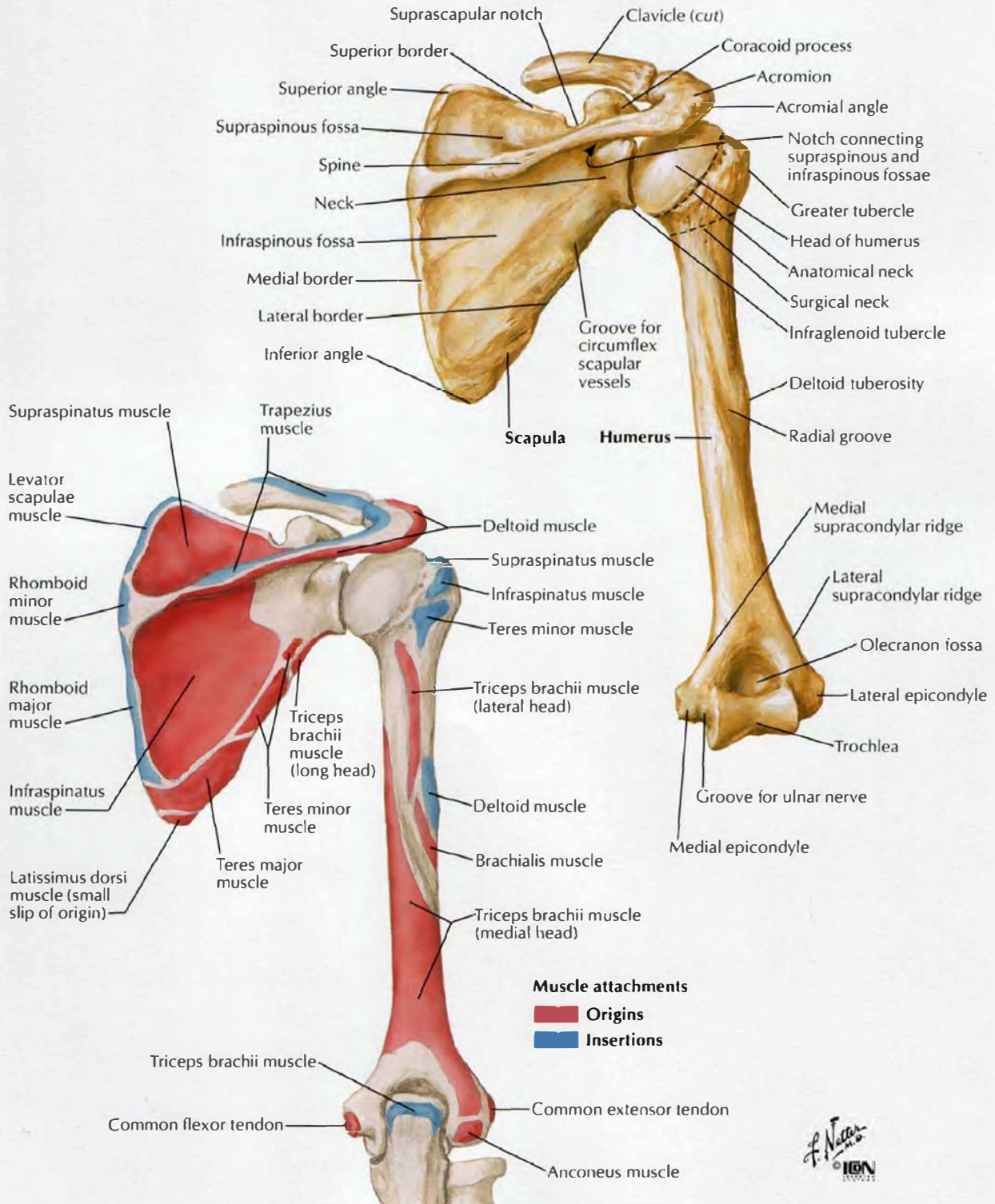
Humerus and Scapula: Anterior Views

SEE ALSO PLATE 178



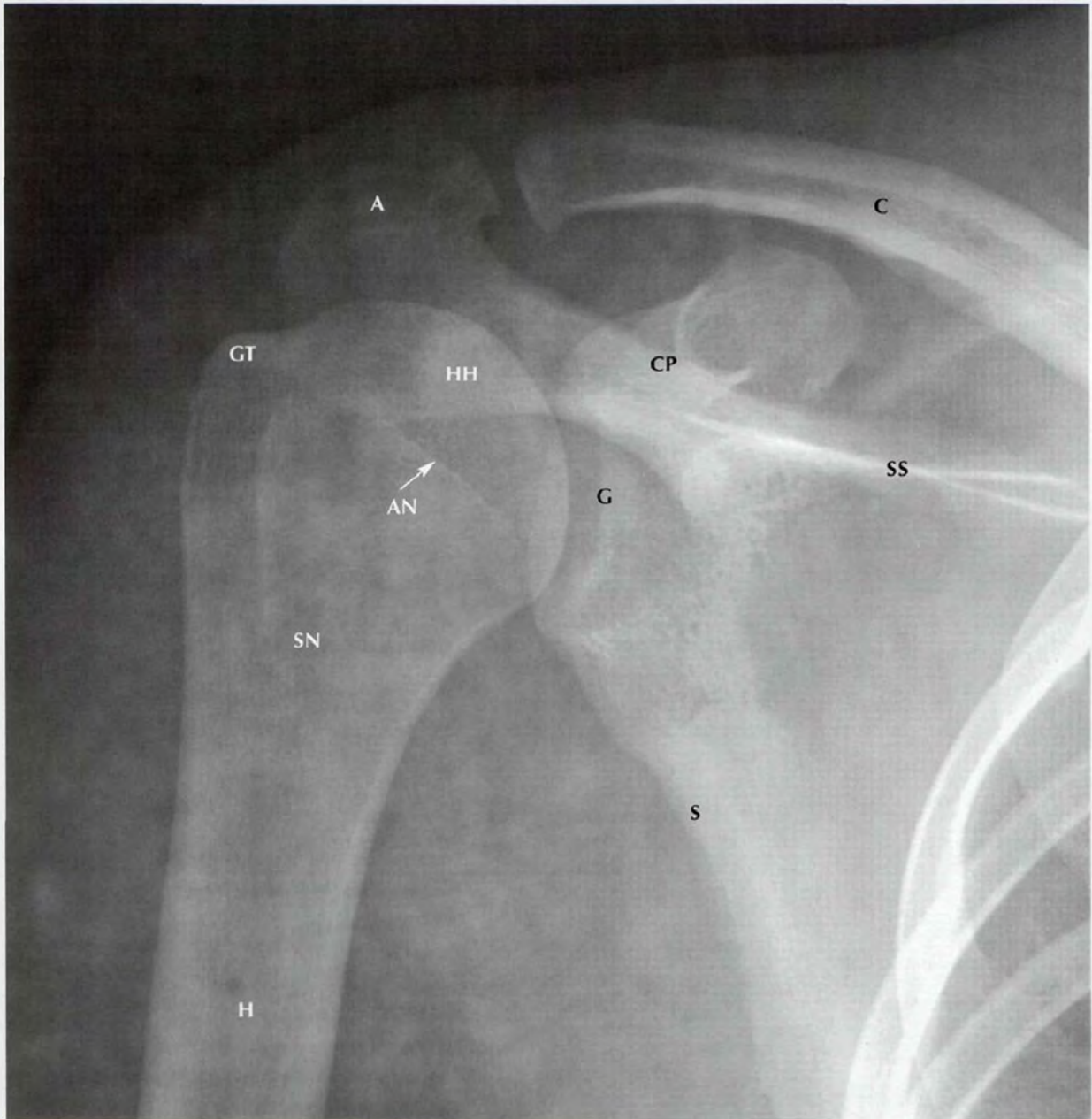
Humerus and Scapula: Posterior Views

SEE ALSO PLATE 178



Shoulder: Anteroposterior Radiograph

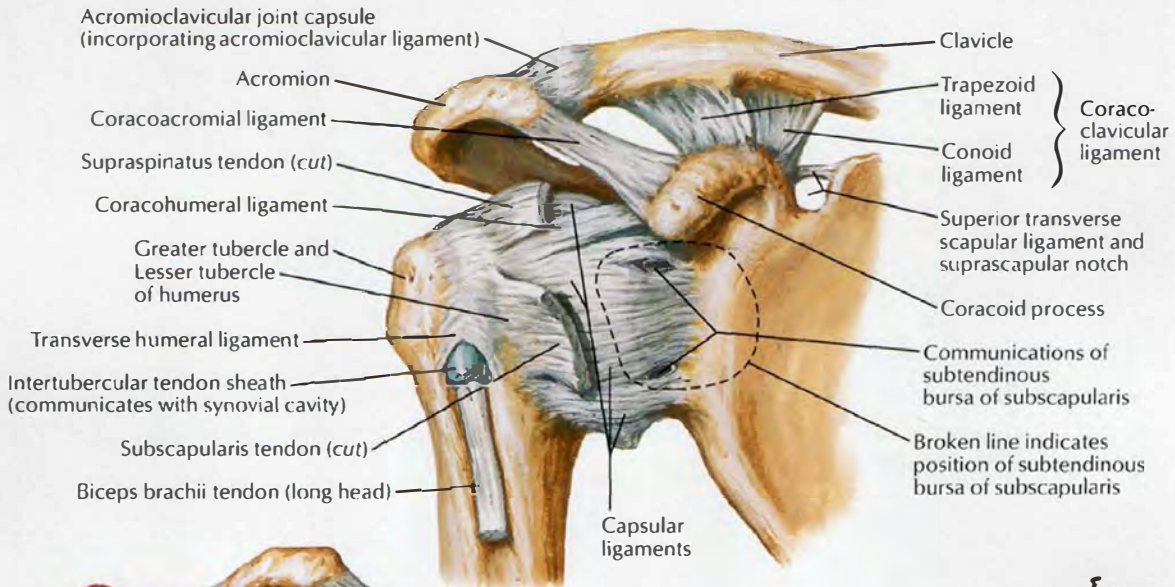
SEE ALSO PLATE 403



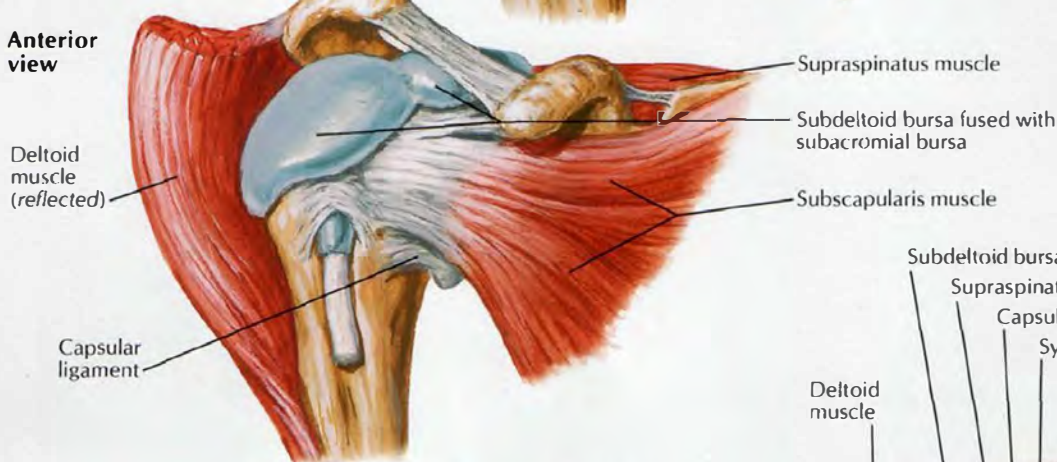
- A Acromion
- AN Anatomical neck of humerus
- C Clavicle
- CP Coracoid process
- G Glenoid cavity of scapula
- GT Greater tubercle
- H Humerus
- HH Head of humerus
- S Scapula (lateral border)
- SN Surgical neck of humerus
- SS Spine of scapula

Shoulder (Glenohumeral) Joint

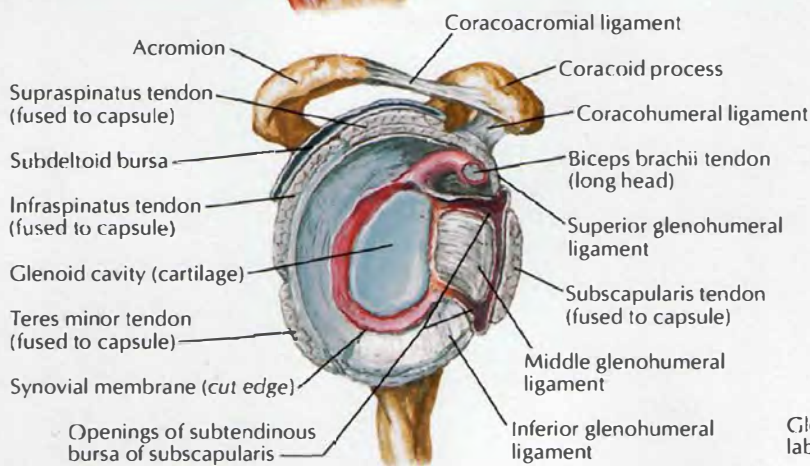
Anterior view



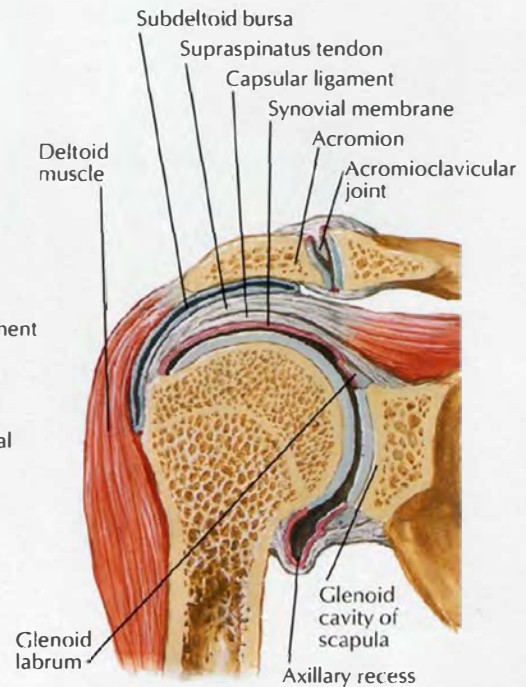
Anterior view



F. Netter M.D.
© IGCN



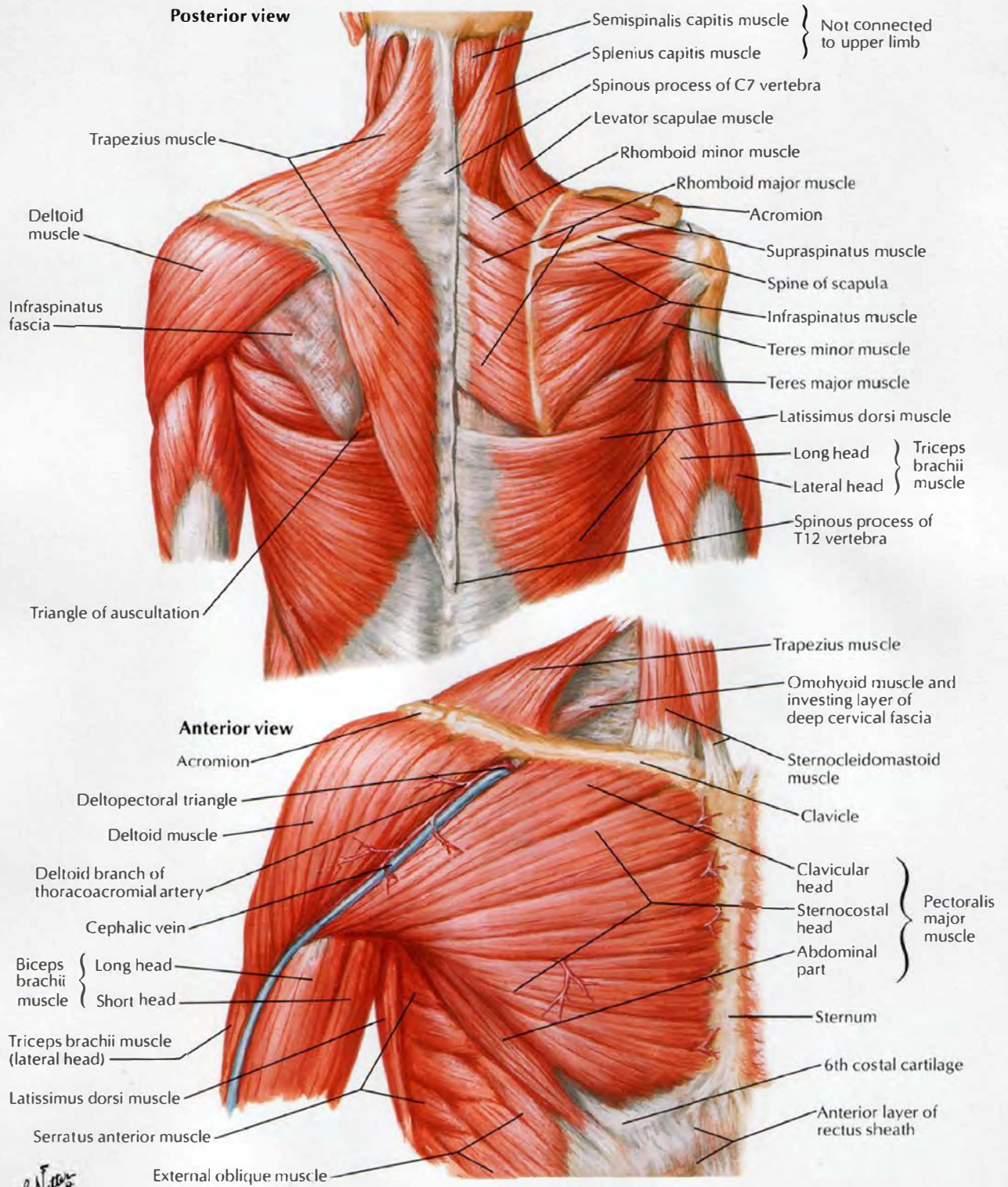
Joint opened: lateral view



Coronal section through joint

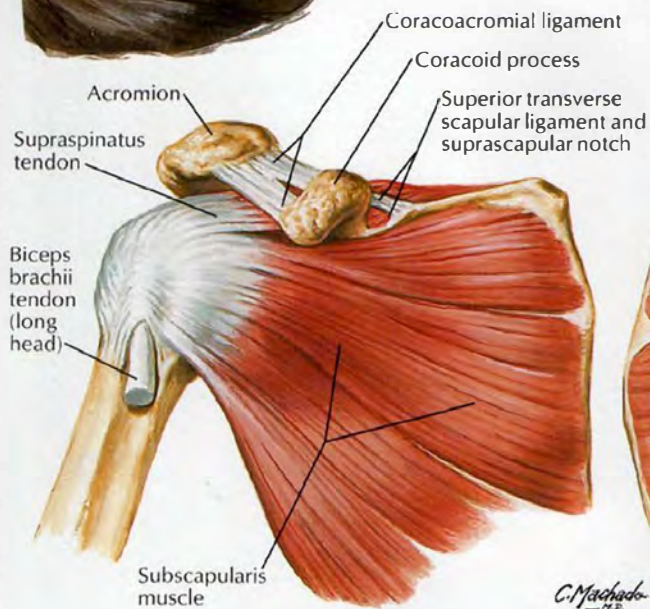
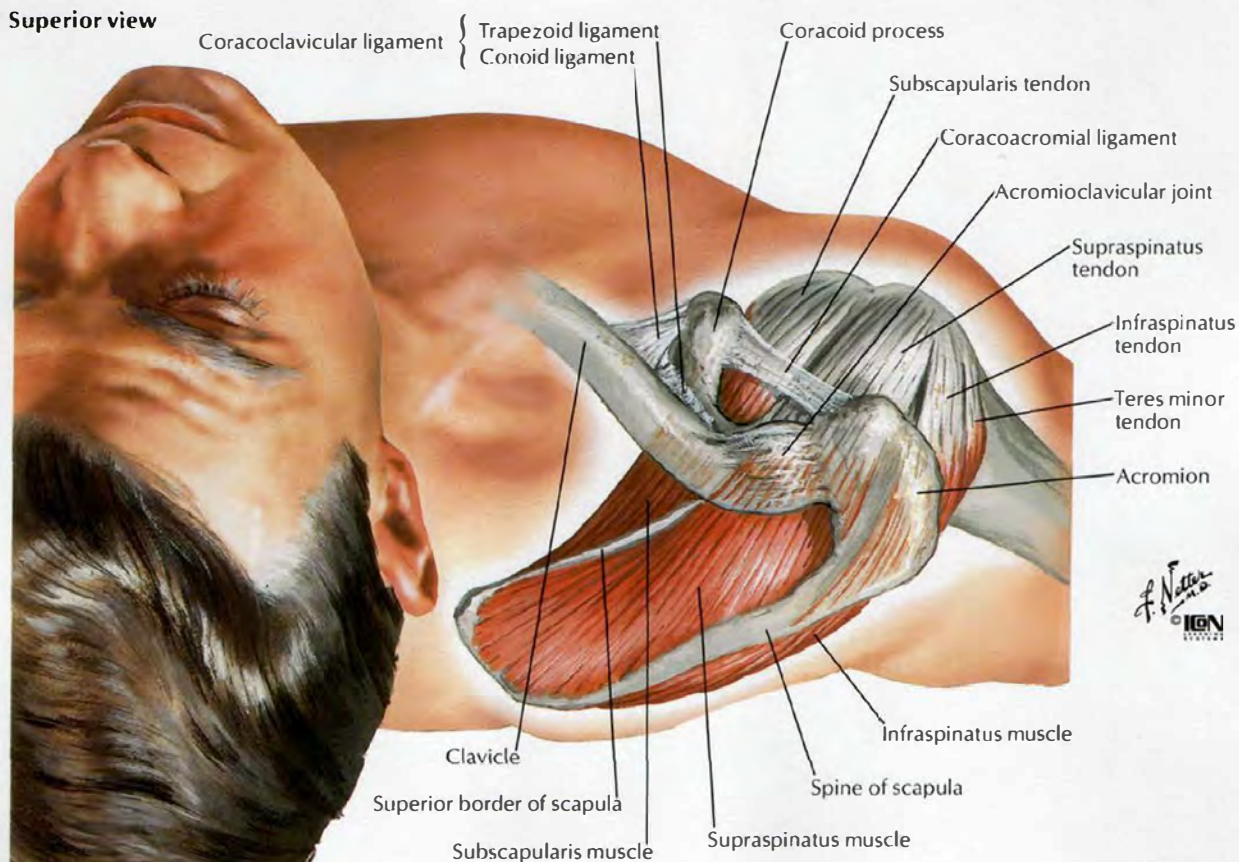
Muscles of Shoulder

SEE ALSO PLATES 23, 167, 182, 183, 185, 186

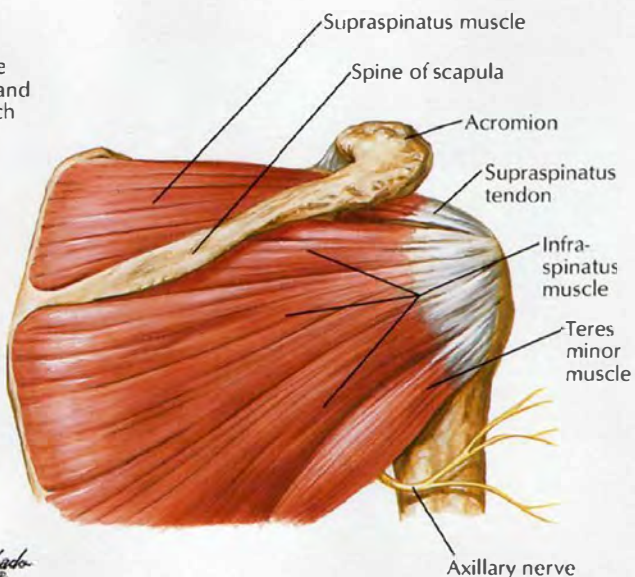


Muscles of Rotator Cuff

Superior view



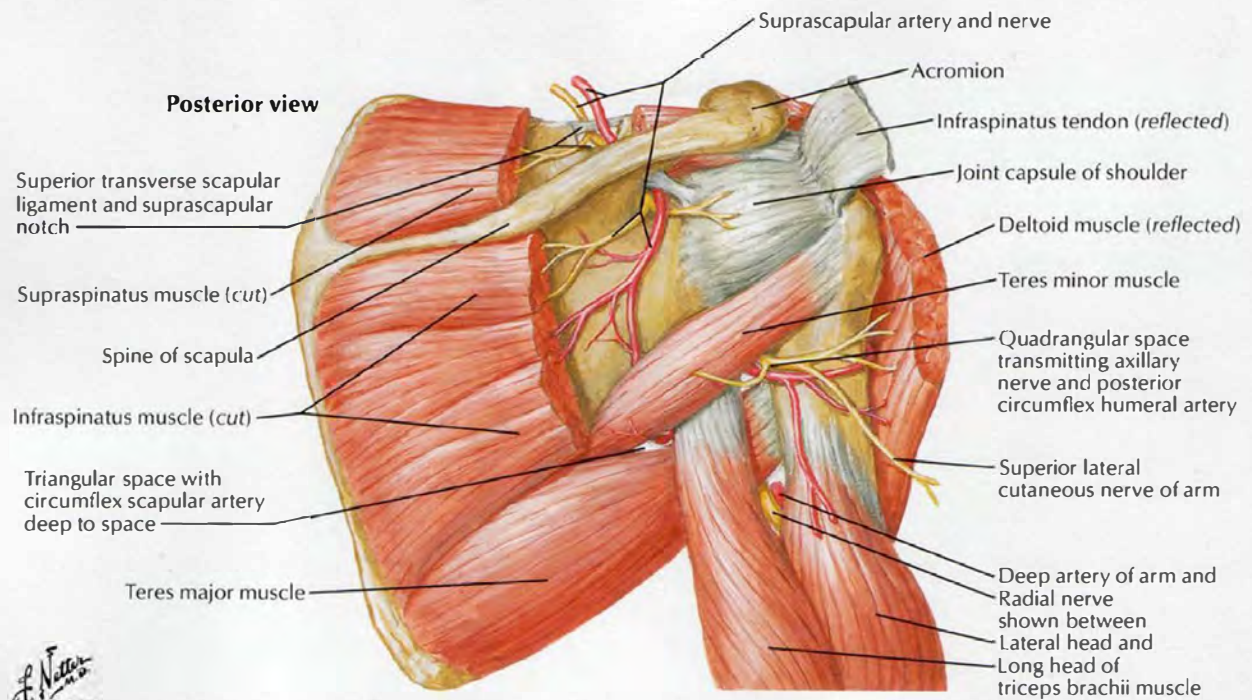
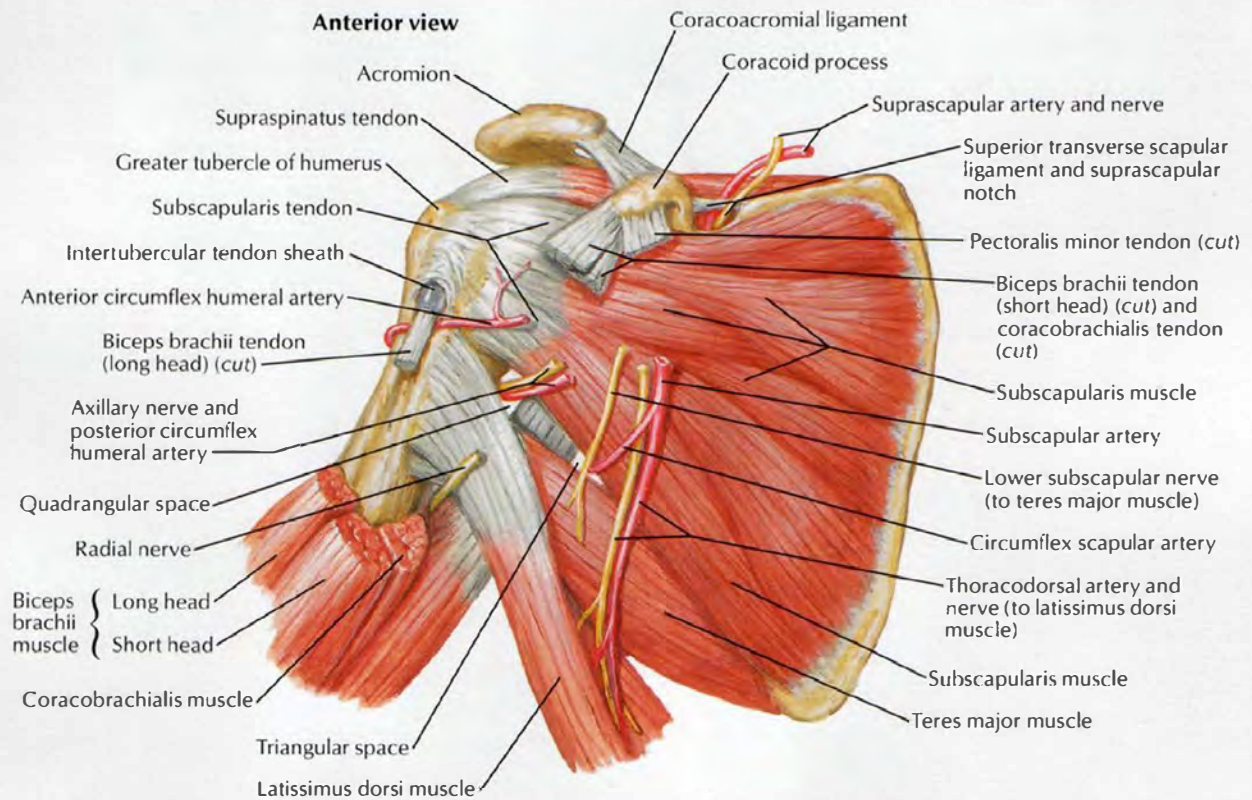
Anterior view



Posterior view

Scapulohumeral Dissection

SEE ALSO PLATE 460

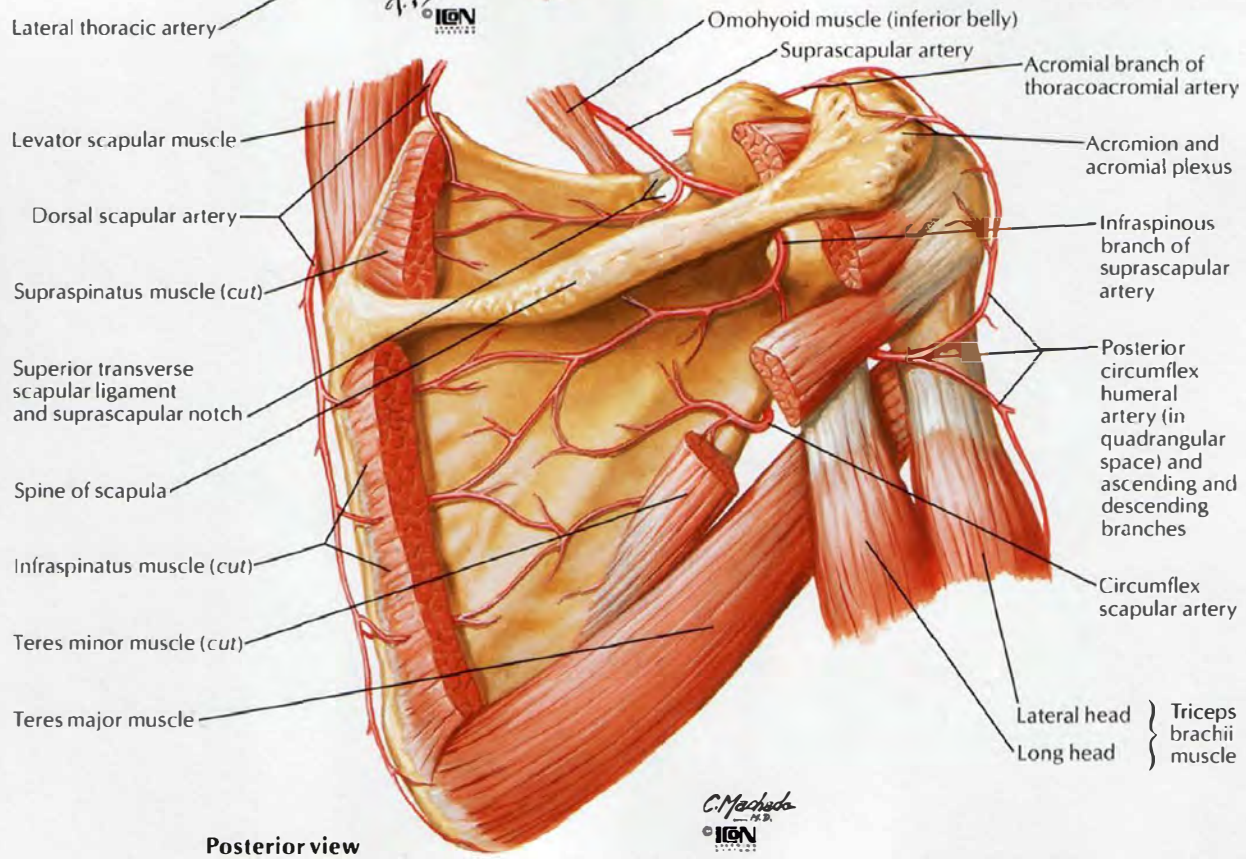
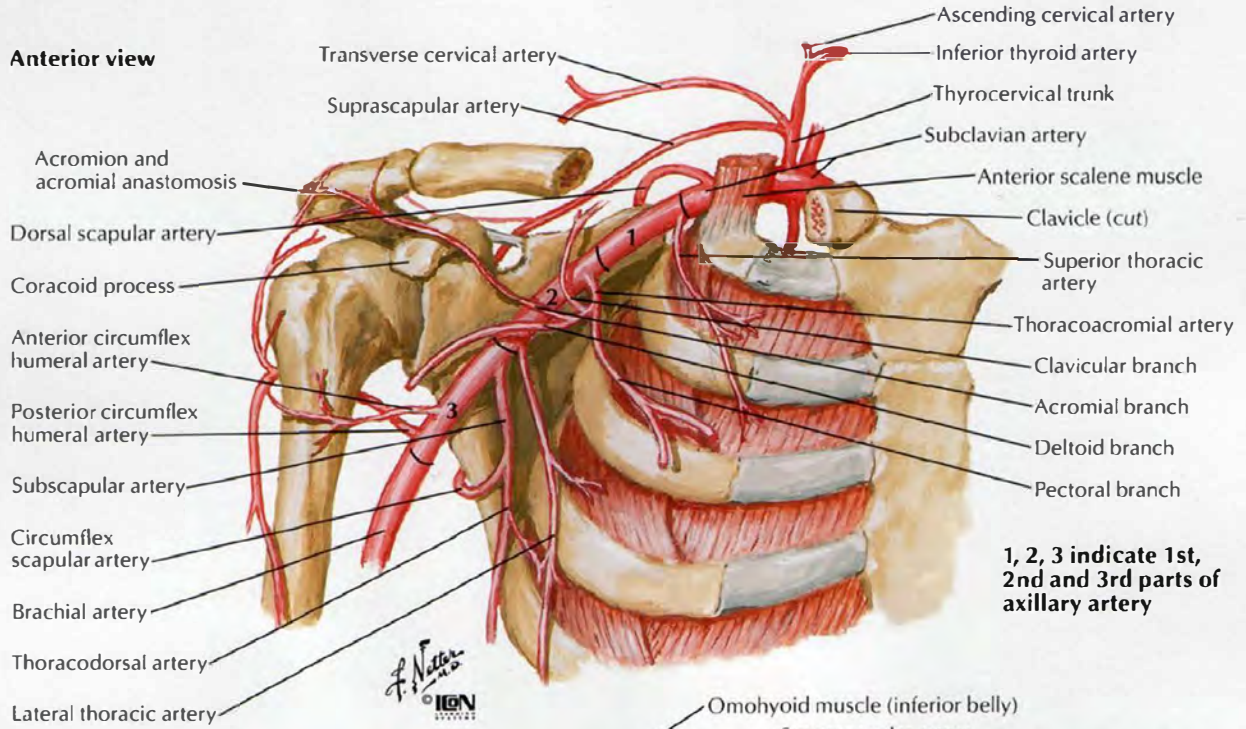


F. Netter
© IGM
2002

Axillary Artery and Anastomoses Around Scapula

SEE ALSO PLATES 29, 417

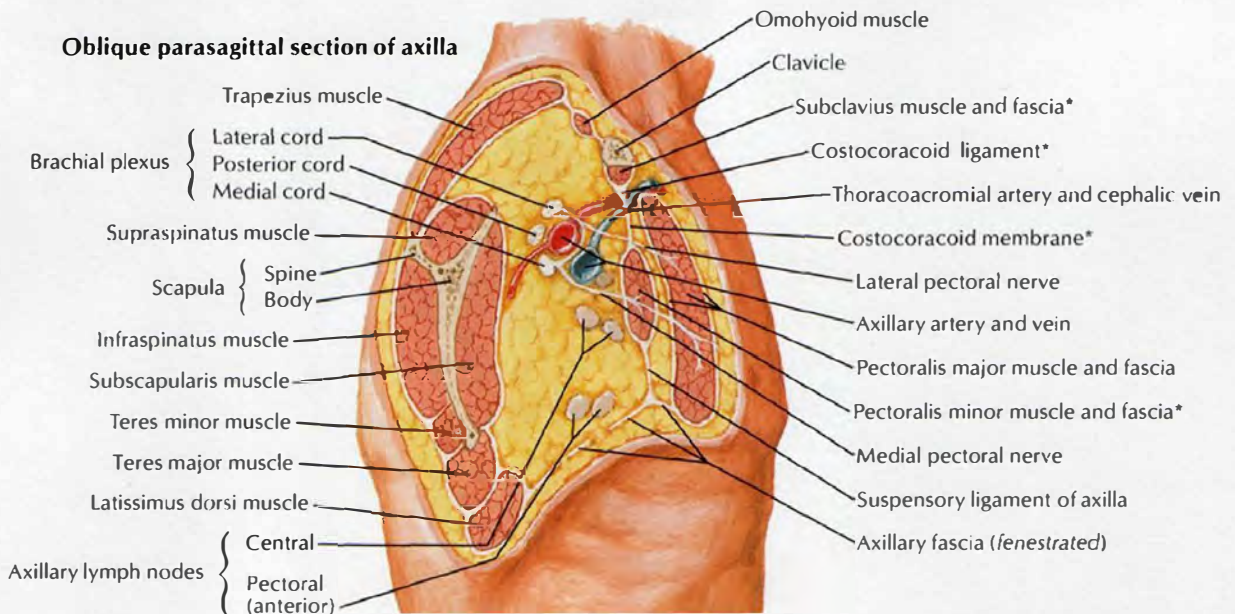
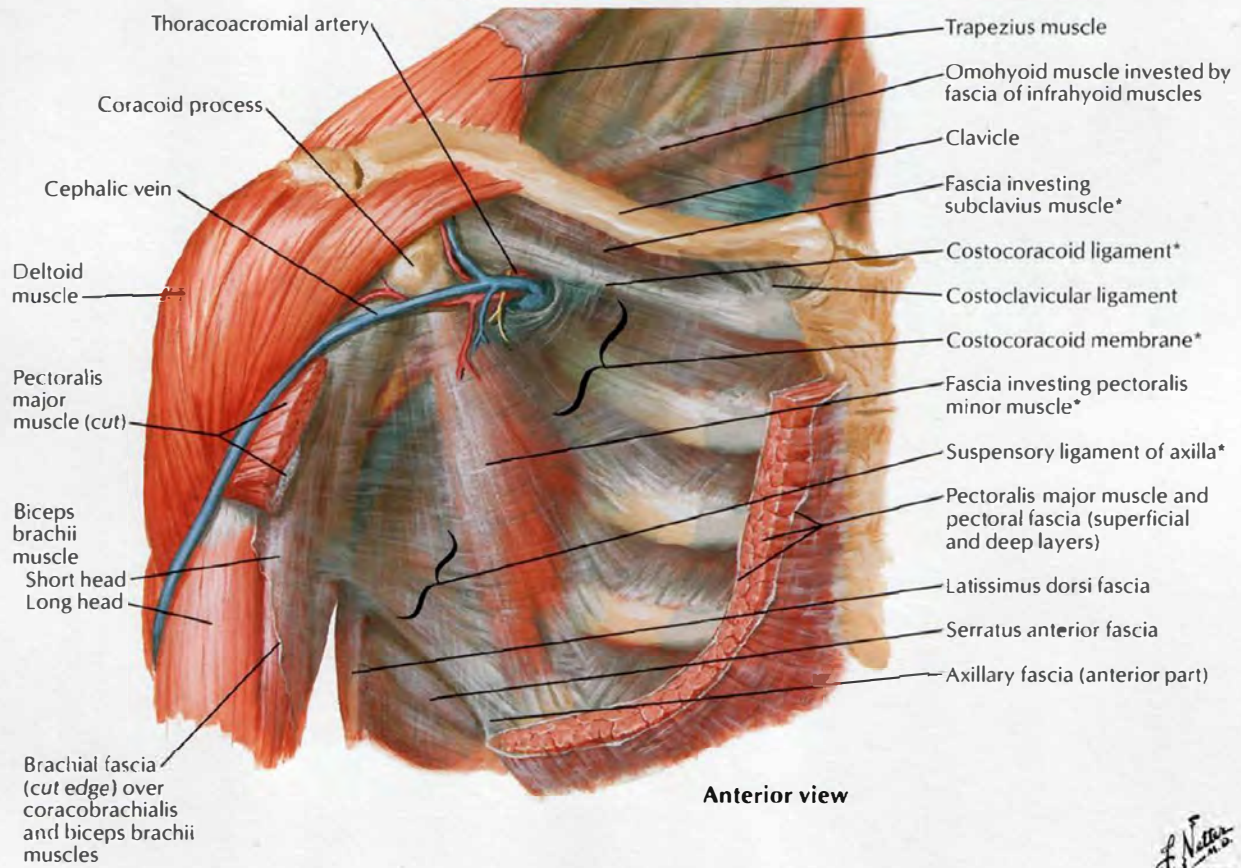
Anterior view



Posterior view

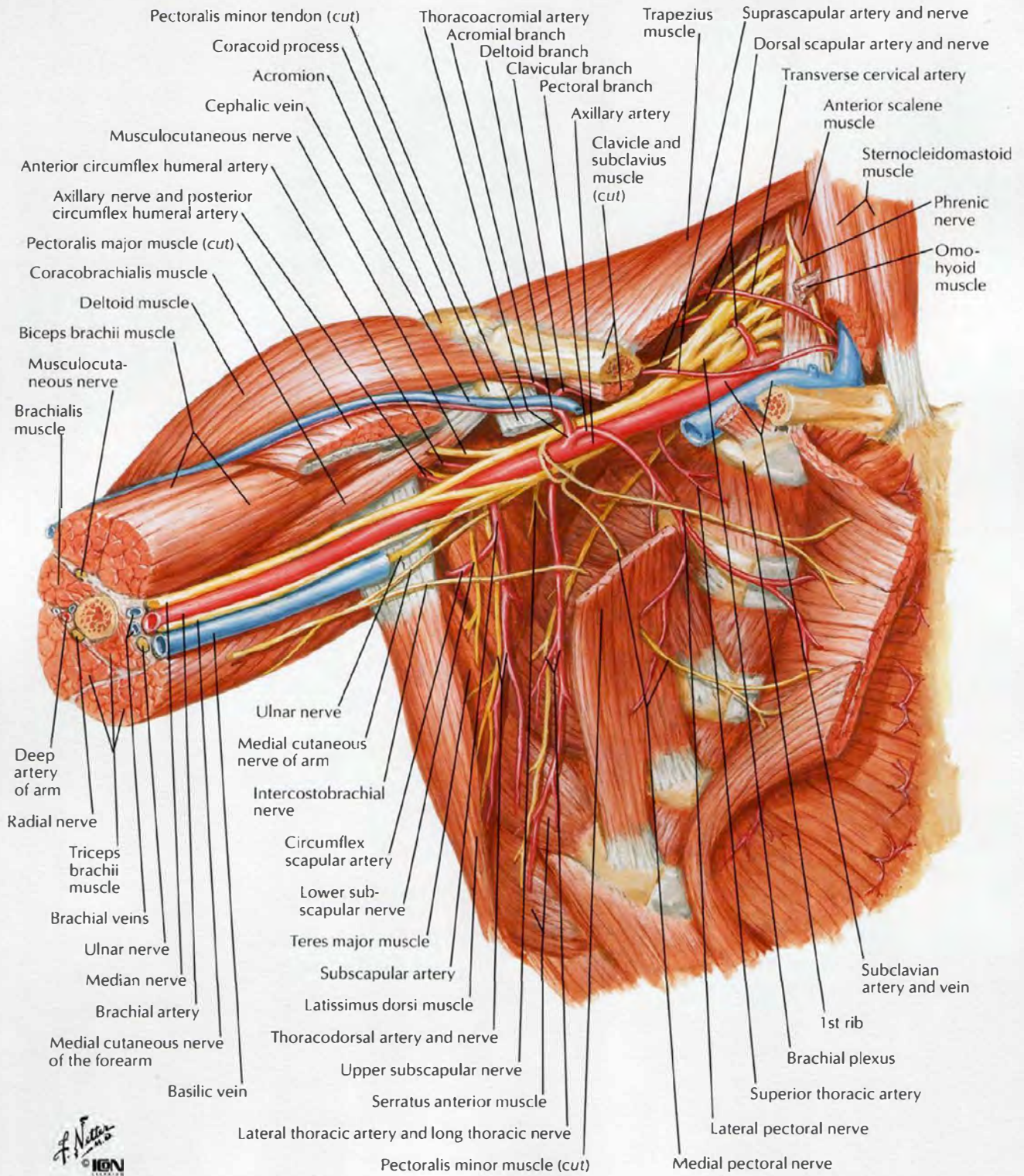
Pectoral, Clavipectoral and Axillary Fasciae

SEE ALSO PLATE 182



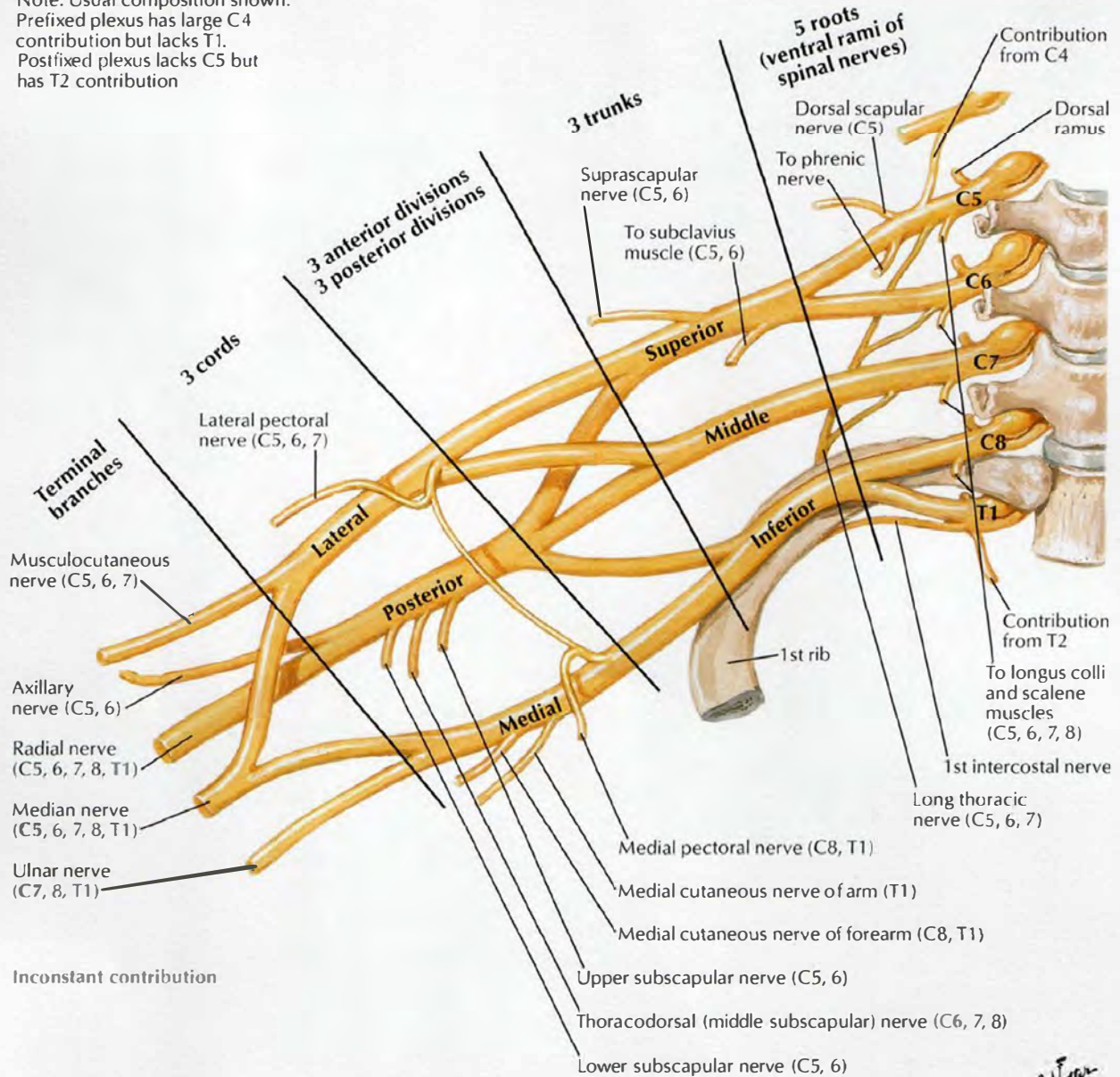
*Components of clavipectoral fascia

Axilla (Dissection): Anterior View



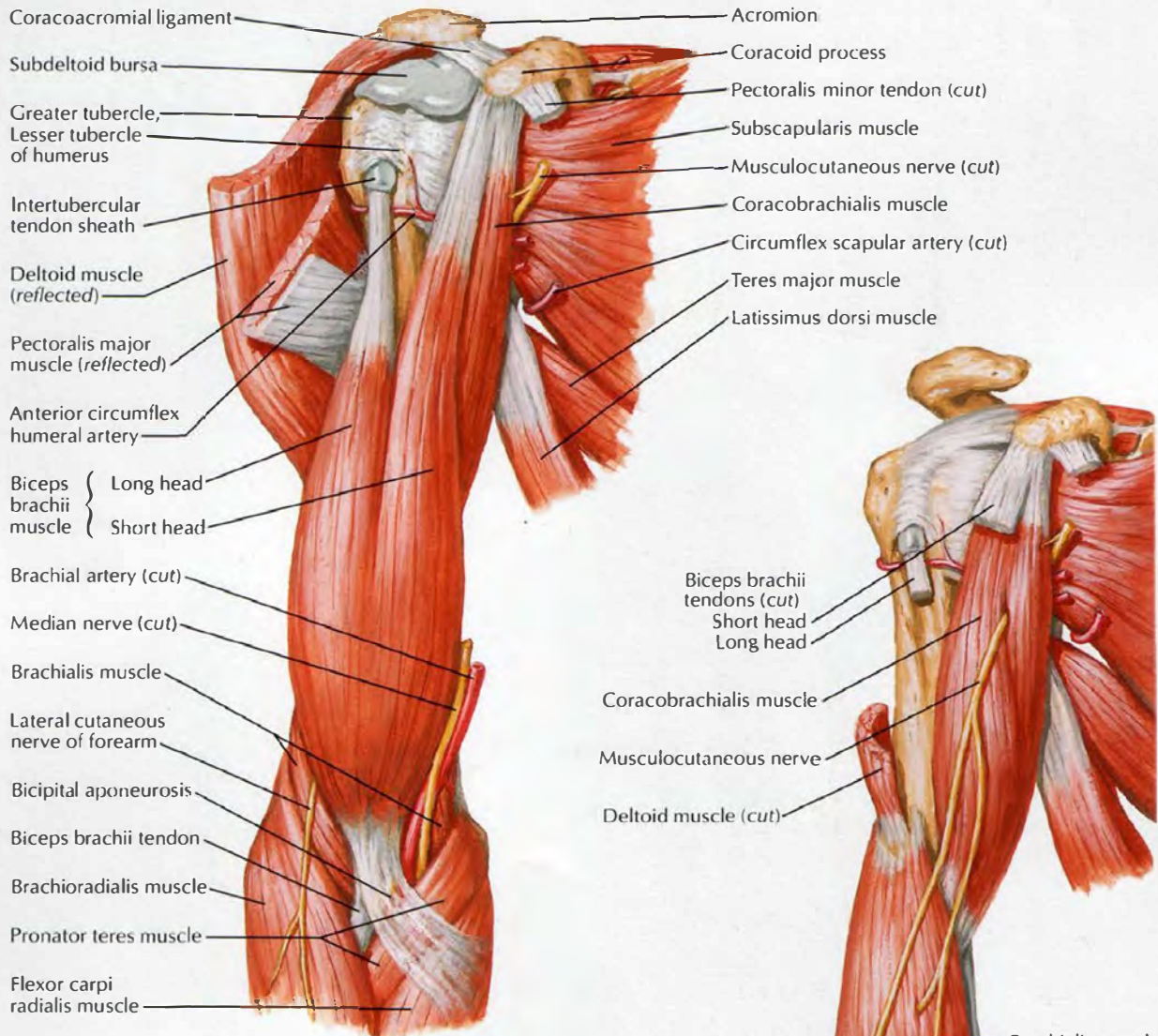
Brachial Plexus: Schema

Note: Usual composition shown.
 Prefixed plexus has large C4 contribution but lacks T1.
 Postfixed plexus lacks C5 but has T2 contribution

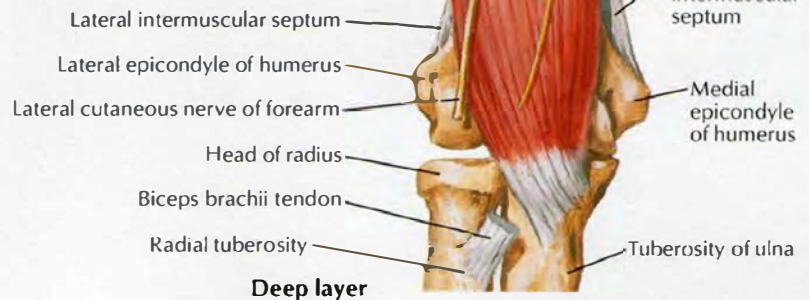


Muscles of Arm: Anterior Views

SEE ALSO PLATE 457



Superficial layer

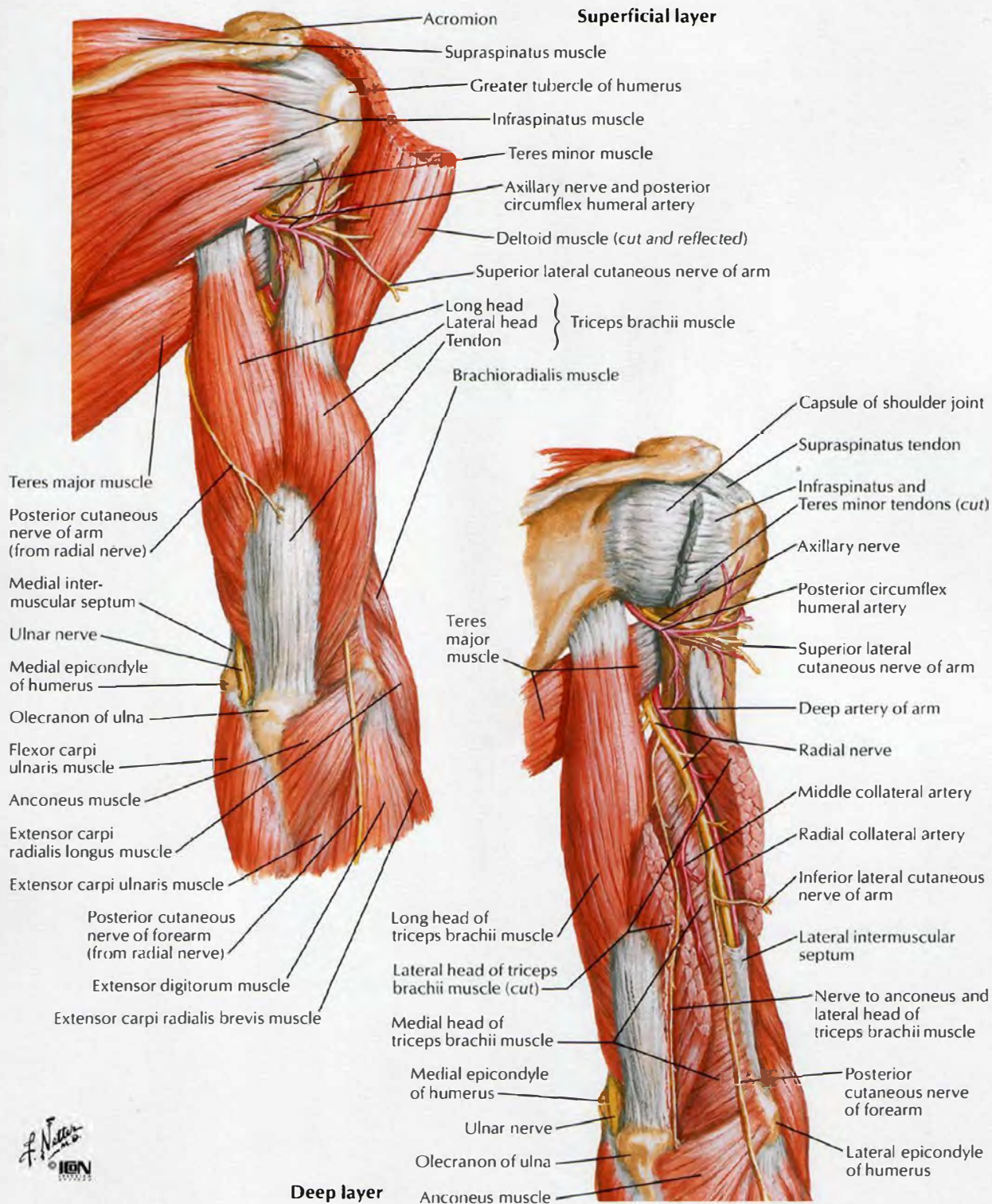


Deep layer



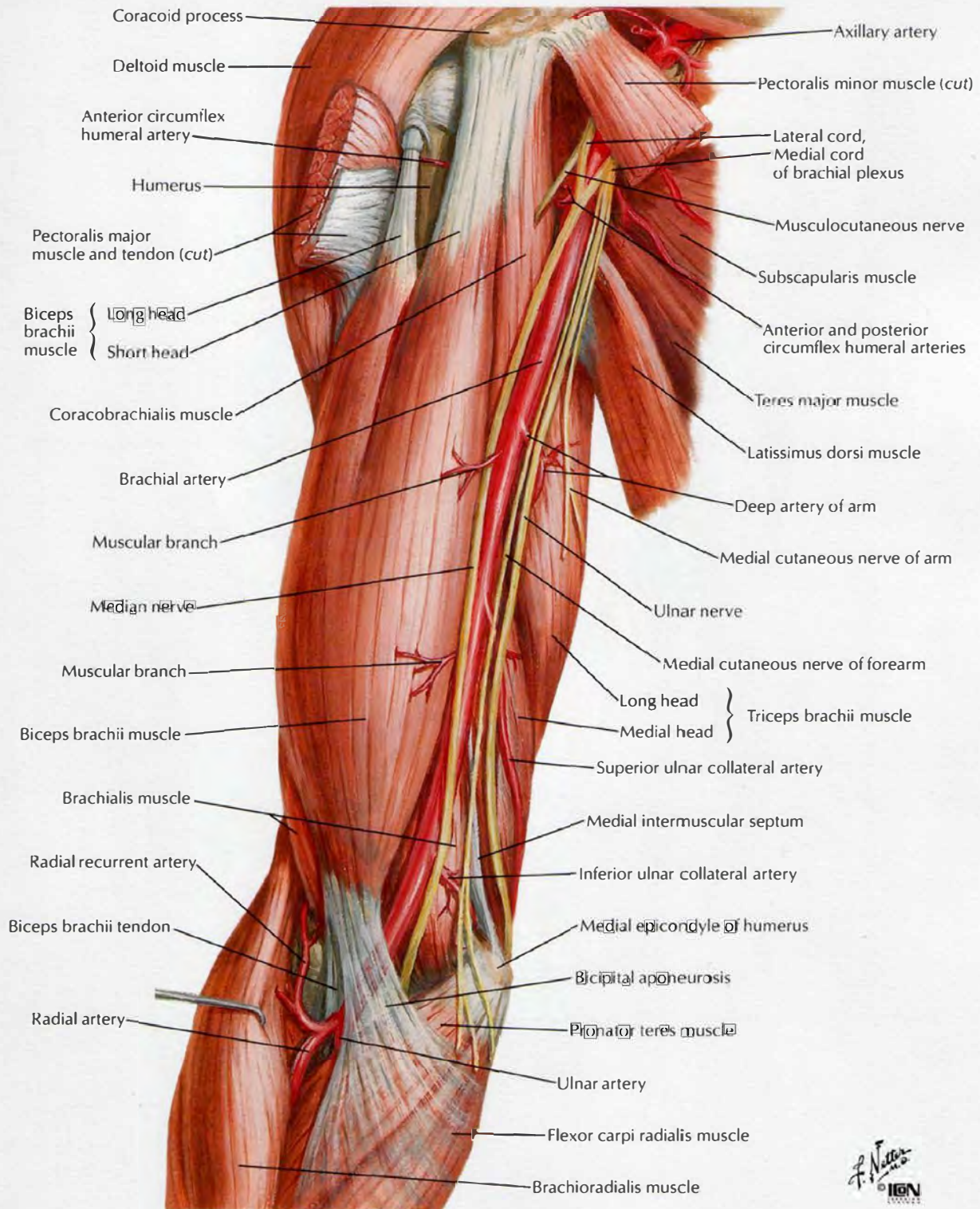
Muscles of Arm: Posterior Views

SEE ALSO PLATE 460



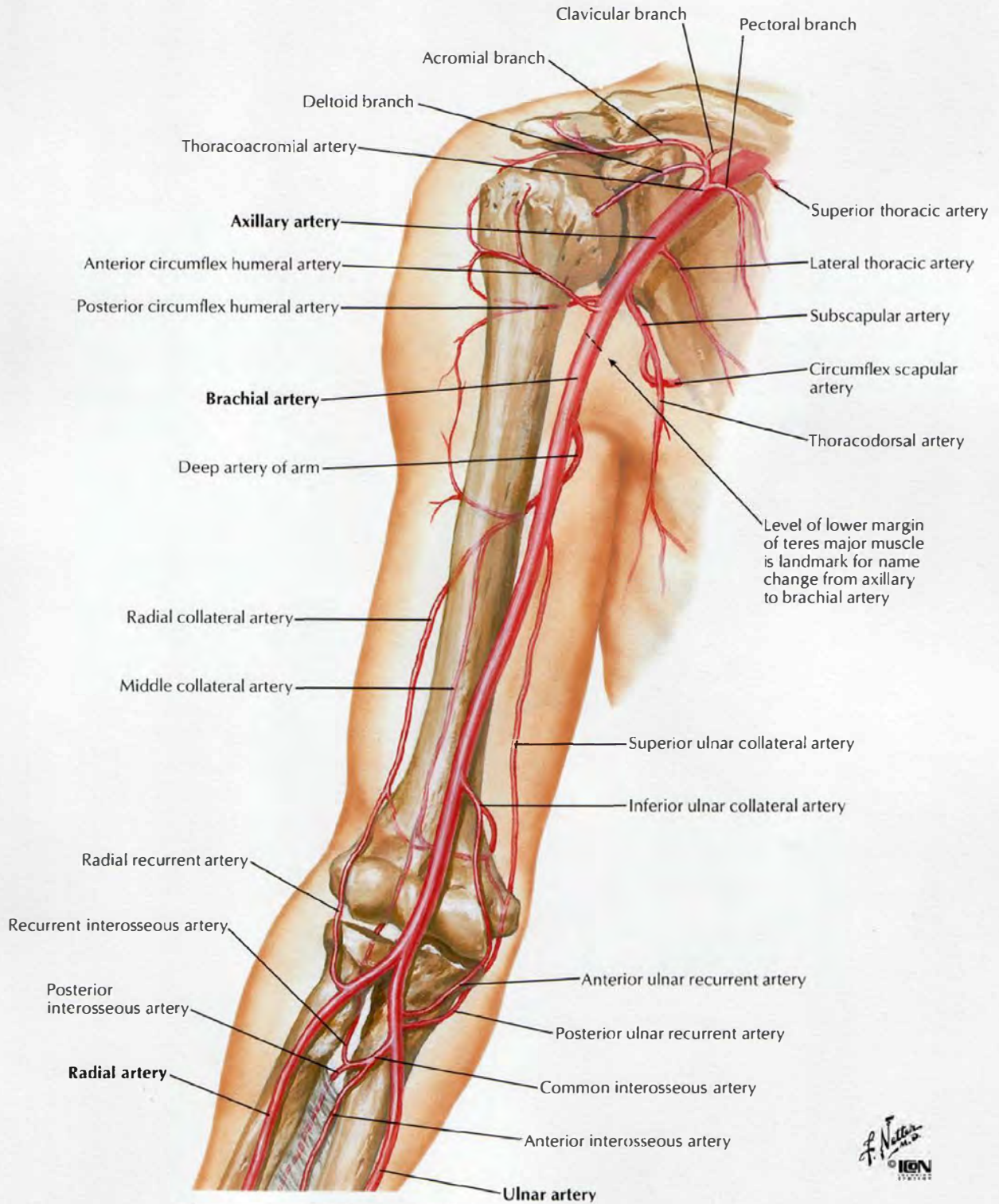
F. Netter M.D.
© IGB

Brachial Artery In Situ

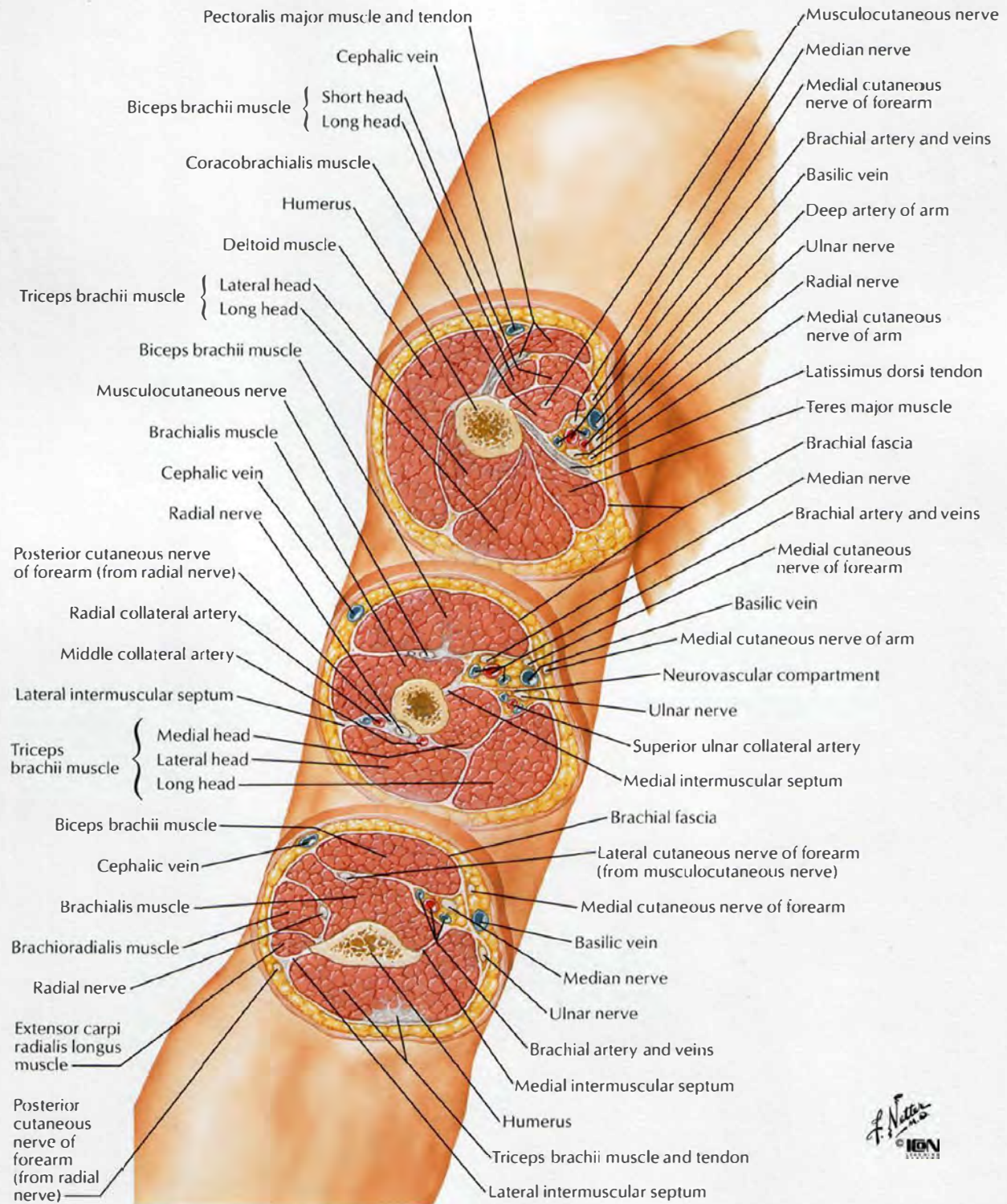


Brachial Artery and Anastomoses Around Elbow

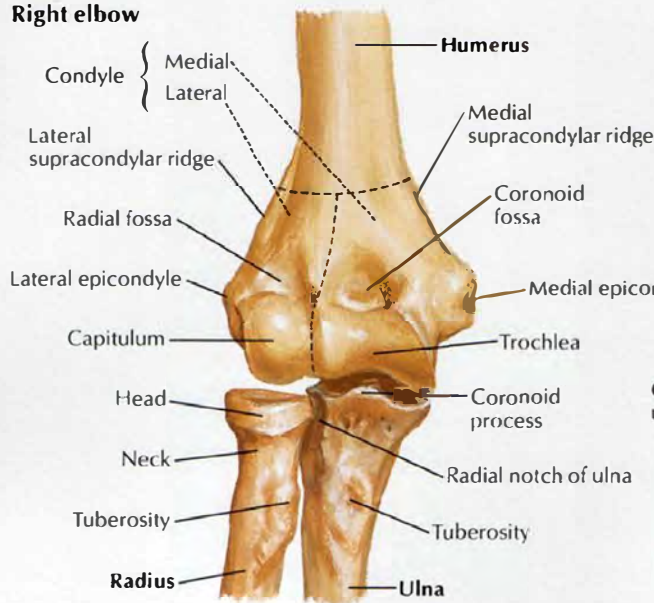
SEE ALSO PLATE 410



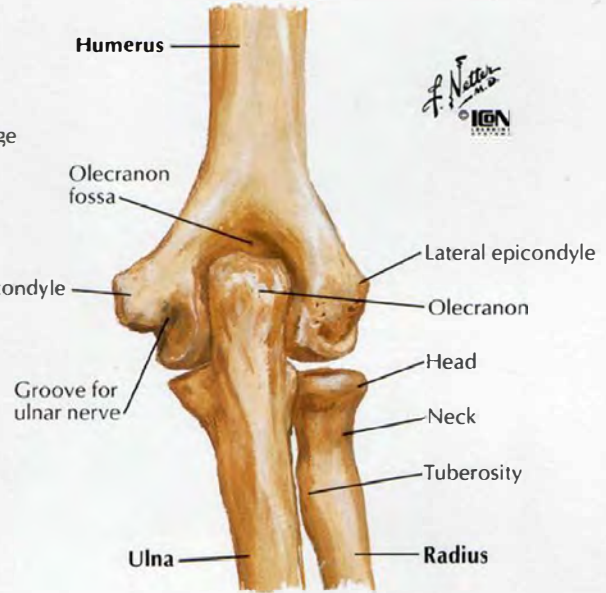Arm: Serial Cross Sections



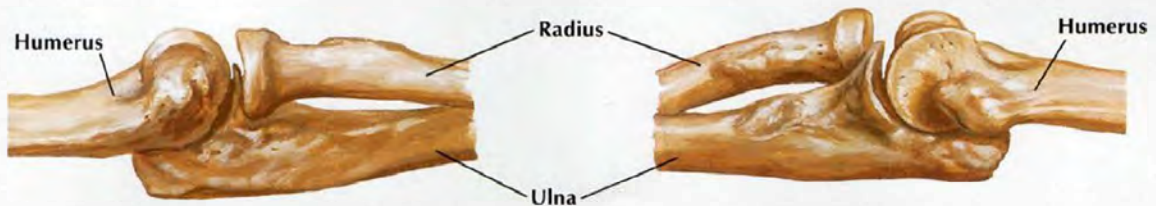
Right elbow



In extension: anterior view

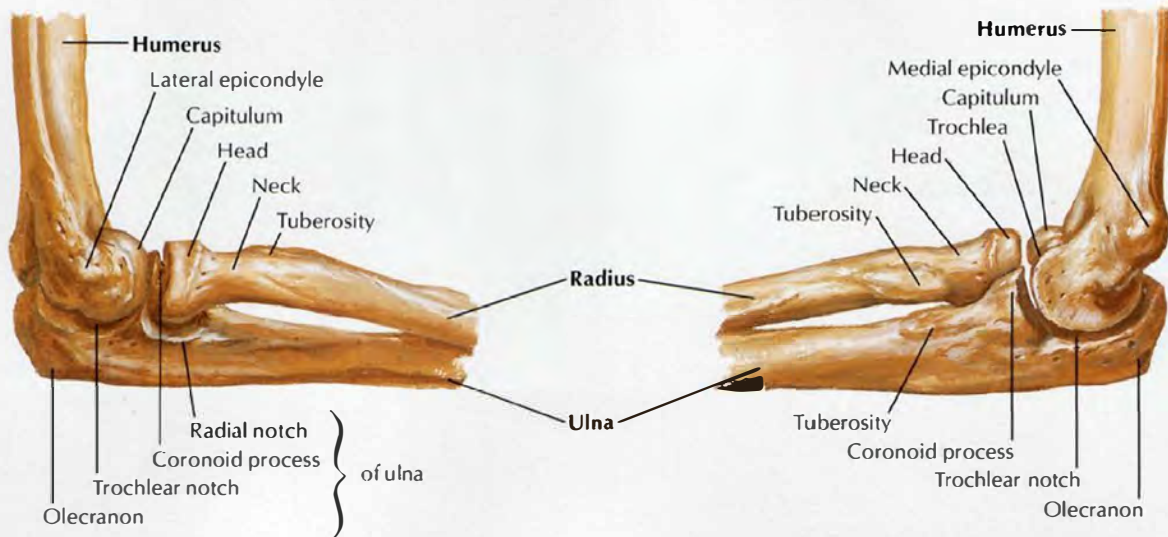


In extension: posterior view



In extension: lateral view

In extension: medial view

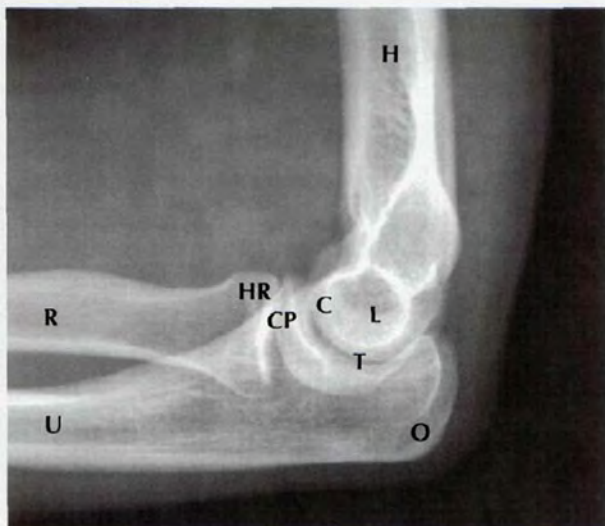


In 90° flexion: lateral view

In 90° flexion: medial view

Elbow: Radiographs

SEE ALSO PLATE 419

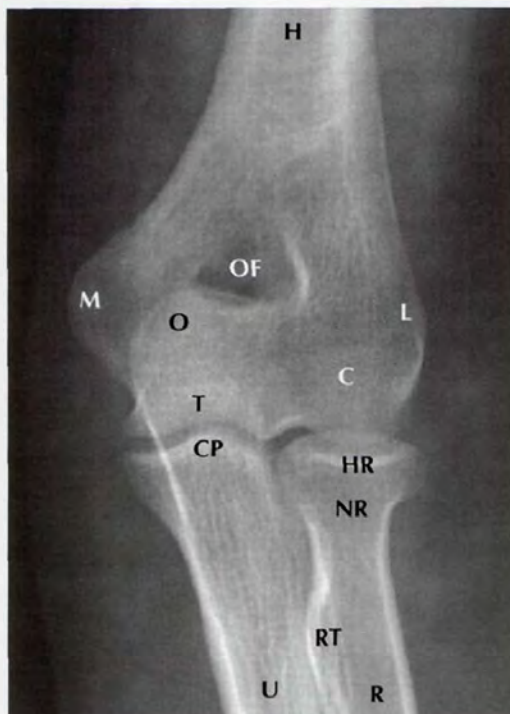


Lateral radiograph

- C Capitulum
- CP Coronoid process of ulna
- H Humerus
- HR Head of radius
- L Lateral epicondyle
- O Olecranon
- R Radius
- T Trochlear notch
- U Ulna

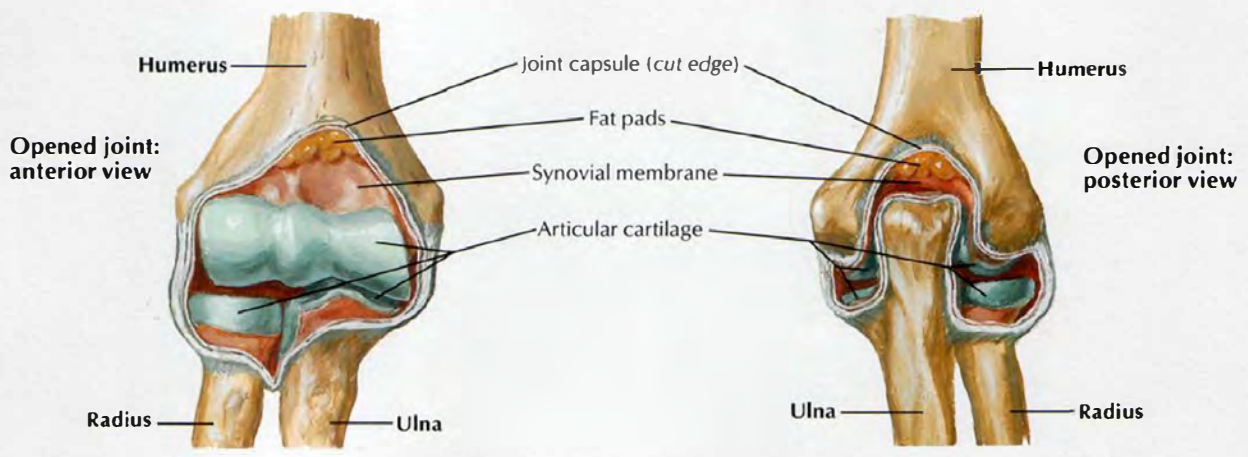
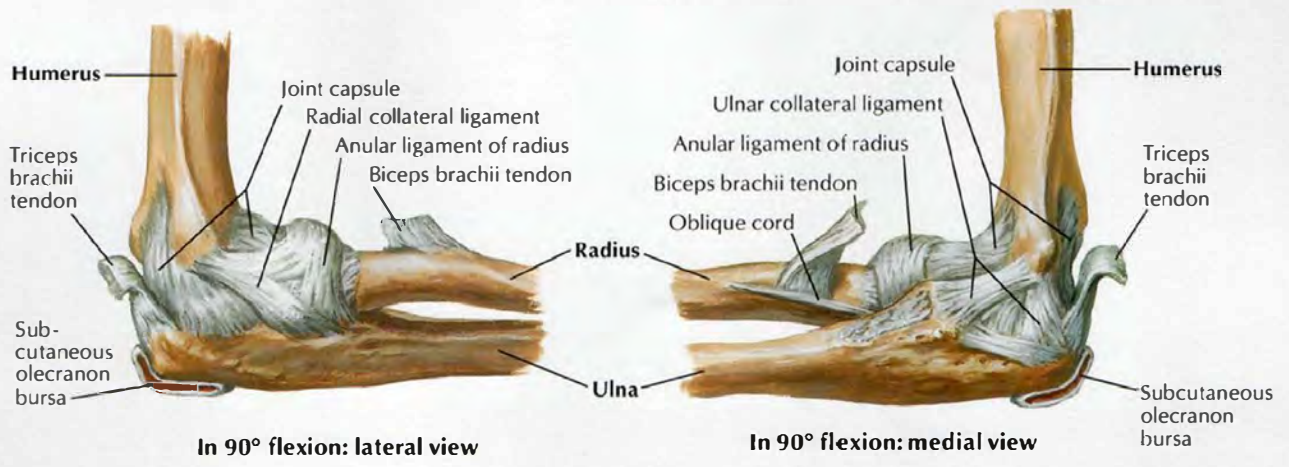
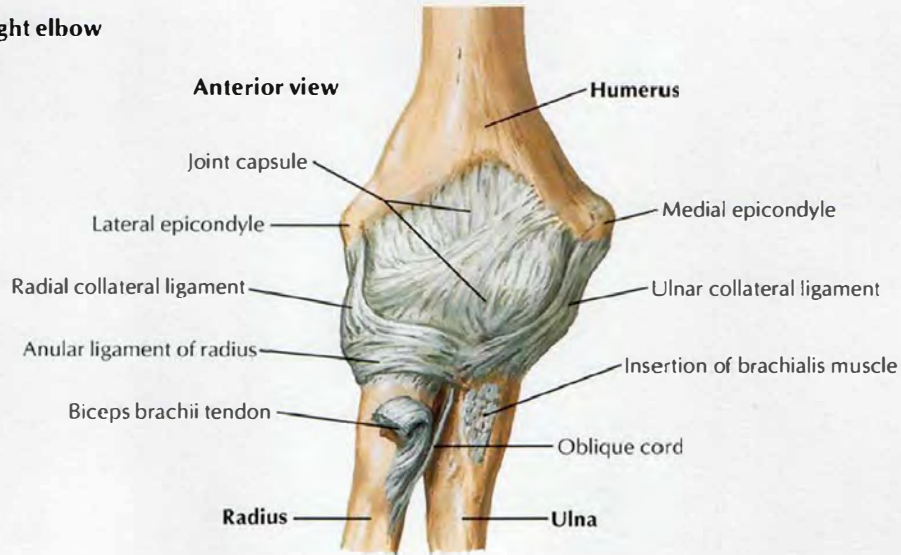
Anteroposterior radiograph

- C Capitulum
- CP Coronoid process of ulna
- H Humerus
- HR Head of radius
- L Lateral epicondyle
- M Medial of epicondyle
- NR Neck of radius
- O Olecranon
- OF Olecranon fossa
- R Radius
- T Trochlea of humerus
- RT Radial tuberosity
- U Ulna



Ligaments of Elbow

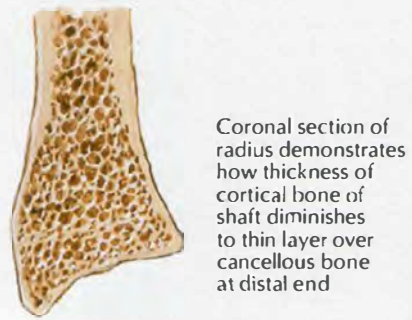
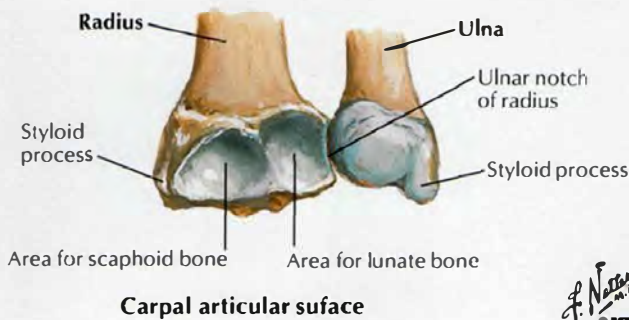
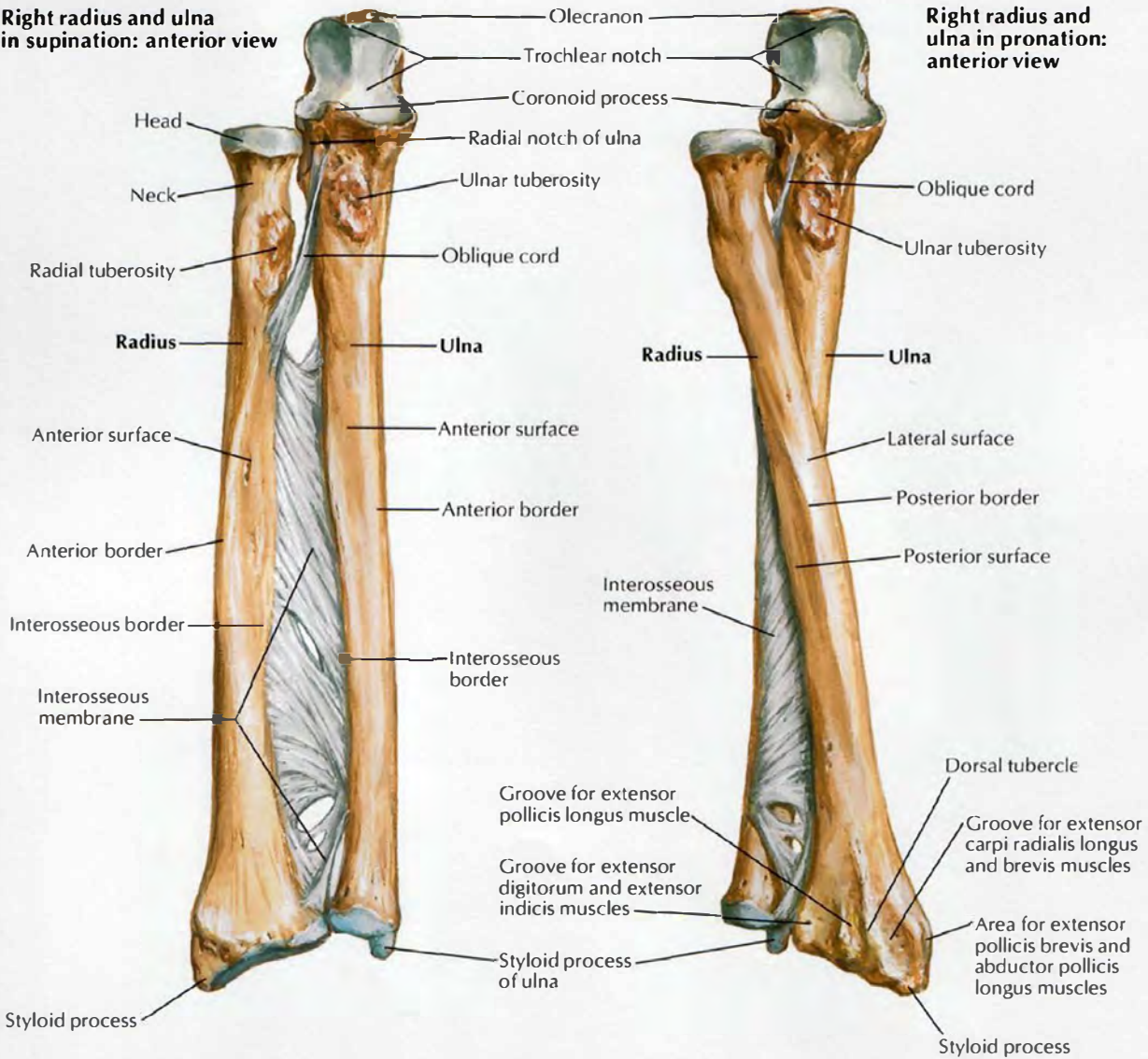
Right elbow



Bones of Forearm

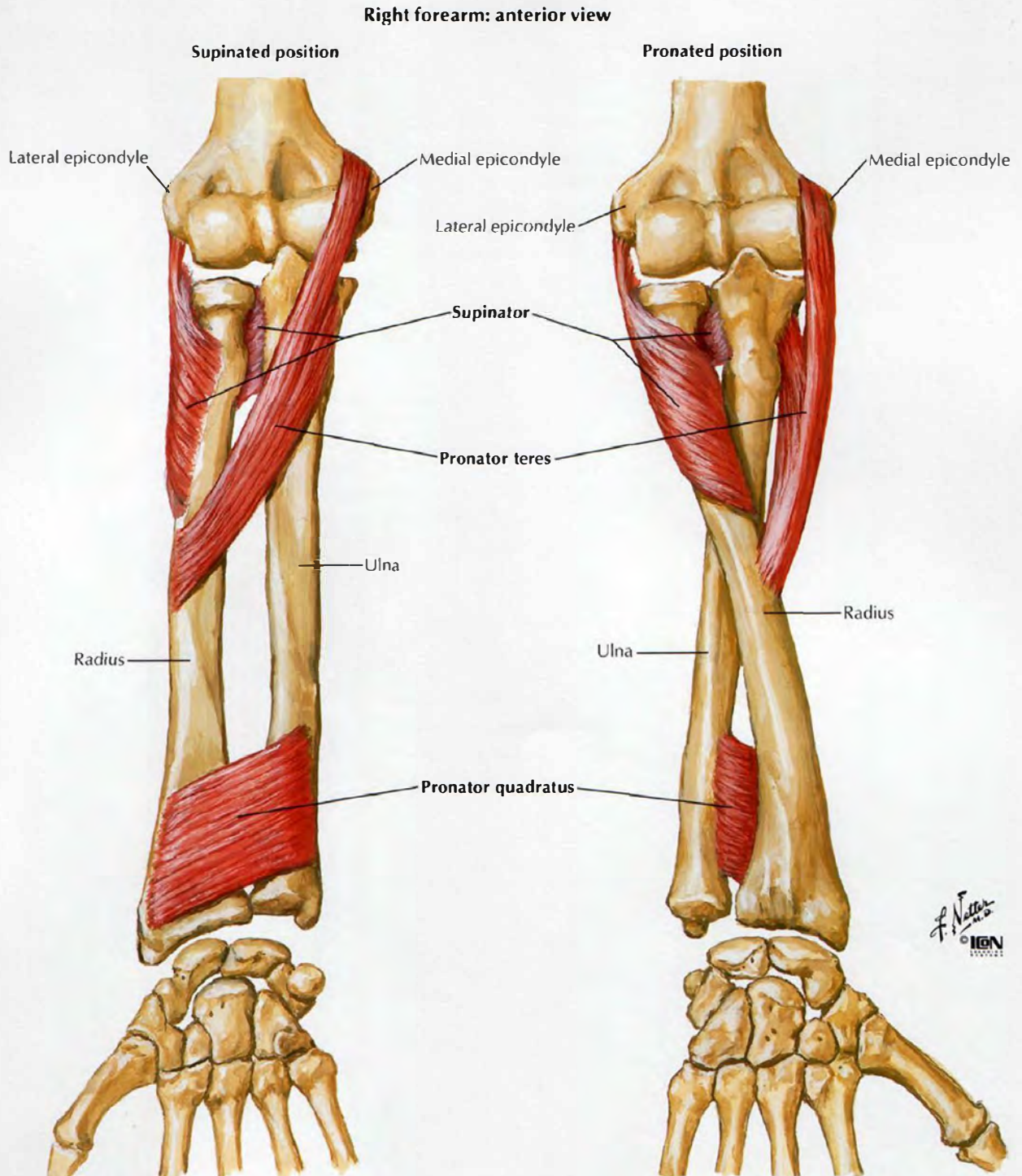
Right radius and ulna in supination: anterior view

Right radius and ulna in pronation: anterior view

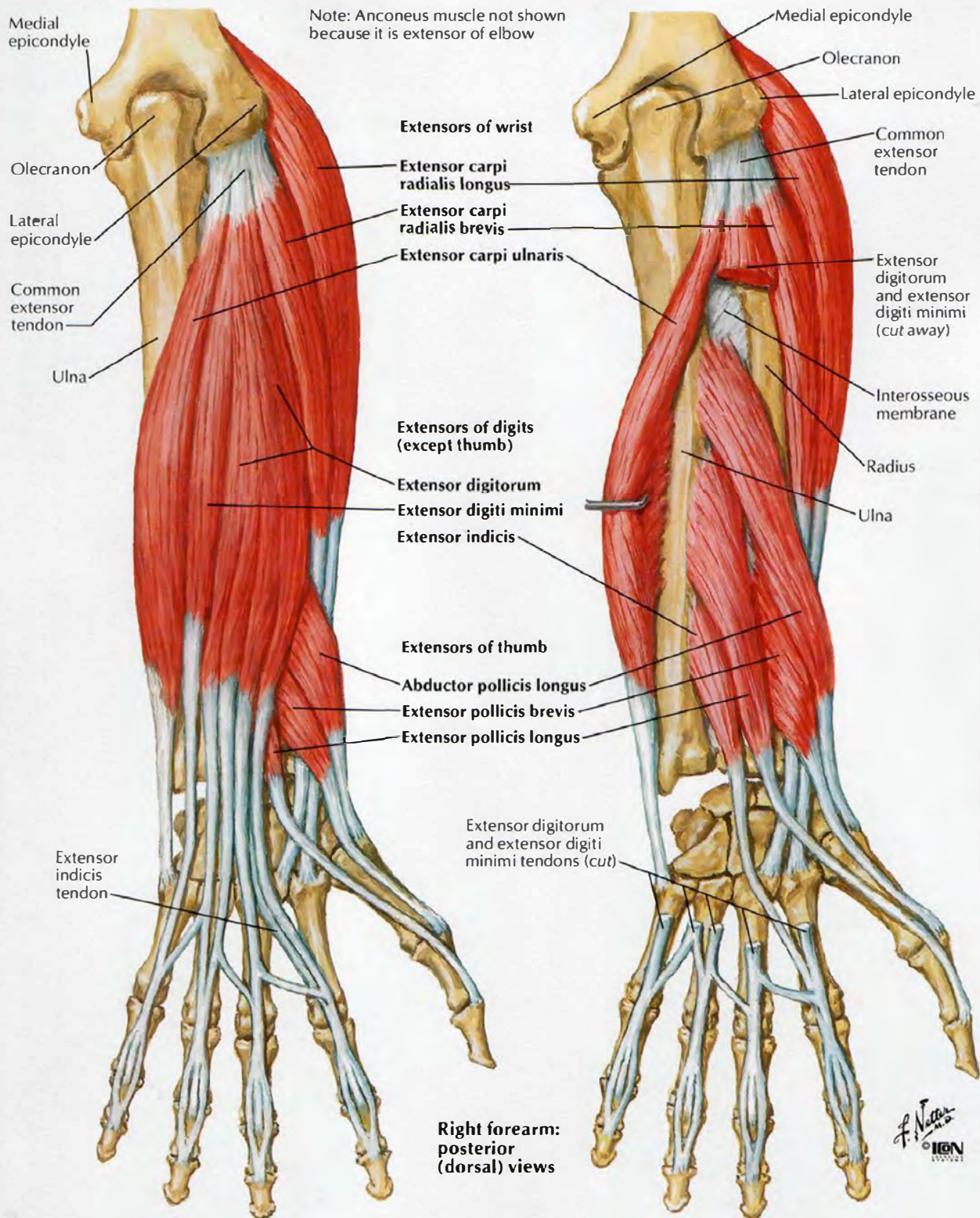


F. Netter M.D.
© ICGN

Individual Muscles of Forearm: Rotators of Radius

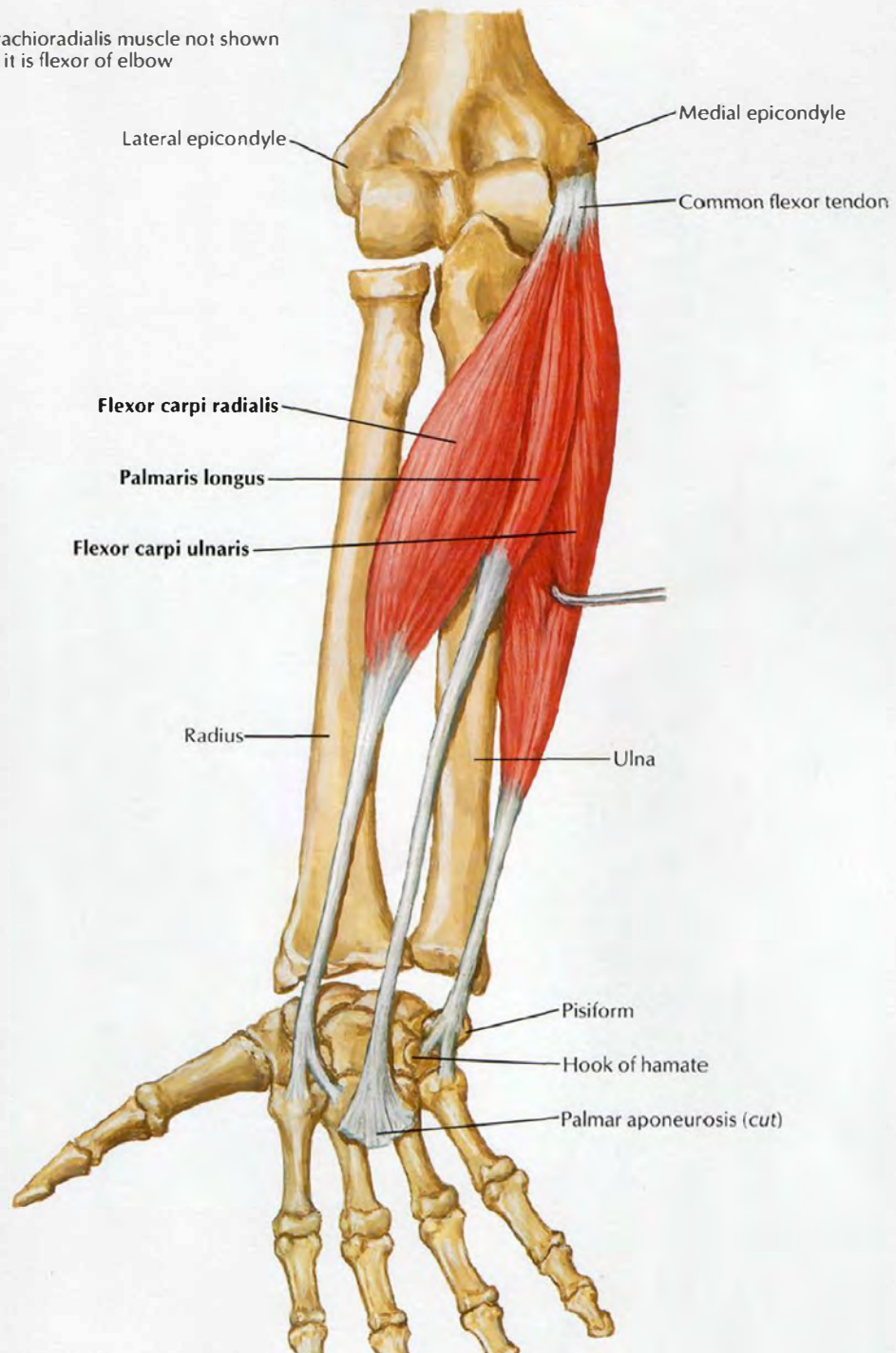


Individual Muscles of Forearm: Extensors of Wrist and Digits



Individual Muscles of Forearm: Flexors of Wrist

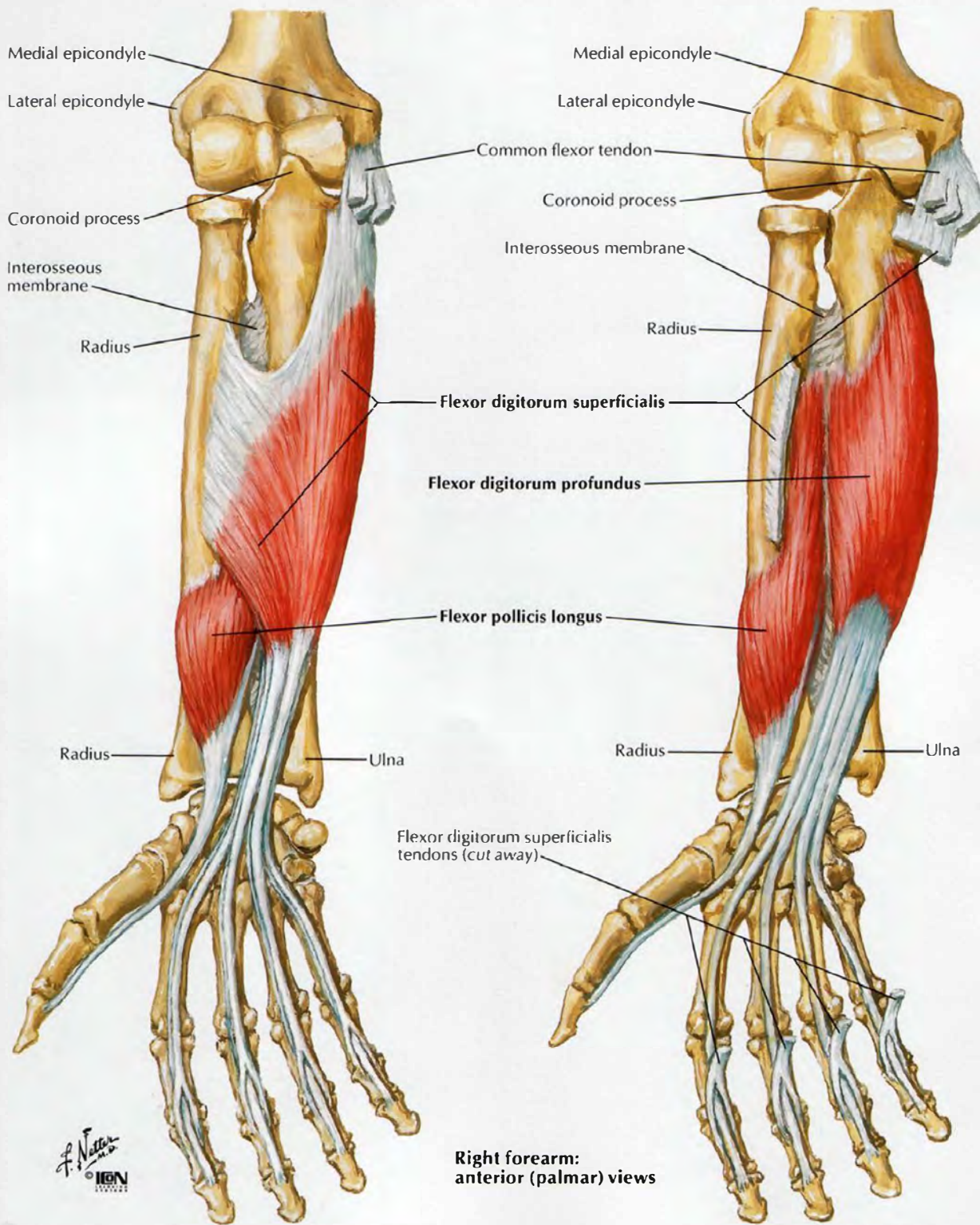
Note: Brachioradialis muscle not shown because it is flexor of elbow



Right forearm:
anterior (palmar) view

F. Netter M.D.
© IGM

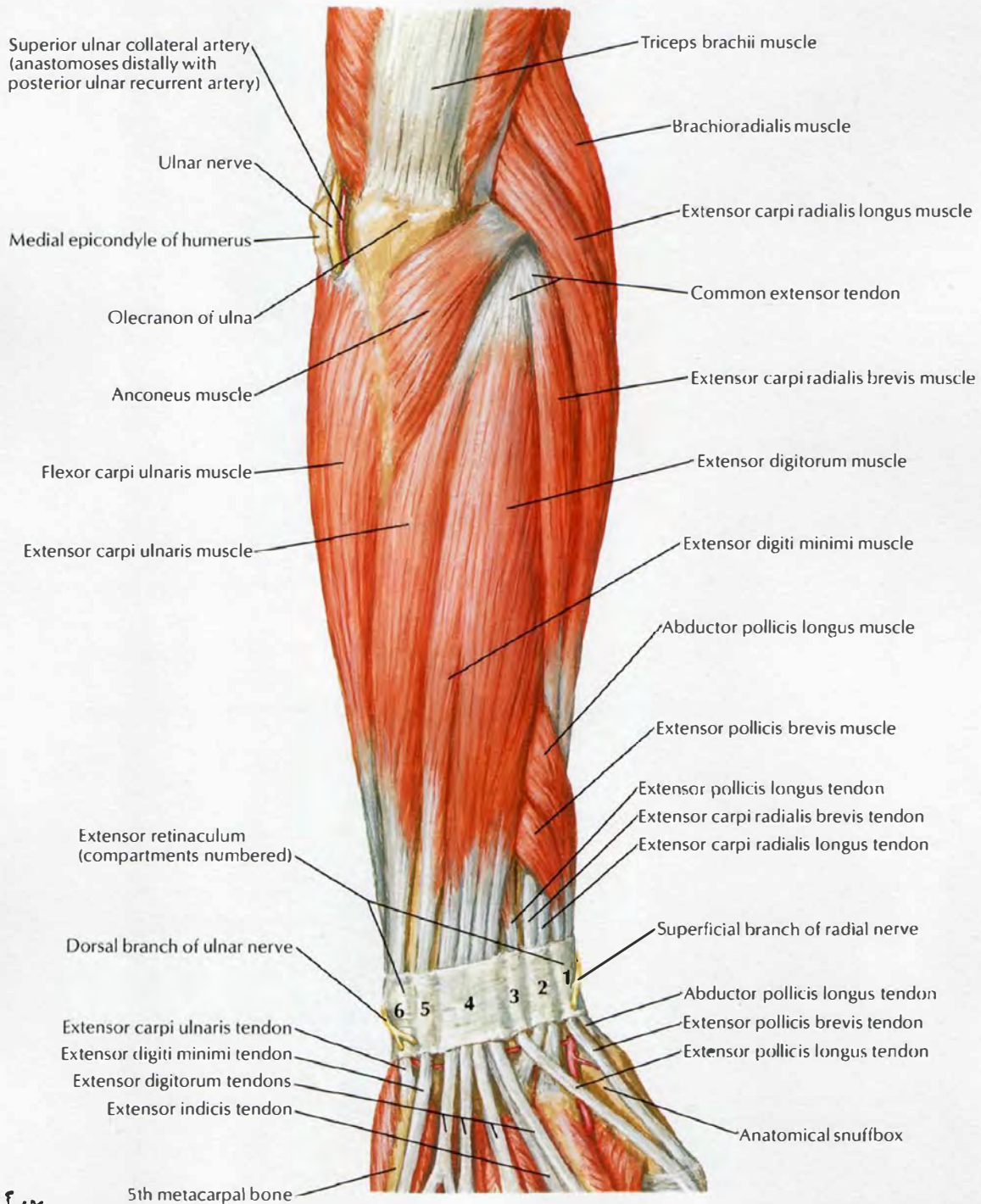
Individual Muscles of Forearm: Flexors of Digits



Right forearm:
anterior (palmar) views

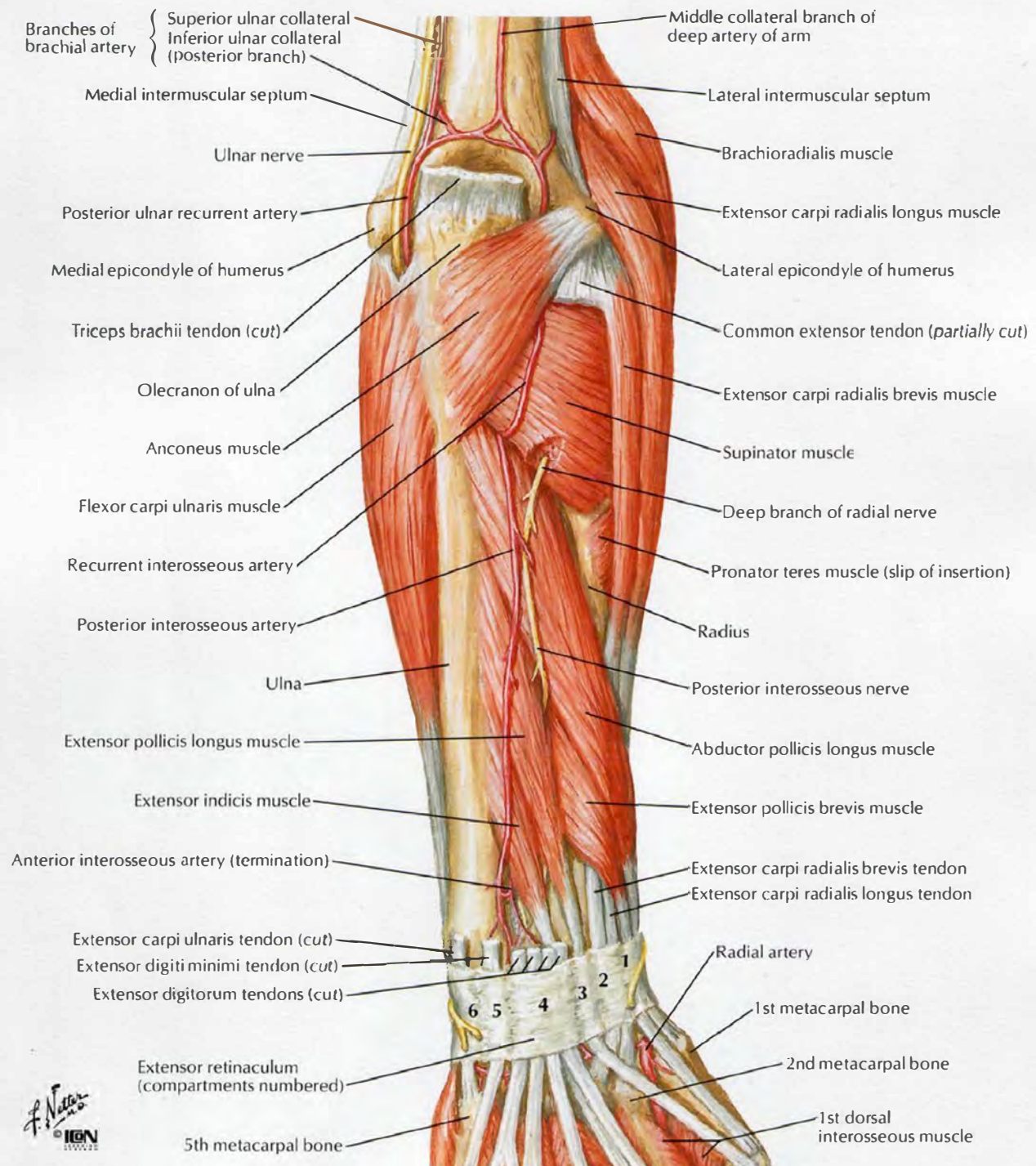
Muscles of Forearm (Superficial Layer): Posterior View

SEE ALSO PLATES 453, 461



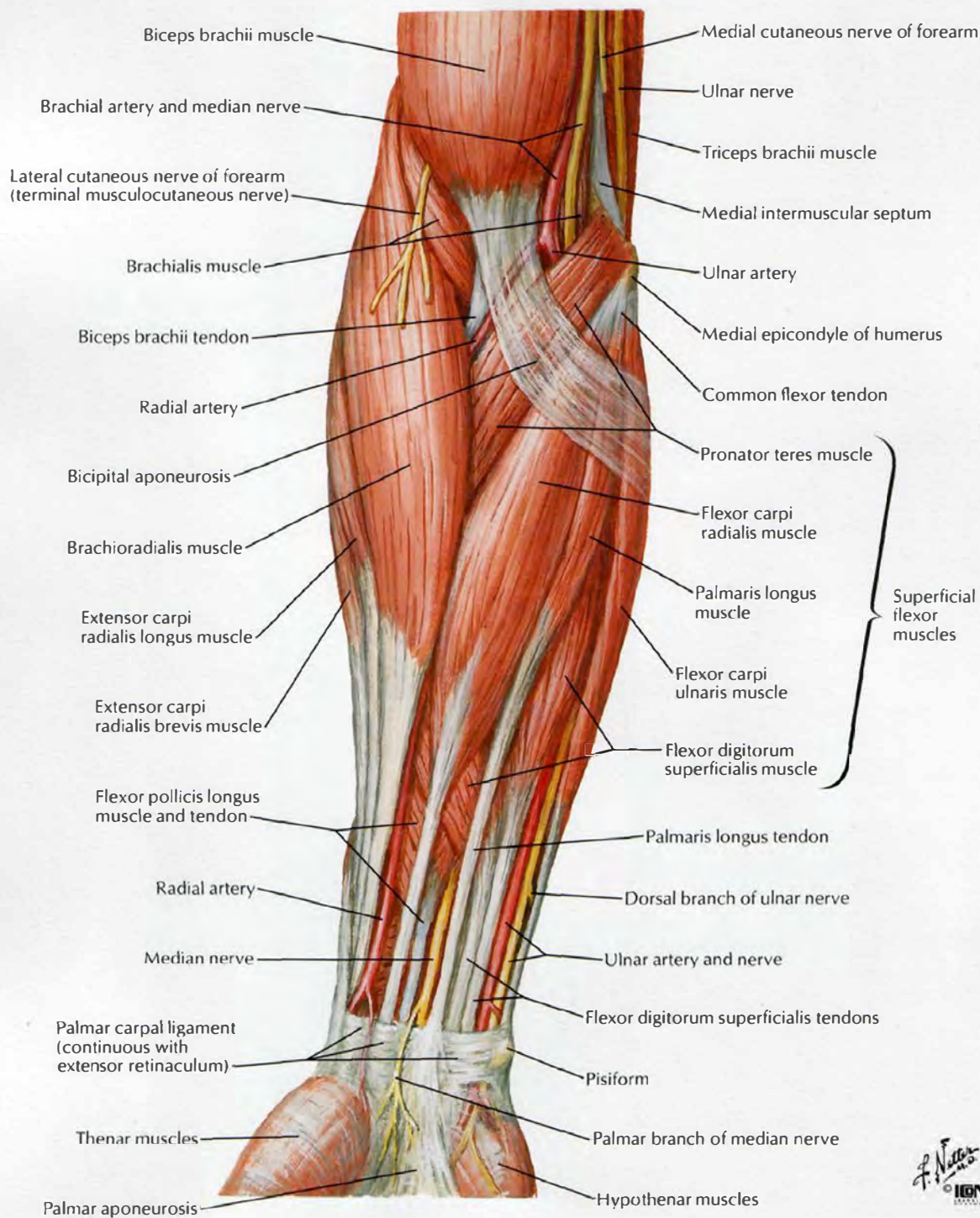
Muscles of Forearm (Deep Layer): Posterior View

SEE ALSO PLATES 453, 461



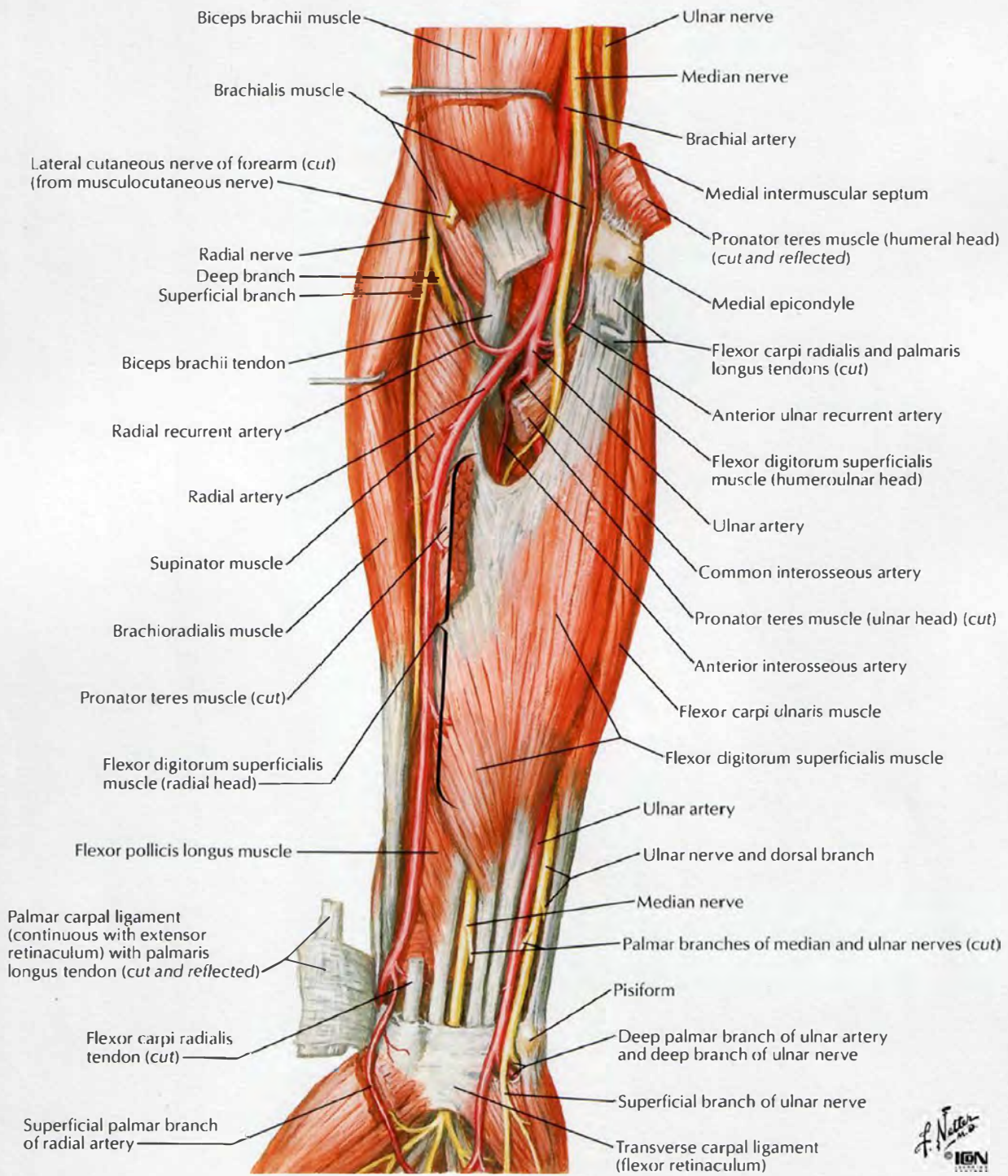
Muscles of Forearm (Superficial Layer): Anterior View

SEE ALSO PLATES 458, 459



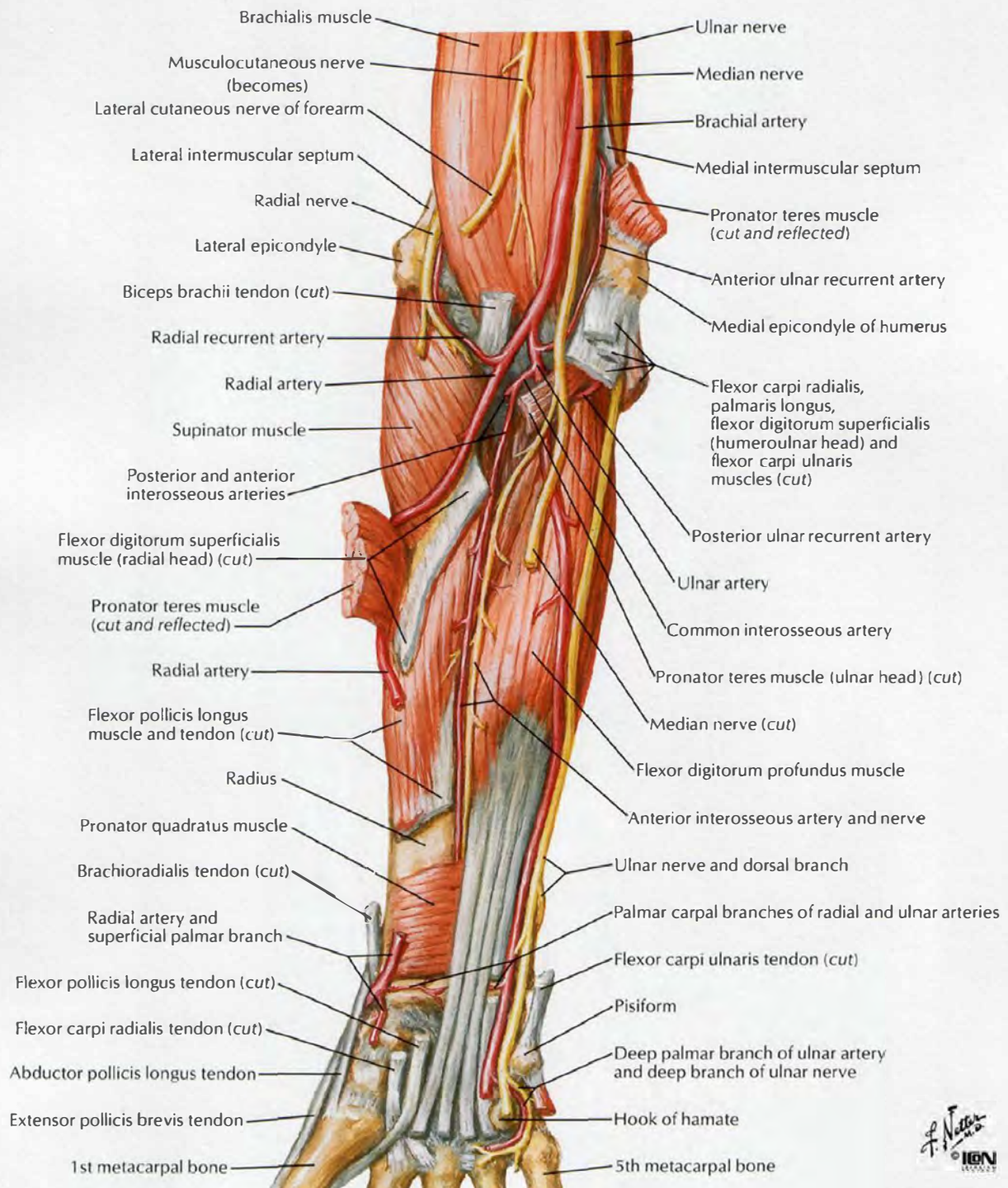
Muscles of Forearm (Intermediate Layer): Anterior View

SEE ALSO PLATES 458, 459

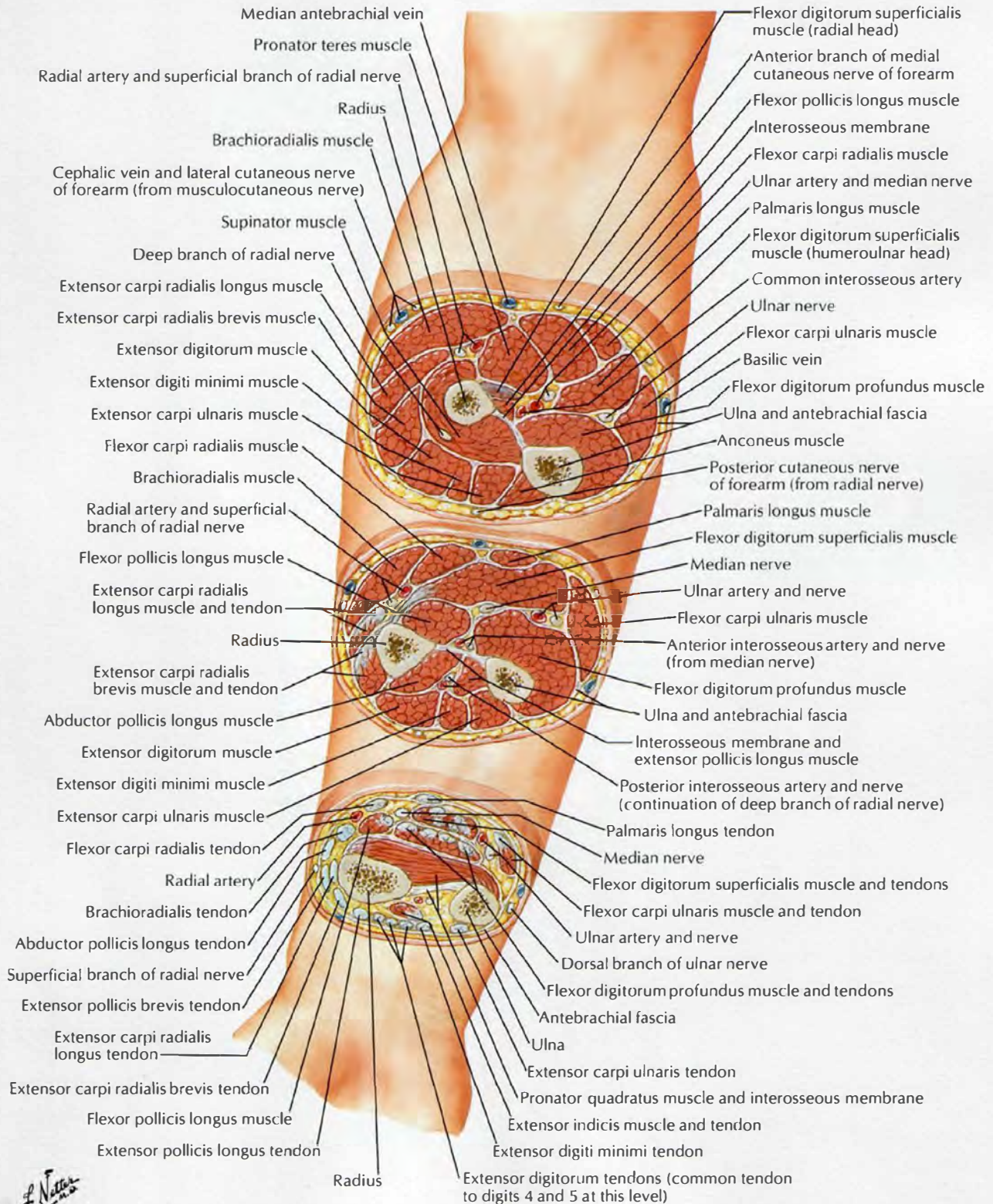


Muscles of Forearm (Deep Layer): Anterior View

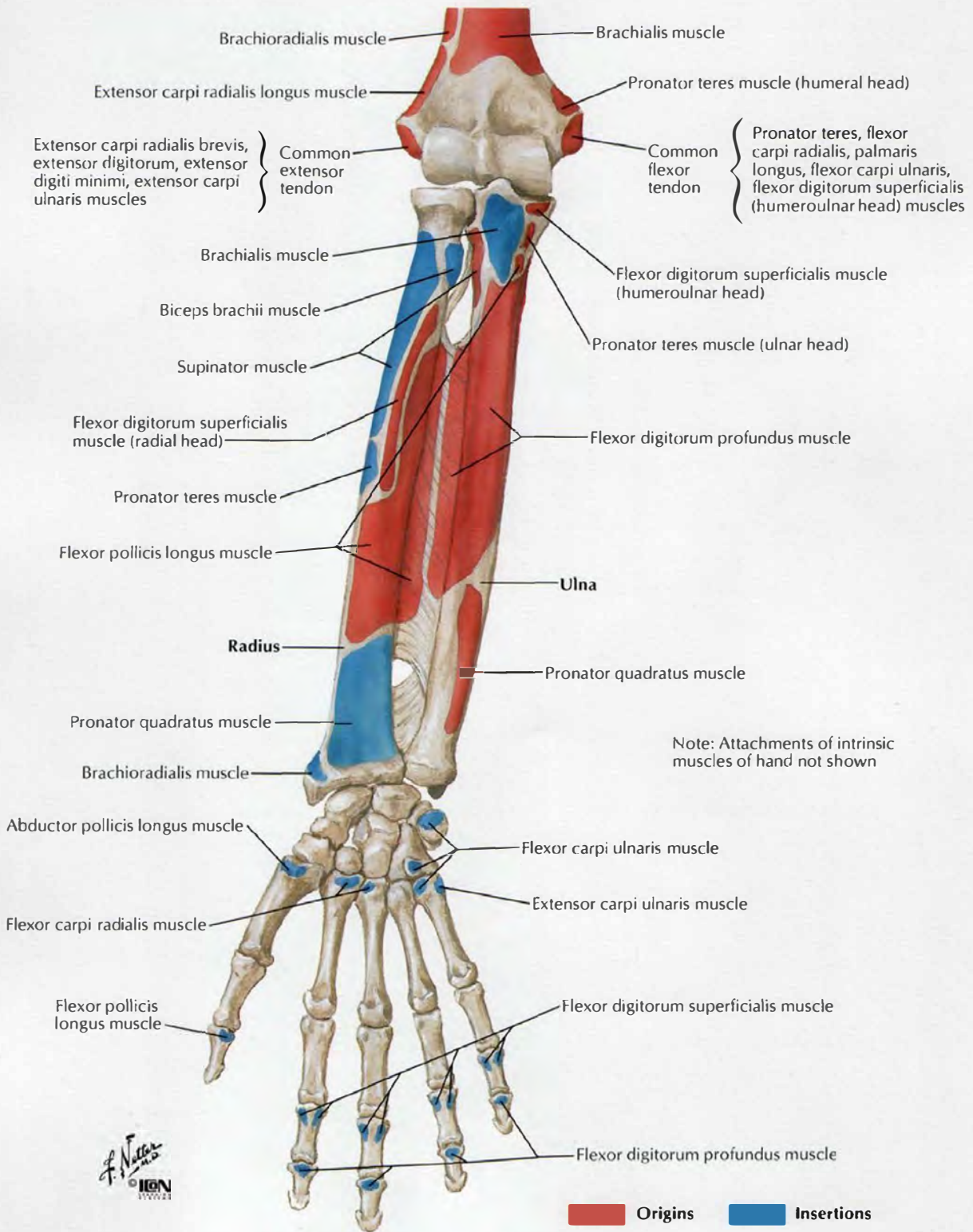
SEE ALSO PLATES 458, 459



Forearm: Serial Cross Sections

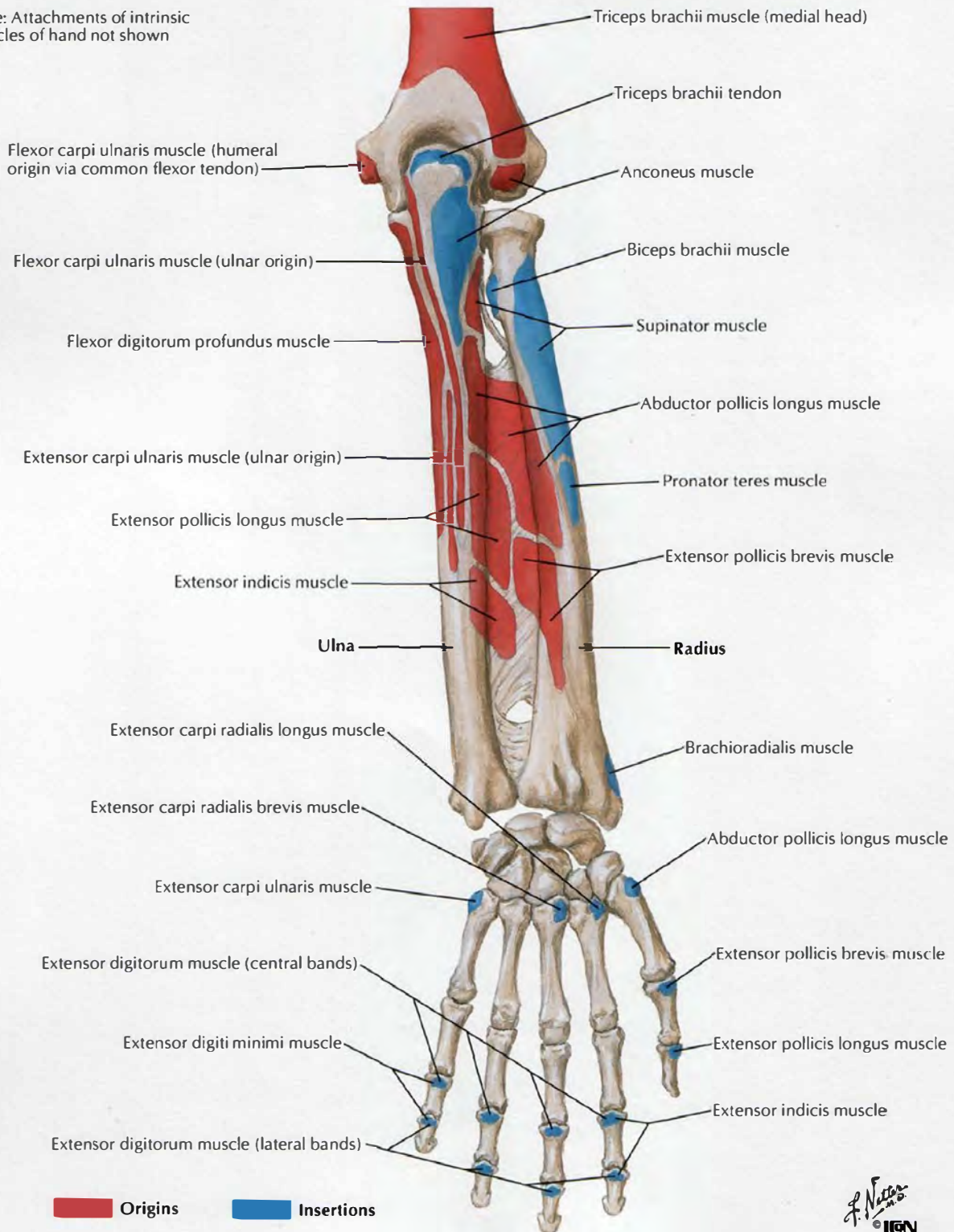


Attachments of Muscles of Forearm: Anterior View

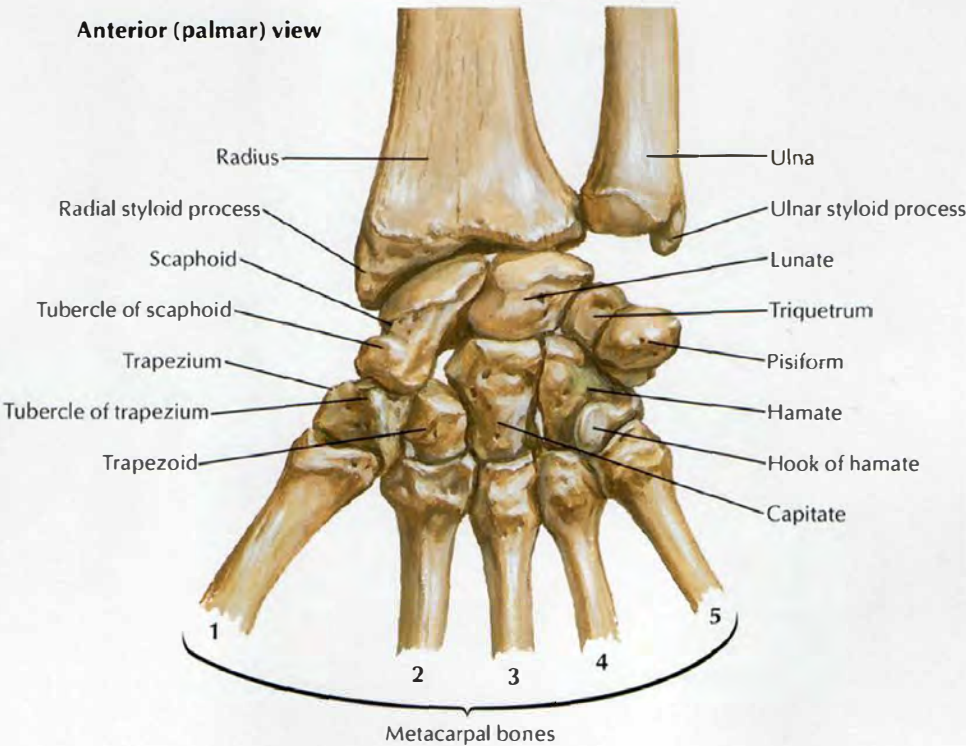


Attachments of Muscles of Forearm: Posterior View

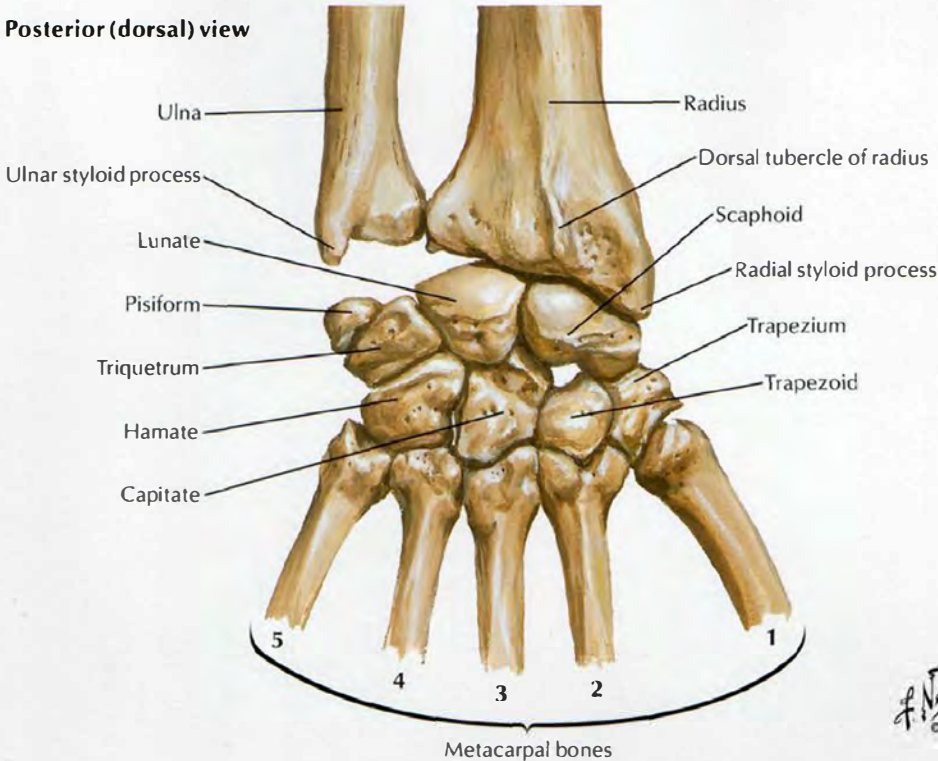
Note: Attachments of intrinsic muscles of hand not shown



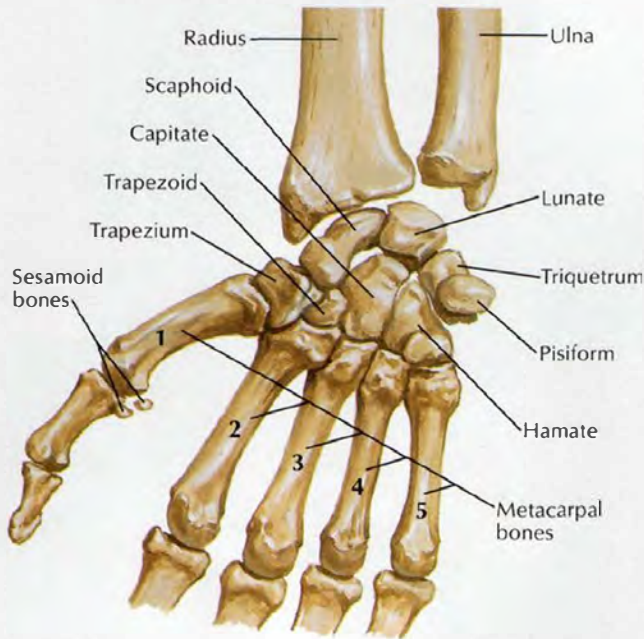
Anterior (palmar) view



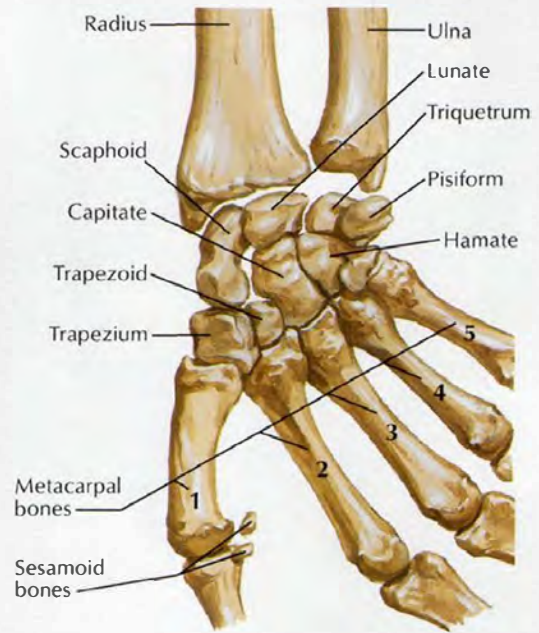Posterior (dorsal) view



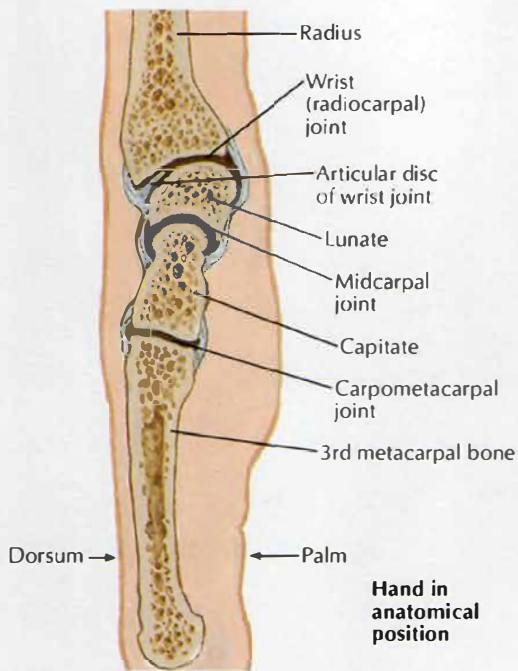
Movements of Wrist



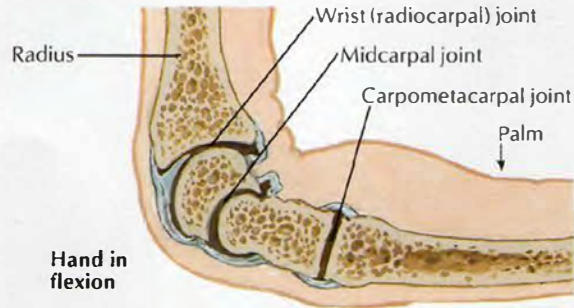
Position of carpal bones with hand in abduction: anterior (palmar) view



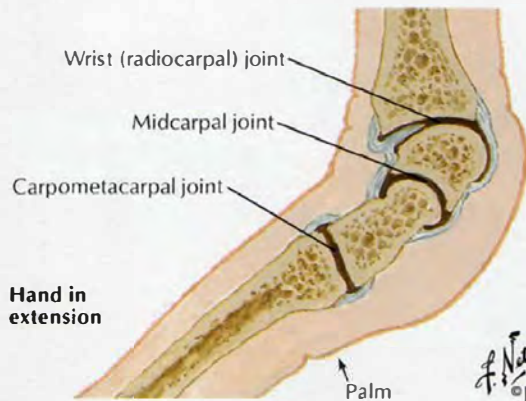
Position of carpal bones with hand in adduction: anterior (palmar) view



Sagittal sections through wrist and middle finger

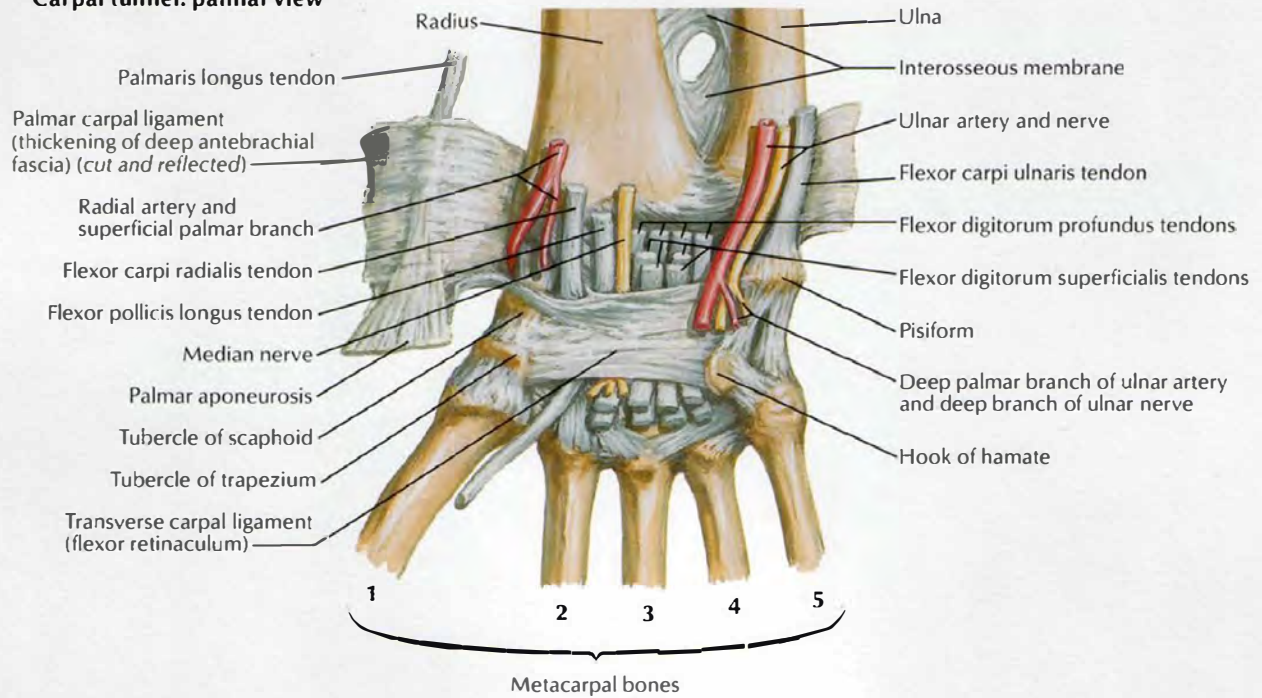


Hand in flexion

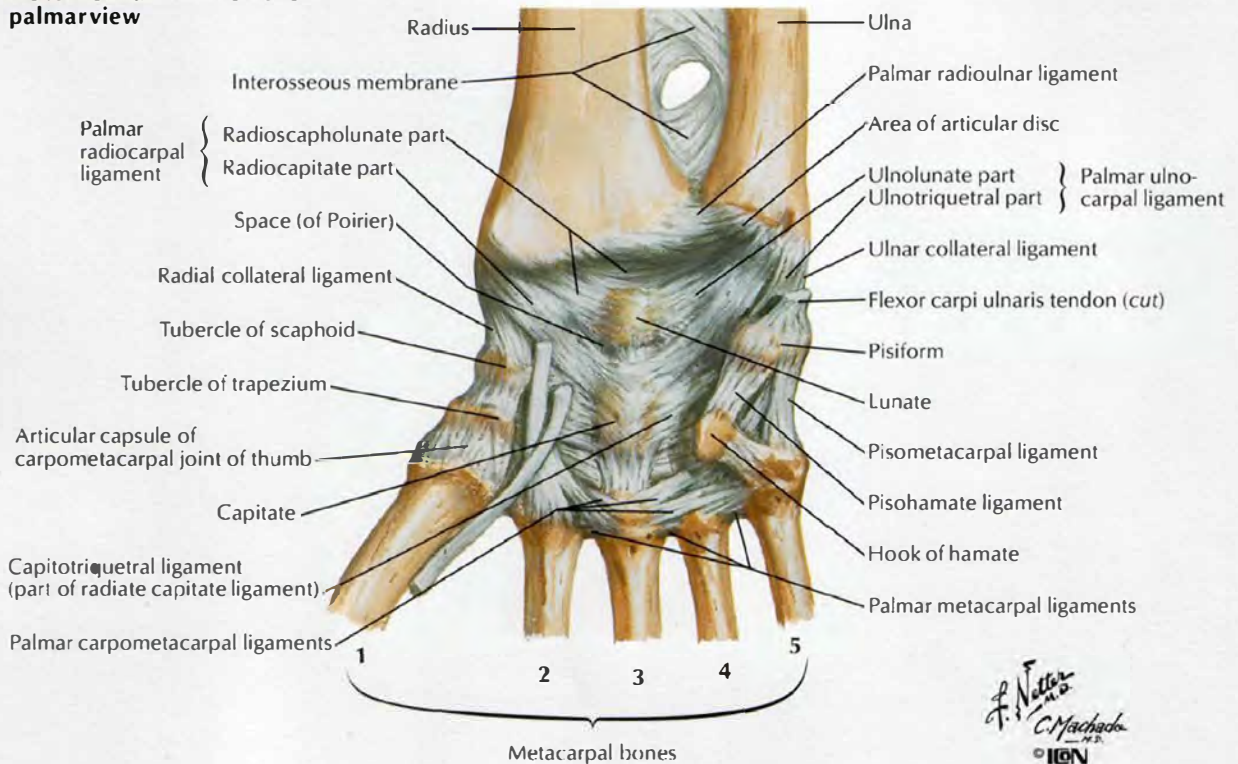


Hand in extension

Carpal tunnel: palmar view

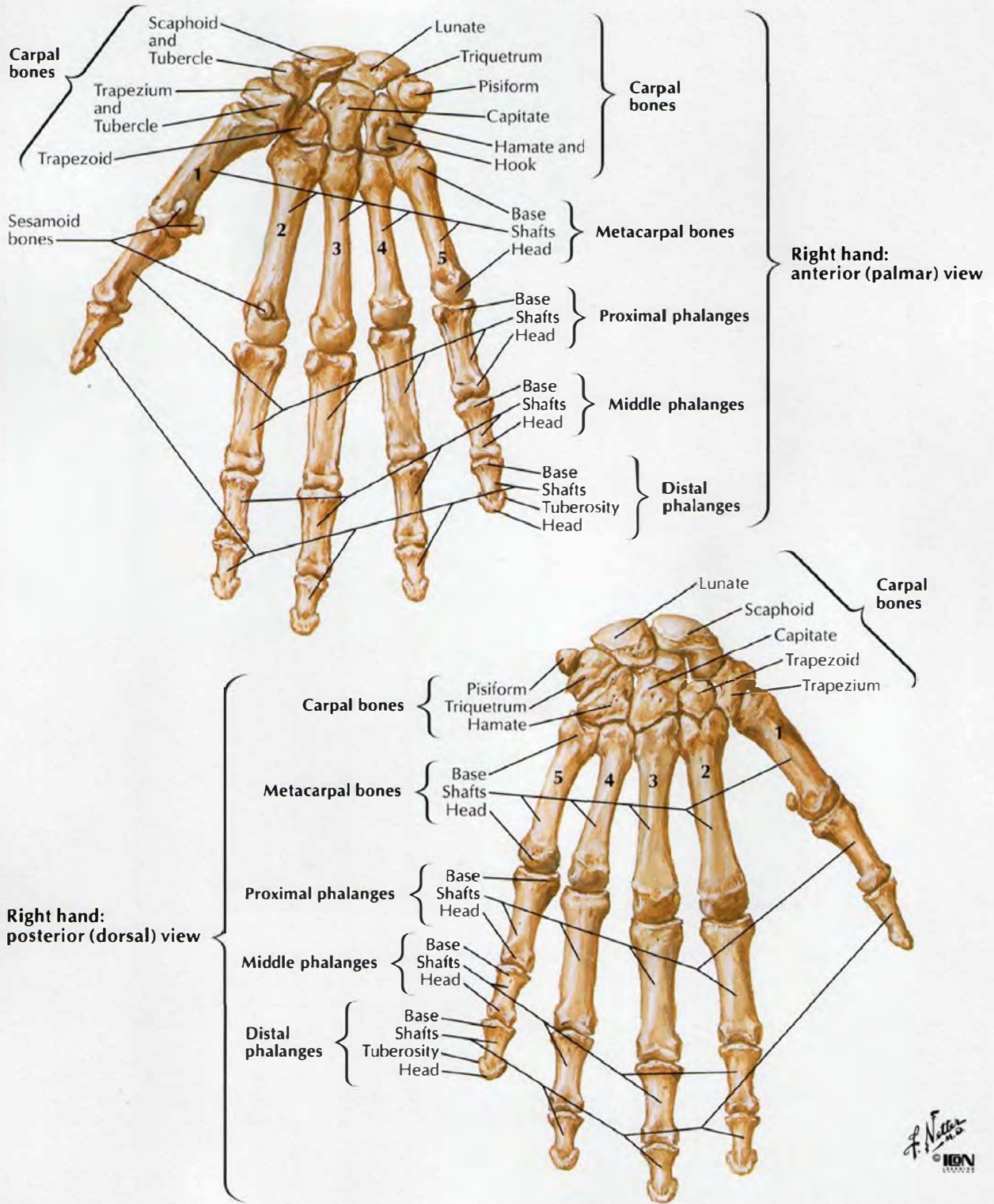


Flexor retinaculum removed: palmar view



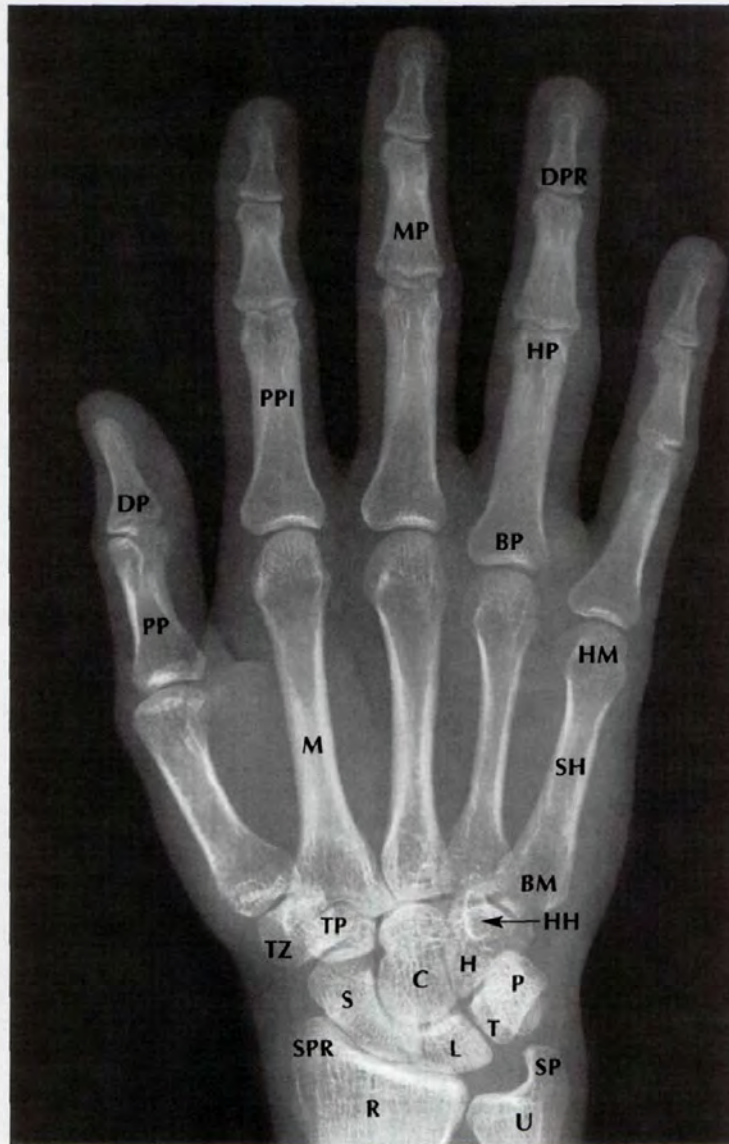F. Netto
C. Machado
 ION

Bones of Wrist and Hand



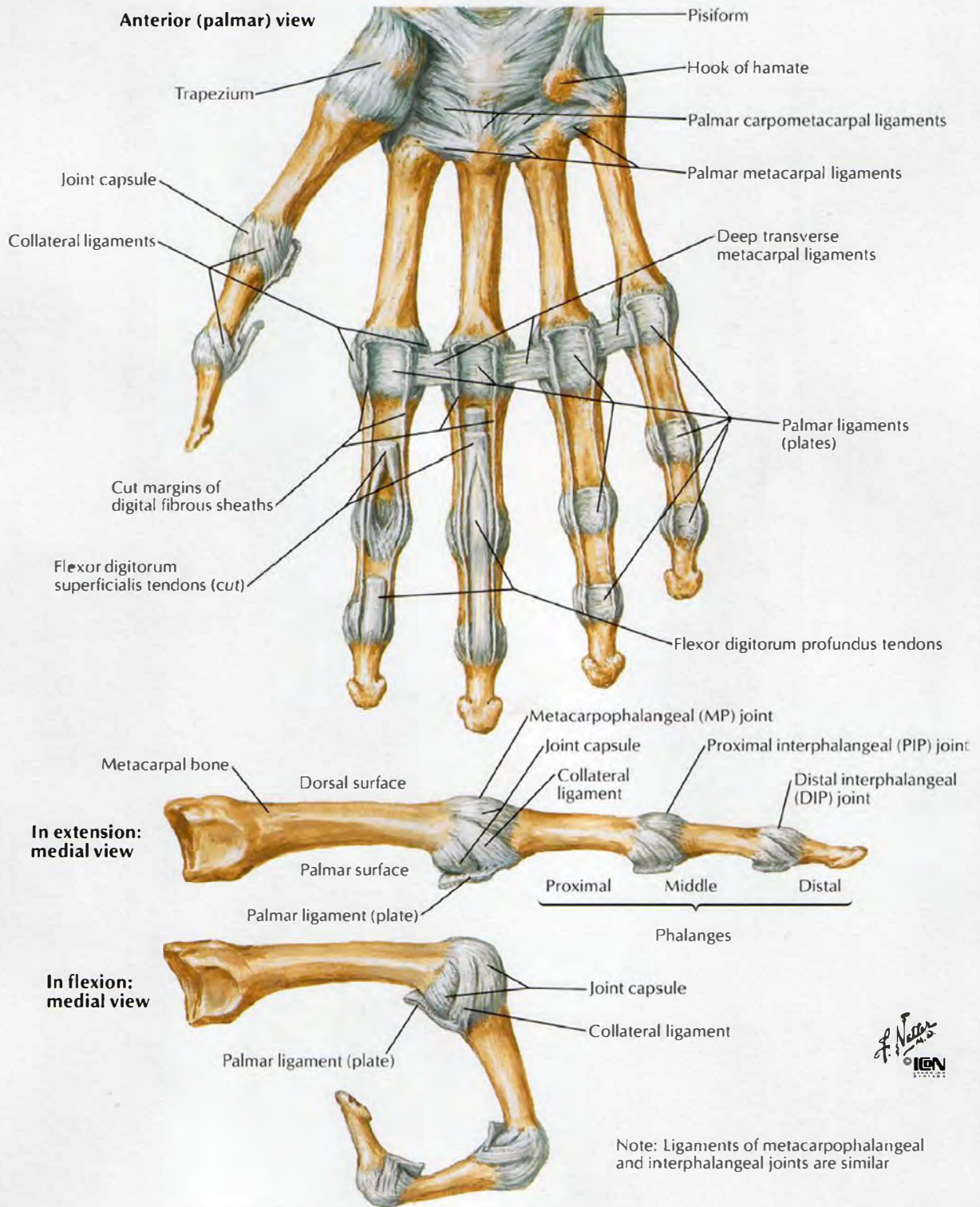
Wrist and Hand: Anteroposterior Radiograph

SEE ALSO PLATE 439

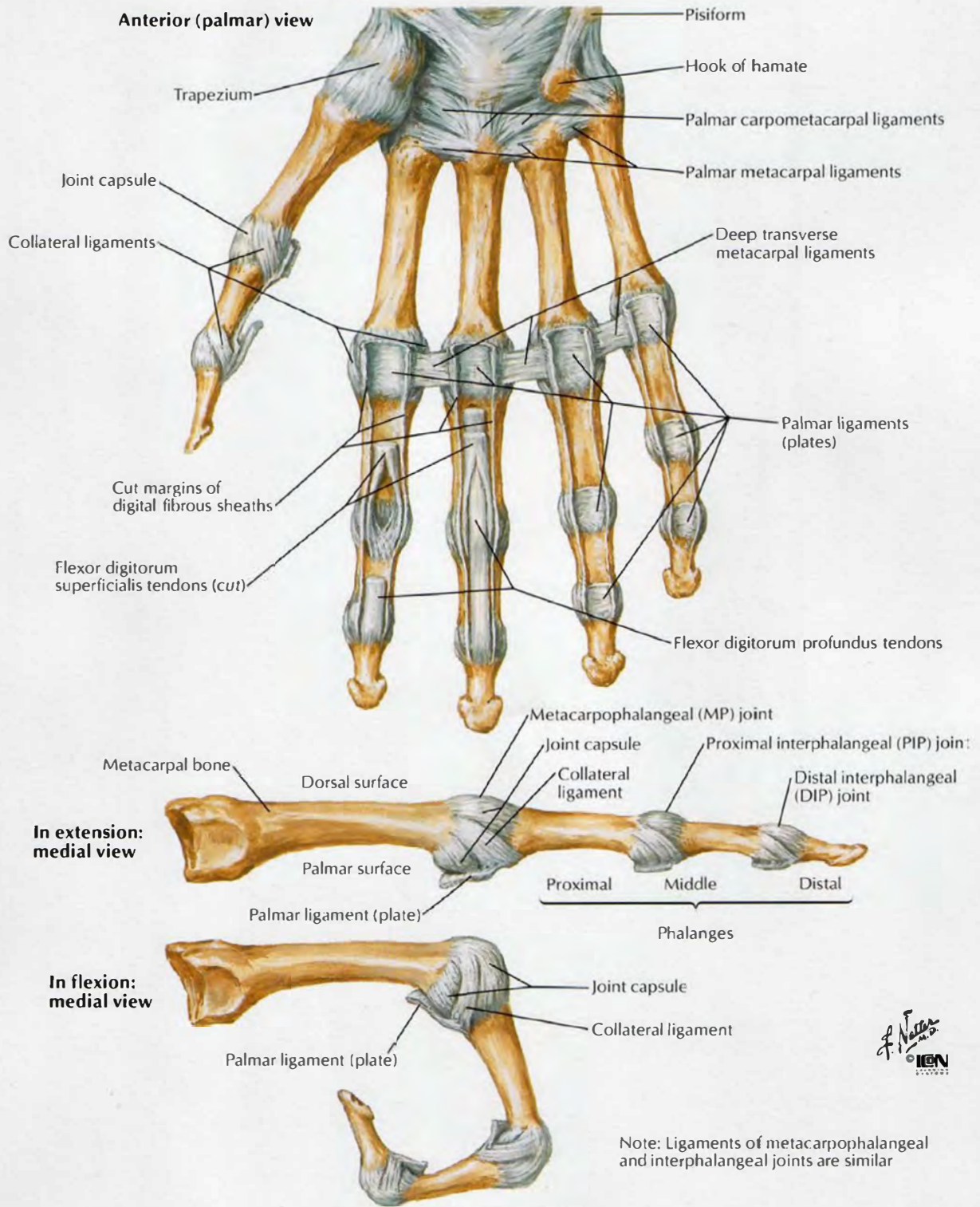


- | | | | |
|------------|---------------------------------|------------|----------------------------------|
| BM | Base of 5th metacarpal | P | Pisiform |
| BP | Base of 4th proximal phalanx | PP | Proximal phalanx of thumb |
| C | Capitate | PPI | Proximal phalanx of index finger |
| DP | Distal phalanx of thumb | R | Radius |
| DPR | Distal phalanx of ring finger | S | Scaphoid |
| H | Hamate | SH | Shaft of 5th metacarpal |
| HH | Hook of hamate | SP | Styloid process of ulna |
| HM | Head of 5th metacarpal | SPR | Styloid process of radius |
| HP | Head of proximal phalanx | T | Triquetrum |
| L | Lunate | TP | Trapezoid |
| M | Metacarpal of index finger | TZ | Trapezium |
| MP | Middle phalanx of middle finger | U | Ulna |

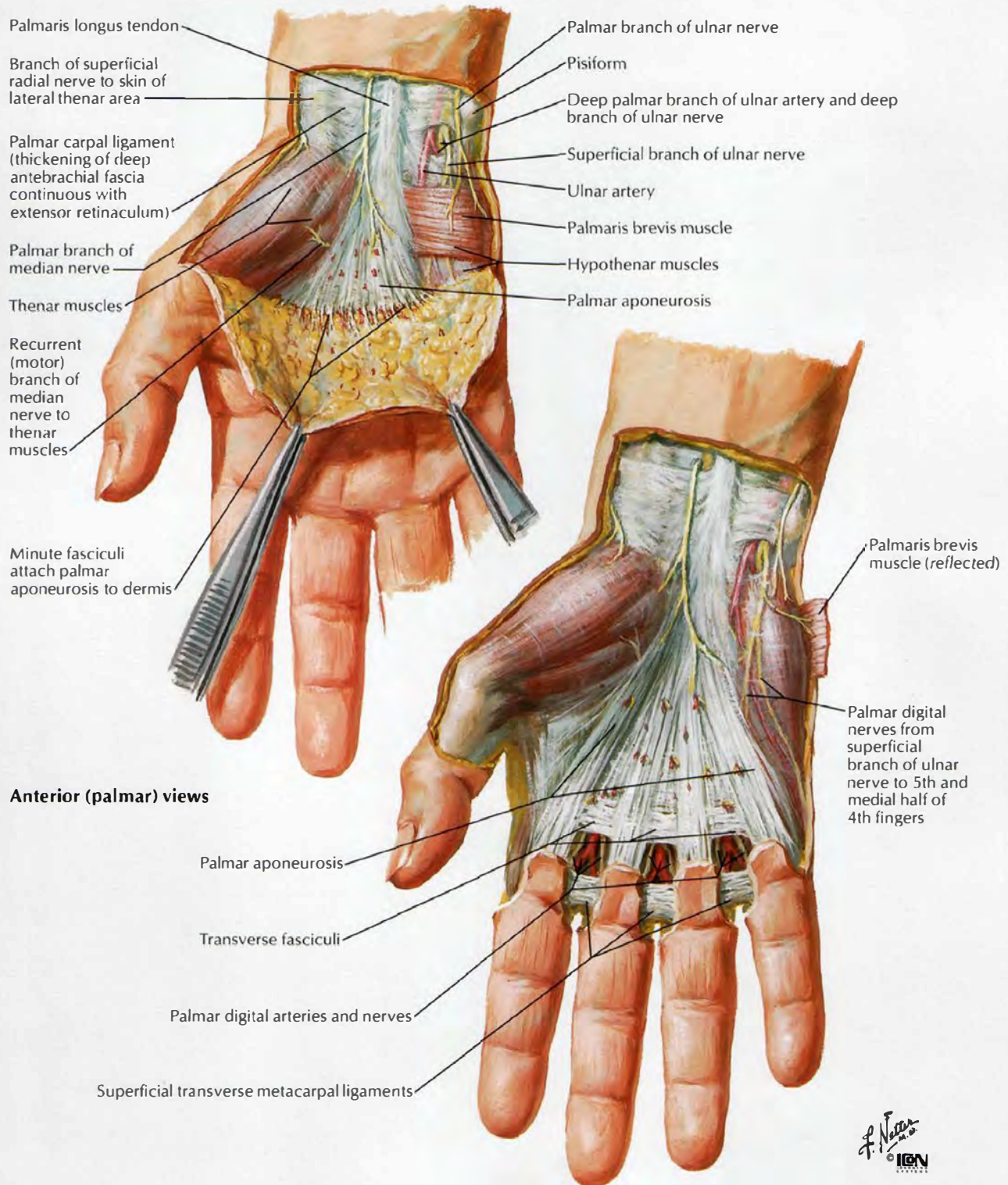
Metacarpophalangeal and Interphalangeal Ligaments



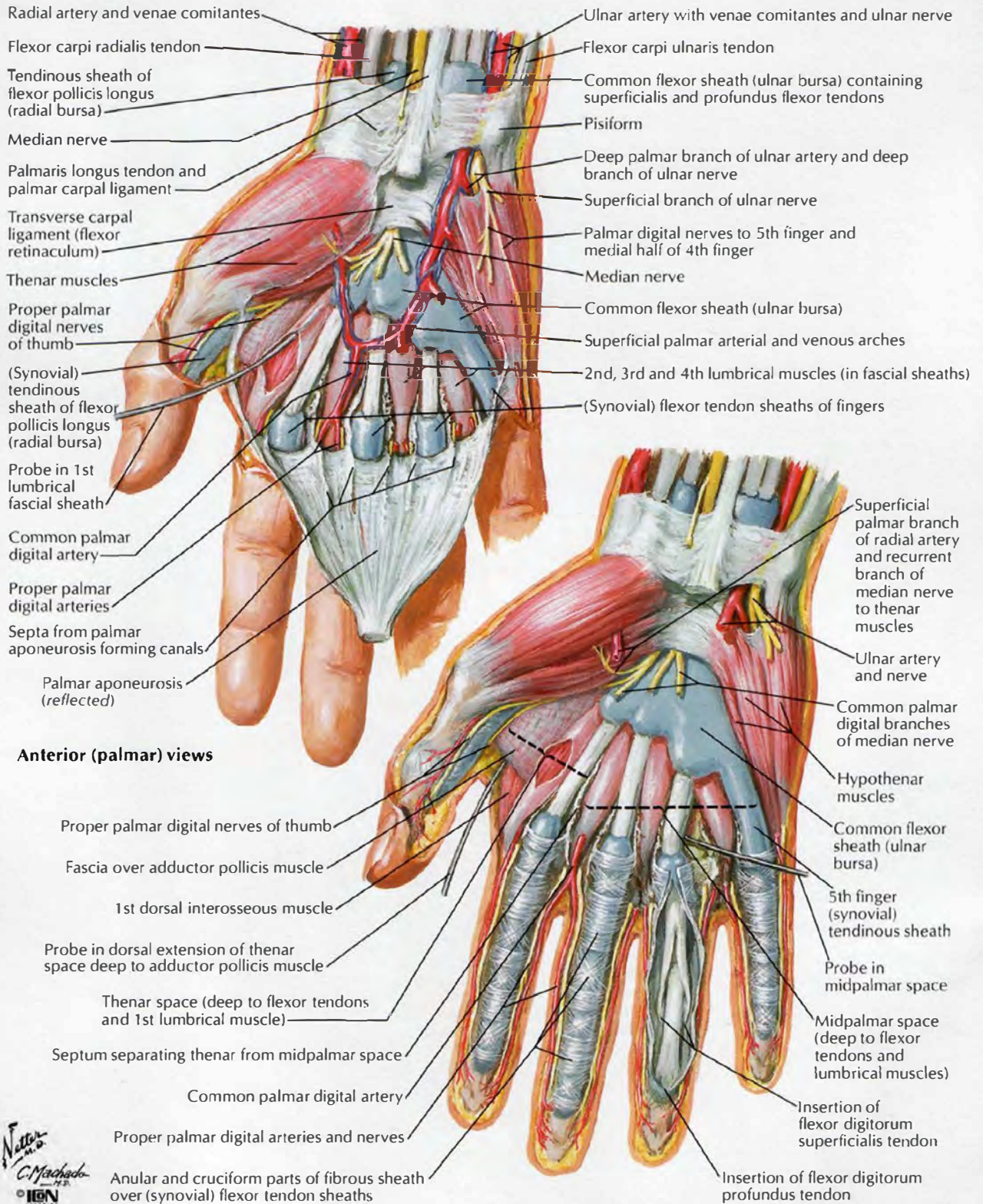
Metacarpophalangeal and Interphalangeal Ligaments



Wrist and Hand: Superficial Palmar Dissections



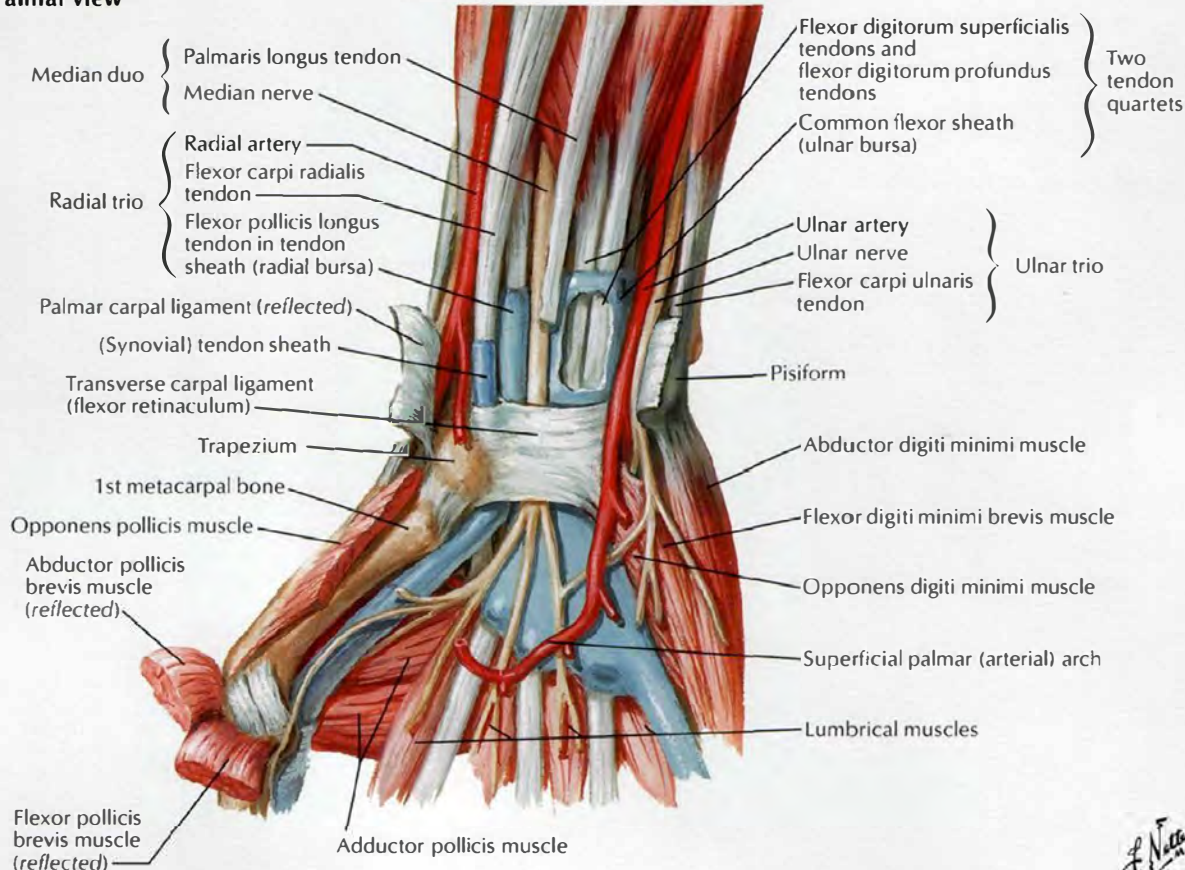
Wrist and Hand: Deeper Palmar Dissections



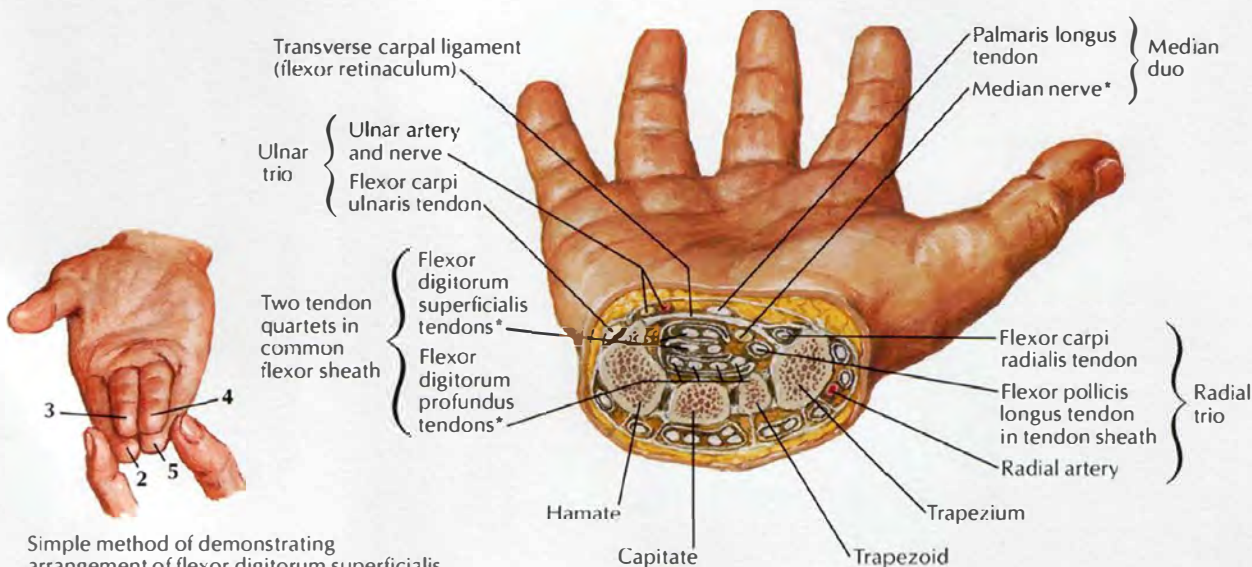
F. Netter
C. Machado
© IGM

Flexor Tendons, Arteries and Nerves at Wrist

Palmar view



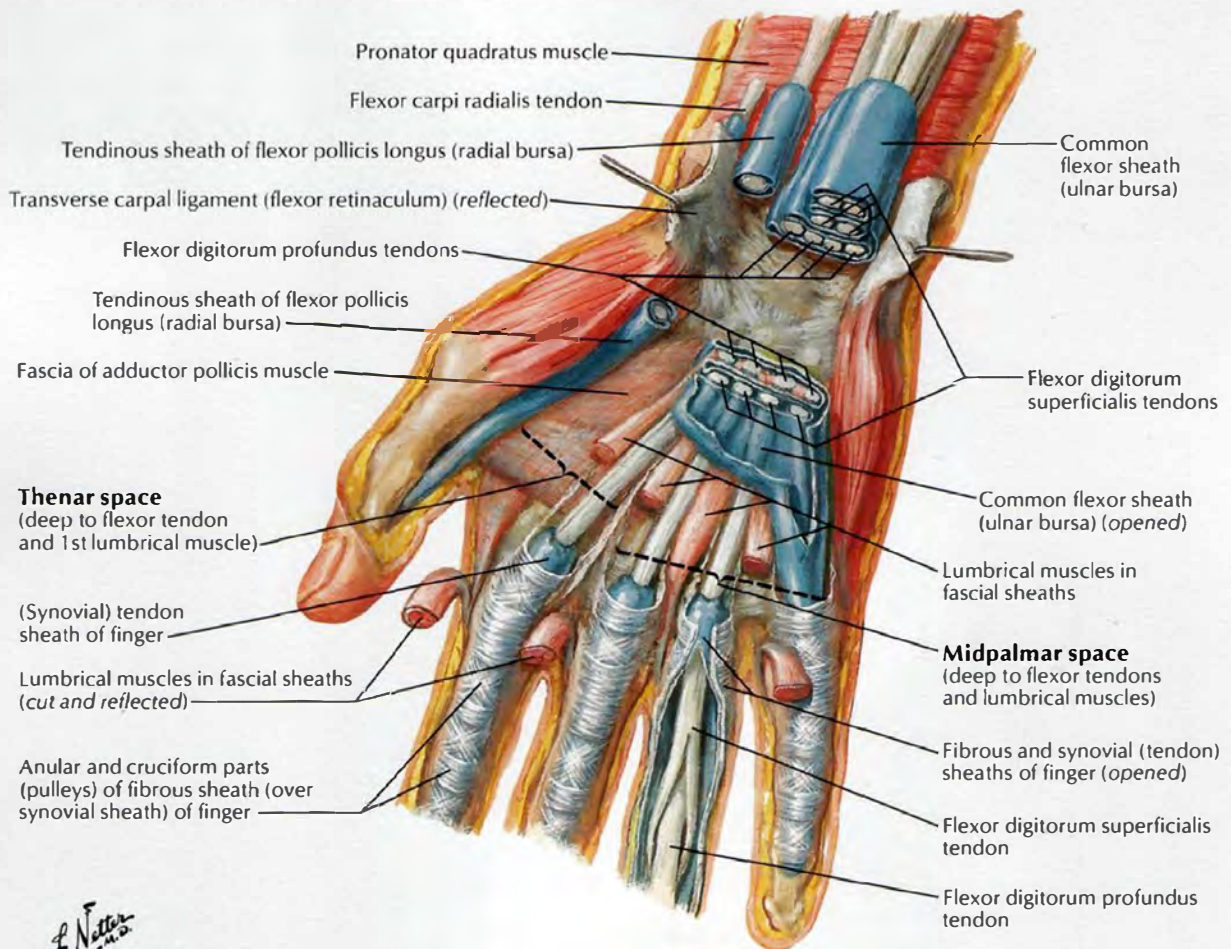
Transverse cross section of wrist demonstrating carpal tunnel



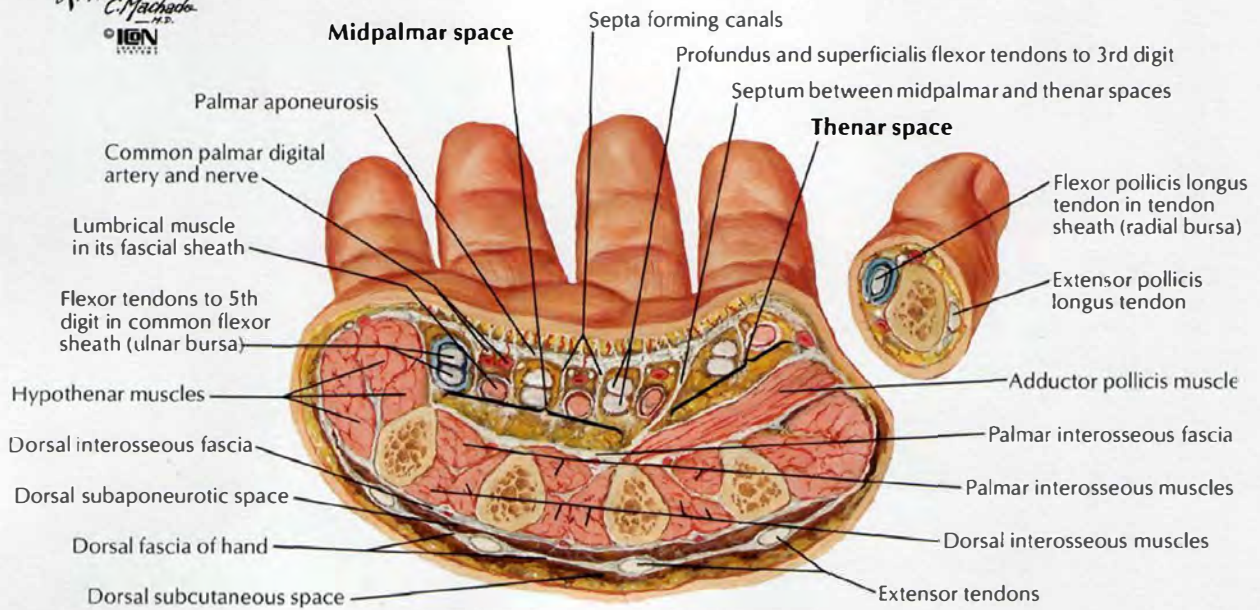
Simple method of demonstrating arrangement of flexor digitorum superficialis tendon quartet within carpal tunnel

*Contents of carpal tunnel

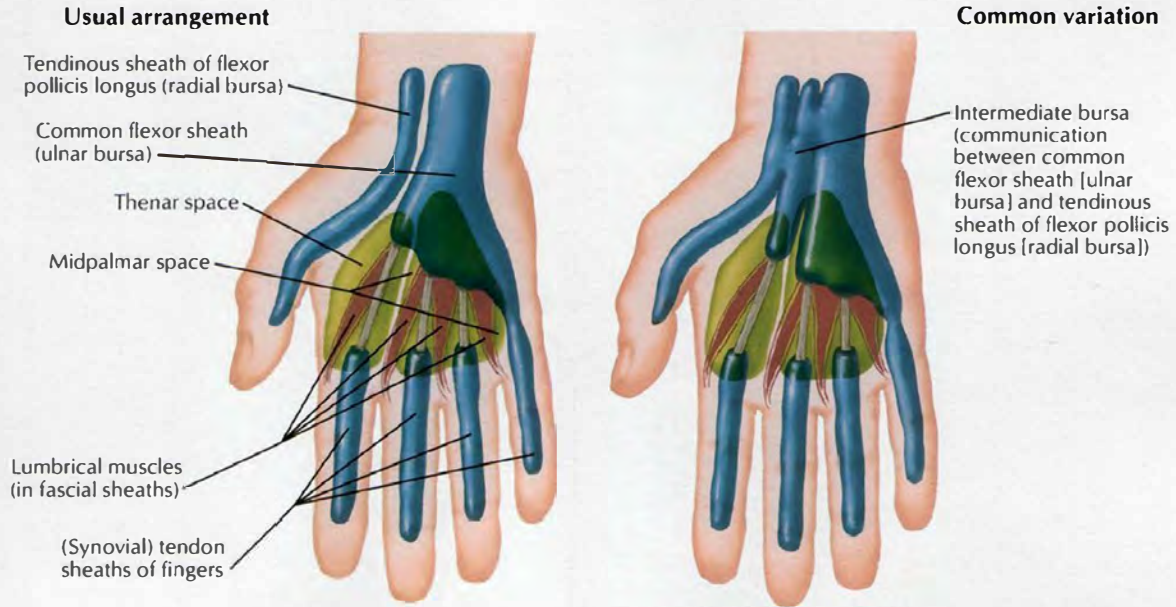
Bursae, Spaces and Tendon Sheaths of Hand



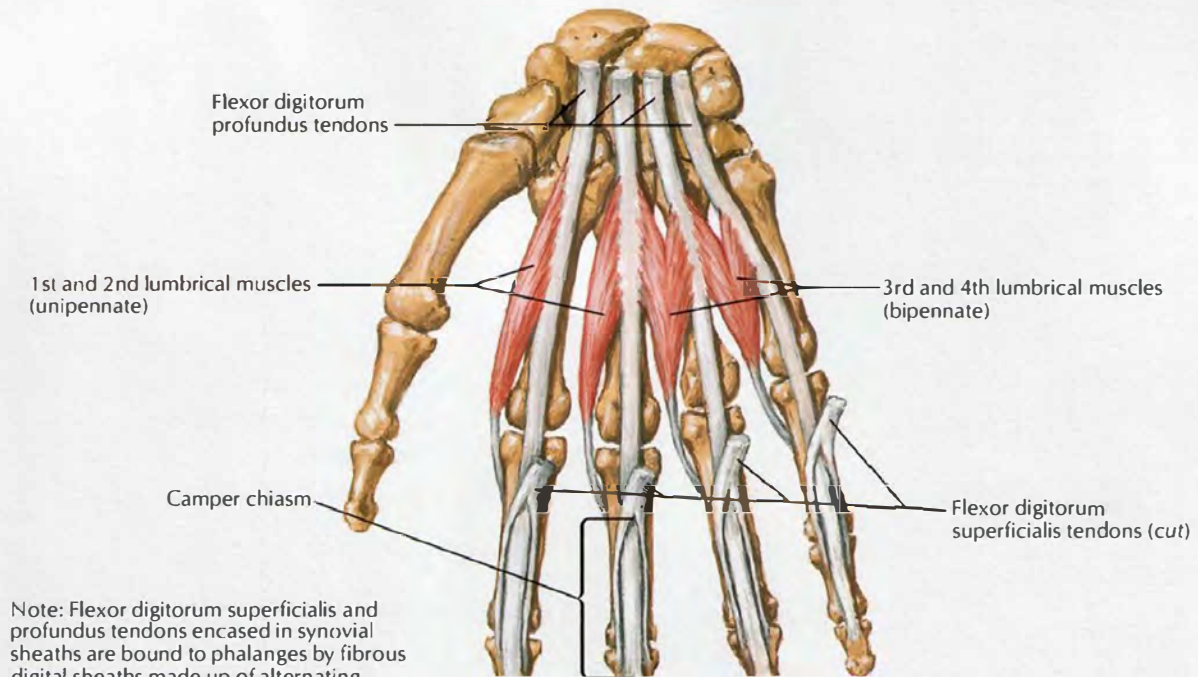
F. Netto
C. Machado
IGN



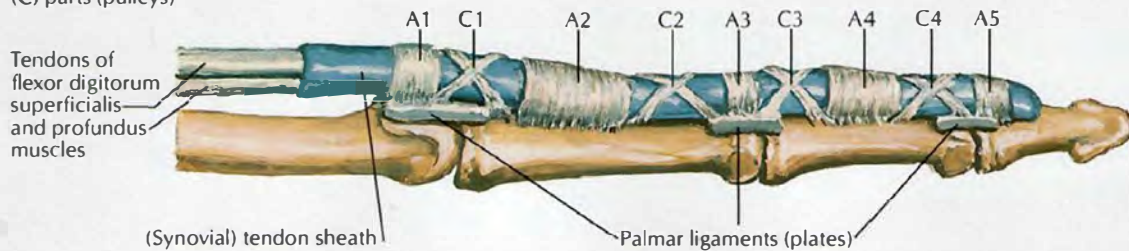
Lumbrical Muscles and Bursae, Spaces and Sheaths: Schema



Lumbrical muscles: schema

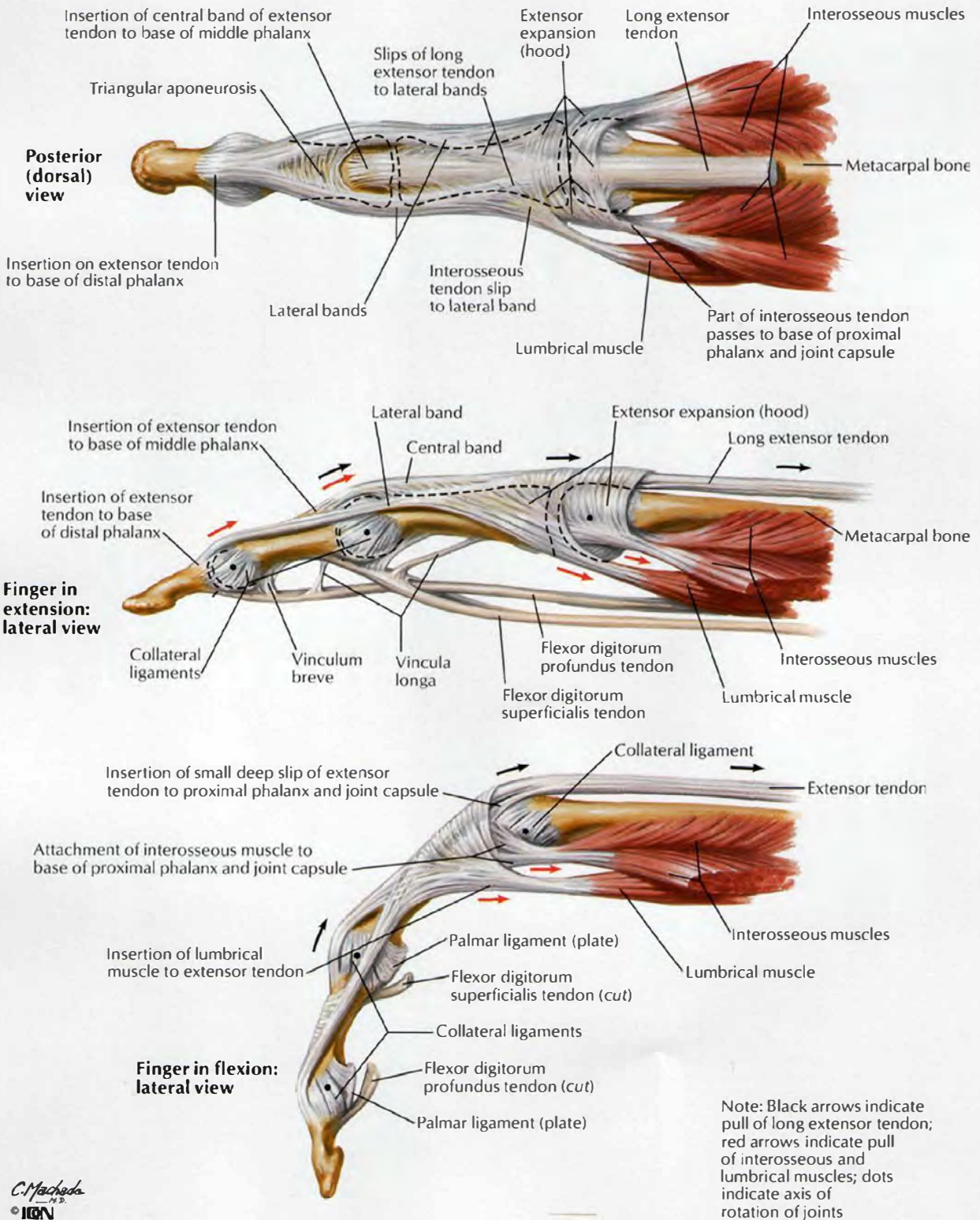


Note: Flexor digitorum superficialis and profundus tendons encased in synovial sheaths are bound to phalanges by fibrous digital sheaths made up of alternating strong annular (A) and weaker cruciform (C) parts (pulleys)



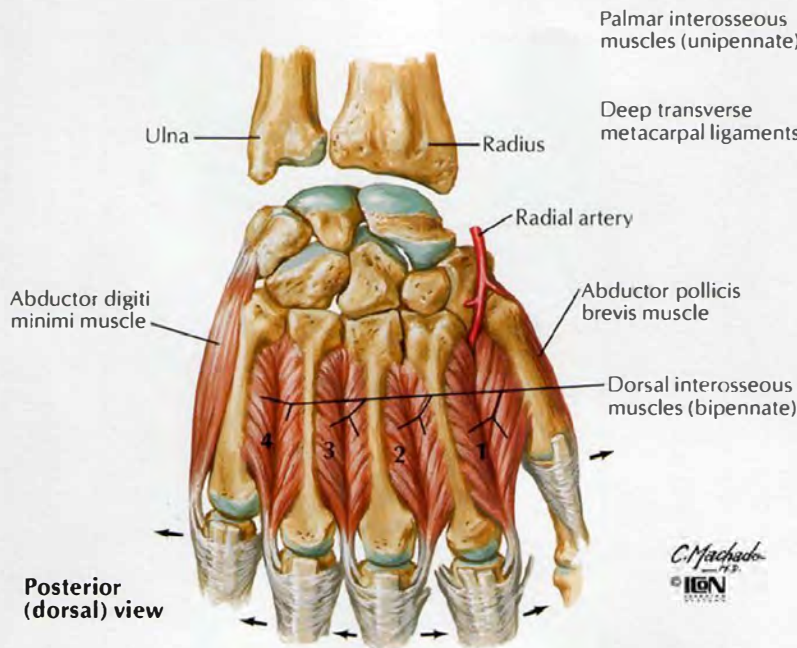
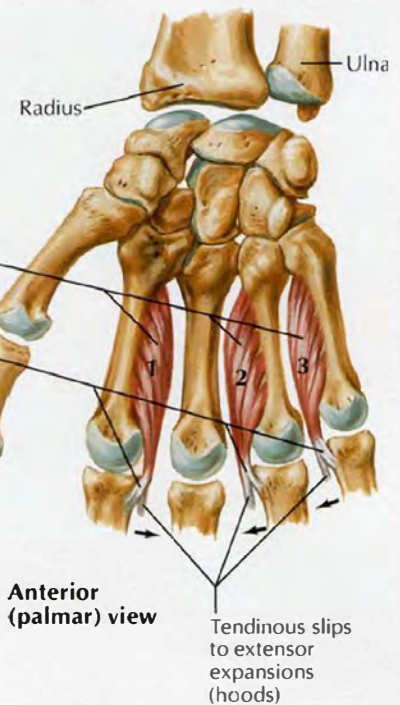
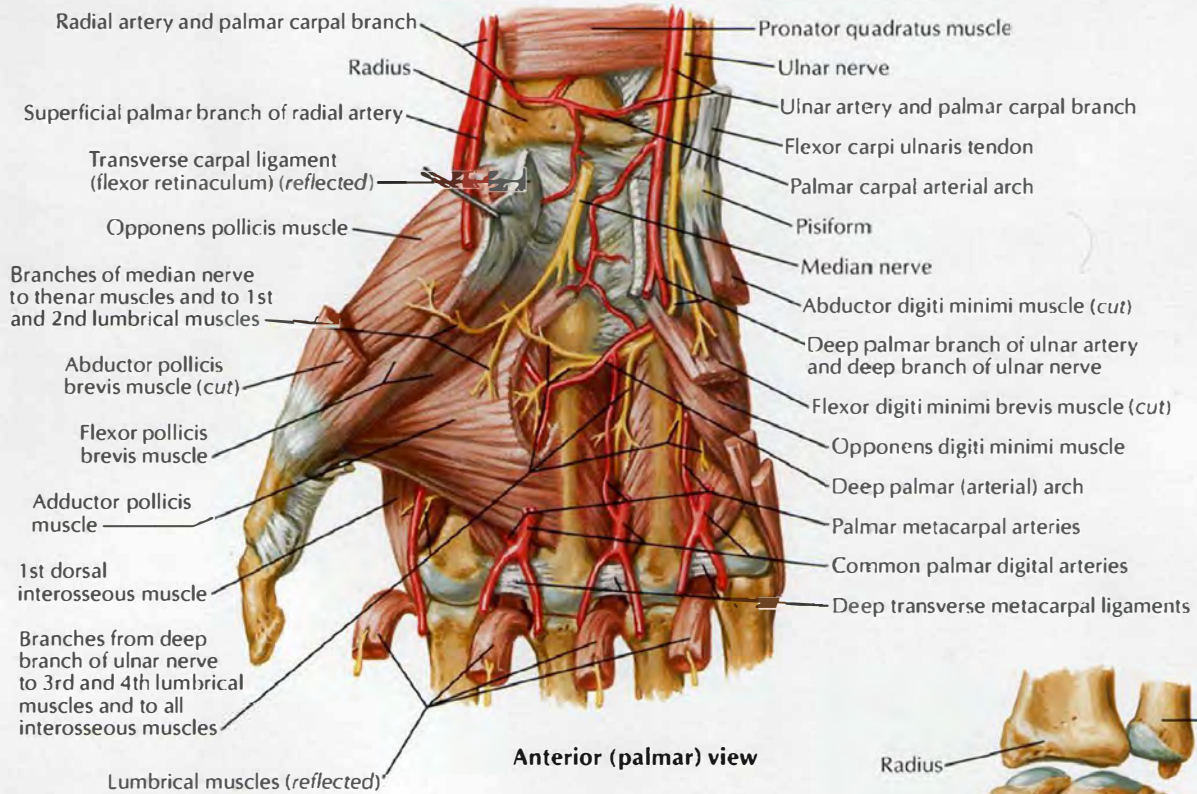
F. Netter M.D.
© IGM

Flexor and Extensor Tendons in Fingers



C. Machado
M.D.
© ION

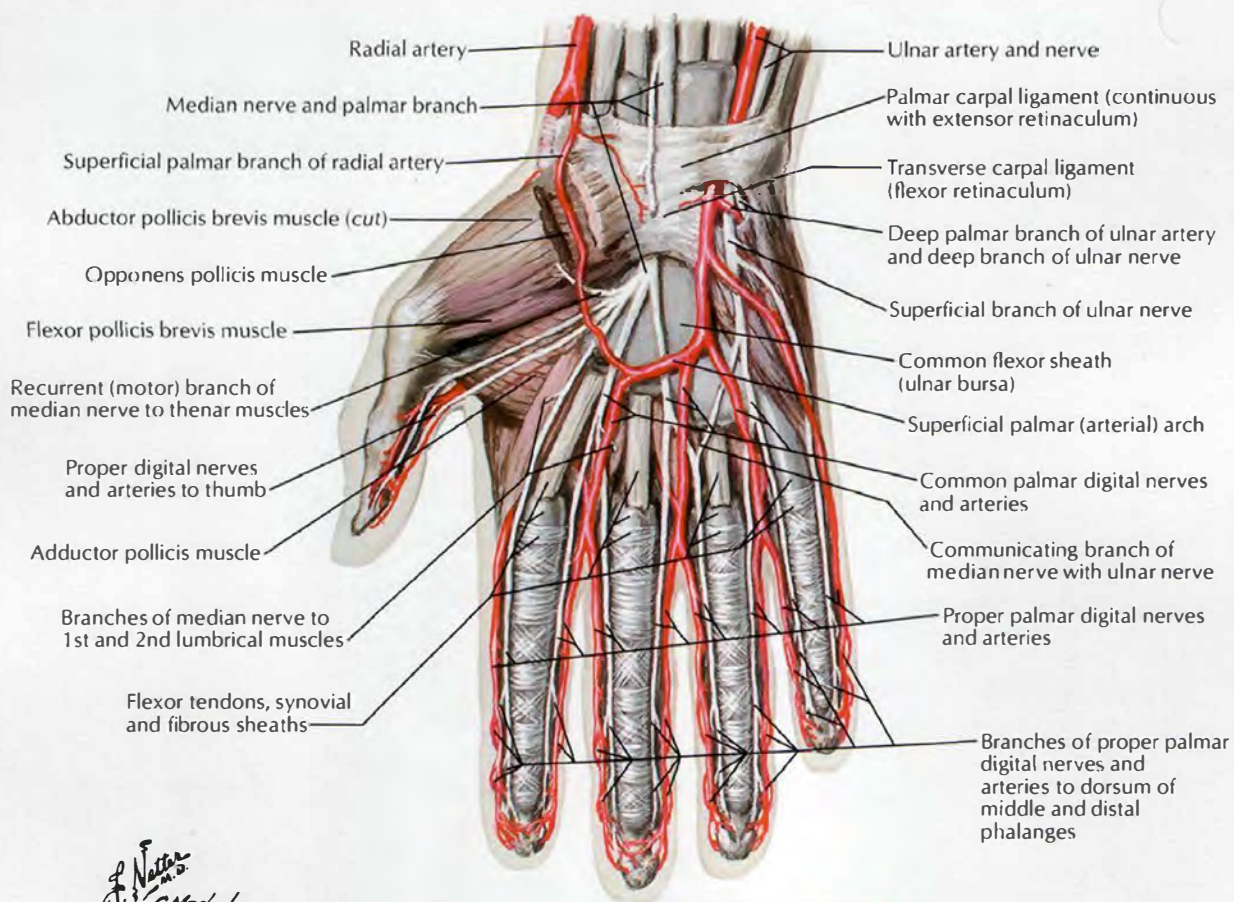
Intrinsic Muscles of Hand



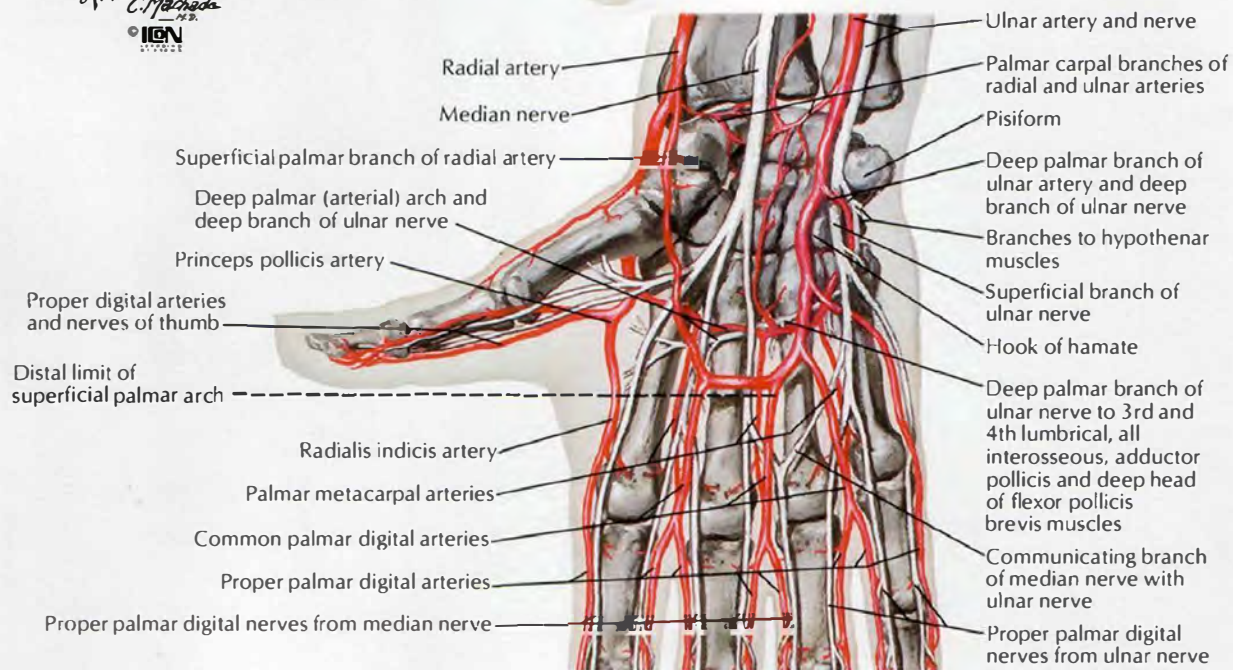
C. Machado
M.D.
© IAN
STUDIO

Note: Arrows indicate action of muscles

Arteries and Nerves of Hand: Palmar Views

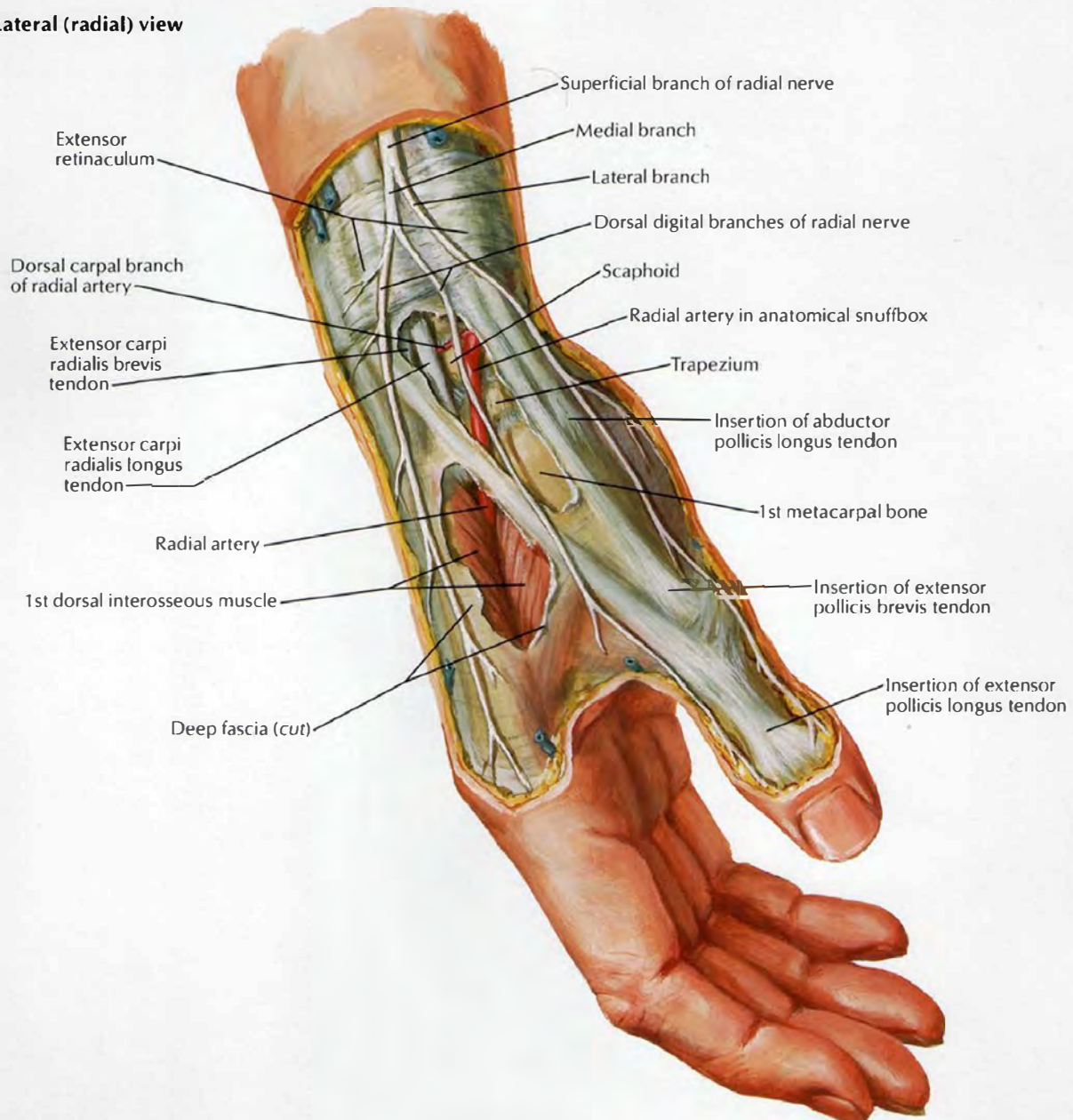


F. Netto
C. Machado
 ICA



Wrist and Hand: Superficial Radial Dissection

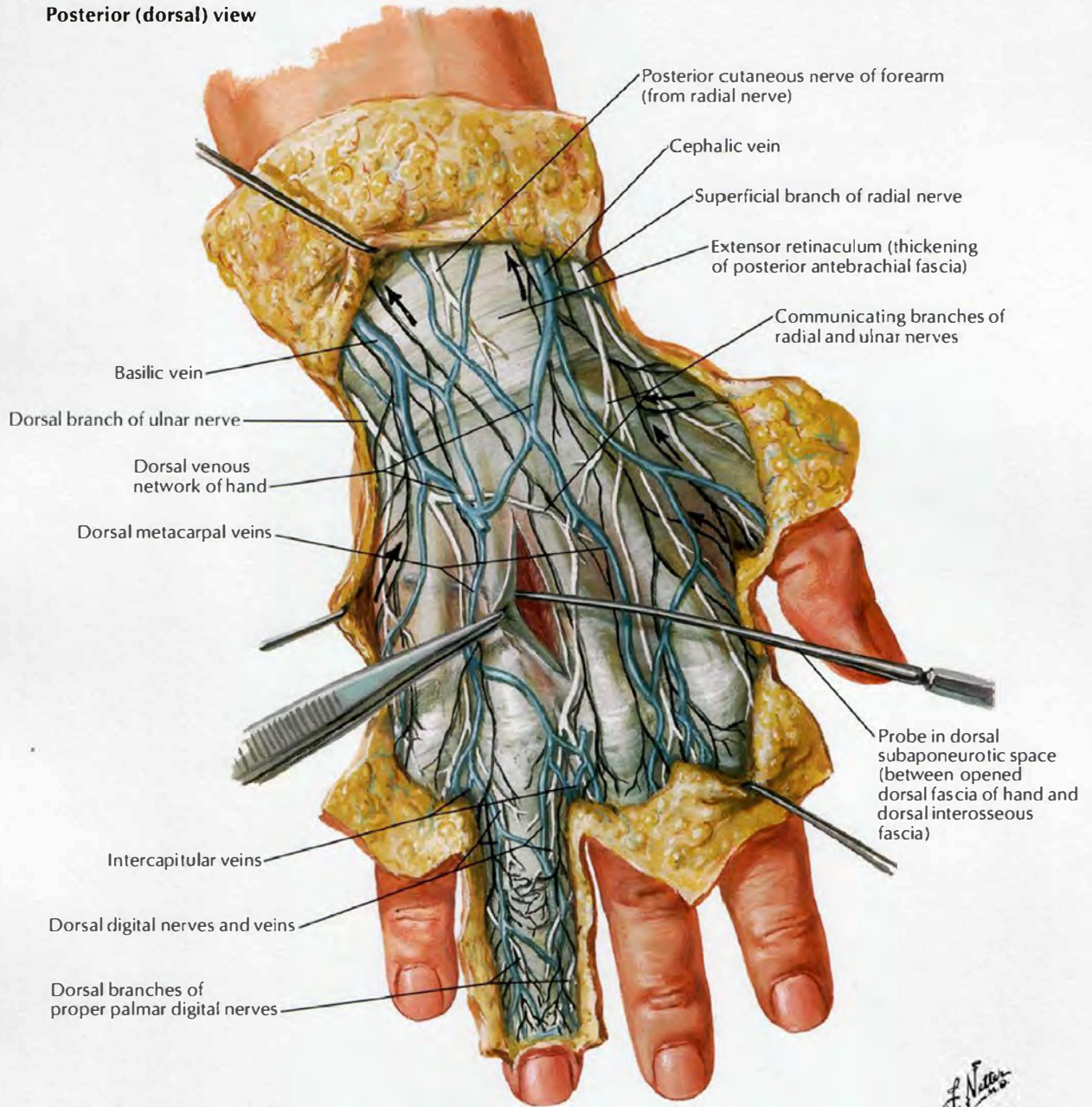
Lateral (radial) view



F. Netter
© IGM
1992

Wrist and Hand: Superficial Dorsal Dissection

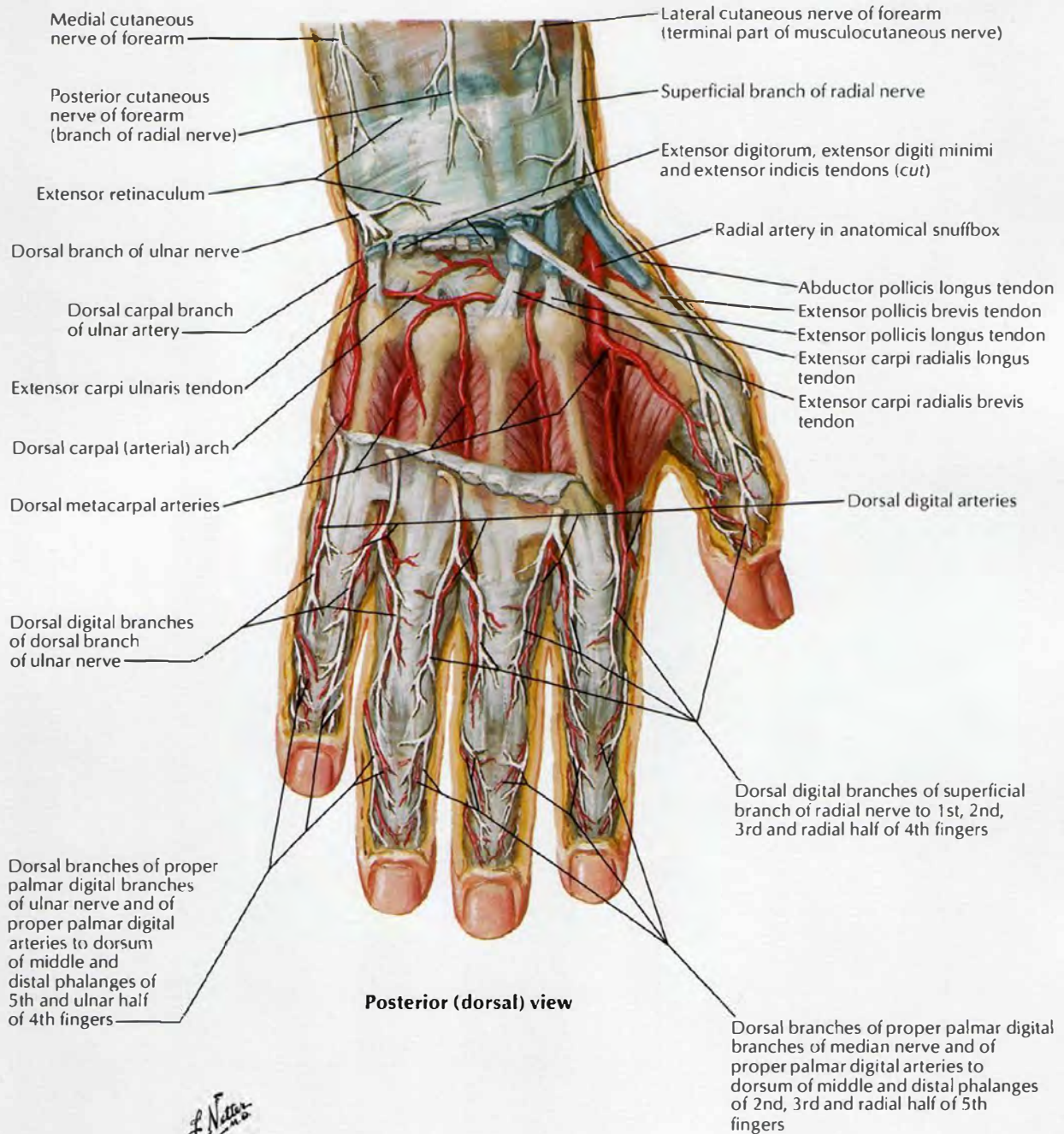
Posterior (dorsal) view



Note: Lymphatic pathways shown in black; arrows indicate direction of drainage

F. Netter
© IGM

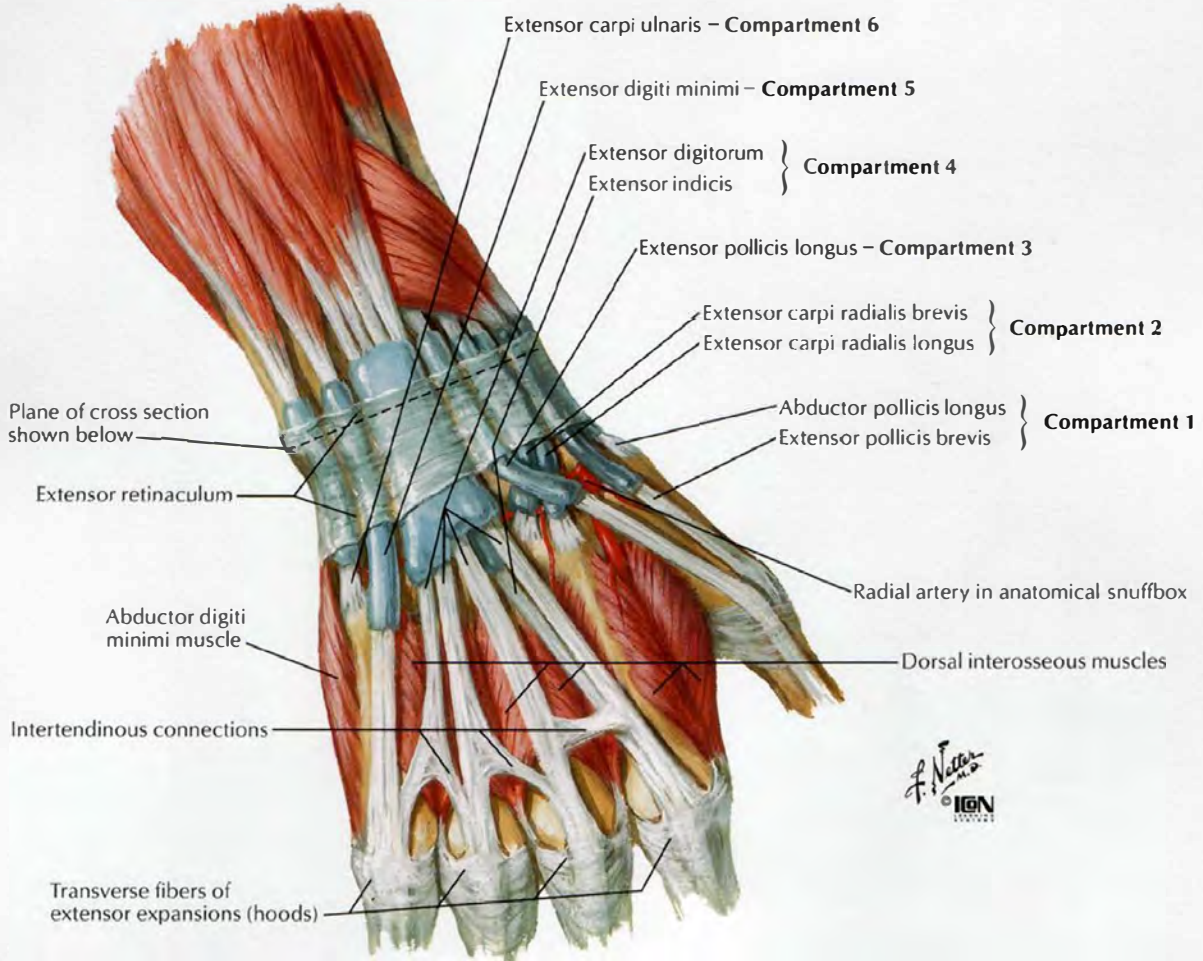
Wrist and Hand: Deep Dorsal Dissection



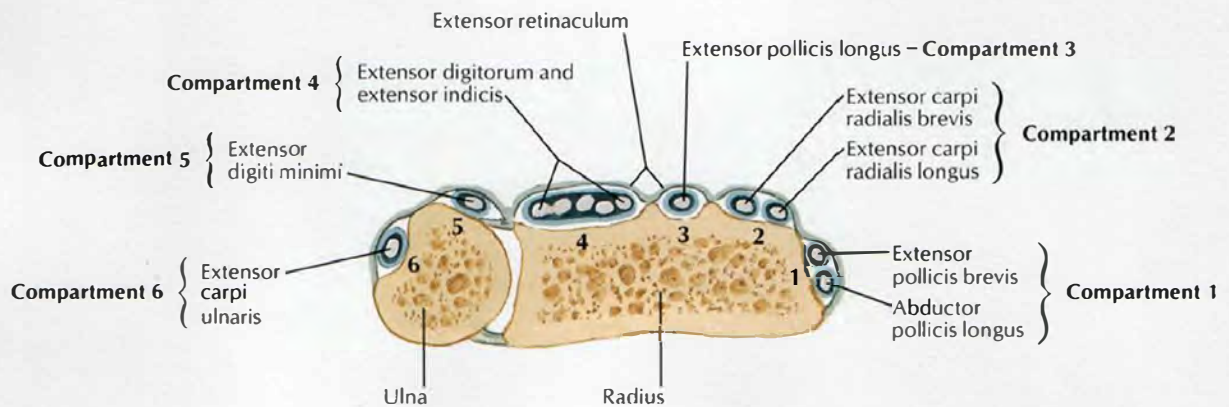
F. Netter M.D.
© IGIN

Extensor Tendons at Wrist

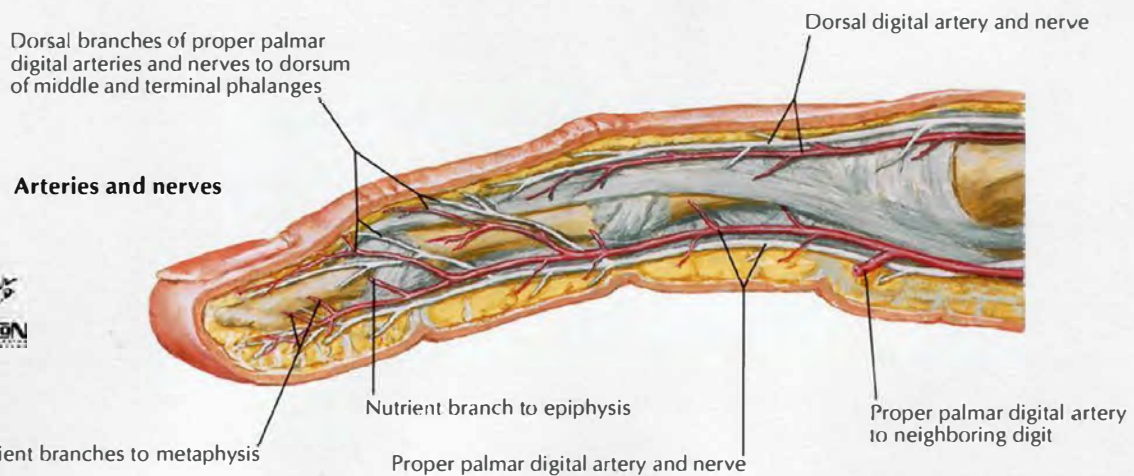
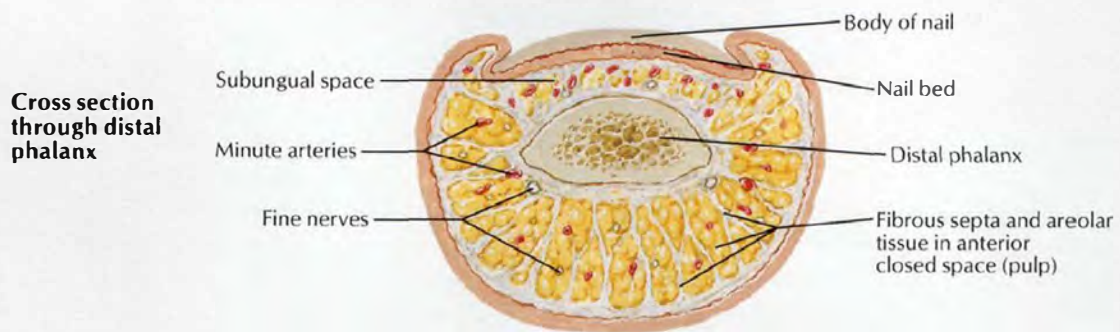
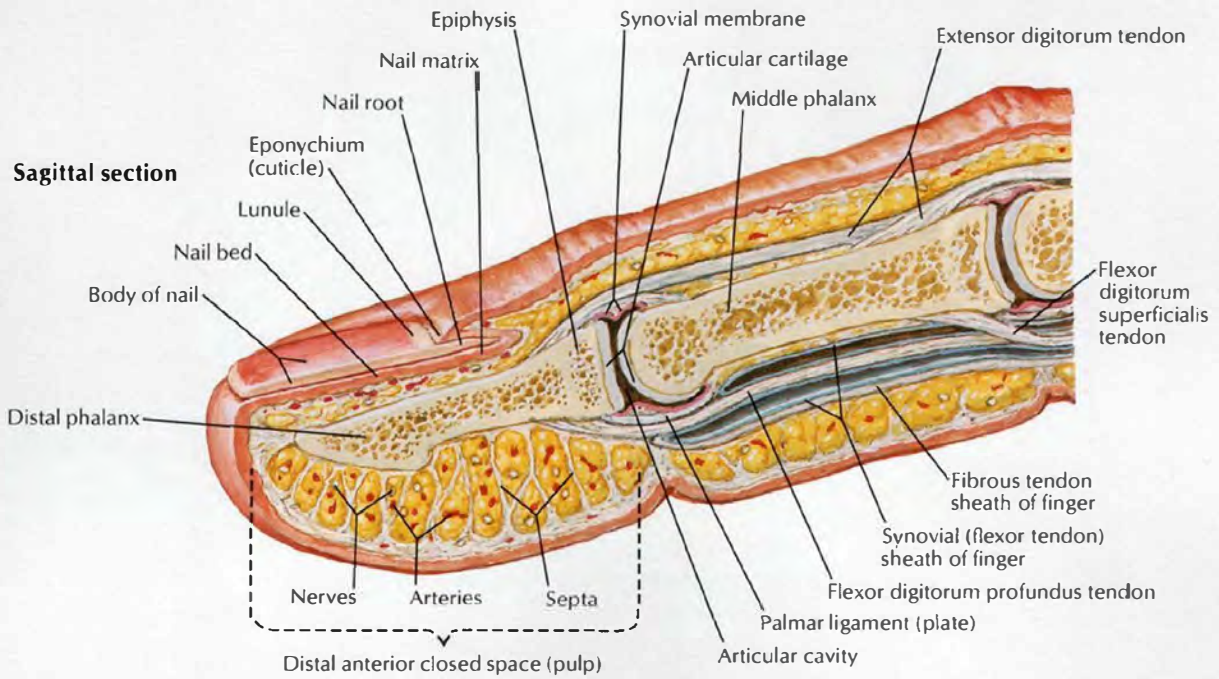
Posterior (dorsal) view



Cross section of most distal portion of forearm

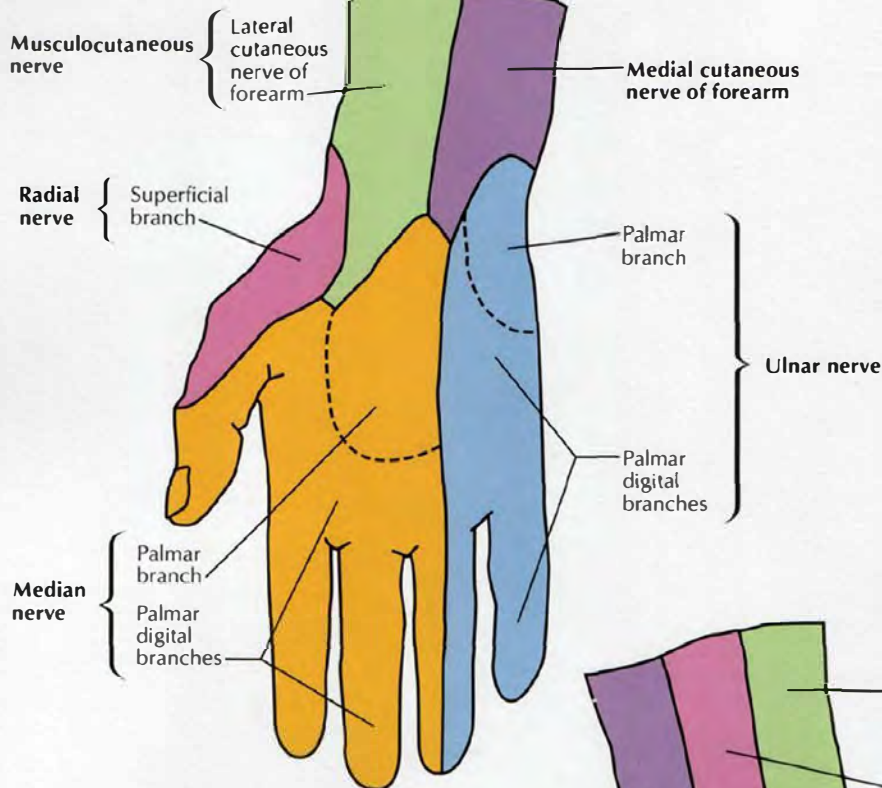


Fingers

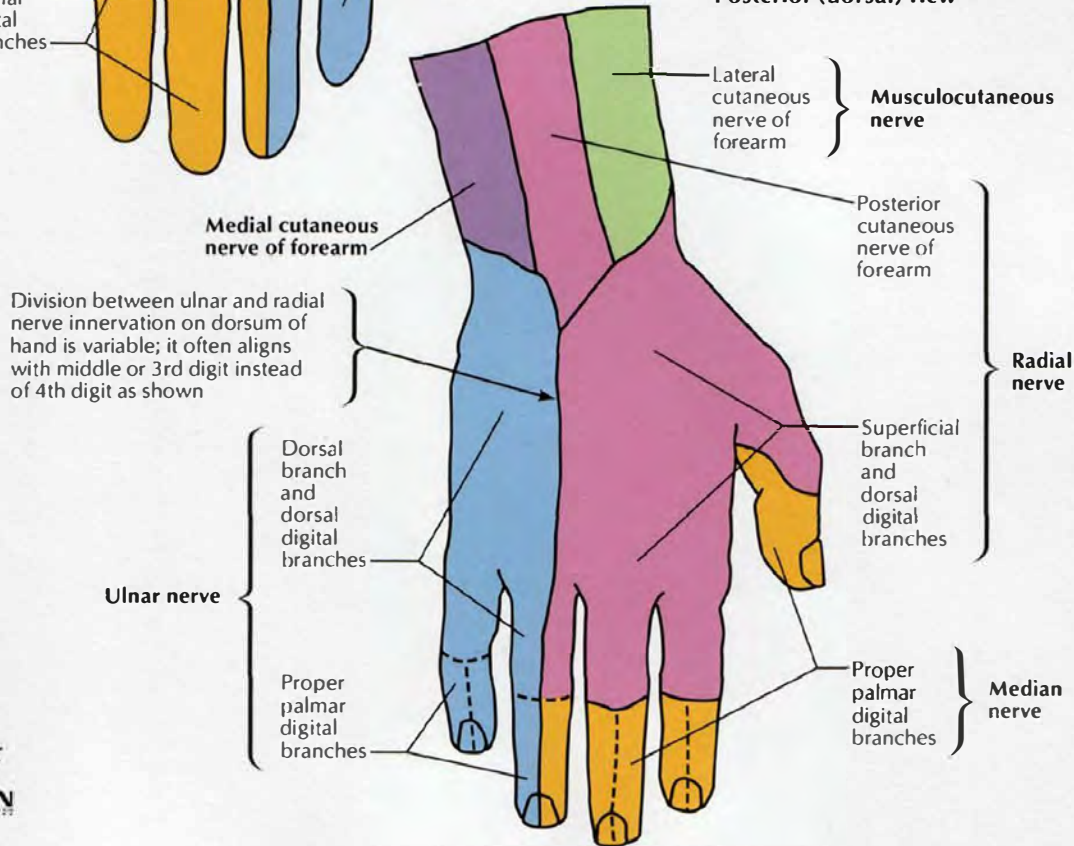


Cutaneous Innervation of Wrist and Hand

Anterior (palmar) view



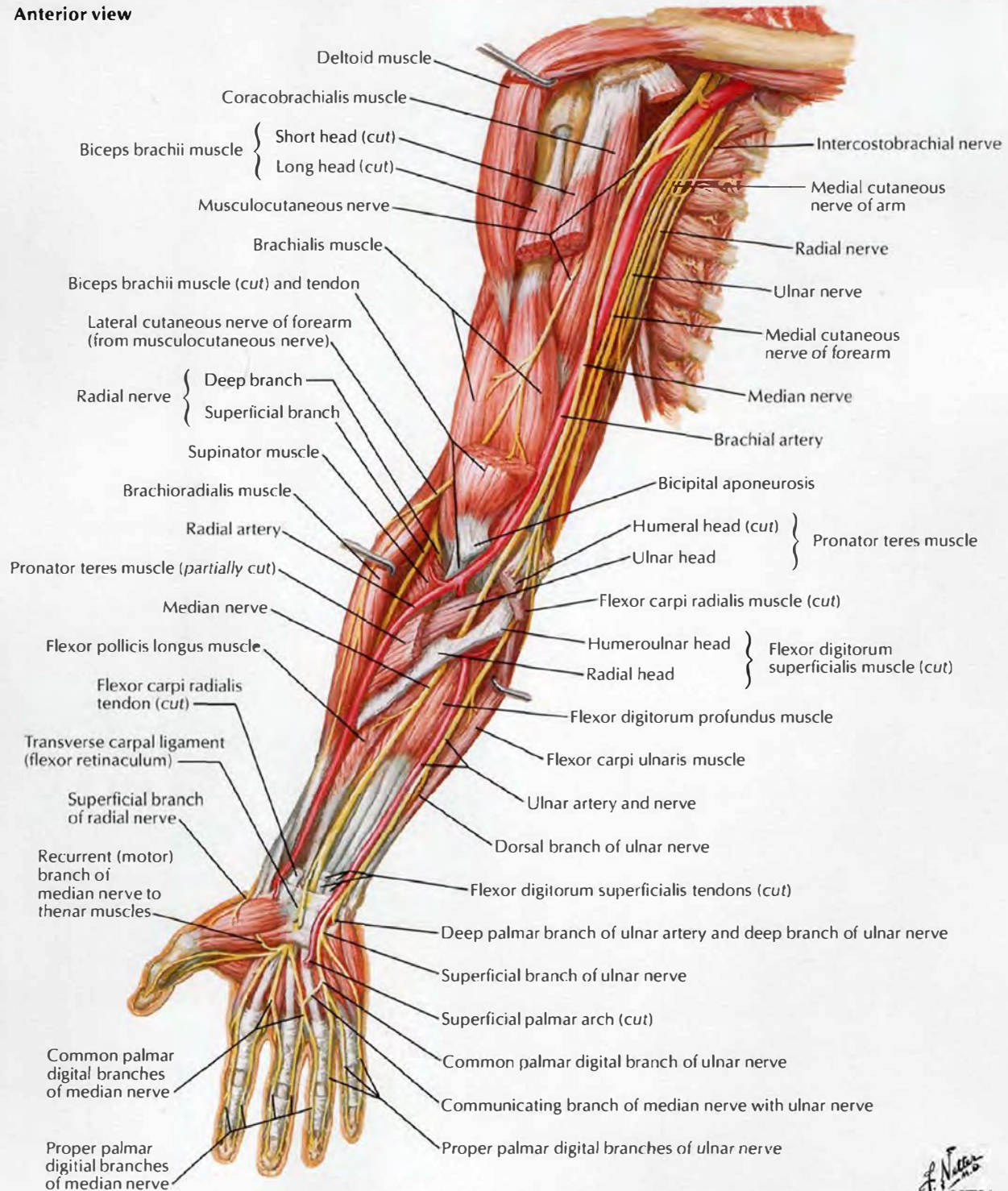
Posterior (dorsal) view



F. Netter M.D.
© IGV

Arteries and Nerves of Upper Limb

Anterior view

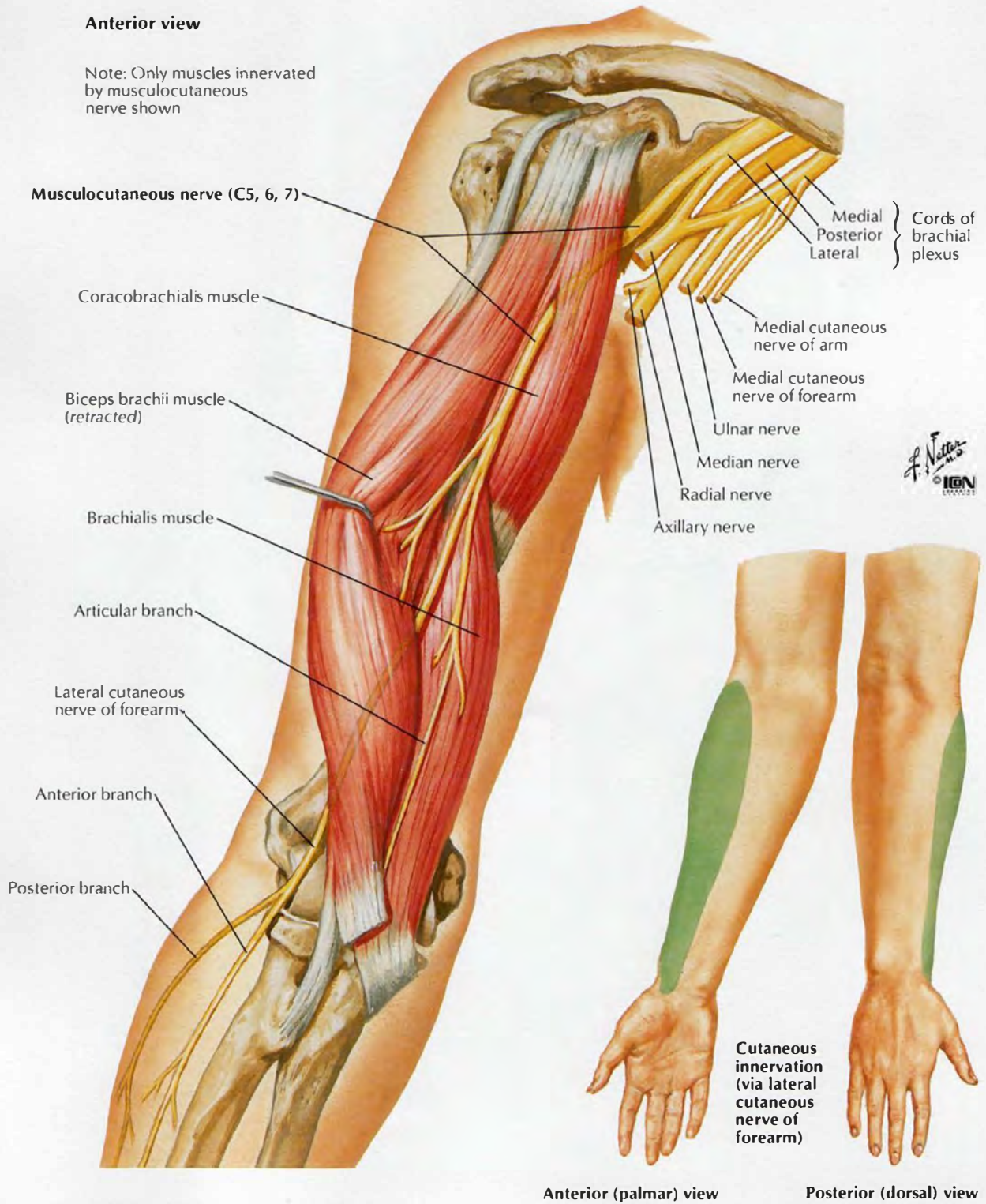


F. Netter M.D.
© H&M

Musculocutaneous Nerve

Anterior view

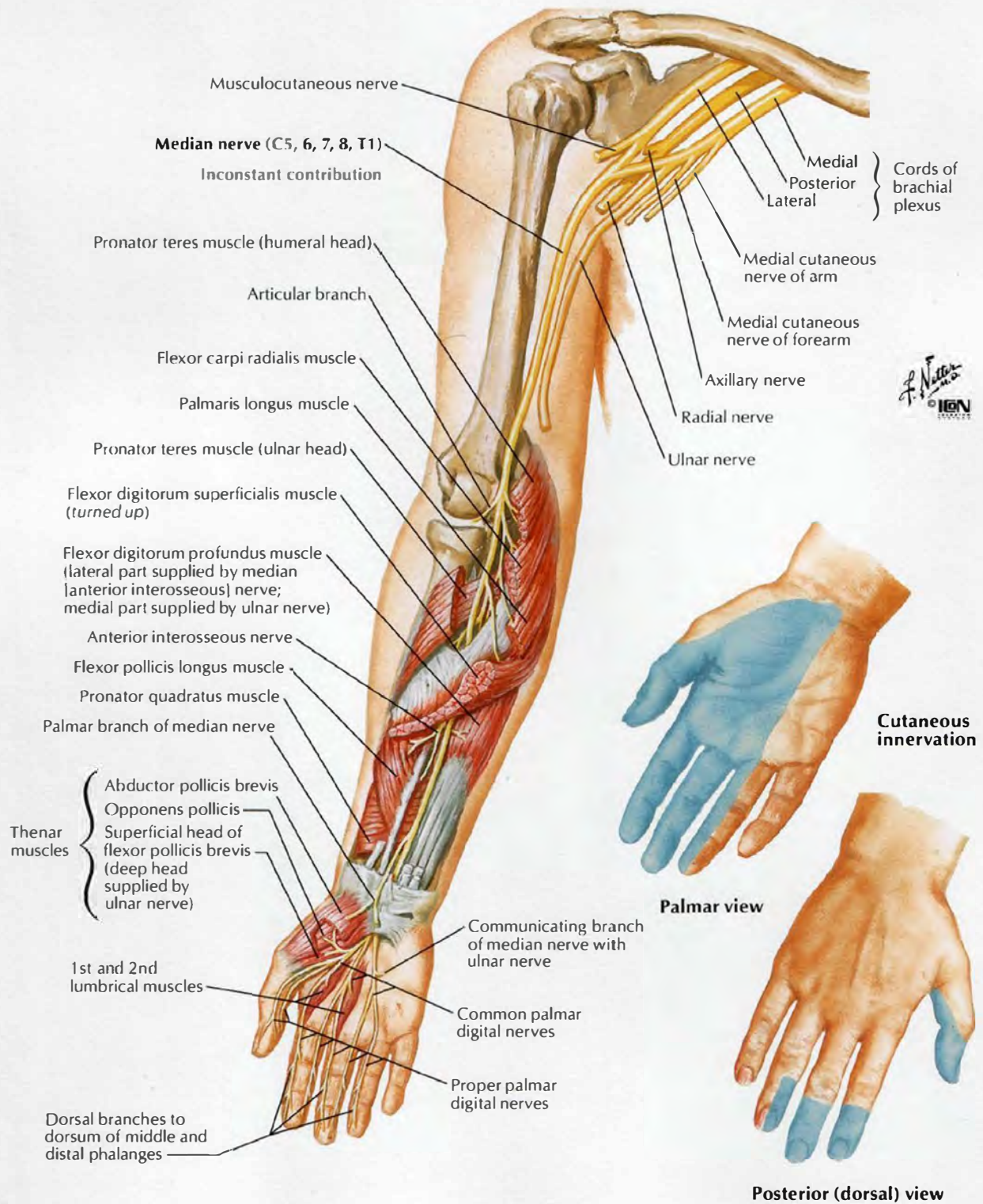
Note: Only muscles innervated by musculocutaneous nerve shown



Median Nerve

Anterior view

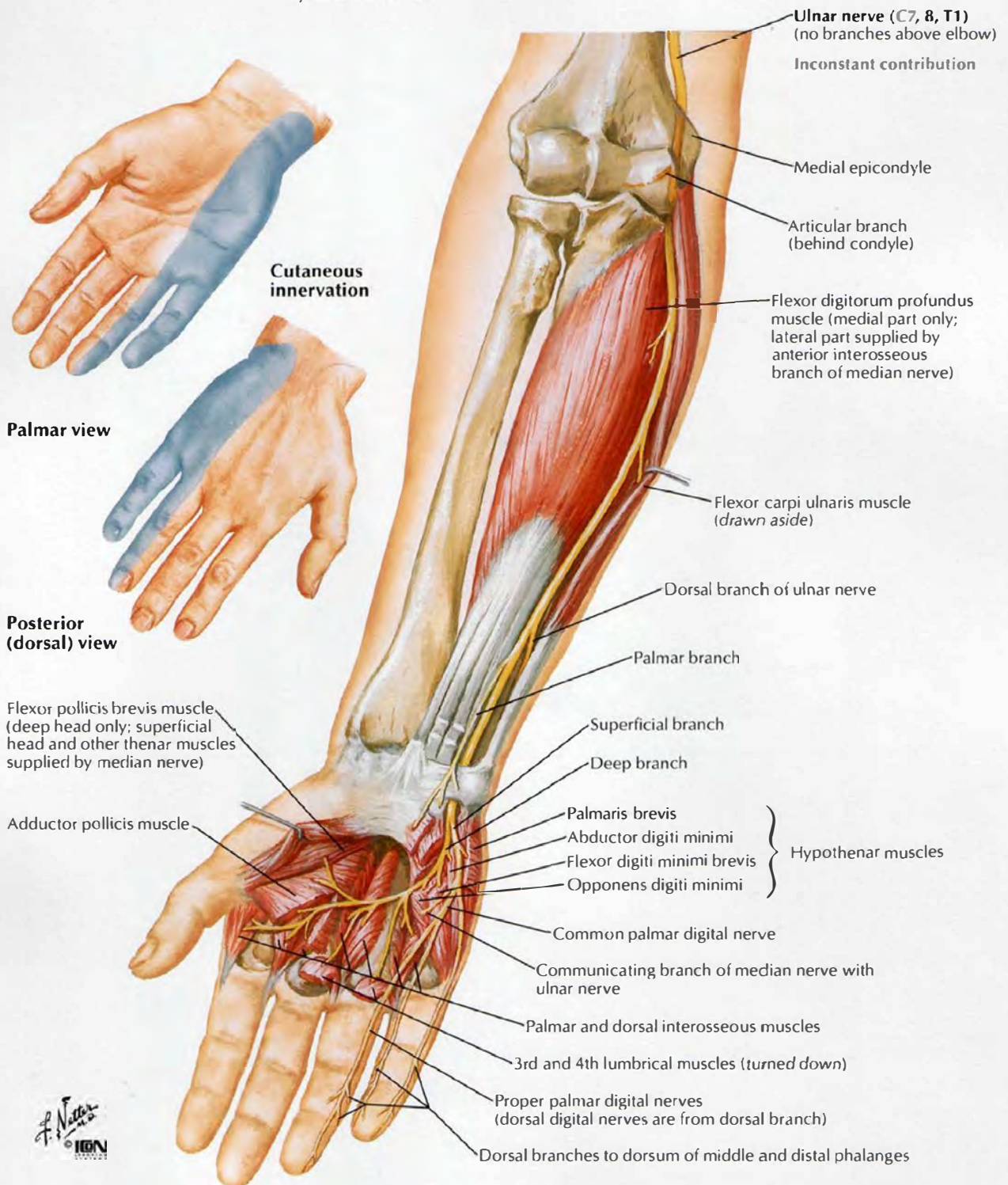
Note: Only muscles innervated by median nerve shown



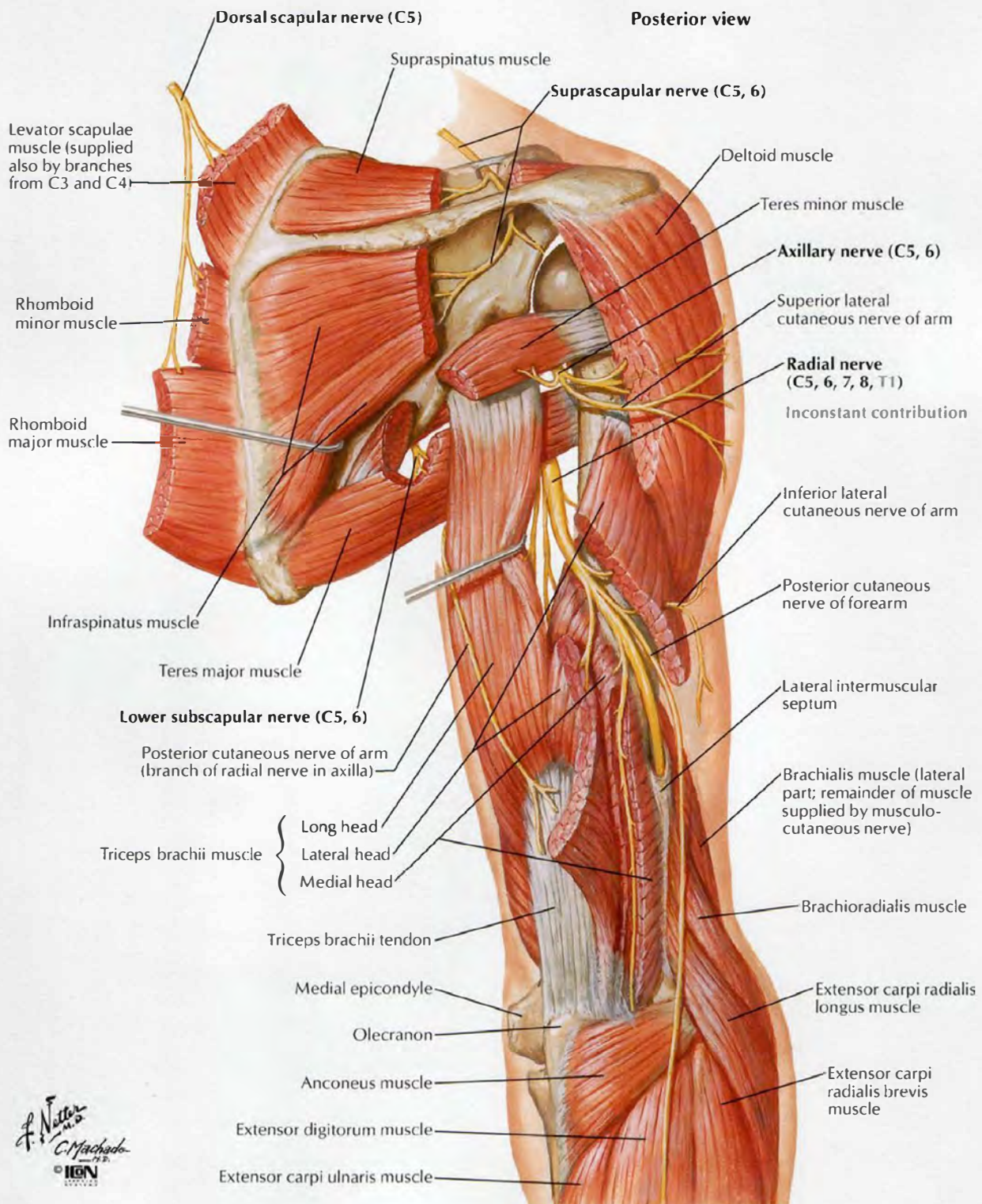
Ulnar Nerve

Anterior view

Note: Only muscles innervated by ulnar nerve shown



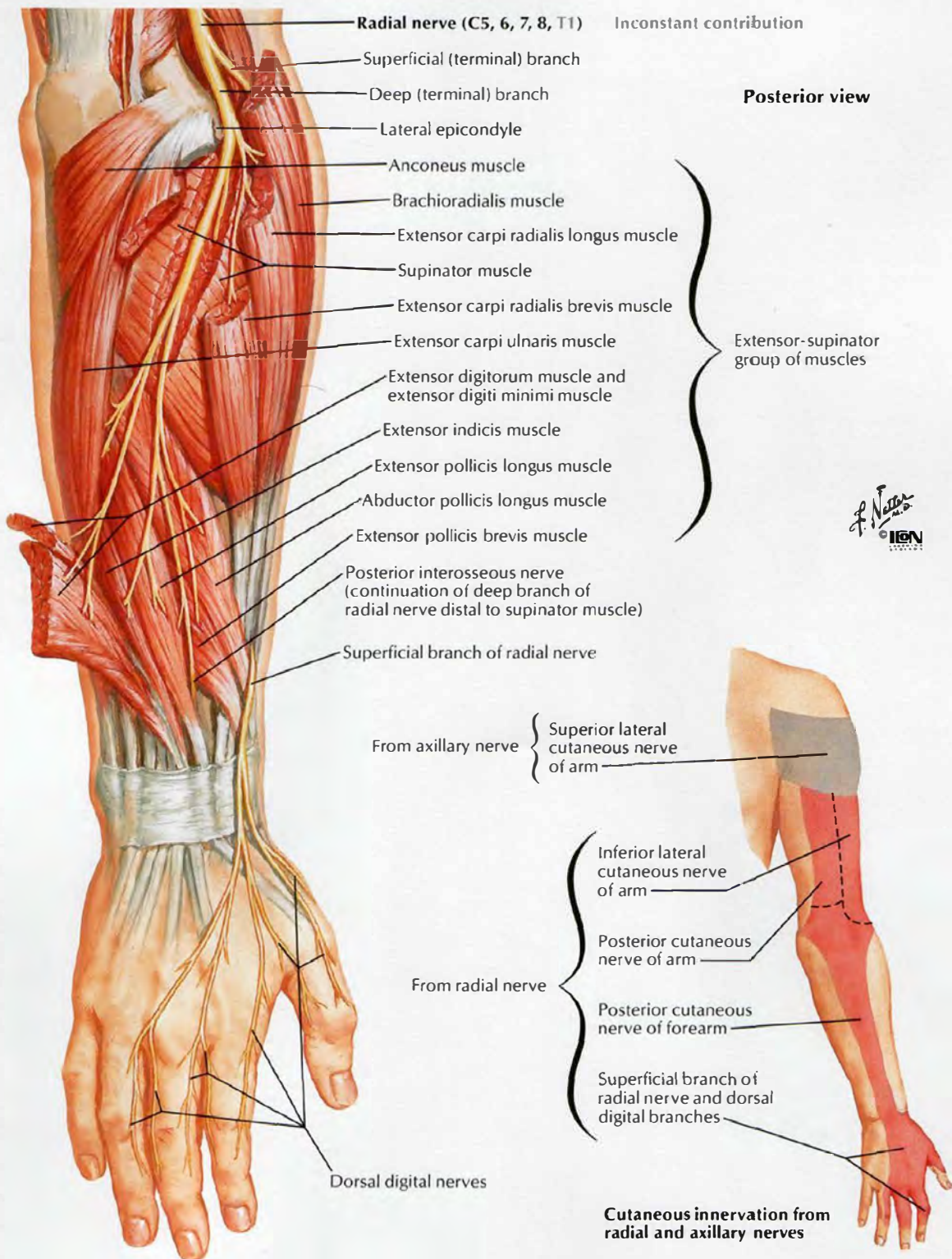
Radial Nerve in Arm and Nerves of Posterior Shoulder



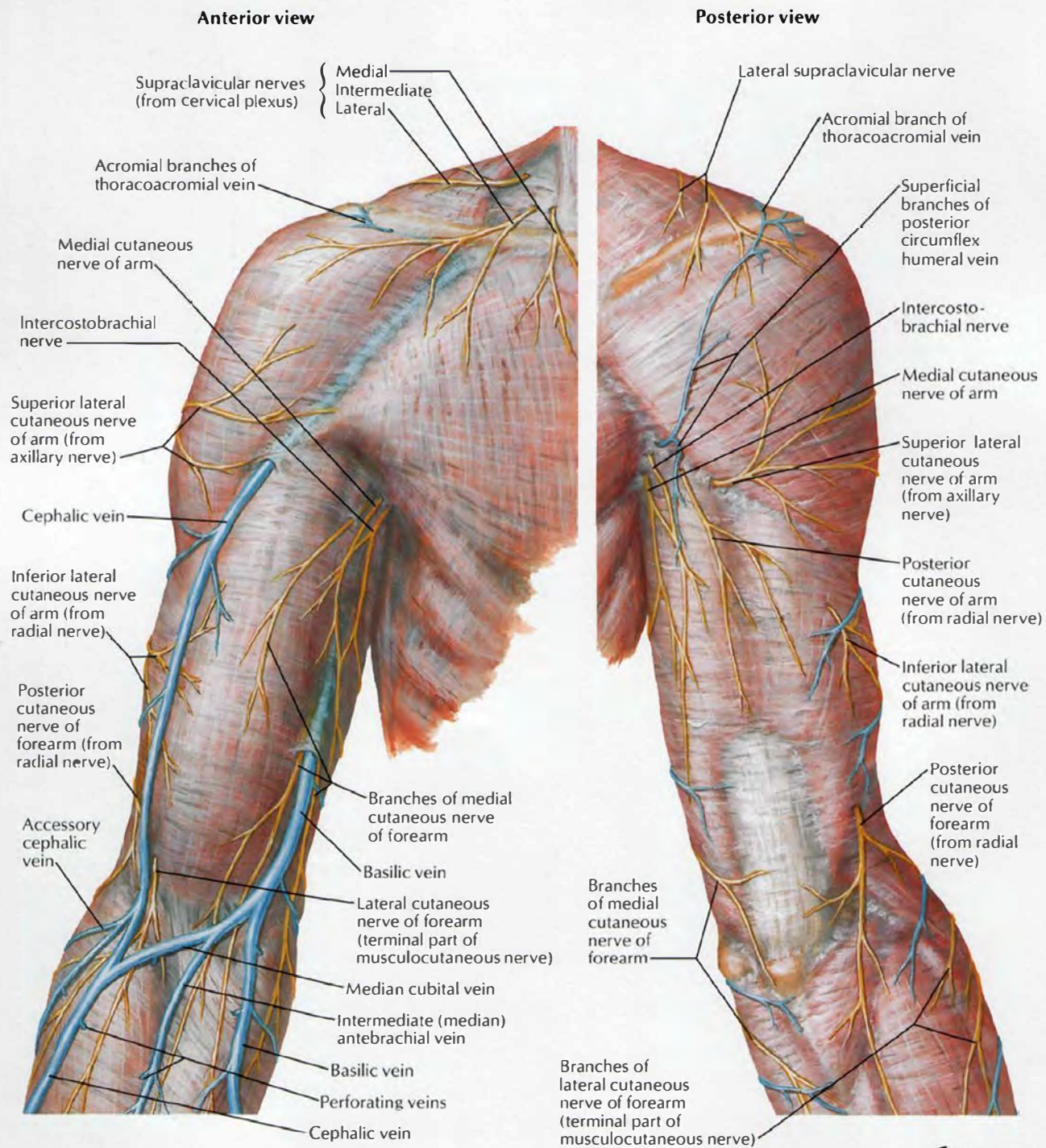
F. Netter M.D.
C. Machado
© IGI

Radial Nerve in Forearm

SEE ALSO PLATE 450

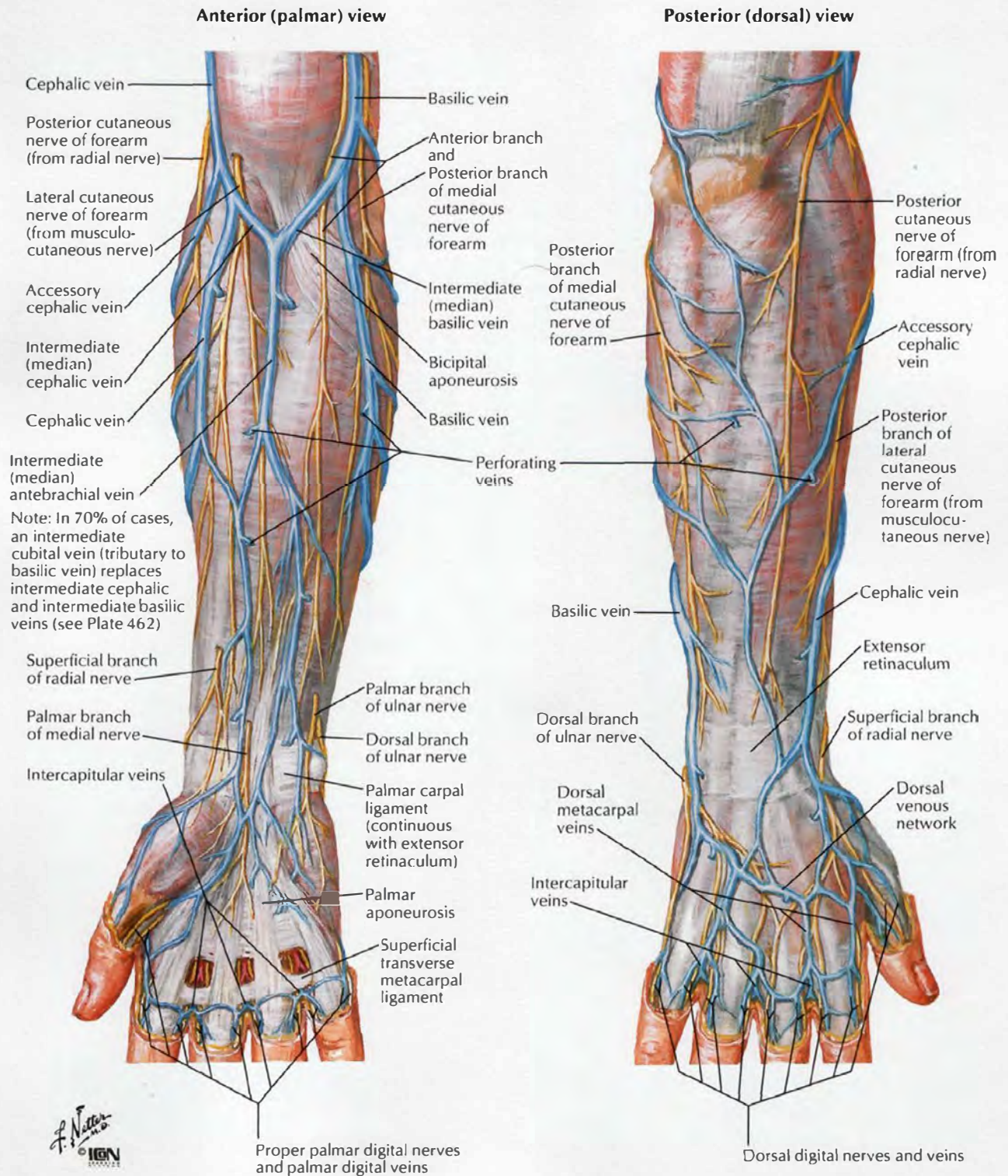


Cutaneous Nerves and Superficial Veins of Shoulder and Arm

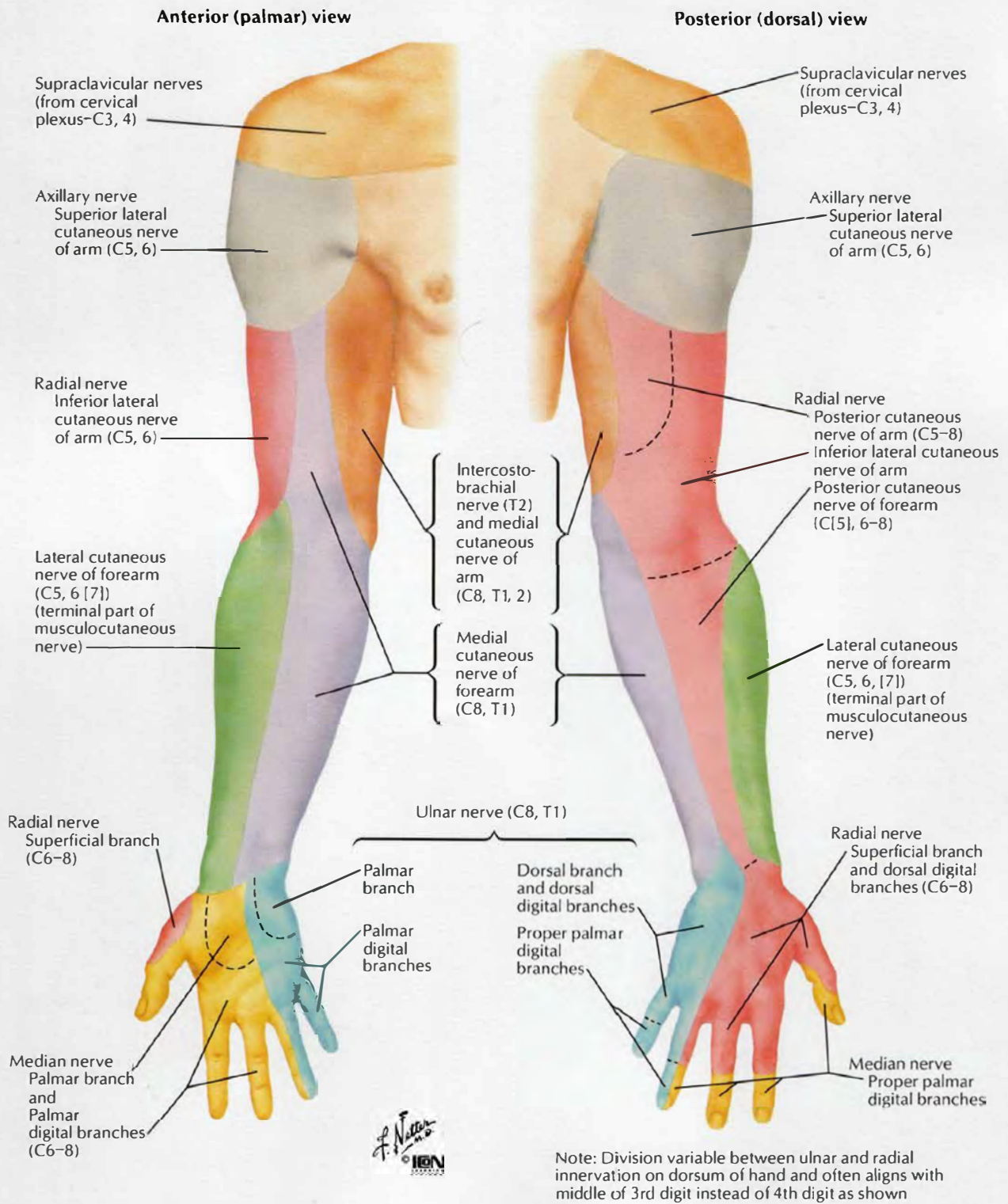


F. Netter M.D.
© IGM

Cutaneous Nerves and Superficial Veins of Forearm

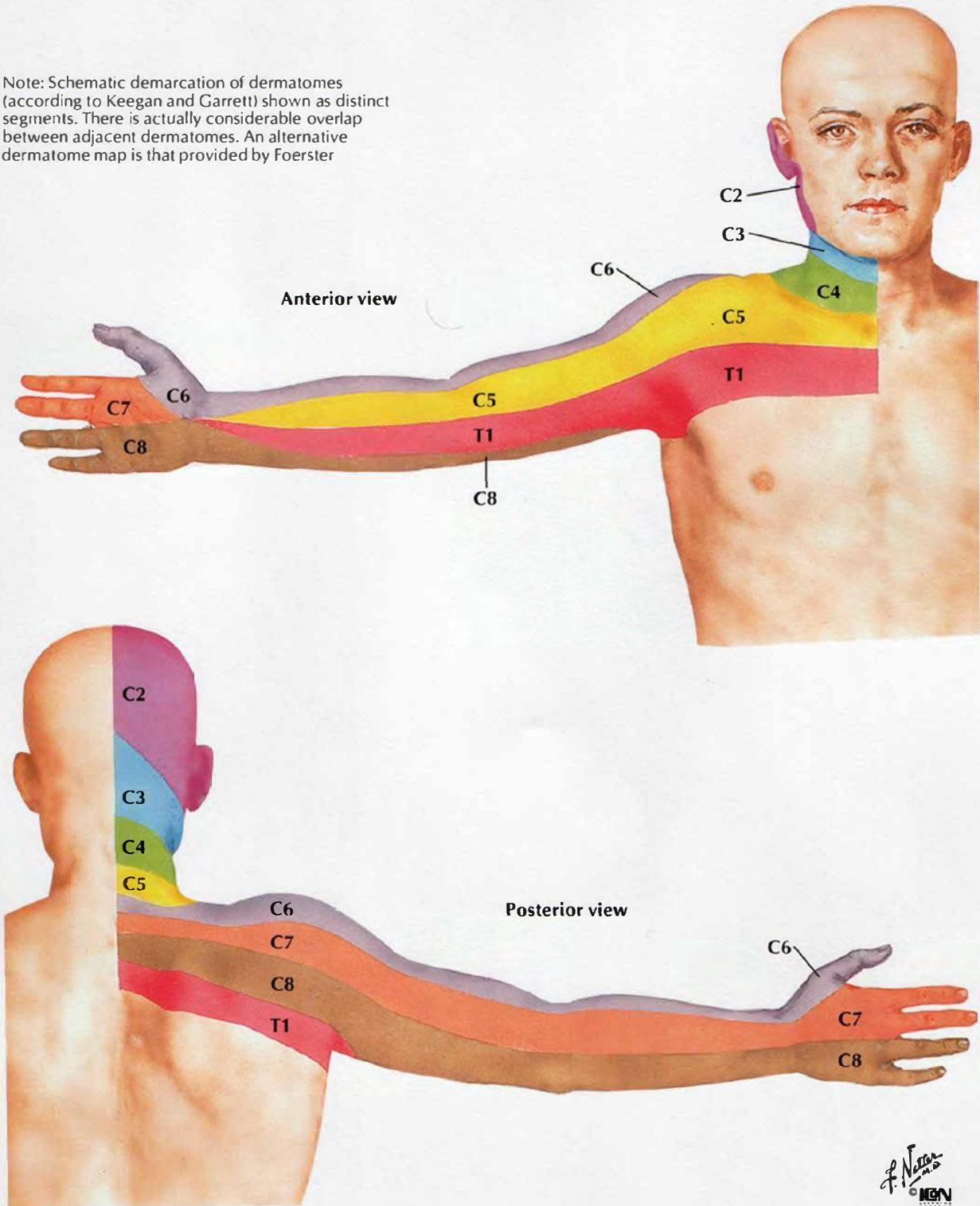


Cutaneous Innervation of Upper Limb



Dermatomes of Upper Limb

Note: Schematic demarcation of dermatomes (according to Keegan and Garrett) shown as distinct segments. There is actually considerable overlap between adjacent dermatomes. An alternative dermatome map is that provided by Foerster



Lymph Vessels and Nodes of Upper Limb

SEE ALSO PLATES 177, 451

