MICROSURGERY OF SCHLEMM'S CANAL AND THE HUMAN AQUEOUS OUTFLOW SYSTEM

MURRAY A. JOHNSTONE, M.D., AND W. MORTON GRANT, M.D.
Boston, Massachusetts

One basis for some of the present approaches to microsurgery of Schlemm's canal is the finding by Grant[1-3] that approximately 75% of the resistance of the aqueous outflow system could be eliminated in perfused enucleated human eyes by providing an opening from the anterior chamber into Schlemm's canal by internal trabeculotomy with a cystotome, and that in open-angle glaucomatous eyes, abnormal resistance could be eliminated in the same way. Much earlier, Barkan[4,5] showed that open-angle glaucoma could be relieved in adults by an internal trabeculotomy with a goniotomy knife. The effect of the Barkan trabeculotomy procedure appears generally not to have been long lasting. The cystotome laboratory procedure has not been readily adaptable to clinical use, but recently Bietti and Quaranta[6] have reported clinical successes by internal trabeculotomy with another type of cutting instrument.

Other procedures have been devised and applied clinically with the aim of reducing resistance to aqueous outflow by surgery on Schlemm's canal, in particular ab externo trabeculotomy procedures, but their effects have not been evaluated in the same experimental manner as those of internal cystotome trabeculotomy.

The present study was carried out to compare in postmortem enucleated human eyes the changes induced in the structure and function of the trabecular meshwork and Schlemm's canal aqueous outflow system by internal cystotome trabeculotomy, by ab externo probing of Schlemm's canal with nylon and metal probes, and by causing the probes to rupture from the canal into the anterior chamber as in current clinical practice.

PROCEDURES AND METHODS

Quantitative aqueous perfusion—We made measurements before and after experimental dissections as follows. We stored enucleated normal eyes obtained at autopsy at 4°C in a moist environment until 30 minutes prior to perfusion, which was started 4 to 48 hours post mortem. After removal from refrigeration, we placed the eyes in a silicone rubber mold that enveloped the posterior segment to the equator. We covered the anterior segment with absorbent paper saturated in perfusion fluid. An opening 5 mm in diameter was trephined in the center of the cornea to give access to the anterior chamber and the inner angle. Except in one special group of eyes, we regularly performed a radial iridotomy through the trephine opening to prevent artificial deepening of the chamber. For quantitative aqueous perfusion, we used Bárány's[7] constant pressure technique, with a commercial, sterile filtered, phosphate-buffered balanced salt solution containing glucose. We infused the solution into the anterior chamber through a stainless steel fitting (previously described[1]), which sealed the opening in the cornea. We generally measured steady state flow while maintaining intraocular pressure at 15 mm Hg, but in certain instances at 5, 30, or 50 mm Hg. The measurements made before each experimental procedure required approximately ten minutes of perfusion to attain what appeared to be a steady state. After manipulation or dissection, we carried out similar perfusion and monitored flow rate for 120 minutes. If the same eye underwent a sec

From the Howe Laboratory of Ophthalmology of Harvard Medical School, at Massachusetts Eye and Ear Infirmary, Boston, Massachusetts. This study was supported by Public Health Service center grant 5-PO1-EY000292, training grant 5-TO1-EY-00018, and research grant 5-RO1-EY-00002 from the National Eye Institute.

Reprint requests to W. Morton Grant, M.D., Howe Laboratory of Ophthalmology, 243 Charles St., Boston, MA 02114.

and experimental procedure, perfusion measurement sul group of eyes was perfused trols for the same length of perimental, omitting the diss ing procedures.

Microscopic morphologica histologic examination, tis fused with 4% glutaraldel meridional sections contai structures were excised. W with 1% osmium tetroxide, dehydrated in ethyl alcohol a upon. For light microscopy, 1 μ and stained them wi blue.

For scanning electron mi ue was fixed for 24 to 48 hc containing equal parts of 1 malin and 4% glutaraldehy 15M phosphate buffer (p then rinsed in distilled wate frozen in isopentane, and chi quid nitrogen. The frozen rated for three hours und We coated the freeze-dried old and 40% palladium. A ue from stored enucleated the quality generally prepare for examination of fine deta of value in demonstrating th phologic features in control the gross alterations resulti dissection procedures.

Dissections and surgical Internal cystotome trabecu formed in 180 degrees of th in the same manner as by llingsen and Grant.[8] T through the 5-mm corneal t under direct visualization w microscope at 25 to 40× ma ploying a cystotome with th right angles to the shaft. point from within the ar through the trabecular Schlemm's canal, and passec canal circumferentially, wit

D THE HUMAN

GRANT, M.D.

e trabeculotomy, by ab ex-
Schlemm's canal with nylon
, and by causing the probes
the canal into the anterior
rent clinical practice.

RES AND METHODS

aqueous perfusion—We
nts before and after experi-
is as follows. We stored
l eyes obtained at autopsy
environment until 30 min-
fusion, which was started 4
st mortem. After removal
n, we placed the eyes in a
old that enveloped the pos-
the equator. We covered
nent with absorbent paper
fusion fluid. An opening 5
was trephined in the center
give access to the anterior
inner angle. Except in one
f eyes, we regularly per-
iridotomy through the tre-
prevent artificial deepening
For quantitative aqueous
ed Bárány's[7] constant pres-
ith a commercial, sterile fil-
buffered balanced salt solu-
glucose. We infused the so-
nterior chamber through a
ing (previously described[1]),
opening in the cornea. We
red steady state flow while
aocular pressure at 15 mm
in instances at 5, 30, or 50
surements made before each
ocedure required approx-
utes of perfusion to attain
o be a steady state. After
dissection, we carried out
and monitored flow rate for
he same eye underwent a sec-

ond experimental procedure, we made a third perfusion measurement subsequently. One group of eyes was perfused as normal controls for the same length of time as the experimental, omitting the dissection and probing procedures.

Microscopic morphological methods—For histologic examination, tissues were perfused with 4% glutaraldehyde, and small meridional sections containing the angle structures were excised. We treated these with 1% osmium tetroxide, then they were dehydrated in ethyl alcohol and embedded in epon. For light microscopy, we cut sections 1 μ and stained them with 1% toluidine blue.

For scanning electron microscopy the tissue was fixed for 24 to 48 hours in a solution containing equal parts of 10% neutral formalin and 4% glutaraldehyde in Sorensen 15M phosphate buffer (pH 7.2). It was then rinsed in distilled water for one hour, frozen in isopentane, and chilled in a bath of liquid nitrogen. The frozen tissue was dehydrated for three hours under high vacuum. We coated the freeze-dried tissue with 60% gold and 40% palladium. Although this tissue from stored enucleated eyes was not of the quality generally prepared by anatomists for examination of fine detail, we felt it was of value in demonstrating the principal morphologic features in control normal eyes and the gross alterations resulting from microdissection procedures.

Dissections and surgical manipulations—Internal cystotome trabeculotomy was performed in 180 degrees of the circumference in the same manner as by Grant[1,2] and by Ellingsen and Grant.[8] This was done through the 5-mm corneal trephine opening under direct visualization with an operating microscope at 25 to 40× magnification, employing a cystotome with the point oriented at right angles to the shaft. We inserted the point from within the anterior chamber through the trabecular meshwork to Schlemm's canal, and passed it along in the canal circumferentially, with the blunt surface of the cystotome facing the external wall of Schlemm's canal. In this position it presented a triangular shape with its base facing the external wall of Schlemm's canal, and a sharp slanting edge engaging the trabecular meshwork. This was intended to cut the inner wall of the canal and the trabecular sheets from within the canal while limiting damage to the external wall of the canal. Usually the cystotome pushed a strip of meshwork ahead of itself in the manner of a plow.

2. We performed ab externo trabeculotomy and other ab externo surgical manipulations on excised human eyes in a manner similar to that employed by Dannheim and Harms in patients. A 4 × 4-mm lamellar scleral flap hinged at the cornea was dissected to include approximately two thirds of the thickness of the sclera. With this flap reflected, we localized Schlemm's canal under the operating microscope, guided by the anatomic landmarks of gray corneoscleral transition zone and by use of a transilluminator to demonstrate the position of the scleral spur. The transilluminator was most helpful when applied to the outer surface of the globe just anterior to the limbus, diametrically opposite the site of dissection. This caused the structures anterior to the insertion of the ciliary body into the sclera to appear brightly illuminated, while those posterior were dark. A bright distinct line of demarcation, which was characteristically seen in the posterior part of the gray transition zone, provided a particularly reliable guide to localization of Schlemm's canal. We then made an opening in the outer wall of the canal to permit insertion of probes circumferentially in the canal. The ab externo dissections involved either three or six hours of the superior circumference, with no attempt at selection of quadrants. During the whole procedure, we maintained the intraocular pressure in the eyes at 15 mm Hg through connection with a reservoir of perfusion fluid. After we completed the experimental manipulations, we sutured the scleral flap

tightly back in place with six 8-0 silk sutures. Testing with fluorescein added to the perfusion fluid established that we obtained a reliably leak-free closure in this way. The following experimental manipulations were performed.

2A. Ab externo, we made a nylon suture of 0.13-mm diameter slide circumferentially in the canal for 15 mm, and in some eyes the suture was pulled taut to rupture the trabecular meshwork in the manner described by Redmond Smith.[9,10]

2B. We performed ab externo probe trabeculotomy with a curved hairpin probe (0.275-mm diameter) of the type described by Dannheim and Harms,[11] inserting it circumferentially within Schlemm's canal and then rotating it to rupture through trabecular meshwork into the anterior chamber. We attempted to swing the probe in a plane that would cause disruption nearer to scleral spur than Schwalbe's line. In certain instances after this type of trabeculotomy had been completed, we performed an additional dissection in which we removed persisting flaps of trabecular meshwork with jeweler's forceps under direct view with the operating microscope through the corneal trephine opening.

2C. We performed ab externo diathermy probe trabeculotomy with a special probe devised by Ellingsen. This was made from hard stainless steel wire, 0.175-mm diameter, conforming to the basic curved hairpin design of Dannheim and Harms, but insulated with a 0.05-mm coating of TFE Teflon. We stripped the insulating Teflon coating from along that side of the probe that was to come into contact with the trabecular meshwork side of Schlemm's canal. The external wire handle was left bare. With the probe in the canal, a diathermy electrode was touched to the handle to carry cutting diathermy current through the probe to the bared portion facing the trabecular meshwork. We applied two to three bursts of diathermy of 0.5- to 1-second duration so the probe could be rotated into Schlemm's canal with no mechanical resistance.

2D. As a control for the trabeculotomy procedures, we carried out an ab externo circumferential passage of a standard probe in Schlemm's canal without actually performing a trabeculotomy. We simply inserted the probe within Schlemm's canal in the same manner as for probe trabeculotomy, but instead of application of diathermy or rotation of the probe into the anterior chamber, the probe was merely slid back out again and the scleral flap resutured as after actual trabeculotomy. We made perfusion measurements in these eyes at pressures of 5, 30, or 50 mm Hg, as well as at the standard 15 mm Hg, and in another group of eyes that were subjected to the passage of the probe without rupture of the meshwork, we omitted the standard iridotomy and determined the influence of artificial deepening of the anterior chamber.

Observations on normal control eyes

As a basis for comparison, six eyes were perfused at 15 mm Hg for 130 minutes in the same manner as eyes subjected to experimental dissections or surgical manipulations, but in these six eyes, we performed no experimental procedures. During this time the flow changed slightly in individual eyes, as shown in Table 1, but the mean for the group remained essentially constant, as shown in Figure 1.

By light microscopy of 1-μ sections, Schlemm's canal was seen normally to have a strikingly plexiform character, with irregular fusiform dilatations of the outer wall. Septa were frequently present, dividing the canal into two to four channels. The canal seldom resembled a simple endothelial lined tube. In some normal eyes after perfusion at 15 mm Hg, the trabecular meshwork almost touched the external wall, reducing Schlemm's canal to little more than a potential space in areas without septa, as previously described by Johnstone and Grant.[12] Dissection with fine forceps and razor blade in segments of normal eyes showed that the trabecular meshwork could be removed to

TABLE 1

PERFUSION FLOW RATE* IN UND EYES, SPONTANEOUS VARIATI

Eye	Minu 0	20	40
1	2.6	2.5	2.5
2	2.3	2.4	2.5
3	5.3	5.7	4.7
4	3.7	4.2	4.3
5	2.2	2.2	2.3
6	1.8	1.7	1.5

*Flow in μl/min at 15 mm H

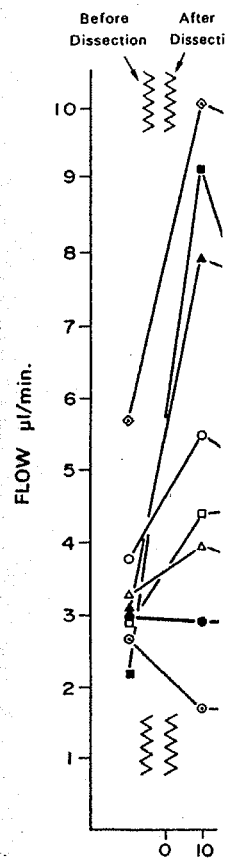

Fig. 1 (Johnstone and Grant sure in groups of postmortem tions and manipulations were p of the mean in a group of undiss

rol for the trabeculotomy
rried out an ab externo cir-
age of a standard probe in
without actually perform-
ny. We simply inserted the
lemm's canal in the same
obe trabeculotomy, but in-
on of diathermy or rotation
the anterior chamber, the
slid back out again and the
red as after actual trabecu-
e perfusion measurements
ressures of 5, 30, or 50 mm
t the standard 15 mm Hg,
oup of eyes that were sub-
sage of the probe without
meshwork, we omitted the
y and determined the influ-
deepening of the anterior

ON NORMAL CONTROL EYES

comparison, six eyes were
nm Hg for 130 minutes in
as eyes subjected to experi-
s or surgical manipulations,
eyes, we performed no ex-
dures. During this time the
ghtly in individual eyes, as
1, but the mean for the
essentially constant, as
1.
roscopy of 1-μ sections
was seen normally to have a
orm character, with irregu-
atations of the outer wall,
uently present, dividing the
o four channels. The canal
d a simple endothelial lined
rmal eyes after perfusion at
trabecular meshwork almost
external wall, reducing
to little more than a poten
as without septa, as previ-
by Johnstone and Grant.[12]
fine forceps and razor blade
normal eyes showed that the
work could be removed to

TABLE 1

PERFUSION FLOW RATE* IN UNDISSECTED CONTROL EYES, SPONTANEOUS VARIATIONS WITH TIME

Eye	Minutes					
	0	20	40	70	100	130
1	2.6	2.5	2.5	2.5	2.7	2.2
2	2.3	2.4	2.5	2.7	3.0	2.9
3	5.3	5.7	4.7	4.3	4.3	4.3
4	3.7	4.2	4.3	4.2	4.5	4.8
5	2.2	2.2	2.3	2.3	2.4	2.5
6	1.8	1.7	1.5	1.5	1.5	1.6

*Flow in μl/min at 15 mm Hg.

reveal undisturbed structures within Schlemm's canal and along the external wall, but this required careful cutting, because some of the tissues within the canal were firmly adherent to the trabecular meshwork. Scanning electron micorscopy of the opened canal in normal eyes revealed thick structures consisting of nonfibrillar homogeneous tissue extending at a slightly oblique angle along the canal, joining a ridge of tissue along the external wall, as shown in Figure 2. These structures seemed to represent septa previously firmly adherent to trabecu-

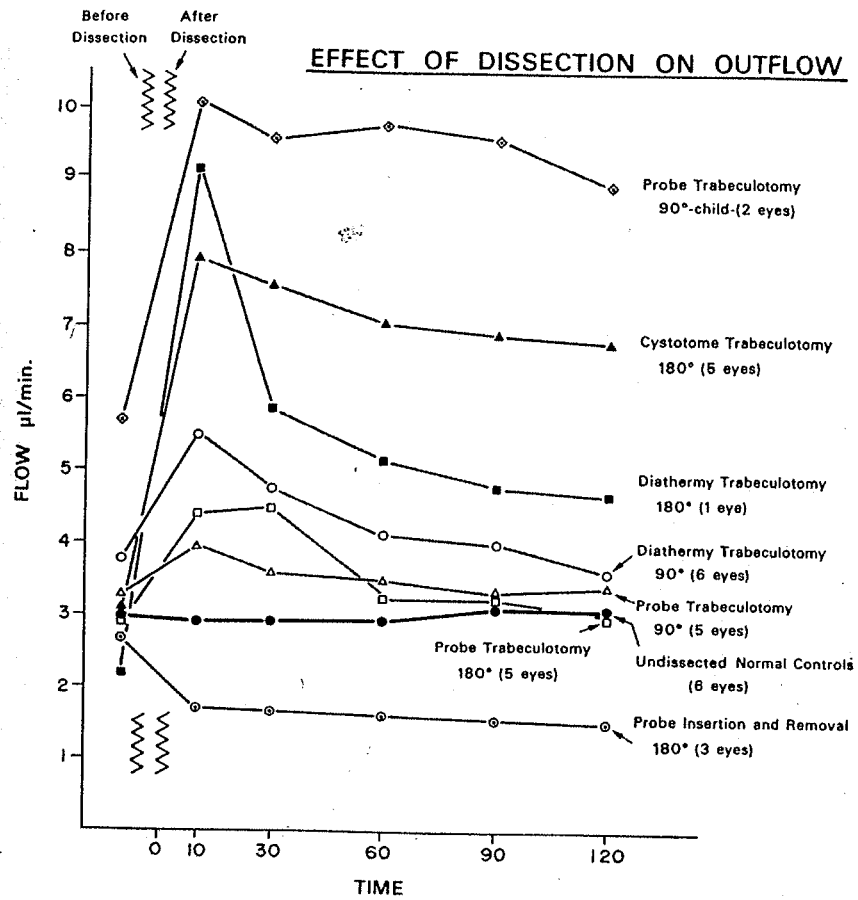

Fig. 1 (Johnstone and Grant). Aqueous perfusion steady-state flow rate mean values at 15 mm Hg pressure in groups of postmortem human eyes before and at intervals during 120 minutes after various dissections and manipulations were performed on Schlemm's canal, in comparison with the spontaneous variation of the mean in a group of undissected control eyes.

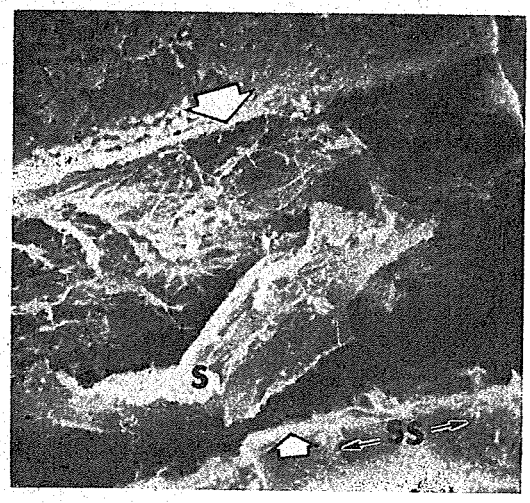

Fig. 2 (Johnstone and Grant). Scanning electron micrograph of Schlemm's canal (between large arrows) after trabecular meshwork has been dissected away with razorblade knife and forceps, revealing a large septum (S) left intact within the canal anterior to the scleral spur (SS) (×100).

lar meshwork. The prominent ridges along the posterior portion of the external wall, which were joined by septa, ran in a circumferential fashion at a slightly oblique angle. An infolding was present along the posterior border of the ridges forming a narrow zone of discontinuity. Several deep clefts, apparently representing collector channel entrances, were visible at intervals along this line of discontinuity.

Results of experimental procedures

1. Trabeculotomy performed internally with a cystotome in half the circumference caused a marked increase in outflow in each of five eyes, as recorded in Table 2. During 120 minutes of perfusion after trabeculotomy, the rate of flow generally remained high, with only a slight tendency to decrease toward pretrabeculotomy values, as shown in Figure 1 where mean values for the group are plotted.

As observed through the operating microscope, the cystotome generally passed along near the scleral spur, tending to push trabecular tissue ahead of it, but usually leaving the anterior portion of the trabecular meshwork in place. The residual material was rather ragged and what was exposed of the external wall of the canal had an irregular pattern.

From light microscopy of histologic sections (Fig. 3) it was evident that in addition to disruption of the trabecular meshwork the cystotome trabeculotomy caused damage to endothelium of the external wall of Schlemm's canal, disruption of septa, and splitting along the posterior wall of the canal. Scanning electron microscopy (Fig. 4) showed that a strip of trabecular meshwork was pulled from its attachments and moved ahead of the cystotome, leaving structures within the canal in a configuration suggesting that prior to disruption they had been drawn away from the external wall.

Ab externo procedures on Schlemm's canal gave the following results.

2A. Ab externo insertion of a nylon suture circumferentially in Schlemm's canal was accomplished without difficulty, and although the suture had a diameter of only 0.13 mm compared with the 0.275 mm of the steel trabeculotomy probe, it stretched and distorted the walls of the canal. Light microscopy of sections after insertion of the suture showed damage to the trabecular meshwork, to the endothelium of both the internal and external walls, compression of scleral lamellae along the external wall, and splitting

TABLE 2

PERFUSION FLOW RATE* BEFORE AND AFTER CYSTOTOME TRABECULOTOMY IN HALF THE CIRCUMFERENCE

Eye	Minutes						
	Before		After Trabeculotomy				
	10	0	10	30	60	90	120
7	4.0	—	8.0	7.7	7.7	7.5	6.8
8	2.9	—	10.8	10.8	10.3	10.1	9.8
9	4.3	—	6.6	6.8	6.7	6.3	6.2
10	1.8	—	5.3	4.3	3.7	4.0	4.0
11	2.4	—	9.0	8.3	7.8	6.8	6.5

* Flow in μl/min at 15 mm Hg.

Fig. 3 (Johnstone and Grant). rabecular meshwork and also disr

f tissue along the posteri urded in Figure 5. Ab ext eculotomy ruptured the tr

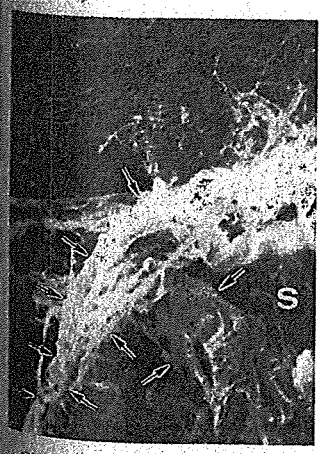

Fig. 4 (Johnstone and Grant). icrograph demonstrating a st eshwork (arrows) which had n cystotome just anterior to SS). In the sulcus (S) of Sch hich the cystotome was remov ts do not appear to be com

DOCKET ALARM

Explore Litigation Insights

Docket Alarm provides insights to develop a more informed litigation strategy and the peace of mind of knowing you're on top of things.

Real-Time Litigation Alerts

Keep your litigation team up-to-date with **real-time alerts** and advanced team management tools built for the enterprise, all while greatly reducing PACER spend.

Our comprehensive service means we can handle Federal, State, and Administrative courts across the country.

Advanced Docket Research

With over 230 million records, Docket Alarm's cloud-native docket research platform finds what other services can't. Coverage includes Federal, State, plus PTAB, TTAB, ITC and NLRB decisions, all in one place.

Identify arguments that have been successful in the past with full text, pinpoint searching. Link to case law cited within any court document via Fastcase.

Analytics At Your Fingertips

Learn what happened the last time a particular judge, opposing counsel or company faced cases similar to yours.

Advanced out-of-the-box PTAB and TTAB analytics are always at your fingertips.

API

Docket Alarm offers a powerful API (application programming interface) to developers that want to integrate case filings into their apps.

LAW FIRMS

Build custom dashboards for your attorneys and clients with live data direct from the court.

Automate many repetitive legal tasks like conflict checks, document management, and marketing.

FINANCIAL INSTITUTIONS

Litigation and bankruptcy checks for companies and debtors.

E-DISCOVERY AND LEGAL VENDORS

Sync your system to PACER to automate legal marketing.