

# Percutaneous Transcatheter Implantation of an Aortic Valve Prosthesis for Calcific Aortic Stenosis

## First Human Case Description

Alain Cribier, MD; Helene Eltchaninoff, MD; Assaf Bash, PhD; Nicolas Borenstein, MD; Christophe Tron, MD; Fabrice Bauer, MD; Genevieve Derumeaux, MD; Frederic Anselme, MD; François Laborde, MD; Martin B. Leon, MD

**Background**—The design of a percutaneous implantable prosthetic heart valve has become an important area for investigation. A percutaneously implanted heart valve (PHV) composed of 3 bovine pericardial leaflets mounted within a balloon-expandable stent was developed. After ex vivo testing and animal implantation studies, the first human implantation was performed in a 57-year-old man with calcific aortic stenosis, cardiogenic shock, subacute leg ischemia, and other associated noncardiac diseases. Valve replacement had been declined for this patient, and balloon valvuloplasty had been performed with nonsustained results.

**Methods and Results**—With the use of an antegrade transseptal approach, the PHV was successfully implanted within the diseased native aortic valve, with accurate and stable PHV positioning, no impairment of the coronary artery blood flow or of the mitral valve function, and a mild paravalvular aortic regurgitation. Immediately and at 48 hours after implantation, valve function was excellent, resulting in marked hemodynamic improvement. Over a follow-up period of 4 months, the valvular function remained satisfactory as assessed by sequential transesophageal echocardiography, and there was no recurrence of heart failure. However, severe noncardiac complications occurred, including a progressive worsening of the leg ischemia, leading to leg amputation with lack of healing, infection, and death 17 weeks after PHV implantation.

**Conclusions**—Nonsurgical implantation of a prosthetic heart valve can be successfully achieved with immediate and midterm hemodynamic and clinical improvement. After further device modifications, additional durability tests, and confirmatory clinical implantations, PHV might become an important therapeutic alternative for the treatment of selected patients with nonsurgical aortic stenosis. (*Circulation*. 2002;106:3006-3008.)

**Key Words:** stenosis, aortic ■ valves, prosthetic ■ prosthesis ■ catheterization

Percutaneous catheter-based systems for the treatment of valvular heart disease have been designed and studied in animal models for several years.<sup>1-4</sup> Recently, Bonhoeffer et al,<sup>5,6</sup> using a bovine jugular vein valve mounted within a stent, performed the first in-human percutaneous implantations of artificial valves in children with right ventricle to pulmonary prosthetic conduits.

The goals of our research project were to develop a biological heart valve, mounted on a specially designed balloon-expandable stent, which could be delivered percutaneously via standard catheter-based techniques and implanted within a diseased aortic valve in calcific aortic stenosis. This concept was based on personal unpublished autopsy observations on calcific aortic stenosis showing that a stent could effectively open while strongly adhering within the native

diseased valve without impairing the coronary ostia or the mitral valve.

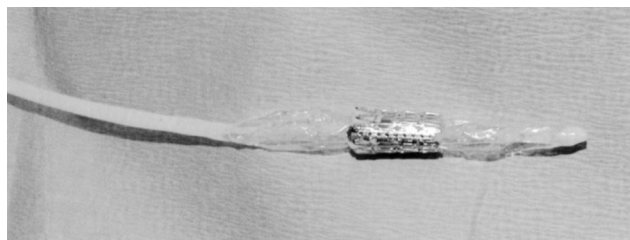
An original percutaneous heart valve (PHV) was developed (Percutaneous Valve Technologies, Inc), which consisted of 3 bovine pericardial leaflets mounted within a tubular, slotted, stainless steel balloon-expandable stent, 14 mm in length, designed to achieve a diameter of 21 to 23 mm. PHV function and durability were first tested in ex vivo pulse duplicator models. Valve durability passed 100 million cycles (2 and a half years). In animal models, the PHV was accurately delivered by balloon inflation at various cardiac sites<sup>7</sup> in 60 sheep. Acute and short-term valve functions were satisfactory. Implantation in the subcoronary aortic valve position was technically difficult in this animal model (which varies considerably from humans) and was

Received September 5, 2002; revision received October 18, 2002; accepted October 20, 2002.

From the Department of Cardiology (A.C., H.E., C.T., F.B., G.D., F.A.), Charles Nicolle Hospital, University of Rouen, Rouen, France; the Centre d'Experimentation et de Recherche Appliquée (CERA) (N.B., F.L.), Institut Montsouris, Paris, France; the Cardiovascular Research Foundation (M.B.L.), Lenox Hill Hospital, New York, NY; and Percutaneous Valve Technologies, Fort Lee, NJ (A.B.).

Correspondence to Pr Alain Cribier, Service de Cardiologie, Hôpital Charles Nicolle, 1 rue de Germont, 76 000, Rouen, France. E-mail Alain.Cribier@chu-rouen.fr

© 2002 American Heart Association, Inc.



**Figure 1.** The percutaneous valve crimped over the 30-mm-long balloon before implantation.

frequently associated with early migration (<15 days) because of the lack of any calcific or fibrotic lesion. Increase in valvular thickness was commonly observed at 1 to 3 months after implantation in the venous system (pulmonary valve) but not in the arterial system (descending aorta).

## Methods

### Patient

The first human implantation of this PHV was a “last-resort” case in a 57-year-old man with severe calcific aortic stenosis for whom aortic valve replacement had been declined by several cardiac surgical teams because of hemodynamic instability and significant comorbidities. His medical history included peripheral vascular disease with aorto-bifemoral bypass in 1996, silicosis, lung cancer in 1999, and chronic pancreatitis. He presented with cardiogenic shock (systolic blood pressure 80 mm Hg, cyanosis, and oliguria), bilateral pleural effusions and pulmonary edema, and subacute ischemia of the right leg due to recent occlusion of the right limb of the aorto-femoral bypass. Transthoracic echocardiography indicated a severely calcified bicuspid aortic valve with a mean transvalvular gradient of 30 mm Hg, valve area 0.6 cm<sup>2</sup>, and ejection fraction 14%. No myocardial contractility reserve was shown on dobutamine stress-echocardiography. Because of the severe peripheral vascular disease (the left limb of the aorto-femoral bypass was also severely narrowed), aortic valvuloplasty was performed with the transseptal antegrade approach with 20-mm-diameter balloon inflations. He sustained initial hemodynamic improvement with a reduction in gradient to 13 mm Hg and an increase in valve area to 1.06 cm<sup>2</sup>. During the ensuing week, however, his condition deteriorated with recurrence of cardiogenic shock and impending death (systolic blood pressure 70 mm Hg despite vasopressors and ejection fraction of 8% to 12%). Under these desperate circumstances, as a last-resort, potentially lifesaving intervention that might also bridge surgical valve replacement, the approval of our Institutional Ethics Committee was obtained, and the patient and his relatives consented to attempted implantation of the investigational PHV.

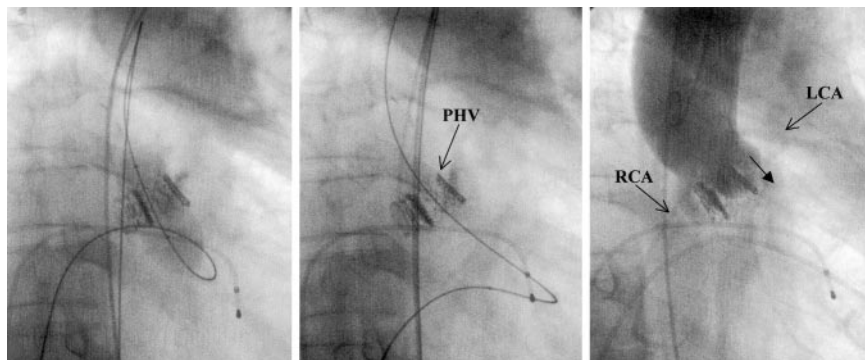
### Procedure

The procedure was undertaken under mild sedation and local anesthesia. A 5F catheter from the left femoral artery was used for continuous blood pressure monitoring, and the antegrade approach from the right femoral vein was used for PHV insertion. After standard transeptal catheterization, a straight 0.035-inch guidewire was advanced across the stenotic aortic valve through a balloon flotation catheter. After advancement of the balloon catheter into the descending aorta, the guidewire was exchanged for a stiff 260-cm-long guidewire, which was snared from the left femoral arterial access site and externalized via the arterial sheath. A 24F sheath was inserted into the right femoral vein, and the interatrial septum was dilated with a 10-mm-diameter balloon catheter. With the use of a mechanical crimping device, the PHV was securely crimped over a 3-cm-long, 23-mm-diameter balloon catheter (NuMED) (Figure 1). The PHV was easily advanced through the sheath, across the interatrial septum, and within the diseased stenotic aortic valve. With the valvular calcification used as a marker, the PHV was placed at midposition of the aortic valve. The balloon was then maximally inflated, rapidly deflated, and immediately withdrawn (Figure 2). Hemodynamic assessment and left ventricular and supraortic angiograms were performed. A transesophageal echocardiography was obtained immediately after the procedure and repeated at day 7 and every 2 weeks thereafter to assess the PHV function.

### Results

Cardiac standstill was present during the 20 seconds of final PHV deployment. Thereafter, the aortic pressure rose steadily and stabilized at 120/60 mm Hg. Immediately after the procedure, mean transvalvular gradient was 6 mm Hg, left ventricular end-diastolic pressure 25 mm Hg, cardiac index 2.5 L/min per square meter, and calculated aortic valve area 1.9 cm<sup>2</sup> according to Gorlin’s formula.<sup>8</sup> A left ventricular angiogram revealed a normal flow across the aortic valve, no mitral regurgitation, and an ejection fraction of 17%. A supraortic angiogram demonstrated that both coronary ostia were patent and well removed from the valve apparatus and showed mild paravalvular aortic regurgitation (Figure 2). Procedure and fluoroscopy times were 126 and 24 minutes, respectively.

Transesophageal echocardiography performed within 30 minutes of PHV implantation revealed a completely excluded native aortic valve, circular stent geometry with a diameter of 21 mm, optimal PHV function with a mean gradient of 9 mm Hg, a valve area of 1.6 cm<sup>2</sup> by planimetry in the cross-section view, and a moderate paravalvular regurgitation through a nonapposed calcified commissure of the bicuspid aortic valve.



**Figure 2.** PHV delivery within the native calcific valve. Left, Maximal balloon inflation (23 mm) for valve delivery. Middle, The PHV in position at mid part of the native aortic valve, pushing aside the calcific leaflets. Right, Supraortic angiogram after PHV implantation showing no aortic regurgitation across the PHV and a mild paravalvular regurgitation (arrow). Both coronary ostia are patent and removed from the valve prosthesis. LCA indicates left coronary artery; RCA, right coronary artery.

### Follow-Up

The postprocedural treatment included permanent anticoagulation with heparin and aspirin and intravenous administration of vasopressors at decreasing doses over the first 4 weeks after PHV implantation.

### PHV Echocardiographic Assessment

The PHV function remained satisfactory on transesophageal echocardiographies performed at 1, 4, 7, and 9 weeks after implantation. The PHV leaflets remained thin and mobile with no sign of PHV regurgitation and unchanged paravalvular regurgitation. By planimetry, the aortic valve area was 1.6, 1.6, 1.5, and 1.5 cm<sup>2</sup>, respectively, and the mean transvalvular gradient 15, 10, 8, and 14 mm Hg, respectively. The left ventricular ejection fraction remained poor, in the range of 13% to 20%.

### Clinical Evolution

In the next 48 hours after PHV implantation, there was a dramatic clinical improvement with reduced signs of congestive heart failure, and the patient could resume off-bed activities.

Several noncardiac-related complications occurred during the subsequent 4-month follow-up: an episode of pulmonary embolism at day 3, requiring intravenous fibrinolysis; an episode of septicemia at day 10, starting with septic shock; and a progressive worsening of the right leg ischemia, requiring a midhigh amputation 10 weeks after PHV implantation as the only possible option. The patient's clinical condition progressively deteriorated after surgery, with permanent infection and lack of healing of the amputation site, weight loss, and bedsores eschars, leading to death 17 weeks after PHV implantation. No acute episode of heart failure occurred over this follow-up period. Unfortunately, autopsy could not be obtained.

### Discussion

This dramatic case demonstrates the feasibility of implanting a prosthetic heart valve percutaneously, with the use of standard interventional techniques, within the native diseased valve of a patient with calcific aortic stenosis. A successful short-term therapeutic result was achieved under life-threatening circumstances. A satisfactory PHV function was observed on transesophageal echocardiography, which remained unchanged over 9 weeks of sequential assessment.

In aortic stenosis, emergency valve replacement is often rejected because of a prohibitive risk in the setting of cardiogenic shock.<sup>9</sup> Balloon valvuloplasty, which can be successfully used as a bridge to surgery in such desperate situations,<sup>10</sup> led to nonsustained improvement in our patient. PHV implantation could be easily, successfully, and safely performed with the transseptal approach. This antegrade approach, which was necessary because of severe peripheral artery disease, provided several advantages over the retro-

grade route used in animals: The 24F sheath could be inserted percutaneously into the right femoral vein, the long guidewire exiting the left femoral artery provided excellent support for tracking the device, and the PHV tended to move in concert with the heart, making precise placement more predictable. Also, it is likely that the poor left ventricular contractility helped stabilize the system during PHV deployment. Immediate and midterm PHV function were satisfactory, associated with early clinical improvement. The left ventricular function, however, remained severely depressed in this patient who had no myocardial contractility reserve. Finally, secondary surgical valve replacement could never be considered because of noncardiac complications.

At present, the PHV is targeted for end-stage patients with severe aortic stenosis not amenable to surgical valve replacement. Further indications might follow from ongoing chronic studies in animals with a newly designed PHV. The optimal anticoagulation regimen after PHV implantation (heparin followed by oral anticoagulant and/or antiplatelet therapy) will also be assessed in these studies. In the future, with further device modifications and corroborative clinical studies, this less invasive, catheter-based approach to the treatment of aortic stenosis may become an important and versatile therapeutic alternative.

### Acknowledgments

The authors thank Stanton Rowe and Stanley Rabinovitch from Percutaneous Valve Technologies, Inc, Fort Lee, NJ, for their support in the research program and in the development of the device.

### References

1. Davies H. Catheter mounted valve for temporary relief of aortic insufficiency. *Lancet*. 1965;1:250.
2. Andersen HR, Knudsen LL, Hasenkam JM. Transluminal implantation of artificial heart valves: description of a new expandable aortic valve and initial results with implantation by catheter technique in closed chest pigs. *Eur Heart J*. 1992;13:704-708.
3. Bonhoeffer P, Boudjemline Y, Saliba Z, et al. Transcatheter implantation of a bovine valve in pulmonary position. *Circulation*. 2000;102:813-816.
4. Boudjemline Y, Bonhoeffer P. Steps toward percutaneous aortic valve replacement. *Circulation*. 2002;105:775-778.
5. Bonhoeffer P, Boudjemline Y, Saliba Z, et al. Percutaneous replacement of pulmonary valve in a right-ventricle to pulmonary-artery prosthetic conduit with valve dysfunction. *Lancet*. 2000;356:1403-1405.
6. Bonhoeffer P, Boudjemline Y, Qureshi SA, et al. Percutaneous insertion of the pulmonary valve. *J Am Coll Cardiol*. 2002;39:1664-1669.
7. Cribier A, Eltchaninoff H, Borenstein N, et al. Trans-catheter implantation of balloon-expandable prosthetic heart valves: early results in an animal model. *Circulation*. 2001;104(suppl II):II-552. Abstract.
8. Gorlin R, Gorlin G: Hydraulic formula for calculation of area of stenotic mitral valve, other valves and central circulatory shunts. *Am Heart J*. 1951;41:1-10.
9. Desnoyers MR, Salem DN, Rosenfield K, et al. Treatment of cardiogenic shock by emergency aortic balloon valvuloplasty. *Ann Intern Med*. 1988; 108:833-835.
10. Cribier A, Remadi F, Koning R, et al. Emergency balloon valvuloplasty as initial treatment of patients with aortic stenosis and cardiogenic shock. *N Engl J Med*. 1992;323:646.