

## Successful Transradial Use of the GuideLiner Catheter to Selectively Treat Severe Disease in the LAD

### PHYSICIAN

Mark Spence, MB BCH BAO Honours, MRCP (Edinburgh), MD  
Colm Hanratty, MD, FRCPI  
Royal Victoria Hospital, Belfast, Northern Ireland

### PRESENTATION

A male patient presented with an acute coronary syndrome and uncontrolled atrial fibrillation. The patient has a medical history of hypertension and hyperlipidemia. He presented with Inferolateral ST depression on 12-lead ECG; troponin level T 0.05. An echocardiogram showed asymmetrical septal hypertrophy and inferior hypokinesis.

### INITIAL FINDINGS

Coronary angiography confirmed severe ostial disease in the RCA, extending into the proximal segment of the artery and a long segment of heavily calcified disease in the mid-LAD (Figure 1). The LCX showed minimal disease and overall LV function was mildly impaired (LVEDP 16mmHg).

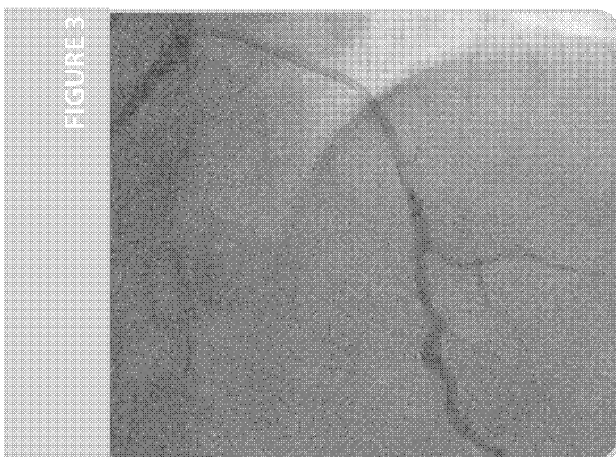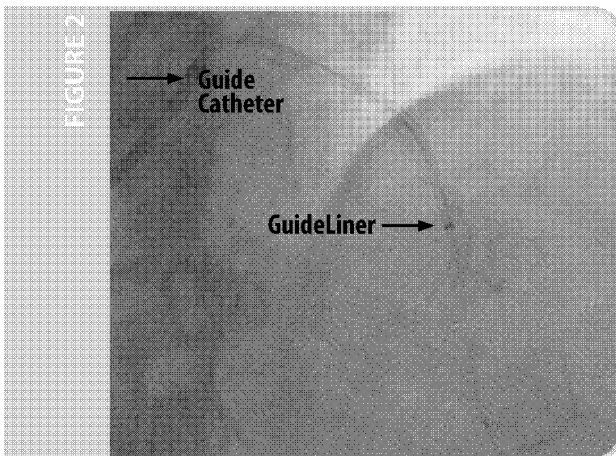
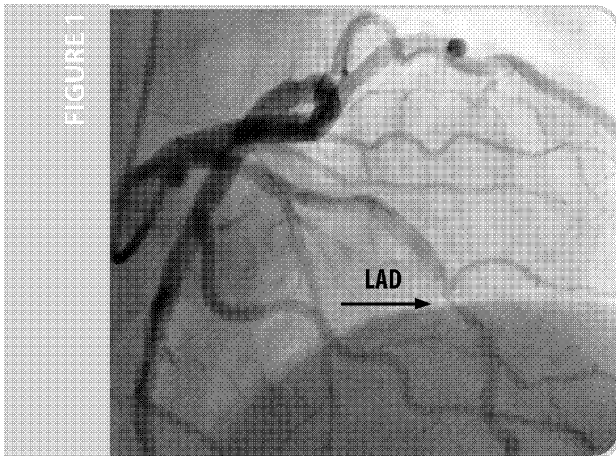
### TREATMENT

The RCA was treated satisfactorily with a Liberté® 3.0 x 12mm bare-metal stent. Initial access to treat the LAD was obtained through the transradial approach using a 7F JL3.5 Asahi sheathless guide catheter. A 1.5mm Rotablator® burr was used to modify the calcified LAD. The lesion was predilated serially with an Apex® 3.0 x 20mm balloon. Due to the friction encountered in the proximal LAD and guide catheter back out, a 3.0 x 38mm Taxus® stent could not be delivered to the target lesion.

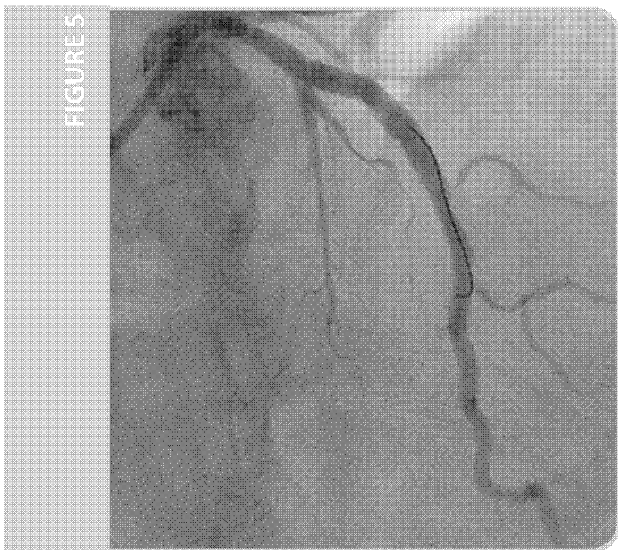
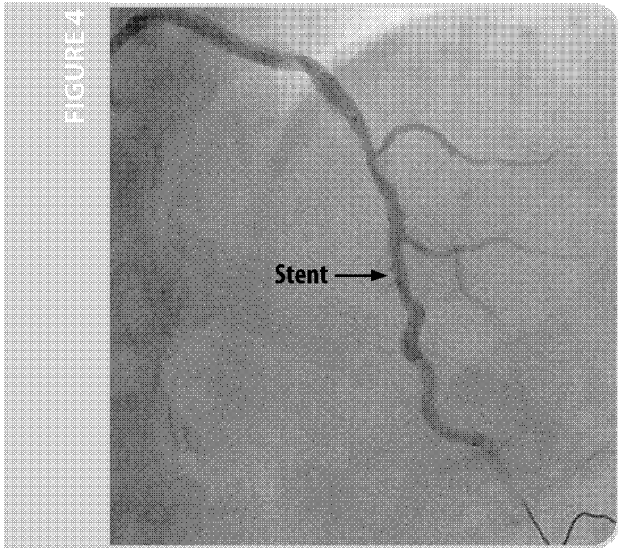
### TREATMENT OF THE LAD WITH GUIDELINER SUPPORT

A 6F GuideLiner catheter was inserted over the in-place .014" guidewire and easily passed through the proximal lesion and into the mid-LAD (Figure 2). Selective contrast injection improved visualization of the target vessel (Figure 3) and facilitated accurate stent sizing and positioning.

*(continued on back)*



VSIQXM\_E00044656



## TREATMENT (CONTINUED)

The GuideLiner catheter was used to successfully deliver a 3.0 x 38mm Taxus stent to the mid-LAD, which was subsequently overlapped with an additional 4.0 x 24mm Taxus stent proximally (Figure 4). The GuideLiner catheter was then used to deliver a 4.0 x 15mm Quantum™ balloon for post-dilatation stent expansion.

## CONCLUSION AND POST PROCEDURE

There was a good angiographic end result (Figure 5), following stenting and post-dilatation. IVUS confirmed the stent was apposed and optimally sized and deployed. The patient was discharged well, without complication the following day and was asymptomatic at 8 week review.

## SUMMARY

By overcoming resistance in the proximal LAD, the GuideLiner catheter enabled successful delivery of interventional equipment to the heavily calcified mid-vessel.

The facility for selective contrast injection via the GuideLiner catheter into the target vessel improved visualization facilitating optimal stent sizing and placement with limited total contrast volume.

### Mark Spence, MB BCH BAO Honours, MRCP (Edinburgh), MD

Dr. Spence received his MD from Queen's University Belfast in Northern Ireland, UK and is an Honorary Senior Lecturer at the University. Dr. Spence completed an interventional cardiology fellowship, specializing in Coronary and Structural Heart Disease, at Royal Jubilee Hospital in Vancouver, British Columbia, Canada. In addition, Dr. Spence completed a fellowship in Congenital Heart Disease Intervention at Royal Brompton Hospital and Guy's and St. Thomas' Hospitals in London, UK. He now practices at Royal Victoria Hospital in Belfast as a Consultant Interventional Cardiologist.



### Colm Hanratty, MD, FRCPI

Dr. Hanratty received his MD from Queen's University Belfast in Northern Ireland, UK followed by a fellowship at North Shore Hospital in Sydney, Australia. He now practices with the Belfast Trust as a Consultant Interventional Cardiologist.



GuideLiner catheters are intended to be used in conjunction with guide catheters to access discrete regions of the coronary and/or peripheral vasculature, and to facilitate placement and exchange of guidewires and other interventional devices. Please see the Instructions for Use for a complete listing of the indications, contraindications, warnings and precautions.

CAUTION: Federal law (U.S.A.) restricts this device to sale by or on the order of a physician.

GuideLiner is a registered trademark of Vascular Solutions, Inc. All other trademarks and registered trademarks are property of their respective owners.

©2016 Vascular Solutions, Inc. All rights reserved. ML2212 Rev. B 10/16



Vascular Solutions, Inc.  
6464 Sycamore Court North  
Minneapolis, Minnesota 55369 USA  
Customer Service:  
United States: 888.240.6001  
International: (001) 763.656.4298  
customerservice@vasc.com  
www.vasc.com

VSIQXM\_E00044657