

## Successful Use of the GuideLiner Catheter to Treat Sequential Distal Carotid Artery Stenoses

### PHYSICIAN

George Petrossian, MD  
St. Francis Hospital, Roslyn, New York

### PRESENTATION

The patient is a male with a history of hypertension and hypercholesterolemia. He has a remote history of neck surgery for a parotid tumor, followed by radiation.

Five months ago, he presented with a left hemispheric CVA, with moderate residual arm weakness. Angiography demonstrated a 50% ulcerated right internal carotid stenosis. The left carotid contained a proximal 90% stenosis at the origin, an 80% tubular mild left ICA stenosis distal to an angulated segment, and an 80% stenosis in the distal left ICA (petrous segment). At that time, an 8mm x 10mm, tapered Xact® stent was placed at the proximal stenosis with distal protection.

Two weeks ago, the patient developed one hour of severe right arm weakness which resolved. He then underwent repeat carotid angiography.

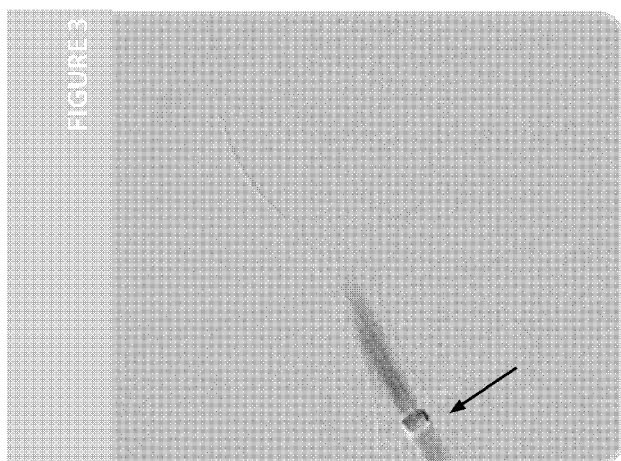
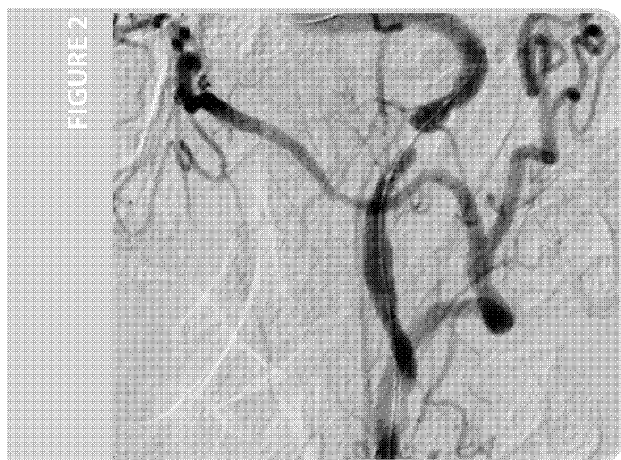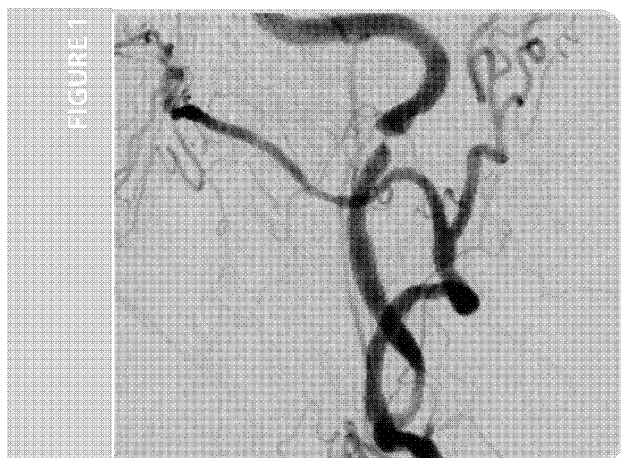### INITIAL FINDINGS

Carotid angiography demonstrated a stable 50% ulcerated plaque within the right ICA. The left ICA proximal stent was widely patent. The mid left ICA contained an 80% tubular stenosis and the distal left ICA (petrous segment) had progressed and contained a 95% stenosis (Figure 1).

### TREATMENT

Without distal protection, a 3mm x 15mm balloon was used to perform PTA of the 2 distal stenoses (Figure 2). A 7mm x 20mm Xact stent would not cross the distal lesion, and was deployed at the more proximal lesion, with a similar 7mm x 20mm stent placed just proximally. A significant residual stenosis was present at the distal stent margin as well as the most distal lesion in the petrous segment. Further attempts to cross the remaining lesions with a 2.0mm balloon over a 0.014" guidewire were unsuccessful.

*(continued on back)*



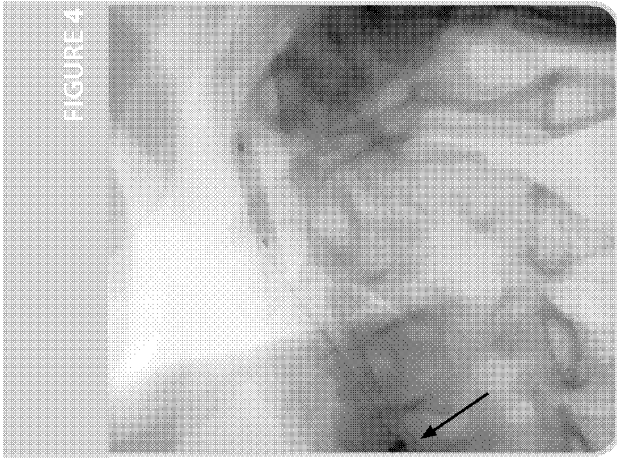


FIGURE 4

## TREATMENT WITH GUIDELINER CATHETER

A 0.014" BMW 300cm guidewire was placed distally in the left ICA and the Guideliner catheter was advanced into the stented segment of the left ICA (Figure 3). A 2mm x 15mm OTW balloon crossed the distal lesion with Guideliner support and a 300cm Wiggle™ guidewire was placed distally after removal of the BMW guidewire.

A 3.5mm x 15mm bare metal stent and a 4.5mm x 18mm bare metal stent were deployed distally (Figure 4) within the left ICA and post dilated (Figure 5). The end result was a widely patent left ICA (Figure 6).

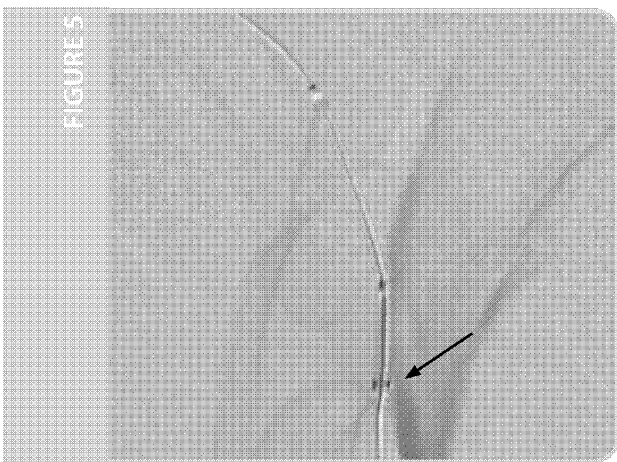


FIGURE 5

## CONCLUSION

The Guideliner catheter provided the support necessary to advance balloon and stent catheters to the distal left ICA in a patient with prior radiation, vessel tortuosity and prior stent implantation. Without the Guideliner catheter, this procedure would have been unsuccessful.




FIGURE 6

## George Petrossian, MD

Dr. Petrossian received his M.D. from The Mount Sinai School of Medicine. He completed his Medical and Cardiology training at Columbia Presbyterian Hospital, New York and his Interventional Cardiology training at Massachusetts General Hospital. He is the Director of Interventional Cardiovascular Procedures, St. Francis Hospital, The Heart Center, Roslyn, NY.



Guideliner catheters are intended to be used in conjunction with guide catheters to access discrete regions of the coronary and/or peripheral vasculature, and to facilitate placement and exchange of guidewires and other interventional devices. Please see the Instructions for Use for a complete listing of the indications, contraindications, warnings and precautions.

CAUTION: Federal law (U.S.A.) restricts this device to sale by or on the order of a physician.

Guideliner is a registered trademark of Vascular Solutions, Inc. All other trademarks and registered trademarks are property of their respective owners.

©2016 Vascular Solutions, Inc. All rights reserved. ML2326 Rev. B 10/16



Vascular Solutions, Inc.  
6464 Sycamore Court North  
Minneapolis, Minnesota 55369 USA  
Customer Service:  
United States: 888.240.6001  
International: (001) 763.656.4298  
customerservice@vasc.com  
www.vasc.com

VSIQXM\_E00044668