

The GuideLiner[®] Catheter in Complex Coronary Interventions

Utilización del catéter GuideLiner[®] en angioplastias coronarias complejas

To the Editor,

Stent placement frequently poses considerable difficulty in coronary interventions, especially in tortuous or calcified arteries and chronic occlusions; this is evidenced by the fact that failed stent deployment still occurs in 2.7% to 3.3% of the interventions undertaken.¹

In complex angioplasty procedures of this type, different strategies have been emerging to resolve the problem of inadequate guiding catheter support, including the use of high-support guide wires and techniques involving buddy wires, buddy balloons, or anchoring balloons (inflation of an anchoring balloon in side branches). Deep intubation of the coronary artery is another of the strategies, but is limited by the possible occurrence of the dissection of proximal plaques or total occlusion of the vessel during maneuvers of this type.

The GuideLiner[®] catheter (Vascular Solutions Inc., Minneapolis, Minnesota, United States) is a coaxial “mother and child” catheter, mounted on a monorail system, that extends the angioplasty guiding catheter and enables deep intubation of the coronary artery to achieve extra support and improve coaxial alignment. It has a distal end of 20 cm, consisting of a flexible extension with a radiopaque marker situated 2.7 mm from the tip and a coaxial exchange system 20 cm from the tip, joined to a 125-mm compact metal hypotube by means of a ring (Fig. 1). The flexible design of the catheter and the absence of a distal primary curve permit deep and theoretically atraumatic intubation of the coronary tree, increasing guiding catheter support, which enables selective injections and reduces the amount of contrast medium employed. In addition, it provides an extension to the guiding catheter that, on occasion, makes it possible to gain access to the ostia of hard-to-reach coronary arteries or coronary bypass grafts. It is compatible with standard guiding catheters (except those with a conical tip) and its lumen is 1 Fr smaller than that of the catheter utilized. We describe the initial experience with the use of the GuideLiner[®] in a single center.

The GuideLiner[®] was employed in 7 complex elective coronary interventions. Three of them involved chronic occlusions of right coronary artery (including 1 case of complete stent occlusion), another 2 were procedures in highly calcified right coronary arteries, and the remaining 2 were interventions in circumflex and anterior descending coronary arteries. In 2 cases the GuideLiner[®] was used from the start of the procedure as the instrument of choice, and in the other 5 when standard measures to increase the degree of support had failed.

A femoral approach using an 8-Fr introducer sheath was employed in every case; in 2 of them, the intervention was performed with bilateral access for contralateral injections (Fig. 1). Rotational atherectomy was carried out in 3 procedures, followed by the use of the GuideLiner[®] to advance the materials used in the angioplasty.

The characteristics of the patients and of the interventions are shown in the Table 1.

In 6 procedures, the GuideLiner[®] afforded adequate alignment of the catheter with the artery; however, in one case, deep vessel intubation was not achieved because the advance of the device was impeded by a stent implanted at a proximal level. In 4 cases, the GuideLiner[®] was considered key to the success of the intervention as it enabled the advance of the angioplasty materials, a maneuver that had not been achieved with other techniques. There were no complications related to the utilization of the device and the course

of the patients was favorable, with a mean postintervention hospital stay of 3.8 days.

There are few publications on the utilization of this catheter²⁻⁵ and they have not reported complications associated with its use.

Its monorail design permits rapid exchange and offers important advantages over its predecessors, the “five-in-six mother and child” catheters Heartrail II[®] (Terumo Corp., Tokyo, Japan), which had a coaxial system that made their utilization more demanding.⁵

Its use is not recommended in vessels measuring less than 2.5 mm or in saphenous vein grafts, although concerning the latter, cases have been published in which the GuideLiner[®] was especially useful as it provided good alignment with the graft.⁶

For optimal use of this device, the following recommendations can be taken into account:

- The GuideLiner[®] should be inserted using a guiding catheter over a first angioplasty guide wire in such a way that the tip protrudes a maximum of 10 cm beyond the guiding catheter tip. Intubation of more than 20 cm can result in the introduction of the entire GuideLiner[®] into the coronary artery, a circumstance that could complicate its withdrawal. In addition, the connection to the flexible segment should be situated in the straight portion of the guiding catheter in order to facilitate the passage of devices along it.
- It is recommended that the stents be advanced over the first angioplasty guide wire inserted, given that the second guide wire may be positioned outside the GuideLiner[®] and interfere with the deployment of the stent.

Despite the small number of cases, we consider that this catheter may be highly useful in complex coronary interventions, in which it provides extra support that considerably facilitates the advance of the materials used in angioplasty and avoids the potential complications associated with more aggressive techniques.

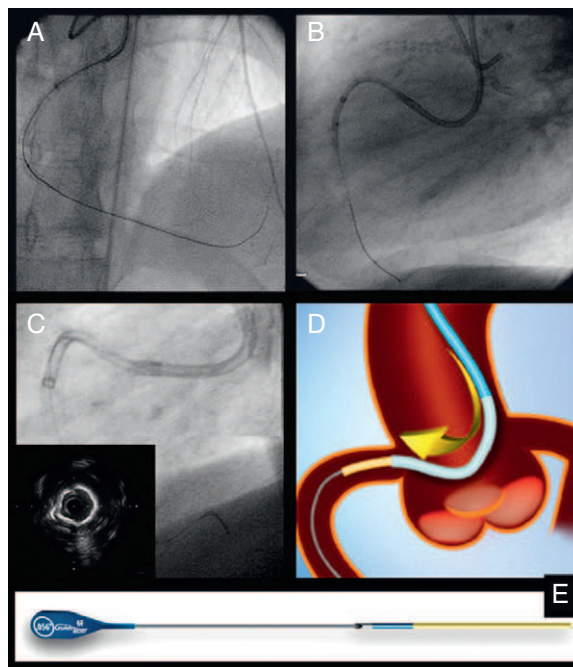


Figure 1. A and B, angioplasties to correct chronic total occlusion of right coronary artery involving bilateral access and the GuideLiner[®] catheter. C, selective intubation with GuideLiner[®] in a highly calcified right coronary artery. D and E, diagram.

Table 1
Baseline Characteristics of the Patients in Which the GuideLiner® Was Employed and Description of the Procedure

	Patient 1	Patient 2	Patient 3	Patient 4	Patient 5	Patient 6	Patient 7
Age, years	69	68	74	72	43	45	75
Sex	M	M	F	M	M	M	M
Logistic EuroSCORE, %	8	15	8	30 ^a	1	1	11 ^a
Ventricular dysfunction	Yes	No	Yes	Yes	No	No	Yes
Clinical indication	Resting angina	Non-Q-wave infarction	Positive ischemia test	Resting angina	Resting angina	Positive ischemia test	Positive ischemia test
Target vessel	LMC-AD	RC	CTO RC	RC ^b	CTO RC	CTO RC	CX
Duration of procedure, min	60	90	220	124	240	180	55
Fluoroscopy time, min	12.8	39.9	55	43	118	80	27.4
Contrast medium volume, ml	130	200	230	200	370	320	270
Length of hospital stay following angioplasty, days	14	2	1	7	1	1	1

AD, anterior descending coronary artery; CTO, chronic total occlusion; CX, circumflex coronary artery; F, female; LMC, left main coronary artery; M, male; RC, right coronary artery.

^a Patient no. 4 had chronic renal failure requiring hemodialysis, as well as severe peripheral arterial disease. Patient no. 7 had advanced chronic obstructive pulmonary disease.

^b Patient no. 4 had total occlusion of the right coronary artery stent; complete right coronary artery reconstruction was performed in a previous procedure.

Leire Unzué,* Felipe Hernández, María Teresa Velázquez, Julio García, Agustín Albarrán, and Javier Andreu

Unidad de Hemodinámica y Cardiología Intervencionista, Hospital 12 de Octubre, Madrid, Spain

*Corresponding author:

E-mail address: leireunzue@yahoo.es (L. Unzué).

Available online 12 October 2011

REFERENCES

1. Hynes B, Dollard J, Murphy G, O'Sullivan J, Ruggiero N, Margey R, et al. Enhancing back-up support during difficult coronary stent delivery: single-center case

- series of experience with the Heartrail II catheter. *J Invasive Cardiol.* 2011; 23:E43-6.
2. Mamas MA, Fath-Ordoubadi F, Fraser DG. Distal stent delivery with Guideliner catheter: first in man experience. *Catheter Cardiovasc Interv.* 2010;76: 102-11.
3. Kumar S, Gorog DA, Secco GG, Di Mario C, Kukreja N. The GuideLiner "child" catheter for percutaneous coronary intervention - early clinical experience. *J Invasive Cardiol.* 2010;22:495-8.
4. Rao U, Gorog D, Syzguna J, Kumar S, Stone C, Kukreja N. The GuideLiner "child" catheter. *EuroIntervention.* 2010;6:277-9.
5. Mamas MA, Fath-Ordoubadi F, Fraser D. Successful use of the Heartrail III catheter as a stent delivery catheter following failure of conventional techniques. *Catheter Cardiovasc Interv.* 2008;71:358-63.
6. Wiper A, Mamas M, El-Omar M. Use of the GuideLiner catheter in facilitating coronary and graft intervention. *Cardiovasc Revasc Med.* 2011;12:68.5-7.

doi: 10.1016/j.rec.2011.08.003

Variegate Porphyria and Atrial Fibrillation: Acute Attack Induced by Propafenone

Porfiria variegata y fibrilación auricular: ataque agudo inducido por propafenona

To the Editor,

Porphyrias are metabolic bone diseases caused by deficiencies of enzymes involved in heme biosynthesis. Acute hepatic porphyrias (AHPs) can present as episodes of acute porphyria with abdominal pain, autonomic dysfunction (hypertension, tachycardia, and gastrointestinal disorders), and deep motor neuropathy. Variegate porphyria (VP) is a type of autosomal dominant hepatic porphyria secondary to protoporphyrinogen oxidase activity deficiency that can present acute neurological manifestations and/or cutaneous photosensitivity. Drugs are the factors most commonly implicated as triggers of acute attacks. We describe a patient with VP who received class Ic antiarrhythmic agents for paroxysmal atrial fibrillation (AF) and presented with an acute episode of porphyria, which consisted of acute abdomen and syndrome of inappropriate antidiuretic hormone secretion (SIADH).

Our patient was a 40-year-old male with a history of VP diagnosed by skin biopsy and elevation of blood aminolevulinic

acid and porphobilinogen and fecal protoporphyrins who had a relative with the same condition but no activity to date. The patient experienced various episodes of paroxysmal AF. He was initially treated with flecainide but later switched to propafenone due to digestive intolerance. One week after initiating propafenone therapy, the patient began to have abdominal pain and bloody urine. He came to the emergency room and was referred to the internal medicine department for further study. During the examination, only the diffuse abdominal pain without accompanying signs of peritonism was relevant. The laboratory workup showed normal kidney function, GOT, 41 U/L; GPT, 43 U/L; alkaline phosphatase, 50 IU/L; GGT, 50 IU/L; LDH, 539 IU/L; sodium, 111 mEq/L; and plasma osmolality, 231 mOsm/L. The urinary tests showed urinary sodium of 109 mEq/L and elevated osmolality. The heart, thyroid, and adrenal panels were normal. An abdominal ultrasound showed no relevant findings; the Hoesch test was positive. Porphyrin and porphyrin precursor determination in urine showed an increase in porphobilinogen, as well as delta-aminolevulinic acid, coproporphyrin, and protoporphyrins in stools. Based on these findings and the normalization of biochemical and clinical parameters once propafenone was discontinued, an attack of propafenone-induced VP with SIADH as a form of expression was diagnosed. Hematin (5 mg/kg/day) was given for 4 consecutive days, and