

# Zero contrast retrograde chronic total occlusions percutaneous coronary intervention: a case series

Raja Hatem<sup>1,2,3</sup>, Matthew T. Finn<sup>1,2</sup>, Robert F. Riley<sup>4</sup>, Moses Mathur<sup>4</sup>, William L. Lombardi<sup>4</sup>, Ziad A. Ali<sup>1,2†</sup>, and Dimitri Karpaliotis<sup>1,2\*†</sup>

<sup>1</sup>Columbia University, 161 Fort Washington Avenue, 6th Floor, New York, NY 10032, USA; <sup>2</sup>Cardiovascular Research Foundation, 1700 Broadway, 8th Floor, New York, NY 10019, USA; <sup>3</sup>Hôpital du Sacré-Coeur de Montréal, Université de Montréal, 5400 Boul Gouin O, Montréal, QC H4J 1C5, Canada; and <sup>4</sup>Department of Cardiology, University of Washington Medical Center, 1959 NE Pacific St, Seattle, WA 98195, USA

Received 30 November 2017; accepted 28 March 2018; online publish-ahead-of-print 2 April 2018

## Introduction

Percutaneous coronary intervention (PCI) in patients with advanced chronic kidney disease (CKD) is associated with a high risk of contrast-induced nephropathy and resulting progression of CKD to need for renal replacement therapy. Chronic total occlusions (CTO) PCI is increasingly utilized in the treatment of refractory stable angina and ischaemic heart failure. Recent studies have described the feasibility of 'minimal' or 'zero' contrast PCI by employing intravascular imaging and intra-coronary physiology to guide successful stent implantation with resolution of ischaemia. We extended these techniques to CTO lesions via the retrograde approach.

## Case presentation

Two patients with estimated glomerular filtration rate  $\leq 15$  mL/min who presented with angina symptoms and had subsequent positive stress tests were referred for CTO-PCI. The patients had diagnostic angiography with minimal contrast. After a recovery period, the patients underwent successful retrograde zero contrast CTO-PCI with the use of adjunctive intravascular ultrasound imaging.

## Discussion

The described reports are the first two successful attempts at zero contrast retrograde procedures and demonstrate the feasibility of imaging and physiology-guided retrograde PCI without contrast administration in two patients with significant coronary artery disease requiring intervention. When indicated, zero contrast PCI offers the ability to treat obstructive coronary disease without worsening renal function in patients with severe CKD.

## Keywords

Chronic occlusion • Percutaneous coronary intervention • Retrograde • Chronic kidney disease • Contrast-induced nephropathy • Case series

## Learning points

- These cases describe a first-in-man technique utilizing zero contrast to perform retrograde chronic total occlusions percutaneous coronary intervention (PCI) to treat patients with concomitant coronary artery disease and chronic kidney disease (CKD).
- The procedure utilizes prior angiographic films together with intravascular imaging and invasive physiological testing to enable zero contrast retrograde lesion crossing and stenting.
- Minimal or zero contrast PCI, when indicated, offers the opportunity to improve overall outcomes related to ischaemic heart disease without risking worsening renal function or dialysis in patients with CKD.

\* Corresponding author. Tel: (212) 305-7060, Fax 212-305-0676, Email: dk2787@cumc.columbia.edu. This case report was reviewed by Joshua Chai and Dejan Milasinovic.

† These authors contributed equally to this work.

© The Author(s) 2018. Published by Oxford University Press on behalf of the European Society of Cardiology.

This is an Open Access article distributed under the terms of the Creative Commons Attribution Non-Commercial License (<http://creativecommons.org/licenses/by-nc/4.0/>), which permits non-commercial re-use, distribution, and reproduction in any medium, provided the original work is properly cited. For commercial re-use, please contact [journals.permissions@oup.com](mailto:journals.permissions@oup.com)

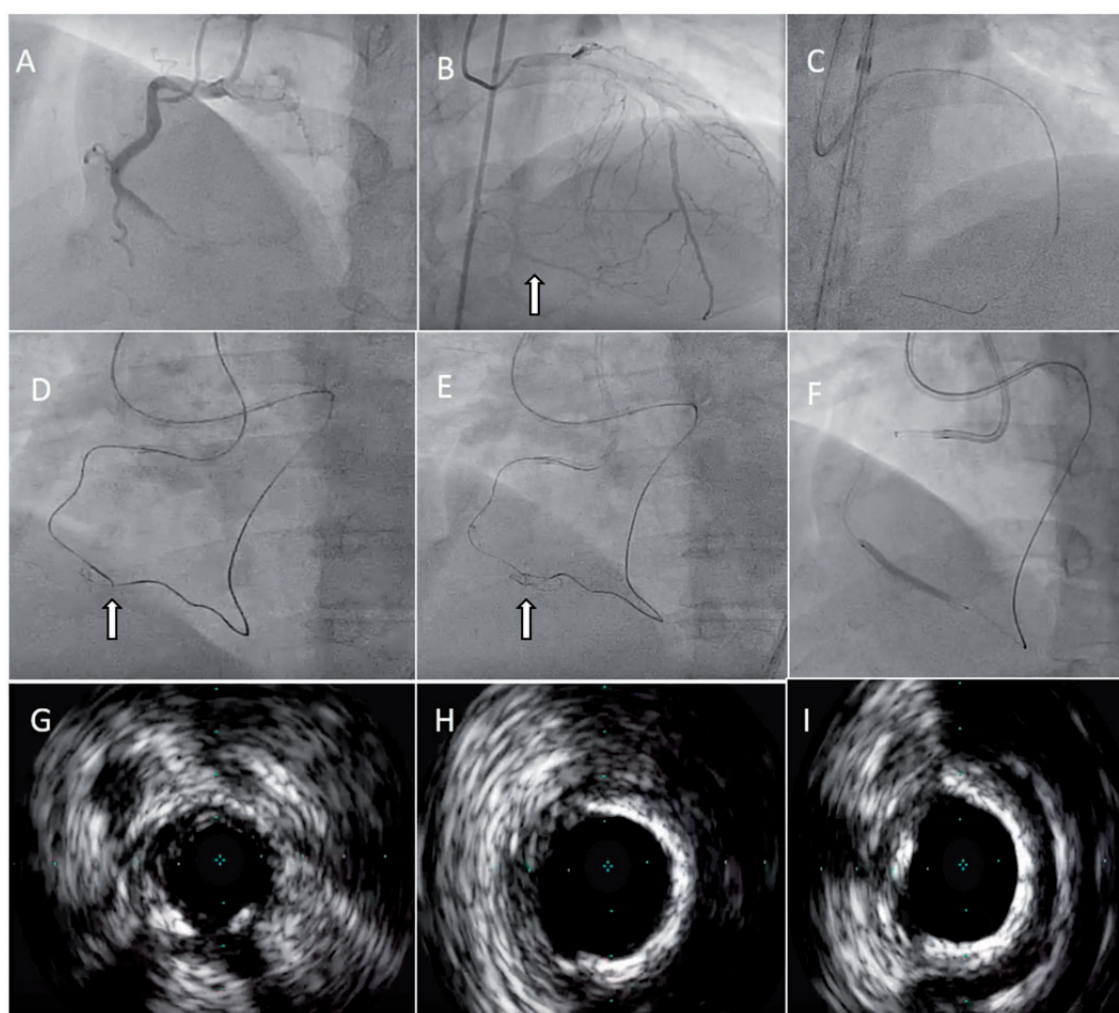
## Introduction

Percutaneous coronary intervention (PCI) in patients with advanced chronic kidney disease (CKD) is associated with a high risk of contrast-induced nephropathy (CIN), risking progression of CKD and need for renal replacement therapy.<sup>1,2</sup> We have recently described the feasibility and safety of imaging and physiology-guided PCI without contrast utilization by employing intravascular imaging and intracoronary physiology to guide successful stent implantation.<sup>3</sup> Chronic total occlusions (CTO) PCI is an increasingly utilized approach in the treatment of refractory stable angina and ischaemic heart failure with data demonstrating improved clinical and functional outcomes in selected patients.<sup>4</sup> We describe the feasibility and safety of imaging and physiology-guided PCI without contrast administration in two cases

using the retrograde approach, illustrating a successful method to treat this extreme risk subset of patients.

### Case 1: clinical background

A 54-year-old man with a history of Type I diabetes mellitus, hypertension, and CKD Stage IV with an estimated glomerular filtration rate (eGFR) of 15 mg/min/1.73 m<sup>2</sup> (normal:  $\geq 60$  mg/min/1.73 m<sup>2</sup>) presented for diagnostic angiography after a non-invasive nuclear scan, done for exertional chest pain, identified a moderate size and moderate severity ischaemic defect in the basal half of the inferior and inferolateral walls. Diagnostic angiography (20 mL contrast), demonstrated a right coronary artery (RCA) CTO (Figure 1A and B; Supplementary material online, Videos S1 and S2 Case S1).

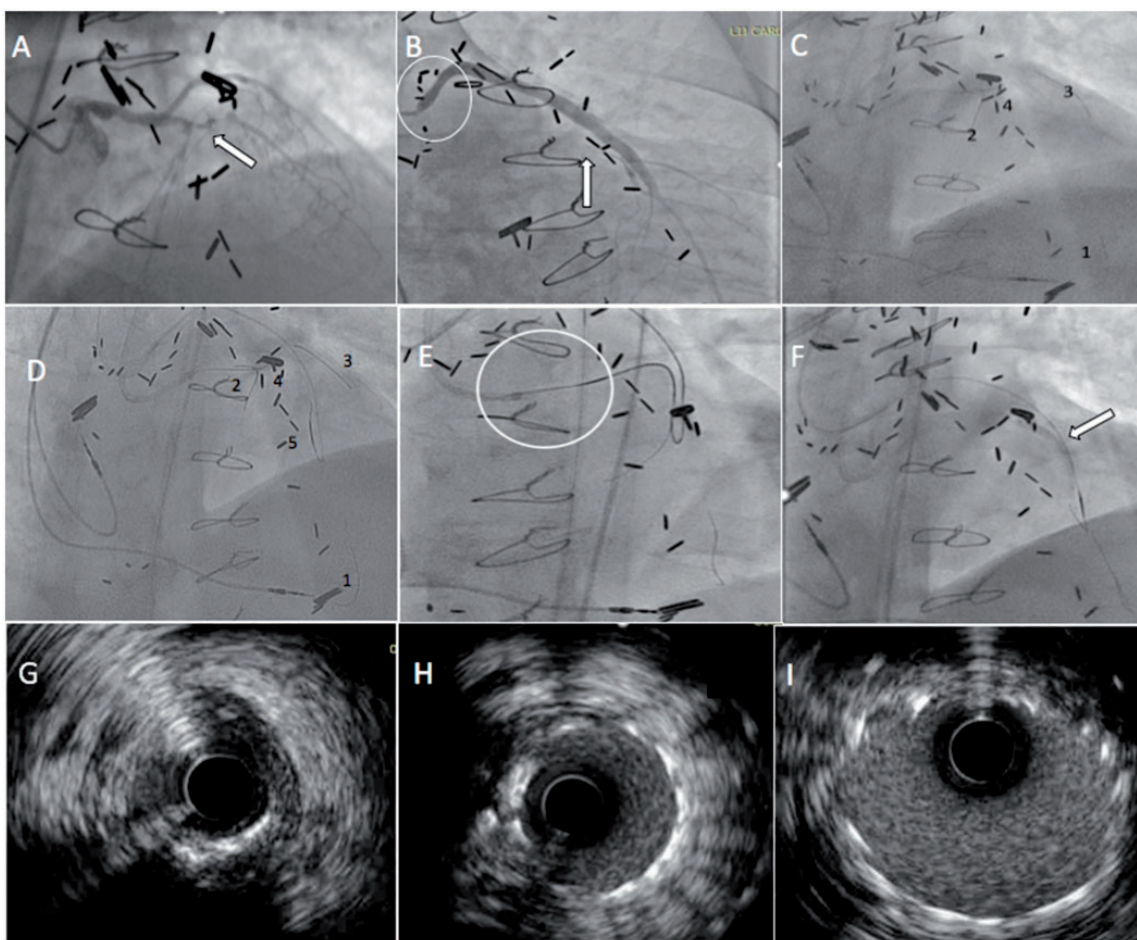


**Figure 1** (A and B) Diagnostic angiography performed 1-month prior to chronic total occlusions percutaneous coronary intervention demonstrating a right coronary artery chronic total occlusions and left anterior descending distal and septal collaterals to the right coronary (arrow). (C) Retrograde wiring via septal collateral. (D) Positioning of microcatheters at the proximal and distal chronic total occlusions caps to prepare for reverse controlled antegrade or retrograde subintimal tracking. (E) GuideLiner assisted reverse controlled antegrade or retrograde subintimal tracking (arrow). (F) Retrograde wire has been externalized and the patient is undergoing pre-stenting angioplasty for lesion preparation. (G) Intravascular ultrasound image of the pre-stenting angioplasty demonstrating luminal narrowing. (H and I) Distal and proximal intravascular ultrasound images (respectively) after stenting.

### Case 1: procedure description

The patient returned, after failing to respond to medical therapy, for staged CTO-PCI of the RCA 1 month after the initial diagnostic angiogram. Prior to the procedure, previous angiographic films were uploaded to the monitors as a guide for coronary wiring. Using those images as reference, a polymer jacketed hydrophilic wire (Fielder FC, Asahi Intecc, Japan) was successfully manipulated through a septal collateral up to the distal cap of the CTO (Figure 1C; Supplementary material online, Video S3 Case S1). Once the antegrade and retrograde base of operations were confirmed in

comparison to the prior angiographic images, a reverse GuideLiner (Teleflex Vascular Solutions, Minneapolis, MN, USA) assisted controlled antegrade or retrograde subintimal tracking (RCART) technique was used to cross the CTO with an Asahi Gaia Third wire (Figure 1D; Supplementary material online, Video S4 Case S1). After externalization, antegrade IVUS guided angioplasty to the RCA was performed with Doppler colour confirmation of outflow (Figure 1E-I, Supplementary material online, Video S5 Case S1). The procedure was completed with 0 mL of contrast, a total fluoro time of 38.9 min, and a radiation dosage of 0.491 Gy.



**Figure 2** (A) Prior angiographic images demonstrating a proximal left anterior descending chronic total occlusions (arrow). (B) Angiography of the saphenous vein graft to the left anterior descending artery with a high-grade ostial saphenous vein graft stenosis (circle) and retrograde filling of the left anterior descending until distal chronic total occlusions cap (arrow). (C) 1, Wire in distal left anterior descending artery from the saphenous vein graft to mid-left anterior descending using the retrograde guide; 2, antegrade wire in the left anterior descending artery septal using the antegrade guide; 3, antegrade wire in the first diagonal; and 4, wire at the diseased second diagonal next to the proximal chronic total occlusions cap. (D) 1, Wire in distal left anterior descending artery from the saphenous vein graft using to the mid-left anterior descending retrograde guide; 2, antegrade wire in the left anterior descending artery septal; 3, antegrade wire in the first diagonal; 4, wire at the diseased second diagonal next to the proximal chronic total occlusions cap; and 5, Turnpike with pilot 200-wire aimed retrograde at distal chronic total occlusions cap. (E) Chronic total occlusions lesion crossed using reverse controlled antegrade or retrograde subintimal tracking technique with entry of the retrograde wire into the antegrade GuideLiner for externalization. (F) After utilization of the Twin Pass catheter to access the distal left anterior descending from antegrade, a balloon is inflated (arrow) dilating the chronic total occlusions lesion. (G) Intravascular ultrasound of the left anterior descending artery after ballooning and prior to stenting demonstrating luminal narrowing. (H and I) Distal and proximal intravascular ultrasound images (respectively) after stenting.

The patient was discharged the following day following a normal transthoracic echocardiogram (TTE). No renal replacement therapy was required prior to during the inpatient hospital stay. On 6 month follow-up, the patient experienced significant improvement in their chest pain symptoms without need for hospitalization or initiation of renal replacement therapy.

## Case 2: clinical background

A 73-year-old man with a past history of poorly controlled diabetes mellitus Type II, Stage V CKD with an eGFR of 10 mg/min/1.73 m<sup>2</sup> (normal:  $\geq 60$  mg/min/1.73 m<sup>2</sup>) ischaemic cardiomyopathy (ejection fraction of 40%), moderate aortic stenosis and two separate coronary artery bypass grafting surgeries with saphenous vein grafts (SVGs) to the mid-left anterior descending (LAD) artery (previous LIMA to LAD was atretic), first obtuse marginal and right posterior descending artery presented with a NSTEMI. The patient previously received two layers of drug eluting stents to his SVG-LAD graft and initial angiography showed that he had developed recurrent ostial in-stent restenosis (Figure 2A and B, Supplementary material online, Videos S1 and S2 Case S2). He was discharged on optimal medical therapy with subsequent stress testing showing a large area of moderate ischaemia in the LAD territory. Given his high-risk stress test findings and in preparation for renal transplantation evaluation, a heart team decision was made to proceed with percutaneous revascularization of his native LAD approximately 3 months after his NSTEMI.

## Case 2: procedure description

Angiographic films from the patient's initial angiography were uploaded to the monitors to guide contrast-free wiring. First, the distal LAD was wired via the SVG. Then, three anterograde wires were placed down the septal perforator, the first diagonal artery and the diseased second diagonal adjacent to the proximal CTO cap. These wire positions allowed improved contrast-free visualization of the proximal cap location (Figure 2C and D; Supplementary material online, Video S3 Case S2). A 7 Fr Trapliner (Teleflex Vascular Solutions, Minneapolis, MN, USA), Turnpike microcatheter, and Pilot 200 (Abbott, Abbott Park, IL, USA) were advanced retrograde from the SVG and aimed at the distal CTO cap. Once the antegrade and retrograde base of operations were confirmed in comparison to the previous angiogram, a GuideLiner assisted Reverse CART technique was used to successfully cross the CTO using an Asahi Confianza Pro 12 wire (Figure 2E, Supplementary material online, Video S4 Case S2). After externalization, a Twin Pass catheter (Teleflex Vascular Solutions, Minneapolis, MN, USA) was used over the externalized wire to help wire the distal LAD from the antegrade guide (Figure 2F, Supplementary material online, Video S5 Case S2). IVUS guided PCI was then performed (Figure 2G-I, Supplementary material online, Video S6 Case S2) and resolution of ischaemia in the LAD was confirmed with post-PCI FFR (0.94) utilizing a balloon occlusion of the SVG to LAD to mitigate competitive flow. The procedure was completed with 0 mL of contrast, a fluoroscopic time of 95 min and 3.5 Gy radiation dosage. The patient was discharged on postoperative Day 1 with no immediate or follow-up complications. The patient remained off dialysis at 3 months follow-up and was approved for listing for renal transplantation.

## Timeline

### Case 1

1 month prior to index procedure	Exertional Angina, Ischaemia on Nuclear Stress Test, baseline eGFR 15 ml/min
Index Procedure	Diagnostic Catheterization with 20 ml/min Zero Contrast Retrograde CTO PCI - Successful
6 months post-index procedure	Significant improvement in angina, no hospitalization, no haemodialysis

### Case 2

3 months prior to index procedure	Chest pain and NSTEMI, diagnostic catheterization, medical management of CAD
1 month prior to index procedure	Renal transplant evaluation, high-risk stress test
Index Procedure	Zero Contrast Retrograde CTO PCI - Successful
3 months post-index procedure	Approved for renal transplant, no haemodialysis

## Discussion

Percutaneous coronary intervention of CTO represents the most technically challenging procedure in contemporary interventional cardiology. Patients with a CTO generally have increased cardiac risk profiles compared with those without CTO. Among this high-risk patient subset, patients with advanced CKD are at an even greater risk of adverse events, as CIN is directly correlated with higher rates of adverse clinical events and progression to end stage renal disease.<sup>1</sup> Performing minimal or zero contrast PCI, when indicated, offers the opportunity to improve overall outcomes related to ischaemic heart disease without risking worsening renal function or dialysis in this extreme risk group of patients.<sup>3</sup> The present cases demonstrate, for the first time, the feasibility of retrograde complex CTO-PCI without contrast utilization.

Careful study of the prior diagnostic angiogram is fundamental to successful wire navigation without using contrast. Significant expertise with IVUS and coronary physiological technology is also quintessential and only highly trained IVUS interpreters operators should attempt these procedures. Use of physiological measurements such as FFR or flow-based imaging can aid confirmation of the restoration of antegrade flow in the treated vessel at the end of the procedure.

A high level of preparedness and expertise in managing coronary complications is paramount for such procedures. The threshold for using contrast in the event of a suspected complication is low and close monitoring of these patients during the peri-procedural period with pre- and post-TTE is necessary to evaluate for pericardial effusion from non-visualized coronary perforations during the procedure.

While the described procedures should currently be limited to expert CTO operators only, we feel that this case series has broader implications. First, taken together with recent publications on minimal contrast PCI, one can infer that in most cases operators are capable

of using less contrast than the current standard placing some patients with baseline renal dysfunction at additional avoidable risk.

Secondly, these cases demonstrate that even the most complex PCI is possible with zero/minimal contrast. While, we describe two cases with zero contrast using planned RCART CTO approaches, it is possible that retrograde 'true-to-true' wiring could be performed with zero contrast once the coronary tree had been mapped using antegrade and retrograde wires. Other CTO approaches may not permit contrast-free wiring; however, may be successfully completed with minimal contrast use.

In conclusion, we describe successful imaging and physiology-guided CTO-PCI without contrast utilization. Such techniques may be adopted in centres with expertise in complex PCI and use of intravascular imaging and physiology to provide revascularization without the major complications of CIN in these extremely high-risk group of patients.

## Supplementary material

Supplementary material is available at *European Heart Journal – Case Reports* online.

## Funding

National Institutes of Health (T32HL007854 to M.T.F.).

**Consent:** The author/s confirm that written consent for submission and publication of this case report including image(s) and associated text has been obtained from the patient in line with COPE guidance.

**Conflict of interest:** D.K. is speaker honoraria from Abbot Vascular, Boston Scientific, Asahi, and Medtronic. Z.A.A. grants from St Jude Medical and Cardiovascular Systems and personal fees from St Jude Medical, Acist Medical outside the submitted work. W.L.L. discloses equity with Bridgepoint Medical. R.F.R. received speaker honoraria from Abiomed and Spectranetics. All other authors have nothing to disclose.

## References

1. Giacoppo D, Madhavan MV, Baber U, Warren J, Bansilal S, Witzensichler B, Dangas GD, Kirtane AJ, Xu K, Kornowski R, Brener SJ, Généreux P, Stone GW, Mehran R. Impact of contrast-induced acute kidney injury after percutaneous coronary intervention on short- and long-term outcomes: pooled analysis from the HORIZONS-AMI and ACUITY Trials. *Circ Cardiovasc Interv* 2015;**8**:e002475.
2. Christakopoulos GE, Karpaliotis D, Alaswad K, Yeh RW, Jaffer FA, Wyman RM, Lombardi W, Grantham JA, Kandzari DA, Lembo N, Moses JW, Kirtane A, Parikh M, Green P, Finn M, Garcia S, Doing A, Patel M, Bahadorani J, Christopoulos G, Karatasakis A, Thompson CA, Banerjee S, Brilakis ES. Contrast utilization during chronic total occlusion percutaneous coronary intervention: insights from a contemporary multicenter registry. *J Invasive Cardiol* 2016;**28**:288–294.
3. Ali ZA, Karimi Galougahi K, Nazif T, Maehara A, Hardy MA, Cohen DJ, Ratner LE, Collins MB, Moses JW, Kirtane AJ, Stone GW, Karpaliotis D, Leon MB. Imaging- and physiology-guided percutaneous coronary intervention without contrast administration in advanced renal failure: a feasibility, safety, and outcome study. *Eur Heart J* 2016;**37**:3090–3095.
4. Joyal D, Afilalo J, Rinfret S. Effectiveness of recanalization of chronic total occlusions: a systematic review and meta-analysis. *Am Heart J* 2010;**160**:179–187.