

28  
01  
W1 CA967  
NO.3 1993  
SEQ: C09720000  
CATHETERIZATION AND  
CARDIOVASCULAR DIAGNOSIS

Volume 28 • Number 3 • March 1993

# Catheterization and Cardiovascular Diagnosis

NATIONAL  
LIBRARY  
MAR 03 1993  
OF  
MEDICINE

# Catheterization and Cardiovascular Diagnosis

Editor • Frank J. Hildner, MD • Editorial Office, Ocala, Florida

## Associate Editors

Robert A. Chahine, MD  
University of Miami  
Miami, Florida

David A. Clark, MD  
Stanford University  
Stanford, California

Morton J. Kern  
St. Louis University  
St. Louis, Missouri

George W. Vetrovec, MD  
Medical College of Virginia  
Richmond, Virginia

## Editorial Board

Donald S. Baim, MD  
Beth Israel Hospital  
Boston, Massachusetts

Thomas M. Bashore, MD  
Duke University  
Durham, North Carolina

Michel E. Bertrand, MD  
Hôpital Cardiologique  
Lille, France

Peter C. Block, MD  
Massachusetts General Hospital  
Boston, Massachusetts

Alfred A. Bove, MD  
Temple University  
Philadelphia, Pennsylvania

Tsung O. Cheng, MD  
George Washington University  
Washington, DC

David C. Cumberland, MD  
Northern General Hospital  
Sheffield, England

Gerald Dorros, MD  
St. Luke's Health Sciences Offices  
Milwaukee, Wisconsin

Ted E. Feldman, MD  
University of Chicago, Chicago, Illinois

Barry S. George, MD  
Riverside Methodist Hospital  
Columbus, Ohio

Julius H. Grollman, Jr., MD  
Little Company of Mary Hospital  
Torrance, California

Geoffrey O. Hartzler, MD  
Mid America Heart Institute  
Kansas City, Missouri

John W. Hirshfeld, Jr., MD  
Hospital of the University of  
Pennsylvania  
Philadelphia, Pennsylvania

David R. Holmes, Jr., MD  
Mayo Clinic  
Rochester, Minnesota

Abdulmassih S. Iskandrian, MD  
Philadelphia Heart Institute  
Philadelphia, Pennsylvania

Jeffrey M. Isner, MD  
St. Elisabeth Hospital  
Boston, Massachusetts

Harvey G. Kemp, Jr., MD  
St. Luke's Hospital Center  
New York, New York

Spencer B. King III, MD  
Emory University Clinic  
Atlanta, Georgia

Warren K. Laskey, MD  
University of Pennsylvania  
Philadelphia, Pennsylvania

Francis Y.K. Lau, MD  
Loma Linda University  
Loma Linda, California

Ben D. McCallister, MD  
Cardiovascular Consultants, Inc.  
Kansas City, Missouri

Bernhard Meier, MD  
Hôpital Cantonal Universitaire  
Geneva, Switzerland

Charles E. Mullins, MD  
Texas Children's Hospital  
Houston, Texas

Richard K. Myler, MD  
San Francisco Heart Institute  
Daly City, California

Martin P. O'Laughlin  
Texas Childrens Hospital  
Houston, Texas

Igor F. Palacios, MD  
Massachusetts General Hospital  
Boston, Massachusetts

William W. O'Neill, MD  
William Beaumont Hospital  
Royal Oak, Michigan

Johan H.C. Reiber, PhD  
University Hospital  
Lieden, The Netherlands

John O. Parker, MD  
Etherington Hall  
Kingston, Ontario, Canada

Sven Paulin, MD  
Beth Israel Hospital  
Boston, Massachusetts

Carl J. Pepine, MD  
University of Florida  
Gainesville, Florida

Gerald M. Pohost, MD  
University of Alabama  
Birmingham

Gary S. Roubin, MD, PhD  
University of Alabama  
Birmingham, Alabama

Carlos E. Ruiz, MD  
Loma Linda University  
Loma Linda, California

Simon H. Stertzer, MD  
San Francisco Heart Institute  
Daly City, California

Zoltan Turi, MD  
Wayne State University  
Detroit, Michigan

Manuel Viamonte, Jr., MD  
Mount Sinai Medical Center  
Miami Beach, Florida

David O. Williams, MD  
Rhode Island Hospital  
Providence, Rhode Island

William H. Willis, Jr., MD  
Florida Hospital  
Orlando, Florida

© 1993 Wiley-Liss, Inc. All rights reserved. No part of this publication may be reproduced in any form or by any means, except as permitted under section 107 or 108 of the 1976 United States Copyright Act, without either the prior written permission of the publisher, or authorization through the Copyright Clearance Center, 27 Congress Street, Salem, MA 01970, (508) 744-3350, fax (508) 745-9379. Requests to the publisher for permission should be addressed to the Permissions Department, John Wiley & Sons, Inc.

**Catheterization and Cardiovascular Diagnosis** (ISSN 0098-6569) is published monthly by Wiley-Liss, Inc., a division of John Wiley & Sons, Inc., 605 Third Avenue, New York, NY 10158-0012. **Send subscription inquiries to:** John Wiley & Sons, Inc., Subscription Department, 9th floor, 605 Third Avenue, New York, NY 10158.

**Advertising Inquiries** should be addressed to: Roberta Frederick, Advertising Sales Manager, Wiley-Liss, Inc., 605 Third Avenue, New York, NY 10158-0012, phone (212) 850-8832, fax (212) 850-8888.

**Subscription price:** Volumes 28-30, 1993, twelve issues: \$552 in the US, \$672 in Canada and Mexico, \$717 outside North America.

**Special Personal Rate:** Volumes 28-30, 1993, twelve issues: \$155 in the US, \$215 outside the US. NOTE: Subscriptions at the personal rate MUST be paid by personal check, credit card, bank draft or money order. **Special "Physicians in Training" Rate:** \$65; ALL orders at the Special Physicians in Training rate MUST be accompanied by a signature certifying participation in the program (Director of Program).

All subscriptions outside North America will be sent by air. Payment must be made in US dollars drawn on a US bank. **Members of the Society for Cardiac Angiography and Interventions** receive the journal as part of their dues. **Change of Address:** Please forward to the subscriptions address listed above 6 weeks prior to move; enclose present mailing label with change of address. **Claims** for undelivered copies will be accepted only after the following issue has been received. Please enclose a copy of the mailing label or cite your subscription reference number in order to expedite handling. Missing copies will be supplied when losses have been sustained in transit and where reserve stock permits. Send claims to John Wiley & Sons, Inc., Customer Service, 605 Third Avenue, New York, NY 10158. If claims are not resolved satisfactorily, please write to Susan Malawski, Director, Subscription Fulfillment and Sales, John Wiley & Sons, Inc., 605 Third Avenue, New York, NY 10158.

**Cancellations:** Subscription cancellations will not be accepted after the first issue has been mailed. **Second class postage paid at N.Y., N.Y., and at an additional mailing office. POSTMASTER:** Send change of address to Catheterization and Cardiovascular Diagnosis, Susan Heaney, Subscription Fulfillment and Distribution, John Wiley & Sons, Inc., 605 Third Avenue, New York, NY 10158. March, 1993.

**Indexed by:** BIOSIS Data Base · Biomedical Engineering Citation Index · Cardiology Digest · Current Contents/Clinical Medicine · Science Citation Index · Scisearch · Current Opinion in Cardiology · Current Opinion in Radiology · Excerpta Medica · Index Medicus.

Printed in the United States of America.  
Copyright © 1993 Wiley-Liss, Inc.

This material was copied  
This journal is printed on acid-free paper

# Catheterization and Cardiovascular Diagnosis

Volume 28 • Number 3

March 1993

**ORIGINAL STUDIES**

**Accuracy and Precision of Quantitative Digital Coronary Arteriography: Observer-, Short-, and Medium-Term Variabilities**, Johan H.C. Reiber, Pieter M.J. van der Zwet, Gerhard Koning, Craig D. von Land, Bert van Meurs, Jan J. Gerbrands, Beert Buis, and Ad E. van Voorthuisen ..... 187

**Effect of Balloon Size and Stepwise Inflation Technique on the Acute Results of Inoue Mitral Commissurotomy**, Ted Feldman, John D. Carroll, Howard C. Herrmann, David R. Holmes, Thomas M. Bashore, Jeffrey M. Isner, Gerald Dorros, and Jonathan M. Tobis ..... 199

**Coronary Venous Retroperfusion of Arterial Blood for the Treatment of Acute Myocardial Ischemia**, J. Craig Barnett, Robert J. Freedman, Robert C. Touchon, and Mark R. Mesner ..... 206

**Urokinase Infusion After Unsuccessful Angioplasty in Patients With Chronic Total Occlusion of Native Coronary Arteries**, Felipe A. Ceceña ..... 214

**Cardiac Catheterization 1991: A Report of the Registry of the Society for Cardiac Angiography and Interventions (SCA&I)**, Lewis W. Johnson, Ronald Krone, and the Registry Committee of the Society for Cardiac Angiography and Interventions ..... 219

**CASE REPORTS**

**Coronary Artery Spasm Culminating in Thrombosis Following Ergonovine Stimulation**, John T. Hays, R. Dennis Hamill, Clement A. DeFelice, and Albert E. Raizner ..... 221

**Radiation-Induced Stenosis of the Left Main Coronary Artery**, Sun King Wan and Joseph D. Babb ..... 225

**Patent Ductus Arteriosus Presenting in Old Age**, Chi-Ling Hang and J. Thompson Sullebarger ..... 228

**Partial Congenital Defect of the Left Pericardium: Angiographic Diagnosis and Treatment by Thoracoscopic Pericardiectomy: Case Report**, Andrew P. Rees, William Risher, P. Michael McFadden, Stephen R. Ramee, and Christopher J. White ..... 231

**Angiographic Recognition of a Proximal Balloon Tear During Inoue Balloon Mitral Valvotomy**, Wing-Hing Chow, Tsun-Cheung Chow, and King-Loong Cheung ..... 235

**Repeat Balloon Occlusion of a Pulmonary Arteriovenous Fistula Following Cavopulmonary Anastomosis in Tetralogy of Fallot**, Henry J. Chen, Thomas J. Wargovich, J. Parker Mickle, and James A. Hill ..... 238

**"Hugging Balloon" Dilatation: Modification and Limitation of the Technique in Oversized Vessels**, N.S. Chan, J. Berland, A. Cribier, and B. Letac ..... 241

**HEMODYNAMIC ROUNDS**

**Interpretation of Cardiac Pathophysiology From Pressure Waveform Analysis: Acute Aortic Insufficiency**, K.J. Godlewski, J. David Talley, and Glenn T. Morris ..... 244

**COMMENTARY** Morton J. Kern ..... 248

**PEARLS**

**Tracker Tricks: Applications of a Novel Infusion Catheter in Coronary Intervention**, A.G. Violaris and D. Tsikaderis ..... 250

**TECHNICAL NOTE**

**Balloon Catheter Systems for PTCA: The Importance of the Catheter Length**, Eliezer A. Rozenbaum, On Topaz, and Douglas G. Wysham ..... 252

**PRELIMINARY REPORTS**

**Rupture and Entrapment of a Balloon Catheter in the Left Anterior Descending Artery: Fluoroscopic Appearance of Impending Balloon Failure**, William G. Kussmaul III, Kevin Marzo, John Tomaszewski, and Verdi J. DiSesa ..... 256

**New Technique for Right Heart Catheterization Using a Mullins' Sheath**, J.C. Tascón Pérez, J.F. Delgado Jiménez, C. Gomez Pajuelo, A. Albarran Gonzalez, A. Llovet Verdugo, Zuheir Kabbani, and J. Andreu Dussac ..... 260

**Coronary Stenting Through 6 French Guiding Catheters**, Philip Urban, Bernhard Meier, Emmanuel Haine, Vitali Verine, and Vivek Mehan ..... 263

**Letters to the Editor** ..... 267

**Society News** ..... 270



A JOHN WILEY & SONS, INC., PUBLICATION  
 New York • Chichester • Brisbane • Toronto • Singapore  
This material was copied at the NLM and may be subject to US Copyright Laws

## Coronary Stenting Through 6 French Guiding Catheters

Philip Urban, MD, Bernhard Meier, MD,  
Emmanuel Haine, MD, Vitali Verine, MD,  
and Vivek Mehan, MD

**Most stent implantation procedures currently require the use of large-diameter guiding catheters. We describe our preliminary successful experience with 6 French guiding catheters to deliver balloon-expandable Palmaz-Schatz stents to the coronary arteries.**

**Key words:** stent implantation, 6 French guiding catheter, coronary arteries

### INTRODUCTION

Coronary stent implantation constitutes a rapidly developing adjunct to balloon angioplasty. It is an effective form of treatment for a majority of cases when abrupt closure occurs [1,2] and is currently being evaluated in several randomized trials for its potential benefit in preventing late restenosis. The major drawback of all currently available devices, however, is the risk of thrombotic stent occlusion and the ensuing need for aggressive antiplatelet and anticoagulant treatment. Vascular access site is a frequent localization for bleeding complications since the sheath must be retrieved without prolonged interruption of the anticoagulation regimen [3,4]. This problem can be partially overcome by the use of vascular sealing devices [5] and improved external compression, but it remains desirable to minimize local arterial trauma.

Guiding catheters have been decreasing in outer diameter over the years: from the early 9 French (9F) to current high-flow 7F systems [6]. Recently, our group [7,8] and others [9] have reported the use of 6F and even 4F diagnostic catheters [10] for coronary angioplasty with excellent results for selected cases. During the past months, several manufacturers have produced 6F high-flow guiding catheters that allow the use of Monorail type balloons. We report our early experience with coronary stent implantation using a Monorail balloon through such catheters in 3 patients.

From Cardiology Center, University Hospital, Geneva, Switzerland.

Received August 20, 1992; revision accepted November 16, 1992.

Address reprint requests to Philip Urban M.D., Cardiology Center, University Hospital, 1211 Geneva 4, Switzerland.

© 1993 Wiley-Liss, Inc.

### MATERIALS AND METHODS

Our current stent implantation protocol consists of manually crimping a naked articulated Palmaz-Schatz stent (or half a stent, [11]) onto the previously used Monorail balloon catheter, placing this across the target segment, and inflating the balloon to deliver the stent. When 2 stents are required, the distal one is implanted first. Heparin is given in all cases, either a 20,000-IU bolus, or titrated to reach an ACT of 300 sec. We no longer routinely give dextran or urokinase to all patients, the femoral sheath is pulled immediately after completing the procedure, and local hemostasis is achieved with a combination of a collagen sealing device (Vasoseal, Datascope) and an external compression system (Femostop, Radi Medical Systems). Following this, oral anti-coagulation is given for 3 to 6 months (INR > 2.3) together with aspirin (100 mg/day) and dipyridamole (225 mg/day).

### RESULTS

#### Patient 1

A 59-year-old man with recent onset of Canadian Cardiovascular Society (CCS) class 3 angina pectoris and a positive stress test. Angiography showed normal left ventricular function with an ejection fraction of 72% and a single 95% stenosis of the midportion of the left anterior descending coronary artery with good collaterals originating from the right coronary artery. Heparin (20,000 IU) was given and balloon angioplasty was carried out during the same session using a 6F femoral sheath, a 6F number 4 Judkins guiding catheter with a 0.060-inch inner lumen (Schneider) and a 3.0-mm Speedy-plus Monorail balloon catheter (Schneider) with a 0.014-inch wire. After 4 inflations to a maximum of 6 bars, there was a significant, long dissection with reduced flow at the site of previous balloon inflations. There was no chest pain or resting ECG changes due to the well developed collaterals. Two Palmaz-Schatz stents (Johnson and Johnson) were successively hand-crimped onto the Speedy balloon and delivered to the dissected site by balloon inflation to 6 bar with a good angiographic result. The femoral sheath was removed immediately after the procedure, a Vasoseal collagen sealing device was placed and external compression was achieved with a Femostop device. The patient's subsequent hospital course was uneventful, and he was discharged home 6 days later with a regimen of phenprocoumon, aspirin 100 mg/day and dipyridamole 225 mg/day.

**Patient 2**

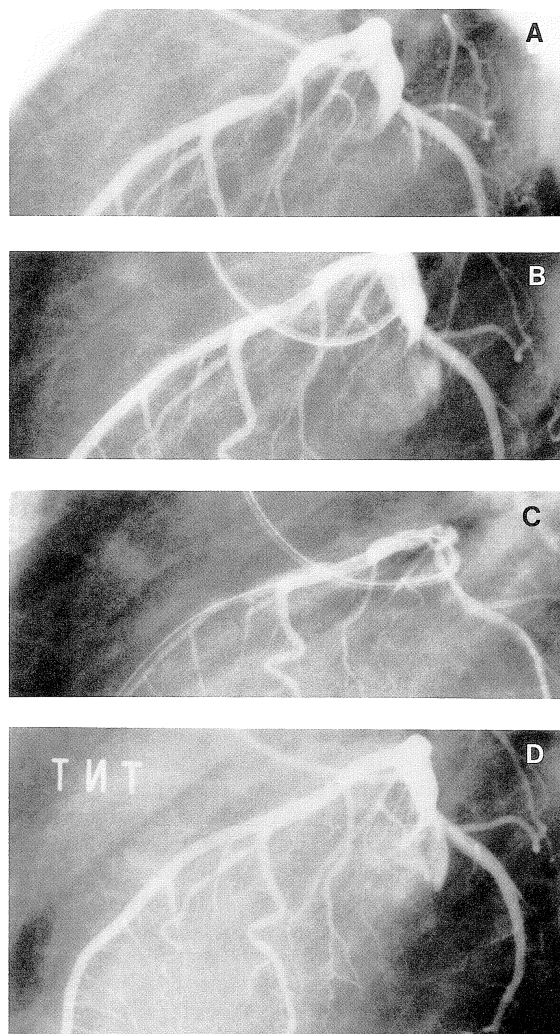
A 55-year-old man with CCS class 3 angina pectoris following a nontransmural anterior myocardial infarct. Angiography showed a tight stenosis of the middle third of the left anterior descending artery. During the same session, and after informed consent was obtained, the patient was included in an ongoing randomized multicenter study of elective stent implantation for prevention of restenosis. Heparin 20,000 IU was given and balloon angioplasty was first carried out with a Schneider Speedy 3.5-mm Monorail balloon catheter and a 0.014-inch floppy wire through a 6F number 4 Judkins guiding catheter with a 0.060-inch inner lumen (Schneider) and a 6F femoral sheath. After this was completed, a Palmaz-Schatz stent was hand-crimped onto the previously used balloon and implanted into the target lesion. Angiographic appearance was excellent (Fig. 1). The femoral sheath was withdrawn immediately upon completing the procedure, and a combination of Vasoseal and Femostop devices was again used to insure local hemostasis. The patient developed a minor groin hematoma, but was ambulated normally after 48 hours and did not require transfusions. He was discharged free of angina on day 6 with acenocoumarol, aspirin, dipyridamole and nifedipine.

**Patient 3**

A 68-year-old carpenter with stable CCS class 2 angina pectoris and a positive stress test. Cardiac catheterization in another hospital had shown the left ventricular function to be normal, and revealed single vessel disease with a 70% proximal stenosis in the left anterior descending artery. After heparin 20,000 IU was administered, balloon angioplasty was carried out using a 6F sheath, a 6F number 4 left Judkins guiding catheter with a 0.062-inch inner lumen (Cordis) and a Speedy 3.0-mm monorail balloon catheter over a 0.014-inch wire. A large dissection developed after 2 inflations to a maximum of 6 bar and bail-out stenting was decided. A single Palmaz-Schatz stent was hand-crimped onto the previously used balloon and delivered to the dissected site with an excellent angiographic result (Fig. 2). The sheath was pulled immediately and hemostasis was achieved with a combination of Vasoseal and Femostop devices. The hospital course was uneventful, the patient remained asymptomatic and was discharged after 4 days on acenocoumarol, aspirin and dipyridamole.

**DISCUSSION**

Minimizing the size of the femoral puncture site is a desirable improvement for all angioplasty procedures, since it should bring about a decrease of local bleeding complications [7-10]. This is all the more true when



**Fig. 1.** A: Left lateral view of the left coronary artery showing a moderately severe stenosis of the mid left anterior descending coronary artery. B: Intermediate result, after dilatation with a 3.5-mm balloon. The guide wire remains across the lesion. C: The 15-mm Palmaz-Schatz stent is crimped onto the same balloon and placed across the lesion. The central balloon marker is well visible, and dye injection allows for precise positioning prior to deployment. D: After implantation, there is no visible residual stenosis.

uninterrupted anticoagulation is necessary after the procedure, as is the case after metallic coronary stent implantation [3,4]. Using 6F diagnostic catheters for selected patients undergoing coronary balloon angioplasty has shown itself to be a safe, rapid, and simple approach when the anatomy of the stenosis was favorable, but the

# Explore Litigation Insights

Docket Alarm provides insights to develop a more informed litigation strategy and the peace of mind of knowing you're on top of things.

## Real-Time Litigation Alerts



Keep your litigation team up-to-date with **real-time alerts** and advanced team management tools built for the enterprise, all while greatly reducing PACER spend.

Our comprehensive service means we can handle Federal, State, and Administrative courts across the country.

## Advanced Docket Research



With over 230 million records, Docket Alarm's cloud-native docket research platform finds what other services can't. Coverage includes Federal, State, plus PTAB, TTAB, ITC and NLRB decisions, all in one place.

Identify arguments that have been successful in the past with full text, pinpoint searching. Link to case law cited within any court document via Fastcase.

## Analytics At Your Fingertips



Learn what happened the last time a particular judge, opposing counsel or company faced cases similar to yours.

Advanced out-of-the-box PTAB and TTAB analytics are always at your fingertips.

## API

Docket Alarm offers a powerful API (application programming interface) to developers that want to integrate case filings into their apps.

## LAW FIRMS

Build custom dashboards for your attorneys and clients with live data direct from the court.

Automate many repetitive legal tasks like conflict checks, document management, and marketing.

## FINANCIAL INSTITUTIONS

Litigation and bankruptcy checks for companies and debtors.

## E-DISCOVERY AND LEGAL VENDORS

Sync your system to PACER to automate legal marketing.