

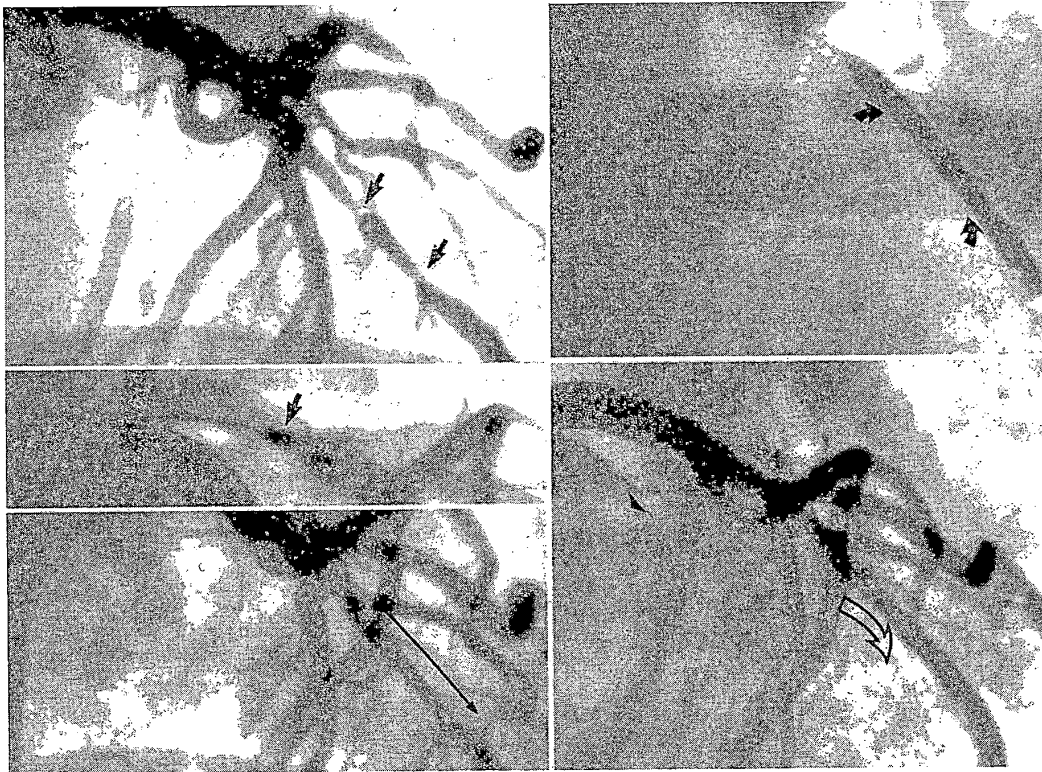
passage of the balloon into the guiding catheter, down the proximal vessel, and across the lesion.

Once the dilatation catheter has been positioned within the target stenosis, the balloon is inflated progressively using a screw-powered, handheld inflation device equipped with a pressure dial. At low pressure (i.e., 2 to 4 atm, or 30 to 60 psi), the balloon typically has an "hour-glass" appearance due to its central restriction by the coronary stenosis being treated. In soft lesions, this restriction, or waist, may expand as pressure is gradually increased, allowing the balloon to assume its full cylindrical shape. In more rigid lesions, the restriction may remain prominent until the balloon expands abruptly at a "stenosis yield pressure" that may be anywhere between 4 and 10 atm (60 to 150 psi) (28). Some operators increase pressure rapidly until all balloon deformity resolves, in the hope that pushing rigid lesions to higher pressure will produce further balloon expansion, but this increases the risk of dissection when a fibrotic or calcified plaque yields suddenly. With the availability of effective tools for dealing with such fibrotic or calcific plaques (i.e., the Rotablator; see Chapter 24), one must then consider whether it is preferable to treat a plaque that resists expansion at 10 atm by rotablation, rather than pushing to the pressures (15 to 20 atm, or 225 to 300 psi; Fig. 23.5) that may be required for full dilation. Calcified or fibrotic rigid stenoses resist expansion at conventional pressures, but elastic (usually eccentric) stenoses are also problematic. These lesions allow full balloon expansion at low pressures but then tend to recoil promptly once the balloon is deflated. This type of lesion was once treated by repeated inflations or cautious use of oversized balloons, but they are now treated routinely by stenting (with or without prior debulking by directional atherectomy). The "cutting balloon," its surface modified by the application of three to four microscopic blades that protrude slightly above the balloon surface when inflated, has also been used for fibrotic or elastic lesions (29).

Despite the more than 20-year history of balloon angioplasty, there is still little objective science behind the speed and maximal pressure used to inflate a dilatation balloon. The classic

approach is to go deliberately (over 10 to 15 seconds) to a pressure that resolves the balloon waist, and then maintain that pressure for 1 minute. On the other hand, some operators prefer a slower speed of inflation and are prepared to tolerate mild persistent balloon deformities that have failed to resolve at moderate (6 to 8 atm) pressure (30) (Fig. 23.6), although the evidence for improved outcome is still inconclusive (31). In addition to this operator-to-operator variability in inflation speed, there is wide variation in the duration of inflation. Early data from Kaltenbach et al. (32) suggested that inflations of 1 minute might offer more benefit than the 30-second inflations used in the early 1980s. Even longer (15-minute) inflations with a perfusion balloon may produce slightly better acute results, with no difference in long-term patency (10).

Whatever inflation strategy is selected, the response of each lesion to balloon dilatation must then be assessed individually so that the dilatation protocol can be tailored to achieve the best possible result. The most common way to assess lesion response to balloon dilatation is repeat angiography performed through the guiding catheter. By leaving the exchange-length guide-wire in place during such angiography, access to the distal vessel and the ability to perform additional intervention (e.g., repeat balloon inflation, stent placement) are maintained. Complete normalization of the vessel lumen would be the ideal end result of coronary angioplasty. Given the mechanism of angioplasty (see later discussion), the more typical result of a successful angioplasty is a 30% residual diameter stenosis (i.e., a 1.9-mm lumen in a 3-mm vessel) with some degree of intimal disruption (reflected as localized haziness, filling defect, or dissection). The operator must decide whether this result is adequate or whether further treatment is needed. Some additional benefit frequently can be obtained by repeated or more prolonged balloon inflation, (i.e., 3 to 5 minutes rather than the usual 1 minute), which may require use of a perfusion balloon to attenuate associated myocardial ischemia. A larger balloon may provide greater lumen enlargement. This possibility can be explored by exploiting any compliance in the



**FIG. 23.6.** Demonstration of low-pressure balloon inflation (2 atm, or 30 psi) **Left, top:** Long calcified lesion in the middle left anterior descending coronary artery (*small arrows*). **Left, center:** Rotablator burr (1.75 mm, *arrow*) being advanced across the lesion. **Left, bottom:** Result after application of Rotablator shows residual stenosis despite improvement in lumen (*long arrow*). **Right, top:** Low-pressure inflation of a 2.5 × 30 mm balloon shows full expansion of the balloon at either end of the lesion but tubular mild constriction throughout the lesion (*arrows*). **Right, bottom:** Despite absence of full balloon inflation, a postdilatation angiogram shows excellent luminal patency without dissection (*open arrow*). Although higher inflation pressure might have produced further lumen enlargement, it would probably have caused prominent local dissection, resulting in the need for stent implantation despite the unfavorable small caliber and long length of the target lesion.

initial balloon (e.g., inflating it to higher pressure, such as 10 rather than 6 atm) or by using the next-larger balloon size. In doing so, however, one must weigh any potential benefits against the clear risk of using an oversized balloon: Although dilatation with a larger balloon may improve luminal caliber, it also may increase the risk of producing a large dissection leading to abrupt vessel closure (26). This creates a clear dilemma, however, because “better is frequently the enemy of good”: Striving for “perfect” luminal enlargement with balloon angioplasty not uncommonly led to conversion of

a patient with a fair result to one who had to go to immediately to the operating room for treatment of a dissection caused by “one more balloon inflation.”

In the stent era, of course, much less emphasis is placed on pushing the results of balloon angioplasty to the maximum. Most lesions that *can* be stented *are* stented. Even if stenting is not planned, the mere *availability* of stenting to treat balloon-induced dissection has helped improve the results of balloon angioplasty by allowing the operator to push for the best result, knowing that stenting is always available to fine-tune the

angioplasty results if there is persistent stenosis of more than 20% or to repair a balloon-induced dissection. It remains uncertain what percentage of patients must be stented for such a "provisional" stent strategy to have its results approach those of preemptive stenting (see also Chapter 25). In trials evaluating provisional stenting, upwards of 40% of balloon angioplasty patients received stents before short and long-term results were as good as those in patients who underwent preemptive stenting (see Chapter 25). But even stenting in the approximately 15% of patients with the worst angioplasty outcomes has substantially improved the results of balloon angioplasty (both acute success and complications, as well as long-term freedom from clinical and angiographic restenosis) in the "control" arm of trials comparing new devices to balloon angioplasty performed after the 1994 introduction of widespread stenting in the United States. In the current view, the best position for stand-alone balloon angioplasty is in lesions that are poorly suited to stenting—vessels smaller than 2.5 mm, with lesions longer than 30 mm, particularly in patients with diabetes mellitus.

Given the importance of achieving the best acute angiographic result and the uncertainty about the adequacy of the acute result as assessed angiographically, a number of other techniques have been employed to grade the quality of an angioplasty result. In the initial years of PTCA, operators relied heavily on the transstenotic gradient as an index of dilatation adequacy, seeking a postdilatation pressure difference of less than 15 mm Hg between the aortic pressure (measured through the guiding catheter) and the distal coronary artery pressure (measured through the tip of the dilatation catheter). In practice, measurement of the gradient is complicated by the presence of the dilatation catheter within the stenosis and the small size of the dilatation catheter lumen; these factors, together with the switch to low-profile over-the-wire dilatation catheters, led to abandonment of the gradient measurement by 1988 (33). There has been some recent reawakened interest based on the availability of newer, solid-state *pressure-measuring*

*guidewires* that can be used to assess the transstenotic gradient at baseline flow and during maximal hyperemia (34).

The fractional flow reserve (FFR) is defined as the ratio of distal coronary pressure to aortic pressure during adenosine-induced hyperemia (see Chapter 18), with a goal FFR greater than 0.95 after a successful angioplasty. The same type of physiologic assessment can be done using Doppler *flow-measuring* guidewires to assess diastolic/systolic flow ratios or coronary flow reserve (CFR) as an index of baseline lesion significance and a confirmation of adequate dilatation. Alternatively, *intravascular ultrasound* (IVUS; see Chapter 19) can more accurately measure lumen diameter and cross-sectional area after dilatation. IVUS has been helpful in procedures (such as directional atherectomy or stenting) where additional dilatation is likely to provide further improvement in luminal caliber. It has provided important mechanistic insights into balloon angioplasty but is not used in more than 10% to 15% of routine clinical cases because of the added procedural time and expense. In most laboratories, the postdilatation angiogram remains the "gold standard" for determining whether an adequate result has been obtained. If the intent is to perform stand-alone balloon angioplasty and the angiogram shows that a technically appropriate attempt at conventional dilatation has produced a poor result (residual stenosis greater than 50%, prominent dissection, frank abrupt closure), secondary use of a new device such as a stent is indicated.

Once adequate dilatation is deemed to have been achieved, it is common to withdraw the balloon catheter completely from the guiding catheter. The exchange-length guidewire is then left across the dilated segment for several minutes, while the treated vessel is observed over several minutes for angiographic deterioration. Injections through the guiding catheter with the balloon removed provide excellent angiographic visualization, while the indwelling guidewire provides easy access to the dilated segment to permit readvancement of the balloon if needed. With more predictable interventions such as stenting, however, a single set of postprocedure

angiograms in orthogonal views is usually sufficient to document a suitable result in the treated lesion and the absence of dissections or branch occlusions in the adjacent portions of the vessel. Once stability of the dilated segment has been established, the guidewire is withdrawn, and other significant lesions are dilated similarly or the patient is transferred to a recovery area.

### POSTPROCEDURE MANAGEMENT

Although the heparin administered during PTCA was once reversed to allow immediate removal of the femoral sheaths, it later became routine to leave the sheaths in place overnight with continued heparin infusion, perfusion of the sheath lumen (Intra-flow II, 30 mL/hr), and monitoring for distal limb ischemia. This practice allowed prompt vascular reaccess should delayed abrupt closure occur (35). In current interventional practice, however, such delayed abrupt closure occurs so infrequently (well less than 1%) that most laboratories now remove the sheaths later the same day, as soon as the heparin effect wears off. There is no evidence that prolonged postprocedure heparin infusion improves outcome (36), and there are compelling data that same-day ACT-guided sheath removal has lowered the incidence of femoral complications and facilitated next-morning discharge. The current standard is thus to give no further heparin after an uncomplicated procedure that has had a good angiographic result, and then to perform same-day sheath removal once the ACT has fallen below 160 seconds. When angioplasty is performed with 7F or 8F sheaths, control of the arterial puncture site during sheath removal can be achieved with the same manual compression techniques used for diagnostic catheterizations. With larger sheaths (or more intense anticoagulation protocols), however, prolonged compression (more than 30 minutes) may be required; this is better performed with the use of a mechanical aid, such as Femo-stop (USCI) or Compressar (Instromedix, San Diego, CA). The other alternative is to perform immediate sheath removal in the setting of full heparinization by

using one of the several arterial puncture sealing devices now available (see Chapter 4).

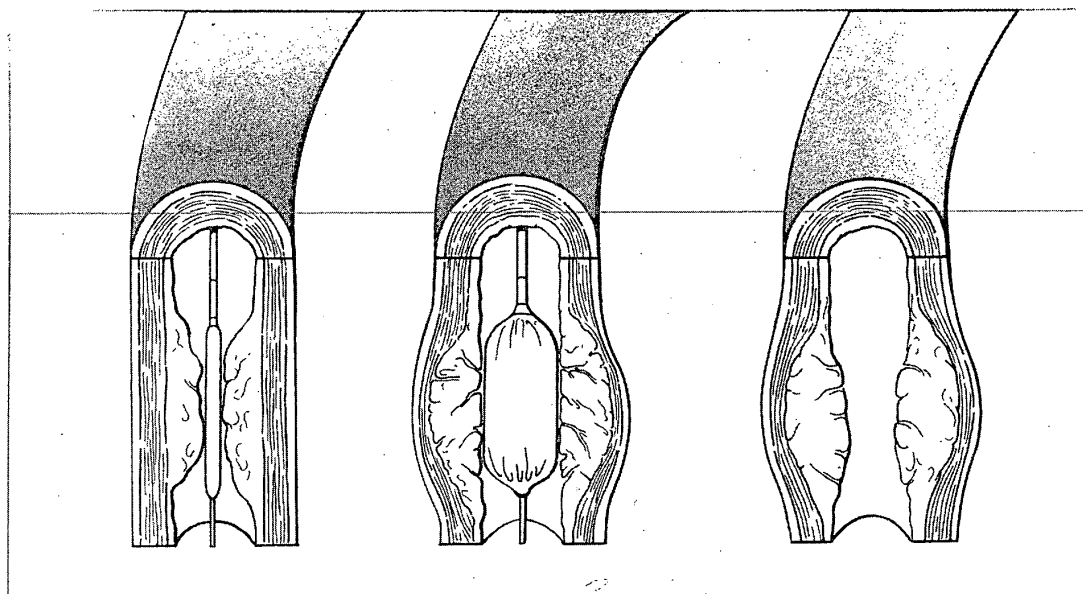
After sheath removal, the patient typically remains at bedrest for 18 to 24 hours and then ambulates before discharge. On discharge, patients are usually given a calcium channel blocker for 6 weeks (longer if required for another indication such as hypertension) and aspirin (325 mg/day) indefinitely. Patients who received a stent are also given additional antiplatelet therapy (ticlopidine or clopidogrel) for 2 to 4 weeks. With a good angiographic result in the treated lesions, marked relief of ischemic symptoms should be expected unless other significant disease has been left behind. In the patient with multivessel disease (see later discussion), it may be particularly helpful to evaluate the postangioplasty physiologic state by a maximal exercise test in the first few weeks after discharge. Earlier (i.e., pre-discharge) exercise testing was once performed on a routine basis but has now been largely abandoned due to the potential for groin rebleeding, delay of discharge, or the small risk of precipitating thrombotic closure of the dilatation site. Patients may return to full activity within 72 hours, by which time the groin puncture site should have healed sufficiently to allow even brisk physical activity.

Patients should expect to have no anginal symptoms early after discharge. Ongoing anginal symptoms suggest persistent untreated disease or a poor result at the treatment site. On the other hand, initial symptomatic relief followed by recurrence of symptoms after 2 to 6 months suggests restenosis of the dilated segment. Recurrence of symptoms 1 or more years after successful angioplasty suggests progression of disease at another site. Along with education regarding these possibilities and their proposed management (repeat exercise testing and catheterization, with the possibility of more catheter intervention or bypass surgery), the acute angioplasty admission should be viewed as an opportunity to educate the patient and family about changes in lifestyle or drug therapy (to control hypertension or lipid abnormalities), and to reduce the risk for the progression of atherosclerotic disease (37).

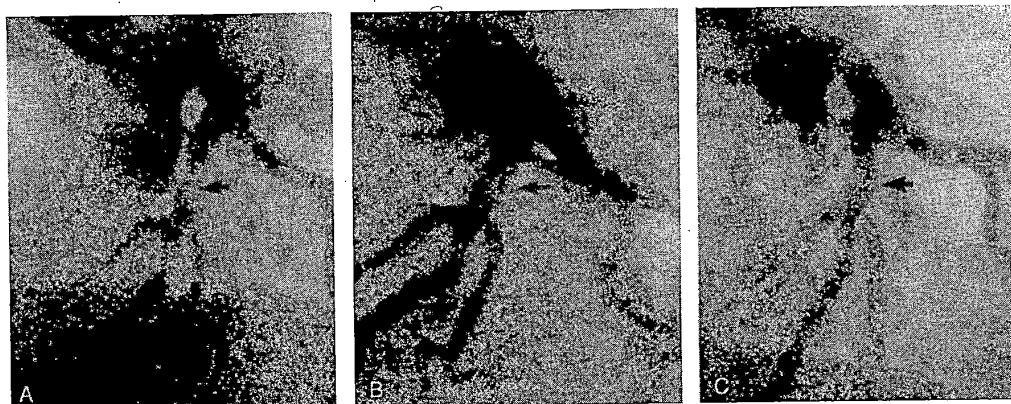
### MECHANISM OF PERCUTANEOUS TRANSLUMINAL CORONARY ANGIOPLASTY

According to the original explanation proposed by Dotter and Judkins (1) and by Gruentzig et al. (3), the enlargement of the vessel lumen after angioplasty was ascribed to compression of the atheromatous plaque—akin to footprints in the snow. In fact, true plaque compression accounts for the minority of the observed improvement (38). Extrusion of liquid components from the plaque does permit some compression of soft plaques but contributes minimally to improvement in more fibrotic lesions, even when balloon inflation is prolonged to 1 minute. Absent significant reduction in plaque volume, most luminal improvement after PTCA seems to result from plaque redistribution—more like footprints in wet sand. Some of this takes place by longitudinal displacement of plaque upstream and downstream from the lesion. Most improve-

ment in the lumen, however, results from controlled overstretching of the entire vessel segment by the PTCA balloon. This stretching leads to fracture of the intimal plaque, partial disruption of the media and adventitia, with consequent enlargement of both the lumen and the overall outer diameter of the vessel (38) (Fig. 23.7). Although use of a full-sized balloon (balloon/artery ratio of 1:1) should theoretically eliminate all narrowing at the treatment site, the overstretched vessel wall invariably exhibits elastic recoil (39,40) after balloon deflation, as well as some degree of local vasospasm (41). These processes typically leave the stretched vessel with a 30% residual stenosis (i.e., a 2-mm lumen in a 3-mm vessel that has been dilated with a 3-mm balloon). Newer devices such as stenting or directional atherectomy are able to provide lower (0% to 10% rather than 30%) postprocedural residual stenosis, by reducing or even eliminating this elastic recoil and vascular tone.



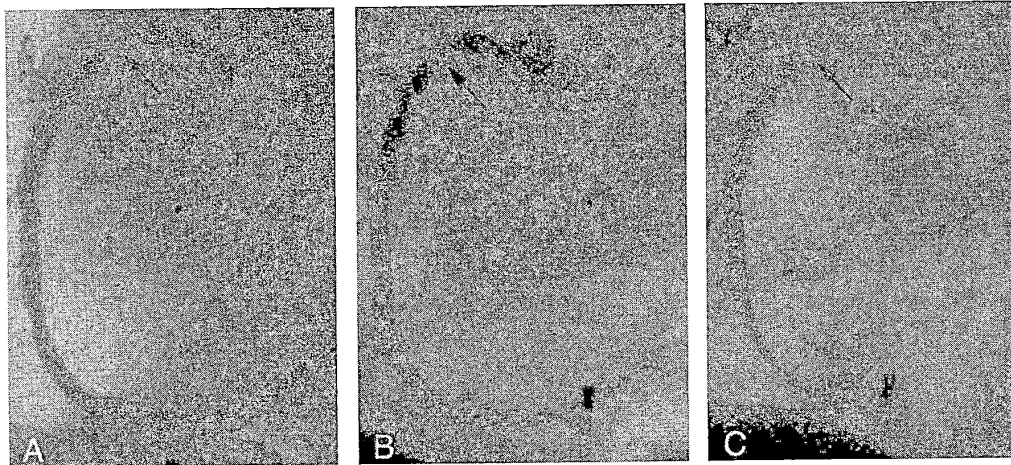
**FIG. 23.7.** Proposed mechanism of angioplasty. **A:** Deflated balloon positioned across stenosis. **B:** Inflation of the balloon catheter within the stenotic segment causes cracking of the intimal plaque, stretching of the media and adventitia, and expansion of the outer diameter of the vessel. **C:** After balloon deflation, there is partial elastic recoil of the vessel wall, leaving a residual stenosis of 30% and local plaque disruption that would be evident as "haziness" of the lumen contours on angiography. (From Willerson JT, ed. *Treatment of heart diseases*. New York: Gower Medical, 1992.)



**FIG. 23.8.** Normal healing of percutaneous transluminal coronary angioplasty (PTCA)-related coronary dissection. Compared with the baseline angiogram (A), the immediate post-PTCA angiogram (B) shows enlargement of the left anterior descending coronary artery lumen with two small filling defects typical of an uncomplicated coronary dissection. C: Follow-up angiogram 3 months later shows preservation of luminal caliber with complete healing of the localized dissection. (From Baim DS. Percutaneous transluminal coronary angioplasty. In: Braunwald E, ed. *Harrison's principles of internal medicine: update VI*. New York: McGraw-Hill, 1985.)

In addition to wrestling with tendencies of the deeper vessel wall to exhibit elastic recoil, the operator also must contend with the problems produced by localized trauma to more superficial plaque components. This trauma is apparent as an almost universal haziness of the lumen margin in the post-PTCA angiogram, reflecting superficial plaque injury (42). Greater degrees of disruption are reflected by intimal filling defects (Fig. 23.8), contrast caps outside the vessel lumen, or spiral dissections that may interfere with antegrade blood flow (Fig. 23.9). This local disruption has been seen on IVUS, on angiography, and on histologic examination of post-mortem angioplasty specimens, and its extent correlates with the risk of an occlusive complication (43) (see Abrupt Closure). Given the amount of "angioplasty" that takes place, it is remarkable that dislodgment and distal embolization of plaque fragments seemed to be infrequent in both experimental studies (44) and most early angioplasty procedures. Disruption of the plaque, however, may clearly lead to embolization of atherosclerotic debris in patients undergoing dilatation of a saphenous vein bypass graft and in those with large thrombi adherent to the lesion (45). In these patients, distal embolization of large (more than 1 mm) plaque

elements is usually manifested as an abrupt "cutoff" of flow in the embolized distal vessel. In contrast, *microembolization* of plaque debris or adherent thrombus may be more common than suspected (46) and may contribute to post-procedure chest pain and enzyme elevation. In 2% to 5% of angioplasties (particularly of vein grafts or platelet-rich thrombi in patients with recent myocardial infarction [MI]) there may be a dramatic reduction in antegrade flow with manifestations of severe ischemia (chest pain, ST-segment elevation). This may be caused by release of vasoactive agents (including serotonin, which may cause intense arteriolar vasospasm of the distal microvasculature) or by liberation of a very large number of microemboli that physically plug the distal microcirculation. It is important to distinguish this "no-reflow" phenomenon from more proximal causes of flow restriction (dissection, spasm, proximal thrombosis), because the no-reflow phenomenon can usually be quickly reversed by administration of low doses of intracoronary calcium channel blockers (e.g., 100  $\mu$ g of verapamil or 500  $\mu$ g of diltiazem) into the distal vessel (47,48). Others have reported reversal with distal injections of other vasodilators such as adenosine or nitroprusside, but the syndrome is usually *not* respon-



**FIG. 23.9.** Coronary dissection leading to abrupt reclosure. The appearance of a right coronary artery stenosis before (A) and immediately after (B) coronary angioplasty, with an evident localized dissection. Within 15 minutes after removal of the dilatation catheter, the patient experienced chest pain associated with inferior ST-segment elevation and angiographic evidence of progressive dissection with impeded antegrade flow (C). Standard management in 1980 (when this case was done) consisted of emergency bypass surgery, which was accomplished without complication. Current practice would be to attempt to recross the lesion and "tack down" the dissection by repeat balloon inflation or, more likely, to place a stent. (From Baim DS. Percutaneous transluminal angioplasty: analysis of unsuccessful procedures as a guide toward improved results. *Cardiovasc Intervent Radiol* 1982;5:186.)

sive to nitrates. When drug therapy is not effective at restoring normal flow, the patient with no reflow will almost certainly go on to sustain a substantial MI, and consideration should be given to intraaortic balloon counterpulsation support. In patients with vein graft disease, alternative approaches (distal occlusion aspiration devices or debris filters) are being investigated to prevent this problem before it occurs (see Chapter 24).

Although it is a theoretical possibility with sufficient local stretching trauma, frank vessel rupture has turned out to be a rare consequence during conventional balloon angioplasty, barring the use of significantly oversized balloons (49). Such vessel perforation is more common (approximately 1% incidence) when new atherectomy devices such as directional atherectomy, rotational atherectomy, or laser angioplasty are used (50) (see Chapter 24).

#### ACUTE RESULTS OF ANGIOPLASTY

Early published data on coronary angioplasty success derive mostly from the 3,000-patient

NHLBI Angioplasty Registry, which collected all procedures performed between 1977 and September of 1981 (51). Although case selection in the registry focused on "ideal" PTCA candidates—those with proximal, discrete, concentric, subtotal, noncalcified stenoses of a single vessel—the primary success rate of 63% would be considered disappointing by current standards. The main explanations for this low rate were failure to cross the lesion with the dilatation system (29% of cases) and failure to dilate the lesion adequately once having crossed it (12% of cases). These failures resulted from two factors: the relative lack of experience of operators contributing cases to the registry (the "learning curve") and the use of original Gruentzig fixed-wire dilatation catheters, which had limited maneuverability, a comparatively high deflated balloon profile, and a low peak inflation pressure.

Despite the inclusion of patients with more difficult coronary anatomy, progressive improvement in equipment (with widespread availability of steerable guidewires since 1983) has

allowed progressive improvement in the primary success rate of coronary angioplasty (5). The second PTCA registry enrolled patients at 14 centers between 1985 and 1986 (52), with a success rate of 90%. Moreover, analysis of complications in the 1985–1986 registry (53) shows a concomitant reduction in the incidence of emergency bypass surgery (from 5.8% to 3.5%) and a reduction in the mortality rate for patients with single-vessel disease (SVD) (from 0.85% to 0.2%), although overall procedural mortality remained close to 1% because of the inclusion of greater numbers of patients with multivessel disease. In the late 1980s and early 1990s, success was obtained in roughly 85% of patients undergoing balloon angioplasty, with major complications occurring in roughly 6% of patients and including death in 1.5%, Q-wave MI in 1.5%, and emergency surgery in 3%. These outcomes have improved further with the introduction of new devices (late 1990s), with acute procedural success rising to more than 95% and major adverse cardiac events falling to roughly 3% (death, 1%; emergency surgery, 0.7%; and Q-wave or large non-Q wave MI, 1.3%).

Anatomic improvement after an angiographically successful PTCA correlates with elimination of anginal symptoms and improved function on atrial pacing or conventional exercise testing (54,55). Studies using thermodilution, videodensitometry, and Doppler flow measurement have shown restoration of coronary flow reserve after successful coronary angioplasty, although full normalization may take a matter of weeks to return (see Chapter 18).

### COMPLICATIONS

As a specialized form of cardiac catheterization, coronary angioplasty is attended by the usual risks related to invasive cardiac procedures (see Chapter 3). In contrast to diagnostic procedures, the larger-caliber guiding catheter used for angioplasty is more likely to result in damage to the proximal coronary artery and to cause local bleeding complications at the catheter introduction site. Selective advancement of guidewires and dilatation catheters into diseased coronary arteries may lead to vessel injury if they

are manipulated too aggressively. The most common complications of coronary angioplasty, however, relate directly to local injury at the dilatation site caused as part of the angioplasty process (56), as described in the section concerning mechanisms (see earlier discussion).

### Coronary Artery Dissection

Although plaque dissection may be caused by overly vigorous attempts to pass the guidewire through a tortuous stenotic lumen, most dissections are the result of the “controlled injury” induced intentionally by inflation of the dilatation catheter (37,38). In fact, localized dissections can be found routinely in animal or cadaveric models of angioplasty and are evident angiographically in approximately one half of patients immediately after angioplasty (42). When these dissections are small and nonprogressive and do not interfere with antegrade flow in the distal vessel, they have no clinical consequence other than transient mild pleuritic chest discomfort. Follow-up angiography as soon as 6 weeks after the angioplasty procedure usually demonstrates complete healing of the dissected segment (Fig. 23.8), although localized formation of aneurysm at the site of dissection has occasionally been described (57,58).

### Abrupt Closure

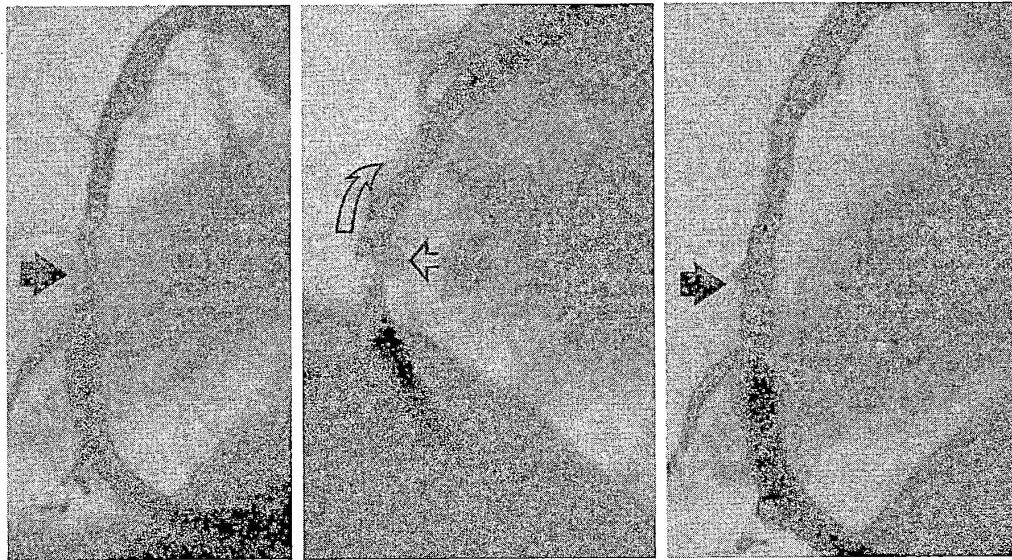
Although small dissections may be well tolerated, large progressive dissections may interfere with antegrade flow and lead to total occlusion of the dilated segment (a phenomenon known as abrupt closure; Fig. 23.9). With the use of balloon angioplasty alone (before the advent of new devices), abrupt closure occurred in approximately 5% of patients as the result of compression of the true lumen by the dissection flap (43), with superimposed thrombus formation, platelet adhesion, or vessel spasm. In one study (59), postangioplasty dissections were evident angiographically in 40% of dilated lesions, with spiral (type-D) dissections (51) in 3.5% of patients. The presence of a type D dissection increased the risk of frank or “threatened” abrupt closure (residual stenosis greater than 50%, with re-



duced antegrade flow) from a baseline of 6.1% to 28%. This finding supports the earlier findings of Ellis et al. (60), showing a five-fold increase in abrupt closure with postprocedure dissection and stressing the relative importance of the postprocedure result (as opposed to preprocedure clinical or angiographic variables; Table 23.1) on the risk of abrupt closure.

Most abrupt closures after stand-alone balloon angioplasty developed within minutes after the final balloon inflation, so that it was desirable to observe the patient for 10 minutes before leaving the catheterization laboratory. Abrupt closure could also occur up to several hours later (in 0.5% to 1% of cases), particularly as the heparin anticoagulation wore off. Under those circumstances, it was heralded by severe chest pain and clear electrocardiographic changes (usually ST-segment elevation) similar to those observed during prolonged balloon inflation. Before 1985, most patients who experienced abrupt closure of a major epicardial coronary artery went directly to emergency surgery, in an effort to minimize

the amount of consequent myocardial damage. The rate of emergency surgery was 5% to 6%, but even with emergency surgery within 90 minutes after the onset of vessel occlusion, up to 50% of patients sustained a Q-wave MI (61). The development of "perfusion" catheters—infusion catheters or angioplasty balloons with multiple sideholes along their distal shaft to allow 40 to 60 mL/min of blood to enter proximal to the site of occlusion, flow through the central lumen, and reexit into the lumen distal to the point of occlusion—allowed patients to go to the operating room in a nonischemic state (Fig. 23.4), reducing the incidence of transmural infarction during emergency surgery to approximately 10% (62). Once it was realized that many abrupt closures can be reversed by simply re-advancing the balloon dilatation catheter across the lesion to "tack up" the dissection via repeated balloon inflation (35) (Fig. 23.10), the emergency surgery rate fell in half, to roughly 3%. Prolonged balloon inflations—up to 20 minutes, using an autoperfusion balloon (63) to



**FIG. 23.10.** Reversal of abrupt closure by repeat balloon inflation. Eccentric stenosis in the mid-right coronary artery (*left, arrow*) dilates (*center*) with production of a large dissection (*curved arrow*), focal dye stain (*open arrow*), and retarded distal flow. Repeat inflations with a 0.5-mm-larger balloon catheter, using inflation durations of up to 5 minutes, "tacked up" the dissection to provide a stable luminal appearance (*right, arrow*). Approximately 50% of abrupt closure events can be reversed in this manner, with up to 90% reversal by use of a coronary stent.

limit ongoing ischemia—further improved the ability to reverse abrupt closure.

Since 1993, the availability of coronary stents has increased the certainty of reversing abrupt closure to almost 90% (64). This success has made it routine to stent any patient with a large postprocedure dissection, as a preemptive treatment for “threatened” abrupt closure even when flow compromise is not apparent. With elective stenting of more than 80% of interventional procedures, this problem has been largely eliminated, and emergency surgery rates having fallen below 0.5%. Because emergency surgery is still required in some cases, the recommendation is still in place to perform elective coronary angioplasty only in settings where the resources for prompt emergency bypass surgery are available (16).

Beyond the mechanical issues of residual stenosis and local dissection, it is now clear that platelet-rich clots contribute significantly to the abrupt closure process. The presence of thrombus, reflected as a globular filling defect, increases the risk of abrupt closure from 7.2% to 27.8% (59). The role of thrombus in abrupt closure is further supported by an increased risk of abrupt closure in patients with a subtherapeutic ACT value (20) and by the reduction of ischemic end points seen in patients treated with a bolus plus infusion of various platelet IIb/IIIa integrin blockers (Table 23.2) (17). Although platelets may adhere to damaged vessel walls through

other receptors, it is the activation of the 50,000 to 80,000 glycoprotein IIb/IIIa receptors on each platelet’s surface that allows them to bind avidly to fibrinogen to cause platelet aggregation and thrombosis. Vessels with moderate local dissection but preserved antegrade flow are more likely to stay patent in the presence of agents that reduce the affinity of the activated IIb/IIIa receptor for fibrinogen, thereby reducing the incidence of emergency surgery or unplanned (bailout) stent placement. These agents also appear to reduce the incidence of periprocedural MI, particularly the incidence of creatine kinase (CK) elevations (non-Q wave MIs) that are seen in 10% to 30% of patients undergoing coronary intervention (65). Until it is clear that prophylactic use of such agents improves hard end points such as mortality or emergency surgery, however, the expense and increased bleeding risks associated with the use of these agents has constrained their use in most laboratories to the 30% to 40% of patients who have high-risk lesion morphologies or a suboptimal mechanical result after mechanical intervention.

In certain subgroups—those with extensive prior or ongoing myocardial damage, multivessel disease, a large myocardial territory perfused by the target stenosis, or prior coronary bypass surgery—the consequences of abrupt closure may be more severe. Before the widespread availability of stenting, these patients had a procedure-related mortality rate several times

**TABLE 23.2.** Intravenous blockers of the platelet glycoprotein IIb/IIIa receptors used during coronary intervention at Beth Israel Deaconess Medical Center

| Tradename  | Agent        | Manufacturer  | Loading dose <sup>a</sup>                     | Infusion (for 24 hr)                                 |
|------------|--------------|---------------|---|--|
| ReoPro     | Abciximab    | Lilly/Centcor | 250 $\mu$ g/kg (0.25 mg/kg)                   | 0.125 $\mu$ g/kg/min (max 10 $\mu$ g/min)            |
| Aggrastat  | Tirofiban    | Merck         | 12 $\mu$ g/kg (over 3 minutes)                | 0.1 $\mu$ g/kg/min (one-half dose for $C_{Cr}$ < 30) |
| Integrilin | Eptifibatide | Key/Cor       | 180 $\mu$ g/kg (may be repeated 10 min later) | 2.0 $\mu$ g/kg/min                                   |

<sup>a</sup> Various dose regimens of these agents are in use in different laboratories, and the ability to monitor platelet receptor occupancy is still limited. Care should be taken to avoid excess heparin administration (activated clotting time, >250 sec) when IIb/IIIa blockers are given and to check for early profound thrombocytopenia (incidence approximately 1%) as well as potentially serious excessive bleeding that may require discontinuation of the infusion or administration of fresh platelets. Although tirofiban and eptifibatide have short half-lives (approximately 90 mins) after discontinuation, abciximab has persistent effects for 24–48 hours after discontinuation of the infusion. (See Dobesh RP, Latham KA. Advancing the battle against acute ischemic syndromes—a focus on the GP IIb/IIIa inhibitors. *Pharmacotherapy* 1998;18:663, for additional information on these agents.)

higher than the 0.3% to 0.6% rate seen with elective coronary angioplasty (66). This required the most vigilant surgical standby and immediate availability of hemodynamic support devices, including intraaortic balloon counterpulsation and, potentially, percutaneous cardiopulmonary support (CPS) via 18F femoral arterial and venous cannulas (67,68) (see Chapter 21). More recently, however, the high degree of reliability of stent intervention has meant that such patients do well with nothing more than prophylactic intraaortic balloon counterpulsation.

### Other Complications

A number of other complications have been described as the result of coronary angioplasty. Q-wave MI occurs in approximately 1% of patients (53), often as a result of abrupt closure or "snowplow" loss of a major side branch originating within or in close proximity to the lesion being treated. If creatine kinase MB (CK-MB) isoenzyme levels are measured routinely, however, 10% to 30% of patients show some elevation after apparently uncomplicated procedures (65), usually as the result of distal microembolization or loss of smaller side branches. The importance of these "infarctlets" is still the subject of some debate. Certainly larger non-Q wave infarctions—those with absolute CK-MB levels greater than 5 times the upper limit of normal or those associated with new ST-T wave abnormalities—probably have the same import as a periprocedural Q-wave infarction. Overnight electrocardiographic monitoring is prudent, and discharge should be delayed for 24 to 48 hours to ensure clinical stability. The debate, however, centers on smaller elevations of CK-MB, between 1 and 5 times normal. These events do not significantly impair ventricular function or increase the 1-year mortality rate, and in our laboratory we do *not* generally classify such enzymatic abnormalities as significant infarctions or delay the timing of planned discharge (69). On the other hand, a number of large studies have demonstrated that patients with CK-MB elevations 1 to 5 times greater than normal have an increased incidence of adverse events (variously identified as death, repeat MI, repeat revascularization) at 3 to 5 years. Were this a *cause-*

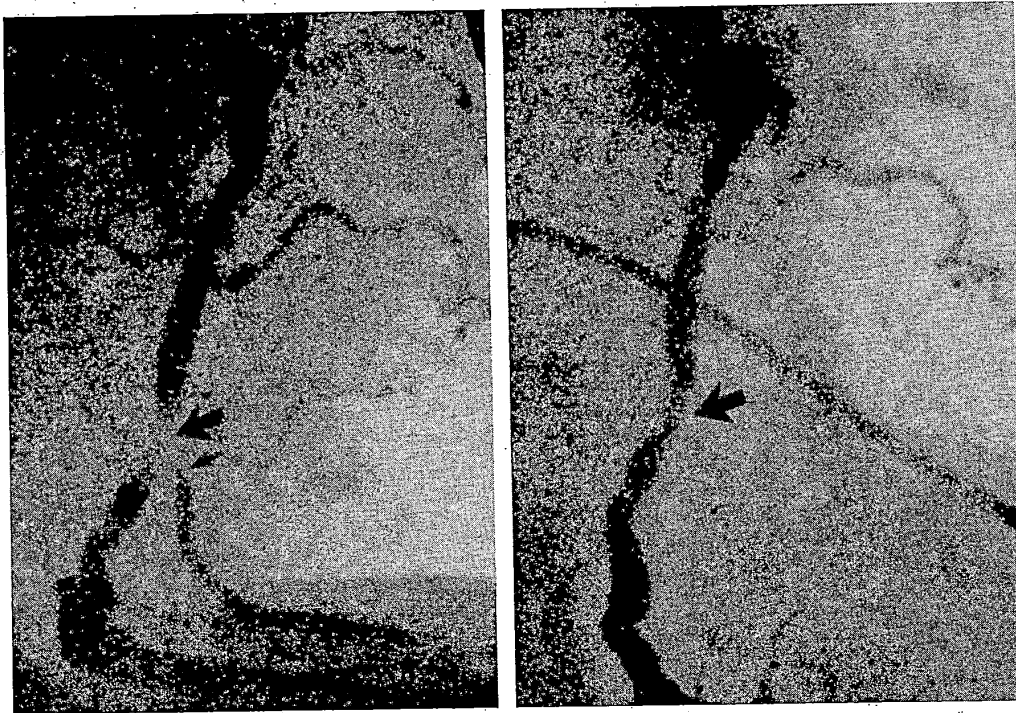
*and-effect* relationship, one would expect those randomized device trials in which one study arm had greater CK elevation (e.g., directional atherectomy) to show higher mortality, which has not been the case (70). One would also expect that drug interventions that decrease the frequency of CK-MB elevation (e.g., IIb/IIIa platelet receptor blockers) would significantly lower mortality, but this has been seen only for *post hoc* selected subgroups. In a pooled analysis of more than 12,000 interventional patients enrolled in randomized trials of IIb/IIIa receptor blockers versus placebo, the odds ratio for mortality at 6 months was 0.90 (95% confidence interval, 0.70 to 1.16;  $p = .41$ ) (17). If the relationship is not cause-and-effect, the other possibility is that *both the CK elevations and the variety of late events are related to a common factor* (a confounder), such as the diffuseness of atherosclerotic disease. By analogy to the example of the association of carrying matches and lung cancer (through the confounder of cigarette smoking), devices or drugs that decrease the incidence of CK elevation would not change the underlying disease process or its late manifestations (any more than banning matches would eliminate smoking-related lung cancer). Until and unless a cause-and-effect relationship is demonstrated (i.e., through an across-the-board reduction in late mortality by periprocedural IIb/IIIa blocker administration), the practice in my laboratory is to use these agents only for the approximately 30–40% of patients who have certain high-risk lesions or lesions in which the best attempt at mechanical revascularization still fails to provide an angiographically perfect result.

Other than embolization of plaque constituents, embolization of large thrombi that are adherent to the stenosis may occur and should be taken into account during angioplasty of patients with unstable angina or acute MI (see earlier discussion). This may include overnight intracoronary infusion of a thrombolytic agent or use of one of the new mechanical thrombectomy devices (see Chapter 24). Embolization of smaller thrombus or plaque particulates, which can cause slowed antegrade perfusion and transmural ischemia in the absence of proximal vessel compromise or distal cutoffs, known as the "no reflow" phenomenon (45). It is most common

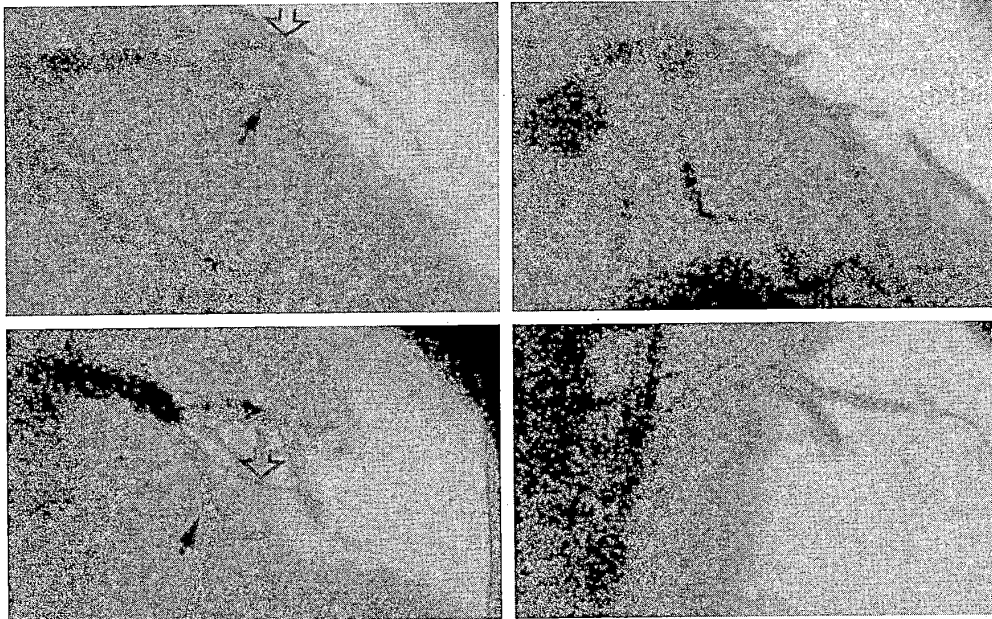
(2% to 8%) in patients who undergo treatment of a lesion responsible for recent MI or treatment of a saphenous vein graft. The mechanism may include embolization of platelet-rich thrombi that release vasoconstrictive substances (e.g., serotonin) which can cause intense vasospasm of the distal microcirculation, or release of atherosclerotic plaque debris (particularly during vein graft intervention) that can "sludge" the distal vessels (46).

Occlusion of branch vessels originating from within the stenotic segment occurs in 14% of vessels at risk during angioplasty of the main vessel, according to what has been called the "snowplow effect" (71) (Fig. 23.11). If the branch vessel is small, this event usually has no significant clinical sequelae and should not discourage attempted angioplasty. On the other hand, if a large branch vessel originates from within the stenosed segment, simultaneous dilata-

tion of the main vessel and the involved branch with two separate dilatation systems (the "kissing balloon" technique) may be required for preservation of both vessels (72). This originally required two separate guiding catheter and balloon dilatation catheter systems (Fig. 23.12). Alternatively, two guidewires were inserted through a single guiding catheter (one guidewire being placed into the main vessel and one into the involved side branch), to allow advancement of a balloon catheter into one and then the other vessel (73). Current large-lumen guiding catheters and low-profile dilatation systems now allow actual kissing balloon inflations through a single guiding catheter. The results can be improved, however, by performing atherectomy of both the parent and branch vessel (74) (see Chapter 24). When the involved side branch is noncalcified and larger than 2.5 mm, directional atherectomy of the main vessel and then the side-



**FIG. 23.11.** The "snowplow" effect. Dilatation of mid-right coronary artery stenosis (**left**) resulted in occlusion of a diseased right ventricular branch that originated from within the stenotic segment (**right**). There were no clinical sequelae. Approximately 14% of involved branches suffer a similar fate. (From Baim DS. Percutaneous transluminal angioplasty. In: Braunwald E, ed. *Harrison's principles of internal medicine: update VI*. New York: McGraw-Hill, 1985.)

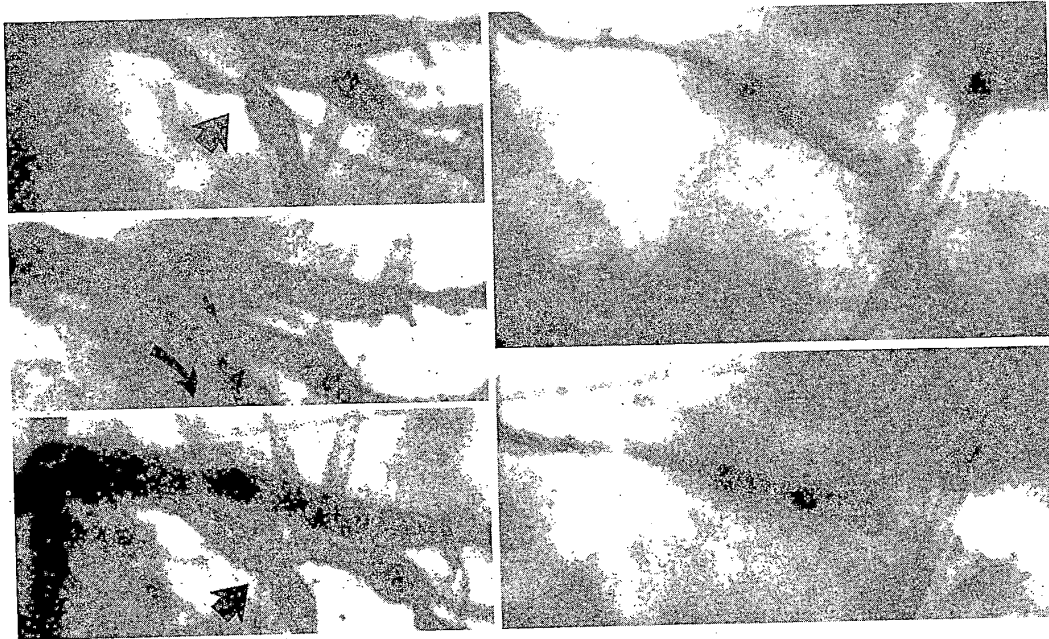


**FIG. 23.12.** "Kissing balloon" treatment of a bifurcation lesion. **Left, top:** A severe stenosis involves the bifurcation of the left anterior descending (LAD) coronary artery (*dark arrow*) and a large diagonal branch (*open arrow*). With conventional dilatation of the LAD, the diagonal branch would be at risk for "snowplow" occlusion, which did occur (**left, bottom**). Note, however, a second guidewire (*open arrow*), which was placed in the diagonal branch before LAD dilatation to allow alternating dilatation of the LAD and the diagonal branch. When this failed to provide adequate improvement in both vessels, a true "kissing balloon" procedure (simultaneous inflation of two balloon catheters) was performed (**right, bottom**). Although some luminal thrombus was present (**right, top**), it had resolved at follow-up angiography the next day.

branch ostium has proved to be an effective way of maintaining patency of both vessels (Fig. 23.13). For smaller branches or calcified bifurcations, rotational atherectomy provides similar benefit. Various stent strategies have been used in bifurcation lesions, but at this time none offers significant benefit in long-term patency over the atherectomy approaches followed by kissing balloon dilatation.

Perforation of the coronary artery with a stiff guidewire occurs rarely and does not necessarily have dire consequences, unless a device is passed over the wire or the wire perforation takes place in a patient receiving a platelet IIb/IIIa receptor blocker. Frank rupture of the coronary artery resulting from use of too large a dilatation balloon or use of an atherectomy device (see Chapter 24) can cause vessel perforation

that leads to rapid tamponade and hemodynamic collapse (49,50). Tamponade also may result from perforation of the right atrium or right ventricle during placement of temporary pacemaker electrode catheters, particularly in angioplasty patients who are receiving antiplatelet therapy in addition to full heparinization. This potential complication and the infrequency (less than 1%) of severe bradycardiac complications support our recommendation against prophylactic pacing during coronary angioplasty (19). Ventricular fibrillation occurs in approximately 1% of angioplasty procedures (53), usually as the result of prolonged ischemia during balloon advancement or inflation. In addition to causing electrical instability, ischemia during balloon inflation may cause marked electrocardiographic changes, (75) abnormalities in re-



**FIG. 23.13.** Bifurcation atherectomy. **Left, top:** Bifurcation stenosis involving the circumflex (*arrow*) and the large obtuse marginal branch. **Left, center:** Directional atherectomy of circumflex has provided a large smooth lumen (*curved arrow*), with ongoing stenosis of the origin of the marginal branch (*small arrow*). **Left, bottom:** After atherectomy of the marginal branch, excellent patency of both the main vessel and the involved side branch have been secured. **Right, top:** Position of the directional atherectomy catheter during cuts in the circumflex. **Right, bottom:** Position of atherectomy catheter during cuts in the marginal branch. Atherectomy of the main branch and involved side branch, followed by kissing balloon dilatation, remains an effective way to approach such lesions (see reference 74), although several stent-based approaches are being developed (see Chapter 25).

gional left ventricular systolic and diastolic function (76,77), and regional myocardial lactate production.

Although angioplasty guidewires and catheters are extremely reliable devices, failures can occur when any device is subjected to severe operating stresses, as when a guidewire is rotated repeatedly in a single direction while its tip is held fixed in a total occlusion or when a balloon catheter is inflated past its operating pressure range in an attempt to dilate a resistant stenosis. In a small percentage of cases, this may lead to detachment of a part of the wire or dilatation catheter, with a fragment remaining in the coronary artery (78). In the stent era, this also includes dislodgment of a bare-mounted stent from its delivery balloon. To avoid the need for surgical removal, the angioplasty operator

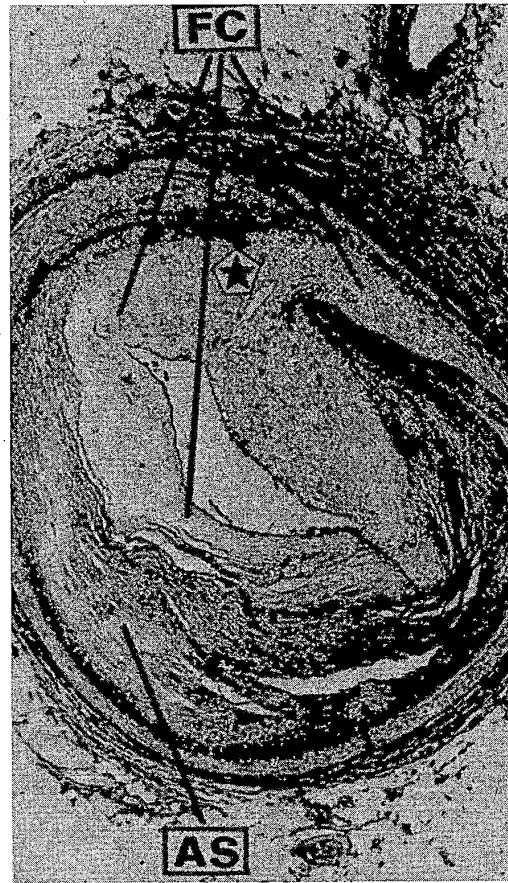should be familiar with the techniques of catheter retrieval (79). Finally, the operator must be careful to limit the amount of contrast material administered (usually to 3 or at most 4 mL/kg) to avoid renal toxicity, particularly during complex or multivessel procedures.

#### THE HEALING RESPONSE TO CORONARY ANGIOPLASTY: RESTENOSIS

After successful balloon angioplasty, the body attempts to repair the damage caused by the procedure-related mechanical injury. Within minutes, a carpet of platelets and fibrin is deposited. Within hours to days, inflammatory cells begin to infiltrate the site, cytokines are released, and vascular smooth muscle cells begin to migrate

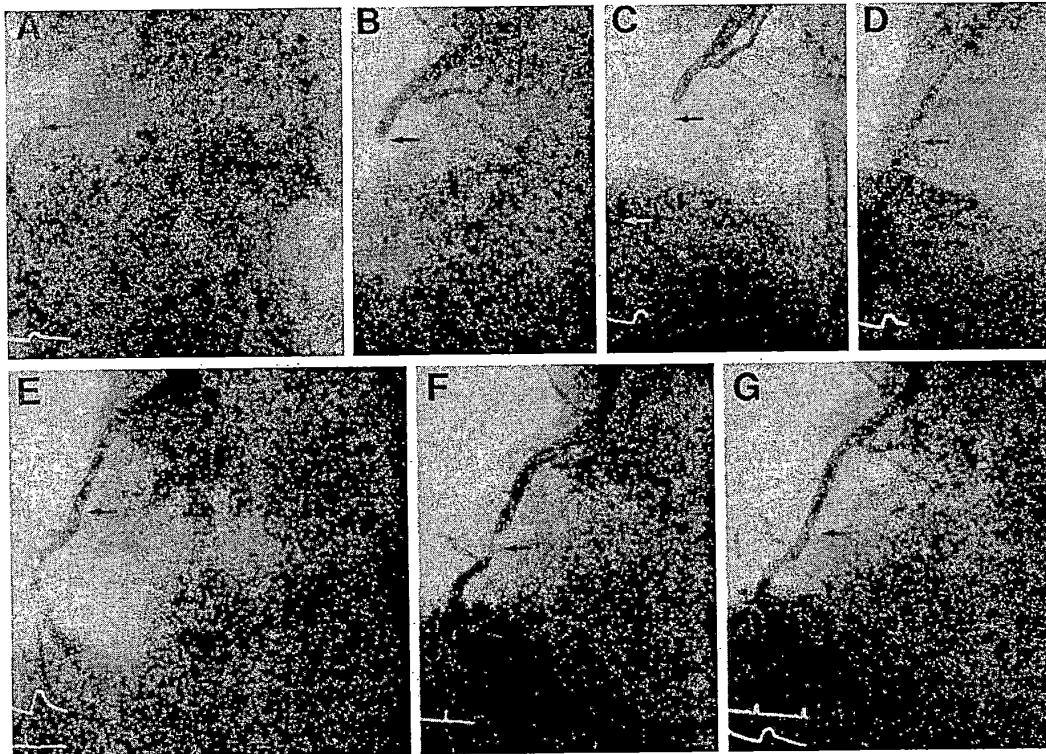
from the media toward the lumen. These smooth muscle cells and fibroblasts convert from their normal phenotype to a synthetic phenotype and remain in this form as they undergo hypertrophy, proliferate, and begin to secrete extensive extracellular matrix. The luminal surface is simultaneously colonized by endothelial cells that slowly regain their normal barrier function and secretory functions in making tissue plasminogen activator (tPA) and endothelial-derived relaxation factor. Along with this proliferative neointimal response, there may be further elastic recoil and fibrotic contraction of the vessel wall during this period. Different arteries and interventions appear to result in different degrees of proliferation and vessel contraction—for example, stents rearrow exclusively by neointimal hyperplasia, whereas most other devices also undergo a significant amount of late narrowing due to contraction (unfavorable remodeling) of the entire vessel wall (80). There are also significant patient-to-patient variations in the late healing response after coronary intervention, reflected in variables amounts of “late loss” in lumen diameter between the completion of the intervention and the time when the repair process stabilizes (roughly 6 months) (Fig. 23.14). Follow-up angiography shows continued maintenance of lumen diameter at the treated site beyond 6 to 9 months (81).

If the healing response is excessive, however, most or all of the gain in lumen diameter produced by the initial intervention may be lost to the healing process. This causes the return of a severe stenosis and ischemic symptoms—a phenomenon known as *restenosis* of the dilated segment (82) (Fig. 23.15). Throughout the 1980s, restenosis was considered to be a dichotomous outcome (i.e., it either did or did not develop). A large number of competing dichotomous restenosis definitions (e.g., loss of half the gain, late loss more than 0.72 mm) were developed, adding to the general confusion about restenosis rates. Although a great deal was learned about restenosis from the study of conventional angioplasty patients (e.g., its time course, histology, various clinical factors correlating with an increased incidence of restenosis) (83), data derived from stent and atherectomy procedures



**FIG. 23.14.** Mechanisms of restenosis: cross-section of a restenotic lesion in the left anterior descending coronary artery 5 months after initial coronary angioplasty shows the original atherosclerotic plaque (AS), the crack in the medial layer induced by the original procedure (star), and the proliferation of fibrocellular tissues (FC) that constitutes the restenotic lesion. (From Seruys PW, et al. Assessment of percutaneous transluminal coronary angioplasty by quantitative coronary angiography: diameter versus videodensitometric area measurements. *Am J Cardiol* 1984;54:482.)

have led to new paradigms for evaluating restenosis (84). It is now considered more useful to consider restenosis as a continuous variable. A cumulative distribution curve may be used to show the ranked population distribution of the late result, expressed either in terms of late lumen diameter or late percent diameter steno-



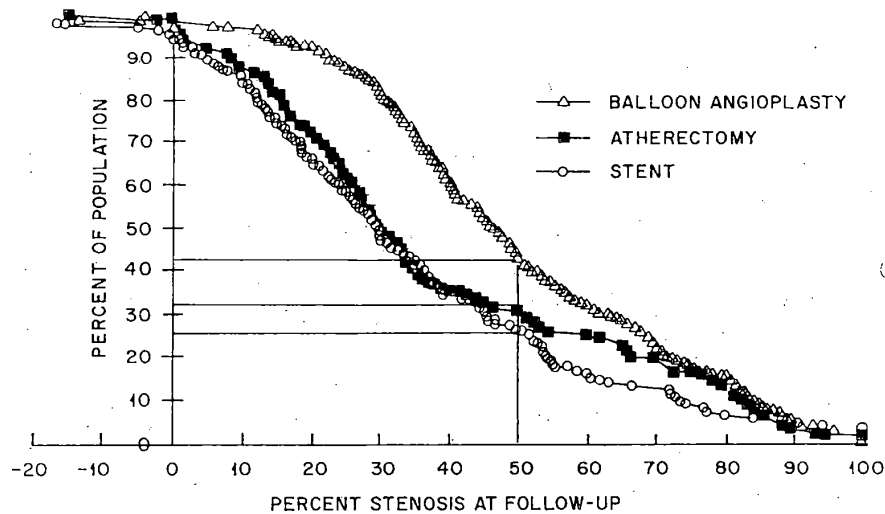
**FIG. 23.15.** Clinical restenosis. **A** through **D**: A totally occluded right coronary artery with filling of the distal vessel by way of left to right collaterals. **E**: The essentially normal appearance of the right coronary artery after successful angioplasty. **F**: The appearance 6 weeks later, when angina had recurred. **G**: The appearance after successful repeat percutaneous transluminal coronary angioplasty (PTCA). Restenosis developed again after 6 weeks, but the patient has now been asymptomatic after a third PTCA procedure. (From Dervan JP, Baim DS, Cherniles J, et al. Transluminal angioplasty of occluded coronary arteries: use of a movable guidewire system. *Circulation* 1983;68:776.)

sis, for the whole treated population (Fig. 23.16). On the diameter stenosis curve, the percentage of the population with a late diameter stenosis of more than 50% (analogous to the original dichotomous Emory definition) serves as a useful benchmark for comparing the angiographic "restenosis rates" between different populations or treatment groups.

Further understanding is gained by comparing the acute gain in lumen produced by the intervention to the late loss in lumen diameter that results from the healing process. Every treated lesion undergoes some degree of late loss, but this process usually negates only part (roughly half) of the acute gain, so that a long-term net gain in lumen diameter (and alleviation of is-

chemia) results. Another important finding is the tendency toward a linear relationship between late loss in lumen diameter (caused by the proliferative and fibrotic reaction of the artery during the healing phase) and the acute gain in lumen diameter caused by the intervention. The slope of this relationship (the *loss index*) is roughly 0.5 for most interventions, corresponding to the payment of a late loss "tax" equal to about half of the acute gain. Larger lumen diameters immediately after intervention translate into larger lumen diameters at 6-month angiographic restudy (the "bigger is better" dictum). To date, all new mechanical devices (e.g., stents, directional atherectomy) that have lowered the restenosis rate compared with balloon angioplasty have



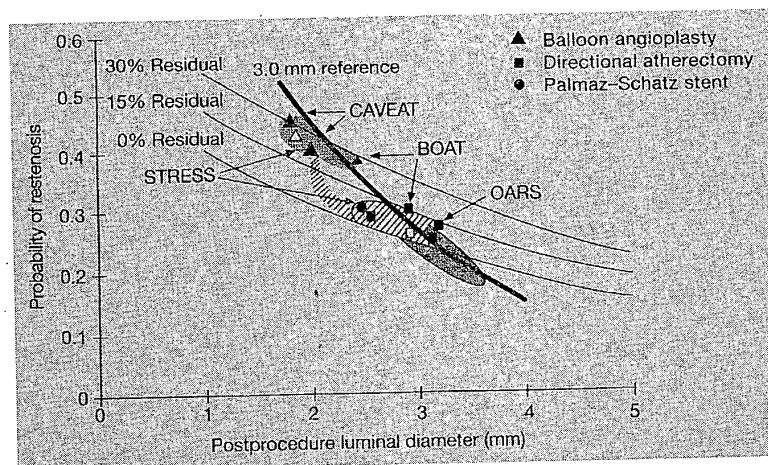


**FIG. 23.16.** The view of restenosis as a continuous process that takes place to some degree in every treated segment favors displaying the late result (here, percent stenosis at follow-up) for the whole treated population. For patients treated by balloon angioplasty, directional atherectomy, or stenting, the y-axis shows the percentage of patients who have a stenosis greater than the value on the x-axis. The ability of stenting and atherectomy to lower restenosis is shown by a shift of their "cumulative distribution function" curves to the left. If a dichotomous definition of restenosis is applied, the intersection of each curve with a late diameter stenosis of 50% (vertical line) corresponds to a dichotomous restenosis rate of 43% for angioplasty, 31% for atherectomy, and 26% for stenting. (From Kuntz RE, et al. Novel approach to the analysis of restenosis. *J Am Coll Cardiol* 1992;19:1493.)

done so by providing a larger acute lumen diameter (more acute gain). Once minimal lumen diameter is included in the statistical model, the particular device used (stent or atherectomy versus PTCA) is no longer an important determinant of restenosis (Fig. 23.17).

The importance of postprocedure geometry to the late result does not, however, mean that other biologic variables are unimportant. A number of biologic factors (e.g., diabetes, LAD lesion location, prior restenosis, the presence of previously activated smooth muscle cells) have been shown to increase the loss index to as high as 0.70 (84), a level at which even perfect (0% residual stenosis) acute results are associated with a large late loss, a small net gain, and a high restenosis rate in vessels smaller than 4 mm. From this perspective, a drug or other treatment that could decrease the loss index "tax" rate would be dramatically effective in reducing restenosis. Efforts to reduce the restenosis rate by

manipulating procedure-related variables such as duration of conventional balloon inflation (10) have been largely unrewarding unless, like stenting, they produce markedly more favorable acute results (i.e., a larger posttreatment minimal luminal diameter). Similarly, trials of numerous drug regimens (e.g., aspirin, nifedipine, ticlopidine, steroids, prolonged heparin administration, fish oil, mevinolin, ketanserin) have shown no beneficial effect against restenosis. The search for such treatments is vital, however, since finding an agent that would decrease the loss index even slightly (e.g., from 50% to 35%), would have a major impact on angiographic restenosis rate. Because the complex healing response involves so many mechanisms (smooth muscle cell proliferation, matrix synthesis, recoil, and fibrotic vessel contraction), and because it appears to be driven by a variety of agonists (e.g., platelet-derived growth factor, thrombin), agents (such as antisense DNA to the protoonco-

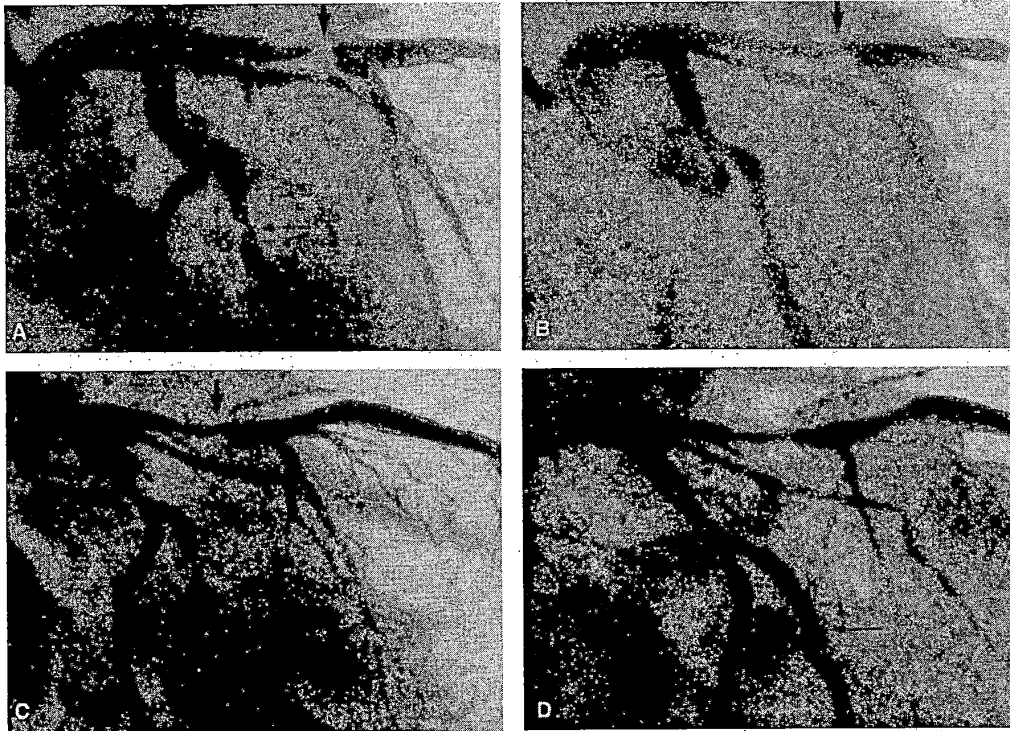


**FIG. 23.17.** The strongest determinants of the probability of restenosis (using a definition of late diameter stenosis greater than 50%) are a large postprocedure lumen diameter and a low residual percent stenosis. Once these variables are taken into account, it no longer matters which device was used—it is the result and not the device that matters. Balloon angioplasty (triangles) resulted in a 2- to 2.3-mm lumen with a 40% restenosis rate, whereas stenting produces a 2.9- to 3.2-mm lumen with a 20% restenosis rate (slightly worse results with stenting in the STRESS study are shown, as well). Directional atherectomy (squares) had an angioplasty-like result in CAVEAT but a more stent-like result in BOAT and OARS (see Chapters 24 and 25). (Modified from Kuntz RE, et al. A generalized model of restenosis following conventional balloon angioplasty, stenting, and directional atherectomy. *J Am Coll Cardiol* 1993;21:15.)

gene *c-myc*) that selectively inhibit a final common pathway (smooth muscle cell division) may be of benefit (85). In conventional angioplasty, where late vessel contraction (in addition to the neointimal proliferation response) plays an important role, drugs such as probucol, which seem to favorably affect late remodeling, may be of value (86). On the possibility that antirestenosis drugs might have to be delivered locally or in high concentration or prolonged duration to the treatment site, a number of local drug delivery systems and sustained-delivery vehicles are being investigated (87). The other promising approach is local radiation therapy (brachytherapy). Studies with both  $\gamma$ - and  $\beta$ -radiation (88,89,89a) suggest that a dose of roughly 1,400 to 1,800 rad (cGy) delivered to the treatment site by a catheter system retards the local proliferative response and may be a promising primary or secondary treatment for restenosis, particularly the purely proliferative restenosis that takes place within stents.

### LONG-TERM RESULTS OF ANGIOPLASTY

Although the preceding discussion of restenosis emphasizes mechanistic and quantitative angiographic analyses of late outcome (with an emphasis on the status of the treated site), the long-term *clinical* benefit of coronary angioplasty as a strategy for treating patients with coronary artery disease derives from its ability to prevent subsequent ischemic events. The traditional measure of this ability has been the freedom of angioplasty patients from any subsequent events, including death, MI, or a repeat revascularization procedure (either repeat PTCA or late bypass surgery). As trials of new devices have unfolded, however, it has become increasingly important to distinguish whether the cause of a late cardiac event or repeat revascularization is *restenosis of the dilated segment* or the *unchecked natural history of coronary artery disease* (i.e., the persistence or progression of disease elsewhere in the coronary tree). In general,



**FIG. 23.18.** Recurrent angina caused by progressive disease in a nondilated segment. Left coronary artery in right anterior oblique projection before (A) and after (B) successful dilatation of the middle left anterior descending (LAD) coronary artery. Despite the presence of a moderate lesion in the circumflex marginal branch, this patient had an entirely normal exercise tolerance test until the recurrence of symptoms 1 year later. C and D: Preserved patency of the LAD but interval progression of the circumflex stenosis, which was then dilated successfully to restore an asymptomatic status. (From Baim DS. Percutaneous transluminal coronary angioplasty: analysis of unsuccessful procedures as a guide toward improved results. *Cardiovasc Intervent Radiol* 1982;5:186.)

the events that develop during the restenosis window—the first 8 months after successful angioplasty—reflect predominantly restenosis of the treated segment (84). Given the quiescence of the dilated lesion beyond 6 months (81,90), most of the events that develop after 8 months reflect the progression of disease at other sites (Fig. 23.18). Because most late events trigger a repeat cardiac catheterization, it is possible to decide whether the originally treated lesion was responsible, thus “filtering” late clinical end points into those that are and are not related to failure at the original treatment site (target lesion revascularization, or TLR). Such distinctions have become commonplace when reporting or comparing the incidence of clinical events after

a particular coronary intervention. On the other hand, when strategies for treating the patient with coronary artery disease are compared (i.e., medicine versus angioplasty or angioplasty versus bypass surgery), the more meaningful comparison remains the occurrence of any late clinical event.

The concept of collecting and analyzing late clinical and angiographic follow-up data began with Gruentzig’s original series of 169 patients, of whom 133 underwent a successful procedure, in Zurich between 1977 and 1980. A 10-year follow-up study on that group (91) showed an overall survival rate of 89.5%, higher in the 81 patients with SVD than in the 52 patients with multivessel disease (95% vs. 81%, respectively).

This was comparable to the 92% survival rate in the 36 patients who underwent unsuccessful PTCA, of whom 32 had coronary artery bypass graft (CABG) surgery (emergency in 13 and elective CABG in 19). Angiography at 6 months showed recurrence in 38 patients (a 31% restenosis rate), 36 of whom had associated symptoms. Only 4 additional patients who had a patent angioplasty site at 6 months developed restenosis later during follow-up (a 3% later restenosis rate), although 25 patients (18%) went on to develop significant narrowing at other non-dilated sites during follow-up. At 10 years, patients with single-vessel versus multivessel disease at the time of initial PTCA had substantially better clinical outcomes, with a lower actuarial incidence of MI (9% vs. 29%); MI or bypass surgery (26% vs. 48%); and MI, bypass surgery, or repeat PTCA (37% vs. 44%). They also had better symptomatic status, with freedom from angina in 79% versus 67%, respectively.

These long-term data from this "index" angioplasty series are mirrored in more recent studies (except for a much higher initial procedural success rate). Because most of the late events relating to the treatment site occur in the first 6 to 8 months, it is appropriate to concentrate on a shorter follow-up period (i.e., 1 year). A follow-up report on 838 patients with SVD in the 1985-1986 Registry (92) showed mortality in 1.6%, MI in 1.9%, repeat angioplasty in 18.1%, and bypass surgery in 6.2% within the first year after hospital discharge. In more recent studies, in which balloon angioplasty has included stenting of the worst acute results (see earlier discussion of provisional stenting), the incidence of repeat revascularization within the first year in patients with single-vessel intervention has fallen further, with a TLR rate (by either catheter intervention or bypass surgery) of only 17%, and similarly-defined 1-year TLR rates in some stent trials as low as 12%.

The repeat revascularization rates for patients with multivessel disease are clearly higher (see later discussion). In the 1985-1986 Registry, patients with multivessel disease had a higher in-hospital mortality rate than those with single-vessel disease (1.7% vs. 0.2%); adverse events within the first year after hospital discharge were

only slightly more common (mortality in 2.8%, MI in 3.4%), but patients with multivessel disease had an increased need for repeat revascularization. This has been borne out in the randomized trials (e.g., Bypass Angioplasty Revascularization Investigation [BARI]) comparing angioplasty with bypass surgery for patients with multivessel coronary artery disease, where up to 35% of angioplasty patients (but only 5% of surgery patients) required a repeat revascularization within the first year after treatment (92). Newer studies, in which patients with multivessel disease are treated with stenting (rather than with conventional balloon angioplasty alone, as in the studies performed in the late 1980s), have a reduced (approximately 20%) late need for repeat revascularization.

Until a practical and completely effective means of preventing restenosis is established, patients who develop recurrent symptoms in the months after a successful angioplasty should be presumed to have a problem with restenosis. They should be scheduled for repeat coronary angiography, with the anticipation that, should the presence of restenosis of the dilated segment be confirmed, a repeat intervention (Fig. 23.15) will be performed during the same procedure. When repeat balloon angioplasty was the only such procedure available, it was noted that the acute success and safety rates of a repeat angioplasty for restenosis were somewhat higher than those of first angioplasties, but that at least 30% of such patients would go on to develop a second restenosis (93). At particularly high risk (94) were men with long lesions or associated disease progression at other sites who presented with recurrent stenosis within 5 months after the first dilatation. Subsequent restenoses were treated by third, fourth, or even fifth dilatations, although the restenosis rate approached 50% as the number of repeat dilatations increased (95). Many patients with recurrent restenosis ultimately chose the alternative of surgical revascularization. In the new device era, most such patients will have undergone stent placement for these lesions at some point in their treatment history. Although this may decrease the incidence of subsequent restenosis, when it does occur the special considerations relating to the

treatment of in-stent restenosis apply (see Chapters 24 and 25). With recent studies suggesting that local radiation (brachytherapy) is the key to controlling in-stent restenosis, however, this long-standing limitation of angioplasty may be largely controlled.

Several other causes of recurrent symptoms after apparently successful coronary angioplasty should be considered. The first is coronary artery spasm, which may be exacerbated within the first 6 weeks after the procedure (96). Many groups use calcium channel blockers during this period, particularly given the suggestion that uncontrolled spasm may increase the chance of organic restenosis (97). A second cause of recurrent symptoms after successful angioplasty is persistence of disease in undilated segments. Whereas cardiac surgeons routinely bypass all significant stenoses at the time of surgery, most angioplasty operators confine their efforts to the severe (greater than 70%) stenoses (98), leaving behind more moderate lesions that are unlikely to cause persistent symptoms. The rationale for this approach is that dilatation of these milder lesions requires additional time and administration of contrast medium, exposes the patient to additional hazards of abrupt vessel closure, and may initiate progressive restenosis leading to a more severe lesion than was present initially (99). On the other hand, failure to dilate significant and clinically relevant lesions in patients with multivessel disease may cause persistent symptoms leading to subsequent need for revascularization (Fig. 23.18). When symptoms recur more than 6 months after successful dilatation, disease progression is the most likely explanation (100). Whether symptom recurrence is triggered by restenosis or lesion progression, repeat catheter-based intervention is usually effective in long-term nonoperative management (101). Late stenosis at the left or right coronary ostium (presumably the result of guiding catheter-induced injury) also has been reported as a rare cause of late symptom recurrence (102) and is readily apparent on angiographic restudy.

#### CURRENT INDICATIONS

With the improvements in equipment and technique that have been described, coronary an-

gioplasty has grown progressively through the 1980s and 1990s (Fig. 23.1). By 1990, more than 400,000 angioplasty procedures were performed annually, represent almost half all revascularizations (angioplasty plus bypass) performed in the United States each year (5). By the end of the 1990s, the number of percutaneous catheter-based revascularizations (including both conventional balloon angioplasty and the ever-growing family of newer devices) had grown to more than 500,000. The fact that there has been no demonstrable fall in the use of bypass surgery during this period suggests that the use of angioplasty has moved beyond the narrow group of patients who would have undergone bypass surgery (as had been suggested in the original NHLBI registry guidelines) to the point where it is now also seen as an alternative to medical therapy in selected patients.

These trends toward greater reliance on catheter-based intervention are also evident in the record of individual programs. Since the mid-1980s, about one third of all patients coming through our diagnostic laboratory have been treated by coronary angioplasty. Data from Emory between 1981 and 1988 (103) show a similar pattern. The percentage of diagnostic catheterization patients going on to coronary angioplasty increased from 4.3% to 30.3%, while the percentage undergoing bypass surgery decreased only from 44.0% to 28.5%. Therefore, almost as much of the growth in angioplasty procedures over that period was explained by contraction of the fraction of patients treated medically (from 51.7% to 41.2%) as by the shift from surgery to angioplasty. In a survey of practice extending from 1989 to 1997 at the 17 U.S. sites that participated in the BARI trials (see Multivessel Coronary Artery Disease), the percentage of all revascularizations that were catheter based (versus surgical) increased from 52.2% to 62% by 1997, with a corresponding growth of new devices from 11.6% to 67% of all catheter-based procedures (104).

Because the person who is responsible for case selection is often the person who will perform the angioplasty, it is critically important that operators have a full understanding of the indications and outcomes so that only suitable patients are treated. The issues that need to be

addressed include (a) how compelling is the clinical justification for revascularization, (b) do the "culprit" lesions have anatomic features that suggest reasonable level of safety and probability of successful dilatation, (c) what combination of conventional balloon angioplasty and newer interventional devices would offer the best short- and long-term outcomes, and (d) does angioplasty compare favorably (or at least equally) with the other therapeutic options such as bypass surgery or continued medical therapy. This evaluation process involves integration of complex clinical, angiographic, pathophysiologic, and technical knowledge to decide whether a particular patient is a "candidate" for angioplasty and therefore constitutes an important component of angioplasty operator training (see earlier discussion).

With the rapid growth of coronary angioplasty, several cardiology organizations have prepared position statements that attempt to outline its "correct" utilization (16,105) (Table 23.3). These statements are useful compilations that outline some well accepted indications and

contraindications for coronary angioplasty, but they each consign situations in which decisions are difficult and individualized to a "possibly indicated" category. In an effort to review some aspects of these evolving or controversial indications, the following discussion of various anatomic clinical applications of coronary angioplasty is offered.

### Single-Vessel Coronary Disease

When the NHLBI registry was formed in 1979, patients were selected in the context of the abilities of then-current angioplasty equipment and the considerable risk of the new therapeutic modality. To be candidates for coronary angioplasty, a patient was required to have medically refractory angina, objective evidence of myocardial ischemia, and single-vessel coronary disease (51), with a lesion that was proximal, discrete, subtotal, concentric, and noncalcified. Although these criteria (in the form of the American College of Cardiology/American Heart Association [AHA/ACC] lesion classification scheme) continue to identify patients with the

**TABLE 23.3.** *Clinical indications for percutaneous transluminal coronary angioplasty (PTCA)<sup>a</sup>*

| Potential indications   | Potential absolute or relative contraindications   |
|---|--|
| Significant stenosis of one or more major epicardial arteries, which subtend at least a moderate-sized area of viable myocardium, in a patient with any of the following: | High-risk anatomy, including significant left main coronary artery disease in which vessel closure would probably result in hemodynamic collapse |
| Recurrent ischemic episodes after myocardial infarction or major ventricular arrhythmia   | Severe, diffuse, and/or extensive coronary artery disease better treated surgically  |
| Angina that has not responded adequately to medical therapy   | Target lesion morphology (type C) with anticipated success less than 60%, unless PTCA is the only reasonable treatment option                    |
| Clear evidence of myocardial ischemia on resting, ambulatory or exercise electrocardiography  | No coronary stenosis greater than 50% diameter reduction   |
| Objective evidence of myocardial ischemia that increases the overall risk of required noncardiac surgery  | No objective or compelling clinical evidence of myocardial ischemia  |
| Acute myocardial infarction with obstruction or severe stenosis of the infarct-related vessel   | Absence of on-site surgical backup, qualified PTCA operators, or adequate radiographic imaging equipment   |

<sup>a</sup> General concepts behind patient selection for PTCA favor anatomically suitable lesions in a patient with a convincing clinical presentation suggesting benefit from revascularization. The application of these concepts to individual patients requires considerable clinical judgment.

Modified from Ryan TJ, et al. Guidelines for percutaneous transluminal coronary angioplasty: a report of the ACC/AHA task force. *J Am Coll Cardiol* 1993;22:2033.

**TABLE 23.4.** *Characterization of lesion suitability (AHA/ACC A,B,C Classification)<sup>a</sup>*

| Type A lesions<br>(minimally complex) | Type B lesions<br>(moderately complex)          | Type C lesions<br>(severely complex)                   |
|---------------------------------------|---|--|
| Discrete (length <10 mm)              | Tubular (length 10–20 mm)                       | Diffuse (length >2 cm)                                 |
| Concentric                            | Eccentric                                       | Excessive tortuosity of proximal segment               |
| Readily accessible                    | Moderate tortuosity or proximal segment         | Extremely angulated segments (>90°)                    |
| Nonangulated segment (<45°)           | Moderately angulated segment (45°–90°)          | Total occlusions >3 mo old and/or bridging collaterals |
| Smooth contour                        | Irregular contour                               | Inability to protect major side branches               |
| Little or no calcification            | Moderate or heavy calcification                 | Degenerated vein grafts with friable lesions           |
| Less than totally occlusive           | Total occlusions <3 mo old                      |  |
| Not ostial in location                | Ostial in location                              |  |
| No major side branch involvement      | Bifurcation lesions requiring double guidewires |  |
| Absence of thrombus                   | Some thrombus present                           |  |

<sup>a</sup> Although the A,B,C lesion classification was generated by consensus rather than prospective analysis, it still correlates well with the expected outcome of the procedure. Minimally complex (type A) lesions have the highest probability of success and the lowest probability of complication. Moderately complex (type B) lesions have somewhat lower probability of success and a somewhat higher probability of complication, particularly if multiple type B factors are present. Severely complex (type C) lesions have the lowest probability of success and the highest probability of complication and are generally avoided. The availability of new devices has "upgraded" some traditional B and C morphologies. For example, calcified lesions respond well to rotational atherectomy, bifurcation lesions respond well to directional atherectomy, and vein grafts respond well to stenting.

highest likelihood of success (Table 23.4), major improvements in equipment and technique have permitted the safe and effective application of coronary angioplasty in patients with far less than this ideal anatomy. Steerable guidewires, dilatation catheters with smaller deflated profiles, and adjunctive devices such as stenting, directional atherectomy, rotational atherectomy, and excimer laser have allowed operators to attempt dilatation of progressively more complex anatomic lesions, in progressively sicker patients, with ever-improving results. Recent data suggest that a lesion's high AHA/ACC class does not itself correlate with unfavorable success or complication probability—rather, that specific morphologies such as bifurcation lesions or degenerated saphenous vein grafts are more predictive (106, 106a)—and that experienced operators are able to select lesions at low, medium, or high risk of complication in a way that transcends their AHA/ACC class (107).

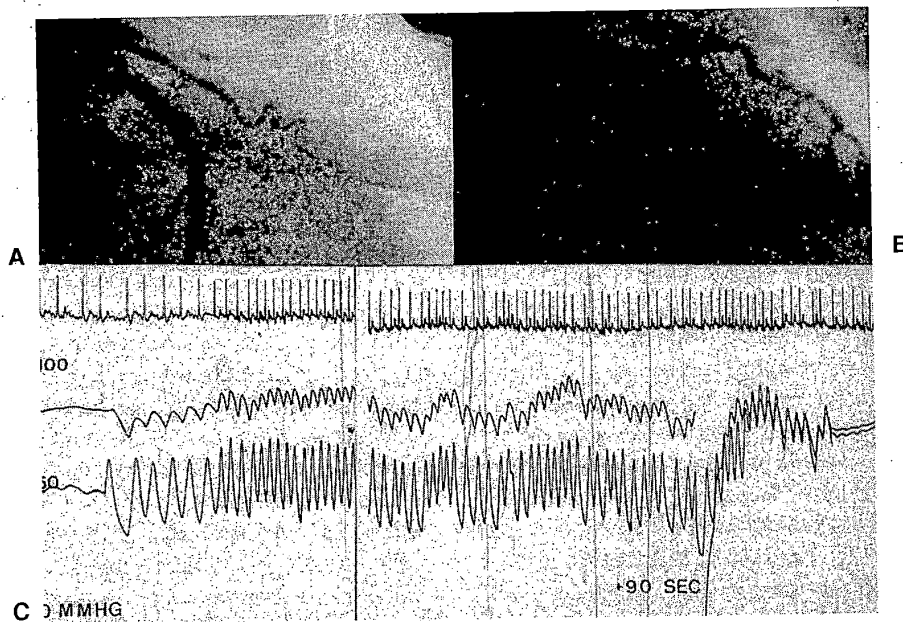
However the clinical and anatomic circumstances have changed, patients with a single lesion needing treatment still account for the majority of angioplasty procedures. In the Emory data from 1988, 318 (46%) of 692 patients with SVD were treated by angioplasty, compared with 159 (30.1%) of 528 patients with double-

vessel disease and 43 (10.6%) of 405 patients with triple-vessel disease (103). In those patients with SVD, the intent of angioplasty is not to improve life expectancy (which is already excellent with medical therapy), although Duke data-bank analysis does suggest a slightly higher 5-year survival rate with angioplasty (95%, vs. 93% with CABG and 94% with medical therapy) (108). Rather, the primary intent in the patient with angina due to SVD is to improve quality of life by alleviating angina. The Veterans Administration (VA) Angioplasty Compared to Medical Therapy (ACME) trial (109) suggested that even conventional balloon angioplasty is better able to achieve this goal than is ongoing medical therapy. Despite a PTCA success rate of only 80%, 64% of PTCA patients (compared with 46% of medically treated patients) were free of angina at 6 months, with the PTCA patients showing a greater increase (2.1 minutes) in exercise time off antianginal medication (compared with a 0.5-minute increase in the medical patients receiving antianginal drugs). The price paid for this symptomatic improvement was a small risk of acute complications (2% emergency bypass, 1% Q-wave MI) and a 23% need for a repeat procedure (PTCA in 16%, bypass surgery in 7%) in the cohort assigned to

PTCA. In contrast, 9% of the group assigned to medical therapy had late angioplasty for refractory symptoms. At 6 months, there was one death in the medical group and none in the angioplasty group. Follow-up to 3 years showed ongoing symptomatic benefit in the angioplasty group. Based on these data, not all patients with stable angina resulting from SVD need, to undergo angioplasty, particularly if they are reasonably content with their quality of life on medical therapy. Most patients, however, seek better exercise tolerance or relief from medication side effects, if angioplasty for an anatomically suitable single-vessel lesion can be offered at a low risk. This would appear to be an even more compelling option since the possibility of stent placement has further reduced the short-term risk of failure or complication, as well as the long-term risk of restenosis. In the setting of unstable angina or acute MI, the use of angioplasty to treat SVD becomes even more reasonable (see later discussion).

### Total Coronary Occlusion

Although total occlusion was initially a contraindication to attempting angioplasty, it has been clear since the early to mid-1980s that many chronic total occlusions can be dilated successfully. The main reason to attempt such a procedure is if the distal myocardium receives collaterals that are adequate to maintain viability but inadequate to meet the increased demand of exercise (Fig. 23.19). The main challenge in angioplasty of a total occlusion is the need to pass a guidewire through the area of occlusion and into the vessel lumen beyond. This is best done by crossing through the path of least resistance (i.e., the "latent" true lumen), without causing vascular dissection or perforation in the attempt. The traditional approach is to use a series of guidewires (progressing from soft- to stiff-tipped) to gently probe the stump of the occlusion until the latent vascular channel is entered. The wire is then rotated and advanced millimeter



**FIG. 23.19.** Angioplasty of a totally occluded left anterior descending (LAD) coronary artery, shown before (A) and after (B) angioplasty. C: The proximal (PROX) and distal (DIST) LAD pressure waveforms. This patient had normal anterior wall motion because of the presence of right-to-left collaterals capable of maintaining a distal occluded LAD pressure of almost 50 mm Hg, but not capable of meeting flow requirements during exertion. (From Dervan JP, Baim DS, Cherniles J, et al. Transluminal angioplasty of occluded coronary arteries: use of a movable guidewire system. *Circulation* 1983;68:776.)



by millimeter through the total occlusion until it emerges into the distal coronary artery beyond. Even in experienced hands, this approach has a primary success rate in cases of chronic total occlusion of only 60% to 70% (110), mostly because of inability to advance the guidewire across the occlusion. The presence of one or more chronic total occlusions is one of the most common reasons for sending a patient to bypass surgery rather than attempting angioplasty. Until alternative approaches (such as drug- or laser-induced angiogenesis to enhance collateral inflow or more effective mechanical devices) are developed, the biggest factors in approaching total occlusions successfully will be careful case selection and operator expertise.

The success rate may be higher for chronic occlusions that have a tapered or funnel-like entry suggesting the presence of a small (0.010-inch) residual lumen (111). The presence of bridging (vasa vasora) collaterals across the area of total occlusion has been thought to be a negative predictor of success, but with careful technique (staying within the lumen rather than exiting into the vasa) success and safety comparable to that seen without such collaterals can be achieved (112). This is facilitated by aiming deliberately toward the continuation of the vessel, which can be aided by performing separate contrast injections into the contralateral (collateral-supplying) coronary artery to opacify the target vessel beyond the area of total occlusion, and by visualizing the anatomy with biplane fluoroscopy or frequent alternation of the single-plane projection. The success of crossing such lesions has improved with the introduction of stiffer and lubricious coated guidewires (Choice-PT, SciMed; Shinobi, Cordis Corporation, Miami, FL) (113) and ball-tip wires (Magnum, Sci Med) (114). A variety of other approaches have been evaluated, including low-speed rotational angioplasty (115), ultrasound vibrational angioplasty (116), and the excimer laser guidewire (117). None of these more aggressive techniques has significantly increased the ability to cross the chronic total occlusion, and they tend to increase the incidence of vessel perforation or extensive local dissection. Still newer techniques (including forward-looking imaging) are under devel-

opment. If a device can be found that safely improves crossing success for these difficult lesions, it will greatly increase the number of patients who can be served by coronary angioplasty.

Once the guidewire has been passed into the distal vessel, treatment of the total occlusion proceeds as does any other catheter-based intervention. If crossing the lesion has been difficult or has required the use of aggressive guidewire manipulation, it is appropriate to confirm that the distal wire position is in fact intraluminal before advancing or inflating larger devices by performance of a distal injection through an infusion catheter (e.g., Ultrafuse-X, Boston Scientific, Natick, MA). This injection also evaluates the distal anatomy for additional areas of disease. Once these issues are clear, the lesion can be crossed with a balloon catheter and dilated in the usual manner. Perhaps because of competitive flow by way of distal collaterals, plaque bulk, or other lesional characteristics, successfully dilated total occlusions appear to have a higher (40% to 50%) restenosis rate than do subtotal stenoses (110). Several randomized trials have shown that long-term patency can be improved by the use of coronary stents, which further improve the acute lumen caliber, with a restenosis rate of 32% after stenting compared with 74% with balloon angioplasty alone (118).

#### Multivessel Coronary Artery Disease

With the improved success rate in single-vessel coronary angioplasty, extension of the technique to patients with multivessel disease seemed natural. Selected patients with severe stenosis of two or even all three coronary arteries began to be considered for true multivessel angioplasty in the late 1980s. But most patients with multivessel disease who received angioplasty actually underwent single-vessel dilatation, with the hope that correction of the most severe "culprit" lesions would control ischemic symptoms even though milder lesions in other vessels remained untreated (98). Although it is possible to attempt angioplasty on these milder residual lesions, experience showed that these dilatations carried a significant risk of acute ves-

sel occlusion and their treatment could initiate the restenosis process, resulting in the formation of a severe stenosis within a matter of months (99). On the other hand, leaving significant lesions untreated increased the chance of a late repeat procedure (angioplasty or bypass surgery). In one analysis (119), performing incomplete revascularization (leaving behind stenoses greater than 50% in vessels greater than 1.5 mm in diameter) more than doubled the chance of a late event and increased the risk of 5-year events by 50% even after adjustment for other variables such as left ventricular function, angina class, and territory at risk. This is an important consideration, because fewer than half of the patients undergoing angioplasty in the setting of multivessel disease meet these strict criteria for complete revascularization (92,120). Furthermore, angioplasty in multivessel disease is more demanding technically than single-vessel angioplasty and carries a higher risk of complications should vessel occlusion occur (52,53).

Reanalysis of the medicine versus surgery trials from the 1970s only strengthened the conclusion that bypass surgery offers a clear benefit over medical therapy in patients with multivessel disease (121). It was therefore important to determine how well angioplasty as an initial strategy would compare with bypass surgery. Registries such as the Duke database suggested that surgery would have a survival benefit over angioplasty in patients with triple-vessel disease or double-vessel disease involving severe stenosis of the proximal LAD (108). To gain a clearer picture, several randomized trials of angioplasty versus surgery in multivessel disease were performed in the late 1980s. Several of the trials have been summarized in a metaanalysis by Pocock (122), and two are discussed here in some detail.

Both the Emory EAST trial (123) and BARI (92) showed that fewer than 15% of screened patients with multivessel disease could even be considered suitable for angioplasty—chief exclusions being one or more chronic occlusions, left main coronary artery disease, or a left ventricular ejection fraction of less than 25%. About 60% of the randomized group had double-vessel disease and 40% had triple-vessel disease. In

EAST, angioplasty (compared with surgery) provided somewhat less complete initial revascularization (73% vs. 99%), a slightly lower incidence of major in-hospital complications (death, 1%; MI, 3% vs. 10%; stroke, 0.5% vs. 1.5%), and a lower initial hospital cost. Over the next 3 years, although patients treated by initial angioplasty had a similar total mortality rate (7.1% vs. 6.2%), they were much more likely to undergo an additional revascularization procedure (repeat angioplasty, 41% vs. 13%; bypass surgery, 22% vs. 1%) to treat angina due to restenosis of the dilated segment or a territory not revascularized during the initial procedure. Although this eroded much of the initial hospital savings, it did not increase the incidence of late irreversible events (i.e., death, MI). In the randomized portion of the BARI trial of 1,829 patients (92), all lesions were successfully dilated in only 57% of patients (an average 1.9 of 3.5 significant lesions per patient); in comparison, there was complete surgical revascularization in 91% of patients (3.1 coronaries bypassed). Despite a slightly lower incidence of in-hospital death or Q-wave MI (3.0% vs. 5.8%) and a similar 5-year survival rate (86.3% vs. 89.3%), patients treated with initial angioplasty were more likely to undergo a repeat revascularization (54%, including 31% with subsequent CABG) than patients undergoing initial bypass (8%). Of concern in BARI, patients with diabetes fared significantly worse with angioplasty than with surgery, with 5-year all-cause mortality rates of 34.5% and 19.4%, respectively (95% confidence interval for difference, 1.4% to 28.9%). This may reflect the more diffuse nature of coronary disease and the higher incidence of restenosis in diabetics (see Restenosis). The difference between surgery and angioplasty was much less pronounced in the BARI Registry (5-year mortality rate, 14.4% vs. 14.9% for surgery) (124). With the freedom of the registry, operators generally performed angioplasty on diabetic patients who had more localized angiographic disease. For example, the incidence of triple-vessel disease in registry was 35% for angioplasty and 60% for bypass; in the randomized BARI cohort, these figures were 43% and 45%, respectively. This complex issue needs to be addressed further

in the 7 and 10-year follow-up of BARI (124a) and the planned BARI-II trial, but it is reasonable to continue to offer catheter-based revascularization to those diabetics who have reasonably discrete lesions while referring patients with more diffuse disease to bypass surgery (125).

Based on these data, fewer than 20% of patients with multivessel disease are likely to be judged as good candidates for coronary angioplasty, compared with more than half of those with SVD (103,123,124). These selected patients can be offered initial angioplasty without increasing their risk of subsequent death or MI, but they must be prepared to accept a four-fold (e.g., 54% vs. 13%) increased need for a subsequent revascularization procedure, including a 22% chance that they will ultimately need bypass surgery anyway. Otherwise, bypass surgery should remain the standard approach to patients with diffuse multivessel coronary artery disease, in whom it provides a more durable benefit than angioplasty, particularly in patients with underlying diabetes. The durability of the result may be improved, however, through the use of other non-balloon technologies such as coronary stenting. Preliminary data suggest that patients treated by multivessel stent placement have a lower and acceptable incidence of late revascularization, with repeat angioplasty rates of 25% to 30% and a low incidence of late bypass surgery (less than 5%) in anatomically suitable patients (126,127).

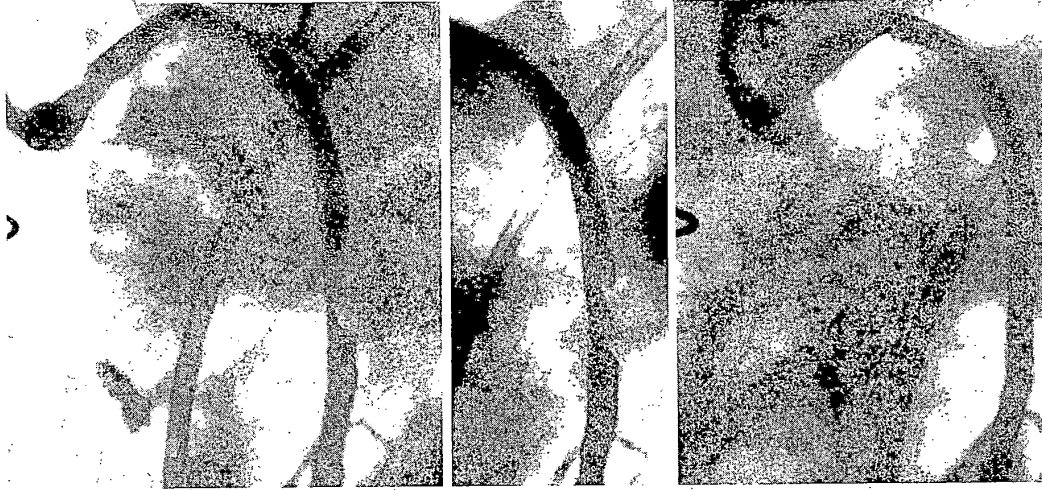
Trials comparing surgery versus stenting are in progress to reexamine the question in the context on the modern new device era, but even these trials do not include newer modalities such as minimally invasive bypass of the LAD combined with catheter-based treatments of the circumflex and right coronary artery (128), or the inclusion of catheter-based treatments of significant left main coronary artery stenosis. Balloon angioplasty of left main lesions not "protected" by a patent graft to the LAD or circumflex was previously demonstrated to have a poor long-term outlook. Experience in the stent era indicates good acute results in elective left main procedures, but still a high (10% or more) mortality rate in the first year, probably reflecting restenosis (129). As the predictability and durability of

catheter-based intervention continue to improve, it is likely that its indications will encompass more patients with left main or multivessel disease.

### Bypass Grafts

Bypass surgery provides excellent early symptomatic benefit, but 40% of saphenous vein conduits become occluded and many more develop severe narrowing within 10 years after surgery (130). Although only 2% of such patients require angioplasty or repeat bypass surgery within the first 5 years, 31% require a repeat revascularization by year 12 (including 20% reoperation and 15% PTCA) (131). Internal mammary conduits have a better long-term track record (132), but some of these grafts develop early significant stenosis at the distal anastomosis. Finally, patients with previous bypass surgery frequently develop new or progressive disease beyond a graft insertion site or in a nongrafted vessel over time. By these various mechanisms, it is common for the patient who has undergone a previous bypass operation to develop recurrent angina. Although this can be managed by repeat bypass surgery, repeat surgery is a higher-risk procedure in a patient population that is older and sicker than those undergoing initial bypass. With the progressive growth of coronary angioplasty, many such patients can be managed by catheter-based intervention on the diseased graft or a stenotic native vessel, and angioplasty of postoperative patients accounts for approximately 20% of current volume. Although angioplasty has a lower in-hospital mortality rate than reoperation (1.2% vs. 6.8%), late mortality is similar and angioplasty carries a higher incidence of repeat interventions, including a 24% 5-year risk of requiring reoperation (133).

When attempting angioplasty in a patient with previous bypass surgery, the operator should keep in mind that the extensive mediastinal fibrosis and risk of injuring functional anterior grafts would prolong the time required for emergency surgery should a complication of angioplasty occur. Although vein-graft stenoses that occur within the first year after surgery are




**FIG. 23.20.** Saphenous vein graft intervention. **Left:** Eccentric stenosis in the midportion of an 8-year-old saphenous vein graft to the left anterior descending coronary artery. **Center:** After conventional balloon angioplasty, there is marked disruption of the plaque and elastic recoil, leaving a 70% residual stenosis. **Right:** After placement of a single Palmaz-Schatz stent, there is a smooth lumen with no residual stenosis. These excellent acute results, plus the favorable late restenosis rate, make stenting the treatment of choice for the focally diseased saphenous vein graft.

caused most commonly by intimal hyperplasia and respond quite well to balloon dilatation, late vein-graft stenoses (average, 8 years after surgery) are caused more commonly by diffuse atherosclerosis that has a distinct tendency to fragment and/or embolize into the distal coronary bed during dilatation (134,135) (Fig. 23.20). In a 1993 report of their experience with angioplasty for bypass grafts, de Feyter et al. (135) found a primary success rate of 88%, with complications including death (1%), MI (4%), emergency bypass (2%), and distal embolization (3%). Although these acute results may be acceptable, they also found that dilated graft lesions had a high restenosis rate (42% overall), and the rate was even higher in the midportion and body of the graft (58% and 52%, respectively). Other factors associated with increased risks of a poor acute result included grafts older than 3 to 4 years, multiple lesions or diffuse disease, small graft diameter, and the presence of intragraft thrombus, each of which increased the restenosis rate to almost 80%. In addition to plaque friability, older grafts frequently contain thrombus, which may embolize during attempted angioplasty. Grafts with large throm-

botic filling defects were often pretreated by intracoronary infusion of a thrombolytic agent (136), such as urokinase 50,000 to 100,000 IU/hour or recombinant tissue plasminogen activator (r-tPA) 20 mg over 20 minutes, to dissolve clot and allow the underlying stenosis to be dilated (Fig. 23.21). More recently, such grafts have been approached with extraction atherectomy (TEC) or rheolytic thrombectomy (Possis AngioJet, Minneapolis, MN) to remove thrombi before definitive mechanical intervention (see Chapter 24). A similar approach can be used on grafts that are more chronically occluded, but poor long-term patency gives such procedures only marginal utility (137).

As with other lesion types, the availability of new devices has improved the results of vein graft treatment. Directional atherectomy has been used successfully, but the randomized CAVEAT-II trial failed to show significant benefit in long-term outcome (see Chapter 24). On the other hand, stenting has consistently shown superior short- and long-term results (Fig. 23.20). Early registries from both my institution (138) and the Washington Hospital Center (139) in the early 1990s used Palmaz-Schat coronary and bil-



**FIG. 23.21.** Thrombus-laden graft. **Top left:** Recently occluded saphenous vein graft in a patient with unstable angina shows long, lobulated filling defect consistent with thrombus. **Bottom left:** A drug infusion catheter (Tracker, Target Therapeutics) with 6 cm of side-holes between the gold markers (*small arrows*) has been placed across the thrombotic segment. **Top right:** After overnight infusion of urokinase (50,000 IU/hour), there has been marked cleanup of the thrombus, revealing the underlying focal stenosis in the distal third of the graft. **Bottom right:** Placement of a single Palmaz-Schatz coronary stent normalizes this area of focal disease. Recent trials with the rheolytic thrombectomy catheter have shown mechanical thrombectomy to be superior to prolonged infusion of a thrombolytic agent (see Chapter 24).

inary stents in a population whose mean graft age exceeded 8 years and achieved a 98% acute success, almost 0% residual stenosis, acute complications in less than 2%, and an angiographic restenosis rate in the 17% to 25% range. Although quite small (approximately 200 patients total) the randomized Saphenous VEin graft Disease (SAVED) trial confirmed these benefits over conventional balloon angioplasty (140) and made stenting the preferred therapy for treatment of the diseased vein graft. With the introduction of second-generation stent designs starting in 1997, more flexible stent designs are now available, including the self-expanding Wallstent (see Chapter 25). But even effective local treatments like stents are unable to prevent

late failures at other (nonstented) portions of the same or other vein grafts, contributing substantially to the need for repeat procedures in follow-up after successful vein graft intervention (141).

Despite the successes of stenting, the problem of distal embolism has continued to plague treatment of these older vein grafts (45–47). Even without angiographically evident filling defects, these diffusely diseased older grafts may contain sufficient debris to increase their risk of developing frank “no reflow” syndrome. This syndrome involves marked diminution in antegrade flow with profound myocardial ischemia, even though the proximal vessel is free of stenosis or dissection and there are no “cutoffs” in the distal vessel. When this condition represents distal

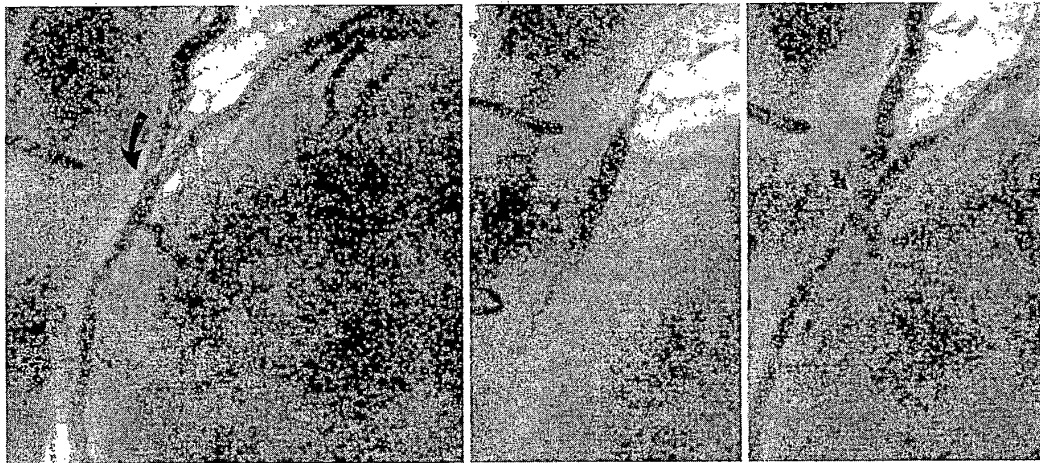
microvascular spasm caused by the release of serotonin from platelet-rich thrombi, it can be reversed quickly by distal injection of a calcium channel blocker (see Chapter 3). In vein grafts, however, many such episodes are refractory to vasodilators and go on to cause large MIs and a substantial (20%) in-hospital mortality. Recent work with a distal occlusion/aspiration device (GuardWire, PercuSurge, Sunnyvale, CA) (142) has demonstrated that the cause of "no reflow" in vein grafts is embolization of atherosclerotic debris (e.g., cholesterol clefts, foam cells), for which the best therapy is likely to be use of distal protective devices (including occlusion devices and filters). The advent of stents with impermeable coverings may also help control this distal embolization problem.

Unlike saphenous veins, *internal mammary artery grafts* are generally resistant to disease, with a 10-year patency rate of better than 90% (132). Still, some patients develop recurrent angina early (within 6 months) after bypass surgery due to stenosis of the internal mammary–native artery anastomosis. These lesions can be dilated effectively with the use of low-profile, trackable

dilatation catheters (143), with a moderate (approximately 20%) restenosis rate (Fig. 23.22). Second-generation stents may easily track through internal mammary grafts to treat these distal anastomotic lesions. When evaluating patients with recurrent ischemia in the distribution of an internal mammary graft, it is also important to investigate the possibility of subclavian or brachiocephalic stenosis proximal to the internal mammary origin, which can now be treated by angioplasty or stent placement (144). Limited data regarding angioplasty of gastroepiploic artery grafts suggest similar results of angioplasty in these arterial conduits (145). Although they are technically also a "graft," the response of the diffuse lesions characteristic of cardiac homografts (accelerated allograft vasculopathy) to coronary angioplasty have not been well characterized (146).

#### Stable Angina

The initial group of patients who were candidates for coronary angioplasty were patients with stable but medically refractory angina pec-



**FIG. 23.22.** LIMA angioplasty. This 58-year-old man developed recurrent angina 5 months after bypass surgery that had involved grafting of the left internal mammary artery (IMA) to the left anterior descending (LAD) coronary artery (whose proximal segments had exhibited early restenosis after two rotational atherectomy procedures). **Left:** In the left lateral projection, severe stenosis (*curved arrow*) is seen at the distal anastomosis, where the IMA meets the LAD. **Center:** Inflation of a 3.0 mm over-the-wire angioplasty balloon at 70 psi. **Right:** Posttreatment angiography shows 20% residual stenosis. This site and timing (as well as the favorable response to conventional balloon angioplasty) are typical for postoperative problems with the IMA graft.

toris and suitable coronary anatomy. Occasionally patients with milder symptoms and ideal anatomy are candidates if they have favorable coronary anatomy and objective evidence of ischemia, and are willing to accept the small risk that angioplasty will lead to emergency bypass surgery and the 20% risk that they will need repeat intervention for the treatment of restenosis (105). This approach was borne out for patients with SVD in the VA ACME trial (109), which showed better freedom from angina and better exercise tolerance in patients randomly assigned to angioplasty treatment, at the expense of more repeat procedures for restenosis. However, patients with mild symptoms should be aware that the ACME trial failed to demonstrate any improvement in the already excellent rates of survival or freedom from infarction seen with medical therapy in a stable angina population with SVD. Of course, the ACME trial was performed before the widespread use of stenting, which has substantially improved the success, safety, and durability of catheter-based intervention, so that similar studies would have to be redone to provide relevant data for today's practice. The findings of the recent Asymptomatic Cardiac Ischemia Pilot study (ACIP) involving 558 patients with ambulatory electrocardiographic evidence of ischemia in the absence of significant symptoms (147) suggest that even these patients may benefit from catheter-based revascularization.

One group worthy of separate mention is elderly patients with severe stable or unstable angina. Unlike bypass surgery (which carries a higher risk and a longer recovery period in the elderly), angioplasty has almost as favorable an outlook in this group as it does in younger patients (148). Although such patients tend to have more challenging anatomy (multiple, diffuse, or calcified lesions), they frequently can be offered palliation by angioplasty as an alternative to bypass surgery. Patients older than 65 years of age now constitute more than 35% of the 1988 Emory angioplasty population (103); 39% of the current patients at Beth Israel are 65 to 79 years of age, and 8% are age 80 or older.

### Unstable Angina

Patients with unstable angina (including angina at rest, post-MI angina, accelerating angina, and new-onset angina) have accounted for the majority of interventions in most institutions. Early reports are available from the ThoraxCenter (149), and the 1985–1986 NHLBI PTCA registry (150). In the Registry, 857 patients had unstable angina, 79% of whom had rest angina. The majority of patients with new-onset angina had SVD, largely severe focal stenosis of the LAD coronary artery. Angioplasty was attempted on a mean of 1.6 lesions per patient, with success in 85% and major complications including death (1.4%), nonfatal MI (2.7%), and emergency surgery (4.3%). Complications were greatest in the subgroup of 219 patients with acute coronary insufficiency (rest pain for more than 30 minutes without diagnostic enzyme elevation).

This approach to the patient with unstable angina was evaluated further in the Thrombolysis in Myocardial Infarction (TIMI) IIIB trial, which examined the role of r-tPA as well as management strategy in 1,473 patients with unstable angina or non-Q-wave MI (151). In the early invasive strategy, patients underwent diagnostic catheterization at a mean of 1.5 days, which led to revascularization in 61% (38% by PTCA and 25% by bypass surgery). PTCA in this group of patients had a favorable outcome (success, 93%; death, 0.4%; nonfatal MI, 2.9%; emergency bypass, 0.7%). Of the patients assigned to a conservative (noncatheterization) strategy, 60% required catheterization primarily for failure of initial therapy, with revascularization in 49% of the patients assigned to this strategy (26% by PTCA and 24% by CABG) within 6 weeks after enrollment. Although there was no difference in the composite end point (death, MI, or positive exercise test) at 6 weeks, patients in the conservative arm required more repeat hospitalizations, more hospital days, and more medications to achieve this end. At 1-year follow-up, the patients receiving early invasive treatment showed a nonsignificant trend toward less death or MI (10.8% vs. 12.2%;  $p = \text{NS}$ ), with fewer repeat

hospitalizations (26 vs. 35%;  $p = .038$ ), and only slightly higher cumulative revascularization rates (64% vs. 58%) with equal bypass rates (30%) at 1 year. The authors concluded that early catheterization after 18 to 48 hours of anti-ischemic therapy can be carried out safely, clarifies the therapeutic options, and allows prompt delivery of revascularization when appropriate.

The benefits of early catheterization and revascularization for patients with unstable angina were less clear in the 920 patient, VA-based VANQWISH trial (152), but this trial has been criticized for the relatively low use of revascularization in both arms (44% invasive; 33% conservative), the 11% surgical mortality in the invasive arm, and differentially high mortality in nonrevascularized patients (9% in the invasive arm, 5% in the conservative arm). In contrast, the recent Scandinavian trial, Fast Revascularization during Instability in Coronary artery disease (FRISC-II) showed clear benefits, in terms of mortality, readmission, and cost, for the strategy of brief initial medical stabilization (with anticoagulants as well as newer antiplatelet agents including IIb/IIIa blockers), followed by cardiac catheterization and (if anatomically suitable) catheter-based revascularization including the use of coronary stents (153). Of the 2,457 patients, 91% of those treated invasively had an intervention within 10 days after hospital admission, and the invasive arm showed a 21% relative reduction in the 6-month composite of death or MI (9.5% vs. 12.0%), with an even greater reduction among males (9.1% vs. 13.9%), who also had a significantly reduced mortality rate (1.5% vs. 3.2%). Most U.S. centers now follow a similar strategy, with initial medical stabilization followed by a diagnostic catheterization performed with "angioplasty standby" so that suitable lesions can be treated by balloon dilatation or other catheter-based therapies during the same procedure.

### Acute Myocardial Infarction

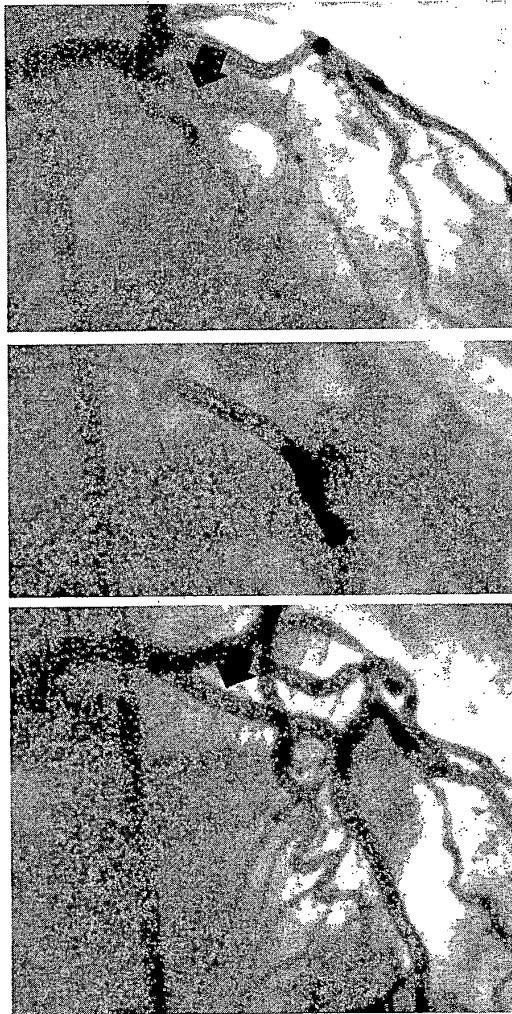
The treatment of acute MI has undergone a major revolution over the past 15 years, with the recognition that intracoronary thrombosis is the

final mechanism of vessel occlusion and the understanding that prompt reestablishment of vessel patency offers significant clinical benefit (154). Current "front-loaded" or "double-bolus" regimens using potent thrombolytic agents (e.g., r-tPA) can open almost 75% of infarct vessels within 90 minutes after intravenous administration. A purely pharmacologic approach to the management of MI has not proved completely satisfactory, however, because approximately 15% of vessels fail to open in response to thrombolytic therapy, only half of the open vessels have normal (TIMI grade 3) flow, and at least 10% of vessels opened by thrombolysis either reocclude or cause recurrent angina during hospitalization due to the persistence of an underlying high-grade atherosclerotic stenosis (155). Although newer combinations of thrombolytics with platelet IIb/IIIa receptor blockers may achieve higher rates of initial patency (156), they do so with an increase in bleeding complications.

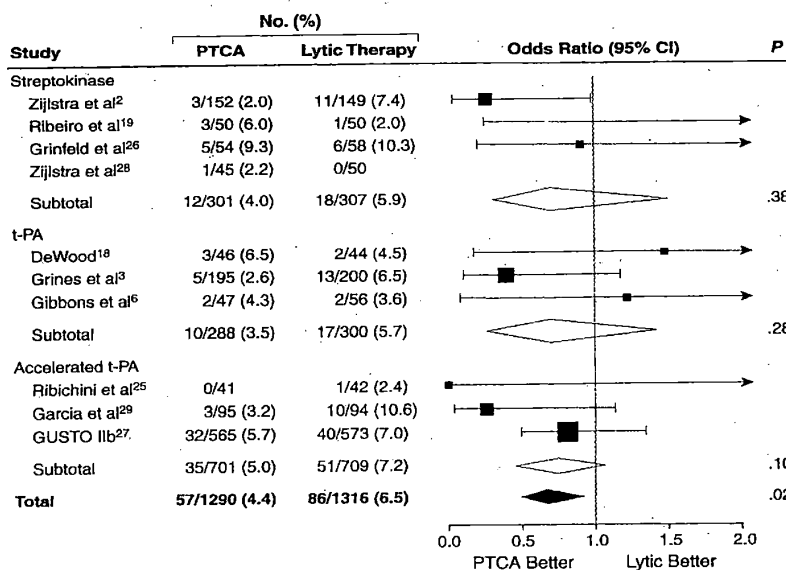
These shortcomings of thrombolysis prompted several large clinical trials in the late 1980s to explore the optimal strategy of combining thrombolysis with mechanical revascularization using balloon angioplasty (if possible) or bypass surgery. These trials demonstrated that immediate catheterization and angioplasty carry an increased risk and offer no additional benefit in terms of survival or recovery of left ventricular function (157). In fact, the TIMI IIB trial reported that even routine delayed catheterization (18 to 48 hours after thrombolysis) offered no additional benefit over a conservative strategy in which catheterization and angioplasty were reserved for patients with recurrent spontaneous or exercise-provoked ischemia (158).

On the other hand, some operators reported excellent results using primary angioplasty instead of thrombolysis to open occluded vessels in the early hours of infarction (159) (Fig. 23.23). In the early 1990s, the Primary Angioplasty in Myocardial Infarction (PAMI) (160), the Zwolle (161) trials, and a metaanalysis of the four principal trials (total of 2,606 patients) (162) established that prompt primary angioplasty offered better acute patency, fewer rein-





**FIG. 23.23.** Primary angioplasty for acute myocardial infarction (MI). A primary angioplasty procedure (**left, top**) shows baseline total occlusion of the proximal left anterior descending coronary artery (*arrow*) 2 hours into acute anterior MI with cardiogenic shock. Primary angioplasty (**left, center**) is shown with placement of a perfusion balloon across the area of occlusion. After angioplasty (**left, bottom**), there is no residual stenosis (*arrow*) and brisk antegrade flow. Despite a peak creatine kinase values approaching 2,000, this patient's hemodynamic status recovered promptly, with normal wall motion on gated nuclear ventriculography 6 weeks later. **Below:** Metaanalysis of more than 2,600 patients from studies comparing primary angioplasty with thrombolytic therapy shows significant reduction in mortality (from roughly 6% to 4%) with primary angioplasty. CABG, coronary artery bypass graft surgery; PTCA, percutaneous transluminal coronary angioplasty. (From Weaver WD, Simes J, Betriu A, et al. Comparison of primary coronary angioplasty and intravenous thrombolytic therapy for acute myocardial infarction: a quantitative review. *JAMA* 1997;278:2093, with permission.)



fractions, better mortality (3% to 4% vs. 6% to 7%), and fewer strokes than a strategy based on primary administration of a thrombolytic agent. Of course, these studies enrolled only thrombolytic-eligible patients, excluding elderly patients, patients with central nervous system disease, those with cardiogenic shock, and those who had ongoing ST-segment elevation after thrombolytic administration, who have an even higher mortality rate (15% to 20%) with medical therapy and would only be treatable only by acute angioplasty. While excluded patients have a higher mortality rate with primary angioplasty than do thrombolytic-eligible patients, there is strong evidence that acute revascularization does reduce the mortality in such patients with cardiogenic shock. In an analysis from the GUSTO I trial, patients with acute cardiogenic shock who underwent revascularization within the first 30 days (predominantly by angioplasty) had a significantly better 1-year mortality rate than those who did not (37% vs. 70%) (163). Similarly, there is evidence that patients with failed thrombolysis have an acute angioplasty success rate of 88% and a mortality rate of 8.6% after successful rescue PTCA that is similar to the 5.2% mortality rate for successful thrombolysis in GUSTO I (164).

Based on those studies, our institution began in 1994 to offer primary angioplasty as our around-the-clock frontline therapy for acute MI. This requires a team of experienced angioplasty operators and catheterization personnel who can be in the cardiac catheterization laboratory within 30 minutes, so that a patient can be brought to the laboratory within 60 minutes and have the infarct-related artery open within 90 minutes after emergency room presentation (165). Results of primary angioplasty have improved further with the use of stenting and IIb/IIIa blockers during the procedure. Some studies have even suggested that community hospitals that do not themselves have cardiac surgery or elective angioplasty programs but are staffed by active interventional cardiologists can also deliver primary angioplasty effectively, although this activity is not included in the most recent (1999) revision of the ACC/AHA guidelines for management of acute MI (166). As

thrombolytic regimens (and associated anti-thrombin and antiplatelet drugs) improve, it is likely that the role of mechanical versus pharmacologic thrombolysis will need to be reexamined, but at present we believe that primary angioplasty (where it is available) constitutes the best revascularization strategy for the patient with acute MI.

### FINANCIAL AND REGULATORY CONSIDERATIONS

Because coronary angioplasty is performed in a cardiac catheterization laboratory under local anesthesia, it is attended by substantially lower in-hospital costs than coronary bypass surgery (167). On the other hand, this cost benefit is partially eroded by the greater need for repeat procedures to treat restenosis within the first year. The net cost savings therefore depend on the extent to which an intervention improves acute outcome and late freedom from restenosis, as well as its cost. In patients with SVD, stenting has proved to be a cost-effective or even cost-saving technology, whereas in patients with extensive multivessel disease catheter-based revascularization may be a more costly approach than bypass surgery. In general, however, catheter-based revascularization strategies offer less patient morbidity, faster return to work, and equivalent mortality benefit and symptom relief (barring the restenosis) and are therefore preferred when anatomically possible. Because the decision frequently is being made by the same operator (i.e., the cardiologist who performs the diagnostic catheterization, makes the decision about treatment, and then performs the coronary angioplasty), the large expense associated with catheter revascularization has increasingly made angioplasty a target for scrutiny in the managed-care environment (168).

In addition to issues about the appropriateness of angioplasty procedures and markedly different utilization rates across the country (169), there is also a major question about whether every hospital should offer bypass surgery or angioplasty. In fact, only about 1,500 of the nation's 7,000 hospitals do so, but there is continued pressure on those that do not to open such

programs (170). Data from California (171) and a nationwide study of 217,836 Medicare beneficiaries who underwent coronary angioplasty (172) clearly show excess mortality and emergency surgery rates in hospitals that perform fewer than 200 angioplasty procedures per year.

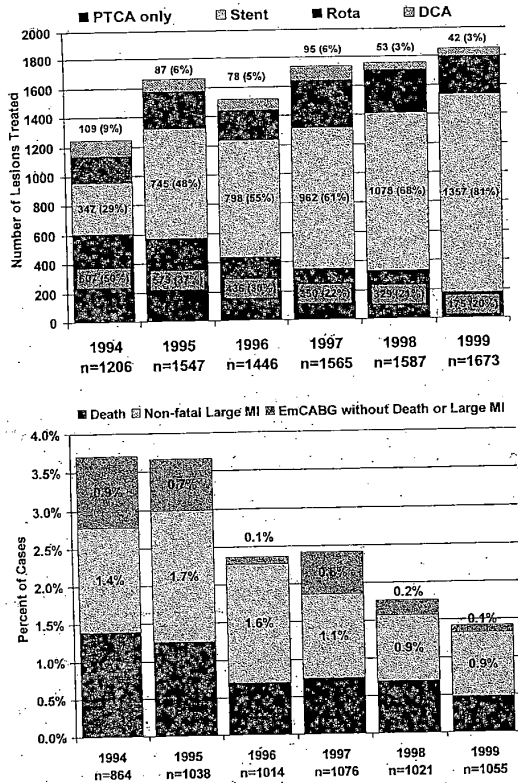
These same issues concern the training and continued caseload for angioplasty operators (173). Early in the development of coronary angioplasty, physicians active in diagnostic catheterization learned to perform angioplasty by attending live demonstration courses and watching or assisting on a small number of procedures (i.e., 10 to 20) under the guidance of a knowledgeable operator. Given the ever-increasing complexity of the procedure, however, virtually all new angioplasty operators since the mid-1980s have received formal training consisting of a third (or third and fourth) year of interventional fellowship beyond completion of their training in diagnostic coronary angiography. During the interventional fellowship, a trainee should perform a minimum of 250 procedures (173a). There is evidence that operators who maintain an annual interventional caseload of fewer than 75 procedures have a higher rate of risk-adjusted complications than higher-volume operators, not just for all patients, but also for low-complexity (AHA/ACC A or B1) lesions (174), and even for stenting (175). To further standardize interventional training in 1999, the Accreditation Council for Graduate Medical Education (ACGME) began certifying interventional fellowship programs, and the Board of Internal Medicine began offering an examination- and caseload-based Certificate of Additional Qualification in Interventional Cardiology (176). These changes will almost certainly put pressure on the more than 7,000 "angioplasty operators" in the United States, most of whom perform less than half of the recommended annual caseload of 75 interventions. As catheter-based interventions continue to evolve toward progressively more challenging clinical and anatomic situations, and as the development of new technologies for coronary intervention continues, increasing functional specialization will be required of "interventional" cardiologists. This action is in keeping with the recommendations

of the 1993 ACP/ACC/AHA task force, which advised that "the proliferation of small-volume operators should be curtailed by appropriate institutional review" (16).

#### ROLE OF CONVENTIONAL ANGIOPLASTY IN THE NEW DEVICE ERA

Between its introduction in 1977 and 1990, conventional balloon angioplasty (POBA) was the only mechanical intervention available for percutaneous coronary revascularization. The choice of devices was very much like the situation described by Mark Twain: "To the man with a hammer, everything looks like a nail." In contrast, the period from 1988 through 1994 saw unparalleled investigation of a wave of new stent and atherectomy devices (177). The first of the new devices (directional coronary atherectomy) was approved by the U.S. Food and Drug Administration (FDA) in 1990, followed by approval of two other atherectomy devices (rotational and extraction atherectomy), excimer lasers, and two balloon-expandable stents by 1994. Second generations of these devices have been developed, and even newer classes of devices (e.g., thrombectomy, distal protection, radiation) have continued to be introduced. Over only a few years, these new devices have progressively replaced POBA as the dominant stand-alone tool for coronary intervention.

To be chosen over balloon angioplasty, a new device must be expected to provide an advantage in terms of (a) the predictability of the acute result, (b) the quality of the acute result (less residual stenosis), (c) the ability to treat a lesion that would have been refractory to conventional angioplasty, or (d) the ability to reduce the incidence of subsequent restenosis. Moreover, such treatment must be provided in a cost-effective way (if it costs more, it also must provide a clinical benefit worth that extra cost [178]), and it must not unduly increase the complication rate. Although balloon angioplasty remains unmatched in its simplicity, anatomic versatility, and broad clinical applicability, the availability of new devices has made balloon angioplasty more of an adjunctive treatment (for predilation



**FIG. 23.24.** Changing new device use and results at Beth Israel Deaconess Medical Center during the “new device era.” **Upper panel:** During the 6-year period from 1994 through 1999, inclusive, there was a dramatic increase in the use of stenting (from 29% to 81% of interventions) as well ongoing use of atherectomy (directional plus rotational atherectomy from approximately 20% of interventions), but a corresponding decrease in the use of stand-alone balloon angioplasty (from 50% to 20% of interventions). **Lower panel:** The clinical benefits of this trend are reflected in the ability to treat a broader range of lesion types, an increasing primary success rate (from 92% to 98%), and a halving in the incidence of major complications—death, large myocardial infarction (MI) (i.e., Q-wave MI or creatine kinase more than 5 times normal), or emergency surgery—from 3.7% to 1.5%. By 1999, intravenous blockers of platelet glycoprotein IIb/IIIa receptor were used in approximately 30–40% of patients in whom a perfect mechanical result could not be achieved by catheter-based techniques.

to aid in device passage or postdilation to improve the new device-created result) than a stand-alone treatment. Coronary stents have become heir apparent to balloon angioplasty and are currently being used in more than 80% of catheter-based interventions (see Chapter 25). The atherectomy technologies (directional and rotational atherectomy) are still beneficial for debulking certain lesion types (ostial, calcified, bifurcation lesions), as definitive treatment or to improve the results of subsequent stent placement. These same debulking treatments are also effective in treating in-stent restenosis, particularly when combined with local radiation therapy to inhibit regrowth of the proliferative neointima (see Chapter 24).

Although there is still some uncertainty about which new device is best for which lesion, I believe that “lesion-specific new device therapy” is here to stay. In our practice, as shown in Fig. 23.24, the percentage of interventional procedures in which a new device was used has risen from roughly 50% in 1994 to more than 80% in 1998. During this time, there has been a progressive fall (from 5% to 1.5%) in the incidence of major adverse clinical events, including virtual elimination of emergency bypass surgery (less than 0.2%) and a stable mortality rate of 0.6% in non-acute-infarction patients, despite the treatment of an older, sicker patient population with more complex lesion anatomy. Although much of the research focus in interventional cardiology has shifted to understanding the mechanism, technique, and optimal indications for these new devices, I believe that balloon angioplasty will continue to play a crucial role as an adjunct to new device therapies. Whatever new modalities are introduced—be they forms of angiogenesis (179,180), laser direct myocardial revascularization (181), or nonsurgical septal reduction for hypertrophic obstructive cardiomyopathy (182)—the skills, knowledge, and judgment derived from balloon angioplasty will continue to form the foundation on which broader interventional skills are built in coming years.

**REFERENCES**

1. Dotter CT, Judkins MP. Transluminal treatment of arteriosclerotic obstruction: description of a new tech-

- nique and a preliminary report of its application. *Circulation* 1964;30:654.
2. Gruentzig A, Kumpe DA. Technique of percutaneous transluminal angioplasty with the Gruentzig balloon catheter. *AJR Am J Roentgenol* 1979;132:547.
  3. Gruentzig AR, Senning A, Siegenthaler WE. Non-operative dilatation of coronary artery stenosis—percutaneous transluminal coronary angioplasty. *N Engl J Med* 1979;301:61.
  4. King SB. Angioplasty from bench to bedside. *Circulation* 1996;93:1621.
  5. Bittl JA. Advances in coronary angioplasty. *N Engl J Med* 1996;335:1290.
  6. Baim D, Kent KM, King SB 3rd, et al. Evaluating new devices: acute (in-hospital) results from the New Approaches to Coronary Intervention Registry. *Circulation* 1994;89:471.
  7. Mehta S, et al. Voda guiding catheter is superior to Amplatz guiding catheter for performing left circumflex PTCA. *J Invasive Cardiol* 1994;6:229.
  8. Simpson JB, Baim DS, Robert EW, et al. A new catheter system for coronary angioplasty. *Am J Cardiol* 1982;49:1216.
  9. Dervan JP, McKay RG, Baim DS. The use of an exchange wire in coronary angioplasty. *Cathet Cardiovasc Diagn* 1985;11:207.
  10. Ohman EM, Marquis JF, Ricci DR, et al. A randomized comparison of the effects of gradual prolonged versus standard primary balloon inflation on early and late outcome: results of a multicenter clinical trial. *Circulation* 1994;89:1118.
  11. Carell ES, Schroth G, Ali A. Circumferential balloon rupture and catheter fracture due to entrapment in a calcified coronary stenosis. *Cathet Cardiovasc Diagn* 1994;32:34.
  12. Tenaglia AN, Zidar JP, Jackman JD Jr, et al. Treatment of long coronary artery narrowings with long angioplasty balloon catheters. *Am J Cardiol* 1993;71:1274.
  13. Cannon AD, Roubin GS, Hearn JA, et al. Acute angiographic and clinical results of long percutaneous transluminal coronary angioplasty and adjuvant stenting for long narrowings. *Am J Cardiol* 1994;73:635.
  14. Plante S, Strauss BH, Goulet G, et al. Reuse of balloon catheters for coronary angioplasty: a potential cost-saving strategy? *J Am Coll Cardiol* 1994;24:1475.
  15. O'Meara JJ, Dehmer GJ. Care of the patient and management of complications after percutaneous coronary artery interventions. *Ann Intern Med* 1997;127:458.
  16. Ryan TJ, et al. Guidelines for percutaneous transluminal coronary angioplasty: a report of the ACC/AHA task force. *J Am Coll Cardiol* 1993;22:2033.
  17. Fuster V, Dyken ML, Vokonas PS, et al. Aspirin as a therapeutic agent in cardiovascular disease: AHA medical scientific statement. *Circulation* 1993;87:659.
  18. Leon MB, Baim DS, Popma JJ, et al. A randomized trial comparing three anti-thrombotic drug regimens following coronary-artery stenting. *N Engl J Med* 1998;339:1665.
  19. Kong DF, Califf RA, Miller DP, et al. Outcomes of therapeutic agents that block the platelet glycoprotein IIb/IIIa integrin in ischemic heart disease. *Circulation* 1998;98:2829.
  20. Harvey JR, Wyman RM, McKay RG, et al. Use of balloon flotation pacing catheters for prophylactic temporary pacing during diagnostic and therapeutic cardiac catheterization. *Am J Cardiol* 1988;62:941.
  21. Ferguson JJ, Dougherty KG, Gaos CM, et al. Relation between procedural activated coagulation time and the outcome after percutaneous transluminal coronary angioplasty. *J Am Coll Cardiol* 1994;23:1061.
  22. Popma JJ, Weitz J, Bittl JA, et al. Antithrombotic therapy in patients undergoing coronary angioplasty. *Chest* 1998;114:728S.
  23. Lefkowitz J, Topol EJ. Direct thrombin inhibitors in cardiovascular medicine. *Circulation* 1994;90:1522.
  24. Karsch KR, Preisack MB, Baildon R, et al. Low molecular heparin (Reviparin) in percutaneous transluminal coronary angioplasty: results of a randomized, double-blind, unfractionated heparin and placebo-controlled multicenter trial (REDUCE trial). *J Am Coll Cardiol* 1996;28:437.
  25. Burchenal JEB, Marks, DS, Mann JT, et al. Effect of direct thrombin inhibition with bivalirudin (Hirulog) on restenosis after coronary angioplasty. *Am J Cardiol* 1998;82:511.
  26. Roubin GS, Douglas JS Jr, King SB 3rd, et al. Influence of balloon size on initial success, acute complications, and restenosis after percutaneous transluminal coronary angioplasty. *Circulation* 1988;78:557.
  27. Nichols AB, Smith R, Berke AD, et al. Importance of balloon size in coronary angioplasty. *J Am Coll Cardiol* 1989;13:1094.
  28. Chenu P, Zakhia R, Marchandise B, et al. Resistance of the atherosclerotic plaque during coronary angioplasty: a multivariable analysis of clinical and angiographic variables. *Cathet Cardiovasc Diagn* 1993;29:203.
  29. Muramatsu T, Tsukahara R, Ho M, et al. Efficacy of cutting balloon angioplasty for lesions at the ostium of the coronary arteries. *J Invasive Cardiol* 1999;11:201.
  30. Shawl FA. Minimally invasive angioplasty: acute and long-term results of low-pressure dilation with a non-compliant balloon during percutaneous transluminal coronary angioplasty. *J Invasive Cardiol* 1993;5:122.
  31. Blankenship JC, Kruckoff MJ, Werns SW, et al. Comparison of slow oscillating versus fast balloon inflation strategies for coronary angioplasty. *Am J Cardiol* 1999;83:675.
  32. Kaltenbach M, Beyer J, Walter S, et al. Prolonged application of pressure in transluminal angioplasty. *Cathet Cardiovasc Diagn* 1984;10:213.
  33. Anderson HV, Roubin GS, Leimgruber PP, et al. Measurement of transstenotic pressure gradient during percutaneous transluminal coronary angioplasty. *Circulation* 1986;73:1223.
  34. Bech GJW, Pijls NHJ, DeBruyne B, et al. Usefulness of fractional flow reserve to predict clinical outcome after balloon angioplasty. *Circulation* 1999;99:883.
  35. Simpendorfer C, Belardi J, Bellamy G, et al. Frequency, management and follow-up of patients with acute coronary occlusions after percutaneous transluminal coronary angioplasty. *Am J Cardiol* 1987;59:267.
  36. Friedman HZ, Cragg DR, Glazier SM, et al. Randomized prospective evaluation of prolonged versus abbreviated intravenous heparin therapy after coronary angioplasty. *J Am Coll Cardiol* 1994;24:1214.
  37. Pearson T, Raaport E, Criqui M, et al. Optimal risk

- factor management in the patient after coronary revascularization: a statement for healthcare professionals from an American Heart Association Writing Group. *Circulation* 1994;90:3125.
38. Sanborn TA, Faxon DP, Haudenschild C, et al. The mechanism of transluminal angioplasty: evidence for formation of aneurysms in experimental atherosclerosis. *Circulation* 1983;68:1136.
  39. Rensig BJ, Hermans WR, Beatt KJ, et al. Quantitative angiographic assessment of elastic recoil after percutaneous transluminal coronary angioplasty. *Am J Cardiol* 1990;66:1039.
  40. Rozenman Y, Gilon D, Welber S, et al. Clinical and angiographic predictors of immediate recoil after successful coronary angioplasty and relation to late restenosis. *Am J Cardiol* 1993;72:1020.
  41. Fischell TA, Derby G, Tse TM, et al. Coronary artery vasoconstriction after percutaneous transluminal coronary angioplasty: a quantitative arteriographic analysis. *Circulation* 1988;78:1323.
  42. Holmes DR Jr, Vlietstra RE, Mock MB, et al. Angiographic changes produced by percutaneous transluminal coronary angioplasty. *Am J Cardiol* 1983;51:676.
  43. Black AJR, Namay DL, Niederman AL, et al. Tear or dissection after coronary angioplasty: morphologic correlates of an ischemic complication. *Circulation* 1989;79:1035.
  44. Sanborn TA, Faxon DP, Waugh D, et al. Transluminal angioplasty in experimental atherosclerosis: analysis for embolization using an in vitro perfusion system. *Circulation* 1982;66:917.
  45. Baim DS, Carozza JP, Kuntz RE, et al. Managing the "embolization" problem during saphenous vein graft intervention. *Cathet Cardiovasc Interventions* 1999; 47:155.
  46. Topol EJ, Yadov JS. Recognition of the importance of embolization in atherosclerotic vascular disease. *Circulation* 2000;101:570.
  47. Piana R, Paik GY, Moscucci M, et al. Incidence and treatment of "no reflow" after percutaneous coronary intervention. *Circulation* 1994;89:2514.
  48. Weyrens FJ, Mooney J, Lesser J, et al. Intracoronary diltiazem for microvascular spasm after interventional therapy. *Am J Cardiol* 1995;75:849.
  49. Saffitz JE, Rose TE, Oaks JB, et al. Coronary artery rupture during coronary angioplasty. *Am J Cardiol* 1983;51:902.
  50. Ellis SG, Ajluni S, Arnold AZ, et al. Increased coronary perforation in the new device era: incidence, classification, management, and outcome. *Circulation* 1994;90:2725.
  51. Kent KM, Mullin SM, Passamani ER, eds. Proceedings of the National Heart, Lung, and Blood Institute Workshop on the Outcome of Percutaneous Transluminal Angioplasty, June 7-8, 1983. *Am J Cardiol* 1984;53: 1C.
  52. Detre K, Holubkov R, Kelsey S, et al. Percutaneous transluminal coronary angioplasty in 1985-1986 and 1977-1981: the NHLBI registry. *N Engl J Med* 1988; 318:265.
  53. Holmes DR Jr, Holubkov R, Vlietstra RE, et al. Comparison of complications during percutaneous transluminal coronary angioplasty from 1977 to 1981 and from 1985 to 1986: the NHLBI PTCA registry. *J Am Coll Cardiol* 1988;12:1149.
  54. Kent KM, Bonow RO, Rosing DR, et al. Improved myocardial function during exercise after successful percutaneous transluminal coronary angioplasty. *N Engl J Med* 1982;306:441.
  55. Hirzel HO, Neusch K, Gruentzig AR, et al. Short- and long-term changes in myocardial perfusion after percutaneous transluminal coronary angioplasty assessed by thallium-201 exercise scintigraphy. *Circulation* 1981; 63:1001.
  56. Bredlau CE, Roubin GS, Leimgruber PP, et al. In-hospital morbidity and mortality in patients undergoing elective coronary angioplasty. *Circulation* 1985;72: 1044.
  57. Hill JA, Margolis JR, Feldman RL, et al. Coronary arterial aneurysm formation after balloon angioplasty. *Am J Cardiol* 1983;52:261.
  58. Vassarelli C, Turri M, Morando G, et al. Coronary artery aneurysm formation after PTCA: a not uncommon finding at follow-up angiography. *Int J Cardiol* 1989;22:151.
  59. Ferguson JJ, et al. The relation of clinical outcome to dissection and thrombus formation during coronary angioplasty. *J Invasive Cardiol* 1995;7:2.
  60. Ellis SG, Roubin GS, King SB 3rd, et al. Angiographic and clinical predictors of acute closure after native vessel coronary angioplasty. *Circulation* 1988;77:372.
  61. Talley JD, Jones EL, Weintraub WS, et al. Coronary artery bypass surgery after failed elective percutaneous transluminal coronary angioplasty: a status report. *Circulation* 1989;79:1126.
  62. Paik GY, Kuntz RE, Baim DS: Perfusion therapy to resolve myocardial ischemia en route to emergency bypass grafting for failed percutaneous transluminal angioplasty. *J Intervent Cardiol* 1995;8:319.
  63. de Muinck ED, den Heijer P, van Dijk RB, et al. Autoperfusion balloon versus stent for acute or threatened closure during percutaneous transluminal coronary angioplasty. *Am J Cardiol* 1994;74:1002.
  64. George BS, Voorhees WD 3rd, Roubin GS, et al. Multicenter investigation of coronary stenting to treat acute or threatened closure after percutaneous transluminal coronary angioplasty: clinical and angiographic outcomes. *J Am Coll Cardiol* 1993;22:135.
  65. Kelly D, Arora D. Prognostic significance of myocardial enzyme release after coronary interventions. *Cathet Cardiovasc Interventions* 1999;46:292.
  66. Hartzler GO, Rutherford BD, McConahay DR, et al. "High-risk" percutaneous transluminal coronary angioplasty. *Am J Cardiol* 1988;61:33G.
  67. Vogel RA, Shawl F, Tommaso C, et al. Initial report of the National Registry of Elective Cardiopulmonary Bypass-Supported Coronary Angioplasty. *J Am Coll Cardiol* 1990;15:23.
  68. Teirstein PS, Vogel RA, Dorros G, et al. Prophylactic versus standby circulatory support for high risk percutaneous transluminal coronary angioplasty. *J Am Coll Cardiol* 1993;21:590.
  69. Kugelmass AD, Cohen DJ, Moscucci M, et al. Elevation of the creatine kinase myocardial isoform following otherwise successful directional coronary atherectomy and stenting. *Am J Cardiol* 1994;74:748.
  70. Baim DS, Cutlip DE, Sharma SK, et al. Final results of the Balloon vs. Optimal Atherectomy Trial (BOAT). *Circulation* 1998;97:322.
  71. Meier B, Gruentzig AR, King SB 3rd, et al. Risk of

- side branch occlusion during coronary angioplasty. *Am J Cardiol* 1984;53:10.
72. Meier B: Kissing balloon coronary angioplasty. *Am J Cardiol* 1984;54:918.
  73. Osterle SN, McAuley BJ, Buchbinder M, et al. Angioplasty at coronary bifurcations: single-guide, two-wire technique. *Cathet Cardiovasc Diagn* 1986;12:57.
  74. Dauerman HL, Higgins PJ, Sparano AM, et al. Mechanical debulking versus balloon angioplasty for the treatment of true bifurcation lesions. *J Am Coll Cardiol* 1998;32:1845.
  75. Wohlgeleit D, Cleman M, Highman HA, et al. Regional myocardial dysfunction during coronary angioplasty: evaluation by two-dimensional echocardiography and 12 lead electrocardiography. *J Am Coll Cardiol* 1986;7:1245.
  76. Bertrand ME, Leblanche JM, Fourrier JL, et al. Left ventricular systolic and diastolic dysfunction during acute coronary artery balloon occlusion in humans. *J Am Coll Cardiol* 1988;12:341.
  77. Serruys PW, Wijns W, van den Brand M, et al. Left ventricular performance, regional blood flow, wall motion, and lactate metabolism during transluminal angioplasty. *Circulation* 1984;70:25.
  78. Hartzler GO, Rutherford BD, McConahay DR. Retained percutaneous transluminal coronary angioplasty equipment components and their management. *Am J Cardiol* 1987;60:1260.
  79. Serota H, Deligonul U, Lew B, et al. Improved method for transcatheter retrieval of intracoronary detached angioplasty guidewire segments. *Cathet Cardiovasc Diagn* 1989;17:248.
  80. Mintz GS, Popma JJ, Pichard AD, et al. Arterial remodeling after coronary angioplasty: a serial intravascular ultrasound study. *Circulation* 1996;94:35.
  81. Serruys PW, Luijten HE, Beatt KJ, et al. Incidence of restenosis after successful coronary angioplasty: a time related phenomenon. A quantitative angiographic follow-up study of 342 patients. *Circulation* 1988;77:361.
  82. McBride W, Lange RA, Hillis LD. Restenosis after successful coronary angioplasty. *N Engl J Med* 1988;318:1734.
  83. Hirshfeld JW Jr, Schwartz JS, Jugo R, et al. Restenosis after coronary angioplasty: a multivariable statistical model to relate lesion and procedure variables to restenosis. *J Am Coll Cardiol* 1991;18:647.
  84. Kuntz RE, Baim DS. Defining coronary restenosis: newer clinical and angiographic paradigms. *Circulation* 1993;88:1310.
  85. Braun-Dullaeus RC, Mann MJ, Dzau VJ. Cell cycle progression: new therapeutic target for vascular proliferative disease. *Circulation* 1998;98:82.
  86. Cote G, Tardif J, Lesperance J, et al. Effects of probucol on vascular remodeling after coronary angioplasty. *Circulation* 1999;99:30.
  87. Lincoff AM, Ellis SG. Local drug delivery for the prevention of restenosis: fact, fancy, and future. *Circulation* 1994;90:2070.
  88. Teirstein PS, Massullo V, Jani S, et al. Catheter-based radiotherapy to inhibit restenosis after coronary stenting. *N Engl J Med* 1997;336:1697.
  89. King SB, Williams DO, Chougule P, et al. Endovascular beta-radiation to reduce restenosis after coronary balloon angioplasty: results from the Beta Energy Restenosis Trial (BERT). *Circulation* 1998;97:2025.
  - 89a. Kuntz RE, Baim DS. Prevention of coronary restenosis—the evolving evidence base for radiation therapy. *Circulation* 2000;101:2130.
  90. Saito T, Date H, Taniguchi I, et al. Outcome of target sites escaping high-grade (> 70%) restenosis after percutaneous transluminal coronary angioplasty. *Am J Cardiol* 1999;83:857.
  91. King SB, Schlumpf M. Ten-year completed follow-up of percutaneous transluminal coronary angioplasty: the early Zurich experience. *J Am Coll Cardiol* 1993;22:353.
  92. Detre K, Holubkov R, Kelsey S, et al. One-year follow-up results of the 1985–1986 National Heart, Lung, and Blood Institute's percutaneous transluminal coronary angioplasty registry. *Circulation* 1989;80:421.
  93. Black AJR, Anderson HV, Roubin GS, et al. Repeat coronary angioplasty: correlates of a second restenosis. *J Am Coll Cardiol* 1988;11:714.
  94. Leimgruber PP, Roubin GS, Hollman J, et al. Restenosis after successful coronary angioplasty in patients with single vessel disease. *Circulation* 1986;73:710.
  95. Tierstein PS, Hoover CA, Ligon RW, et al. Repeat coronary angioplasty: efficacy of a third angioplasty for a second restenosis. *J Am Coll Cardiol* 1989;13:291.
  96. Hollman J, Austin GE, Gruentzig AR, et al. Coronary artery spasm at the site of angioplasty in the first two months after successful percutaneous transluminal coronary angioplasty. *J Am Coll Cardiol* 1983;2:1039.
  97. Bertrand ME, Leblanche JM, Fourrier JL, et al. Relation of restenosis after percutaneous transluminal coronary angioplasty to vasomotion of the dilated arterial segment. *Am J Cardiol* 1989;63:277.
  98. Wohlgeleit D, Cleman M, Highman HA, et al. Percutaneous transluminal coronary angioplasty of the "culprit lesion" for management of unstable angina in patients with multivessel coronary artery disease. *Am J Cardiol* 1986;58:460.
  99. Ischinger LT, Gruentzig AR, Hollman J, et al. Should coronary arteries with less than 60% diameter stenosis be treated by angioplasty? *Circulation* 1983;68:148.
  100. Joelson JM, Most AS, Williams DO. Angiographic findings when chest pain recurs after successful percutaneous transluminal coronary angioplasty. *Am J Cardiol* 1987;60:792.
  101. Lehmann KG, Maas AC, van Domburg R, et al. Repeat interventions in the management of progressive coronary artery disease. *J Am Coll Cardiol* 1996;27:1398.
  102. Lowe HC, Chesternab CN, Khachigian LM. Left main coronary artery stenosis after percutaneous transluminal coronary angioplasty: importance of remaining "minimally invasive." *Cathet Cardiovasc Diagn* 1999;46:254.
  103. Weintraub WS, Jones EL, King SB, et al. Changing use of coronary angioplasty and coronary bypass surgery in the treatment of chronic coronary artery disease. *Am J Cardiol* 1990;65:183.
  104. Holubkov R, Detre KM, Sopko G, et al. Trends in coronary revascularization 1989–1997: the Bypass Angioplasty Revascularization Investigation (BARI) survey of procedures. *Circulation* 1999;84:157.
  105. Gibbons RJ, Chatterjee K, Daley J, et al. ACC/AHA/ACP-ASIM Guidelines for the management of patients with chronic stable angina: executive

- summary and recommendations. *Circulation* 1999;99:2829.
- 106a. Ellis SG, Gutta V, Miller D, et al. Relation between lesion characteristics at risk with percutaneous intervention in the stent and glycoprotein IIb/IIIc era. *Circulation* 1999;100:1971.
  106. Zaacks SM, Allen JE, Calvin JE, et al. The value of the American College of Cardiology/American Heart Association stenosis morphology classification for coronary interventions in the late 1990s. *Am J Cardiol* 1998;82:43.
  107. Brueren BRG, Suttrop MJ, Ernst JMPG, et al. How good are experienced interventional cardiologists in predicting the risk and difficulty of a coronary angioplasty procedure: a prospective study to optimize surgical standby. *Cathet Cardiovasc Interventions* 1999;46:257.
  108. Mark DB, Nelson CL, Califf RM, et al. Continuing evolution of therapy for coronary artery disease: initial results from the era of coronary angioplasty. *Circulation* 1994;89:2015.
  109. Parisi AF, Folland ED, Hartman P. A comparison of medical therapy in the treatment of single-vessel coronary artery disease. *N Engl J Med* 1992;326:10.
  110. Puma JA, Sketch MH, Tchong JF, et al. Percutaneous revascularization of chronic coronary occlusions: an overview. *J Am Coll Cardiol* 1995;26:1.
  111. Katsuragawa M, Fujiwara H, Miyamae M, et al. Histologic studies in percutaneous transluminal coronary angioplasty for chronic total occlusion: comparison of tapering and abrupt type of occlusion and short and long occluded segments. *J Am Coll Cardiol* 1993;21:604.
  112. Kinoshita I, Katoh O, Nariyama J, et al. Coronary angioplasty of chronic total occlusions with bridging collateral vessels: immediate and follow-up outcome from a large single-center experience. *J Am Coll Cardiol* 1995;26:409.
  113. Freed M, Boatman JE, Siegel N, et al. Glidewire treatment of resistant coronary occlusion. *Cathet Cardiovasc Diagn* 1993;30:201.
  114. Meier B, Carlier M, Finci L, et al. Magnum wire for balloon recanalization of chronic total occlusion. *Am J Cardiol* 1989;64:148.
  115. Kaltenbach M, Vallbracht C, Hartman A. Recanalization of chronic coronary occlusion by low speed rotational angioplasty (ROTACS). *J Intervent Cardiol* 1991;4:155.
  116. Siegel RJ, Gunn J, Ahsan A, et al. Use of therapeutic ultrasound in percutaneous coronary angioplasty: experimental in vitro studies and initial clinical experience. *Circulation* 1994;89:1587.
  117. Hamburger JN, Serruys PW, Scabra-Gomes R, et al. Recanalization of total coronary occlusions using the laser guidewire. *Am J Cardiol* 1997;80:1419.
  118. Sirnes PA, Golf S, Myreng Y, et al. Stenting in chronic coronary occlusion (SICCO): a randomized, controlled trial of adding stent implantation after successful angioplasty. *J Am Coll Cardiol* 1996;28:1444.
  119. Cowley MJ, Vandermael M, Topol EJ, et al. Is traditionally defined complete revascularization needed for patients with multivessel disease treated by elective coronary angioplasty? *J Am Coll Cardiol* 1993;22:1289.
  120. Bourassa MG, Holubkov R, Yeh W, et al. Strategy of complete revascularization in patients with multivessel coronary artery disease (a report from the 1985-1986 NHLBI PTCA registry). *Am J Cardiol* 1992;70:174.
  121. Yusuf S, Zucker D, Peduzzi P, et al. Effect of coronary artery bypass surgery on survival: overview of 10-year results from randomized trials by the Coronary Artery Bypass Surgery Trialists. *Lancet* 1994;344:563.
  122. Pocock SJ, Henderson RA, Rickards AF, et al. Meta-analysis of randomised trials comparing coronary angioplasty with bypass surgery. *Lancet* 1995;346:1184.
  123. King SB, Lembo NJ, Weintraub WS, et al. A randomized trial comparing coronary angioplasty with coronary bypass surgery. *N Engl J Med* 1994;331:1044.
  124. Detre KM, Guo P, Holubkov R, et al. Coronary revascularization in diabetic patients: a comparison of the randomized and observational components of the Bypass Angioplasty Revascularization Investigation (BARI). *Circulation* 1999;99:633.
  - 124a. The BARI Investigators. Seven-year outcome in the Bypass Angioplasty Revascularization Investigation (BARI) by treatment and diabetic status. *J Am Coll Cardiol* 2000;35:1122.
  125. Kuntz RE. Importance of considering atherosclerosis progression when choosing a coronary revascularization strategy: the diabetes-percutaneous transluminal coronary angioplasty dilemma. *Circulation* 1999;99:847.
  126. Laham RJ, Ho KKL, Baim DS, et al. Multivessel Palmaz-Schatz stenting: early results and one-year outcome. *J Am Coll Cardiol* 1997;30:180.
  127. Moussa I, Reimers B, Moses J, et al. Long-term angiographic and clinical outcome of patients undergoing multivessel coronary stenting. *Circulation* 1997;96:3873.
  128. Cohen HA, Zenati M, Smith AJC, et al. Feasibility of combined percutaneous transluminal angioplasty and minimally invasive direct coronary artery bypass in patients with multivessel coronary artery disease. *Circulation* 1998;98:1048.
  129. Baim DS. Is it time to offer elective percutaneous transluminal treatment of the unprotected left main coronary artery? *J Am Coll Cardiol* 2000;35:1551.
  130. Fizzigibbon GM, Kafka HP, Leach AJ, et al. Coronary bypass graft fate and patient outcome: angiographic follow-up of 5,065 grafts related to survival and reoperation in 1,388 patients during 25 years. *J Am Coll Cardiol* 1996;28:616.
  131. Weintraub WS, Jones EL, Craver JM, et al. Frequency of repeat coronary bypass or coronary angioplasty after coronary artery bypass surgery using saphenous venous grafts. *Am J Cardiol* 1994;73:103.
  132. Loop FD, Lytle BW, Cosgrove DM, et al. Influence of internal-mammary-artery graft on 10-year survival and other cardiac events. *N Engl J Med* 1986;314:1.
  133. Weintraub WS, Jones EL, Morris DC, et al. Outcome of reoperative coronary bypass surgery versus coronary angioplasty after previous bypass surgery. *Circulation* 1997;95:868.
  134. Waller BF, Rothbaum DA, Gorfinkel HJ, et al. Morphologic observations after percutaneous transluminal angioplasty of early and late aortocoronary saphenous vein bypass grafts. *J Am Coll Cardiol* 1984;4:784.
  135. deFeyter P, van Suylen RJ, de Jaegere PP, et al. Balloon angioplasty for the treatment of lesions in saphenous vein bypass grafts. *J Am Coll Cardiol* 1993;21:1539.



136. Hartmann JR, McKeever SLS, O'Neill WW, et al. Recanalization of chronically occluded aortocoronary saphenous vein bypass grafts with long-term, low-dose direct infusion of urokinase (ROBUST): a serial trial. *J Am Coll Cardiol* 1996;27:60.
137. de Feyter PJ, Serruys P, van den Brand M, et al. Percutaneous transluminal angioplasty of a totally occluded venous bypass graft: a challenge that should be resisted. *Am J Cardiol* 1989;64:88.
138. Piana RN, Moscucci M, Cohen DJ, et al. Palmaz-Schatz stenting for treatment of focal vein graft stenosis: immediate results and long-term outcome. *J Am Coll Cardiol* 1994;23:1296.
139. Wong SC, Popma JJ, Pichard AD, et al. Comparison of clinical and angiographic outcomes after saphenous vein graft angioplasty using coronary versus "biliary" tubular slotted stents. *Circulation* 1995;91:339.
140. Savage MP, Douglas JS, Fishman DL, et al. Stent placement compared with balloon angioplasty for obstructed coronary bypass grafts. *N Engl J Med* 1997;337:740.
141. Ellis SG, Brener SJ, DeLuca S, et al. Late myocardial ischemic events after saphenous vein graft intervention: importance of initially "non-significant" vein graft lesions. *Am J Cardiol* 1997;79:1460.
142. Webb JG, Carere RG, Virmani R, et al. Retrieval and analysis of particulate debris following saphenous vein graft intervention. *J Am Coll Cardiol* (in press).
143. Hearne SE, Davidson CJ, Zidar JP, et al. Internal mammary artery graft angioplasty: acute and long-term outcome. *Cathet Cardiovasc Diagn* 1998;44:153.
144. Kugelmass AD, Kim D, Kuntz RE, et al. Endoluminal stenting of a subclavian artery stenosis to treat ischemia in the distribution of a patent left internal mammary artery graft. *Cathet Cardiovasc Diagn* 1994;33:175.
145. Isshiki T, Yamaguchi T, Tamura T, et al. Percutaneous angioplasty of stenosed gastroepiploic artery grafts. *J Am Coll Cardiol* 1993;22:727.
146. Topaz O, Cowley MJ, Mohanty PK, et al. Percutaneous revascularization modalities in heart transplant recipients. *Cathet Cardiovasc Interventions* 1999;46:227.
147. Davies RF, Goldberg AD, Forman S, et al. Asymptomatic cardiac ischemia pilot (ACIP) study two-year follow-up: outcomes of patients randomized to initial strategies of medical therapy versus revascularization. *Circulation* 1997;95:2037.
148. Forman DE, Berman A, McCabe CH, et al. PTCA in the elderly: "young old" versus the "old old." *J Am Geriatr Soc* 1992;40:19.
149. deFeyter PJ, Serruys PW, van den Brand M, et al. Emergency angioplasty in refractory unstable angina. *N Engl J Med* 1985;313:342.
150. Bentivoglio LG, Detre K, Yeh W, et al. Outcome of percutaneous transluminal coronary angioplasty in unstable angina pectoris: a report from the 1985-1986 National, Heart, Lung, and Blood Institute Percutaneous Transluminal Coronary Angioplasty Registry. *J Am Coll Cardiol* 1994;24:1195.
151. Anderson HV, Cannon CP, Stone PH, et al. One-year results of the Thrombolysis in Myocardial Infarction (TIMI) IIIB clinical trial: a randomized comparison of tissue-type plasminogen activator versus placebo and early invasive versus early conservative strategies in unstable angina and non-Q wave myocardial infarction. *J Am Coll Cardiol* 1995;26:1643.
152. Boden WE, O'Rourke RA, Crawford MH, et al. Outcomes in patients with acute non-Q-wave myocardial infarction randomly assigned to an invasive as compared with a conservative management strategy (VAN-QWISH). *N Engl J Med* 1998;328:1785.
153. No authors listed. Invasive compared with non-invasive treatment in unstable coronary-artery disease: FRISC prospective randomised multicentre study. FRagmin and Fast Revascularisation during InStability in Coronary artery disease Investigators. 1999;354:708.
154. Ryan TJ, Anderson JL, Antman EM, et al. ACC/AHA guidelines for the management of patients with acute myocardial infarction: executive summary. *Circulation* 1996;94:2341.
155. White HD, Van de Werf FJJ. Thrombolysis for acute myocardial infarction. *Circulation* 1998;97:1632.
156. Antman EM, Giugliano RP, Gibson CM, et al. Abciximab facilitates the rate and extent of thrombolysis: results of the Thrombolysis In Myocardial Infarction (TIMI) 14 trial. *Circulation* 1999;99:2720.
157. Rogers WJ, Baim DS, Gore JM, et al. Comparison of immediate invasive, delayed invasive and conservative strategies after tissue-type plasminogen activator: results of the TIMI IIA trial. *Circulation* 1990;81:1457.
158. The TIMI Study Group. Comparison of invasive and conservative strategies after treatment with intravenous tissue plasminogen activator in acute myocardial infarction. *N Engl J Med* 1989;320:618.
159. O'Keefe JH, Rutherford BD, McConahay DR, et al. Early results and long-term outcome of direct coronary angioplasty for acute myocardial infarction in 500 consecutive patients. *Am J Cardiol* 1989;64:1221.
160. Grines CL, Browne KF, Marco J, et al. A comparison of immediate angioplasty with thrombolytic therapy for acute myocardial infarction. *N Engl J Med* 1993;328:673.
161. deBoer MJ, Hoorntje JC, Ottervanger JP, et al. Immediate coronary angioplasty versus intravenous streptokinase in acute myocardial infarction: left ventricular ejection fraction, hospital mortality, and reinfarction. *J Am Coll Cardiol* 1994;23:1004.
162. Weaver WD, Simes J, Betriu A, et al. Comparison of primary coronary angioplasty and intravenous thrombolytic therapy for acute myocardial infarction: a quantitative review. *JAMA* 1997;278:2093.
163. Berger PB, Tuttle RH, Holmes DR, et al. One-year survival among patients with acute myocardial infarction complicated by cardiogenic shock, and its relation to early revascularization: results from the GUSTO-I trial. *Circulation* 1999;99:873.
164. Ross AM, Lundergan CF, Rohrbeck SC, et al. Rescue angioplasty after failed thrombolysis: technical and clinical outcomes in a large thrombolysis trial. *J Am Coll Cardiol* 1998;31:1511.
165. Caputo RP, Ho KKL, Stoler RC, et al. Effect of continuous quality improvement analysis on the delivery of primary percutaneous transluminal coronary angioplasty for acute myocardial infarction. *Am J Cardiol* 1997;79:1159.
166. Ryan TJ, Antman EM, Brooks NH, et al. 1999 Update: ACC/AHA guidelines for the management of patients with acute myocardial infarction. *J Am Coll Cardiol* 1999;34:890.
167. Ellis SG, Brown KJ, Ellert R, et al. Cost of cardiac

- care in three years after coronary catheterization in a contained care system: clinical determinants and implications. *J Am Coll Cardiol* 1998;31:1306.
168. Langa KM, Sussman EJ. The effect of cost-containment policies on rates of coronary revascularization in California. *N Engl J Med* 1993;329:1784.
169. Topol EJ, Ellis SG, Cosgrove DM, et al. Analysis of coronary angioplasty practice in the United States with an insurance-claims data base. *Circulation* 1993;87:1489.
170. Robinson JC, Garnick DW, McPhee SJ. Market and regulatory influences on the availability of coronary angioplasty and bypass surgery in US hospitals. *N Engl J Med* 1987;317:85.
171. Ritchie JL, Phillips KA, Luft HS. Coronary angioplasty: statewide experience in California. *Circulation* 1993;88:2735.
172. Jolis JG, Peterson ED, DeLong ER, et al. The relation between the volume of coronary angioplasty procedures at hospitals treating Medicare beneficiaries and short-term mortality. *N Engl J Med* 1994;331:1625.
173. Hirshfeld JW, Ellis SG, Faxon DP, et al. Recommendations for the assessment and maintenance of proficiency in coronary interventional procedures. *J Am Coll Cardiol* 1998;31:722.
174. Ellis SG, Weintraub W, Holmes D, et al. Relation of operator volume and experience to procedural outcome of percutaneous coronary revascularization at hospitals with high interventional volumes. *Circulation* 1997;96:2479.
175. Ryan TJ. Stents: expanding the case for volume minimums in interventional cardiology. *J Am Coll Cardiol* 1998;32:977.
176. Parmley WW. Interventional cardiology: an added qualification to the cardiovascular boards. *J Am Coll Cardiol* 1998;30:716.
177. Baim DS, Leon MB, Popma JJ, et al. Problems in the evaluation of new devices for coronary intervention: what have we learned since 1989? *Am J Cardiol* 1997;80[Suppl]:3K.
178. Cohen DJ, Breall JA, Ho KK, et al. Evaluating the potential cost-effectiveness of stenting as a treatment for symptomatic single-vessel coronary disease: use of a decision-analytic model. *Circulation* 1994;89:1859.
179. Losordo DW, Vale PR, Symes JF, et al. Gene therapy for myocardial angiogenesis: initial results with direct myocardial injection of phVEGF-165 as sole therapy for myocardial ischemia. *Circulation* 1998;98:2800.
180. Kornowski R, Leon MB, Fuchs S, et al. Electromagnetic guidance for catheter-based trans-endocardial injection: a platform for intramyocardial angiogenesis therapy. *J Am Coll Cardiol* 2000;35:1031.
181. Shawl FA. Percutaneous transluminal myocardial revascularization: an emerging technology. *J Invasive Cardiol* 1999;11:169.
182. Knight C, Kurbaan AS, Seggewiss H, et al. Nonsurgical septal reduction for hypertrophic obstructive cardiomyopathy: outcome in the first series of patients. *Circulation* 1997;95:2075.

## 24

# Coronary Atherectomy, Atheroablation, and Thrombectomy\*

Richard E. Kuntz and Donald S. Baim

*REK: Harvard Medical School, Division of Clinical Biometry, Brigham and Women's Hospital, Boston, Massachusetts 02115*

*DSB: Harvard Medical School, Center for Innovative Minimally Invasive Therapy, Brigham and Women's Hospital, Boston, Massachusetts 02115*

Unlike balloon angioplasty (Chapter 23) or stent placement (Chapter 25), which widen the coronary lumen by merely displacing atherosclerotic plaque, the family of atherectomy techniques seeks to widen the lumen by actually removing tissue (plaque or thrombus) from the vessel wall. A variety of specific devices and mechanisms of action are available, ranging from cutting and retrieval (directional [1,2] and transluminal excisional atherectomy [3]) to atheroablation without recovery of the resulting debris (rotational [4,5] and laser atherectomy [6]). Also included are the recently approved Possis AngioJet thrombectomy suction catheter (which has no cutting elements but uses a highly efficient vacuum generation system to provide efficient removal of intracoronary thrombus) and the new class of embolus containment devices (which do not act on the lesion itself, but rather trap and recover atheroembolic debris liberated from the lesion by other devices).

The proportion of interventions involving atherectomy has diminished (to roughly 20% in our laboratory) since reaching its zenith (at about 30%) from 1992 to 1994, largely because stenting generally provides a simpler, easier, and often less costly option. But atherectomy continues to be used for indications that are unfavora-

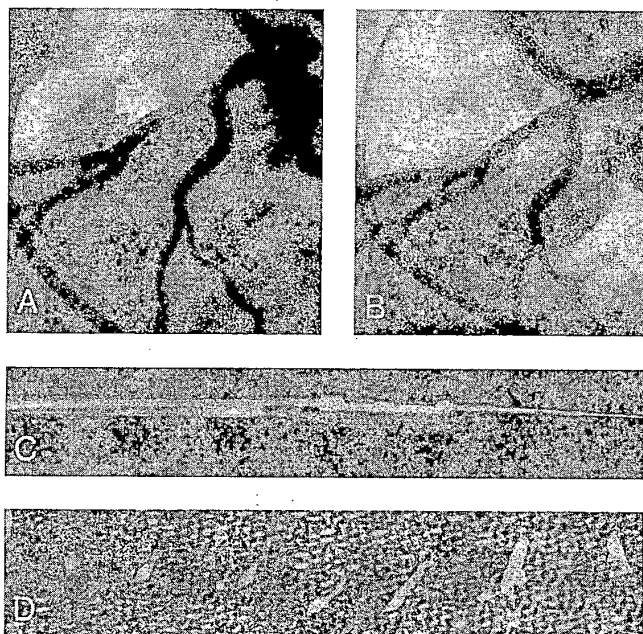
ble for stenting, or where atherectomy before stenting improves results. It is therefore important to understand the techniques available and how to match available devices to patient and lesion characteristics, so as to optimize the final posttreatment lumen diameter and procedural safety. Given the wide variety of devices and associated mechanisms, the design, technique, results, and applications of each will be reviewed separately.

### DIRECTIONAL CORONARY ATHERECTOMY

#### Device Description

The directional coronary atherectomy (DCA) catheter, also called the Simpson AtheroCath (Guidant, Santa Clara, CA), was first used in human peripheral vessels in 1985 (1) and in coronary arteries in 1986 (7). The coronary device was approved in 1990, following a large multicenter experience (8). Despite several minor improvements, the basic concept remains intact—a windowed steel housing is pressed up against the lesion by a low-pressure positioning balloon. Any plaque that protrudes into the window is then shaved from the lesion and trapped in the device nose cone by a spinning cup-shaped cutter that is advanced across the window opening. The coronary device tracks over a 0.014-inch guidewire (Fig. 24.1), and wire braid allows the

\* Drs. Robert D. Safian and John Bittl were contributors to this chapter in the previous editions.



**FIG. 24.1.** Directional coronary atherectomy. Left coronary angiography (lateral view) reveals a long eccentric stenosis in the mid-left anterior descending (LAD) artery (A). After atherectomy, the lumen is smooth, and there is no significant residual stenosis or dissection (B). A 7F AtheroCath was employed (C), and several pieces of atheroma were retrieved (D).

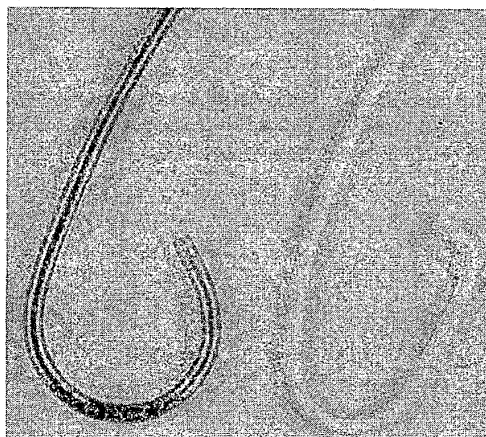
shaft to be rotated to reduce friction as the device is advanced across the lesion and to allow precise rotational orientation of the cutting window. During cuts, a separate battery-powered motor drive unit spins the cup-shaped cutter at approximately 2,500 rpm, as it is advanced manually by a small lever on the motor drive unit.

Three different sizes of housing are available for coronary use, with diameters of 5F, 6F, and 7F (1.7, 2.0, and 2.3 mm, respectively). A 7F-graft device with a larger-diameter positioning balloon is also available. A newer design (Flexi-Cut) now in clinical trials uses a single 6F housing with a wider (160° versus 120° window opening), and different size positioning balloons to achieve different effective working diameters.

#### Directional Atherectomy Procedure

The large size of the device requires special 9.5F and 10F guiding catheters, which are constructed with gentle curves rather than sharp angles to facilitate passage of the rigid housing (Fig. 24.2). Some large-lumen 9F catheters are capable of delivering the 6F and 7F devices, and a new flexi-cut design promises 8F guiding catheter compatibility. The size of the atherectomy

device is determined by the size of the normal vessel adjacent to the stenosis (the reference segment). The 6F device is generally used when the reference diameter is less than 3 mm, and the 7F device, when the reference diameter is between 3 and 4 mm or when a residual stenosis



**FIG. 24.2.** Guiding catheters for directional coronary atherectomy (devices for vascular intervention) are constructed with gentle curves rather than sharp angles. **Left:** The 11F JCL 3.5 guiding catheter for coronary atherectomy. **Right:** The 9F JCL 4 guiding catheter for conventional PTCA.

remains despite use of the 6F device with balloon inflation pressures up to 40 psi. The 7F graft device uses a larger-diameter positioning balloon on the 7F housing to treat vessels of more than 4 mm. A smaller, 5F device may be used rarely (e.g., subtotal lesions in calcified or moderately tortuous vessels) to partially debulk the plaque and thereby facilitate passage of a larger (definitive) device. Predilation with a small (e.g., 2-mm) conventional balloon also may be used to facilitate passage of the Athero-Cath, but larger predilating balloons should not be used to avoid causing dissections or making recovery of tissue more difficult during subsequent atherectomy cuts.

After flushing the central lumen and filling the balloon lumen with dilute contrast material, the device is passed into the guiding catheter over an exchange-length guidewire that has been positioned well across the target lesion through a large-bore rotating hemostatic valve. To advance the device across the target lesion, the device is gently advanced until its nose cone passes into the proximal portion of the vessel. Gentle withdrawal or rotation of the guiding catheter helps align the device with the long axis of the vessel, and gentle forward pressure is applied during continuous rotation of the atherectomy catheter. If the device does not pass easily, attempts to force it into the lesion or around curves in the vessel should be avoided, since forceful advancement of the rigid housing through a stiff, calcified, tortuous vessel could traumatize the vessel wall. Likewise, deep seating the guiding catheter (a common maneuver in PTCA) should be avoided during atherectomy, since the stiff guiding catheter itself may cause injury to the coronary ostium or proximal vessel.

Once the device is in position at the target lesion, a fluoroscopic projection is utilized that maximizes visualization of the target lesion and its eccentricity. In that projection, the device is rotated until the cutting window is seen to point toward the greatest plaque burden. The cutter is withdrawn to the proximal end of the window, and the positioning balloon is inflated to 10 to 20 psi. The motor is activated, and the cutter is advanced slowly (>5 seconds) across the window. After each cut, the balloon is deflated as

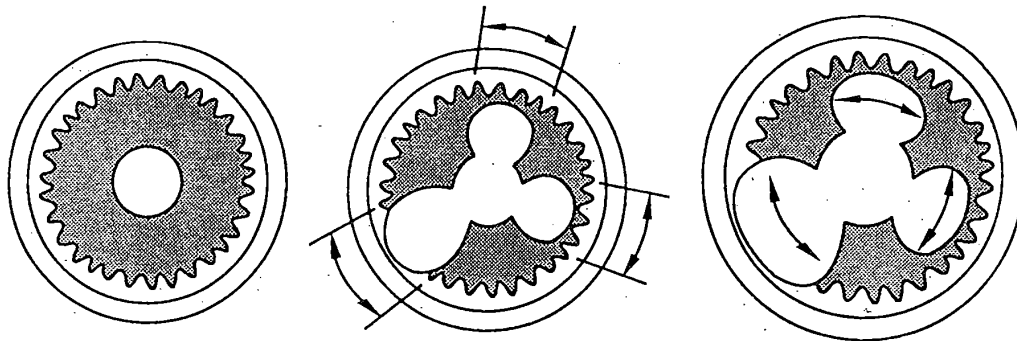
the device is rotated by 45° to 90° to reorient it toward additional plaque burden. To prevent embolization of plaque, the balloon is inflated to 10 psi during cutter withdrawal prior to making the next cut. Higher balloon inflation pressures (30 to 40 psi) may be used on subsequent cuts to retrieve remaining plaque, but cuts oriented toward nondiseased walls should be avoided to minimize the risk of vessel perforation. After four to six cuts, or if incomplete cutter advancement indicates that the nose cone collecting chamber is full, the device should be removed and emptied before additional cuts are made.

The number of passes and the final size of the device are determined based on the size of the reference segment and the presence of any angiographic residual stenosis. Intravascular ultrasound (Chapter 19) may be helpful in assessing the lumen diameter as well as the amount and location of residual plaque burden. Atherectomy is considered successful if there is tissue removal; a residual stenosis is less than 50% after atherectomy, and there are no major complications (death, Q-wave myocardial infarction [MI], or emergency coronary bypass surgery).

#### Mechanisms of Lumen Enlargement

Directional atherectomy was designed to excise atherosclerotic plaque (2). While lumen enlargement is predicated on plaque removal, the acute result is actually due to a combination of plaque removal and dilation. Early data showed that the amount of plaque removed (averaging 18.5 mg) accounts for less than half the observed gain in volume seen at the lesion site (9,10), with the rest resulting from "facilitated angioplasty" (Fig. 24.3). Even after a successful atherectomy that has normalized the angiographic vessel lumen relative to that of the adjacent reference segments, a substantial amount of plaque (40% to 50% of the outer vessel [external elastic lamina, or EEL] cross-sectional area) remains, reflecting the substantial Glagov remodeling that typically has taken place at the lesion site (11).

Since atherectomy improves the radial compliance of the diseased and stiff coronary segment and since the mechanism of lumen enlargement is due in part to dilation, it stands to reason



**FIG. 24.3.** Schematic representation of mechanism of directional coronary atherectomy and the concept of "facilitated angioplasty." **Left:** Concentric stenosis in a coronary artery. The shaded area represents intimal plaque contained within the internal elastic lamina (*wavy line*). **Center:** Excision of plaque and media at 8 o'clock results in thinning of the vessel wall; subsequent cuts at 1 and 4 o'clock do not penetrate the media. **Right:** With disruption of the internal elastic lamina, radial compliance increases so that subsequent balloon inflations cause focal stretching of the vessel wall within the channels produced by previous atherectomy cuts ("facilitated angioplasty"). The resulting lumen appears smooth and free of residual stenosis in any angiographic projection, despite only partial atherectomy with the continued presence of residual intimal plaque.

that postatherectomy balloon angioplasty should impart additional volume expansion. Although early studies considered such an application of balloon angioplasty after successful atherectomy to be tantamount to a "crossover," current "optimal" atherectomy practice makes routine use of low-pressure postdilation to further enlarge the treated lumen (12–14).

### Procedural Results

There has been considerable experience with directional coronary atherectomy (with the Simpson AtheroCath), with more than 200,000

procedures performed worldwide. Published experience includes single-center reports (15,16) and results from two multicenter registries (8,17), five multicenter randomized trials (Tables 24.1 through 24.4) (13,14,18–20). Device success rate (defined as achievement of more than 20% gain and less than 50% residual stenosis with tissue removal) is greater than 95%, with overall procedural success (defined as less than 50% residual stenosis, with adjunctive postatherectomy balloon angioplasty or other device) greater than 98%. Major complications are generally quite similar to balloon angioplasty except for the higher incidence of perforation (approx-

**TABLE 24.1.** Clinical studies and trials with directional atherectomy (see text)

|                             | Lesion (n) | Device success (%) | Residual stenosis (%) |
|-----------------------------|------------|--------------------|-----------------------|
| Beth Israel Hospital (15)   | 225        | 98                 | 7                     |
| Sequoia Hospital (16)       | 447        | 94                 | 12                    |
| NACI (17)                   | 1084       | 94                 | 13                    |
| WHC (10)                    | 306        | 95                 | 14                    |
| Multicenter preapproval (8) | 1032       | 92                 | N/A                   |
| CAVEAT I (18)               | 512        | N/A                | 29                    |
| CCAT (19)                   | 138        | 94                 | 26                    |
| OARS (13)                   | 216        | 98                 | 7                     |
| BOAT (14)                   | 989        | 99                 | 15                    |
| ABACAS (20)                 | 210        | 99                 | 13                    |

TABLE 24.2. Complications of directional atherectomy

|                      | Major     |          |          | Other        |                 |
|----------------------|-----------|----------|----------|--------------|-----------------|
|                      | Death (%) | CABG (%) | Q MI (%) | Non-Q MI (%) | Perforation (%) |
| Beth Israel Hospital | 0         | 0.5      | 0        | 7.4          | 0.5             |
| Sequoia Hospital     | 0.2       | 3.0      | 0.8      | N/A          | 1.3             |
| NACI                 | 0.6       | 1.6      | 1.0      | 4.8          | N/A             |
| WHC                  | 0.7       | 2.0      | 0.3      | 9.8          | N/A             |
| DCA investigators    | 0.5       | 4.0      | 0.9      | 5            | 0.6             |
| CAVEAT I             | 0         | 3        | 2        | 19           | 0.4             |
| CCAT                 | 0         | 1.4      | 0.7      | 3.6          | N/A             |
| OARS                 | 0         | 1.0      | 1.5      | 14           | 1.0             |
| BOAT                 | 0         | 1.0      | 2.0      | 16           | 1.4             |
| ABACAS               | 0         | 0        | 0.5      | 0.9          | 0.5             |

mately 1%) and CK elevation greater than three times normal (approximately 15%). The importance of the high incidence of clinically silent elevations in creatine kinase myocardial band (CK-MB) enzymes following directional atherectomy remains unsettled and controversial, but in the Balloon versus Optimal Atherectomy Trial (BOAT) (14) there was no association with deaths at 1 or 3 years and there tended to be more late deaths by 1 year in the balloon angioplasty arm compared with the DCA arm (eight deaths vs. three deaths,  $p = .14$ ).

The main differences among trials concern the residual stenosis and the subsequent rate of angiographic restenosis. For the two early (1990 to 1991) randomized trials, high (>25%) residual stenoses (29% for CAVEAT I and 26% for CCAT) (18,19) reflected cautious tissue removal and the discouragement of adjunctive balloon postdilatation. In contrast, more recent experi-

ences utilizing the optimal atherectomy technique have used more aggressive tissue removal and routine (> 75% of cases) adjunctive postdilatation angioplasty to obtain much lower residual stenoses (<15%). The benefit of this approach in lowering restenosis compared with stand-alone balloon angioplasty has been confirmed in the OARS (13), BOAT (14), and ABACAS (20) studies with angiographic restenosis rates of 21% to 31%, compared with the 46% to 50% restenosis rates in the earlier trials. In BOAT, the lower residual stenosis for DCA versus PTCA (14% vs. 28%) led to significantly lower angiographic restenosis rates (31% vs. 40%).

The mechanism of late lumen narrowing has been carefully evaluated for directional atherectomy using intravascular ultrasound (IVUS). Analysis of the OARS multicenter registry IVUS substudy (11) and the Serial Ultrasound Restenosis (SURE) trial (21) demonstrated that lumen renarrowing following directional atherectomy occurs between 1 and 6 months after the procedure and is due primarily to shrinkage (negative remodeling) of the external elastic membrane as well as some neointimal hyperplasia. The results of the OARS intravascular substudy are summarized in Table 24.4.

#### Tissue Analysis and Consequences of Deep-Wall Resection

Atherectomy provides a unique opportunity for studying the pathophysiology of atherosclerosis and coronary restenosis in human coronary

TABLE 24.3. Angiographic and clinical restenosis after directional atherectomy

|                      | Angiographic restenosis | Clinical restenosis |
|----------------------|-------------------------|---------------------|
| Beth Israel Hospital | 32%                     | 26%                 |
| Sequoia Hospital     | 30%*                    | N/A                 |
| WHC                  | N/A                     | 28%                 |
| CAVEAT I             | 50%                     | 37%                 |
| CCAT                 | 46%                     | 28%                 |
| OARS                 | 29%                     | 21%                 |
| BOAT                 | 31%                     | 25%                 |
| ABACAS               | 21%                     | 17%                 |

\* De novo native coronary lesions or one previous treatment.

TABLE 24.4. IVUS analysis of acute and late results of directional atherectomy (OARS)

| Variable                               | Before intervention | After intervention | Follow-up   |
|--|---------------------|--------------------|-------------|
| <b>QCA</b>                             |                     |                    |             |
| Reference diameter (mm)                | 3.39 ± 0.47         | 3.51 ± 0.46        | 3.22 ± 0.44 |
| MLD (mm)                               | 1.21 ± 0.39         | 3.22 ± 0.47        | 2.03 ± 0.72 |
| DS (%)                                 | 64 ± 10             | 8 ± 10             | 38 ± 20     |
| <b>IVUS</b>                            |                     |                    |             |
| Reference EEM CSA (mm <sup>2</sup> )   | 18.3 ± 7.5          | 19.1 ± 7.7         | 17.6 ± 8.0  |
| Reference lumen CSA (mm <sup>2</sup> ) | 10.2 ± 3.9          | 10.8 ± 3.9         | 9.5 ± 4.6   |
| Reference P + M CSA (mm <sup>2</sup> ) | 8.1 ± 4.4           | 8.4 ± 4.6          | 8.1 ± 4.3   |
| Lesion EEM CSA (mm <sup>2</sup> )      | 17.7 ± 5.7          | 19.7 ± 5.6         | 16.9 ± 6.2  |
| Lesion lumen CSA (mm <sup>2</sup> )    | 2.0 ± 1.3           | 8.8 ± 2.5          | 5.5 ± 4.0   |
| Lesion P + M CSA (mm <sup>2</sup> )    | 15.6 ± 5.3          | 10.9 ± 4.2         | 11.3 ± 3.9  |

IVUS, Intravascular ultrasound; QCA, quantitative coronary angioplasty.

arteries (22). Standard light microscopy demonstrates that atherosclerotic plaque (97%), media (66%), adventitia (30%), and thrombus (43%) are commonly recovered. Remarkably, retrieval of deep-wall components seems to be well tolerated acutely, and at 6 months, angiographic follow-up (23,24) shows no relationship between deep-wall resection and restenosis, although the risk of late aneurysm formation may be increased (25,26).

Histologic analysis of DCA specimens shows intimal hyperplasia in 93% of restenotic lesions, with proliferating-phenotype smooth muscle cells interspersed with ground substance. Surprisingly, however, 44% of primary (*de novo*) lesions have intimal hyperplasia that is histologically indistinguishable from intimal hyperplasia seen in lesions with prior restenosis (27).

### Use in Specific Lesion Types

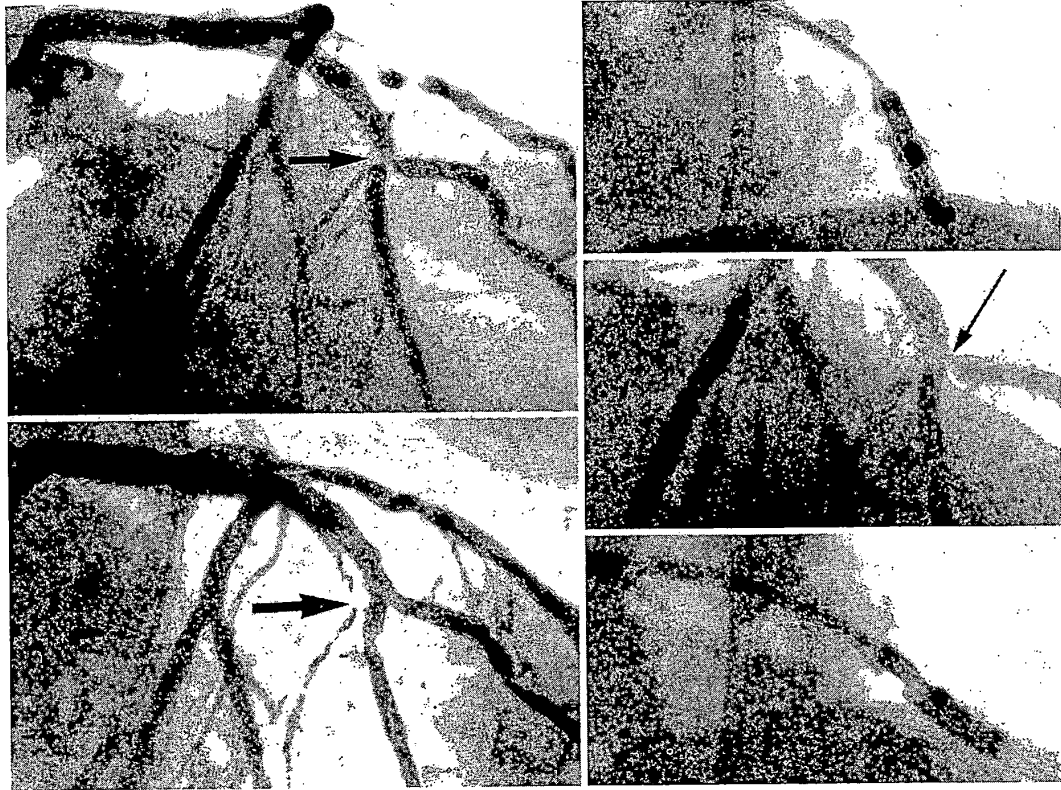
#### *Bifurcation Lesions*

Plaque obstruction in large epicardial coronary arteries that involves the origin of a large branch, such as the left anterior descending/diagonal branch bifurcation, presents a special problem to the interventionist. The treatment of such true bifurcation lesions using conventional balloon angioplasty techniques is limited due to plaque shifting that occurs between the parent vessel and the ostium of the branch vessel

(Chapter 23). In contrast, directional atherectomy provides superior treatment of bifurcation lesions, since the mechanism of lumen enlargement includes excision of the tissue that might otherwise be displaced into the branch ostium (28–30). The preferred technique involves sequential atherectomy of the main vessel and its branch, if the branch is large enough to accommodate the device (Fig. 24.4).

The acute and long-term results of directional atherectomy for the treatment of true bifurcation lesions were compared with balloon angioplasty by Dauerman (31). The atherectomy group had lower acute residual diameter stenosis and lower target vessel revascularization rate (28% for atherectomy vs. 53% for balloon angioplasty.  $P = .01$ ). DCA should only be performed in non-calcified bifurcation lesions where the main vessel and involved side branch are larger than 2.5 mm (otherwise, rotational atherectomy should be used). We first position the 0.014-inch guidewire into the distal parent vessel and perform initial cuts directed toward the ostium of the branch vessel in an effort to minimize “snowplow” branch compromise. Next, the guidewire is withdrawn and redirected into the branch vessel, where additional cuts are performed. Finally, kissing balloon inflation in the parent and branch vessel is performed, with stent placement reserved for situations in which there is excessive recoil or dissection.





**FIG. 24.4.** Bifurcation atherectomy. **Upper left:** "Mercedes Benz" lesion involving the bifurcation of the left anterior descending (LAD) and diagonal branch (*arrow*). **Upper right:** Directional atherectomy of LAD, leaving tight stenosis of the diagonal origin (*right center, arrow*). **Lower right:** Atherectomy of the diagonal origin leaves excellent result (*lower left*). (From Friedman HZ, et al. Mechanical rotary atherectomy: the effects of microparticle embolization on myocardial blood flow and function. *J Interv Card* 1989;2:77, with permission.)

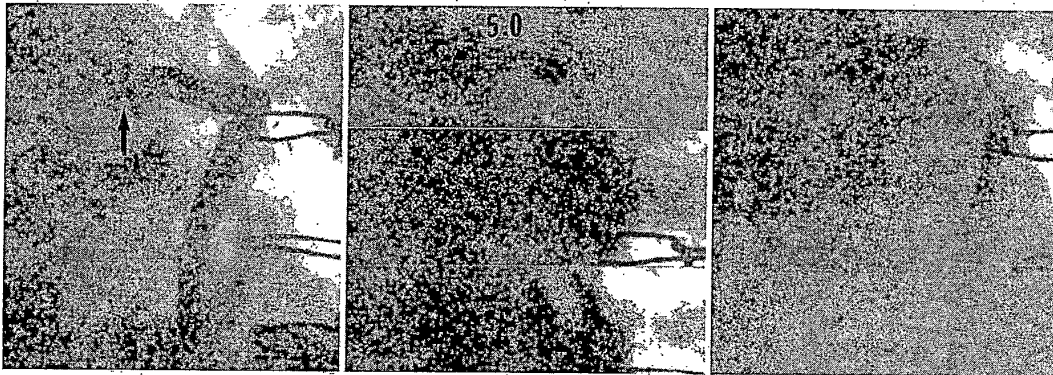
#### *Aortoostial Stenoses*

The ostium of the right coronary artery or saphenous vein graft is located within the thick-walled aorta, where substantial elastic recoil makes the use of stand-alone balloon angioplasty problematic (see Chapter 23). Such recoil has been overcome by tissue excision using directional atherectomy (Fig. 24.5) (32,33). This requires delivery of the device coaxially with the proximal portion of the target vessel. The guiding catheter must be disengaged before performing atherectomy cuts (to avoid cutting the tip of the guiding catheter itself). This requires use of bony landmarks for positioning the device at the ostium, since the disengaged guide can no

longer provide adequate contrast angiography. Generally, postatherectomy balloon angioplasty or stent placement may be used to further "up-size" the lumen result beyond the working diameter of the AtheroCath. The presence of intracoronary calcium, especially at the lumen surface, is a relative contraindication for directional atherectomy of ostial stenoses, and such lesions are more suited for rotational atherectomy (see later discussion).

#### *Salvage Atherectomy*

Directional coronary atherectomy can be used successfully to rescue failed or suboptimal bal-



**FIG. 24.5.** Aortoostial saphenous vein graft atherectomy. **Left panel:** Ostial stenosis of saphenous vein graft (*arrow*) represents stenosis within the wall of the aorta, based on its location between the aortic lumen and the ring marker. This was refractory to dilatation with a 5-mm balloon (*center, top*) but responded to directional atherectomy (*center, bottom*) with favorable results (**right panel**). Such lesions are currently treated with stent placement (see Chapter 25).

loon angioplasty (34,35), particularly when plaque recoil results in plaque avulsion into the intraluminal space. This application has become quite rare with the widespread use of stent placement to stabilize abrupt or threatened closure after balloon angioplasty and should not be attempted when there are deep spiral dissections in which attempted resection may result in perforation.

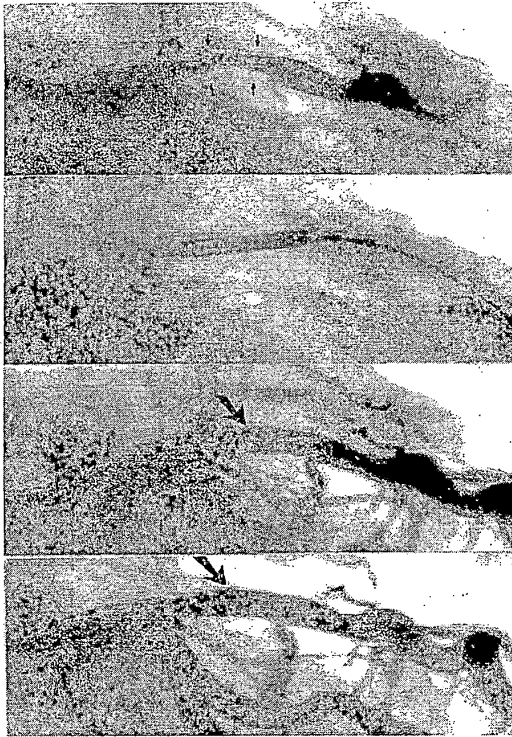
#### ***In-Stent Restenosis***

Although coronary stenting has been proven to reduce the incidence of restenosis compared with balloon angioplasty, the high recurrence rate (50% to 80%) of treating diffuse restenosis within stent in-stent restenosis has become evident. Debulking techniques using laser, rotational atherectomy, or DCA have been shown in case-matched series to cut this recurrence rate roughly in half (36–38), although further substantial reductions in recurrence have now been seen with beta or gamma radiation of the in-stent restenosis (39). Directional atherectomy, which offers potentially the highest debulking capacity of the atherectomy and atheroablative devices, has been shown to be safe and effective in achieving less than 20% residual in-stent diameter stenoses and subsequent clinical restenosis

rates of less than 30% (Fig. 24.6). In some atherectomy procedures for in-stent restenosis, the tissue sample may include a small section of stent strut, although without apparent clinical consequence.

#### **Debulking Before Coronary Stenting**

The concept of stand-alone “optimal” atherectomy was validated in the OARS, BOAT, and ABACAS studies (13,14,20). Recent studies have suggested that performing directional atherectomy before stenting may improve long-term stent results. In the Stenting after Optimal Lesion Debulking (SOLD) study (40), 71 patients underwent directional atherectomy of coronary lesions before stenting, achieving an angiographic restenosis rate of 11%. Interestingly, this was due both to a slightly larger acute result reduction and to a reduced late loss index (33% vs. the more typical 50%) compared with stenting alone. A similar experience has been reported by Kiesz and coworkers (the ADAPTS study), in which 89 lesions in 60 patients were treated with a combination of DCA debulking followed by stenting (41). Two more definitive randomized trials, AMIGO and DESIRE, are currently under way to test the hypothesis that directional coronary atherectomy before stent-



**FIG. 24.6.** Directional atherectomy of in-stent restenosis. **Top:** Restenosis within stent in the mid-left anterior descending artery (arrows denote stent struts). **Upper center:** Directional atherectomy catheter positioned within stent. **Lower center:** Enlarged lumen following atherectomy (arrow). **Bottom:** Final result after balloon dilatation.

ing may result in a lower restenosis rate than stenting alone.

## TRANSLUMINAL EXTRACTION CORONARY ATHERECTOMY

### Device Description

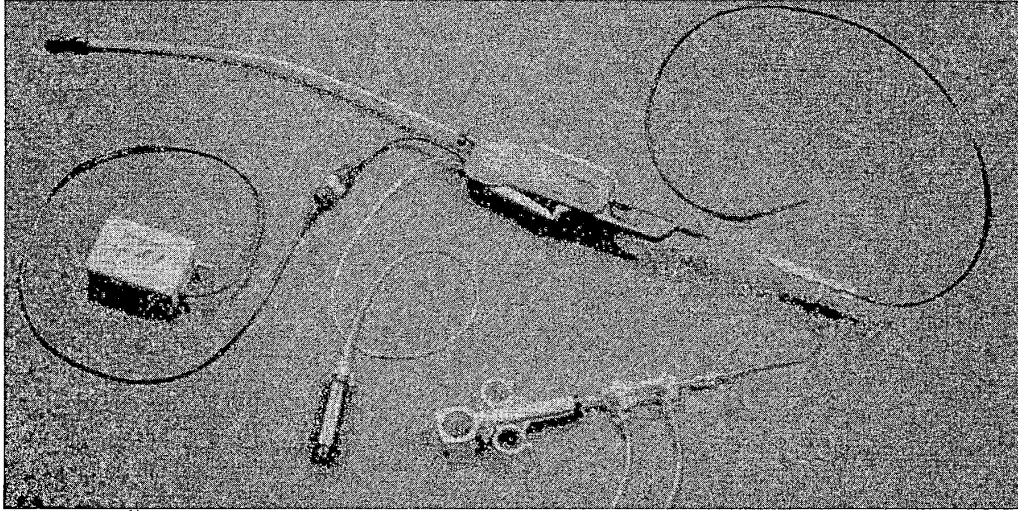
The transluminal extraction catheter (TEC) (Interventional Technologies, Inc., San Diego, CA) uses a tip-mounted cutting blade and an external vacuum source to macerate and aspirate thrombus and soft plaque material (Figs. 24.7 and 24.8). A trigger on the handle of the motor drive unit activates shaft and blade rotation at 750 rpm, and a sliding lever on top of the motor drive unit permits advancement or retraction of

the cutter over the 300-cm-long 0.014-inch guidewire. Warm, heparinized lactated Ringer's solution is infused during atherectomy passes to produce a thin slurry of blood and tissue that is then continuously aspirated into the external suction bottle during cutter activation.

### TEC Atherectomy Procedure

Device selection remains empirical, with the largest cutter being 1 to 1.5 mm smaller than the normal vessel diameter. For coronary use, TEC cutters range from 5.5F (1.8 mm), 6F (2 mm), 6.5F (2.15 mm), and 7F (2.3 mm) to 7.5F (2.5 mm). The larger cutters (7F or 7.5F) should be reserved for vessels greater than 3.5 mm in diameter or for lesions associated with large amounts of thrombus. Special 10F tungsten-braided soft-tip guiding catheters are recommended for all TEC atherectomy procedures, but a 9F guiding catheter can be used for TEC cutters of 6.5F or less. Guiding catheters with an inner diameter of more than 0.105 inch are required for 7F or 7.5F cutters.

After engaging the vessel ostium with the guiding catheter, the target lesion should be crossed with the special TEC guidewire using a bare-wire technique. The floppy tip of the guidewire should be positioned in the distal vessel so the stiff shaft of the wire is across the lesion. If difficulty is anticipated crossing the lesion, a conventional wire may be used first and then exchanged for the TEC wire using a transport catheter that will accommodate the 0.021-inch ball at the tip of the special TEC guidewire. Once the guidewire is in proper position, the TEC cutter should be advanced up to the lesion, and the infusion of warmed lactated Ringer's is begun through the guiding catheter. The operator then depresses the trigger to activate cutter rotation and slowly advances the lever to traverse the entire lesion. Two to five passes should be made slowly through the lesion (15 to 30 seconds per 10-mm segment) until there is no further resistance to cutter advancement. After retracting the cutter into the guiding catheter, repeat angiography should be performed to determine the need for a larger device or adjunctive angioplasty.



**FIG. 24.7.** Components of the transluminal extraction catheter (TEC), including the cutter, motor drive unit, battery pack, and vacuum bottle. (Reproduced with permission from Interventional Technologies, Inc., and Physician's Press.)


#### Mechanism of Action

TEC atherectomy theoretically enlarges the lumen by cutting, aspirating, and removing thrombus, plaque, and other debris. In contrast to the discrete tissue fragments commonly retrieved by directional atherectomy, TEC results in a slurry of blood and debris that does not lend itself easily to tissue analysis. In angioscopic studies of saphenous vein grafts, TEC resulted in partial or complete removal of fresh thrombus in more than 75% of lesions in which thrombus was identified (42,43) but was less effective in removing laminated thrombus. Other an-

gioscopic findings included the frequent development of intimal flaps and dissection. By intravascular ultrasound, plaque fissures and residual plaque were identified in 100% of lesions after TEC, and intimal dissections were identified in 36% of lesions (44). Others have suggested that most of the improvement results from mechanical dilatation rather than removal of plaque or thrombus (45).

#### Results

The treatment of saphenous vein grafts with luminal irregularities or the presence of frank



**FIG. 24.8.** Close-up view of the conical cutting head and stainless steel blades of the transluminal extraction catheter (TEC) and special 0.014-inch TEC guidewire. (Reproduced with permission from Interventional Technologies, Inc., and Physician's Press.)

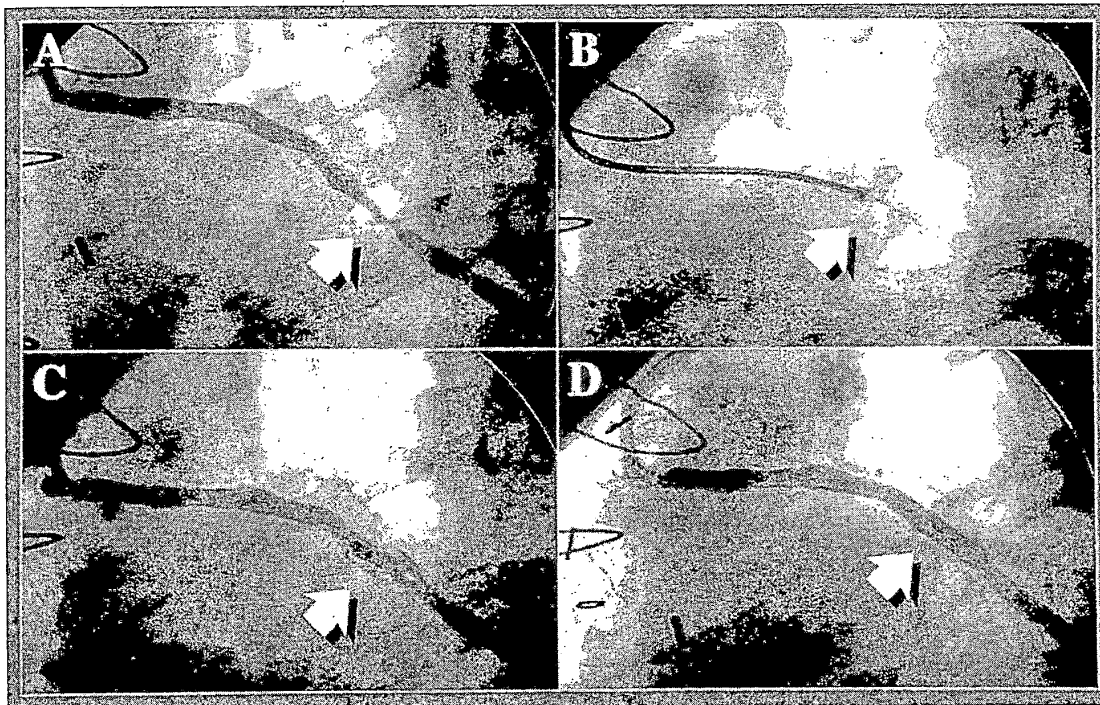


FIG. 24.9. Bypass graft angiography (left anterior oblique [LAO] projection) and angioscopy before and after TEC atherectomy. **A:** Angiography of a vein graft to the obtuse marginal branch reveals a tubular stenosis in the midbody of the graft. There is no definite thrombus by angiography. **B:** TEC atherectomy is performed with a 6.5F cutter. **C:** Angiography immediately after TEC reveals a complex residual stenosis with dissection and/or thrombus. **D:** A single Palmaz-Schatz P204 biliary stent is inserted and further dilated to 14 atm. After adjunctive angioplasty, there is no residual stenosis, dissection, or filling defect.

thrombus is unfavorable for any coronary device, because of high rates of distal embolization, no reflow, and recurrent ischemia and restenosis, but may be suited for the TEC device with its potential to cut and aspirate thrombus and “grummosus” material (Fig. 24.9) (Table 24.5).

The overall procedure success rate ranges from 80% to 90% (3,46,47; Table 28.4), but modest quantitative angiographic improvement in lumen diameter immediately after TEC required adjunctive balloon angioplasty in approximately 90% of cases (48). Although lesions containing

TABLE 24.5. Angiographic results and major clinical complications after TEC atherectomy

| Author (Ref.)       | Vessel | n   | PTCA (%) | Success (%) | Death (%) | CABG (%) | QMI (%) |
|---------------------|--------|-----|----------|-------------|-----------|----------|---------|
| Popma (44)          | SVG, N | 51  | 86       | 82          | 5.9       | 3.9      | 7.8     |
| Safian <sup>a</sup> | SVG    | 158 | 91       | 84          | 2.0       | 0.7      | 2.0     |
| Twidale (46)        | SVG    | 88  | 95       | 86          | 0         | 1.5      | 4.4     |
| NACI (57)           | SVG, N | 240 | 89       | 80          | 5.7       | 0.9      | 1.4     |
| Safian (51)         | N      | 181 | 84       | 84          | 2.3       | 3.4      | 2.8     |

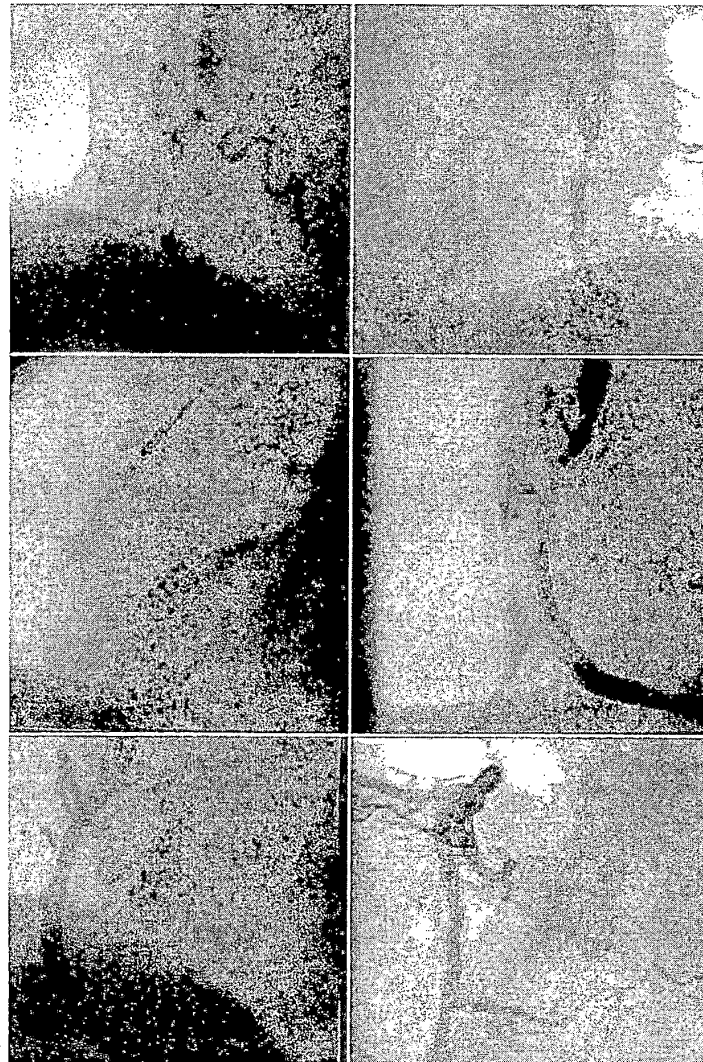
Abbreviations: n = number of lesions; PTCA = adjunctive balloon angioplasty; success = final diameter stenosis <50% in the absence of death, emergency bypass surgery (CABG), or Q-wave myocardial infarction (QMI); SVG = saphenous vein bypass graft, N = native coronary artery.

<sup>a</sup> Safian RD, et al. Clinical and angiographic results of transluminal extraction coronary atherectomy in sphenous vein bypass grafts. *Circulation* 1994;89:302.

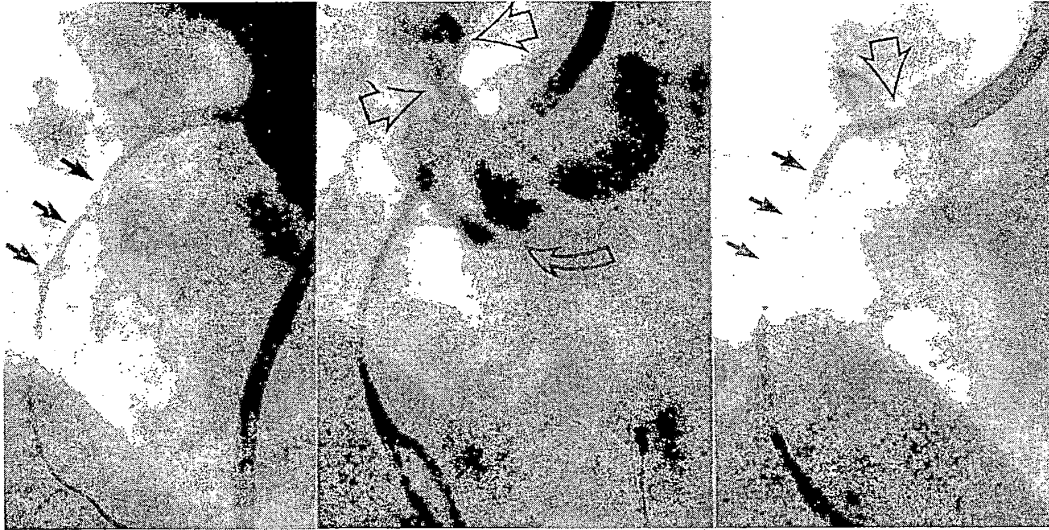
thrombus have been shown to be associated with lower procedure success for the TEC device than that achieved in lesions without thrombus (49), TEC atherectomy before stenting may be better than conventional balloon or stent treatment alone for thrombotic lesions (50).

The incidence of death (0 to 5.9%), emergency bypass surgery (0.7% to 3.9%), and MI (2% to 7.8%), however, is generally similar to

the incidence of death (0 to 5%), emergency bypass surgery (0 to 3%), and MI (0 to 9%) for patients with vein graft lesions treated by conventional angioplasty (3,17,44,46). Angiographic follow-up confirmed the high incidence of restenosis, with 52% to 69% of lesions having a follow-up diameter stenosis of more than 50% (44,46), and late vessel total occlusion in 29% of lesions.



**FIG. 24.10.** TEC atherectomy of the native right coronary artery (RCA). Baseline angiography (**top left**, LAO projection; **top right**, right anterior oblique [RAO] projection) reveals a severe stenosis with intraluminal haziness in the mid-RCA. TEC atherectomy is performed with a 7F cutter (**middle left**), resulting in significant luminal improvement and a moderate residual stenosis (**middle right**). After adjunctive angioplasty (**bottom left**, LAO projection; **bottom right**, RAO projection), there is trivial residual stenosis.



**FIG. 24.11.** Perforation of the right coronary artery (RCA, LAO projection) after TEC atherectomy. Baseline angiography reveals a long stenosis in the proximal RCA (**left panel, black arrows**). After TEC atherectomy with a 7F cutter, there is a jet of free contrast extravasation into the pericardium (**middle panel, open arrowheads**) and deep periadventitial contrast staining (**middle panel, open arrow**). After prolonged inflation with a perfusion balloon and pericardiocentesis, there is no residual contrast extravasation (**right panel, open arrowhead**), although there is a mild residual stenosis at the site of the original lesion (**right panel, black arrows**).

In native coronaries, the TEC device has a procedure success rate that ranges from 85% to 95%, with adjunctive angioplasty required in approximately 80% (Table 24.5) (51). The final incidence of major in-hospital complications was death in 2.3%, emergency bypass surgery in 2.8%, and Q-wave MI in 3.4%, which was somewhat higher than the incidence of major complications for comparable lesions treated with balloon angioplasty. Other TEC-induced angiographic complications included side-branch occlusion in 2.7%, distal embolization in 0.5%, guiding catheter dissection in 2.2%, coronary artery perforation in 2.2% of lesions (Figs. 24.10 and 24.11).

Since TEC atherectomy has not been shown to consistently remove plaque, the immediate angiographic results of TEC atherectomy in native coronary arteries do not appear to be superior to balloon angioplasty, and most lesions were treated with adjunctive angioplasty after TEC, the value of TEC in native coronary arteries remains uncertain. Procedural costs for TEC are also significantly higher than those for con-

ventional angioplasty of similar lesions (52). One exception may be the use of TEC to remove thrombus in the setting of acute MI, especially where large thrombus burdens are present (53,54).

### Randomized Trials

#### *Thrombus-Containing Lesions Trial*

The TEC or PTCA in Thrombus-Containing Lesions (TOPIT) Trial was a 245-patient multicenter randomized trial comparing TEC plus optional balloon angioplasty with balloon angioplasty for patients with either a clinical likelihood for coronary thrombus (unstable angina or postinfarction angina) or angiographically apparent thrombus (55). The procedure success rate was 97% for both groups, owing to the frequent (35%) rate of stent use to repair dissections. The primary end point—a composite rate of in-hospital major adverse cardiac events (death, MI, bailout intervention, or emergent surgery)—was noted in 11.2% of pa-

tients randomized to balloon angioplasty versus 4.5% for those randomized to TEC ( $p = .06$ ). A secondary end point of CK-MB isoenzyme peak elevation greater than three times normal was observed more frequently in the balloon angioplasty group (15.4% vs. 4.5%,  $p = .03$ ).

#### ***Transluminal Extraction Coronary . . . (TECBEST)***

The Transluminal Extraction Coronary (TECBEST) trial examined the potential role of TEC compared with balloon predilation before stenting in saphenous vein grafts (56). There was no improvement in acute angiographic results by TEC pretreatment, and the incidence of distal embolization and periprocedural MI was not reduced.

#### **Contraindications and Limitations of TEC**


TEC is contraindicated for the treatment of dissection caused by other devices and should not be used in cases of extreme angulation or calcification and where vessels are less than 2.5

mm in diameter. The theoretical benefits of TEC atherectomy suggest that its benefit is generally limited to thrombus-containing vein grafts. Published data disclose inadequate lumen enlargement as a "stand-alone" device, a high incidence of serious angiographic complications, frequent need for adjunctive angioplasty, high procedural cost, and high incidence of clinical and angiographic restenosis (57). Even in the cases of large thrombi, the use of newer thrombectomy devices (see later discussion) may offer safer and more efficient thrombus removal.

#### **HIGH-SPEED MECHANICAL ROTATIONAL ATHERECTOMY (ROTABLATOR)**

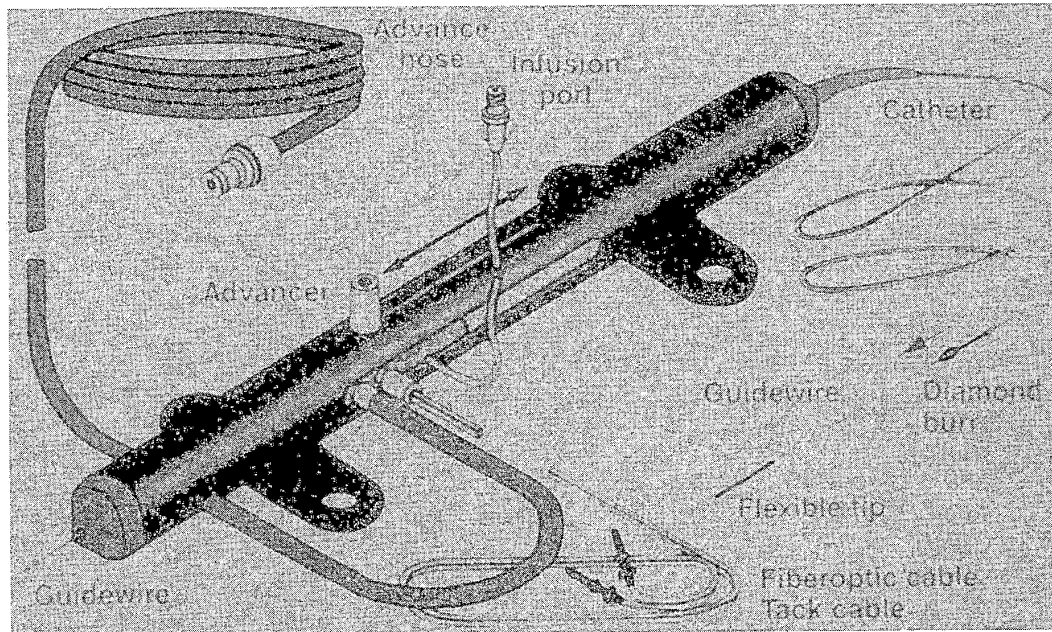
##### **Device Description**

The high-speed mechanical rotational atherectomy device, or Rotablator (Boston Scientific, Boston, MA) (4,5,58), consists of an olive-shaped stainless steel or brass burr whose surface is embedded with diamond chips measuring 30 to 120  $\mu$ m in diameter (Fig. 24.12). The burr is attached to a hollow, flexible drive shaft that



**FIG. 24.12.** Close-up view of the Rotablator burr embedded with diamond chips and special 0.009-inch guidewire. (Reproduced with permission from Heart Technology, Inc., and Physician's Press.)





**FIG. 24.13.** Schematic overview of the original Rotablator assembly. (Reproduced with permission from Boston Scientific, and Physician's Press.) In the current Rota-link design, the drive unit is separate and can be used with a series of different burr cables.

permits passage of a steerable, movable 0.009-inch guidewire with a 0.014-inch platinum coil at its tip. The drive shaft is encased within a Teflon sheath through which warm, heparinized Ringer's lactate solution is pumped into the sheath to lubricate and cool the drive shaft and burr. A compressed-air turbine rotates the drive shaft at 150,000 to 200,000 rpm (Fig. 24.13). Burrs for coronary use are available in diameters of 1.25, 1.5, 1.75, 2.0, 2.15, 2.25, and 2.5 mm (Table 24.6).

### Rotablator Atherectomy Procedure

As with conventional balloon angioplasty, all patients should be pretreated with aspirin at least 24 hours before the procedure, and intravenous heparin adequate to maintain the activated clotting time at approximately 300 seconds. Intracoronary nitroglycerin (100- to 200- $\mu$ g bolus), and intravenous nitroglycerin (20- to 100- $\mu$ g/min infusion) should be administered as tolerated. For patients with target lesions in the distribution of the right coronary artery, prophylactic temporary pacemaker insertion is recommended, frequently in the form of a right heart catheter that combines capabilities for pacing and monitoring pulmonary artery pressure. Conventional angioplasty guiding catheters may be used for Rotablator atherectomy as long as their lumen is at least 0.020 inch larger than the largest burr to be used (Table 24.6). Two guidewires are available, a floppy guidewire and an extra-support guidewire. The floppy wire has the advantage of minimizing guidewire bias—a phenomenon in which a stiff guidewire tends to

**TABLE 24.6.** Inner diameter of guiding catheters to accommodate rotablator burrs

| Rotablator Burr Size (mm) | Guiding Catheter ID |
|---------------------------|---------------------|
| 1.25                      | 0.059               |
| 1.50                      | 0.069               |
| 1.75                      | 0.078               |
| 2.0                       | 0.088               |
| 2.15                      | 0.092               |
| 2.25                      | 0.097               |
| 2.5                       | 0.107               |

Abbreviation: ID = inner diameter (in).

straighten out curved vessel segments and cause deep cuts or dissection as the burr is forced against the tautly stretched lesser curvature of the vessel. On the other hand, the floppy guidewire may fail to adequately control the travel of the burr around tight bends, leading to uncontrolled cutting on the greater curvature of the vessel. If difficulty is anticipated crossing the target lesion with the Rotablator guidewire using a bare-wire technique, the lesion may be crossed with a conventional angioplasty wire and exchanged for the Rotablator guidewire using a suitable transport catheter.

Once the guidewire is across the lesion, the burr should be advanced to within a few centimeters of the rotating hemostatic valve, with the lines for compressed air supply and tachometer readout attached to the drive console. The system should be tested by depressing the foot pedal adjusting the turbine to maintain burr speeds of 140,000 to 160,000 rpm. During the test, the operator should also confirm adequate flow of heparinized flush through the Teflon sheath, free motion of the advance lever, and a firm grip of the wire brake. Once this test has been completed, the burr can be advanced into and through the guiding catheter. Any resistance encountered as the burr is passed around the primary curve of the guiding catheter can be overcome by firm traction on the guidewire, but this is less common with the use of gentle ("Q") curves analogous to those used for DCA. The guiding catheter must be well seated in the vessel ostium while advancing the burr to prevent kinking of the guidewire in the aortic root. Once the burr has been advanced to 1 to 2 cm proximal to the target lesion, the advancer lever should be unlocked and pulled all the way back to its proximal limit so as to take up any slack in the drive shaft that might otherwise cause the burr to lurch forward into the lesion upon activation.

Under fluoroscopy, the burr is then activated by stepping on the pedal, and adjusted to the desired "platform" speed (160,000 rpm for smaller burrs and 140,000 rpm for burrs bigger than 2 mm) before engaging the lesion. Advancement of the lever then brings the spinning burr slowly into contact with the lesion. It is important to be aware of the sound of the turbine, the rotational speed display, and tactile feedback

during "rotablation," to avoid speed drops of more than 5,000 rpm during advancement. Greater speed drops caused by excessive pressure on the burr may result in the liberation of larger particles, frictional heating of the plaque, or torsional dissection. Brief (1- to 3-second) periods of plaque contact should be alternated with longer (3- to 5-second) periods of reperfusion provided by pulling the burr back from the plaque face, to aid in clearance of particulate debris through the distal circulation. After 15 to 30 seconds of operation, the device should be withdrawn into the proximal vessel and rotation should be suspended for a similar time before reactivating and advancing the burr again. This sequence should be repeated until the device can be advanced through the full length of the lesion without any fluoroscopic or tactile resistance to burr advancement and with no audible change in the pitch of the turbine or reduction in burr speed. If a second, larger burr is to be used, the initial burr is then removed during continuous rotation (decreased to 90,000 rpm, in the "dynaglide" mode).

The selection of burr sizes is largely empirical but should progress to a final burr/artery ratio of roughly 0.7 (e.g., 2.15-mm burr in a 3-mm vessel). In treating long segments of disease, heavily calcified lesions, and subtotal de novo lesions, it is generally a good idea to start with a smaller (1.5 or 1.75 mm) burr and step up to the final burr size in 0.5-mm increments. With the Rota-Link system, this involves changing only the burr with reuse of a single-drive turbine throughout the procedure. With a maximum burr-to-artery ratios of 0.7, optimal improvement in vessel lumen requires liberal use of adjunctive angioplasty (or other devices). When adjunctive postdilation is desired, most operators use low inflation pressures (<2 atm) to minimize barotrauma, but there are no published data to suggest that this technique results in lower residual stenoses or fewer complications than other approaches.

#### Mechanisms of Rotablator

Unlike other atherectomy devices, which rely on tissue cutting and retrieval (directional atherectomy) or cutting and aspiration (TEC atherec-

tomy), high-speed mechanical rotational atherectomy relies on plaque abrasion and pulverization. By the principle of differential cutting, the Rotablator tends to selectively abrade inelastic tissue (i.e., plaque) while elastic tissue (i.e., normal vessel wall) is deflected away from the burr (59). The abraded plaque is pulverized into particles 20 to 50  $\mu\text{m}$  in diameter that pass through the coronary microcirculation and undergo phagocytosis in the liver, spleen, and lung (4,60,61). Although these particles have long been felt to not interfere with the coronary microcirculation (62), the reported benefit of glycoprotein IIb/IIIa receptor blockers against transient hypoperfusion suggests a role for platelet-mediated microvascular flow reduction during rotational atherectomy (63). Reisman has confirmed *ex vivo* platelet activation, with greater activation at higher burr speeds (64), as well as greater vessel heating. These findings have encouraged the use of lower (<160,000 rpm) speed during rotational atherectomy, although this necessitates longer cumulative burr time.

Although two independent studies demonstrated no immediate or long-term impact on left ventricular ejection fraction (65,66), other studies show a significant incidence of non-Q-wave MI and no reflow (67), particularly in longer lesions (>2 mm). These problems could be secondary to particle embolization, spasm, microcavitation caused when the burr surface velocity exceeds the speed of sound in water (Bernoulli phenomenon) (68). Microcavitations or hemolysis of red blood cells may also contribute to transient bradycardia and atrioventricular (A-V) block, whereas mechanical stimulation and the loss of endothelium in the lesion and adjacent normal wall may explain the propensity for severe vasospasm during rotational atherectomy. Accordingly, liberal use of nitroglycerin and calcium channel blockers is routine, and temporary pacing should be considered, as discussed earlier.

## Results

### Immediate Results

Following Rotablator, the average residual diameter stenosis was 37% to 54% (65,67,69-73),

but this high residual diameter stenosis may reflect an increase in vessel tone after rotational atherectomy. Reisman thus demonstrated that the lesion site diameter was significantly larger 24 hours after rotational atherectomy than it was immediately after the procedure (74). IVUS may be useful for identifying which lesions are best suited to Rotablator and for guiding the use of larger burrs, balloon angioplasty, directional atherectomy, or stenting (75). In general, superficial calcium deposits are most amenable to Rotablator, since deep calcium deposits do not come in contact with the burr surface. Hoffman and coworkers demonstrated that treatment of calcified lesions with rotational atherectomy before stenting resulted in larger posttreatment lumen diameters and higher 9-month event-free survival than with stenting alone (76). The use of adjunctive low-pressure balloon angioplasty is frequent after Rotablator (70) (Table 24.7), and Rotablator pretreatment improves vessel compliance and therefore stent expansion (77). This "rota-stent" approach is our standard technique for calcified ostial and left main lesions (78,79) although it showed no significant advantage in the randomized SPORT trial of non- or minimally-calcified lesions. Rotablator is also an effective technique for debulking in-stent restenosis (Fig. 24.14) (36).

Rotablator atherectomy may be particularly indicated for specific lesion subsets where balloon angioplasty is known to be associated with suboptimal angiographic results. For calcified lesions, ostial lesions (Fig. 24.15), nondilatable lesions, and chronic total occlusions, Rotablator success has been reported to be 92% to 97%, with an acceptably low incidence of major clinical complications (80) (Table 24.7). Quantitative angiographic studies using matching lesion subsets suggest that pretreating many types of lesions with Rotablator can facilitate the results of adjunctive angioplasty (81) (Fig. 24.16).

While early studies indicated significant angiographic complications in nearly 40% of lesions after Rotablator—including angiographic dissection in 29%, side-branch occlusion in 1.8%, distal embolization in 0.9%, no reflow in 6.1%, abrupt closure in 11.2%, and severe spasm in 13.8%, and perforation in 1% to 2% of lesions—current technique has made the compli-

TABLE 24.7. Angiographic results and major clinical complications after rotablator atherectomy

| Author               | n    | Adjunctive PTCA (%) | Success (%) | Death (%) | MI (%)<br>Q/non-Q | CABG (%) | Restenosis (%) |
|----------------------|------|---------------------|-------------|-----------|-------------------|----------|----------------|
| Teirstein (67)       | 42   | 0                   | 76          | 2.0       | 0/19.0            | 2.0      | 59             |
| Bertrand (65)        | 129  | 29                  | 86          | 0         | 2.3/5.4           | 1.6      | 38             |
| Zacca (58)           | 36   | 0                   | 97          | 0         | 0/3.2             | 3.2      | NR             |
| Henson <sup>a</sup>  | 463  | 82                  | 95          | 1.0       | 0.7/NR            | 2.2      | NR             |
| Safian (70)          | 116  | 77                  | 75          | 0.9       | 4.4/2.7           | 1.8      | 51             |
| Stertz (71)          | 346  | 77                  | 94          | 0         | 3.3/11.0          | 1.2      | 37             |
| Gilmore <sup>b</sup> | 143  | 69                  | 92          | 0.9       | 0.9/2.8           | 2.8      | NR             |
| Bertrand (65)        | 1688 | 70                  | 95          | 0.9       | 1.0/5.4           | 2.3      | 48             |
| Ellis (72)           | 400  | 82                  | 90          | 0.3       | 2.2/5.7           | 0.9      | NR             |
| Warth (73)           | 874  | NR                  | 95          | 0.8       | 0.9/3.8           | 1.7      | 38             |
| NACI <sup>c</sup>    | 349  | 82                  | 97          | 0.8       | 1.5/4.9           | 0.4      | NR             |
| Villa <sup>d</sup>   | 574  | 39                  | 94          | 1.0       | 0.8/4.8           | 2.4      | 38             |

Abbreviations: n = number of lesions; PTCA = adjunctive balloon angioplasty; success = final diameter stenosis <50% in the absence of a major complication (death, emergency bypass surgery, or Q-wave myocardial infarction); MI = Q wave myocardial infarction/non-Q-wave myocardial infarction; CABG = emergency bypass surgery.

<sup>a</sup> Hanson KD. *Am J. Cardiol* 1993;71:862.

<sup>b</sup> Gilmore. *Clin Cardiol* 1993;16:311.

<sup>c</sup> Brown DL. *Am J. Cardiol* 1997;80:601.

<sup>d</sup> Villa. *Interven Cardiol* 1993;9:135.

cation rate comparable to other catheter-based techniques (81a). Like DCA, there is a higher incidence of non-Q-wave MI after Rotablator, which was 19% in one study of long lesions (67).

#### Late Results

In the Excimer, Rotablator, Balloon Angioplasty for Complex Lesions (ERBAC) study, a randomized trial of rotational atherectomy, exci-

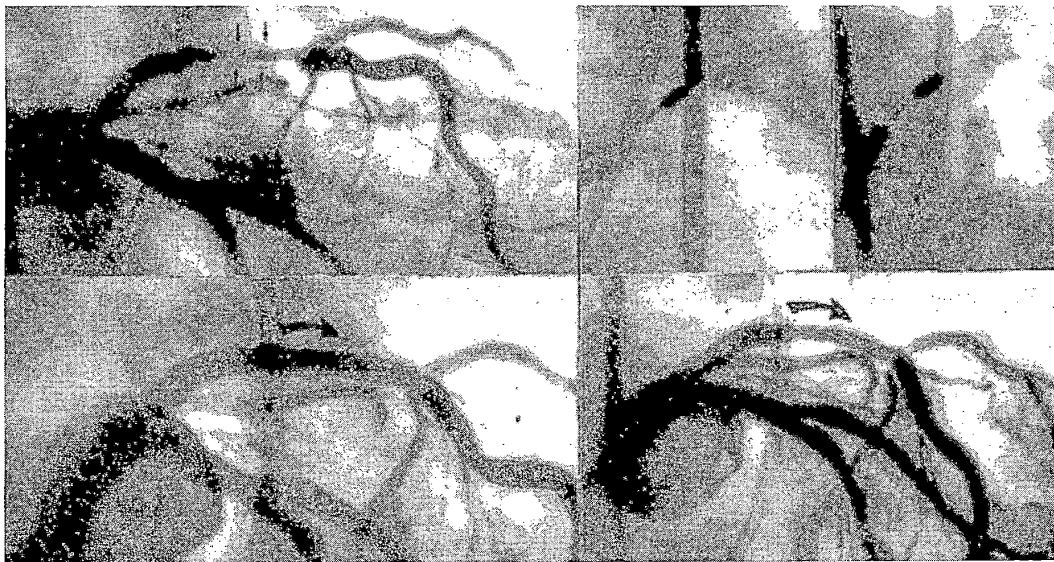
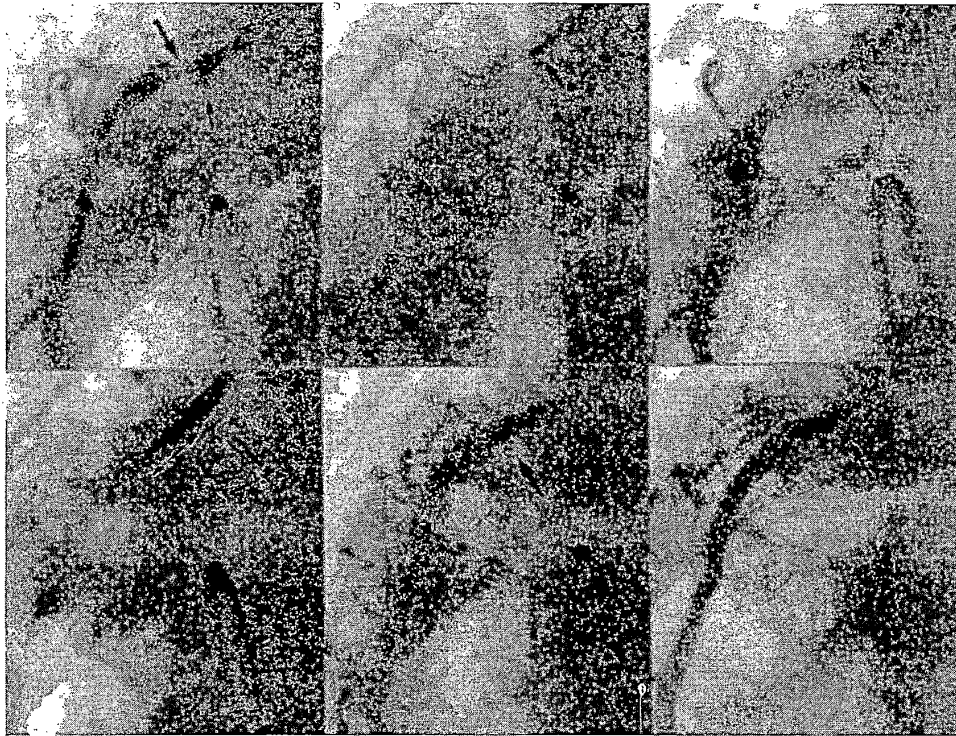
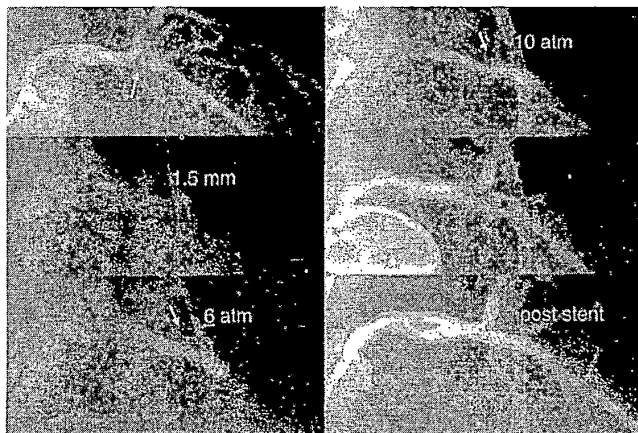


FIG. 24.14. Rotablator for in-stent restenosis (**upper left**). Severe restenosis is present in the proximal left anterior descending (note stent struts, *small arrows*). **Upper center and upper right**: Rotational atherectomy with 1.75- and 2.15-mm burrs. **Lower right**: Appearance post-Rotablator. **Lower left**: Appearance after final balloon dilatation.



**FIG. 24.15.** Ostial RCA rota-stent. **Upper left:** Severe ostial right coronary stenosis (*long arrow*) with heavy calcification (*short arrow*). **Upper center:** 1.75-mm Rotablator burr positioned just outside the lesion. **Upper right:** Modest lumen enlargement after rotational atherectomy. **Bottom left:** The resulting lumen, however, allowed advancement of a PS 104 biliary stent. **Bottom center:** Stent deployment. **Bottom right:** Final result postdilatation.



**FIG. 24.16.** Resistant calcified lesion becomes responsive after Rotablator. **Upper left:** Severe stenosis in the proximal left anterior descending artery (*arrow*). **Upper right:** Persistent waist despite inflation of angioplasty balloon to 10 atm. **Center left:** Advancement of a 1.5-mm Rotablator burr (note the heavy calcium shadows). **Center right:** Modest lumen enlargement following Rotablator. **Bottom left:** Following Rotablator, however, the same balloon now expands completely at 6 atm. **Bottom right:** Final result after stent placement.

mer laser angioplasty, or balloon angioplasty (see later, in the laser section), the final diameter stenosis after Rotablator and adjunctive angioplasty was significantly lower than that for adjunctive angioplasty after excimer laser or balloon angioplasty alone, but angiographic restenosis at 6 months was not significantly different at 45% to 50% (82). Other observational studies suggest a clinical restenosis rate of 38% and an angiographic restenosis rate between 31% and 59% (Table 24.6). The 500-patient randomized STRATAS trial compared aggressive rotational atherectomy, defined as high (>0.75) burr-to-artery ratio, with standard burr sizing (<0.7) to evaluate the impact of greater debulking (83). There was no difference in acute outcomes (except for a higher trend of non-Q-wave MI in the aggressive arm), with 6-month restenosis rates of 58% for the aggressive arm versus 52% for the conventional arm;  $p = \text{NS}$ .

#### Recommendations for Use of Rotablator Atherectomy

Although detailed randomized trial data are limited, we recommend the use of Rotablator for those lesions that are least likely to benefit from conventional angioplasty, such as long, ostial, and heavily calcified lesions, including protected left main arteries calcified bifurcation lesions (84), as well as the rare (1% to 2%) lesion that cannot be dilated successfully at inflation pressures of 12 atm (Table 24.8). Lesions that cannot be crossed with a balloon catheter due to lesion rigidity or excessive tortuosity of the proximal vessel may also be amenable to Rotablator (80). Rotablator has also proven to be

an excellent tool for the debulking of in-stent restenosis, with some studies suggesting a substantial reduction in recurrence rates after Rotablator plus balloon dilatation of such lesions (36,85–87).

Rotablator should be avoided soon after attempted angioplasty, particularly if there is any evidence for local dissection. Other contraindications to Rotablator include the presence of visible thrombus or extremely eccentric lesions in a severe bend in which the normal vessel wall lies on the outer curve of the bend. Although Rotablator is technically feasible in long lesions, it may be associated with a significant incidence of no reflow or non-Q-wave MI, and there are as yet no data to suggest superiority to conventional angioplasty using long balloons.

Despite its ability to facilitate the immediate results of balloon angioplasty for a variety of lesions, Rotablator has a clear learning curve for safe use. It is further limited by the maximum 2.5-mm burr diameter, the frequent need for adjunctive balloon angioplasty or stenting, the high cost of procedures, and the lack of a confirmed impact on restenosis. While the complications of distal embolization, no reflow, severe coronary vasospasm, bradycardia, and perforation are uncommon with refinement in Rotablator technique as described earlier, they can clearly occur and stand as a reason that Rotablator use is uncommon for low-volume operators.

#### ABLATIVE LASER TECHNIQUES

It was hoped that laser angioplasty would permit precise plaque removal with fewer acute complications and lower incidence of clinical restenosis (88). Despite the evolution of catheter

TABLE 24.8. *In-hospital results of rotablator atherectomy for specific lesion subsets*

| Author         | Lesion       | n   | Success (%) | Death (%) | CABG (%) | QMI (%) |
|----------------|--------------|-----|-------------|-----------|----------|---------|
| Whitlow        | Calcified    | NR  | 96          | 1.5       | 1.3      | 1.3     |
| Leon           | Calcified    | 220 | 95          | 0.5       | 1.1      | 1.6     |
| Kent           | Ostial       | 147 | 93          | 2.1       | 3.5      | 0       |
| Motwani (78)   | Ostial       | 119 | 97          | 0         | 0        | 0.8     |
| Reisman        | Nondilatable | 34  | 97          | 0         | 2.9      | 0       |
| Rosenblum (80) | Nondilatable | 41  | 98          | 0         | 0        | 0       |
| Warth (73)     | Chronic TO   | 68  | 93          | 1.5       | 0        | 0       |

Abbreviations: n = number of lesions; success = final diameter stenosis <50% in the absence of death, emergency bypass surgery (CABG), or Q-wave myocardial infarction (QMI); TO = total occlusion.

system designs over the years, restenosis rates following laser angioplasty have not been lower than those with balloon angioplasty alone (6,82). Given the lack of clinical benefit over other mechanical therapies and the significant capital cost (\$100,000 to \$250,000) for acquiring a laser system, hopes for laser angioplasty have shifted from a mainstream stand-alone therapy to an infrequently used adjunctive treatment to debulk plaque before balloon angioplasty or stenting in coronary lesions with large atherosclerotic and restenosis plaque burdens, or to debulk in-stent restenosis. Because laser systems are still in use in some laboratories, newer applications may still be found. The body of theoretical and clinical data will be reviewed.

### Laser Generation

Light amplification by stimulated emission of radiation (LASER) is the process of creating an in-phase (coherent) beam of monochromatic light with high energy. The lasing medium is "pumped" by an external energy source to force most of the atoms or molecules from their lower-energy ground state to a higher-energy excited state. After a brief time—measured in nanoseconds—the atoms begin to relax to their ground state by giving off a photon whose wavelength is determined by the energy difference between the excited and ground states, by the equation  $E = hn$ , where  $h$  = Planck's constant and  $n = c/l$  ( $c$ , speed of light;  $l$ , wavelength). One spontaneously released photon of precisely matched energy ( $hn$ ) can induce other excited atoms in the lasing medium to relax to the ground state and emit photons that are identical in direction, wavelength, and phase to the stimulating photon (stimulated emission). As this wave passes through the laser cavity, light coalesces into a single wave front whose intensity increases exponentially as it travels along the optical axis of the laser cavity and is reflected back and forth between the mirrors positioned at either end of the chamber. This standing wave of intense, monochromatic, coherent light then permeates the optical coupler, from which it travels down the optical fibers within the multifiber laser catheter whose other end is positioned within the

coronary artery lumen so as to illuminate the obstructing plaque with a burst of laser light.

### Laser/Tissue Interactions

The interaction between laser light and biologic tissue depends on the wavelength, the mode of laser operation (continuous-wave or pulsed), the energy density of the laser light (fluence), any interposed fluid medium (saline or blood) and the tissue's intrinsic absorption characteristics. For coronary laser angioplasty, lasers can be divided into ultraviolet lasers (e.g., XeCl excimer lasers, 300 nm) in which ablative energy is absorbed directly by atherosclerotic plaque absorption, and near-infrared/infrared lasers (e.g., holmium or neodymium YAG [yttrium-aluminum-garnet], 2,000 nm) in which thermal energy produced by water absorption leads to secondary photocoagulation. It is also important to distinguish continuous-wave laser systems, in which laser light is emitted in an uninterrupted manner, from newer pulsed systems that deliver peak laser over a very short pulse followed by a long interpulse interval to reduce heating of surrounding tissue. Despite these theoretical advantages, all pulsed laser systems still produce some thermal effects that are detectable with histologic examination after holmium and excimer laser radiation (89,90).

While water is almost completely transparent to ultraviolet light at wavelengths greater than 193 nm, it absorbs infrared light strongly due to excitement of the translational, vibrational, and rotational frequencies of the H—O bond. On the other hand, blood, x-ray contrast agents (such as ioxaglate), and tissue DNA absorb ultraviolet (UV) light avidly. When laser light encounters biologic tissue, tissue vaporization occurs if the light contains wavelengths that are absorbed by the tissue, and if the absorbed energy exceeds the threshold for triggering a phase transformations. Tissue ablation then takes place through one of three mechanisms: vaporization of tissue (photo-thermal effects), ejection of debris (photoacoustic effect), or direct breakdown of molecules (photochemical dissociation) (91).

Because early experimental studies involving free-laser beams in air (88) showed tidy ablation




FIG. 24.17. Ablation of postmortem human aortic tissue with pulsed excimer laser radiation at 193 nm in air.

of biologic tissue with clean margins and no histologic evidence of thermal injury (Fig. 24.17), it was initially thought that photodissociation was the predominant mechanism of excimer laser ablation of atherosclerotic plaque *in vivo*. Studies under saline or blood, however, disclosed less efficient plaque ablation and significant dissection of adjacent tissue due to forma-

tion and implosion of vapor bubbles at the impact site. This observation has immediate implications for excimer laser angioplasty. The use of intracoronary saline infusion to displace blood and radiographic contrast in the excimer laser field may thus reduce the risk of vessel dissection during excimer laser angioplasty (Fig. 24.18).

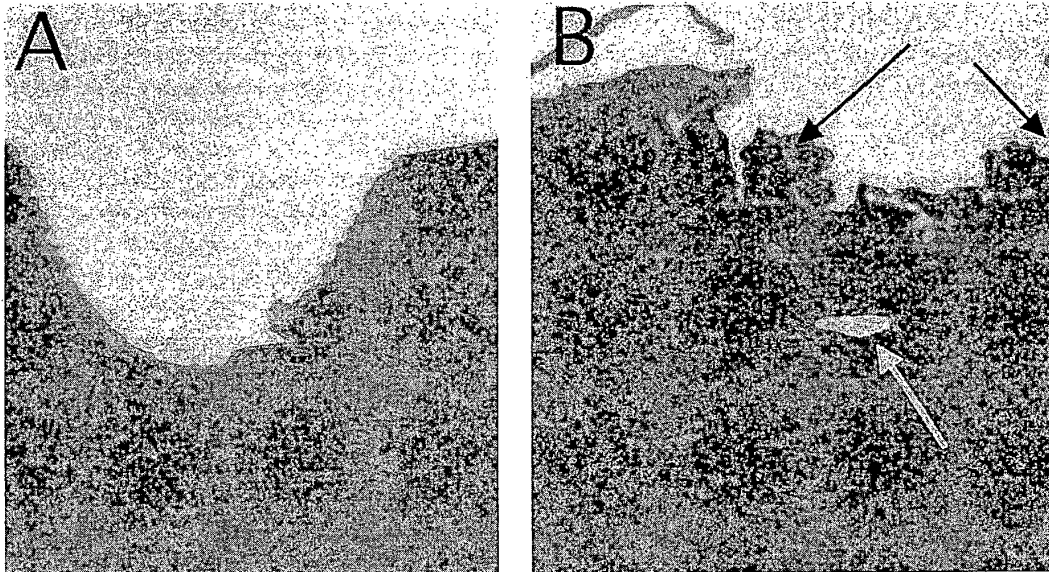


FIG. 24.18. Ablation of porcine aortic tissue after pulsed excimer laser angioplasty at 308 nm with multifiber laser catheters under saline (A) or blood (B). (Photomicrographs courtesy of L. Wells, Spectranetics, Colorado Spring, CO.)



### Catheter Delivery Systems

The history of laser angioplasty includes experimentation with bare laser fibers, coaxial fiber-centering balloons, laser-heated metal tips, the laser balloon for local vessel heating, and "smart" laser systems that used a diagnostic laser to interrogate the vessel and confirm the presence of plaque rather than normal vessel wall before firing the therapeutic laser. None of these techniques have survived clinical investigation. All current clinical laser systems share common elements: a laser generator, an energy coupler, and a catheter delivery system—a trackable, flexible, over-the-wire or monorail catheter that contain several hundred optical fibers. Each optical fiber is composed of a transmitting material (such as a purified silica for excimer laser angioplasty) surrounded by a cladding. Since the cladding and silica fibers have different refractive indices, this creates an interface that promotes internal reflection and transmission of light down the length of fiber with negligible energy loss. The brittle fiber and cladding materials are surrounded by a flexible protective coating to allow bending without fissuring. Efficient coupling of energy between the laser generator and the optical fibers requires critical tolerances for alignment and precise polishing of the fiber ends.

### The Technique of Laser Angioplasty

Conventional, commercially available guiding catheters can be used for excimer laser angioplasty. Because laser catheters are stiffer than balloon catheters and have difficulty negotiating acute angles into the target vessel, coaxial alignment is imperative. A stiff guiding catheter helps delivery, but firm guide support theoretically is not needed to advance the activated laser catheter through the target lesion, and excessive pushing of the catheter across the lesion may increase the risk of vessel dissection.

To maximize the likelihood of a safe outcome and reduce the risk of vessel perforation with excimer laser angioplasty, it is important to select a laser catheter with a diameter at least 1 mm smaller than the reference diameter of the target vessel (e.g., a 2-mm catheter for a 3-mm

vessel). For diffuse disease or total and subtotal occlusions, an even smaller laser catheter (1.3 or 1.4 mm) should be used initially to cross the lesion. The current recommendation is thus to limit ablation to one pass of a laser catheter per lesion.

After the target lesion is crossed with the guidewire, the laser catheter is advanced to lie at the proximal end of the lesion. This catheter position should be documented on cine. Before activating the laser and beginning ablation of the lesion, every effort must be made first to remove all contrast medium from the target vessel by flushing the guide catheter with at least 30 mL of saline. This is important because the interaction between excimer laser radiation and any retained contrast medium may increase the generation of shock waves with disruption of adjacent tissue planes (92).

During pulsed excimer laser angioplasty, laser energy is delivered at a fluence of 40 to 70 mJ/mm<sup>2</sup> at a frequency of 20 to 25 Hz for a duration of 1 to 5 seconds as the tip of the catheter is advanced through the lesion. For soft lesions such as saphenous vein graft lesions and restenosis lesions, laser ablation may commence at a fluence of 40 mJ/mm<sup>2</sup>, but for calcified lesions and *de novo* lesions in the native coronary arteries, the initial fluence should be 50 mJ/mm<sup>2</sup>. As the laser is activated, the catheter is advanced slowly under fluoroscopic guidance through the lesion at an average rate of 0.5 to 1 mm/sec. After each 1- to 5-second train of laser pulses, the laser catheter should "rest" for 10 seconds, to avoid potential attenuation of energy transmission through the optical fibers. If the laser catheter meets resistance and cannot pass through the lesion at the initial fluence, the energy output should be increased by increments of 10 mJ/mm<sup>2</sup> to a maximum of 60 or 70 mJ/mm<sup>2</sup>. If the laser catheter still cannot be advanced at higher fluence levels, the repetition rate also can be increased by increments of 5 Hz to a maximum of 40 Hz. If the laser catheter still fails to make progress through a stenotic segment after 15 seconds of laser time, the temptation for forceful advancement of the catheter should be avoided, since this will only increase the risk of vessel perforation. Once the laser catheter has been advanced completely through

the stenotic segment, adjunctive balloon postdilatation will be required in about 90% of laser angioplasty procedures to reduce the residual stenosis to below 30% (93-95). Further improvement can be achieved by following excimer laser angioplasty by stent placement or directional atherectomy in selected cases.

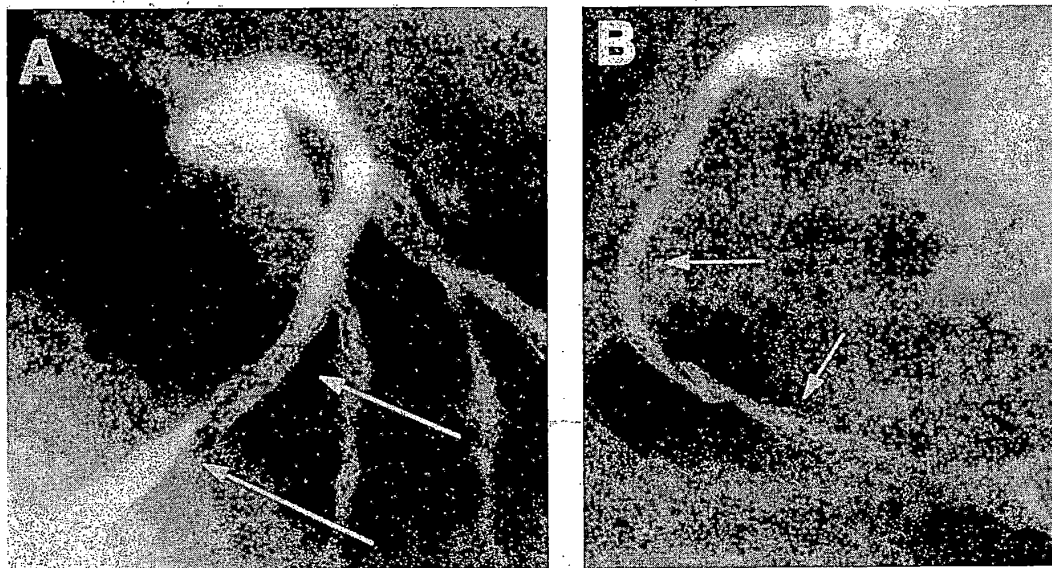
#### Clinical Results of Laser Angioplasty

Clinical success with the excimer laser, defined as less than 50% residual stenosis (after all treatments) and absence of major in-hospital complications, has been reported in 84% to 94% of patients with saphenous vein graft lesions, aortoostial stenoses, total occlusions, long lesions, and undilatable lesions (82,93-95). Early clinical experience with holmium laser coronary angioplasty in 331 patients demonstrated a procedural success rate of 94% and a perforation rate of 1.9% (96). Because of the similarities for both excimer laser and holmium laser interaction with tissue, the clinical results for the two systems are probably quite similar.

Despite increased clinical success with catheter

improvements, the rates of vessel dissection and perforation have remained constant. Indeed, the incidence of propagating dissection as high as 22% (Fig. 24.19) has continued to limit the usefulness of excimer laser angioplasty (93,95). Although coronary artery dissection is not unique to laser angioplasty, extension of the dissection beyond the treated site is probably more common following laser angioplasty than after use of balloon angioplasty or other devices. Vessel perforation occurs during laser angioplasty in 1% to 2% of patients treated (97) and commonly leads to a major complication (death, MI, cardiac tamponade, or bypass surgery). Risk factors for perforation include the use of oversized laser catheters, bifurcation lesions, and diabetes mellitus (98). The use of a saline flush during lasing has been shown to reduce the incidence of dissection and perforation both experimentally (99) and clinically.

Although laser angioplasty was developed initially to reduce restenosis by ablating atheromatous plaque without injuring the normal components of the arterial wall, restenosis has been reported in approximately 50% of patients (100).



**FIG. 24.19.** Coronary artery dissections after excimer laser angioplasty. Treatment of a long lesion in the left anterior descending artery (A, proximal arrow) was associated with propagating dissection (distal arrow). Treatment of a total occlusion in the midportion of the right coronary artery (B, proximal arrow) was associated with propagating dissection to the distal right coronary artery (distal arrow).

### *Undilatable Lesions*

Some fibrotic and calcified lesions cannot be dilated with balloon angioplasty at high pressures. Excimer laser angioplasty is associated with successful treatment in 89% of 36 patients with lesions that could be crossed with a guidewire but could not be dilated with balloon angioplasty (101). Although the excimer laser angioplasty is of value, rotational atherectomy is more commonly used for this indication. Neither should be attempted, however, in cases where dilation attempts resulted in local vessel dissection. Under such circumstances, excimer laser angioplasty is invariably associated with worsened dissection or perforation.

### *Total Occlusions*

Total occlusions crossable with a guidewire are associated with procedural success rates of 84% to 90% with excimer laser angioplasty (102,103). Many dissections that occur with excimer laser angioplasty, especially in the treatment of total occlusions, arise because the guidewire has traveled along an extraluminal course. It is therefore important to ensure that the guidewire is in the true lumen of the vessel by frequent contrast injections and confirming that the distal tip remains mobile, before advancing the laser catheter. The long-term success after excimer laser treatment of total occlusions is limited by the development of restenosis in approximately 50% of patients. In the randomized Amsterdam-Rotterdam (AMRO) trial (94), no restenosis benefit was seen for excimer laser compared with balloon angioplasty in a subset of 103 patients who presented with total occlusions.

For total occlusions not crossable with a conventional guidewire, a new approach with an excimer laser-based guidewire recently has entered clinical investigation. The Prima laser guidewire system (Spectranetics Corp., Colorado Springs, CO) consists of an 0.018-inch fiberoptic bundle coupled to a pulsed excimer laser operating at a tip fluence of 60 mJ/mm<sup>2</sup> at 25 to 40 Hz. The system uses a centering balloon for blinded tissue ablation through the obstruction.

The Prima system was also evaluated more

formally in two prospective trials in which the laser guidewire was used only after conventional guidewire techniques were performed and documented to fail. The U.S. TOTAL trial evaluated the learning phase of the lasing strategy in a 179-patient registry (104). Using the Prima catheter alone or in combination with a conventional guidewire, 61% of the refractory total occlusions were successfully crossed. Major complications were low, with a 1.1% death rate and a 1.7% rate of perforation leading to tamponade. A similar European feasibility trial demonstrated a 59% successful recanalization rate in 39 patients who could not be treated with conventional guidewire techniques (105). The European TOTAL surveillance study was a multicenter trial done to evaluate the safety and performance of the excimer laser system among 345 patients with a median occlusion age of 29 weeks (106). The recanalization rate was 59%, with no deaths, emergency surgery, or Q-wave MIs. While coronary perforations (laser "exits") were seen in 21% of cases, only 1% had tamponade. The independent covariates associated with success were occlusion age less than 40 weeks and lesion length less than 30 mm.

### *Calcified Lesions*

Calcified lesions initially were thought to be an indication for excimer laser angioplasty (107), but results of more recent studies have tempered the enthusiasm for this indication. In the Excimer Laser Rotational Atherectomy Balloon Angioplasty Comparison (ERBAC) trial involving 620 patients (82), excimer laser angioplasty was compared with conventional balloon angioplasty and percutaneous transluminal rotational atherectomy for type B and C lesions and a high proportion of calcified lesions. The procedural success rate was 84% for balloon angioplasty, 88% for excimer laser angioplasty, and 93% for rotational atherectomy. The incidence of major complications (death, MI, or bypass surgery) was greater after excimer laser angioplasty than after rotational atherectomy or balloon angioplasty (6.2% vs. 2.3% and 4.8%, respectively). At 6-month follow-up, the incidence of clinical events (death, MI, bypass surgery, or

repeat intervention) was greater after treatment with rotational atherectomy than after balloon angioplasty (53% vs. 45%;  $p < .05$ ), whereas treatment with excimer laser angioplasty was associated with an intermediate rate of clinical events (49%). This does not support the use of laser in calcified lesions.

### *Long Lesions*

Although long lesions were identified initially as the most promising indication for excimer laser angioplasty (93–95), recent analyses have suggested that long lesions are associated with trends toward reduced success, and strategies using long balloons and selective use of coronary stent placement (108) may result in superior success rates.

In a randomized comparison of excimer laser angioplasty with balloon angioplasty for lesions greater than 10 mm in length in 308 patients, the AMRO trial reported equivalent results for both types of treatment (109). In 151 patients randomly assigned to excimer laser angioplasty, 126 patients (80%) had procedural success and 50 (33%) experienced at least one cardiac event (death, MI, bypass surgery, or repeat angioplasty) within 6 months of the procedure. In 157 patients assigned to balloon angioplasty alone, 132 patients (79%) had procedural success and 47 (30%) experienced at least one cardiac event (death, MI, bypass surgery, or repeat angioplasty) within 6 months. Laser did not appear to confer a better acute or long-term benefit than balloon angioplasty for patients with lesions greater than 10 mm in length.

### *In-Stent Restenosis*

Laser angioplasty may be used successfully as a debulking treatment for in-stent restenosis. Excimer laser angioplasty with adjunctive balloon dilatation was evaluated in 527 in-stent lesions in 440 patients previously treated with a variety of coronary stents (110). There was a 92% laser angioplasty success, with serious adverse events, including death (1.6%), Q-wave MI (0.5%), perforation (0.9%), and dissections after laser (4.8%) or postdilatation (9.3%). Meh-

ran and coworkers compared the results of balloon angioplasty alone with excimer laser followed by balloon angioplasty in 98 cases of in-stent restenosis (111). By quantitative angiography and intravascular ultrasound, excimer laser was found to safely provide greater acute gain, plaque reduction, larger cross-sectional lumen area, and a trend for lower clinical restenosis than seen with balloon angioplasty.

### **MECHANICAL THROMBECTOMY**

The pathogenesis of acute myocardial ischemic syndromes in native coronary arteries and saphenous aortocoronary vein grafts clearly involves thrombus formation (112–114). Often the small amount of thrombus formation at the surface of a ruptured plaque is sufficient to interrupt coronary flow, may not be evident by coronary angiography, but may permit larger thrombi to propagate beyond the culprit plaque or into a proximal area of stagnant flow. Such large thrombi may be evident on angiography, and attempted intervention in such lesions tends to produce significant clinical problems (distal embolization, no reflow, abrupt closure). They were previously treated by infusions of thrombolytic drugs, but these large thrombi—recognized by certain angiographic and clinical clues (recent onset of symptoms, a mobile, rat-tail filling defect)—are now considered to be suitable targets for mechanical thrombectomy devices.

### **Earlier Pharmacologic Strategies to Remove Thrombus**

Before the development of mechanical thrombectomy, standard therapy involved direct intracoronary or intragraft infusion of urokinase (115–117). The safety and efficacy of this approach was evaluated in the ROBUST trial (118), in which 107 patients were treated with direct urokinase infusion through a 0.035-inch infusion wire. After 25.4 hours of urokinase infusion to a mean dosage of 3.7 million units, 69% recanalization success rate was observed with major complications, including a 3% stroke rate and a 6.5% death rate. Broader use of adjunctive urokinase infusion during intervention

has, however, been associated with a worsening of clinical outcomes (119).

In an attempt to avoid systemic lytic complications, urokinase has also been delivered directly to the thrombus surface using specialized delivery catheters. The Dispatch (Boston Scientific, Natick, MA) catheter is an over-the-wire, nondilatation catheter with a 20-mm spiral inflation coil whose inflation creates an external space apposed to the vessel surface into which urokinase may be infused. The initial experience showed complete dissolution of thrombus in patients with angiographically evident thrombus in native coronary and vein graft obstructions (120,121). Urokinase may also be absorbed into a hydrogel balloon coating to transfer urokinase locally to the site of thrombotic obstruction (122).

#### Mechanical Thrombectomy

The limitations in speed, efficacy, and bleeding complications have fostered the development of catheter-based techniques for direct thrombus removal. Catheter-based systems can be categorized broadly into systems designed to disintegrate thrombus (e.g., the therapeutic ultrasound Acolysis device and the vortex-creating rotational Amplatz device), and systems designed to aspirate and remove thrombus from the body (e.g., the Possis AngioJet, the Hydrolyzer, TEC [see earlier discussion]).

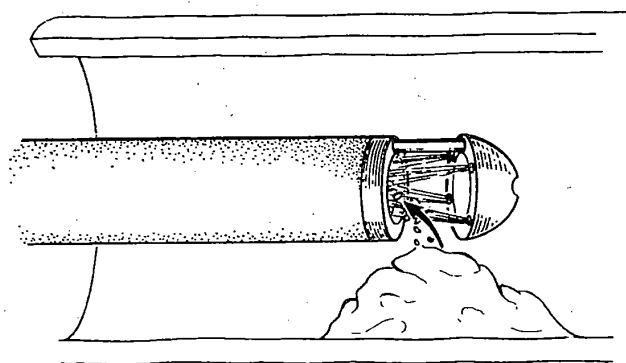
The mechanical cutting and aspirating TEC device (see earlier discussion) has been advocated as a potential strategy for the treatment of thrombus-containing native coronaries and vein

grafts (46–50), but has problems with distal embolization and vessel injury. The Cordis Hydrolyzer has had limited European exposure in humans in peripheral vessels (123), hemodialysis shunts (124), and coronary arteries and vein grafts (125,126).

The Amplatz thrombectomy device is another mechanical thrombectomy device that macerates thrombus. There is limited experience in peripheral artery thrombosis and occluded hemodialysis shunts (127–130). The Acolysis system employs therapeutic coronary ultrasound (at 41.9 kHz) to produce thrombolysis by fragmentation (131,132). Of 20 patients treated with the coronary ultrasound thrombolysis for vein graft disease (75% had total occlusions), there was a 70% device success (defined as final Thrombolysis in Myocardial Infarction [TIMI] 2 or 3 flow in occluded vessels or reduction in thrombus in patent vessels) with only one patient (5%) having evident distal embolization.

#### *Possis AngioJet Catheter Design and Technique*

The AngioJet is a 5F catheter with a stainless steel tip connected to a high-pressure hypotube (Fig. 24.20). Saline is injected into the tip via the hypotube, where it exits as three high-speed jets directed back into the main catheter lumen. By the Venturi-Bernoulli principle, this creates a low-pressure region at the tip (Fig. 24.21) that approaches a perfect vacuum ( $-760$  mm Hg). With a normal pressure in the arterial lumen of  $+100$  mm Hg, this produces a driving pressure



**FIG. 24.20.** Principle of rheolytic thrombectomy with the Possis AngioJet. High-speed saline jets exit orifices near the catheter tip and spray back into the mouth of the catheter. This creates intense local suction by the Venturi effect, which pulls thrombus into the jets, where the thrombus is macerated and propelled down the catheter lumen for external collection.

repeat intervention) was greater after treatment with rotational atherectomy than after balloon angioplasty (53% vs. 45%;  $p < .05$ ), whereas treatment with excimer laser angioplasty was associated with an intermediate rate of clinical events (49%). This does not support the use of laser in calcified lesions.

### *Long Lesions*

Although long lesions were identified initially as the most promising indication for excimer laser angioplasty (93–95), recent analyses have suggested that long lesions are associated with trends toward reduced success, and strategies using long balloons and selective use of coronary stent placement (108) may result in superior success rates.

In a randomized comparison of excimer laser angioplasty with balloon angioplasty for lesions greater than 10 mm in length in 308 patients, the AMRO trial reported equivalent results for both types of treatment (109). In 151 patients randomly assigned to excimer laser angioplasty, 126 patients (80%) had procedural success and 50 (33%) experienced at least one cardiac event (death, MI, bypass surgery, or repeat angioplasty) within 6 months of the procedure. In 157 patients assigned to balloon angioplasty alone, 132 patients (79%) had procedural success and 47 (30%) experienced at least one cardiac event (death, MI, bypass surgery, or repeat angioplasty) within 6 months. Laser did not appear to confer a better acute or long-term benefit than balloon angioplasty for patients with lesions greater than 10 mm in length.

### *In-Stent Restenosis*

Laser angioplasty may be used successfully as a debulking treatment for in-stent restenosis. Excimer laser angioplasty with adjunctive balloon dilatation was evaluated in 527 in-stent lesions in 440 patients previously treated with a variety of coronary stents (110). There was a 92% laser angioplasty success, with serious adverse events, including death (1.6%), Q-wave MI (0.5%), perforation (0.9%), and dissections after laser (4.8%) or postdilatation (9.3%). Meh-

ran and coworkers compared the results of balloon angioplasty alone with excimer laser followed by balloon angioplasty in 98 cases of in-stent restenosis (111). By quantitative angiography and intravascular ultrasound, excimer laser was found to safely provide greater acute gain, plaque reduction, larger cross-sectional lumen area, and a trend for lower clinical restenosis than seen with balloon angioplasty.

### MECHANICAL THROMBECTOMY

The pathogenesis of acute myocardial ischemic syndromes in native coronary arteries and saphenous aortocoronary vein grafts clearly involves thrombus formation (112–114). Often the small amount of thrombus formation at the surface of a ruptured plaque is sufficient to interrupt coronary flow, may not be evident by coronary angiography, but may permit larger thrombi to propagate beyond the culprit plaque or into a proximal area of stagnant flow. Such large thrombi may be evident on angiography, and attempted intervention in such lesions tends to produce significant clinical problems (distal embolization, no reflow, abrupt closure). They were previously treated by infusions of thrombolytic drugs, but these large thrombi—recognized by certain angiographic and clinical clues (recent onset of symptoms, a mobile, rat-tail filling defect)—are now considered to be suitable targets for mechanical thrombectomy devices.

### Earlier Pharmacologic Strategies to Remove Thrombus

Before the development of mechanical thrombectomy, standard therapy involved direct intracoronary or intragraft infusion of urokinase (115–117). The safety and efficacy of this approach was evaluated in the ROBUST trial (118), in which 107 patients were treated with direct urokinase infusion through a 0.035-inch infusion wire. After 25.4 hours of urokinase infusion to a mean dosage of 3.7 million units, 69% recanalization success rate was observed with major complications, including a 3% stroke rate and a 6.5% death rate. Broader use of adjunctive urokinase infusion during intervention

has, however, been associated with a worsening of clinical outcomes (119).

In an attempt to avoid systemic lytic complications, urokinase has also been delivered directly to the thrombus surface using specialized delivery catheters. The Dispatch (Boston Scientific, Natick, MA) catheter is an over-the-wire, nondilatation catheter with a 20-mm spiral inflation coil whose inflation creates an external space apposed to the vessel surface into which urokinase may be infused. The initial experience showed complete dissolution of thrombus in patients with angiographically evident thrombus in native coronary and vein graft obstructions (120,121). Urokinase may also be absorbed into a hydrogel balloon coating to transfer urokinase locally to the site of thrombotic obstruction (122).

#### Mechanical Thrombectomy

The limitations in speed, efficacy, and bleeding complications have fostered the development of catheter-based techniques for direct thrombus removal. Catheter-based systems can be categorized broadly into systems designed to disintegrate thrombus (e.g., the therapeutic ultrasound Acolysis device and the vortex-creating rotational Amplatz device), and systems designed to aspirate and remove thrombus from the body (e.g., the Possis *AngioJet*, the *Hydrolyzer*, *TEC* [see earlier discussion]).

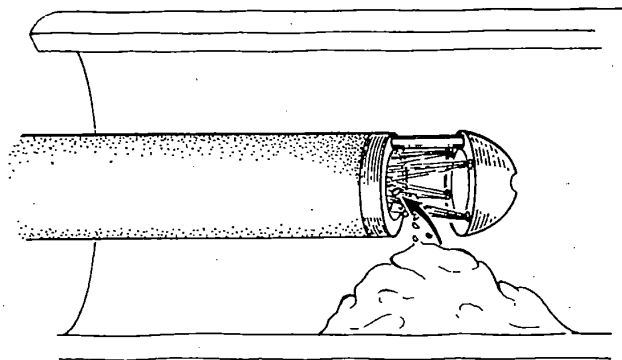
The mechanical cutting and aspirating *TEC* device (see earlier discussion) has been advocated as a potential strategy for the treatment of thrombus-containing native coronaries and vein

grafts (46–50), but has problems with distal embolization and vessel injury. The *Cordis Hydrolyzer* has had limited European exposure in humans in peripheral vessels (123), hemodialysis shunts (124), and coronary arteries and vein grafts (125,126).


The *Amplatz* thrombectomy device is another mechanical thrombectomy device that macerates thrombus. There is limited experience in peripheral artery thrombosis and occluded hemodialysis shunts (127–130). The *Acolysis* system employs therapeutic coronary ultrasound (at 41.9 kHz) to produce thrombolysis by fragmentation (131,132). Of 20 patients treated with the coronary ultrasound thrombolysis for vein graft disease (75% had total occlusions), there was a 70% device success (defined as final Thrombolysis in Myocardial Infarction [TIMI] 2 or 3 flow in occluded vessels or reduction in thrombus in patent vessels) with only one patient (5%) having evident distal embolization.

#### *Possis AngioJet Catheter Design and Technique*

The *AngioJet* is a 5F catheter with a stainless steel tip connected to a high-pressure hypotube (Fig. 24.20). Saline is injected into the tip via the hypotube, where it exits as three high-speed jets directed back into the main catheter lumen. By the Venturi-Bernoulli principle, this creates a low-pressure region at the tip (Fig. 24.21) that approaches a perfect vacuum (–760 mm Hg). With a normal pressure in the arterial lumen of +100 mm Hg, this produces a driving pressure



**FIG. 24.20.** Principle of rheolytic thrombectomy with the *Possis AngioJet*. High-speed saline jets exit orifices near the catheter tip and spray back into the mouth of the catheter. This creates intense local suction by the Venturi effect, which pulls thrombus into the jets, where the thrombus is macerated and propelled down the catheter lumen for external collection.



**FIG. 24.21.** Rheolytic thrombectomy with the Possis AngioJet in a patient with an occluded saphenous vein graft (*upper left, insert*). **Upper left:** Following balloon angioplasty of the graft ostium, a large filling defect (*open arrow*) is apparent in the body of the graft. **Lower left:** The AngioJet (*arrow*) is advanced beyond the presumptive thrombus, activated, and pulled back slowly. **Upper right:** Following AngioJet treatment, only small defects remain. **Bottom right:** Placement of Palmaz-Schatz biliary stents in the ostium and body of the graft provides near-normal appearance and antegrade flow.

of 860 mm Hg that pulls surrounding fluid (blood, thrombus, and saline) into the tip opening. There the jets break the thrombus into sub-cellular-sized particles and propel them proximally through the catheter lumen and out of the body. A hemostasis valve allows for the evacuation lumen to be sealed around a 0.014- to 0.018-inch diameter guidewire, over which the catheter is advanced down the coronary vessel. Previous *in vivo* histologic studies have shown that the catheter produces minimal or no vessel wall damage (133).

Once the culprit lesion is identified, it is crossed using a 0.014- to 0.018-inch guidewire. The 5F AngioJet is then advanced over the wire and distal to the thrombotic lesion. The saline jets are then activated and the catheter is with-

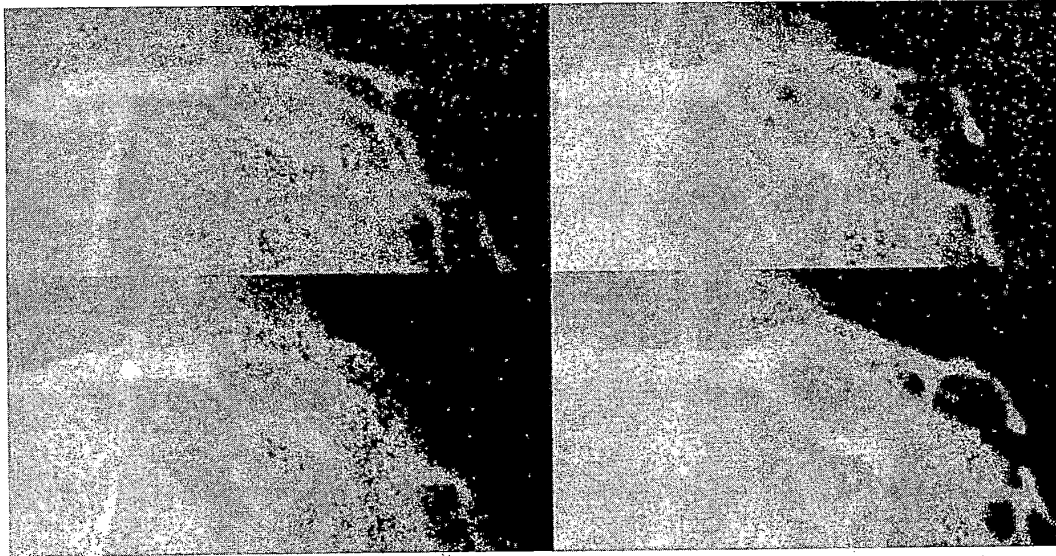
drawn slowly across the lesion at 0.5 to 1 mm/sec. Angiography is then performed after the first such withdrawal, and repeated passes of the AngioJet may be performed until angiography shows no further evidence of improvement in the lumen diameter or thrombus burden. The AngioJet has been used successfully to remove thrombus in elective situations such as thrombotic vein grafts (Fig. 24.21) and acute coronary ischemic scenarios, including acute MI (Fig. 24.22) (134–136).

### Studies

#### VEGAS I

The Vein Graft AngioJet Study (VEGAS I) consisted of multicenter registry of 90 patients





**FIG. 24.22.** AngioJet for AMI. **Upper left:** Primary angioplasty for acute anterior wall myocardial infarction shows thrombotic occlusion of the proximal left anterior descending. **Bottom left:** Passage of the AngioJet distal to thrombus. **Top right:** Following aspiration with the AngioJet, the thrombotic filling defect is gone. **Bottom right:** Following stent placement, a large, smooth lumen and brisk antegrade flow are present.

with acute ischemic syndromes demonstrated. It showed that the AngioJet rheolytic thrombectomy catheter system reduced the angiographically measured thrombus burden within native coronary arteries or saphenous vein bypass grafts by an average of 86% (137).

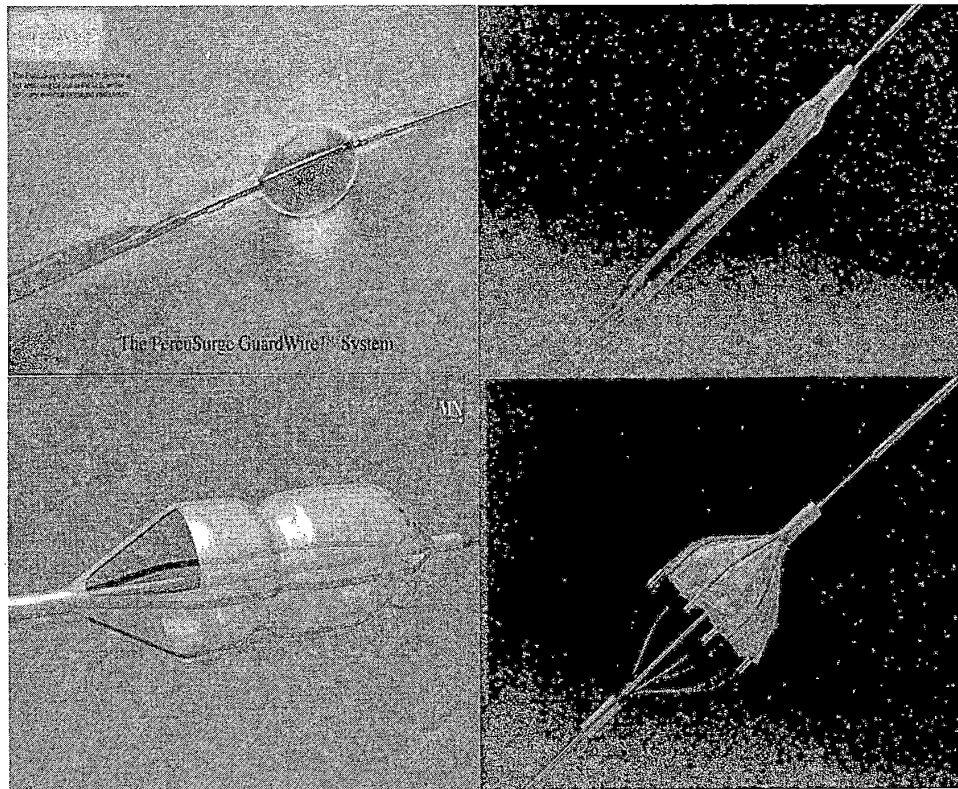
### VEGAS II

The Vein Graft AngioJet Study randomized trial (VEGAS II) was designed as a 500-patient multicenter randomized trial comparing the AngioJet rheolytic thrombectomy system with direct urokinase infusion for safety and effectiveness of thrombus removal before stenting for the treatment of saphenous vein grafts or native coronaries with angiographically apparent intraluminal thrombus (138). Because the 30-day event-free survival for major adverse cardiac events (defined as freedom from death, MI, emergent bypass surgery, target lesion revascularization, or stroke) was significantly lower for the AngioJet group after enrollment of 300 patients, the data safety committee recommended early termination at a final enrollment of 349

patients (180 in the AngioJet arm and 169 in the urokinase arm). The results of VEGAS I and VEGAS II were used by the Food and Drug Administration to approve the device in June of 1998.

### DISTAL EMBOLIZATION PROTECTION DEVICES

Each of the devices discussed earlier actively seeks to remove plaque or thrombus from the target lesion, but it is now clear that even such interventions as balloon angioplasty or stent placement may break free fragments of friable plaque. This appears to be one of the main causes of no reflow during saphenous vein graft intervention, and may cause distal embolic events during carotid artery intervention (see Chapter 27). Various devices have been introduced recently for clinical trial evaluation that seek to trap such embolic material and remove it from the circulation (Fig. 24.23). As such, they are technically members of the "atherectomy" family. As their development progresses, it is likely that distal embolus protection will be used in



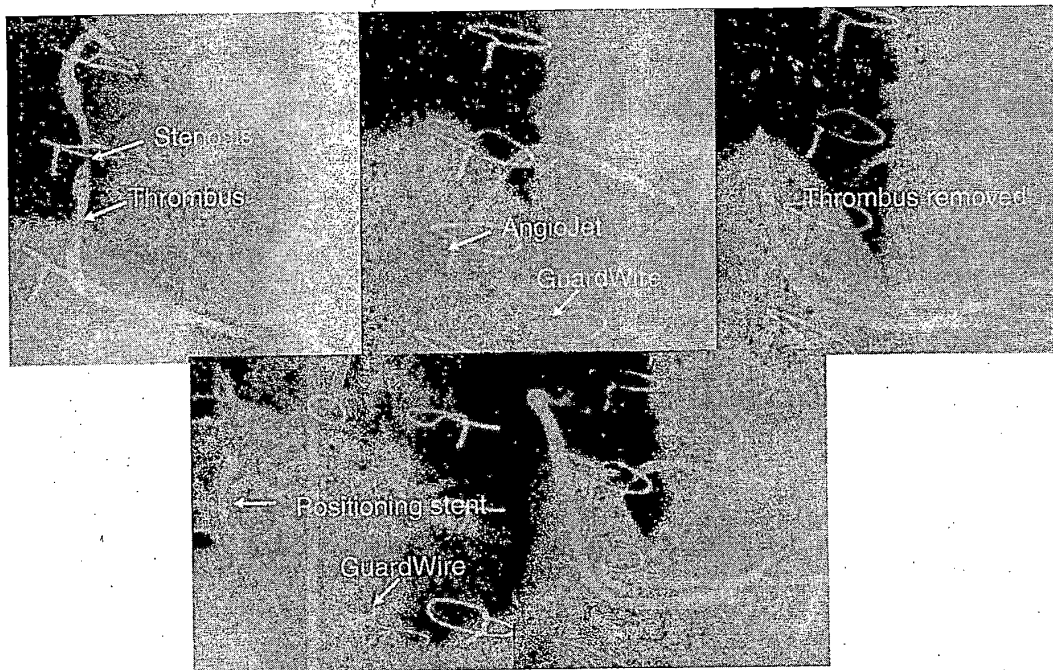
**FIG. 24.23.** Distal embolus retrieval devices. **Upper left:** The PercuSurge Guardwire shown during inflation of the low-pressure distal occlusion balloon and passage of the Export aspiration catheter to aspirate liberated debris. **Lower left:** The MedNova filter device shown open with collected debris in the filter, and the AngioGuard filter shown collapsed during delivery (*upper right*) and expanded (*lower right*) for collection of embolic material.

combination with a broad variety of interventional devices (such as thrombectomy and stent placement, Fig. 24.24) to protect the distal circulation from embolization and consequent no-reflow.

The Guardwire (PercuSurge, Sunnyvale, CA) is a compliant balloon mounted on a hypotube that can function as a 0.014-inch steerable guide-wire (139). Once it is positioned across the target lesion, the balloon can be inflated to block the flow of blood in the vessel, as the mechanical intervention is performed. With any liberated debris still trapped by the inflated Guardwire, an aspiration catheter is brought into the vessel and removes the blood and suspended debris. The Guardwire is then deflated to restore flow

into the distal vessel. Preliminary analysis of the aspirate shows extensive plaque debris, and a randomized trial (SAFER) is now under way to evaluate whether performing vein graft angioplasty with such protection is associated with a lowering in the incidence of periprocedural slow flow and CK release. Preliminary results in the carotid artery is also encouraging.

There are also a series of semiporous filter devices that can be advanced into the distal vessel and deployed during intervention, to catch and remove liberated emboli. The first devices that will undergo clinical trial evaluation are the Emboshield (MedNova), the AngioGuard, and the Filter Wire (Emboloc Protection Inc., San Carlos, CA). All (Johnson & Johnson Medical)



**FIG. 24.24.** Combination of distal protection and rheolytic thrombectomy. **Upper left:** Severe stenosis and adherent distal thrombus are present in this vein graft to the right coronary artery. **Upper center:** The PercuSurge Guardwire has been passed into the distal vessel and inflated, with advancement of the AngioJet over the Guardwire. **Upper right:** After removal of the thrombus, the Guardwire is deflated, and injection shows the residual stenosis. **Lower left:** Re-inflation of the Guardwire allows placement of a stent. **Lower right:** Following aspiration of any liberated atheroembolic debris, the Guardwire is again deflated to restore flow.

devices are nitinol expandable polymer filters located on the distal end of a modified 0.014-inch guidewire, which is deployed using specialized delivery and retrieval catheters. The shaft of the device can then function as a rail for advancement of over-the-wire platform for percutaneous coronary devices. After intervention, the filter is collapsed and withdrawn with any trapped debris.

### SUMMARY

Although they have proven no more effective than stenting for the treatment of routine lesions, mechanical and laser-based atherectomy techniques continue to play an important adjunctive role in coronary intervention. These techniques are of particular value in treating ostial, bifurca-

tion, or in-stent restenotic lesions, in debulking before stenting, and in treating long, fibrotic, or calcified lesions. In general, they are more challenging to use than balloon and stent techniques, and frequently carry a higher cost and an increased risk of some complications (such as periprocedure CK elevation, perforation, or dissection). But they have survived as important parts of interventional cardiology simply because they extend the range of lesions treatable by catheter-based therapy. The newer devices for thrombus removal and distal embolic protection also extend the range of treatable lesions and improve procedural results. Still newer atherectomy concepts are under development, including some with on-board ultrasound guidance to facilitate safe and more complete plaque removal, making it likely that atherectomy will remain as a strong

minority player in an interventional world dominated by stenting.

### REFERENCES

1. Simpson JB, Selmon MR, Robertson GC, et al. Transluminal atherectomy for occlusive peripheral vascular disease. *Am J Cardiol* 1988;61:96G.
2. Simpson JB. How atherectomy began: a personal history. *Am J Cardiol* 1993;72:3E.
3. Safian RD, et al. Clinical and angiographic results of transluminal extraction coronary atherectomy in saphenous vein bypass grafts. *Circulation* 1994;89:302.
4. Ahn SS, Authi D, Marcus DR, Moore WS. Removal of focal atheromatous lesions by angioscopically guided high-speed rotary atherectomy. *J Vasc Surg* 1988;7:292.
5. Fourrier JL, et al. Percutaneous coronary rotational atherectomy in humans: preliminary report. *J Am Coll Cardiol* 1989;14:1278.
6. Bittl JA. Clinical results with excimer laser coronary angioplasty. *Semin Interv Cardiol* 1996;1:129.
7. Hinohara T, Selmon MR, Robertson GC, Braden L, Simpson JB. Directional atherectomy: new approaches for treatment of obstructive coronary and peripheral vascular disease. *Circulation* 1990;81[Suppl IV]:IV-79.
8. Baim DS, et al. Results of directional coronary atherectomy during multicenter preapproval testing. *Am J Cardiol* 1993;72:6E.
9. Penny WF, Schmidt DA, Safian RD, Erny RE, Baim DS. Insights into the mechanism of luminal improvement after directional coronary atherectomy. *Am J Cardiol* 1991;67:435.
10. Matar FA, Mintz GA, Farb A, et al. The contribution of tissue removal to the lumen improvement after directional coronary atherectomy. *Am J Cardiol* 1994;74:647.
11. Lansky AJ, Mintz GS, Popma JJ, et al. Remodeling after directional coronary atherectomy (with and without adjunct percutaneous transluminal coronary angioplasty): a serial angiographic and intravascular ultrasound analysis from the Optimal Atherectomy Restenosis Study. *J Am Coll Cardiol* 1998;32:329.
12. Gordon PC, Kugelmass AD, Cohen DJ, et al. Balloon postdilatation can safely improve the results of successful (but suboptimal) directional coronary atherectomy. *Am J Cardiol* 1993;72:71E.
13. Simontón CA, Leon MB, Baim DS, et al. "Optimal" directional coronary atherectomy: final results of the Optimal Atherectomy Restenosis Study (OARS). *Circulation* 1998;97:332.
14. Baim DS, Cutlip DE, Sharima SK, et al. Final results of the Balloon vs Optimal Atherectomy Trial (BOAT). *Circulation* 1998;97:322.
15. Fishman RF, Kuntz RE, Carrozza JP, et al. Long-term results of directional coronary atherectomy: predictors of restenosis. *J Am Coll Cardiol* 1992;20:1101.
16. Hinohara T, Rowe MH, Robertson GC, et al. Effect of lesion characteristics on outcome of directional coronary atherectomy. *J Am Coll Cardiol* 1991;17:1112.
17. Waksman R, Popma JJ, Kennard ED, et al. Directional coronary atherectomy—a report from the NACI Registry. *Am J Cardiol* 1997;80[Suppl]:50K.
18. Topol EJ, Leya F, Pinkerton CA, et al. A comparison of directional atherectomy with coronary angioplasty in patients with coronary artery disease. *N Engl J Med* 1993;329:221.
19. Adelman AG, et al. A comparison of directional atherectomy with balloon angioplasty for lesions of the left anterior descending coronary artery. *N Engl J Med* 1993;329:228.
20. Suzuki T, Hosokawa H, Katoh O, et al. Effects of adjunctive balloon angioplasty after intravascular ultrasound-guided optimal directional atherectomy—results of the ABACAS study. *J Am Coll Cardiol* 1999;34:1028.
21. Lansky AJ, Mintz GS, Popma JJ. Remodeling after directional coronary atherectomy (with or without percutaneous adjunct transluminal coronary angioplasty)—a serial angiographic and intravascular ultrasound analysis from the Optimal Atherectomy Restenosis Study. *J Am Coll Cardiol* 1998;32:329.
22. Schnitt SJ, Safian RD, Kuntz RE, Schmidt DA, Baim DS. Histologic findings in specimens obtained by percutaneous directional coronary atherectomy. *Hum Pathol* 1992;23:415.
23. Kuntz RE, Hinohara T, Safian RD, Selmon MR, Simpson JB, Baim D. Restenosis following directional coronary atherectomy: the effects of luminal diameter and deep wall excision. *Circulation* 1992;86:1394.
24. Holmes DR Jr, Garratt KN, Isner JM, et al. Effect of subintimal resection on initial outcome and restenosis for native coronary lesions and saphenous vein graft disease treated by directional coronary atherectomy. A report from the CAVEAT I and II investigators. *Coronary Angioplasty Versus Excisional Atherectomy Trial*. *J Am Coll Cardiol* 1996;28:645.
25. Bell MR, Garratt KN, Bresnahan JF, Edwards WD, Holmes DR Jr. Relation of deep arterial resection and coronary artery aneurysms after directional coronary atherectomy. *J Am Coll Cardiol* 1992;20:1474.
26. Imai Y, Hara K, Yamasaki M, et al. Mid-term follow-up of coronary artery aneurysm after directional coronary atherectomy. *J Cardiol* 1999;33:201.
27. Miller MJ, Kuntz RE, Friedrich SP, et al. Frequency and consequences of intimal hyperplasia in specimens retrieved by directional atherectomy of native primary coronary artery stenoses and subsequent restenoses. *Am J Cardiol* 1993;71:652.
28. Mansour M, Fishman RF, Kuntz RE, et al. Feasibility of directional atherectomy for the treatment of bifurcation lesions. *Coron Artery Dis* 1992;3:761.
29. Safian RD, Scriber TL, Baim DS. Specific indications for directional atherectomy: origin left anterior descending coronary artery and bifurcation lesions. *Am J Cardiol* 1993;72:35E.
30. Eisenhauer AC, Clugston RA, Ruiz CE. Sequential directional atherectomy of coronary bifurcation lesions. *Cathet Cardiovasc Diagn* 1993;[Suppl 1]:54.
31. Dauerman HL, Higgins PJ, Sparano AM, et al. Mechanical debulking versus balloon angioplasty for the treatment of true bifurcation lesions. *J Am Coll Cardiol* 1998;32:1845.
32. Popma JJ, Dick RJ, Haudenschild CC, Topol EJ, Ellis SG. Atherectomy of right coronary ostial stenoses: initial and long-term results, technical features and histologic findings. *Am J Cardiol* 1991;67:431.
33. Jain SP, Liu MW, Dean LS, et al. Comparison of bal-

- loon angioplasty versus debulking devices versus stenting in right coronary ostial lesions. *Am J Cardiol* 1997;79:1334.
34. McKeever LS, Marek JC, Kerwin PM, et al. Bail-out directional atherectomy for abrupt coronary artery occlusion following conventional angioplasty. *Cathet Cardiovasc Diagn* 1993;[Suppl 1]:31.
  35. Harris WO, Berger PB, Holmes DR Jr, et al. "Rescue" directional coronary atherectomy after unsuccessful percutaneous transluminal coronary angioplasty. *Mayo Clin Proc* 1994;69:717.
  36. Dauerman HL, Baim DS, Cutlip DE, et al. Mechanical debulking versus balloon angioplasty for the treatment of diffuse in-stent restenosis. *Am J Cardiol* 1998;82:277.
  37. Strauss BH, Umans VA, van Suylen RJ, et al. Directional atherectomy for treatment of restenosis within coronary stents: clinical, angiographic and histologic results. *J Am Coll Cardiol* 1992;20:1465.
  38. Mahdi NA, Pathan AZ, Harrell L, et al. Directional coronary atherectomy for the treatment of Palmaz-Schatz in-stent restenosis. *Am J Cardiol* 1998;82:1345.
  39. Teirstein PS, Massullo V, Jani S, et al. Catheter-based radiotherapy to inhibit restenosis after coronary stenting. *N Engl J Med* 1997;336:1697.
  40. Moussa I, Moses J, Di Mario C, et al. Stenting after optimal lesion debulking (SOLD) registry: angiographic and clinical outcome. *Circulation* 1998;98:1604.
  41. Kiesz RS, Rozek MM, Mego DM, et al. Acute directional coronary atherectomy prior to stenting in complex coronary lesions: ADAPTS Study. *Cathet Cardiovasc Diagn* 1998;45:105.
  42. Annex BH, Larkin TJ, O'Neill WW, Safian RD. Thrombus removal by transluminal extraction coronary atherectomy (TEC): evaluation by percutaneous coronary angiography. *Am J Cardiol* 1994;74:606.
  43. Kaplan BM, Safian RS, Grines CL, et al. Usefulness of adjunctive angiography and extraction atherectomy before stent implantation in high risk narrowings in aorto-coronary artery saphenous vein grafts. *Am J Cardiol* 1995;76:822.
  44. Popma JJ, et al. Results of coronary angioplasty using the transluminal extraction catheter. *Am J Cardiol* 1992;70:1526.
  45. Pizzulli L, Kohler U, Manz M, Luderitz B. Mechanical dilatation rather than plaque removal as major mechanism of transluminal extraction atherectomy. *J Intervent Cardiol* 1993;6:31.
  46. Twidale N, Barth CW, Kipperman RM, et al. Acute results and long-term outcome of transluminal extraction catheter atherectomy for saphenous vein graft stenoses. *Cathet Cardiovasc Diagn* 1994;31:187.
  47. Meany TB, Leon MB, Kramer BL, et al. Transluminal extraction catheter for the treatment of diseased saphenous vein grafts: a multicenter experience. *Cathet Cardiovasc Diagn* 1995;34:112.
  48. Sullebarger JT, Dalton RD, Tauth JG, Matar FA. One-year follow-up of recanalization of totally occluded aortocoronary saphenous vein grafts using transluminal extraction atherectomy. *Am J Cardiol* 1998;81:636.
  49. Dooris M, et al. Comparative results of transluminal extraction atherectomy in saphenous vein graft lesions with and without thrombus. *J Am Coll Cardiol* 1995;25:1700.
  50. Braden GA, Xenopoulos NP, Young T, et al. Transluminal extraction catheter atherectomy followed by immediate stenting in treatment of saphenous vein grafts. *J Am Coll Cardiol* 1997;30:657.
  51. Safian RD, et al. Detailed clinical and angiographic analysis of transluminal extraction coronary atherectomy for complex lesions in native coronary arteries. *J Am Coll Cardiol* 1995;25:848.
  52. Nino CL, et al. Procedural cost of new interventional devices. *Am J Cardiol* 1994;74:1165.
  53. Kaplan BM, Larkin T, Safian RD, et al. Prospective study of extraction atherectomy in patients with acute myocardial infarction. *Am J Cardiol* 1996;78:383.
  54. Topaz O, Miller G, Vetrovec GW. Transluminal extraction catheter for acute myocardial infarction. *Cathet Cardiovasc Diagn* 1997;40:291.
  55. Kaplan BM, Gregory M, Schreiber TL, et al. Transluminal extraction atherectomy versus balloon angioplasty in acute ischemic syndrome. *Circulation* 1996;94:1317.
  56. Kaplan BM. Results of the TECBEST trial. Presented at Transcatheter Therapeutics, September 22-25, 1999, Washington DC.
  57. Sketch MH, Davidson CJ, Yeh W, et al. Predictors of acute and long-term outcome with transluminal extraction atherectomy: the new approaches to coronary intervention registry. *Am J Cardiol* 1997;80[Suppl]:68K.
  58. Zacca NM, et al. Treatment of symptomatic peripheral atherosclerotic disease with a rotational atherectomy device. *Am J Cardiol* 1989;63:77.
  59. Auth DC. Angioplasty with high speed rotary ablation. In: Serruys PW, et al, eds. *Restenosis after intervention with new mechanical devices*. Boston: Kluwer Academic Publishers, 1992:275.
  60. Hansen DD, et al. Rotational atherectomy in atherosclerotic rabbit iliac arteries. *Am Heart J* 1988;115:160.
  61. Hansen DD, et al. Rotational endarterectomy in normal canine coronary arteries: preliminary report. *J Am Coll Cardiol* 1988;11:1073.
  62. Friedman HZ, et al. Mechanical rotary atherectomy: the effects of microparticle embolization on myocardial blood flow and function. *J Intervent Card* 1989;2:77.
  63. Koch KC, Vom Dahl J, Kleinhanz E, et al. Influence of platelet Gp IIb/IIIa receptor antagonist on myocardial hypoperfusion during rotational atherectomy as assessed by myocardial Tc-99m sestamibi scintigraphy. *J Am Coll Cardiol* 1999;33:998.
  64. Reisman M, Shuman BJ, Dillard D, et al. Analysis of low-speed rotational atherectomy for the reduction of platelet aggregation. *Cathet Cardiovasc Diagn* 1998;45:208.
  65. Bertrand ME, et al. Percutaneous transluminal coronary rotary ablation with Rotablator (European experience). *Am J Cardiol* 1992;69:470.
  66. O'Neill WW. Mechanical rotational atherectomy. *Am J Cardiol* 1992;69:12F.
  67. Teirstein PS, et al. High-speed rotational coronary atherectomy for patients with diffuse coronary artery disease. *J Am Coll Cardiol* 1991;18:1694.
  68. Zotz R, et al. Analysis of high-frequency rotational angioplasty-induced echo contrast. *Cathet Cardiovasc Diagn* 1991;22:137.
  69. Zacca NM, et al. Rotational ablation of coronary artery.

- lesions using single, large burrs. *Cathet Cardiovasc Diagn* 1992;26:92.
70. Safian RD, et al. Detailed angiographic analysis of high-speed mechanical rotational atherectomy in human coronary arteries. *Circulation* 1993;88:961.
  71. Stertzer SH, et al. Coronary rotational ablation: initial experience in 302 procedures. *J Am Coll Cardiol* 1993; 21:287.
  72. Ellis SG, et al. Relation of clinical presentation, stenosis morphology, and operator technique to the procedural results of rotational atherectomy and rotational atherectomy-facilitated angioplasty. *Circulation* 1994; 89:882.
  73. Warth DC, et al. Rotational atherectomy multicenter registry: acute results, complications and 6-month angiographic follow-up in 709 patients. *J Am Coll Cardiol* 1994;24:641.
  74. Reisman M, Buchbinder M, Harms V, et al. Quantitative angiography of coronary artery dimensions 24 hours after rotational atherectomy. *Am J Cardiol* 1998; 81:1427.
  75. Mintz GS, et al. Intravascular ultrasound evaluation of the effect of rotational atherectomy in obstructive atherosclerotic coronary artery disease. *Circulation* 1992;86:1383.
  76. Hoffman R, Mintz GS, Kent KM, et al. Comparative early and nine-month results of rotational atherectomy, stents, and the combination of both for calcified lesions in large coronary arteries. *Am J Cardiol* 1998;81:552.
  77. Henneke KH, Regar E, Konig A, et al. Impact of target lesion calcification on coronary stent expansion after rotational atherectomy. *Am Heart J* 1999;137:93.
  78. Motwani JG, Raymond RE, Franco I, et al. Effectiveness of rotational atherectomy of right coronary artery ostial stenosis. *Am J Cardiol* 2000;85:563.
  79. Lopez JJ, Ho KKL, Stoler RC, et al. Percutaneous treatment of protected and unprotected left main coronary stenosis with new devices—immediate angiographic results and intermediate-term follow-up. *J Am Coll Cardiol* 1997;29:345.
  80. Rosenblum J, et al. Rotational ablation of balloon angioplasty failures. *J Invas Cardiol* 1992;4:312.
  81. Safian RD, Freed M, Reddy V, et al. Do excimer laser angioplasty and rotational atherectomy facilitate balloon angioplasty? Implications for lesion-specific coronary intervention. *J Am Coll Cardiol* 1996;27:552.
  - 81a. King A, Marmur JD, Duvvuri S, et al. Rotational atherectomy-improved procedural outcome with evolution of techniques and equipment. Single-center results of the first 1,000 patients. *Cathet Cardiovasc Interv* 1999;46:1522.
  82. Reifart N, Vandormael M, Krajcar M, et al. Randomized comparison of angioplasty of complex coronary lesions at a single center. Excimer Laser, Rotational Atherectomy, and Balloon Angioplasty Comparison (ERBAC) Study. *Circulation* 1997;96:91.
  83. Ferguson J. Meeting highlights—46<sup>th</sup> annual session of the American College of Cardiology. *Circulation* 1997;96:367.
  84. Rihal CS, Garratt KN, Holmes DR Jr. Rotational atherectomy for bifurcation lesions of the coronary circulation: technique and initial experience. *Int J Cardiol* 1998;65:1-9.
  85. Sharma SK, Duvvuri S, Dangas G. Rotational atherectomy for in-stent restenosis: acute and long-term results of the first 100 cases. *J Am Coll Cardiol* 1998;32:1358.
  86. Lee SG, Lee CW, Cheong SS, et al. Immediate and long-term outcomes of rotational atherectomy versus balloon angioplasty alone for the treatment of diffuse in-stent restenosis. *Am J Cardiol* 1998;82:140.
  87. vom Dahl J, Radke PW, Haager PK, et al. Clinical and angiographic predictors of recurrent restenosis after percutaneous transluminal rotational atherectomy for treatment of diffuse in-stent restenosis. *Am J Cardiol* 1999;83:862.
  88. Linsker R, Srinivasan R, Wynne JJ, Alonso DR. Far-ultraviolet laser ablation of atherosclerotic lesions. *Laser Surg Med* 1984;4:201.
  89. Clarke R, Isner JM, Donaldson RF, Jones GI. Gas chromatography light microscopic correlation of excimer laser photoablation of cardiovascular tissues: evidence for a thermal mechanism. *Circ Res* 1987;60:429.
  90. Isner JM, Rosenfield K, White CJ, et al. *In vivo* assessment of vascular pathology resulting from laser irradiation: analysis of 23 patients studied by directional atherectomy immediately after laser angioplasty. *Circulation* 1992;85:2185.
  91. Bonner R, Smith PD, Prevosti LD, Leon MB. New sources for laser angioplasty: Er:YAG, excimer lasers, and nonlaser hot-tip catheters. In: Vogel JHK, King SB III, eds. *Interventional cardiology: future directions*. St Louis: Mosby, 1989:101.
  92. Appelman YE, Piek JJ, Verhoofstad GG, Gijsbers GH, Van Gemert MJ. Tissue ablation and gas formation of two excimer laser systems: an *in vitro* evaluation on porcine aorta. *Lasers Surg Med* 1996;18:197.
  93. Stone GW, de Marchena E, Dageforde D, et al. Prospective, randomized, multicenter comparison of laser-facilitated balloon angioplasty versus stand-alone balloon angioplasty in patients with obstructive coronary artery disease. The Laser Angioplasty Versus Angioplasty (LAVA) Trial Investigators. *J Am Coll Cardiol* 1997;30:1714.
  94. Appelman YE, Koolen JJ, Piek JJ, et al. Excimer laser angioplasty versus balloon angioplasty in functional and total coronary occlusions. *Am J Cardiol* 1996;78: 757.
  95. Litvack F, Eigler N, Margolis J, et al. Percutaneous excimer laser coronary angioplasty: results in the first consecutive 3,000 patients. *J Am Coll Cardiol* 1994; 23:323.
  96. de Marchena EJ, Mallon SM, Knopf WD, et al. Effectiveness of holmium laser-assisted coronary angioplasty. *Am J Cardiol* 1994;73:117.
  97. Holmes DR Jr, Reeder GS, Ghazzal ZMB, et al. Coronary perforation after excimer laser coronary angioplasty: the Excimer Laser Coronary Angioplasty Registry experience. *J Am Coll Cardiol* 1994;23:330.
  98. Baumbach A, Bittl JA, Fleck E, et al. Acute complications of coronary excimer laser angioplasty: analysis of two multicenter registries. *J Am Coll Cardiol* 1994; 23:1305.
  99. Tchong JE, Wells LD, Phillips HR, Deckelbaum LI, Golobic RA. Development of a new technique for reducing pressure pulse generation during 308 nm excimer laser coronary angioplasty. *Cathet Cardiovasc Diagn* 1995;34:15.
  100. Bittl JA, Kuntz RE, Estella P, Sanborn TA, Baim DS. Analysis of late lumen narrowing after excimer laser-

- facilitated coronary angioplasty. *J Am Coll Cardiol* 1994;23:1314.
101. Bitl JA, Sanborn TA, Tchong JE, Watson LE. Excimer laser-facilitated angioplasty for undilatable coronary lesions: results of a prospective, controlled study. *Circulation* 1993;88:1-23 (abst).
  102. Holmes DR Jr, Forrester JS, Litvack F, et al. Chronic total obstruction and short-term outcome: the excimer laser angioplasty registry experience. *Mayo Clin Proc* 1993;68:5.
  103. Schofer J, Kresser J, Rau T, et al. Recanalization of chronic coronary artery occlusions using laser followed by balloon angioplasty. *Am J Cardiol* 1996;78:836.
  104. Oesterle SN, Bitl JA, Leon MB, et al. Laser wire for crossing chronic total occlusions: "learning phase" results from the U.S. TOTAL trial. Total Occlusion Trial with Angioplasty by using a laser wire. *Cathet Cardiovasc Diagn* 1998;44:235.
  105. Hamburger JN, Gijbsers GH, Ozaki Y, et al. Recanalization of chronic total coronary occlusions using a laser guide wire: a pilot study. *J Am Coll Cardiol* 1997;30:649.
  106. Hamburger JN, Serruys PW, Scabra-Gomes R, et al. Recanalization of total coronary occlusions using a laser guidewire (the European TOTAL Surveillance Study). *Am J Cardiol* 1997;80:1419.
  107. Cook SL, Eigler NL, Shefer A, Goldenberg T, Forrester JS, Litvack F. Percutaneous excimer laser coronary angioplasty of lesions not ideal for balloon angioplasty. *Circulation* 1991;84:632.
  108. Cannon AD, Roubin GS, Hearn JA, et al. Acute angiographic and clinical results of long balloon percutaneous transluminal coronary angioplasty and adjuvant stenting for long narrowings. *Am J Cardiol* 1994;73:635.
  109. Appelman YEA, Piek JJ, Strikwerda S, et al. Randomized trial of excimer laser versus balloon angioplasty for the treatment of obstructive coronary disease. *Lancet* 1996;347:79.
  110. Koster R, Hamm CW, Seabra-Gomes R, et al. Laser angioplasty of restenosed coronary stents—results of a multicenter surveillance trial. *J Am Coll Cardiol* 1999;34:25.
  111. Mehran R, Mintz GS, Satler LF, et al. Treatment of in-stent restenosis with excimer laser coronary angioplasty: mechanisms and results compared with PTCA alone. *Circulation* 1997;96:2183.
  112. Mizuno K, Satomura K, Miyamoto A, et al. Angioscopic evaluation of coronary-artery thrombi in acute coronary syndromes. *N Engl J Med* 1992;326:287.
  113. Sherman CT, Litvack F, Grundfest WS, et al. Coronary angiography in patients with unstable angina pectoris. *N Engl J Med* 1986;315:913.
  114. Ambrose JA, Weinrauch M. Thrombosis in ischemic heart disease. *Arch Intern Med* 1996;156:1382.
  115. Hartmann JR, McKeever LS, Stamato NJ, et al. Recanalization of chronically occluded aortocoronary saphenous vein bypass grafts by extended infusion of urokinase: initial results and short-term clinical follow-up. *J Am Coll Cardiol* 1991;18:1517.
  116. Bell C, Kern MJ, Kaiser G. Sequential proximal and distal infusion of urokinase resulting in recanalization of acutely occluded aortocoronary bypass graft after coronary angioplasty. *Cathet Cardiovasc Diagn* 1992;26:224.
  117. Chapekis AT, George BS, Candela RJ. Rapid thrombus dissolution by continuous infusion of urokinase through an intracoronary perfusion wire prior to and following PTCA: results in native coronaries and patent saphenous vein grafts. *Cathet Cardiovasc Diagn* 1991;23:89.
  118. Hartmann JR, McKeever LS, et al. Recanalization of Chronically Occluded Aortocoronary Saphenous Vein Bypass Grafts With Long-Term, Low Dose Direct Infusion of Urokinase (ROBUST): a serial trial. *J Am Coll Cardiol* 1997;27:60.
  119. Ambrose JA, Almeida OD, Sharma SK, et al. Adjunctive thrombolytic therapy during angioplasty for ischemic rest angina. Results of the TAUSA trial. TAUSA Investigators. Thrombolysis and Angioplasty in Unstable Angina trial. *Circulation* 1994;90:69.
  120. McKay RG, Fram DB, et al. Treatment of intracoronary thrombus with local urokinase infusion using a new, site-specific drug delivery system: the Dispatch catheter. *Cathet Cardiovasc Diagn* 1994;33:181.
  121. Glazier JJ, Kiernan FJ, et al. Treatment of thrombotic saphenous vein bypass grafts using local urokinase infusion therapy with the Dispatch catheter. *Cathet Cardiovasc Diagn* 1997;41:261.
  122. Mitchel JF, Azrin MA, et al. Inhibition of platelet deposition and lysis of intracoronary thrombus during balloon angioplasty using urokinase-coated hydrogel balloons. *Circulation* 1994;90:1979.
  123. Rousseau H, Sapoval M, et al. Percutaneous recanalization of acutely thrombosed vessels by hydrodynamic thrombectomy (Hydrolyser). *Eur Radiol* 1997;7:935.
  124. Overbosch EH, Pattynama PM, et al. Occluded hemodialysis shunts: Dutch multicenter experience with the Hydrolyser catheter. *Radiology* 1996;201:485.
  125. van Ommen VG, van den Bos AA, et al. Removal of thrombus from aortocoronary bypass grafts and coronary arteries using the 6Fr Hydrolyser. *Am J Cardiol* 1997;79:1012.
  126. van den Bos AA, van Ommen V, Corbeij HM. A new thrombosuction catheter for coronary use: initial results with clinical and angiographic follow-up in seven patients. *Cathet Cardiovasc Diagn* 1997;40:192.
  127. Rillinger N, Gorich J, et al. Short-term results with use of the Amplatz thrombectomy device in the treatment of acute lower limb occlusions. *J Vasc Interv Radiol* 1997;8:343.
  128. Uflacker R, Rajagopalan PR, Vujic I, Stutley JE. Treatment of thrombosed dialysis access grafts: randomized trial of surgical thrombectomy versus mechanical thrombectomy with the Amplatz device. *J Vasc Interv Radiol* 1996;7:185.
  129. Uflacker R, Strange C, Vujic I. Massive pulmonary embolism: preliminary results of treatment with the Amplatz thrombectomy device. *J Vasc Interv Radiol* 1996;7:519.
  130. Uflacker R. Mechanical thrombectomy in acute and subacute thrombosis with use of the Amplatz device: arterial and venous applications. *J Vasc Interv Radiol* 1997;8:923.
  131. Rosenschein U, Roth A, Rassin T, et al. Analysis of coronary ultrasound thrombolysis endpoints in acute myocardial infarction (ACUTE trial). Results of the feasibility phase. *Circulation* 1997;95:1411.

132. Rosenschein U, Gaul G, Erbel R, et al. Percutaneous transluminal therapy of occluded saphenous vein grafts. *Circulation* 1999;99:26.
133. Drasler WJ, Jenson ML, Wilson GJ, et al. Rheolytic catheter for percutaneous removal of thrombus. *Radiology* 1992;182:263.
134. Weisenaunt BK, Baim DS, Kuntz RE, Garcia LA, Ramee SR, Carozza JP. Rheolytic thrombectomy with the Possis AngioJet—technical considerations and initial clinical experience. *J Invas Cardiol* 1999;11:421.
135. Nakagawa Y, Matsuo S, Kiura T, et al. Thrombectomy with AngioJet catheter in native coronary arteries for patients with acute or recent myocardial infarction. *Am J Cardiol* 1999;83:994.
136. Hamburger JN, Serruys PW. Treatment of thrombus containing lesions in diseased vein bypass grafts using the AngioJet Rapid Thrombectomy System. *Herz* 1997;22:318.
137. Ramee SR, Schatz RA, Carozza JP, et al. Results of the VEGAS-I pilot study of the Possis coronary AngioJet thrombectomy catheter. *Circulation* 1996;94:3622.
138. Ramee SR, Baim DS, Popma JJ, et al. A randomized, prospective, multi-center study comparing intracoronary urokinase to rheolytic thrombectomy with the Possis AngioJet catheter for intracoronary thrombus—final results of the VEGAS-2 trial. *Circulation* 1998;98:437.
139. Webb JG, Carere RG, et al. Retrieval and analysis of particulate debris follow saphenous vein graft intervention. *J Am Coll Cardiol* 1999;34:461.



## 25

# Coronary Stenting

Joseph P. Carrozza, Jr. and Donald S. Baim

*Harvard Medical School; Section of Invasive Cardiology, Beth Israel Deaconess Medical Center, Boston, Massachusetts 02215*

Stents are metallic scaffolds that are deployed within a diseased segment of coronary artery to establish and then maintain a widely patent lumen. Just 6 years after the 1994 approval of the balloon-expandable Palmaz-Schatz slotted tube stent in the United States, stents are utilized in upwards of 80% of interventions and have revolutionized catheter-based treatment. Given the rapid evolution in stent design, techniques, and indications, the goal of this chapter is to highlight some of the underlying principles and concepts and to summarize the key trials on which current stent use is based, expecting that many of the nuances of stent design will continue to evolve.

### HISTORICAL PERSPECTIVE

As described in Chapter 23, despite progressive improvement in the results of conventional balloon angioplasty, it remains limited by abrupt vessel closure (which leads to emergency bypass surgery in 1% of patients) and restenosis (which prompts a repeat revascularization procedure in 30% of patients): The attraction of stenting is that it addresses both of these shortcomings.

Although the concept of an endovascular prosthesis to seal dissections and overcome recoil was first proposed by the late Charles Dotter in 1964 (1), the first implantation of stents in human arteries did not occur until 1985, when Sigwart et al. (2) reported the successful placement of self-expanding Wallstents in the peripheral and coronary arteries of eight patients. One year later, however, Serruys (3) reported a much

less favorable multicenter experience using this device, with 18% thrombotic occlusion and 8% mortality at 1 year. However, those patients who did not experience subacute thrombotic occlusion had a 6-month angiographic restenosis rate of only 14%, suggesting for the first time that stenting could reduce angiographic restenosis. This encouraged Gianturco and Roubin (4) to begin work on a balloon-expandable coil stent, which consisted of stainless steel wire wrapped around a deflated balloon in a serpiginous manner. A phase II study began in 1988 using this stent to reverse postangioplasty acute or threatened vessel closure (5), which led to U.S. Food and Drug Administration (FDA) approval in June 1993. Concurrently, Palmaz introduced a balloon-expandable stent in 1984 (6,7), in which rectangular slots were cut into thin-walled stainless steel tubing, so that balloon inflation within the stent deformed these rectangular slots into diamond-shaped windows or cells. The rigidity of this design made it difficult to pass through guiding catheters and tortuous vessels, until 1989 when Schatz (8,9) added a 1-mm central articulation to join two rigid 7-mm segments, creating the Palmaz-Schatz stent. In 1989, enrollment commenced in two randomized multicenter studies—the U.S. Stent Restenosis Study (STRESS) and the European Belgium Netherlands Stent (Benestent) trial (10,11)—comparing balloon angioplasty with *elective* Palmaz-Schatz stenting, which showed a 30% reduction in angiographic restenosis compared with conventional balloon angioplasty. This led to the

1994 FDA approval of the Palmaz-Schatz stent for elective treatment of focal *de novo* lesions in native vessels, 3 to 4 mm in diameter.

Despite the impressive acute and long-term results observed in the STRESS and Benestent trials, widespread application remained limited by the 3% incidence of thrombosis and a significantly higher incidence of hemorrhagic complications and length of hospital stay associated with the draconian anticoagulation regimens employed as prophylaxis against thrombosis (11). In the early 1990s, Colombo and colleagues, using intravascular ultrasound (IVUS), demonstrated that the majority of stents were inadequately expanded despite excellent angiographic appearance (12). By employing routine high-pressure adjunctive dilatation, he and other European investigators showed that such "optimal stenting" reduced the incidence of stent thrombosis to less than 1% to 2% using only aspirin and a second antiplatelet agent, ticlopidine, rather than prolonged warfarin therapy (13). Subsequently, two randomized trials—the German Intracoronary Stenting and Antithrombotic Regimen (ISAR) study (14) and the U.S. multicenter STent Anticoagulation Restenosis Study (STARS) (15)—definitively established the superiority of dual antiplatelet therapy (with aspirin and ticlopidine) over anticoagulation (with warfarin) for prevention of stent thrombosis. Additional trials showed the efficacy of stenting in broader anatomic and clinical situations (beyond focal *de novo* native vessel lesions). With the more effective antiplatelet regimens and expanding indications (16–19), which included saphenous vein bypass grafts, chronic total occlusions, prior restenosis, and acute myocardial infarction (MI), as well as the introduction since 1997 of a wide range of newer stent designs with improved flexibility, visibility, and profile, stent placement is now used in approximately 80% of percutaneous revascularizations.

### STENT DESIGNS

As of 2000, more than 30 stent types have been implanted in the human coronary circula-


tion (Fig. 25.1). Stent types differ in their *composition* (e.g., stainless steel, tantalum, nitinol), *architecture* (e.g., slotted tube, coiled wire), and *mode of implantation* (e.g., self-expanding, balloon-expandable) (Table 25.1). In theory, the perfect coronary stent would be made of a relatively nonthrombogenic material and have sufficient flexibility in its unexpanded state to allow passage through guiding catheters and tortuous vessels. Despite its flexibility and low profile in the collapsed state, it should have an expanded configuration that provides uniform scaffolding of the vessel wall with low recoil and maximal radial strength. In addition, the stent should be sufficiently radioopaque to allow fluoroscopic visualization but not so opaque as to obscure important vascular details. All clinically tested coronary stents have been constructed from metallic alloys, including stainless steel, tantalum, nitinol, and cobalt/platinum. The largest experience has been with stainless steel. Although each stent design is unique, they can be divided into broad categories based on whether they are balloon-expandable or self-expanding, and subcategorized based on architecture (e.g., coil, tube, hybrid tube-coil).

#### Balloon-Expandable Stents

Balloon-expandable stents are delivered into the coronary artery in their collapsed state, mounted on a delivery balloon. Once in the desired location, inflation of the delivery balloon expands the stent and imbeds it into the arterial wall. Within the balloon-expandable stent category, all stents can be assigned to one of three subgroups, based on construction: wire coils, slotted tubes, and modular designs.

#### Wire Coils

The Gianturco-Roubin FlexStent (Cook Cardiology, Indianapolis, IN) was the initial coil stent prototype. It was constructed by winding stainless steel wire into a serpiginous pattern of reversing loops and then folding that pattern onto a compliant balloon to create an interdigitating coil. Although this device was the first stent to receive FDA approval (in 1993), its me-



**FIG. 25.1.** Ten contemporary stent designs evaluated in humans as of January 2000. **Left to right, top row:** Crown Stent, Minicrown Stent. **Second row:** CrossFlex LC Stent, BX Stent. **Third row:** Duet Stent, NIR Stent. **Fourth row:** Radius Stent, Wallstent. **Bottom row:** GFX stent, BeStent.

chanical deficiencies (e.g., low axial and radial strength and a tendency for plaque to prolapse through large gaps between adjacent loops) largely limited its use to acute or threatened vessel closure. To address these deficiencies, a second-generation Gianturco-Roubin II (GR-II) stent incorporated a longitudinal spine to enhance radial and axial strength. For ease of manufacture, the desired geometry was actually cut from a flat sheet, and small dots of gold solder were placed at each end of the stent to enhance radiographic visualization. Although this design retained the excellent flexibility and deliverability of the original, the GR-II was still troubled

by plaque prolapse and excessive recoil after deployment (up to 30% of cross-sectional area); this must be compensated by intentional oversizing of the delivery balloon (ratio of balloon to artery diameter, about 1.2) (24,25), which may lead to edge dissections or even vessel perforation.

#### *Slotted Tubes*

In the mid 1980s, Palmaz introduced the concept of an endovascular prosthesis whose wall was made of offset rows of rectangular slots, each of which was plastically deformed into a

TABLE 25.1. Stent designs

| Stent                     | Material                     | Radioopacity  | Metallic coverage (%) | Strut thickness (inches) |
|---------------------------|------------------------------|---------------|-----------------------|--------------------------|
| <b>Balloon-expandable</b> |                              |               |                       |                          |
| Slotted tubes             |                              |               |                       |                          |
| Palmaz-Schatz             | Stainless steel              | Low-moderate  | ~20                   | 0.0025                   |
| Palmaz-Schatz Crown       | Stainless steel              | Low-moderate  | ~20                   | 0.0025                   |
| MultiLink                 | Stainless steel              | Low           | ~15                   | 0.002                    |
| Duet                      | Stainless steel              | Moderate      | ~15                   | 0.005                    |
| NIR                       | Stainless steel              | Low-moderate  | 11-18                 | 0.004                    |
| Paragon                   | Nitinol                      | Moderate      | 20                    | 0.006                    |
| BeStent                   | Stainless steel              | Moderate      | 15-18                 | 0.004                    |
| DivYsio                   | Stainless steel <sup>a</sup> | Moderate      | 12-15                 | 0.002-0.003              |
| Pura                      | Stainless steel              | Moderate      | 10-15                 | 0.005                    |
| Tenax                     | Stainless steel <sup>b</sup> | Low-moderate  | ~14                   | 0.003                    |
| <b>Coil</b>               |                              |               |                       |                          |
| Gianturco-Roubin Flex     | Stainless steel              | Moderate      | ~15                   | 0.006                    |
| Gianturco-Roubin II       | Stainless steel              | Moderate      | ~16                   | 0.005                    |
| Wiktor                    | Tantalum                     | High          | ~7-9                  | 0.005                    |
| Freedom                   | Stainless steel              | Moderate      | 10-15                 | 0.007                    |
| Angiostent                | Platinum/iridium             | High          | 9-12                  | 0.005                    |
| <b>Modular-Hybrid</b>     |                              |               |                       |                          |
| AVE MicroStent II         | Stainless steel              | Moderate      | 8-17                  | 0.005                    |
| AVE GFX                   | Stainless steel              | Moderate      | <20                   | 0.005                    |
| CrossFlex LC              | Stainless steel              | Moderate      | 18-23                 | 0.005                    |
| XT                        | Stainless steel              | Moderate-high | 15-18                 | 0.006                    |
| Tensum                    | Tantalum <sup>b</sup>        | High          | ~14                   | 0.003                    |
| <b>Self-expanding</b>     |                              |               |                       |                          |
| Wallstent                 | Cobalt with platinum         | Moderate-high | 14                    | 0.004                    |
| Radius                    | Nitinol                      | Moderate      | 20                    | 0.0045                   |

<sup>a</sup> With phosphorylcholine coating.

<sup>b</sup> With hydrogenated silicon carbide coating.

“diamond” during expansion. In their expanded state, these diamonds (like the trusses of a bridge) made the stent relatively resistant to recoil and compression. The initial Palmaz prototypes, however, were relatively rigid and difficult to deliver through angulated guiding catheters or tortuous vasculature. Schatz therefore modified the original Palmaz design by breaking the 15-mm rigid length into two 7-mm segments joined by a 1-mm central articulation. When bare-mounted on an angioplasty balloon by the operator, the Palmaz-Schatz stent proved susceptible to being stripped off the balloon, leading to systemic embolization if the target lesion could not be crossed. To overcome this problem, a protective 5F delivery sheath was introduced in 1990 (Palmaz-Schatz Coronary Stent Delivery System, Cordis Corporation, Miami, FL); this helped to prevent snagging of the stent on coronary irregularities during ad-

vancement and precluded embolization during withdrawal if advancement across the lesion proves unsuccessful. Although this was the design released in 1994 and used for the pivotal randomized trials of stenting, this relatively inflexible stent and its bulky (5F) delivery sheath required large-lumen (more than 0.084-inch) guiding catheters, was difficult to deliver in tortuous anatomy or to distal lesions, and provided suboptimal scaffolding at the articulation site.

In an effort to preserve the radial strength and wall coverage of the tubular design but improve flexibility in the collapsed state, a number of newer (second- and third-generation) slotted-tube stents were developed. These included the modified Palmaz-Schatz geometry of the Crown (Cordis), the MultiLink and Duet (Guidant Corporation, Santa Clara, CA), and the NIR (Medinol, Israel) stent. Each involves laser cutting of a

unique multicellular pattern into a metallic tube, which increases the overall flexibility of the stent by distributing bending throughout the stent length without compromising radial strength or elastic recoil (see later discussion). The newer stents have also been marketed in a broader range of stent lengths (8 to 32 mm) and diameters (2.25 to 6.0 mm) to facilitate stenting of long lesions, small vessels, saphenous vein grafts, and distal lesions. With better balloon materials and techniques for crimping and retaining the stent on the delivery balloon, the concept of a protective sheath has proved unnecessary. All current slotted tube designs are "bare mounted" on a delivery balloon, with deflated profiles smaller than 0.040-in. (1 mm), comparable with the best angioplasty balloons of only a few years ago.

#### *Modular Stents*

Despite enhanced flexibility, even second-generation slotted-tube stents are sometimes difficult to deliver through tortuous and non-compliant vessels. In an effort to enhance flexibility and deliverability without sacrificing the excellent scaffolding of the slotted-tube stents, the modular or hybrid stents are constructed by flexibly joining multiple, short repeating modules to each other. The initial modular stent was the MicroStent (Arterial Vascular Engineering, Santa Rosa, CA), in which 4-mm-long stainless steel corrugated ring subunits were welded to each other. Although this first-generation MicroStent was extremely deliverable, it was limited by low surface coverage and radial strength. Subsequent designs incorporated an elliptorectangular strut profile and reduced the length of the individual modules to 3 mm (Micro II), 2 mm (GFX), and 1.5 mm (S670), with further reductions in crossing profile and increased surface area coverage.

#### *Self-Expanding Stents*

The prototype self-expanding stent—the Wallstent (Boston Scientific, Minneapolis, MN)—is a direct descendent of the first coronary stent used in 1985. It is manufactured from

16 stainless steel wire strands that are woven together to form a mesh tube (Table 25.1; Fig. 25.1). The stent is positioned on the delivery system in its collapsed state, constrained by an outer membrane. Retraction of the membrane allows the stent to reassume its unconstrained (expanded) geometry, which can be reinforced by balloon dilatation within the stent, if necessary. In the original Wallstent design, a double-layer outer membrane rolled over itself during retraction but gave the delivery system a large diameter (5F); this has been replaced by a single-layer sliding membrane in current designs. In an effort to reduce thrombogenicity and the amount by which the stent shortens during delivery, the braiding angle of the mesh wires has also been reduced by approximately 40° (the Less Shortening Wallstent). The present-generation Wallstent (the Magic Wallstent) incorporates a platinum core within the wires (to increase radioopacity), further modification of the braiding angles, and the ability to readvance the delivery sheath to recapture a partially deployed stent.

The Radius stent (Boston Scientific) is a self-expanding nitinol stent that makes use of the shape memory of the nickel—titanium alloy, nitinol. Once baked at high temperature in its expanded diameter, the superelasticity of this material allows it to be compressed to small diameter and constrained by a membrane on the delivery catheter. The stent is placed within the target lesion and the membrane is withdrawn; the stent then springs back to its memory diameter. The advantage of this design over the Wallstent is the fact that minimal shortening takes place during expansion.

Self-expanding stents typically are selected to have an unconstrained diameter that is oversized by 0.50 to 1.0 mm relative to the diameter of the adjacent reference segment. This ensures contact with the vessel wall and increases the expansile force, but final optimization of stent expansion usually requires inflation of an angioplasty balloon within the stent. (The diameter of that balloon must never exceed the unconstrained stent diameter in air.) Although self-expanding stents are extremely flexible and can be delivered through tortuous vessels without risk of dislodgement, the difficulties relating to accurate

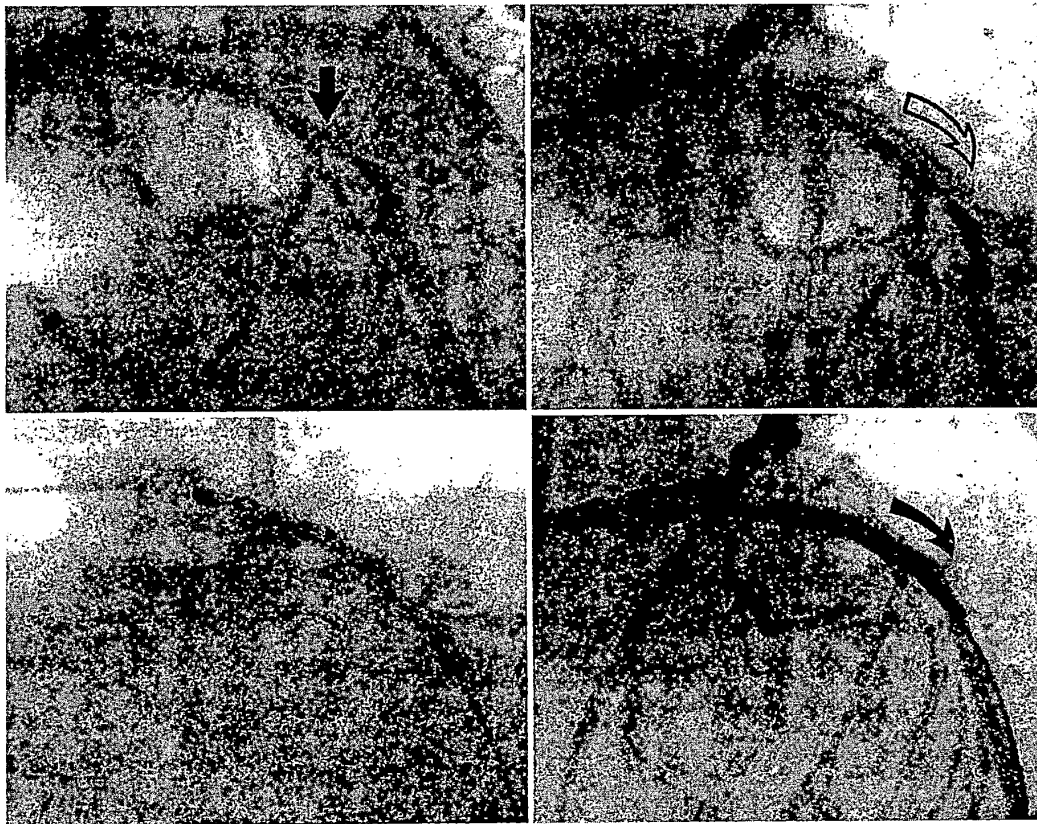
sizing and precise placement necessitate a longer operator "learning curve" and render these stents unsuitable for the treatment of ostial lesions or involved side branches.

### INDICATIONS FOR STENTING


#### Acute or Threatened Closure

Balloon expansion within an arterial stenosis causes luminal enlargement by overall vessel expansion and fracture of atheromatous plaque, but the combination of medial dissection and elastic recoil causes sufficient luminal compromise to culminate in abrupt vessel closure in roughly 5% of lesions treated by balloon angioplasty (see

Chapter 23). One of the major benefits of stenting is the ability to definitively reverse abrupt closure due to dissection and recoil, and thus eliminate the need for high-risk emergency bypass surgery. A 518-patient multicenter registry of the Gianturco-Roubin FlexStent as a definitive treatment for acute or "threatened" vessel closure (local dissection, reduced antegrade flow, or clinical evidence of ongoing ischemia) was conducted from 1988 through 1991 (5) (Fig. 25.2). Although 95% of patients were successfully stented, 7.7% of patients with frank closure (and 2.7% of those with threatened closure) still required surgery, and there was an 8.7% incidence of stent thrombosis, particularly in smaller stents (2.5 mm or less).



**FIG. 25.2.** Early example of placement of a Gianturco-Roubin coil stent for threatened abrupt closure. A long lesion is present in the left anterior descending coronary artery (**upper left**), with a long dissection after angioplasty (**upper right, open arrow**). Placement of a coil stent (**lower left**) results in effacement of the dissection and elimination of the need for emergency bypass (**lower right**).



**FIG. 25.3.** Stenting as definitive treatment for acute vessel closure. A high-grade stenosis is present in an angulated segment of the proximal right coronary artery (*arrow*). After balloon dilatation, a grade F dissection is seen (*middle*). After stent placement, normal flow is restored (*right*).

Two small, randomized trials compared bailout stenting with prolonged inflations with perfusion balloons. In the Trial of Angioplasty and Stents in Canada (TASC II), patients with abrupt or threatened closure were randomly assigned to treatment with a perfusion balloon or stent placement (20). Even though about 25% of the patients assigned to balloon angioplasty crossed over to bailout stenting, the 6-month restenosis rate was significantly lower for stented lesions (22% vs. 50%). In the STENT-BY study, 100 patients were randomly assigned to prolonged balloon inflations or Palmaz-Schatz placement; they showed similar reductions in rate of target vessel revascularization at 6 months (24% vs. 65%) (21). Although bailout stenting is therefore a very effective technique (Fig. 25.3), the exponential growth in *elective* stenting during the past 5 years has left very few vessels that require bailout stenting, as the need for emergency bypass surgery to less than 0.5% between.

#### Elective Stenting of Focal, De Novo Native Coronary Lesions

This indication was used in two landmark studies—STRESS (11) and Benestent I (10)—to establish the ability of the Palmaz-Schatz coronary stent to significantly lower incidence of angiographic and clinical restenosis, compared with balloon angioplasty, in focal *de*

*novo* lesions in 3- to 4-mm native coronary arteries (Table 25.2). These trials also confirmed that this benefit was a result of the ability of the stent to provide a larger acute lumen compared with balloon angioplasty. The strongest predictor of freedom from restenosis was a large posttreatment lumen diameter, and once posttreatment lumen diameter was incorporated into the statistical model of restenosis, there was not any independent effect attributable to the stent itself (22). Other randomized trials comparing stenting with balloon angioplasty (Table 25.2) have consistently demonstrated the superiority of stenting for focal, *de novo* lesions in 3- to 4-mm native coronary arteries.

The superior acute and long-term clinical outcomes reported in the STRESS and Benestent trials heightened the interest in evaluating stenting in other lesion subsets—chronic total occlusions, aortoostial location, and saphenous vein graft lesions—that respond poorly to conventional angioplasty due to marked elastic recoil, a predisposition to dissection, and high restenosis rates. Each of these “non-STRESS/Benestent” lesion categories is reviewed separately below.

#### Saphenous Vein Graft Lesions

The most common cause of recurrent ischemia after coronary artery bypass surgery is

TABLE 25.2. Trials of stenting versus PTCA for de novo lesions in native coronary arteries

| Study Author (ref)                | Major findings    | Stent (%) | PTCA (%) |
|-----------------------------------|-------------------|-----------|----------|
| STRESS, Fischman et al. (11)      | Procedure success | 92        | 85       |
|                                   | Restenosis        | 31        | 42       |
|                                   | TVR               | 14        | 22       |
| Benestent I, Serruys et al. (10)  | Procedure success | 87        | 86       |
|                                   | Restenosis        | 22        | 32       |
|                                   | TVR               | 18        | 27       |
| Benestent II, Serruys et al. (55) | Vascular surg     | 10        | 2        |
|                                   | Procedure success | 96        | 95       |
|                                   | Restenosis        | 16        | 31       |
| LAD, Versaci et al. <sup>a</sup>  | EFS               | 84        | 78       |
|                                   | Procedure success | 95        | 93       |
|                                   | Restenosis        | 19        | 40       |
| TASC I, Penn et al. (30)          | EFS (12 mo)       | 87        | 70       |
|                                   | Major events      | 16        | 14       |
| START, Serra et al. (56)          | Restenosis        | 22        | 37       |
|                                   | TVR               | 11        | 22       |

EFS, event-free survival; PTCA, percutaneous transluminal coronary angioplasty; TVR, target vessel revascularization.

<sup>a</sup> De novo lesions in the left anterior-descending coronary artery. Versaci

atheromatous degeneration within the body of the saphenous vein graft. Balloon angioplasty and atherectomy techniques have high rates of angiographic restenosis (40% to 50%) and long-term clinical failure (23–25), but early single-center registries suggested that stenting of saphenous vein graft lesions had lower rates of angiographic restenosis (17% to 25%) and repeat revascularization of the target site (26,27). This finding was evaluated further in the randomized Saphenous Vein graft Disease (SAVED) trial (28), which compared Palmaz-Schatz stenting with balloon angioplasty for treatment of relatively focal, *de novo* lesions in 3.0- to 5.0-mm saphenous vein grafts. Stenting had greater technical success (residual stenosis less than 50% by QCA, 95% vs. 75%); greater procedural success (technical success in the absence of a major adverse event, 92% vs. 69%); and a lower incidence of adverse clinical events (death, MI, or subsequent revascularization, 26% vs. 38%). Although the angiographic restenosis rates were not statistically different (due to inadequate sample size), the incidence of major adverse events was significantly reduced in stented patients (26% vs. 38%).

The lack of stents that could be expanded beyond 4 mm, however, limited the ability to treat many vein grafts. One option for treatment of large grafts was to use hand-crimped larger Pal-

maz-Schatz biliary stents (Cordis) which could be expanded up to 6 mm (50). With the development of longer stents and those that can be expanded beyond 4 mm (e.g., the Wallstent and the nine-cell NIR stent [Boston Scientific]), vein graft stenting has become easier, although there are still issues relating to “no reflow” and distal embolization (see Chapter 23). Finally, even though the incidence of repeat revascularization triggered by failure of the stented *site* is low (less than 20%), the incidence of clinical events approaches 50% by 5 years owing to progression of disease at nontarget sites within the treated graft, as well as attrition of other grafts and progression of native coronary disease (26).

#### Restenosis After Previous Angioplasty

Retreatment of lesions that have restenosed after previous angioplasty generally has a higher incidence of recurrent restenosis, even after correction for confounding factors such as diabetes mellitus or small reference vessel diameter that might have predisposed to the original restenosis (29). The subset of such patients undergoing treatment of restenotic lesions in the TASC I trial had a significantly lower incidence of repeat revascularization (4.5% vs. 25%) than those in the percutaneous transluminal coronary angioplasty (PTCA) cohort (30). Similarly, the Reste-



nosis Stent Study (REST) randomly assigned 383 patients with prior restenosis to either balloon angioplasty or the Palmaz-Schatz stent and found reductions in angiographic restenosis (18% vs. 32%) and subsequent need for revascularization of the target vessel (10% vs. 27%) with stenting (19). Using aspirin and ticlopidine, Colombo reported an angiographic restenosis rate of 25% with a low (0.8%) incidence of subacute thrombosis in patients with prior restenosis (31).

### Chronic Total Occlusions

Balloon angioplasty of chronically occluded coronary arteries is associated with a high incidence (approximately 50%) of restenosis, reocclusion, and recurrent symptoms, compared with treatment of subtotal stenoses (see Chapter 23). Three randomized trials have compared stenting with conventional balloon angioplasty alone for treatment of chronic total occlusions. In the Stenting in Chronic Coronary Occlusion (SICCO) trial, which compared balloon angioplasty with Palmaz-Schatz stenting for treatment of chronic total occlusion in native coronary arteries, a lower incidence of both angiographic restenosis (32% vs. 74%) and target vessel revascularization (22% vs. 42%) was found with stenting (21,32). The Gruppo Italiano di Studio Stent Nelle Occlusioni Coronariche (GISSOC) trial also showed a lower incidence of restenosis (32% vs. 68%), reocclusion (8% vs. 34%), and target lesion revascularization (5% vs. 22%) in patients assigned to stenting (33). Likewise, in the Total Occlusion Study of Canada (TOSCA), angiographic restenosis and target vessel revascularization were reduced in patients treated with stents compared with conventional angioplasty (34).

### Acute Myocardial Infarction

With the completion of several large registries and randomized trials of acute MI demonstrating better outcomes in patients treated with primary angioplasty rather than thrombolytic therapy, "mechanical reperfusion" has become the preferred treatment for acute MI in many institu-

tions (see Chapter 23). Despite successful initial reperfusion, however, there is a 10% to 15% incidence of reocclusion and a 30% to 50% incidence of restenosis after primary angioplasty (35,36). Although the presence of acute MI was initially considered to be a contraindication to stent placement (because of concerns that this prothrombotic milieu would be associated with an unacceptably high incidence of acute thrombosis), the use of stents to treat suboptimal results and as "upfront" therapy in the treatment of MI has now become widespread. Bauters and colleagues showed that stenting of the infarct-related artery is associated with reduction in the incidence reocclusion (1% vs. 14%) and restenosis (27% vs. 52%) compared with balloon angioplasty (37). Data from several small randomized trials have also suggested that stenting may offer acute and long-term benefits (primarily a reduction in repeat revascularizations) compared with balloon angioplasty alone (38–41) (Table 25.3).

It is less clear that routine stenting of infarct vessels improves already good acute outcomes. The large Stent Primary Angioplasty in Myocardial Infarction (Stent-PAMI) study (balloon angioplasty vs. heparin-coated Palmaz-Schatz stent) randomly assigned 900 patients with acute MI to either PTCA alone or stenting with the heparin-coated Palmaz-Schatz coronary stent. Although patients assigned to stenting had a lower incidence of recurrent ischemia with ST-segment elevation during hospitalization (1.2% vs. 3.5%), angiographic restenosis (12.8% vs. 21.9%), and target vessel revascularization by 6 months (16.3% vs. 20%) (42), they more commonly exhibited reduced posttreatment TIMI flow compared with balloon angioplasty. This question is being evaluated further in the Controlled Abciximab and Device Investigation to Lower Late Angioplasty Complications (CADILLAC), in which patients with acute MI are randomly assigned to stenting (vs. PTCA) and then to abciximab (vs. heparin alone).

### Long Lesions

Lesion length is associated with an increased incidence of acute complications and restenosis after conventional balloon angioplasty, as well

TABLE 25.3. Stenting versus balloon angioplasty in acute myocardial infarction

| Study<br>(reference) | Early MACE  |              | Restenosis  |              | TVR         |              | EFS         |              |
|----------------------|-------------|--------------|-------------|--------------|-------------|--------------|-------------|--------------|
|                      | PTCA<br>(%) | Stent<br>(%) | PTCA<br>(%) | Stent<br>(%) | PTCA<br>(%) | Stent<br>(%) | PTCA<br>(%) | Stent<br>(%) |
| GRAMI (38)           | 12          | 3.8          | —           | —            | 13          | 9.6          | 65          | 83           |
| Suryapranata<br>(39) | —           | —            | —           | —            | 17          | 4.0          | 80          | 95           |
| FRESCO (41)          | 8.0         | 1.0          | 52          | 12           | 25          | 7.0          | —           | —            |

EFS, event-free survival; MACE, major adverse cardiac event; PTCA, percutaneous transluminal coronary angioplasty; TVR, target vessel revascularization.

as directional and rotational atherectomy (43–45). Early randomized trials (e.g., STRESS, Benestent) excluded lesions longer than 15 mm because of the lack of availability of longer stents and the concern that placement of multiple overlapping stents would be associated with a high incidence of subacute thrombosis and restenosis. With the availability of longer stents, improvements in stenting technique, and use of antiplatelet therapy, stenting of longer lesions and diffusely diseased arteries has become a viable option. In the early multicenter registry, lesions treated with multiple Palmaz-Schatz coronary stents had a 65% rate of restenosis (46) and an 8.9% incidence of subacute thrombosis (47). Despite high-pressure dilatation and use of antiplatelet therapy in more than 7,000 patients enrolled in five recently completed stent trials, Cutlip and colleagues found that total stent length was independently associated with stent thrombosis, with an odds ratio of 1.2 for each additional 10 mm of stent placed (48).

The pivotal question remains whether stenting will have any impact on the high rates (more than 50%) of restenosis observed with balloon angioplasty or atheroablative techniques in such lesions. Single-center and registry data suggest an almost linear relation between stent length and restenosis even with contemporary stenting techniques (49). Although total stent length is associated with increased risk for clinical and angiographic restenosis, it is uncertain whether total stent number or the ratios of stent to lesion length also independently affect restenosis. In the multicenter randomized trial comparing the GR-II stent (Cook) to the Palmaz-Schatz stent, the stent-to-lesion ratio was significantly greater

(2.5 vs. 1.9) for patients randomly assigned to the GR-II cohort despite similar baseline lesion lengths, which may have contributed to the higher incidence of restenosis (47% vs. 21%) with that device (50). Similarly, data from Albiro and colleagues suggest that high stent-to-lesion ratios are associated with high rates of restenosis (37% to 40%) in both discreet and long lesions (51). This has led some to advocate the use of “spot stenting,” whereby aggressive balloon angioplasty or rotational atherectomy is performed in diffusely diseased segments and short stents are placed only in areas of high residual plaque burden or residual stenosis exceeding 20% (52). With current devices, it seems that both lesion length and stent length exert an independent effect on subsequent restenosis (53).

#### Small Vessels

Small (less than 3.0 mm) vessels were formally excluded from the early randomized stent trials (8), although a significant number of vessels in both the STRESS and Benestent trials were actually smaller than 3.0 mm by quantitative coronary angiography (most between 2.75 and 3.0 mm). Most trials have suggested a higher incidence of subacute thrombosis and restenosis for stenting in vessels smaller than 3 mm compared with larger vessels. Despite this higher risk, there are emerging data from subgroup analyses of the randomized “stent versus PTCA” trials to suggest that stenting of vessels smaller than 3.0 mm may be associated with better clinical and angiographic outcome compared

**TABLE 25.4.** *Angiographic and clinical outcome of stenting versus balloon angioplasty for small vessels (<3.0 mm)*

| Study<br>(reference) | Binary restenosis (%) |       | TLR (%) |       |
|----------------------|-----------------------|-------|---------|-------|
|                      | PTCA                  | Stent | PTCA    | Stent |
| STRESS (11)          | 55                    | 34    | 27      | 16    |
| Benestent I (10)     | —                     | —     | 41      | 31    |
| START (56)           | 43                    | 24    | —       | —     |
| Benestent II (55)    | 28                    | 19    | —       | —     |

PTCA, percutaneous transluminal coronary angioplasty; START, Stent Versus Angioplasty Restenosis Trial; STRESS, Stent Restenosis Study; TLR, target lesion revascularization.

$p < .05$  for all comparisons of PTCA vs. stent.

with balloon angioplasty (Table 25.4) (10,11,54–56). It must be cautioned, however, that good trials comparing stenting with balloon angioplasty in small vessels (2.0 to 2.7 mm) are lacking, and that the current stent systems for vessels 2.5 mm and smaller are based on the abrupt closure indication rather than elective stenting in these vessels. Finally, there is the unproven hope that stents specifically designed for smaller vessels, such as the MiniCrown (Cordis), may result in benefit from lower metal coverage with correspondingly lower restenosis rates.

#### Aortoostial Lesions

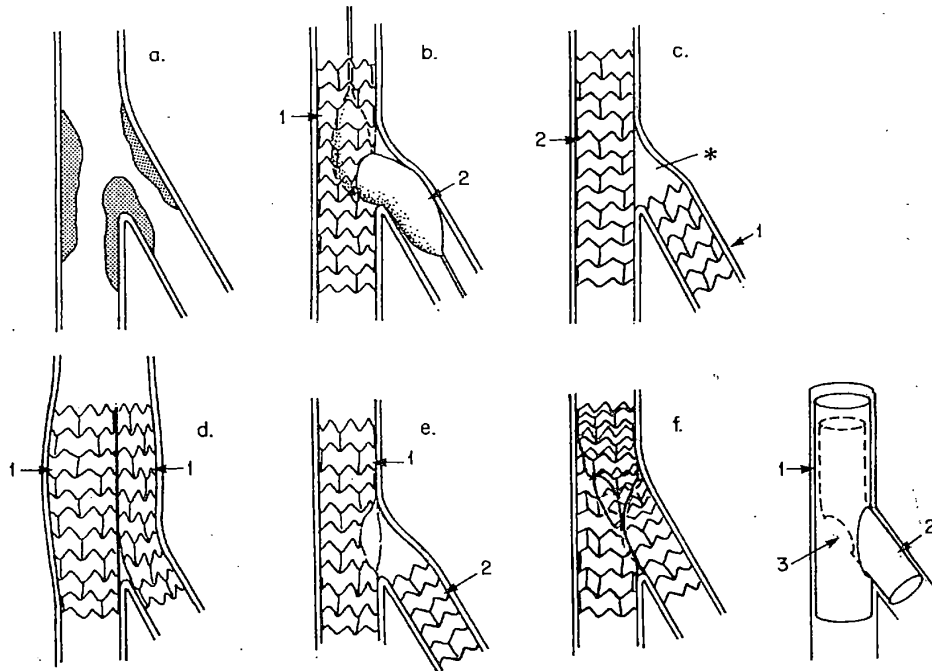
True aortoostial lesions extend proximal to the coronary ostia into the walls of the aorta, where abundant elastic fibers contribute to elastic recoil and poor outcome (57). By resisting recoil, stents may provide significantly larger lumens and lower the risk of restenosis in this lesion subset. Although randomized trials comparing stenting with balloon angioplasty or atherectomy techniques as a treatment for aortoostial lesions have not been performed, Rocha-Singh (58) reported a restenosis rate of 27.8%, and Rechavia (59) a repeat revascularization rate of only 9% after stent placement. Accurate stent placement and expansion in the ostium is often technically challenging, however, because the lesion must be covered completely without excessive protrusion of the stent into the aortic lumen. This is aided by the use of an angiographic projection that shows the coronary ostium and wall of the aorta in profile, by the use

of a radioopaque stent, and by first debulking the lesion with rotational atherectomy (see Chapter 24). These techniques have allowed successful treatment of left main as well as ostial right coronary lesions (60–63), although the risk of restenosis of an “unprotected” left main lesion manifesting as sudden cardiac death is a concern (see Chapter 23).

#### Bifurcation Lesions

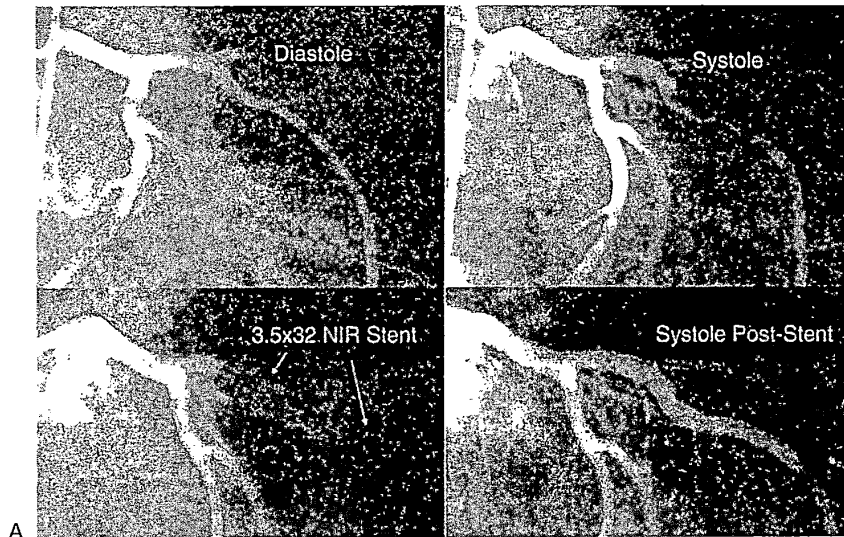
Lesions involving the bifurcation of a coronary artery and a major side branch are associated with increased procedural complications and poor long-term outcome owing to recoil and plaque shifting at the origin of the side branch (64). Dauerman and colleagues (65) demonstrated that atherectomy debulking of such lesions (see Chapter 24) reduces the need for subsequent revascularization, but optimal performance may be technically demanding. Other investigators have explored a number of approaches to stenting of bifurcation lesions (Fig. 25.4). If the parent vessel is large and the side branch is relatively small, a stent can simply be deployed across the side branch, and the compromised side branch can be “rescued” by balloon dilatation out through the wall of the stent, using a low-profile balloon positioned half in the parent vessel and half in the jailed side branch.

When both the parent vessel and the side branch are large (more than 2.5 mm) and involved in the bifurcation lesion, optimal treatment may require stenting of both. With the “T stent” technique, a stent is deployed at the ostium of the side branch, followed by a second

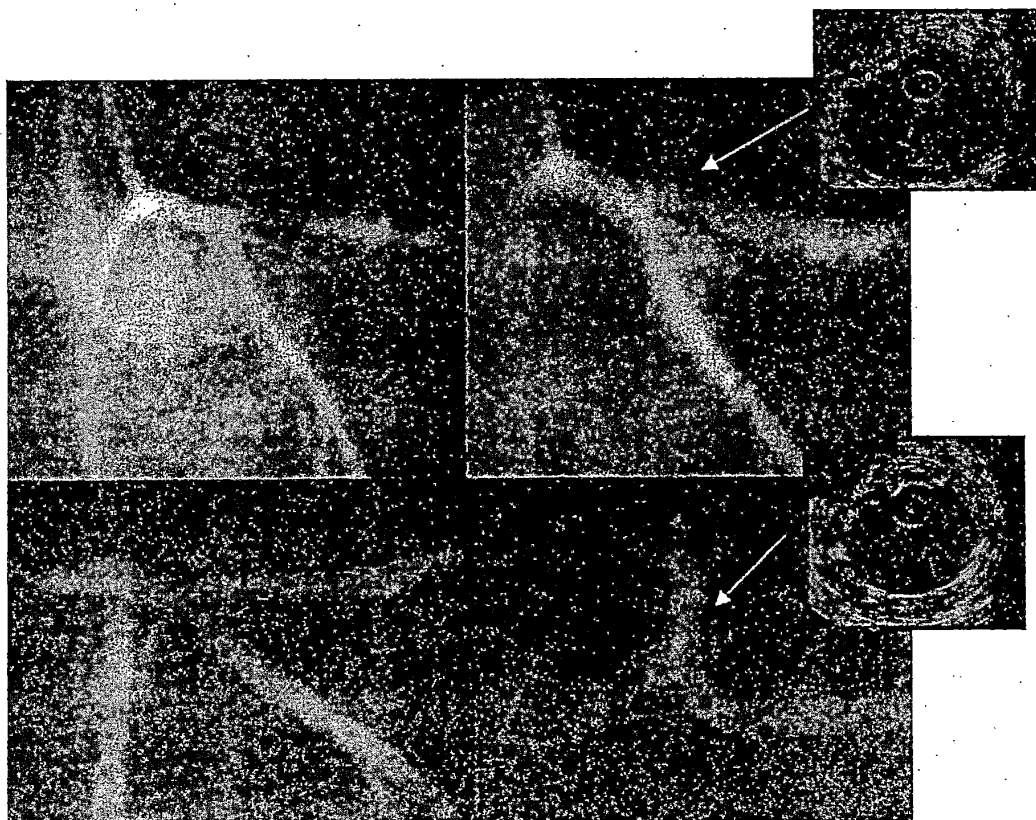


**FIG. 25.4.** Various techniques for stenting bifurcation stenoses. **A:** A typical bifurcation lesion with involvement of both the main vessel and the side branch. **B:** Stenting of the main vessel (1) with side branch rescue by dilatation through the stent struts (2). **C:** T-stent technique with initial placement of a stent in the side branch (1) followed by a second stent (2) in the parent vessel. Note the nonstented gap (\*) caused by a side branch angle less than 90°. **D:** Kissing stents with simultaneous placement of two stents that then run side-by-side in the main vessel proximal to the bifurcation. **E:** Reverse T-stenting with placement of the main vessel stent and rescue as per **B**, but with placement of a second stent (2) into the side branch through the dilated cell of the parent vessel stent. **F:** Culotte stenting, in which the stent is placed in one vessel first (1), the side branch is dilated (as per **B**), and a second stent is placed into the side branch (as per **E**) but extending well into the proximal vessel (2). The procedure is completed (3) by dilating back into the main vessel through the side of the second stent (or with a kissing balloon inflation). None of these techniques is completely reliable, and their complexity and high restenosis rates lead us to favor debulking approaches for most such lesions (see Chapter 24).

**FIG. 25.5.** Unusual applications of stenting. **A:** Stenting of a severe muscle bridge. Upper panels show the left anterior descending (LAD) coronary artery in diastole and compressed in systole. Hemodynamic significance was established by thallium scintigraphy and Doppler flow wire. In the lower panels, systolic compression has been eliminated by placement of a 3.5 × 32 mm NIR stent within the bridged segment. **B:** Stenting as treatment for refractory coronary vasospasm. A young woman developed intermittent chest pain associated with reversible T-wave inversions in the precordial leads despite calcium blockers and nitroglycerin. **Top:** Angiography demonstrated a high-grade stenosis in the proximal LAD (left), which improved after intracoronary nitroglycerin administration (right). **Top, inset:** Intravascular ultrasound revealed moderate, eccentric soft plaque. Angiography and intravascular ultrasound after placement of a Crown stent.



A



B

stent in the parent vessel. Unless the angle of origin of the side branch is 90°, however, the operator is faced with the dilemma of whether it is better to leave a portion of the ostial side branch lesion unstented, or risk having part of the stent protrude into the parent vessel (making subsequent advancement of the parent vessel stent difficult or impossible). The “culotte” technique involves placement of a stent into the side branch with extension into the proximal aspect of the parent vessel. A wire is then passed through the side of this stent and into the distal parent vessel. After balloon dilatation, a second stent is passed into the distal vessel through the side of the first stent, so that the proximal ends of the first and second stents overlap in the proximal vessel. Ideally, this and other bifurcation stent approaches should be finished by “kissing balloon” inflations—simultaneous inflation of balloons in the main and branch vessel—to optimize both lumens (66). Other approaches to stenting of bifurcation lesions include placement of “kissing” stents, whereby stents are simultaneously deployed in the parent vessel and side branch, allowing the operator to shift the “carina” or bifurcation more proximally in the vessel. *All of these techniques are technically difficult and may result in significant difficulty in accessing the parent vessel or side branch because of overlapping metallic elements.* Future purpose-specific bifurcation stents such as the Bifurcate Stent (AVE, Santa Rosa, CA) or the Jostent Bifurcation stent (Jomed International, Helsingborg) may facilitate treatment of this problematic subset and provide more durable long-term results (66a).

#### **Intramyocardial Bridging and Refractory Coronary Vasospasm**

Systolic compression of a coronary artery that courses within the myocardium is a common observation during coronary angiography and occasionally causes myocardial ischemia (see Chapter 13). Using the Doppler flow wire, Klues and colleagues (67) demonstrated that severe myocardial bridging is characterized by abrupt acceleration of diastolic flow velocity, followed by a mid-diastolic plateau, and retrograde systolic flow. In 12 patients, these alterations in

coronary flow were completely normalized and all patients symptomatically improved after stent placement (Fig. 25.5A). Stent placement has also been used successfully to treat coronary vasospasm refractory to vasodilators (68) (Fig. 25.5B).

#### **Multivessel Stenting**

In the past decade, six multicenter, randomized trials compared outcomes after multivessel balloon angioplasty and coronary artery bypass grafting (See Chapter 23) and failed to demonstrate a significant difference in mortality among patients randomly assigned to either mode of revascularization. All of these trials, however, showed a significantly higher incidence of recurrent angina and need for repeat revascularization within the first year after multivessel angioplasty. After multivessel stenting, approximately a 1-year event-free survival rate of 80% has been reported (69–71), and the randomized ARTS trial has confirmed a reduction of roughly 50% in the incidence of excess repeat revascularization procedures, compared with initial surgical treatment, when multivessel stenting is used instead of conventional balloon angioplasty.

#### **COMPARISONS AMONG STENTS**

Approval of the first-generation (Gianturco-Roubin and Palmaz-Schatz) stents was based on the knowledge that they reduced the incidence of emergency surgery for abrupt closure and the rate of restenosis after elective stenting of favorable lesions (see earlier discussion). Once the improved second-generation stent designs were ready for testing (1995–1998), the success of the early stents meant that operators were no longer willing to compare a new stent against balloon angioplasty in a randomized trial. To meet the FDA’s requirement for a randomized pivotal trial, a new “stent versus stent” design was developed to show that a new stent was “equivalent” to the gold-standard Palmaz-Schatz design. A number of such randomized studies—ASCENT (MultiLink), NIRVANA (NIR), SMART (MicroStent II), EXTRA (XT), WINS (Wallstent), PAS (Paragon), SCORES

**TABLE 25.5.** Randomized trials comparing newer coronary stents with the Palmaz-Schatz coronary stent

| Study<br>(reference) | Investigational<br>stent | Restenosis rate (%) |           | Target lesion<br>revascularization (%) |           |
|----------------------|--------------------------|---------------------|-----------|--|-----------|
|                      |                          | PS                  | New stent | PS                                     | New stent |
| ASCENT (71)          | MultiLink                | 21                  | 16        | 11.0                                   | 10.8      |
| NIRVANA (72)         | NIR                      | 21                  | 17        | 9.0                                    | 7.1       |
| GR-II (50)           | GR-II                    | 21                  | 47        | 26.6                                   | 14.6      |
| SCORES (73)          | Radius                   | 19                  | 17        | 9.0                                    | 7.1       |
| EXTRA (74)           | XT                       | 28                  | 35        | 9.0                                    | 8.2       |
| SMART (75)           | Microstent II            | 23                  | 25        | 10.9                                   | 11.2      |

PS, Palmaz-Schatz coronary stent; GR-II, Gianturco-Roubin II stent.

(Radius), and BEST (BeStent)—were performed to compare newer investigational stents with the Palmaz-Schatz coronary stent, using an “equivalency” design (Table 25.5) (71–75). Only the GR-II stent (whose stent recoil, undersizing, and excessive stent length appear to have contributed to higher restenosis rates) failed to show equivalency, but none of the new stents showed significantly better performance than the Palmaz-Schatz stent. In part, this was a result of the inclusion of only lesion types that were stentable with the original Palmaz-Schatz stent. The most technically challenging patient and lesion subsets (e.g., severe calcification and tortuosity), which form such a large part of stent placement in today’s practice, were excluded. This explains why the second-generation stents have completely replaced the Palmaz-Schatz stent in clinical practice since the mid-1997 approval of the MultiLink. Although study-to-study differences in patient and lesion complexity factors preclude direct comparison of one new stent with another, the stent-versus-stent studies have provided a broad database about acceptable stent performance that can be used to develop objective performance characteristics for stent approval, akin to those now used to approve new heart valves.

## COMPLICATIONS OF STENTING

### Thrombotic and Hemorrhagic Complications

Surface charge, surface texture, and surface energy all contribute to the thrombogenic potential of metallic endovascular prostheses. Al-

though all stents attract platelets, they then undergo passivation as proteinaceous material is deposited on metallic surfaces, thereby altering the resting potential of the alloy (76).

At 9 to 12 days after stent placement, a neointima composed of macrophages and  $\alpha$ -actin-negative spindle cells (77) forms over this initial coating and reduces the risk of stent thrombosis.

### Early Experience

Based on animal work, the original stent regimen was a combination of antiplatelet agents (aspirin, dipyridamole, and low-molecular-weight dextran). However, the incidence of stent thrombosis was still 16% to 20% for the early Palmaz-Schatz and Wallstent data (3,9). This prompted the addition of uninterrupted anticoagulation (a transition from intravenous heparin to warfarin therapy sufficient to prolong the prothrombin time to 16 to 18 seconds, for 4 to 8 weeks) in the multicenter Palmaz-Schatz registry and subsequent early randomized trials. Although this regimen reduced the incidence of stent thrombosis to 3%, results were less satisfactory in bailout indication, stenting of small vessels, residual thrombus or dissection after stent placement, presence of inflow or outflow obstruction, incomplete stent expansion, and subtherapeutic anticoagulation (4,5,78–80). And the combination of aggressive antiplatelet and anticoagulation therapies increased the duration of hospitalization (8 vs. 3 days) and increased the incidence of hemorrhagic complica-

tions (14% vs. 3%) compared with balloon angioplasty (10,11).

### Contemporary Experience

A major breakthrough in understanding the pathogenesis of stent thrombosis by Colombo was the demonstration that most stents (approximately 80%) with an excellent angiographic appearance after low-pressure deployment were seen to be incompletely expanded by IVUS (13) (see Chapter 19). Only after high-pressure (18 to 20 atm) dilatation within the stent were full stent expansion and full apposition of struts to the vessel wall observed. Using this strategy of ultrasound-guided high-pressure dilatation, it appeared that antiplatelet therapy alone (with aspirin and ticlopidine) was sufficient to reduce stent thrombosis to less than 1%. This was confirmed in a large, multicenter French registry (81) and in a series of randomized trials (Table 25.6) (14,15,82–84) that demonstrated reduction in subacute thrombosis to 0.6% after optimal stent expansion followed by aspirin and ticlopidine for 4 weeks. In addition, the timing of subacute thrombosis was shortened, from a median of 6 days with coumadin-containing regimens, to 1 to 2 days (84a). The incidence of groin complications, which had fallen with better sheath removal strategies even before the switch away from coumadin (see Chapter 4) was not reduced further, but the length of stay fell

to approximately 2 days with aspirin and ticlopidine therapy.

Ticlopidine, however, has a delayed onset of action (up to 3 days), causes rash and gastric upset in many patients, and is associated with neutropenia in about 1.5% of patients and life-threatening thrombotic thrombocytopenia purpura in a small minority of patients (85). These shortcomings have led many investigators to substitute a related platelet adenosine diphosphate–receptor antagonist (clopidogrel) for ticlopidine. The theoretic advantages of clopidogrel include the ability to achieve a high level of platelet inhibition after an oral loading dose, the absence of a significantly higher incidence of bone marrow suppression compared with aspirin alone, a low incidence of gastrointestinal and dermatologic side effects, and the convenience of once-a-day dosing (86). Moussa and colleagues found no significant difference in the incidence of stent thrombosis or major adverse cardiac events in patients treated with ticlopidine or clopidogrel after stenting (87). However, the incidence of side effects was significantly lower in patients treated with clopidogrel (5.3% vs. 10.6%). Randomized trials comparing outcome in patients treated with ticlopidine versus clopidogrel have failed to show a significant difference between these two agents, and most centers have switched to the better tolerated clopidogrel (88).

One circumstance has remained constant is

**TABLE 25.6.** Randomized trials comparing adjunctive pharmacologic regimens after stenting

| Study (reference)      | Aspirin | Aspirin + ticlopidine | Aspirin + warfarin |
|------------------------|---------|-----------------------|--------------------|
| Stent thrombosis (%)   |         |                       |                    |
| STARS (optimal stents) | 2.9     | 0.5                   | 2.7                |
| ISAR (all)             | —       | 0.8                   | 5.4                |
| ISAR (MI)              | —       | 0.0                   | 9.7                |
| FANTASTIC (all)        | —       | 2.8                   | 3.4                |
| MACE (%)               |         |                       |                    |
| STARS                  | 3.6     | 0.5                   | 2.7                |
| MATTIS (high-risk)     |         | 5.6                   | 11.0               |
| ISAR (all)             |         | 1.6                   | 6.2                |
| ISAR (MI)              |         | 3.3                   | 21.0               |
| FANTASTIC              |         | 13.5                  | 21.0               |

FANTASTIC, Full Anticoagulation versus Aspirin and Ticlopidine Study; ISAR, Intracoronary Stenting and Anti-thrombotic Regimen; MACE, major adverse cardiac events; MATTIS, Multicenter Aspirin and Ticlopidine Trial after Intracoronary Stenting; MI, myocardial infarction; STARS, Stent Anticoagulation Restenosis Study.




that stent thrombosis, when it occurs, causes dire clinical consequences. In the STRESS trial, subacute thrombosis was associated with a 20% mortality rate; all patients had a major complication (either death, Q-wave MI, or emergency bypass surgery) (89). In the contemporary era, the 7,170-patient Cardiovascular Data Analysis Center database shows that 78% of patients with stent thrombosis experienced an acute MI, with a 30-day mortality rate of 15% and a 6-month rate of 19% (48). When thrombosis does occur, recanalization of the occluded stent was possible in 90% of patients by emergency balloon angioplasty or rheolytic thrombectomy (see Chapter 24), often in conjunction with administration of a platelet glycoprotein IIb/IIIa receptor antagonist (90). In patients who are at high risk because of either patient-related factors (e.g., hypercoagulable state, thrombocytosis) or lesion-related factors (e.g., long stents, bifurcation lesions [Fig. 25.6], residual dissection, small vessels, re-

duced final lumen diameter, slow flow), the addition of an intravenous platelet glycoprotein IIb/IIIa receptor antagonist is strongly recommended. In the future, the use of coatings with antithrombotic or antiplatelet activity may further reduce the incidence of stent thrombosis. In four studies, the use of the heparin-coated Palmaz-Schatz coronary stent (Cordis) was associated with a low incidence (0% to 0.8%) of stent thrombosis (18,55,91,92). Further studies must be performed to determine whether these benefits will also be seen when this device is placed for more challenging lesion subsets, such as small vessels or long lesions.

### In-stent Restenosis

Despite overwhelming evidence that stenting reduces restenosis compared with conventional angioplasty alone, the exponential growth in



**FIG. 25.6.** Stent thrombosis 10 days after “T-stenting” the bifurcation of the left circumflex and its obtuse marginal branch (**top, left**). The lesion is crossed with a hydrophilic guidewire and an infusion catheter to establish extent of thrombus and exclude passage under stent struts (**top, center**). The Possis Angiojet is positioned distal to the bifurcation (**top, right**). After aspiration with the Angiojet, antegrade flow is restored and filling defects are no longer apparent (**bottom, left**). However, flow is decreased in the atrioventricular groove portion of the bifurcation (*arrow*). Kissing balloon angioplasty is performed (**bottom, middle**), restoring normal flow in both branches (**bottom, right**).

stent usage has led to new challenges in the treatment of in-stent restenosis. Restenosis after stent placement is caused almost exclusively by smooth muscle hyperplasia (93), superimposed on a small amount of initial recoil. Although this proliferative response peaks at 8 weeks in dogs (94), serial angiographic and angioscopic studies in humans demonstrate that the greatest proliferation occurs between 1 and 6 months after placement, with only a small fraction of stents exhibiting further narrowing between 6 and 12 months (95–97). Thereafter, the proliferating smooth muscle cells are replaced by relatively inactive ground matrix and fibrosis. This transformation of the neointima from active proliferation to a quiescent, fibrotic matrix also explains the extremely low incidence (less than 2%) of late (more than 1 year) target site revascularization observed clinically (98).

#### *Effect of “Optimal” Stenting Techniques*

Although the risk of restenosis after stenting is clearly influenced by biologic factors such as diabetes mellitus and unalterable geometric factors such as small vessel size, there is a clear relationship between the immediate poststent

lumen diameter and the freedom from subsequent restenosis. It is therefore up to the operator to achieve an optimal lumen at the time of stent deployment despite any lesion resistance and elastic recoil. The difficulty in achieving this goal is reflected in the findings of poststent IVUS, which can show poor expansion and apposition of stents that are apparently well deployed angiographically. Achieving an in-stent minimal cross-sectional area equal to at least 55% of the average (proximal/distal) reference cross-sectional area reduces the chance of subsequent restenosis by almost one half, compared with failure to do so (99). Other IVUS criteria have been proposed (see Chapter 19) based on large studies including the Angiography Versus Intravascular Ultrasound Directed Coronary Stent Placement (AVID) trial, the Strategy of ICUS Guided PTCA and Stenting (SIPS) trial, the Optimization with ICUS to Reduce Stent Restenosis (OPTICUS) trial, the Restenosis after IVUS-guided Stenting Trial (RESIST), and the Can Routine Ultrasound Influence Stent Expansion (CRUISE) substudy of the STARS trial. These studies have addressed whether routine use of IVUS guidance is associated with improvements in angiographic and clinical outcome after stenting (Table 25.7). In the RESIST,

**TABLE 25.7.** *Studies of intravascular ultrasound (IVUS)-guided stent placement*

| Study (reference)   | Design           | Major findings  |
|---------------------|------------------|---|
| MUSIC (102)         | Registry         | 81% of lesions met criteria for optimal stenting; larger MLD achieved with IVUS-guidance (compared with Benestent II); very low angiographic (9.7%) and clinical restenosis (4.5%)  |
| RESIST (103)        | Randomized trial | Stent CSA larger with IVUS (7.95 mm <sup>2</sup> ) vs. angiographic (7.16 mm <sup>2</sup> ) guidance; no difference in postprocedure stenosis (19% by angiography vs. 16% by IVUS); no difference in angiographic restenosis (29% by angiography vs. 22% by IVUS) |
| OPTICUS             | Randomized trial | No difference in major adverse cardiac events with IVUS vs. angiographic guidance; no difference in angiographic restenosis   |
| AVID                | Randomized trial | Stent MLD larger with IVUS (3.28 mm) vs. angiographic (2.95 mm) guidance; follow-up pending   |
| CRUISE <sup>a</sup> | Randomized trial | Stent CSA larger with interactive IVUS (7.76 mm <sup>2</sup> ) vs. documentary IVUS (7.11 mm <sup>2</sup> ); target vessel revascularization lower with interactive IVUS (8.9%) vs. documentary IVUS (14.8%)  |

AVID, Angiography Versus Intravascular Ultrasound-Directed Stent Placement trial; CRUISE, Can Routine Intravascular Influence Stent Expansion; CSA, cross-sectional area; MLD, minimum lumen diameter; MUSIC, Multicenter Ultrasound Stenting in Coronaries study; OPTICUS, Optimization with ICUS to Reduce Restenosis trial; RESIST, Restenosis after IVUS-guided Stenting Trial.

<sup>a</sup> CRUISE was a substudy of the Stent Anticoagulation Restenosis Study (STARS); sites were assigned to no IVUS, documentary (blinded) IVUS, or interactive IVUS.

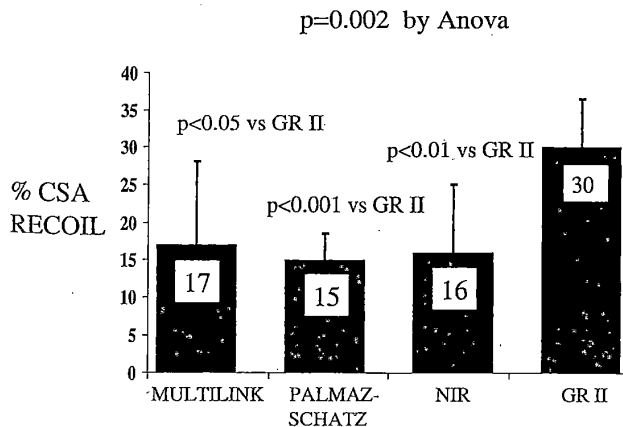
AVID, and CRUISE studies, IVUS-guided stenting was associated with slightly larger stent minimum lumen diameters or cross-sectional areas, but the clinical benefit has been less consistent. Given the added expense and time, formal recommendations regarding routine use of IVUS guidance for stenting cannot be made until the final long-term results from these studies are available and the criteria for optimal stenting are standardized.

One alternative is to perform physiologic assessments of stent deployment, measuring coronary flow reserve or the transstent pressure gradient at peak flow (see Chapter 18). Hanekamp and colleagues showed that a fractional flow reserve of 0.94 or more (measured with a pressure wire) was highly correlated with IVUS-derived parameters of optimal stenting (100). Preliminary observations with coronary flow reserve have also suggested that reduced coronary flow reserve (less than 2.5) after stenting may be associated with major adverse events at 6 months (101).


Despite these measures, 20% to 40% of stents fail to meet criteria for optimal expansion (102,103). Factors contributing to this problem of inadequate stent expansion include balloon underexpansion and acute stent recoil. Although it was originally thought that stents eliminated elastic recoil, more recent data show 7% to 15% diameter recoil after deflation of the deployment

or postdilating balloon (104,105) (Fig. 25.7). To achieve the desired luminal diameter or area, the deployment or postdilating balloon must stretch the stent approximately 10% beyond the desired diameter (e.g., 3.3 mm for a final 3.0 mm result), which is one of the effects produced by inflating a semicompliant balloon to 14 to 16 atm. Contrary to early uncontrolled data, there is no evidence that such high-pressure stent expansion increases the incidence of subsequent restenosis (106), so current practice favors deployment at this pressure level.

In vessels with bulky eccentric or fibrocalcific plaques, balloon underexpansion may account for more than 20% of the discordance between expected and measured balloon cross-sectional area. In such lesions, vascular compliance may be improved by removing plaque from the lesion through pretreatment with high-speed rotational atherectomy (107) (see Chapter 24), thereby lowering the incidence of target vessel revascularization compared with stenting alone (Figs. 25.8 and 25.9). There is also preliminary evidence that debulking of large eccentric plaques with *directional atherectomy* before stenting reduces the amount of in-stent proliferation and lowers the incidence of angiographic restenosis (108,109). These techniques are being evaluated in the randomized SPORT (using rotational atherectomy) and AMIGO (using directional atherectomy) trials.



**FIG. 25.7.** Acute cross-section area (CSA) recoil for four different stents, as measured in normal porcine arteries using a 0.018-inch ultrasound imaging probe within the deployment balloon. (From Carrozza JP Jr, Hosley, SE, Cohen DJ, Baim DS. In-vivo assessment of stent expansion and recoil in normal porcine coronary arteries: Differential outcome by stent design. *Circulation* 1999;100:756, with permission).



**FIG. 25.8.** Rota-stenting. A long, calcified stenosis is present in the left anterior descending coronary artery (**top, left**). After application of the rotational atherectomy burr (**top, right**), a smooth lumen with significant residual stenosis is present (**bottom, left**). After stent deployment, excellent expansion is observed (**bottom, right**). Without Rotablator pretreatment, stent passage and full stent expansion would each have been unlikely.


#### *Pharmacotherapy to Reduce In-stent Restenosis*

A number of agents—including heparin, angiopeptin, angiotensin-converting enzyme inhibitors, and antioxidants—have shown promise in reducing the exuberant proliferative response evoked by stenting in experimental models. However, there are few data available that support their efficacy in reducing the incidence of human in-stent restenosis. Although data from the EPIC trial suggested that the platelet glycoprotein IIb/IIIa receptor antagonist abciximab might be associated with a reduction in restenosis after balloon angioplasty, preliminary observations from the randomized ERASER trial showed no reduction in neointimal volume or restenosis after stenting with abciximab (110). In the larger EPISTENT trial, only diabetic pa-

tients who underwent stenting had a lower incidence of 6-month clinical restenosis events with abciximab (90). Given the difficulty in achieving high tissue concentrations of an agent administered systemically, local delivery may be required to place therapeutic levels of effective agents directly into the arterial wall. However, in neither the HIPS trial (using intraarterial heparin) nor the ITALICS (intraarterial antisense oligonucleotides against *c-myc*) study was active therapy associated with reductions in restenosis after stenting, compared with placebo (111,112).

#### *Treatment of In-stent Restenosis*

Luminal narrowing within stents follows a Gaussian distribution (30). In patients *without* recurrent symptoms or provokable ischemia,



**FIG. 25.9.** Rota-stenting for “protected” left main coronary artery lesion. **Top:** Severe stenosis in the distal left main, which supplies only the left anterior descending coronary artery, given a patent graft to the circumflex (not shown). **Upper center:** 1.75 mm Rotablator burr. **Lower center:** After rotational atherectomy, there is modest lumen improvement but enhanced lesion compliance. **Bottom:** After stent placement, excellent lumen dimension is established.

mild to moderate degrees of in-stent restenosis (40% to 70% diameter stenosis) are associated with a favorable long-term prognosis and therefore can be treated with medical therapy alone (113). When in-stent restenosis results in recurrent coronary ischemia, however, treatment is indicated. The initial experience in treatment of in-stent restenosis involved balloon dilatation within the stent. The procedural success rate was almost 100%, and because the metallic struts were not reexposed to blood elements anticoagulation was not necessary (114), but the rate of recurrent restenosis exceeded 50% for dilatation of diffuse in-stent restenotic lesions (115,116). One reason is that much of the hyperplastic material that has been compressed and extruded through the stent struts returns to the stent lumen within 30 minutes after the final balloon infla-

tion (117). In an effort to improve on the suboptimal long-term results of diffuse in-stent restenosis, several groups have investigated the strategy of plaque removal from within the stent before balloon dilatation, using atheroablative techniques (see Chapter 24). Dauerman (118) and Sharma (119) reported a larger initial lumen and reduction in subsequent target vessel revascularization (from 46% to 26–28%) in lesions treated with rotational atherectomy compared with balloon angioplasty alone. Similar results have also been reported after directional atherectomy (see Chapter 24) or excimer laser angioplasty (120–122). Although controlled, randomized clinical trials using less aggressive debulking and postplacement dilatation have not uniformly confirmed this benefit, the preponderance of evidence favors the concept that strategies incorporating tissue removal (rather than plaque compression alone) result in larger post-treatment lumen diameters and lower rates of target vessel revascularization.

Despite these reductions in repeat revascularizations observed with debulking of in-stent restenosis, almost 30% of these patients require additional interventions to treat this aggressive proliferative response. Because recurrent luminal narrowing after stenting is almost entirely the result of a smooth muscle cellular proliferative process, therapies such as radiation that are effective in the treatment of other benign proliferative disorders (e.g., Graves’ exophthalmos, keloid formation) are particularly attractive. Teirstein demonstrated a marked reduction in angiographic restenosis (17% vs. 54%), target lesion revascularization (12% vs. 45%), and major adverse cardiac events (19% vs. 62%) in patients treated by  $\gamma$ -irradiation with iodine 192 after stent placement (123). These dramatic benefits of  $\gamma$ -irradiation were confirmed in the larger, multicenter Gamma 1 study (124) and the Washington Radiation for In-Stent Restenosis Trial (WRIST) study. The long-term outcome of patients with in-stent restenosis was also favorably influenced by  $\beta$ -radiation with a 47% reduction in angiographic restenosis (46% to 24%), and a 34% reduction in target vessel revascularization (24% to 16%) in the active arm (124a). Although randomized trials of primary

irradiation have not been completed, data from the Beta Energy Restenosis (BERT) trial using an encapsulated strontium 90/yttrium  $\beta$  source (Beta-Cath, Novoste Corporation, Norcross, GA) also suggested a reduction in late loss and restenosis (15%) after balloon angioplasty (125). The effect of primary irradiation on restenosis after initial angioplasty or stenting is currently being studied.

#### Side Branch Occlusion

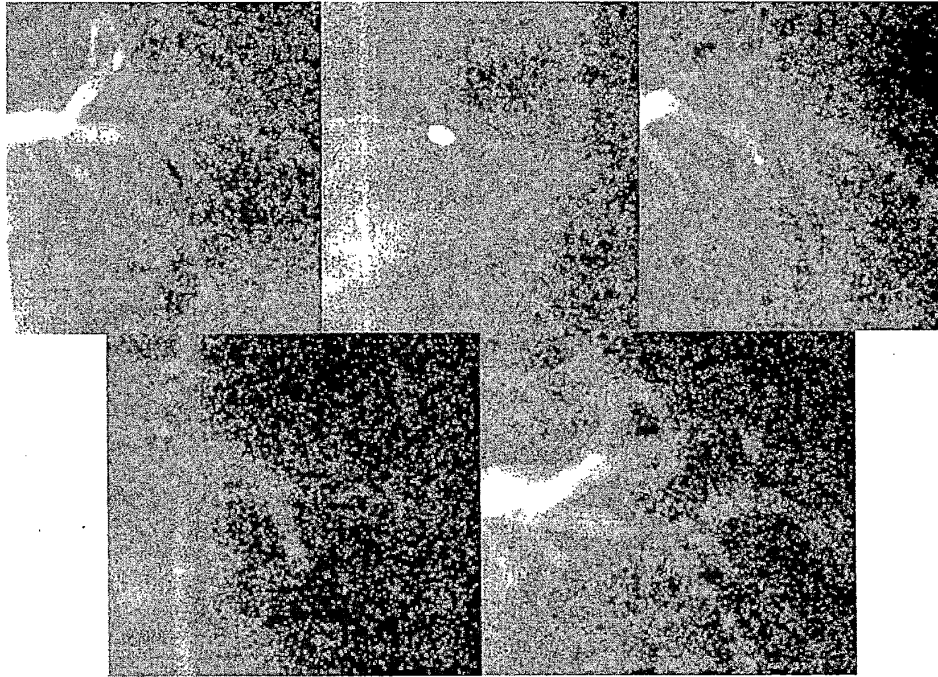
In the early experience with the Palmaz-Schatz stent, Fischman et al. (126) and Iniguez et al. (127) reported a 5% incidence of acute branch occlusion when the stent was placed across a major (more than 1 mm) side branch. In all such cases, ostial stenoses greater than 50% had been present in the involved side branch. Although such side branch occlusion had a low morbidity in these series, it should be noted that stenting across large, diseased side branches was specifically avoided and that stent-induced occlusion of a large side branch clearly may result in significant myocardial ischemia. Because stenting may induce vasospasm in the involved side branch, administration of intracoronary nitroglycerin alone is sometimes adequate to restore normal flow. More commonly, side branch compromise results from the "snowplow" mechanism—shifting of plaque during stent deployment or high-pressure dilatation. If significant ischemia persists, a guidewire can be advanced out through a stent cell and into the effected side branch, to allow advancement of a low-profile angioplasty balloon catheter. The proximal end of the balloon catheter should always be kept in the parent vessel, to avoid the risk of entrapment in the side branch (128). The size of side branch dilatation may be limited by stent cell size (e.g., NIR, Palmaz-Schatz stents), and elastic recoil commonly observed at the origin of side branches may contribute to a high likelihood of repeat restenosis. If restenosis of a "jailed" side branch occurs, rotational atherectomy can safely be performed through the side of previously dilated stent cells to improve acute angiographic appearance (Fig. 25.10).

#### Stent Embolization

In the initial multicenter registry, in which the Palmaz-Schatz coronary stent was hand-mounted on a conventional angioplasty balloon and no sheath was used, stent embolization occurred in 2.5% of patients. There were no reported clinical sequelae (9), but clearly every effort should be made to avoid this complication. Sheathed delivery systems, such as the Palmaz-Schatz Stent Delivery System (Cordis) or the Sheathed MultiLink System (Guidant), reduce the chance of embolization but may impede delivery owing to their large profiles. Present-generation *bare* stents have significantly higher crimp strength and unique attachment features (e.g., NIR on Sox system, Boston Scientific), retentive balloon coatings (e.g., Power Grip balloon, Cordis) or nesting of the stent into the balloon material, which improve stent retention. Nevertheless, virtually any stent may be dislodged from the balloon if it catches on the edge of the guiding catheter during forceful retraction after unsuccessful placement. If guidewire position has been maintained in the distal coronary artery, the delivery balloon or another low-profile balloon may be placed back through the stent, allowing it to be repositioned across the target lesion. If the stent cannot be repositioned, the balloon can be placed distal to the stent and inflated to trap the stent between the balloon and guiding catheter as they are withdrawn into the descending aorta and recovered into the sheath. If guidewire position has been lost and the unexpanded stent is located in a proximal portion of the coronary artery or has embolized into a peripheral artery, it may be removed by use of a variety of snare devices. Alternatively, a second stent may be expanded adjacent to the dislodged stent to trap it against the vessel wall and effectively exclude it from the lumen. If the stent cannot be removed or effectively "excluded" from the coronary lumen, strong consideration should be given to referring the patient for coronary artery bypass surgery.

#### Incomplete Expansion

Incomplete stent expansion may result from rupture of the delivery balloon or failure of the



**FIG. 25.10.** Rotational atherectomy of a restenotic branch “jailed” by an NIR stent in the left anterior descending coronary artery (**top, left**). A 2.15-mm Rotablator burr is seen positioned just proximal to the stent (**top, middle**). After rotational atherectomy through the side of the stent, significant luminal enlargement is seen (**top, right**). Kissing balloon angioplasty (**bottom, left**) is performed, resulting in a large lumen in both the left anterior descending and diagonal arteries (**bottom, right**).

balloon to be expanded adequately in calcified or fibrotic vessels. The risk of incomplete expansion is significantly higher during “primary stenting,” when the operator deploys a stent without predilatation or debulking. This practice is therefore best avoided in heavily calcified vessels or when deploying long stents. In such vessels, full stent expansion may be achieved at lower balloon pressures when the vessel is pretreated with rotational atherectomy.

When the delivery balloon ruptures before the stent is embedded adequately in the vessel wall, further expansion can be achieved by rapidly increasing pressure within the balloon using a power injector or a conventional manual inflation device. A new noncompliant balloon can then be placed within the stent to achieve full expansion. If the stent is markedly underexpanded at the end of the procedure, the administration of a platelet glycoprotein IIb/IIIa receptor antagonist may reduce the risk of stent thrombosis.

### Perforation

Although the routine use of high-pressure postplacement dilatation improves stent expansion, the significant barotrauma imparted to the vessel may result in frank perforation (129). In a retrospective analysis, Ellis and colleagues documented a 0.1% incidence of perforation (130). Colombo showed that high-pressure dilatation of appropriately sized balloons (balloon-artery ratio, 1.1) is safe but that the use of markedly oversized balloons (ratio, 1.2) carries a risk of perforation and vessel rupture of 1.2% to 0% (13). Most small perforations can be sealed with prolonged balloon inflations and reversal of anticoagulation with protamine, unless a platelet glycoprotein IIb/IIIa receptor antagonist has been given. In the event of a large perforation, or when balloon dilatation is unsuccessful in sealing the leak, pericardial tamponade may ensue. The operator must be prepared to block the involved vessel with an angioplasty balloon,

to perform emergency pericardiocentesis, and to obtain cardiac surgical consultation. In the future, deployment of a covered stent may provide reliable sealing and obviate the need for emergency surgery.

### Infectious Endarteritis

Placement of a foreign body endovascular prosthesis carries a theoretic risk of bacterial endarteritis. In an experimental porcine model, after transient bacteremia, a significant number of recently placed coronary stents cultured positive for bacteria (131). In the early stenting experience, all patients received 48 hours of antibiotic prophylaxis during and after stent placement. Because the risk of suppurative endarteritis in stented coronary arteries is extremely rare, with only three documented cases in the literature (132–134), periprocedural antibiotic therapy is no longer recommended. However, if sterile technique has been breached, or if the patient requires an invasive procedure associated with transient bacteremia during the first 4 weeks after stenting, antibiotic prophylaxis should still be strongly considered.

### Cost

In the present era of cost-consciousness, new technologies that affect not only clinical outcome but also resource utilization have come under intense scrutiny. There is no better example than coronary stenting, where the cost of a single stent (approximately \$1,200) may exceed that of an angioplasty balloon by a factor of 4. In two early, single-center observational studies, stenting was associated with significantly higher initial hospital costs than other modalities of catheter-based revascularization. Cohen and colleagues (135) compared the costs of stenting and balloon angioplasty for patients treated in the STRESS trial and found that the initial hospital costs of Palmaz-Schatz stenting exceeded those of balloon angioplasty by \$2,200 (based on a stent price of \$1,400). Despite significant cost savings from the reduction in subsequent hospitalizations and repeat revascularizations, the overall cost of stenting still exceeded that of

PTCA by \$800 at 1 year. This excess cost may have fallen somewhat with the adoption of optimal stenting techniques, the replacement of warfarin-based regimens with antiplatelet therapy, and the concomitant reductions in length of stay and vascular complications. In the randomized Benestent II trial (in which optimal stenting techniques and dual antiplatelet therapy were used), stenting was still associated with a greater overall cost (\$1,020 higher) than balloon angioplasty at 1 year (55), but it was still *cost-effective* (with an acceptable cost-effectiveness ratio of \$23,600 per quality-adjusted life-year gained) due to the reduction in the need for subsequent procedures (136).

## FUTURE TECHNOLOGY

### Coated Stents

Metallic stents are inherently thrombogenic and also provoke an exuberant hyperplastic response within the first year after deployment. Given these limitations, modifications to the metallic surface to reduce its thrombogenicity and alter the long-term arterial response to injury would be desirable. Most stent coatings are polymers, which can be divided into biodegradable and nonbiodegradable groups (137). Biodegradable polymers such as polyurethane, polyethylene terephthalate, and polyorganophosphazene (138–141) were investigated but were found to provoke intense inflammatory reactions. An example of a nonbiodegradable coating that has been used clinically is Biogold, a 30-nm-thick hydrocarbon layer applied by gas exchange to the Wallstent (138). Other nonbiodegradable coatings that are presently under investigation include phosphorylcholine (DivYsio stent, Biocompatibles, Ltd., Surrey, U.K.), amorphous hydrogenated silicon carbide (Tensum and Tenax stents, Biotronik, Berlin, Germany) (137), diamond-like carbon, and pyrolytic carbon (Carbostent, Sorin BioMedica, Italy) (137a).

### Drug-eluting Stents

In the future, stent coatings may also serve as reservoirs for the local delivery of active anti-



platelet, antithrombotic, and antiproliferative agents. The largest experience to date with a coated stent has been with the heparin-coated Palmaz-Schatz coronary stent, in which heparin molecules are covalently bound by end-point attachment to a polymerized surface. The stent does not elute heparin, but it allows heparin to function as an "in situ" catalyst for activation of antithrombin III. Low rates of thrombosis have been observed in the four large studies using this device (18,55,91,92), without any demonstrable antiproliferative effect.

The other approach is to use biodegradable polymers to slowly release pharmacologically active agents. Animal studies have demonstrated that drugs such as forskolin (142) and dexamethasone (143), when embedded into a polymer matrix, can be incorporated into the arterial wall at concentrations several orders of magnitude higher than serum levels. Although the notion of a "therapeutic stent" is attractive, significant hurdles remain, such as identifying appropriate therapeutic agents and noninflammatory polymers, as well as defining optimal delivery kinetics and dosage. Finally, stents may be seeded with cells that secrete biologically active proteins (144).

#### Radioactive Stents

Fischell and colleagues (145) showed that stent wires impregnated with a  $\beta$  emitter (phosphorus 32) inhibited subsequent growth and migration of cultured smooth muscle cells. The concept of a radioactive stent offers several theoretic advantages over other methods of endovascular brachytherapy, but clinical trials with the  $^{32}\text{P}$   $\beta$ -emitting Isostent, in which a Palmaz-Schatz coronary stent is impregnated with  $^{90}\text{Sr}$  (half-life, 14 days) (Cordis), have shown mixed results. At low doses (1  $\mu\text{Ci}$  of total radiation), there was no significant reduction in restenosis (146). At higher doses (0.75 to 6.0  $\mu\text{Ci}$ ), hyperplasia within the stent seemed to be reduced but significant luminal narrowing at the edges of the stents—termed "candy wrapper restenosis"—still occurred (147). Whether this problem can be overcome by increasing the dosage

at the edge of the stent or by avoiding balloon injury to this vulnerable area remains to be seen.

#### Covered Stents

The difficulty in coating stents with noninflammatory polymers has led to the investigation of stents covered completely by artificial or natural material. Stefanidis described a technique for sewing thin segments of autologous veins or arteries to a metallic stent (148). The initial clinical experience with these autologous stents in thrombus-containing lesions and degenerated saphenous vein grafts has been encouraging, but the long-term outcome compared with uncovered stents has not been studied prospectively (149,150). A more practical approach has been the use of stents covered by synthetic material. The Jostent (Jomed) Coronary Stent Graft is layer of polytetrafluoroethylene (PTFE) "sandwiched" between two layers of slotted-tube stent (Fig. 25.11). This covered stent has a relatively low crimped profile and may be an ideal choice for sealing perforations, excluding coronary aneurysms, and decreasing distal embolization when stents are placed in friable lesions. Although initial clinical results suggest that the PTFE-covered portions of the stent are largely free of hyperplasia, pharmacologic regimens to

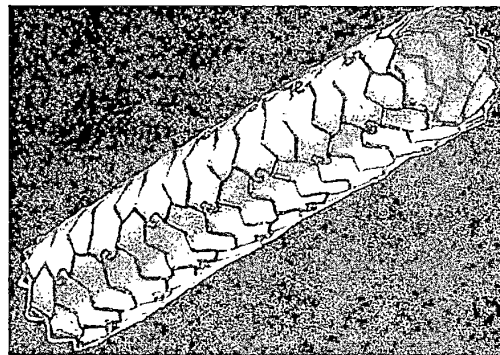


FIG. 25.11. Covered stent. The Jomed Jostent consists of a polytetrafluoroethylene membrane trapped between an inner and an outer Jostent. Such devices are potentially useful in treating vessel perforations, aneurysms, or occluding coronary sinus fistulas.

- sis: Immediate results and longterm outcome. *J Am Coll Cardiol* 1994;23:1296.
27. Wong SC, Popma JJ, Pichard AD, et al. Comparison of clinical and angiographic outcomes after saphenous vein graft angioplasty using coronary versus biliary tubular slotted stents. *Circulation* 1995;91:339.
  28. Savage MP, Douglas JS, Fischman DL, et al. Stent placement compared with balloon angioplasty for obstructed coronary bypass grafts. *N Engl J Med* 1997; 337:740.
  29. Moscucci M, Piana RN, Kuntz RE, et al. Effect of prior coronary restenosis on the risk of subsequent restenosis after stent placement or directional atherectomy. *Am J Cardiol* 1994;73:1147.
  30. Penn IM, Ricci DR, Almond DG, et al. Coronary artery stenting reduces restenosis: Final results from the Trial of Angioplasty and Stents in Canada (TASC) I. *Circulation* 1995;92[Suppl 1]:279a(abst).
  31. Colombo A, Ferraro M, Itoh A, et al. Results of coronary stenting for restenosis. *J Am Coll Cardiol* 1996; 28:830.
  32. Sirnes PA, Golf S, Myreng Y, et al. Sustained benefit of stenting chronic coronary occlusion: Long-term clinical follow-up of the Stenting in Chronic Coronary Occlusion (SICCO) Study. *J Am Coll Cardiol* 1998; 32:305.
  33. Rubartelli P, Niccoli L, Verna E, et al. Stent implantation versus balloon angioplasty in chronic coronary occlusions: Results from the GISSOC trial. *J Am Coll Cardiol* 1998;32:90.
  34. Title LM, Buller CE, Knudtson ML, et al. Efficacy of stenting vs. balloon angioplasty in small diameter (less than 3 mm) total coronary occlusions: A Total Occlusion Study of Canada substudy. *Circulation* 1998; 98[Suppl 1]:639a(abst).
  35. Brodie BR, Grines CL, Ivanhoe R, et al. Six-month clinical and angiographic follow-up after direct angioplasty for acute myocardial infarction. *Circulation* 1994;89:156.
  36. Nakagawa Y, Iwasaki Y, Kimura T, et al. Serial angiographic follow-up after successful direct angioplasty for acute myocardial infarction. *Am J Cardiol* 1996; 78:980.
  37. Bauters C, Lablanche JM, van Belle E, et al. Effects of coronary stenting on restenosis and occlusion after angioplasty of the culprit vessel in patients with recent myocardial infarction. *Circulation* 1997;96:2854.
  38. Rodriguez A, Bernardi V, Fernandez M, et al. In-hospital and late results of coronary stents versus conventional balloon angioplasty in acute myocardial infarction. *Am J Cardiol* 1998;81:1286.
  39. Suryapranata H, van't Hof AW, Hoorntje JC, et al. Randomized comparison of coronary stenting with balloon angioplasty in selected patients with acute myocardial infarction. *Circulation* 1998;97:2502.
  40. Garcia-Canter E, Spaulding C, Corlos T, et al. Stent implantation in acute myocardial infarction. *Am J Cardiol* 1996;77:451.
  41. Antoniucci D, Santoro GM, Bolognese L, et al. A clinical trial comparing primary stenting of the infarct-related artery with optimal primary angioplasty for acute myocardial infarction: Results from the Florence Randomized Elective Stenting in Acute Coronary Occlusions (FRESCO) trial. *J Am Coll Cardiol* 1998;31: 1234.
  42. Grines CI, et al. STENT PAMI: Primary endpoint results of a multicenter, randomized trial of heparin-coated stenting vs. primary PTCA for AMI. *Circulation* 1998;98[Suppl 1]:22a(abst).
  43. Tenaglia AN, Zidar JP, Jackman JD Jr, et al. Treatment of long coronary artery narrowings with long angioplasty balloon catheters. *Am J Cardiol* 1993;71:1274.
  44. Popma JJ, De Cesare NB, Ellis SG, et al. Clinical, angiographic and procedural correlates of quantitative coronary dimensions after directional coronary atherectomy. *J Am Coll Cardiol* 1991;18:1183.
  45. Ellis SG, Popma JJ, Buchbinder M, et al. Relation of clinical presentation, stenosis morphology, and operator technique to the procedural results of rotational atherectomy and rotational-atherectomy facilitated angioplasty. *Circulation* 1994;89:882.
  46. Ellis SG, Savage M, Fischman D, et al. Restenosis after placement of Palmaz-Schatz stents in native coronary arteries: Initial results of a multicenter experience. *Circulation* 1992;86:1836.
  47. Mathew V, Hasdai D, Holmes DR Jr, et al. Clinical outcome of patients undergoing endoluminal coronary artery reconstruction with three or more stents. *J Am Coll Cardiol* 1997;30:676.
  48. Cutlip DE, Baim DS, Ho KKL, et al. Stent thrombosis in the modern era: A pooled analysis of 7,171 patients from multi-center clinical trials conducted by the Cardiovascular Data Analysis Center (CDAC) (*in press*).
  49. Kereiakes D. Duet registry. *Circulation* (*in press*).
  50. Leon MB, Popma JJ, O'Shaughnessy C, et al. Quantitative angiographic outcomes after Gianturco-Roubin II stent implantation in complex lesion subsets. *Circulation* 1997;96[Suppl 1]:653a(abst).
  51. Albiero R, Marsico F, Vaghetti M, et al. The role of lesion length and stent length in restenosis after stenting. *Circulation* 1998;98[Suppl 1]:284a(abst).
  52. DeGregorio J, et al. Intravascular ultrasound guided PTCA with spot stenting. *J Am Coll Cardiol* 1998[Suppl].
  53. Kobayashi Y, DeGregorio J, Kobayashi N, et al. Stented segment length as an independent predictor of restenosis. *J Am Coll Cardiol* 1999;34:651.
  54. Savage MP, Fischman DL, Rake R, et al. Efficacy of coronary stenting versus balloon angioplasty in small coronary arteries: Stent Restenosis Study (STRESS) investigators. *J Am Coll Cardiol* 1998;31:307.
  55. Serruys PW, van Hout B, Bonnier H, et al. Randomised comparison of implantation of heparin-coated stents with balloon angioplasty in selected patients with coronary artery disease (Benestent II). *Lancet* 1998;352: 673.
  56. Serra A, Masotti M, Fernandez-Aviles, et al. Stent vs. Angioplasty Restenosis Trial (START): Influence of vessel size on angiographic restenosis. *Circulation* 1996;94[Suppl]:92a(abst).
  57. Kereiakes DJ. Percutaneous transcatheter therapy of aorto-ostial stenoses. *Cathet Cardiovasc Diagn* 1996; 38:292.
  58. Rocha-Singh K, Morris N, Wong SC, et al. Coronary stenting for treatment of ostial stenoses of native coronary arteries or aortocoronary saphenous venous grafts. *Am J Cardiol* 1995;75:26.
  59. Rechavia E, Litvack F, Macko G, et al. Stent implantation of saphenous vein graft aorto-ostial lesions in patients with unstable ischemic syndromes: Immediate

prevent thrombosis and avoidance of restenosis at the uncovered edges are ongoing issues (151).

### CONCLUSIONS

More than 30 years after Charles Dotter first proposed the concept of an endovascular prosthesis, coronary stenting has emerged as the dominant technology for catheter-based coronary revascularization. The availability of stents with excellent deliverability and scaffolding, the demonstration that stenting improves acute and long-term outcome in a wide variety of lesion types, and the development of effective and better-tolerated regimens to prevent stent thrombosis have facilitated the application of stenting to almost every lesion subset. In the future, stents also have the potential to provide regional arterial delivery of bioactive drugs or radiation to help prevent both thrombosis and subsequent restenosis.

### REFERENCES

- Dotter CT. Transluminally placed coil spring arterial tube grafts: Long-term patency in canine popliteal artery. *Invest Radiol* 1969;4:329.
- Sigwart U, Puel J, Mirkovitch V, et al. Intravascular stents to prevent occlusion and restenosis after transluminal angioplasty. *N Engl J Med* 1987;316:701.
- Serruys PW, Strauss BH, Beatt KJ, et al. Angiographic follow-up after placement of a self-expanding coronary artery stent. *N Engl J Med* 1991;324:13.
- Roubin GS, Robinson KA, King SB III, et al. Early and late results of intracoronary arterial stenting after coronary angioplasty in dogs. *Circulation* 1987;76:891.
- George BS, Voohees III WD, Roubin GS, et al. Multi-center investigation of coronary stenting to treat acute or threatened closure after percutaneous transluminal coronary angioplasty: Clinical and angiographic outcomes. *J Am Coll Cardiol* 1993;22:135.
- Palmaz JC, Windeler SA, Garcia F, et al. Balloon expandable intraluminal grafting of atherosclerotic rabbit aortas. *Radiology* 1986;160:723.
- Palmaz JC, Sibbitt RR, Reuter SR, et al. Expandable intraluminal graft: Preliminary study. *Radiology* 1985;156:73.
- Schatz RA. A view of vascular stents. *Circulation* 1989;79:445.
- Schatz RA, Baim DS, Leon MB, et al. Clinical experience with the Palmaz-Schatz coronary stent: Initial results of a multicenter study. *Circulation* 1991;83:148.
- Serruys PW, de Jaegere P, Kiemeneij F, et al. A comparison of balloon-expandable stent implantation with balloon angioplasty in patients with coronary artery disease. *N Engl J Med* 1994;331:489.
- Fischman DL, Leon MB, Baim DS, et al. A randomized comparison of coronary stent placement and balloon angioplasty in the treatment of coronary artery disease. *N Engl J Med* 1994;331:489.
- Nakamura S, Colombo A, Gaglione A, et al. Intracoronary ultrasound observations during stent implantation. *Circulation* 1994;89:2026.
- Colombo A, Hall P, Nakamura S, et al. Intracoronary stenting without anticoagulation accomplished with intravascular ultrasound guidance. *Circulation* 1995;91:676.
- Schomig A, Neumann FJ, Kastrati A, et al. A randomized comparison of antiplatelet therapy and anticoagulation therapy after placement of coronary artery stents. *N Engl J Med* 1996;334:1084.
- Leon MB, Baim DS, Popma JJ, et al. A clinical trial comparing three antithrombotic-drug regimens after coronary-artery stenting. *N Engl J Med* 1998;339:1665.
- Holmes DR Jr, Hirshfeld J Jr, Faxon D, et al. ACC Expert Consensus Document on Coronary Artery Stents. *J Am Coll Cardiol* 1998;32:1471.
- Sirmes PA, Golf S, Myreng Y, et al. Stenting in Chronic Coronary Occlusion (SICCO): A randomized, controlled trial of adding stent implantation after successful angioplasty. *J Am Coll Cardiol* 1996;28:1444.
- Stone GW, Brodie BR, Griffin JJ, et al. Prospective multicenter study of the safety and feasibility of primary stenting in acute myocardial infarction—in-hospital and 30-day results of the PAMI-Stent pilot trial. *J Am Coll Cardiol* 1998;31:23.
- Erbel R, Haude M, Hopp HW, et al. Coronary-artery stenting compared with balloon angioplasty for restenosis after initial balloon angioplasty. *N Engl J Med* 1998;339:1672.
- Ricci DR, Ray S, Buller CE, et al. Six month follow-up of patients randomized to prolonged inflation or stent for abrupt occlusion during PTCA: Clinical and angiographic data—TASC II. *Circulation* 1995;92[Suppl 1]475a(abst).
- Haude M, Erbel R, Hoeppe HW, and the STENT-BY Study group. STENT-BY Study: A prospective randomized trial comparing immediate stenting versus conservative treatment strategies in abrupt vessel closure or symptomatic dissections during coronary balloon angioplasty. *Eur Heart J* 1996;17[Suppl]:172a(abst).
- Serruys PW, Kay P, Disco C, et al. Procedural quantitative coronary angiography after Palmaz-Schatz stent implantation predicts restenosis rate at six months. *J Am Coll Cardiol* 1999;34:1067.
- Platko WP, Hollman J, Whitlow PL. Percutaneous transluminal angioplasty of saphenous vein graft stenosis: Longterm follow-up. *J Am Coll Cardiol* 1989;14:1645.
- Holmes DR, Topol EJ, Califf RM, et al. A multicenter, randomized trial of coronary angioplasty versus directional atherectomy for patients with saphenous vein bypass graft lesions. *Circulation* 1995;91:1966.
- Bitl JA, Sanborn TA, Yardley DE, et al. Clinical success, complications and restenosis rates with excimer laser coronary angioplasty. *Am J Cardiol* 1992;70:1533.
- Piana RN, Moscucci M, Cohen DJ, et al. Palmaz-Schatz stenting for treatment of focal vein graft stenosis.

- angiographic results and long-term clinical outcome. *J Am Coll Cardiol* 1995;25:866.
60. Lopez JJ, Ho KK, Stoler RC, et al. Percutaneous treatment of protected and unprotected left main coronary stenoses with new devices: Immediate angiographic results and intermediate-term follow-up. *J Am Coll Cardiol* 1997;29:345.
  61. Karam C, Fajadet J, Cassagneau B, et al. Results of stenting of unprotected left main coronary artery stenosis in patients at high surgical risk. *Am J Cardiol* 1998;82:975.
  62. Park SJ, Park SW, Hong MK, et al. Stenting of unprotected left main coronary artery stenoses: Immediate and late outcome. *J Am Coll Cardiol* 1998;31:37.
  63. Ellis SG, Tamai H, Nobuyoshi M, et al. Contemporary percutaneous treatment of unprotected left main coronary stenoses: Initial results from a multicenter registry analysis 1994–1996. *Circulation* 1997;96:3867.
  64. Meier B, Gruentzig AR, King SB 3d, et al. Risk of sidebranch occlusion during coronary angioplasty. *Am J Cardiol* 1984;53:10.
  65. Dauerman HL, Higgins PJ, Sparano AM, et al. Mechanical debulking versus balloon angioplasty for the treatment of true bifurcation lesions. *J Am Coll Cardiol* 1998;22:1845.
  66. Chevalier B, Glatt B, Royer T, et al. Placement of coronary stents in bifurcation lesions by the “culotte” technique. *Am J Cardiol* 1998;82:943.
  - 66a. Cervinka P, Foley DP, Sabate M, et al. Coronary bifurcation stenting using dedicated bifurcation stents. *Cathet Cardiovasc Intervent* 2000;49:105.
  67. Klues HG, Schwarz ER, vom Dahl J, et al. Disturbed intracoronary hemodynamics in myocardial bridging: Early normalization by intracoronary stent placement. *Circulation* 1997;96:2913.
  68. Kultursay H, H Can L, Payzin S, et al. A rare indication for stenting: Persistent coronary artery spasm. *Heart Vessels* 1996;11:165.
  69. Laham RJ, Ho KK, Baim DS, et al. Multivessel Palmaz-Schatz stenting: Early results and one-year outcome. *J Am Coll Cardiol* 1997;30:180.
  70. Kornowski R, Mehran R, Satler LF, et al. Procedural results and late clinical outcomes following multivessel coronary stenting. *J Am Coll Cardiol* 1999;33:420.
  71. Moussa I, Reiners B, Moses J, et al. A long-term clinical and angiographic outcome of patients undergoing multivessel coronary stenting. *Circulation* 1997;96:3873.
  72. Baim DS, Cutlip DE, Midei M, et al. Acute, 30-day and late clinical events in the randomized parallel-group comparison of the ACS Multi-link coronary stent system and the Palmaz-Schatz stent. *Circulation* 1997;96(suppl 1):1.
  73. Baim DS, Cutlip DE, Lansky AJ, et al. Results of the NIRVANA equivalency trial comparing the NIR Primo stent to the Palmaz-Schatz stent. *Circulation* 1998;98(suppl 1):1.
  74. Heuser R, Kuntz R, Lansky A, et al. Six-month clinical and angiographic results of the START trial. *J Am Coll Cardiol* 1998;31(suppl A):64A.
  75. Han RO, Schwartz RA, Lansky A, et al. Influence of mandated coronary angiography on the target vessel revascularization rate in the SCORES trial. *Circulation* 1998;98[Suppl 1]:499a(abst).
  76. DePalma VA, Baier RE, Ford JW, et al. Investigation of three surface properties of several metals and their relation to blood compatibility. In: Homsy C, Armeniades CD, eds. *Biomaterials for skeletal and cardiovascular applications*. New York: Wiley, 1972:37.
  77. Komatsu R, Ueda M, Naruko T, et al. Neointimal tissue response at sites of coronary stenting in humans: Macroscopic, histologic, and immunohistochemical analyses. *Circulation* 1998;98:224.
  78. Nath FC, Muller DWM, Ellis SG, et al. Thrombosis of a flexible coil stent: Frequency, predictors and clinical outcome. *J Am Coll Cardiol* 1993;21:622.
  79. Haude M, Erbel R, Issa H, et al. Subacute thrombotic complications after intracoronary implantation of Palmaz-Schatz stents. *Am Heart J* 1993;126:15.
  80. Sutton JM, Ellis SG, Roubin GS, et al. Major clinical events after coronary stenting: The multicenter registry of acute and elective Gianturco-Roubin stent placement. *Circulation* 1994;89:1126.
  81. Kattrillon GJ, Morice MC, Benveniste E, et al. Intracoronary stent implantation without ultrasound guidance and with replacement of conventional anticoagulation by antiplatelet therapy. *Circulation* 1996;94:1519.
  82. Bertrand ME, Legrand V, Boland J, et al. Randomized multicenter comparison of conventional anticoagulation versus antiplatelet therapy in unplanned and elective coronary stenting. The Full Anticoagulation Versus Aspirin and Ticlopidine (FANTASTIC) study. *Circulation* 1998;98:1597.
  83. Schomig A, Neumann FJ, Kastrati A, et al. A randomized comparison of antiplatelet and anticoagulant therapy after the placement of coronary-artery stents. *N Engl J Med* 1996;334:1084.
  84. Urban P, Macaya C, Rupprecht HJ, et al. Randomized evaluation of anticoagulation versus antiplatelet therapy after coronary stent implantation in high-risk patients: The Multicenter Aspirin and Ticlopidine Trial after Intracoronary Stenting (MATTIS). *Circulation* 1998;98:2126.
  - 84a. Wilson SH, Rihal CS, Bell MR, et al. Timing of coronary stent thrombosis in patients treated with aspirin and ticlopidine. *Am J Cardiol* 1999;83:1006.
  85. Bennett CL, Weinberg PD, Rosenberg BK, et al. Thrombotic thrombocytopenia purpura associated with ticlopidine. *Ann Intern Med* 1998;128:541.
  86. Quinn MJ, Fitzgerald DJ. Ticlopidine and clopidogrel. *Circulation* 1999;100:1667.
  87. Moussa I, Oetgen M, Roubin G, et al. Effectiveness of clopidogrel and aspirin versus ticlopidine and aspirin in preventing stent thrombosis after coronary stent implantation. *Circulation* 1999;99:2364.
  88. CLASSICS, presented in late-breaking clinical trials. 48<sup>th</sup> Annual Scientific Session of the American College of Cardiology, March 1999.
  89. Shaknovich A, Moses JW, Bailey S, et al. Subacute stent thrombosis in the Stent Restenosis Study (STRESS): Clinical impact and predictive factors. *Circulation* 1994;90:650A.
  90. The EPISTENT Investigators. Randomised controlled trial to assess safety of coronary stenting with use of abciximab. *Lancet* 1998;352:85.
  91. Serruys PW, Emanuelsson H, van der Giessen W, et al. Heparin-coated Palmaz-Schatz stents in human coronary arteries: Early outcome of the Benestent-II Pilot Study. *Circulation* 1996;93:412.

92. Stone GW, Brodie BR, Griffin JJ, et al. Prospective, multicenter study of the safety and feasibility of primary stenting in acute myocardial infarction: In-hospital and 30-day results of the PAMI stent pilot trial. Primary Angioplasty in Myocardial Infarction Stent Pilot Trial Investigators. *J Am Coll Cardiol* 1998;31:23.
93. Gordon PC, Gibson CM, Cohen DJ, et al. Mechanisms of restenosis and redilatation within coronary stents: Quantitative angiographic assessment. *J Am Coll Cardiol* 1993;21:1166.
94. Mintz GS, Popma JJ, Hong MK, et al. Intravascular ultrasound to discern device-specific effects and mechanisms of restenosis. *Am J Cardiol* 1996;78[Suppl 3A]:18.
95. Asakura M, Ueda Y, Nanto S, et al. Remodeling of in-stent neointima, which became thinner and transparent over 3 years: Serial angiographic and angioscopic follow-up. *Circulation* 1998;97:2003.
96. Kimura T, Nosaka H, Yokoi H, et al. Serial angiography follow-up after Palmaz-Schatz stent implantation: Comparison with conventional balloon angioplasty. *J Am Coll Cardiol* 1993;21:1557.
97. Farb A, Sangiorgi G, Carter AJ, et al. Pathology of acute and chronic coronary stenting in humans. *Circulation* 1999;99:44.
98. Laham RJ, Carozza JP, Berger C, et al. Long-term (4-6 year) outcome of Palmaz-Schatz stenting: Paucity of late clinical stent-related problems. *J Am Coll Cardiol* 1996;28:820.
99. Moussa I, Moses J, DiMario C, et al. Does the specific intravascular ultrasound criterion used to optimize stent expansion have an impact on the probability of stent restenosis? *Am J Cardiol* 1999;83:1012.
100. Hanekamp CE, Koolen JL, Pijls NH, et al. Comparison of quantitative coronary angiography, intravascular ultrasound, and coronary pressure measurement to assess optimum stent deployment. *Circulation* 1999;99:1015.
101. Di Francesco LD, Di Mario C, De Gregorio J, et al. Clinical, angiographic and physiologic predictors of major adverse cardiac events (MACE) after stent implantation. *J Am Coll Cardiol* 1999;33[Suppl A]:12a.
102. de Jaegere P, Mudra H, Figulla H, et al. Intravascular ultrasound-guided optimized stent deployment: Immediate and 6 months clinical and angiographic results from the Multicenter Ultrasound Stenting in Coronaries Study (MUSIC) Study. *Eur Heart J* 1998;19:1214.
103. Schiele F, Meneveau N, Vuilleminot A, et al. Impact of intravascular ultrasound guidance in stent deployment on 6-month restenosis rate: A multicenter, randomized study comparing two strategies-with and without intravascular ultrasound guidance. *J Am Coll Cardiol* 1998;32:320.
104. Bermejo J, Botas J, Garcia E, et al. Mechanisms of residual lumen stenosis after high-pressure stent implantation: A quantitative coronary angiography and intravascular ultrasound study. *Circulation* 1998;98:112.
105. Carozza JP Jr, Hosley SE, Cohen DJ, Baim DS. In-vivo assessment of stent expansion and recoil in normal porcine coronary arteries: Differential outcome by stent design. *Circulation* 1999;100:756.
106. Dirschinger J, Kastrati A, Neumann F, et al. Influence of balloon pressure during stent placement in native coronary arteries on early and late angiographic and clinical outcome. A randomized evaluation of high-pressure inflation. *Circulation* 1999;100:918.
107. Hoffmann R, Mintz GS, Kent KM, et al. Comparative early and nine-month results of rotational atherectomy, stents, and the combination of both for calcified lesions in large coronary arteries. *Am J Cardiol* 1998;81:552.
108. Moussa I, Moses J, Di Mario C, et al. Stenting after Optimal Lesion Debulking (SOLD) Registry: Angiographic and clinical outcome. *Circulation* 1998;98:1604.
109. Prati F, Di Mario C, Moussa I, et al. In-stent neointimal proliferation correlates with the amount of residual plaque burden outside the stent: An intravascular ultrasound study. *Circulation* 1999;99:1011.
110. Ellis SG, Serruys PW, Popma JJ, et al. Can abciximab prevent neointimal proliferation in Palmaz-Schatz stents? The final ERASER results. *Circulation* 1997;96[Suppl 1]:87a(abst).
111. Kutryk MJ, Serruys PW, Bruining N, et al. Randomized trial of antisense oligonucleotide against *c-myc* for the prevention of restenosis after stenting: Results of the Thoraxcenter "ITALICS" trial. *Eur Heart J* 1998;19[Suppl]:659a(abst).
112. Wilensky RL, Tanguay JF, Ito S, et al. The Heparin Infusion Prior to Stenting (HIPS) Trial: Angiographic and IVUS results. *J Am Coll Cardiol* 1998;31[Suppl]:100a.
113. Gordon PC, Friedrich SP, Piana RN, et al. Is 40-70% diameter at the site of previous stenting or directional coronary atherectomy clinically significant? *Am J Cardiol* 1994;74:26.
114. Baim DS, Levine MJ, Leon MB, et al, for the U.S. Palmaz-Schatz Stent Investigators: Management of restenosis within the Palmaz-Schatz coronary stent (the U.S. multicenter experience). *Am J Cardiol* 1993;71:364.
115. Bauters C, Banos JL, Van Belle E, et al. Six-month angiographic outcome after successful repeat percutaneous intervention for in-stent restenosis. *Circulation* 1998;97:318.
116. Kimura T, Tamura T, Yokoi H, et al. Long-term clinical and angiographic follow-up after placement of Palmaz-Schatz coronary stent. *J Interv Cardiol* 1994;7:129.
117. Shiran A, Mintz GS, Waksman R, et al. Early lumen loss after treatment of in-stent restenosis: An intravascular ultrasound study. *Circulation* 1998;98:200.
118. Dauerman HL, Baim DS, Cutlip DE, et al. Mechanical debulking versus balloon angioplasty for the treatment of diffuse in-stent restenosis. *Am J Cardiol* 1998;82:277.
119. Sharma SK, Duvvuri S, Dangas G, et al. Rotational atherectomy for in-stent restenosis: Acute and long-term results of the first 100 cases. *J Am Coll Cardiol* 1998;32:1358.
120. Strauss BH, Umans VA, van Suylen RJ, et al. Directional atherectomy for treatment of restenosis within coronary stents: Clinical, angiographic and histologic results. *J Am Coll Cardiol* 1992;20:1465.
121. Mahdi NA, Pathan AZ, Harrell L, et al. Directional coronary atherectomy for the treatment of Palmaz-Schatz in-stent restenosis. *Am J Cardiol* 1998;82:1345.
122. Mehran R, Mintz GS, Satler LF, et al. Treatment of in-stent restenosis with excimer laser coronary angio-

- plasty: Mechanisms and results compared with PTCA alone. *Circulation* 1997;96:2183.
123. Teirstein PS, Massullo V, Jani S, et al. Catheter-based radiotherapy to inhibit restenosis after coronary stenting. *N Engl J Med* 1997;336:1697.
  124. Leon MB, Teirstein PS, Lansky AJ, et al. Intracoronary gamma radiation to reduce in-stent restenosis: The multicenter Gamma 1 randomized clinical trial. *J Am Coll Cardiol* 1999;33[Suppl A]:19a.
  - 124a. Popma JJ, Heuser R, Suntharalingam M, et al. Late clinical and angiographic outcomes after use of <sup>90</sup>Sr/<sup>90</sup>Y beta-radiation for the treatment of in-stent restenosis. Results from the Stents and Radiation Therapy (START) trial. Presented at the 49<sup>th</sup> Scientific Session of the American College of Cardiology, March 12, 2000.
  125. King SB III, Williams DO, Chougule P, et al. Endovascular  $\beta$ -radiation after coronary balloon angioplasty: Results of the Beta Energy Restenosis Trial (BERT). *Circulation* 1998;97:2025.
  126. Fischman DL, Savage MP, Leon MB, et al. Fate of lesion related side branches after coronary artery stenting. *J Am Coll Cardiol* 1993;22:1641.
  127. Iniguez A, Macaya C, Alfonso F, et al. Early angiographic changes of side branches arising from a Palmaz-Schatz stented coronary segment: Results and clinical implications. *J Am Coll Cardiol* 1994;23: 911.
  128. Caputo RP, Chafizadeh ER, Stoler RC, et al. Stent jail: A minimum-security prison. *Am J Cardiol* 1996;77: 1226.
  129. Alfonso F, Goicolea J, Hernandez R, et al. Arterial perforation during optimization of coronary stents using high-pressure balloon inflations. *Am J Cardiol* 1996;78:1172.
  130. Ellis SG, Ajluni S, Arnold AZ, et al. Increased coronary perforation in the new device era: Incidence, classification, management, and outcome. *Circulation* 1994;90:2725.
  131. Thibodeaux LC, James KV, Lohr JM, et al. Infection of endovascular stents in a swine model. *Am J Surg* 1996;172:151.
  132. Leroy O, Martin E, Prat A, et al. Fatal infection of coronary stent implantation. *Cathet Cardiovasc Diagn* 1996;39:168.
  133. Bouchart F, Dubar A, Bessou JP, et al. *Pseudomonas aeruginosa* coronary stent infection. *Ann Thorac Surg* 1997;64:1810.
  134. Gunter HU, Strupp G, Volmar J, et al. Koronare Stentimplantation: Infektion and Abszedierung mit Letalem Ausgang. *Z Kardiol* 1993;82:521.
  135. Cohen DJ, Krumholz HM, Sukin CA, et al. In-hospital and 1-year economic outcomes after coronary stenting or balloon angioplasty: Results from a randomized clinical trial. *Circulation* 1995;92:2490.
  136. Cohen DJ, Breall JA, Ho KL, et al. Evaluating the potential cost-effectiveness of stenting as a treatment for single-vessel coronary disease: Use of a decision analytic model. *Circulation* 1994;89:1859.
  137. Bertrand OF, Sipehia R, Mongrain R, et al. Biocompatibility aspects of new stent technology. *J Am Coll Cardiol* 1998;32:562.
  - 137a. Antonucci D, Bartorelli A, Valenti R, et al. Clinical and angiographic outcome after coronary arterial stenting with the Carbestent. *Am J Cardiol* 2000;85:821.
  138. Van der Giessen WJ, van Beusekom HM, van Houten CD, et al. Coronary stenting with polymer-coated and uncoated self-expanding endoprostheses in pigs. *Coron Artery Dis* 1992;3:631.
  139. Murphy JG, Schwartz RS, Edwards WD, et al. Percutaneous polymeric stents in porcine coronary arteries: Initial experience with polyethylene terephthalate stents. *Circulation* 1992;86:1596.
  140. van der Giessen W, Lincoff AM, Schwartz R, et al. Marked inflammatory response sequelae to implantation of biodegradable and non-biodegradable polymers in porcine coronary arteries. *Circulation* 1996;94: 1690.
  141. De Scheerder I, Wilczek K, Verbeken E, et al. Biocompatibility of polymer-coated oversized metallic stents implanted in normal porcine coronary arteries. *Atherosclerosis* 1995;114:105.
  142. Lambert TL, Dev V, Rechavia E, et al. Localized arterial wall drug delivery from a polymer-coated removable metallic stent: Kinetics, distribution, and bioactivity of forskolin. *Circulation* 1994;90:1003.
  143. Lincoff A, Furst J, Ellis S, et al. Sustained local delivery of dexamethasone by a novel intravascular eluting stent to prevent restenosis in the porcine coronary injury model. *J Am Coll Cardiol* 1997;29:808.
  144. Dichek DA, Neville RF, Zweibel JA, et al. Seeding of intravascular stents with genetically engineered cells. *Circulation* 1989;80:1347.
  145. Fischell TA, Kharma BK, Fischell DR, et al. Low-dose beta particle emission from stent wires results in complete, localized inhibition of smooth muscle cell proliferation. *Circulation* 1994;90:2956.
  146. Baim DS, Fischell T, Weissman NJ, et al. Short-term (1 month) results of the IRIS feasibility study of a beta-particle emitting radioisotope stent. *Circulation* 1997; 96[Suppl 1]:218a(abst).
  147. Albiero R, De Gregorio J, Kobayashi N, et al. Acute and 6-month follow-up results of <sup>32</sup>P radioactive  $\beta$ -emitting stent implantation in patients with CAD: The Milan BX Dose-response study. *J Am Coll Cardiol* 1999;33[Suppl A]:20a.
  148. Stefanadis C, Toutouzas K, Tsiamis E, et al. Stents wrapped in autologous vein: An experimental study. *Circulation* 1996;28:1039.
  149. Stefanadis C, Tsiamis E, Vlachopoulos C, et al. Autologous vein graft-coated stents for the treatment of thrombus-containing coronary artery lesions. *Cathet Cardiovasc Diagn* 1997;40:217.
  150. Stefanadis C, Toutouzas K, Tsiamis E, et al. Total reconstruction of a diseased saphenous vein graft by means of conventional and autologous tissue-coated stents. *Cathet Cardiovasc Diagn* 1998;43:318.
  151. Elsner M, Britten M, Auch-Schweik W, et al. Distribution of neointimal proliferation in human coronary arteries treated with polytetrafluorethylene stent-grafts. *J Am Coll Cardiol* 1999;33[Suppl A]:17a.