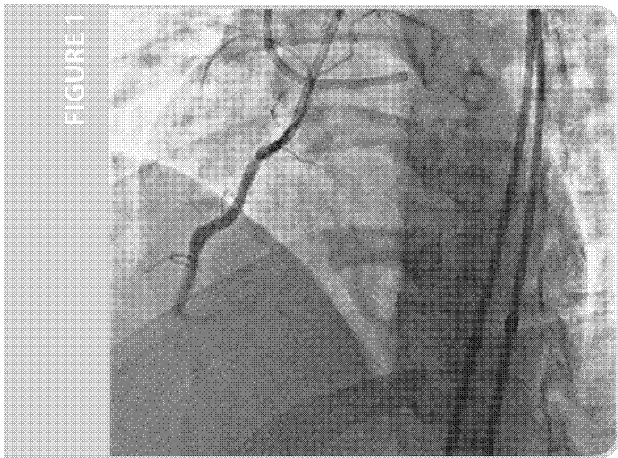

Contemporary Chronic Total Occlusion Percutaneous Coronary Intervention: GuideLiner Catheter and R350 Guidewire Facilitated Reverse-CART

PHYSICIAN

J. Aaron Grantham, MD, FACC, FSCAI
Mid America Heart Institute, Kansas City, MO

PRESENTATION

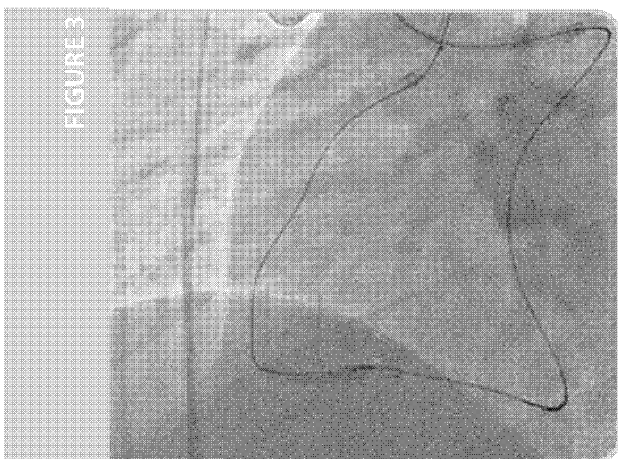
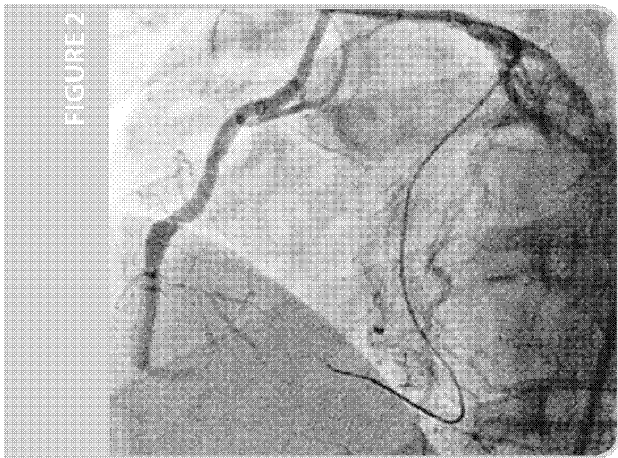
A male with inferior MI two years ago was treated with primary PCI using a drug eluting stent deployed in the mid-right coronary artery (RCA). He presents now to his local cardiologist complaining of exertional shortness of air for the preceding six months. Stress myocardial perfusion imaging demonstrated a large reversible defect in the RCA distribution involving 15% of the myocardium.

INITIAL FINDINGS

Coronary angiography revealed a chronic total occlusion (CTO) of the RCA beyond the previously deployed stent (Figure 1). Attempted percutaneous coronary intervention (PCI) with antegrade wiring was unsuccessful. The occlusion extended past the bifurcation into the RPLV and PDA. He was referred for retrograde CTO-PCI, using the hybrid approach¹.

TREATMENT

The CTO of the RCA was approached with retrograde crossing through a septal collateral from the LAD first septal perforator (Figure 2) using the Corsair® microcatheter and a Sion® wire (both from Asahi-Intecc, Nagoya, Japan). Retrograde dissection and re-entry was performed using the reverse controlled antegrade and retrograde dissection technique (XCART, Figure 3)². After balloon inflation on the antegrade wire (long arrow) the retrograde wire could not be passed into the antegrade true lumen. A GuideLiner catheter was advanced antegrade into the distal RCA over a wire and balloon (Figure 4).



(continued on back)

VSIQXM_E00044654

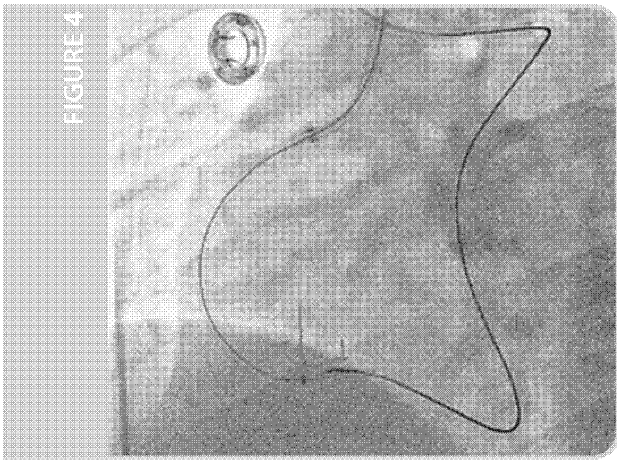


FIGURE 4

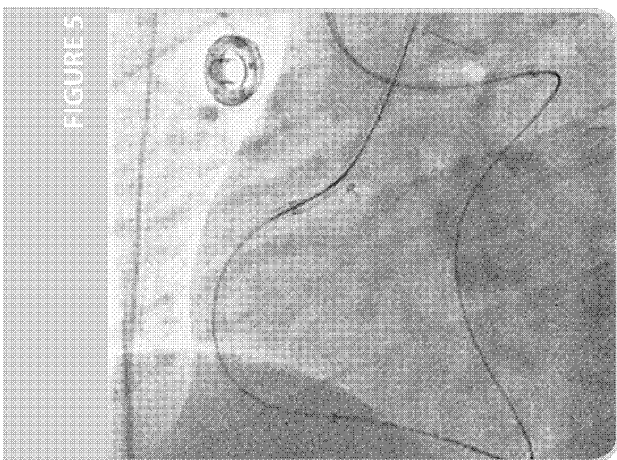


FIGURE 5

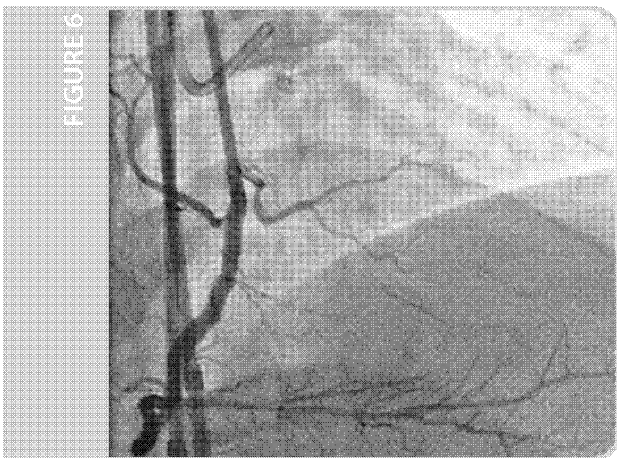


FIGURE 6

TREATMENT CONTINUED

The GuideLiner was intubated (Figure 4, long arrow) with the retrograde wire (Confianza® Pro 12, Asahi-Intecc, Nagoya, Japan) via the Corsair (Figure 4, short arrow). The Corsair (Figure 5, short arrow) was then advanced into the GuideLiner (Figure 5, long arrow) and the Confianza Pro 12 wire removed. An R350 guidewire was passed through the Corsair from the retrograde guide all the way out the antegrade guide and used for antegrade ballooning and stenting with rapid exchange gear. The RPLV branch could not be treated as the retrograde distal cap was ambiguous and could not be penetrated with retrograde wires. Final angiography revealed a large PDA with TIMI-III antegrade flow after deploying a 3.0 x 38mm long drug eluting stent in the distal RCA (Figure 6).

CONCLUSION AND POST PROCEDURE

The patient was dismissed the following day symptom free.

SUMMARY

Vascular Solutions, Inc. has developed a portfolio of useful devices when approaching patients with complex chronic total occlusions. This case demonstrates the utility of the GuideLiner in facilitating reverse CART when re-entry with the retrograde wire is difficult. The R350 guidewire is a stainless steel wire with a 0.013" diameter that can be used as an externalization wire through the Corsair channel dilator for retrograde CTO-PCI.


REFERENCES

- ¹Brilakis E.S., Grantham J.A., et al., (2012). *J. Am. Coll. Card: Cardiovascular Int.*, 5, 368-79.
- ²Saito S., (2008). *Catheter and Cardiovascular Inter.*, F1, 8-19.

J. Aaron Grantham, MD, FACC, FSCAI

Dr. Grantham is an Associate Professor of Medicine at the University of Missouri, Kansas City and an Interventional Cardiologist at Saint Luke's Mid America Heart Institute.

For more information on the Hybrid approach to CTO-PCI, Dr. Grantham suggests physicians visit www.ctofundamentals.org.



GuideLiner catheters are intended to be used in conjunction with guide catheters to access discrete regions of the coronary and/or peripheral vasculature, and to facilitate placement and exchange of guidewires and other interventional devices. Please see the Instructions for Use for a complete listing of the indications, contraindications, warnings and precautions.

CAUTION: Federal law (U.S.A.) restricts this device to sale by or on the order of a physician.

GuideLiner is a registered trademark of Vascular Solutions, Inc. R350 is a trademark of Vascular Solutions, Inc. All other trademarks and registered trademarks are property of their respective owners.

©2016 Vascular Solutions, Inc. All rights reserved. ML2760 Rev. B 10/16



Vascular Solutions, Inc.
6464 Sycamore Court North
Minneapolis, Minnesota 55369 USA
Customer Service:
United States: 888.240.6001
International: (001) 763.656.4298
customerservice@vasc.com
www.vasc.com

VSIQXM_E00044655