

Distal Stent Delivery With Guideliner Catheter: First in Man Experience

Mamas A. Mamas,^{1,2} PhD, BM BCh, Farzin Fath-Ordoubadi,¹ MD, BM BChir, and Douglas G. Fraser,^{1*} MD, BM BChir

Failure to deliver stents is one of the commonest causes of procedural failure in contemporary PCI practice. We describe successful use of the Guideliner Catheter, the first purpose designed FDA and CE marked device delivery catheter in 13 complex cases in native coronary vessels and bypass grafts performed via the radial route to enable distal stent delivery following failure of conventional techniques. We discuss how the Guideliner catheter may be used to facilitate difficult radial cases. © 2010 Wiley-Liss, Inc.

Key words: TRAD; transradial cath; PCI; percutaneous coronary intervention; ANGO; angiography; coronary

INTRODUCTION

Failure to deliver stents during percutaneous coronary interventions (PCI) is one of the major causes of procedural failure that may occur in up to 5% of cases in contemporary PCI practice [1,2]. We have previously described use of the Terumo 5F Heartrail II catheter within a standard 6F guiding catheter (so called “five-in-six” system) to aid stent delivery. Extra deep coronary intubation using this catheter increases backup support and bypasses proximal points of obstruction to enable distal stent delivery in both native coronary vessels and coronary artery bypass grafts [3,4].

The Terumo “five-in-six” Heartrail II system was developed for use in chronic total occlusion PCI cases in order to increase back-up support [5]. Conversely, the Guideliner catheter (Vascular Solutions, MN) that has now been both CE marked and FDA approved has been developed more specifically with device delivery in mind. The Guideliner “five-in-six” catheter (Vascular Solutions, MN) is essentially a rapid exchange or monorail equivalent of the “five-in-six” Heartrail II catheter that consists of a short guide catheter extension connected to an introducer rod, and so is potentially easier to use than the Heartrail II catheter. In this case series we describe our initial experience with the use of this catheter for stent delivery and backup support in a series of challenging cases performed transradially, and discuss its potential utility in complex radial PCI cases.

METHOD OF INTRODUCTION

The 5-in-6 Guideliner catheter is a 20 cm soft tipped 5F catheter with an internal diameter (ID) of 0.056”

connected via a metal collar to a 115 cm stainless steel shaft to a proximal positioning tab (Fig. 1A). At any time, following placement of the mother guide catheter and coronary wire in the target vessel, the 20 cm Guideliner catheter can be advanced over the wire through the haemostatic valve without the need to disconnect this from the mother guide. The catheter tip is then advanced beyond the tip of the mother guide into the coronary vessel by pushing on the proximal tab. The interventional procedure is performed in the usual manner through the haemostatic valve (Fig. 1B and C). Frequently, placement would follow predilation of the target vessel and prior attempts at stent placement.

Conversely, introduction of the much longer 120 cm Heartrail II catheter requires removal of the haemostatic valve followed by advancement over the coronary wire into and through the mother guide, with subsequent reconnection of the haemostatic valve to the proximal end of the Heartrail catheter [3,4,6]. Again,

¹Manchester Heart Centre, Manchester Royal Infirmary, Biomedical Research Centre, Manchester, United Kingdom

²Manchester Academic Health Science Centre, University of Manchester, Manchester, United Kingdom

Conflict of interest: Nothing to report.

*Correspondence to: Dr. Douglas G. Fraser, Manchester Heart Centre, Manchester Royal Infirmary, Biomedical Research Centre, Manchester, M13 9WL, United Kingdom. E-mail: Douglas.Fraser@cmft.nhs.uk

Received 3 December 2009; Revision accepted 5 January 2010

DOI 10.1002/ccd.22458

Published online 8 April 2010 in Wiley InterScience (www.interscience.wiley.com)

© 2010 Wiley-Liss, Inc.

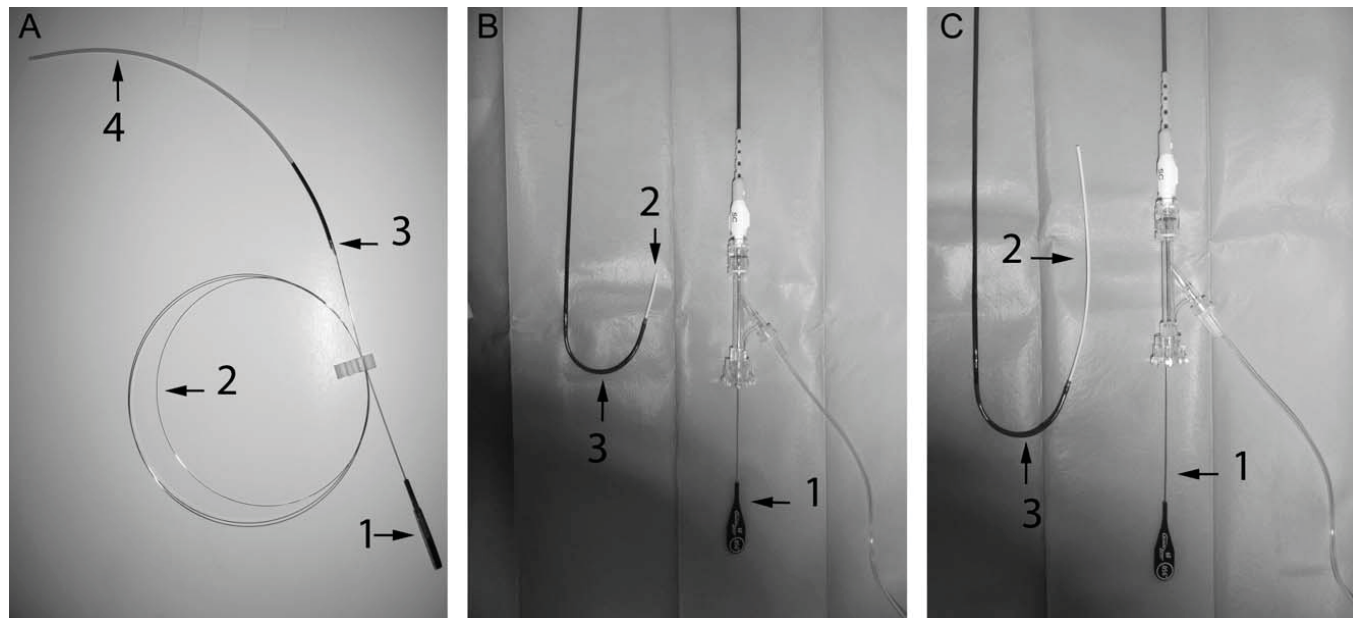


Fig. 1. A: The 6Fr Guideliner catheter is a 20 cm soft tipped catheter (Arrow 4) connected via a metal collar (Arrow 3) to a 115 cm stainless steel shaft (Arrow 2) with a large proximal tab (Arrow 1) for accurate positioning of the device within the coronary system. **B:** Guideliner catheter setup. The Guideliner is passed through the haemostatic valve over a guidewire.

The proximal tab (Arrow 1) is attached to the 115 cm stainless steel shaft that attaches to the 20 cm soft tipped catheter (Arrow 2) seen to extend from the guide catheter (Arrow 3). The proximal tab can be used to position the 20 cm soft tip catheter more distally into the vessel (C).

this is frequently performed following predilation and prior attempts at stent placement. When complete removal of the Heartrail catheter is required, the haemostatic valve needs to be removed and reconnected to the mother guide, and may dislodge the coronary wires if these are not docked. Conversely, removal of the Guideliner catheter can be performed without repositioning of the haemostatic valve or docking the wires in a similar fashion to removal of a monorail balloon. Consequently, advancement, positioning, and removal of the Guideliner catheter is potentially greatly simplified in comparison to the Heartrail catheter.

Case 1

A 48-year-old female with significant exertional angina and good left ventricular function underwent attempted recanalisation of a chronically occluded LAD artery (Fig. 2A). Access was from the right radial artery with a 6F Cordis extra backup guiding catheter. Wire crossing was rapidly achieved using a whisper wire to negotiate a visible microchannel connecting the proximal and distal lumens (Fig. 2B). However, subsequent passage of either a Finecross microcatheter or a low profile 1.25-mm balloon (Riujn, Terumo) was unsuccessful due to marked resistance at the entry to the microchannel. A Guideliner catheter was therefore introduced over the coronary wire, through the guiding catheter. This was advanced 4 cm beyond the tip of

the guide catheter into the LAD, up to the point of occlusion. Subsequent passage of a Quiccross microcatheter across the occlusion was achieved (Fig. 2C), and the Whisper wire was exchanged for a super support Mailman wire. Subsequent introduction of a 1.25 mm balloon allowed expansion of the microchannel, with successful further balloon dilation and finally stenting using a 2.5 × 38 mm Xience (Fig. 2D) and 3 × 28 mm Promus stents. These stents were further expanded with 2.75 and 3 mm balloons to high pressure with an excellent angiographic result (Fig. 2E).

Case 2

A 79-year-old lady with good resting left ventricular function was admitted with an NSTEMI associated with critical single vessel disease of a large RCA. The RCA was heavily calcified with 95% stenoses of the mid vessel and distal vessel at the crux extending into PDA and PLV branches with TIMI 2 flow (Fig. 3A). Access was from the right radial artery using a JR4 guiding catheter. Two Choice floppy wires (Boston Scientific) were advanced into the PDA and PLV branches respectively and both lesions were predilated with 2.5-mm compliant and 3-mm angiosculpt balloons (Pyromed). However, stent delivery across the proximal lesion was not possible due to significant calcification and resistance to stent passage hence a Guideliner catheter was advanced into the RCA. To aid deep

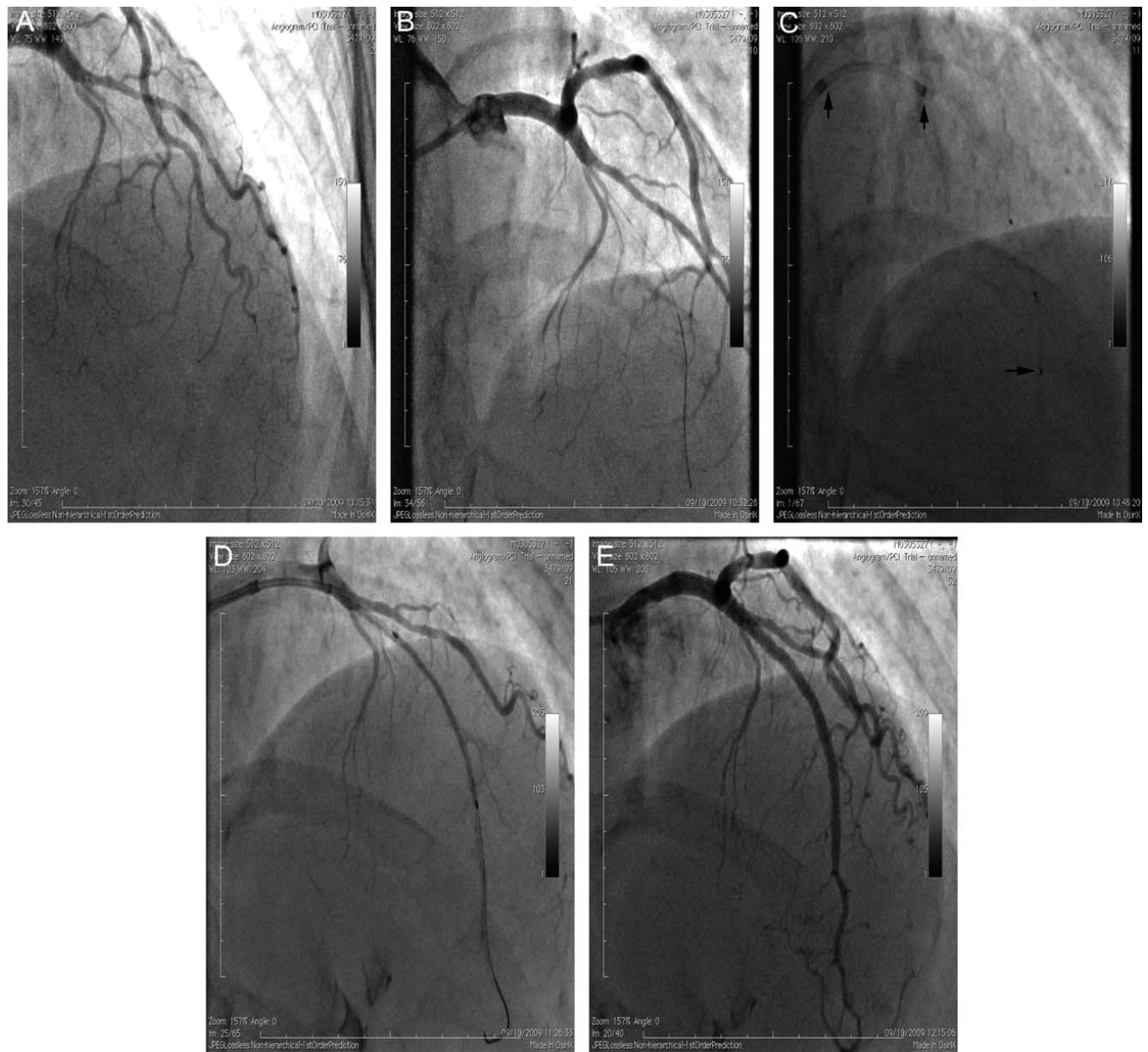


Fig. 2. Chronically occluded LAD (A) and subsequent crossing of the lesion with whisper wire (B). (C) illustrates positioning of the Guideliner catheter into the LAD (second vertical arrow) and the position of the guide catheter is shown by the first arrow. The horizontal arrow illustrates the Quickcross microcatheter used to exchange the whisper wire for a more supportive mailman wire. (D) positioning of xience stent and final result (E).

intubation of the catheter a 2.5-mm balloon was inflated in the distal RCA lesion and a combination of gentle traction on inflated balloon and push on the Guideliner catheter allowed passage of the Guideliner beyond the midvessel lesion. A 4×23 -cm Biomatrix stent was then advanced without resistance through the midvessel lesion within the Guideliner catheter and on into the distal vessel (Fig. 3B). The Guideliner was then brought back into the proximal vessel and the stent was brought back into the mid vessel stenosis where it was inflated with good strut expansion. Again,

using an inflated balloon in the distal lesion as an anchor, the Guideliner was advanced through the deployed stent into the distal vessel. A Triton bifurcation stent was then advanced to the distal vessel through the Guideliner catheter and was deployed across the crux into the PLV branch. Further stents were then placed in the PLV branch distal to the crux and from the distal RCA into the PDA. A final kissing balloon from the distal RCA into the PDA and PLV branches completed the procedure with an excellent angiographic result.

Catheterization and Cardiovascular Interventions DOI 10.1002/ccd.

Published on behalf of The Society for Cardiovascular Angiography and Interventions (SCAI).

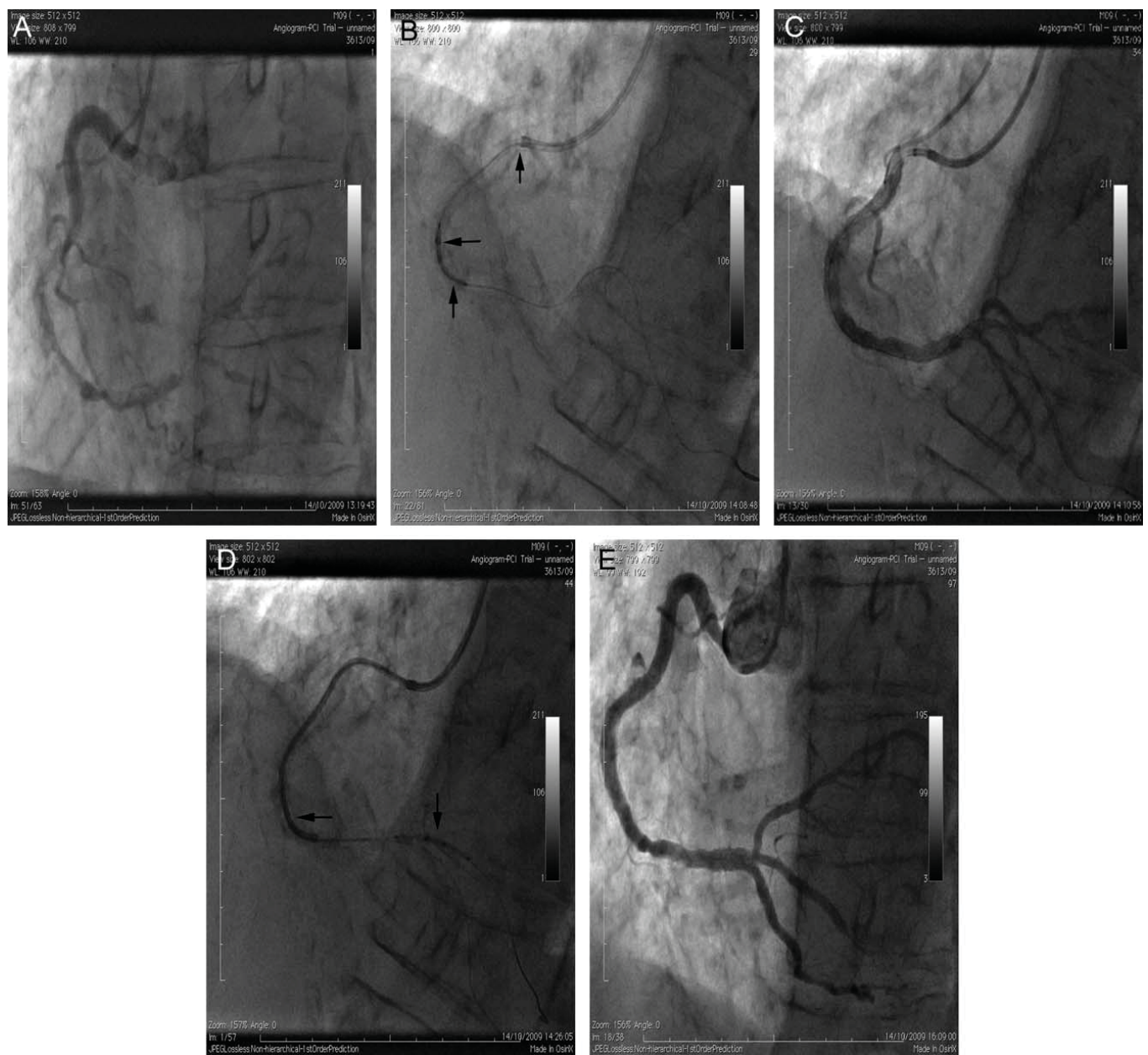


Fig. 3. A: RCA at start of case. B: Guideliner catheter (Horizontal arrow) used to bypass proximal point of obstruction enabling delivery of biomatrix stent (Vertical arrow). The guide catheter is illustrated by vertical arrow at top of figure. C: opacification of RCA following stenting of proximal and mid RCA. D: Triton bifurcation stent (Vertical arrow) delivered into PLV branch of RCA through Guideliner catheter (Horizontal arrow) passed through previously deployed proximal stents. E: Final result.

Case 3

A 76-year-old male with good left ventricular function and previous CABG was scheduled for PCI of the native RCA due to ongoing ischaemia at rest in this territory that had no graft supply. The RCA was diffusely diseased from the proximal to the distal vessel with heavy calcification, marked tortuosity and subtotal occlusion of the midvessel (Fig. 4A). We proceeded from the right radial artery using a 6F JR4 catheter and

successfully crossed into the distal vessel using a Whisper wire. The mid and proximal RCA was dilated with 1.5, 2.5, and 2.75 mm balloons (Maverick, Boston), however stent passage was unsuccessful due to heavy calcification and tortuosity. The Guideliner catheter was then advanced 3.5 cm into the proximal RCA, enabling deployment of a 2.5 by 18 mm Promus stent to the site of subtotal occlusion in the mid RCA (Fig. 4B). Again with the aid of deep intubation an overlapping 3 × 28 mm Promus stent could then

Catheterization and Cardiovascular Interventions DOI 10.1002/ccd.
Published on behalf of The Society for Cardiovascular Angiography and Interventions (SCAI).

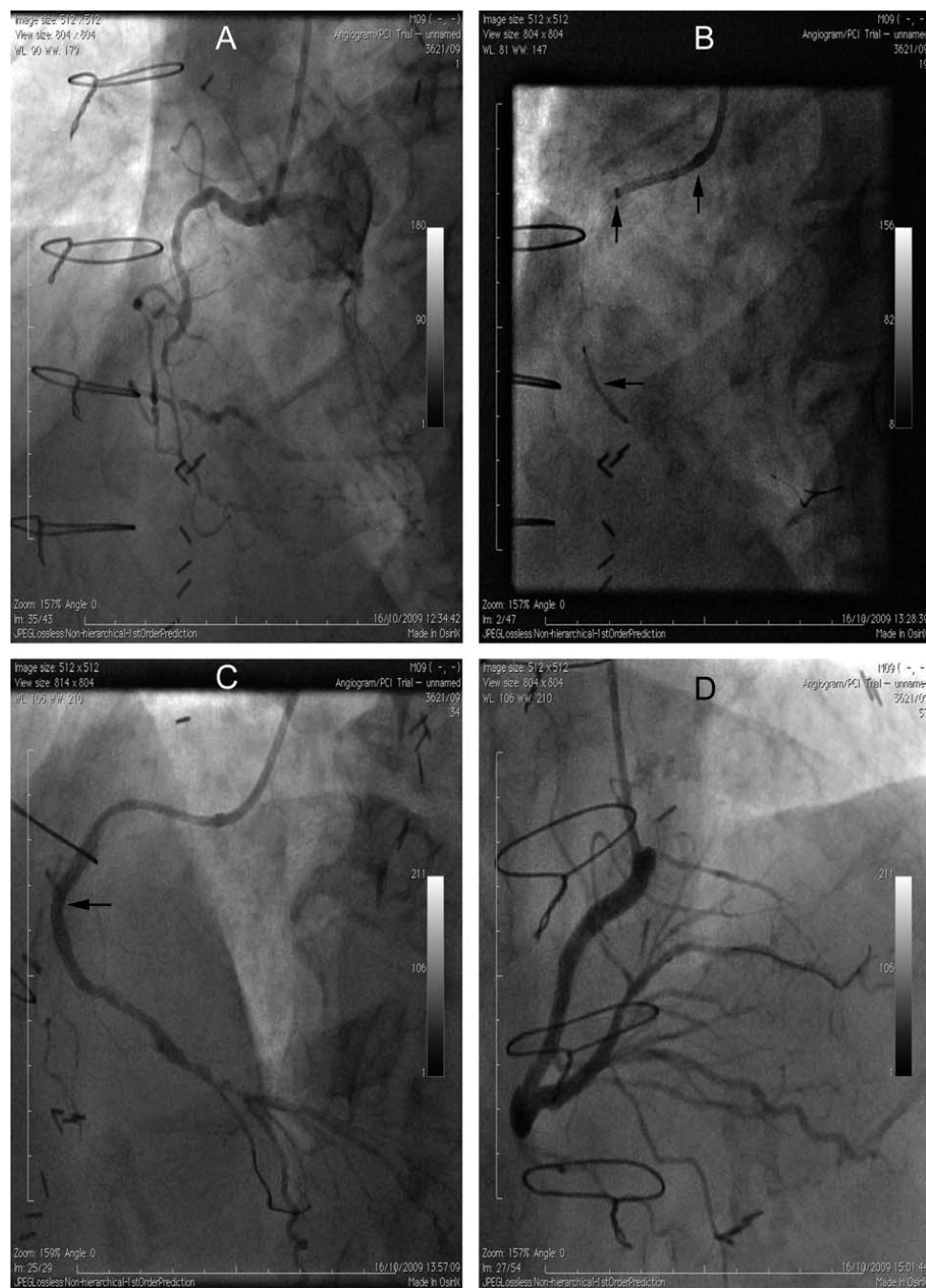

Fig. 4. A: Angiographic appearance of RCA at start of case. B: Positioning of initial Promus stent (Horizontal arrow). The Guideliner catheter and guide catheter are shown by vertical arrows. C: Passage of Guideliner catheter through the proximally deployed stents and opacification of the distal vessel demonstrating further disease. Distal end of Guideliner highlighted by horizontal arrow. D: Final result.

placed proximally extending from the first stent to the proximal RCA. This allowed visualization of the distal RCA that had two further severe stenoses together with a severe stenosis of the proximal PDA. To treat these lesions a 2.5-mm balloon was inflated in the distal RCA and the Guideliner catheter advanced through the stented segments into the distal RCA (Fig. 4C). Following predilation this

allowed easy passage of a 2.25×23 mm Promus stent that extended from the RCA into the PLV and a further 3×28 mm Promus stent that overlapped this stent and the first stent placed. Following post dilation of the RCA stents to 3 mm and stenting of the proximal RCA with two 3.5×8 mm Promus stents, an excellent angiographic result was achieved (Fig. 4D).

Catheterization and Cardiovascular Interventions DOI 10.1002/ccd.

Published on behalf of The Society for Cardiovascular Angiography and Interventions (SCAI).

Explore Litigation Insights

Docket Alarm provides insights to develop a more informed litigation strategy and the peace of mind of knowing you're on top of things.

Real-Time Litigation Alerts



Keep your litigation team up-to-date with **real-time alerts** and advanced team management tools built for the enterprise, all while greatly reducing PACER spend.

Our comprehensive service means we can handle Federal, State, and Administrative courts across the country.

Advanced Docket Research



With over 230 million records, Docket Alarm's cloud-native docket research platform finds what other services can't. Coverage includes Federal, State, plus PTAB, TTAB, ITC and NLRB decisions, all in one place.

Identify arguments that have been successful in the past with full text, pinpoint searching. Link to case law cited within any court document via Fastcase.

Analytics At Your Fingertips



Learn what happened the last time a particular judge, opposing counsel or company faced cases similar to yours.

Advanced out-of-the-box PTAB and TTAB analytics are always at your fingertips.

API

Docket Alarm offers a powerful API (application programming interface) to developers that want to integrate case filings into their apps.

LAW FIRMS

Build custom dashboards for your attorneys and clients with live data direct from the court.

Automate many repetitive legal tasks like conflict checks, document management, and marketing.

FINANCIAL INSTITUTIONS

Litigation and bankruptcy checks for companies and debtors.

E-DISCOVERY AND LEGAL VENDORS

Sync your system to PACER to automate legal marketing.