

Usefulness and safety of the GuideLiner catheter to enhance intubation and support of guide catheters: insights from the Twente GuideLiner registry

Frits H.A.F. de Man¹, MD PhD; Kenneth Tandjung¹, MD; Marc Hartmann¹, MD, PhD; K. Gert van Houwelingen¹, MD; Martin G. Stool¹, MD; Hans W. Louwerenburg¹, MD; Mounir W.Z. Basalus¹, MD; Hanim Sen¹, MD; Marije M. Löwik¹, PhD; Clemens von Birgelen^{1,2*}, MD, PhD

1. Department of Cardiology, Thoraxcentrum Twente, Enschede, The Netherlands; 2. MIRA - Institute for Biomedical Technology and Technical Medicine, University of Twente, Enschede, The Netherlands

KEYWORDS

- angiography
- bypass graft
- complex lesions
- coronary artery disease
- drug-eluting stents

Abstract

Aims: Optimal ostial seating and adequate back-up of guide catheters are required for challenging percutaneous coronary interventions (PCI). The GuideLiner™ (GL) (Vascular Solutions Inc., Minneapolis, MN, USA) is a guide catheter extension system that provides active back-up support by deep coronary intubation. We aimed to assess feasibility and safety of GL-use in routine clinical practice.

Methods and results: We prospectively recorded patient and procedural details, technical success, and in-hospital outcome of 65 consecutive patients undergoing “5-in-6” Fr GL-facilitated PCI of 70 target vessels. The GL was mainly used for PCI of complex coronary lesions: 97% (68/70) had American Heart Association/American College of Cardiology (AHA/ACC) lesion types B2/C; 53% (37/70) were distally located; and 23% (17/70) were heavily calcified. Indications were to increase back-up of the guide and facilitate stent delivery (59%; 41/70), achievement of coaxial alignment of the guide catheter (29%; 20/70), and selective contrast injections (13%; 9/70). Device success rate was 93% (65/70). There were no major complications and two minor complications managed without clinical sequelae: one air embolism and one stent dislodgement.

Conclusions: GL-use resulted in increased back-up and guide catheter alignment for stent delivery in unfavourable tortuous coronary anatomies and complex, heavily calcified, and often distally located lesions, which otherwise may have been considered unsuitable for PCI. Procedural success rate was high and there were no major complications.

*Corresponding author: Thoraxcentrum Twente, Department of Cardiology, Haaksbergerstraat 55, 7513 ER Enschede, The Netherlands. E-mail: c.vonbirgelen@jnst.nl

© Europa Edition 2012. All rights reserved.

Abbreviations

| | |
|---------------|--|
| ACS | acute coronary syndrome |
| CK | creatinine kinase |
| CTO | chronic total occlusion |
| DES | drug-eluting stents |
| GEA | gastroepiploic artery |
| GL | GuideLiner |
| LAD | left anterior descending coronary artery |
| LCX | left circumflex coronary artery |
| LM | left main |
| NSTEMI | non-ST-elevation myocardial infarction |
| PCI | percutaneous coronary intervention |
| STEMI | ST-elevation myocardial infarction |
| RCA | right coronary artery |
| UAP | unstable angina pectoris |

Introduction

Despite the advancements made in percutaneous coronary interventions, the interventional cardiologist nowadays has to deal with an increasing complexity of procedures. A good back-up of the guide catheter is essential to advance guidewires and balloons, and to deliver stents. Support of the guide can be increased by use of extra back-up guides and larger guide dimensions. In addition, the stability of the guide can be improved by advancing a buddy wire, and use of stiffer guidewires or anchoring balloons^{1,2}. Another way to increase back-up support is deep intubation of the guide^{3,4}. There is, however, a considerable risk of dissecting the vessel. Introduction of guide catheter extension systems, in which a long guide catheter with a flexible tip is advanced through the mother guide, has further refined this concept⁵⁻⁷. Besides the improvement in back-up support, the use of guide catheter extensions provides selective visualisation of the target vessel, improves the stability of the guide and allows coaxial alignment of the guide.

There are three systems available: the Heartrail® II catheter (Terumo Corp., Tokyo, Japan), the Proxis™ device (St Jude Medical, St Paul, MN, USA) and the GuideLiner™ catheter (Vascular Solutions Inc., Minneapolis, MN, USA). The Heartrail® II catheter and Proxis™ device are 120 cm catheters that are introduced into the mother guide by removing the Y-connector^{6,9}. The GuideLiner (GL) catheter (**Figure 1**) is a novel rapid exchange guide catheter extension system that provides active guide support by its 20 cm-long flexible tubular end, which can be deeply advanced into target vessels¹⁰⁻¹⁸. Its handling is particularly easy, as it does not require disconnection of the haemostatic valve at the proximal end of the guide catheter and is compatible with standard 180 cm-long guidewires. Its soft distal tip promises a low risk of dissecting vessels compared to the deep-seating of regular guide catheters.

So far, only a limited number of reports and case series have been published on the GL guide catheter extension¹⁰⁻¹⁸. Mamas et al reported a case series of 13 complex coronary interventions, performed via the radial artery with the “5-in-6” Fr GL system¹⁰. Although their success rate was high, the main limitation encountered was stent damage upon advancement of the stent across the metallic collar of the GL (two out of 32 stents)¹⁰. Recently, Luna et al published their experience with the GL catheter in a series of 21 patients¹⁵. In their study, a transfemoral approach and 7 Fr guide catheters were used in the majority of the cases with a procedural success rate of 90%. Pressure dampening was seen in 57% of their patients, contributing to three out of four unsuccessful cases. There was one major complication in the series reported by Luna et al, which was a flow-limiting dissection in the proximal left anterior descending coronary artery (LAD) but they noted no case of stent damage¹⁵. The purpose of the present Twente GuideLiner registry was to assess feasibility and safety of use of the “5-in-6” Fr GL guide catheter extension system during routine, clinical PCI procedures as performed at Thoraxcentrum Twente, a high-volume PCI centre located in Enschede, The Netherlands.

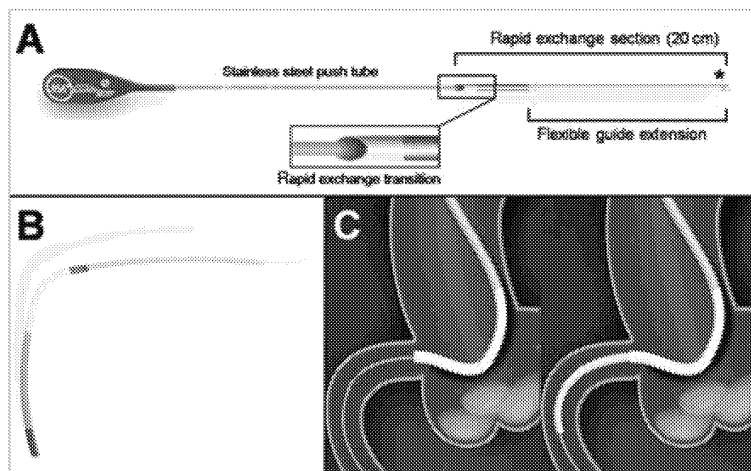


Figure 1. Schematic presentation of the GuideLiner catheter.

Methods

STUDY POPULATION

Between November 2010 and July 2011, we prospectively collected data from a consecutive series of 65 patients, in whom the GL was applied to facilitate routine PCI. The patients had a background of stable or unstable angina pectoris, or presented with an acute myocardial infarction.

INTERVENTIONAL PROCEDURES

A team of five interventional cardiologists performed the PCI procedures; each of them had performed PCI for more than five years (250-500 PCI procedures per operator annually; total PCI experience of 4,000 or more per operator). PCI procedures were performed according to standard clinical protocols via the femoral or radial routes, using 6 Fr guide catheters as a standard. All patients received a bolus of unfractionated heparin (5,000 IE or 70-100 IE/kg). Prior to PCI, all patients received adequate loading doses of acetylsalicylic acid (300 mg) and clopidogrel (300-600 mg), if not pretreated. During the procedure, an intracoronary bolus of nitrates was administered. The choice of interventional approaches, devices, and techniques was left at the operators' discretion, considering current clinical protocols and guidelines. Following PCI, clopidogrel was prescribed for one year (75 mg once daily [o.d.] in addition to life-long treatment with acetylsalicylic acid [at least 100 mg o.d.]).

THE GUIDELINER CATHETER AND ITS USE

The GL (Vascular Solutions, Minneapolis, MN, USA) consists of a flexible, 20 cm, straight, flexible, soft-tipped extension tube that is connected via a metal collar to a thin 115 cm-long stainless steel shaft (Figure 1A and Figure 1B). The extension tube has a silicon coating for lubricity. The procedure starts by positioning the mother guide and advancing the guidewire across the target lesion. Then the GL is advanced over the guidewire through the haemostatic valve of the Y-adapter (handling comparable to regular balloons) to intubate the target coronary artery or bypass graft (Figure 1C). The GL reduces the inner diameter of the mother guide by approximately 1 Fr, but it does not lengthen the guide outside the patient. When the GL is in place, balloons and stents can be delivered over the same initial guidewire. The GL is available in sizes of 6 Fr, 7 Fr, and 8 Fr. In this study, only 6 Fr GL were used (also called the "5-in-6" Fr system), which has an internal diameter of 0.056" (1.422 mm). Notably, the use in vessels <2.5 mm is discouraged by the manufacturer. Bifurcation lesions in our study were treated as follows: two wires were advanced through the guide. Then, the GL was advanced over both wires simultaneously. Provisional stenting was the strategy of choice. In cases where a kissing balloon technique was demanded, a wire exchange was performed followed by balloon dilation of the side branch through the stent struts. Before the final kissing balloon inflation could be performed, the GL had to be removed.

STUDY PARAMETERS AND DATA ACQUISITION

To assess the usefulness (feasibility and safety) of the GL in clinical practice, we prospectively recorded various procedural data and clinical

details on the in-hospital outcome of a consecutive series of 65 patients, who underwent PCI with the use of the GL. Patient demographics, indication for GL use, angiographic and procedural details including technical success, and all complications were recorded. Quantitative coronary angiography (QCA) was used to determine the intubation depth of the GL catheter. Procedural success was defined as the achievement of <20% diameter stenosis with TIMI 3 flow in the target vessel. Routine peri-interventional assessment of cardiac biomarkers was performed to screen for PCI-induced myocardial necrosis up to 24 hours after PCI or until the highest value of creatine kinase (CK) was measured. Peri-PCI myocardial infarction was defined as two times the upper reference limit of CK, confirmed by significant elevation of other specific biomarkers (MB-fraction of CK or troponin).

STATISTICAL ANALYSIS

Values are expressed as mean±SD. Comparison of continuous variables was performed with the Student's t-test. Categorical variables are presented as numbers or percentages and were tested with the chi-square test or Fisher's exact test. A p-value <0.05 was considered statistically significant. Statistical analysis was performed with SPSS version 15.0 for Windows (SPSS Inc., Chicago, IL, USA).

Results

PATIENT POPULATION AND LESION CHARACTERISTICS

The demographic characteristics of the study population are presented in Table 1. The majority of patients were male (74%), and the mean age was 67±13 years. Target lesions were relatively complex as is shown in Table 2. Most lesions (97%) had American Heart Association/American College of Cardiology (AHA/ACC) lesion types B2 or C, with more than half of them being located in distal vessel segments. A total of 90% of lesions was classified as being calcified: 67% mild to moderately and 23% heavily calcified. Mean lesion length was 38±26 mm, which is indicative of long lesions.

Table 1. Demographic characteristics of study population.

| | |
|--|-------------|
| Age (years) | 67±13 |
| Male gender | 74% (48/65) |
| Hypertension | 57% (37/61) |
| Hypercholesterolaemia | 54% (35/61) |
| Diabetes | 25% (16/65) |
| Current smoking | 22% (14/61) |
| Family history of CAD | 28% (18/61) |
| Prior myocardial infarction | 32% (21/65) |
| Prior PCI | 26% (17/65) |
| Prior CABG | 26% (17/65) |
| Indication for PCI | |
| ST-elevation MI | 12% (8/65) |
| Non-ST-elevation MI | 20% (13/65) |
| Unstable angina | 6% (4/65) |
| Stable angina | 62% (40/65) |
| CAD: coronary artery disease; PCI: percutaneous coronary intervention; CABG: coronary artery bypass graft; MI: myocardial infarction | |

Table 2. Target vessels and lesion characteristics.

| Target vessels | |
|---------------------------------|-------------|
| Left anterior descending artery | 17/70 (24%) |
| Left circumflex artery | 20/70 (29%) |
| Right coronary artery | 23/70 (33%) |
| Vein graft | 10/70 (14%) |
| Target lesions | |
| Type B2/C lesion | 68/70 (97%) |
| Distal location | 37/70 (53%) |
| Severe calcification | 16/70 (23%) |
| Chronic total occlusion | 12/70 (17%) |
| Reference vessel diameter (mm) | 3.0±0.5 |
| Diameter stenosis (%) | 89±13 |
| Lesion length (mm) | 38±26 |

INDICATION FOR GL USE AND PROCEDURAL DETAILS

All procedures were carried out with the “5-in-6” Fr GL device. As shown in **Figure 3**, the primary indications for GL use were to increase back-up of the guide catheter, in general to facilitate stent delivery (59%), and to improve alignment of the guide catheter (29%) (**Table 3**). In a few patients (13%), the GL was used for selective contrast injection, predominantly because of dominant left coronary artery (LCA) and/or renal impairment. There were differences between the application in right coronary artery

Table 3. Procedural details, success, failures, and complications.

| Procedural details | |
|---|-------------|
| Radial access | 22/65 (34%) |
| Multivessel procedure | 19/65 (29%) |
| Procedural time (min) | 79±43 |
| Volume of contrast (ml) | 220±118 |
| Total length of stents implanted (mm) | 41±29 |
| Number of stents implanted | 1.8±1.2 |
| Depth of GuideLiner intubation (mm) | 33±21 |
| Primary indication for GuideLiner use | |
| Improvement of back-up and facilitated stent delivery | 41/70 (59%) |
| More selective contrast injection | 9/70 (13%) |
| Improvement of alignment of the guide | 20/70 (29%) |
| Success, failures, and complications | |
| Device success | 65/70 (93%) |
| Procedural success | 64/70 (91%) |
| Major complications | 0/70 |
| Minor complications | 2/70 (3%) |
| Air embolism | 1/70 (1%) |
| Stent dislodgement | 1/70 (1%) |

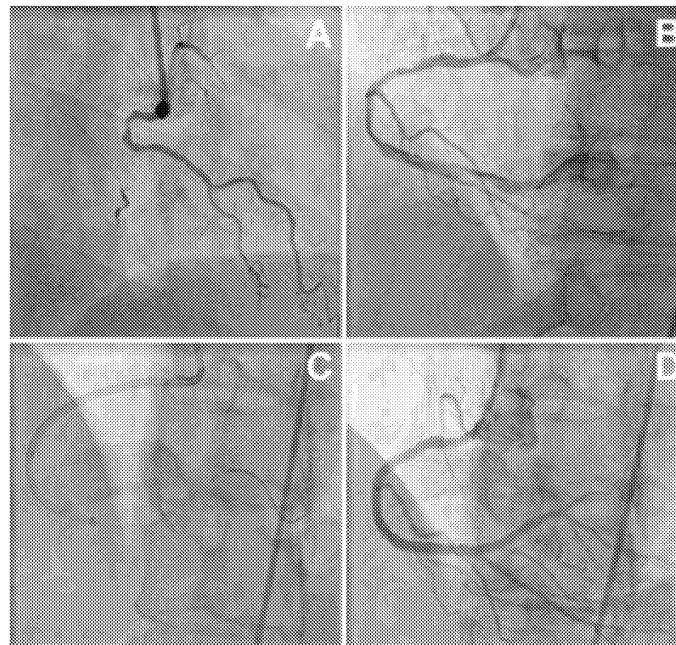


Figure 2. Angiography of a chronically occluded RCA in a 55-year-old female patient (A). Wire crossing was achieved using a pilot 50 wire. After subsequent passage and dilation with low profile balloons, the flow is partially restored and a long dissection can be noted that extends into the postero-lateral branch (B). Passage of a stent was unsuccessful due to marked resistance in the distal segment of the vessel. With the help of an anchoring balloon, the GuideLiner catheter was deeply intubated over the guidewire (C). Then, several drug-eluting stents were successfully delivered and postdiluted, with a good final angiographic result (D).

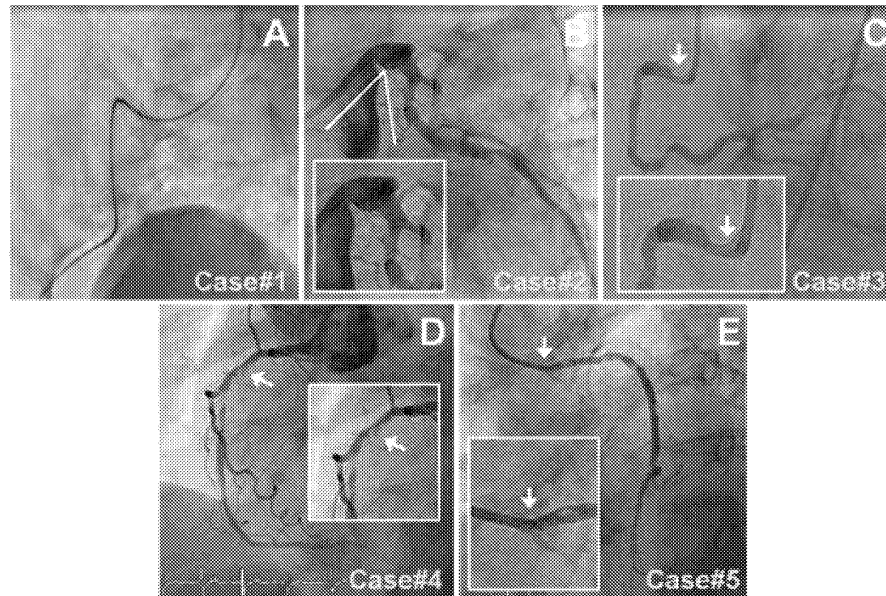


Figure 3. Angiographic overview of the device failures: Case #1) The first case was a 79-year-old male patient with an acute inferior MI. The target lesion was located in a diffusely diseased, heavily calcified RCA. The GL could not be advanced through the guide catheter because of severe iliac tortuosity (A), but procedural success was accomplished by use of a 3DRC guide catheter, two guidewires, and a distal anchoring balloon. Case #2) The second case was a long and calcified proximal LCX lesion, located behind a sharp angle between the LM and LCX that prevented GL intubation (B). Case #3) The third case was a 56-year-old subject who underwent an elective PCI of a diffusely diseased RCA. The GL catheter could not be intubated in the vessel due to a proximal lesion (C). The procedure was finished successfully with an ALI guide. Case #4) In the fourth patient, the target lesion was a heavily calcified long mid RCA lesion (D). The proximal RCA segment was diffusely diseased, which prevented deep GL intubation (a depth of only 5 mm) and resulted in insufficient support; however, this problem was solved by rotablation of the ostium. Case #5) The fifth case was a vital 87-year-old female with stable angina due to a severely calcified proximal lesion in an 18-year-old saphenous vein graft. An AL2 guide catheter was positioned in the ostium and a flexible guidewire with hydrophilic coating was advanced across the lesion. Use of the GL was attempted to increase back-up support but the GL could not be advanced into the ostium (E), and the PCI procedure was terminated as a second guidewire could not pass the ostium either. We discussed the patient with our thoracic surgeons, who then performed an elective repeat bypass surgery with an unevenful clinical course.

(RCA) and LCA interventions. In the LCA, the GL catheter was used regularly to improve the alignment of the guide or enhance selective contrast injections, whereas its use in RCA interventions was mainly to increase catheter back-up ($p=0.024$). An example is shown in **Figure 2**.

A 6 Fr guide catheter was used in all subjects, while radial access was chosen in one third of cases. Multivessel procedures were performed in almost one third of the patients, and there were 17% of chronic total occlusions. Of all 126 stents implanted, 123 (98%) were third-generation drug-eluting stents (DES). In this registry, we noted a single stent that was damaged upon advancement across the metallic collar of the GL; damage to the (secondary) guidewire tip when passing the metallic collar of the GL occurred slightly more often (4/70; 6%).

DEVICE SUCCESS AND DEVICE FAILURE

The overall success rate of the GL was 93%. The average depth to which the GL was intubated in the proximal target vessels was 33 ± 22 mm (range: 0 to 106 mm), however, these generally deep intubations did not cause any coronary dissections. The rate of procedural success of the transradial and transfemoral access routes was 95.5%

and 88.4% ($p=0.35$), respectively, but the power of the study was insufficient to draw sound conclusions from this comparison. There were five device failures (5/70; 7%), which are illustrated in **Figure 3**.

COMPLICATIONS

We noted no major complications or coronary dissections. There were two minor complications, which are outlined below. In the first case, during PCI of a diffusely diseased RCA in a 53-year-old male, the GL was deeply advanced (61 mm intubation depth) to increase back-up support and to pass a balloon catheter across the heavily calcified distal RCA stenosis. During this manoeuvre, some air embolism was noted as a result of insufficient venting of the wedged GL, which caused a brief phase of stasis of coronary flow that was rapidly resolved. The second minor complication occurred during PCI of a long mid lesion in an RCA with “shepherd’s crook” anatomy. After predilatation and stenting of the mid RCA, an attempt to advance a second stent through the first one was made, which turned out to be extremely difficult. To increase support, the GL was advanced over both guidewires and the second stent balloon

Explore Litigation Insights

Docket Alarm provides insights to develop a more informed litigation strategy and the peace of mind of knowing you're on top of things.

Real-Time Litigation Alerts



Keep your litigation team up-to-date with **real-time alerts** and advanced team management tools built for the enterprise, all while greatly reducing PACER spend.

Our comprehensive service means we can handle Federal, State, and Administrative courts across the country.

Advanced Docket Research



With over 230 million records, Docket Alarm's cloud-native docket research platform finds what other services can't. Coverage includes Federal, State, plus PTAB, TTAB, ITC and NLRB decisions, all in one place.

Identify arguments that have been successful in the past with full text, pinpoint searching. Link to case law cited within any court document via Fastcase.

Analytics At Your Fingertips



Learn what happened the last time a particular judge, opposing counsel or company faced cases similar to yours.

Advanced out-of-the-box PTAB and TTAB analytics are always at your fingertips.

API

Docket Alarm offers a powerful API (application programming interface) to developers that want to integrate case filings into their apps.

LAW FIRMS

Build custom dashboards for your attorneys and clients with live data direct from the court.

Automate many repetitive legal tasks like conflict checks, document management, and marketing.

FINANCIAL INSTITUTIONS

Litigation and bankruptcy checks for companies and debtors.

E-DISCOVERY AND LEGAL VENDORS

Sync your system to PACER to automate legal marketing.