

# INTRAVITREAL SILICONE OIL DROPLETS AFTER INTRAVITREAL DRUG INJECTIONS

SOPHIE J. BAKRI, MD, NOHA S. EKDAWI, MD

---

**Purpose:** To present the finding of tiny silicone oil droplets in 15 eyes of 15 patients after intravitreal injections of an anti-vascular endothelial growth factor agent or triamcinolone acetonide and to discuss the likely source of silicone oil.

**Methods:** In an observational case series, charts of patients who had undergone intravitreal injections by one surgeon were reviewed retrospectively. The finding of intravitreal silicone oil droplets was noted. The following information was also documented: number and type of injections before the appearance of silicone oil droplets, symptoms and evidence of ocular inflammation, visual acuity before and after silicone oil droplets, length of follow-up, and visual acuity at the last examination.

**Results:** Fifteen eyes of 15 patients were found to have silicone oil droplets documented after a various number of injections (range, 1–16). Patients were asymptomatic, and there were no adverse side effects associated with the presence of silicone oil droplets at examination.

**Conclusions:** Silicone oil droplets may occur in the vitreous cavity after intravitreal drug injections. There were no adverse effects found associated with silicone oil in the vitreous after injections of anti-vascular endothelial growth factor agents or triamcinolone acetonide. The likely source of silicone oil is the needles and syringes used for the injections.

**RETINA** 28:996–1001, 2008

---

The use of intravitreal injections for the treatment of retinal disorders has become a much more common procedure, in light of the development of drugs specifically designed to block vascular endothelial growth factor and the efficacy of intravitreal steroids. Intravitreal drugs that are US Food & Drug Administration–approved for the treatment of choroidal neovascularization associated with age-related macular degeneration include pegaptanib (Macugen; OSI/Eyetech, New York, NY)<sup>1</sup> and ranibizumab (Lucentis; Genentech, Inc., South San Francisco, CA).<sup>2,3</sup> In addition, intravitreal bevacizumab (Avastin; Ge-

nentech, Inc.) is used off label for the treatment of choroidal neovascularization, diabetic retinopathy, retinal venous occlusive disease, and other vascular endothelial growth factor–mediated diseases.<sup>4</sup> Intravitreal triamcinolone has been shown to be effective in the treatment of macular edema.<sup>5–8</sup> Known complications of intravitreal injections include sterile and infectious endophthalmitis, retinal detachment, intraocular inflammation, vitreous hemorrhage, retinal tears, and damage to the crystalline lens. Most of these complications are procedure related. However, the cumulative damage from repeated injections has not been addressed. We present a series of 15 eyes of 15 patients with intravitreal silicone droplets as a consequence of intravitreal injections with an anti-vascular endothelial growth factor agent or triamcinolone and discuss the likely source of silicone oil.

---

From the Department of Ophthalmology, Vitreoretinal Diseases and Surgery, Mayo Clinic, Rochester, Minnesota.

Supported by Research to Prevent Blindness, Inc. (New York, NY).

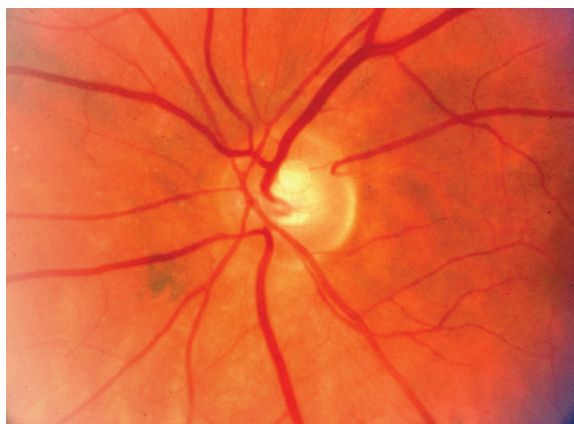
Reprint requests: Sophie J. Bakri, MD, Department of Ophthalmology, Vitreoretinal Diseases and Surgery, Mayo Clinic, 200 First Street SW, Rochester, MN 55905; e-mail: sbakri@hotmail.com

**Methods**

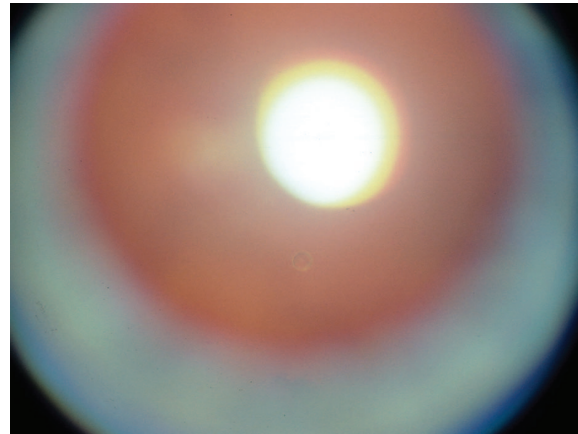
After receiving approval from the Mayo Clinic Institutional Review Board (Rochester, MN), a retrospective review of charts of patients who had received intravitreal injections of pegaptanib, bevacizumab, triamcinolone, or ranibizumab by one surgeon (S.J.B.) between July 2005 and November 2007 was performed. The charts were reviewed for the presence of intravitreal silicone oil droplets. The number and type of injections before the appearance of silicone oil droplets were documented. In addition, symptoms and evidence of ocular inflammation were noted. Visual acuity was also documented before and after silicone oil droplets were noted during examination; length of follow-up and final visual acuity were measured as well.

**Results**

A total of 1,529 intravitreal injections between July 2005 and November 2007 were reviewed. Fifteen eyes of 15 patients had documented intravitreal silicone oil droplets noted during examination. All 15 eyes had tiny silicone oil droplets in the vitreous that were visible by slit-lamp or funduscopic examination (Figs. 1–3). At examination in various head positions, the silicone oil droplets were found to float superiorly. All patients were asymptomatic. There was no ocular inflammation, as evidenced by anterior chamber or vitreous cell throughout the follow-up period. The number of injections before silicone oil droplets were noted varied from 1 to 16 (Table 1) of pegaptanib, bevacizumab, triamcinolone, or ranibizumab. Patients were being treated for choroidal neovascularization and cystoid macular edema due to branch or central retinal vein occlusions. As expected from the course of disease treatment, visual acuity fluctuated throughout treatment, depending on the activity of choroidal



**Fig. 1.** A tiny silicone oil droplet noted just anterior to the optic nerve.

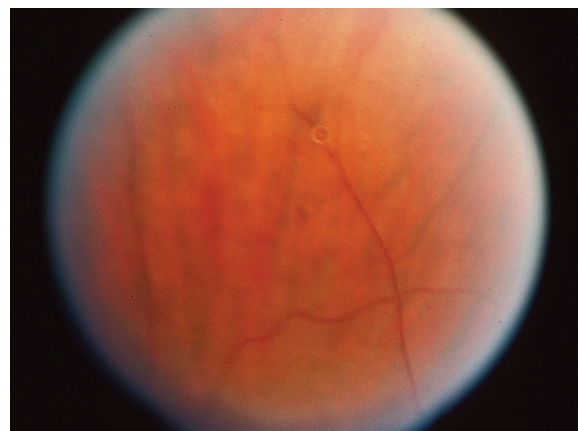


**Fig. 2.** Patient 5. A tiny silicone oil droplet noted in the vitreous cavity during slit-lamp examination. The large yellow area is a light reflection. The red reflex is shown.

neovascularization or macular edema. Visual acuity was not affected by the presence of silicone oil droplets but was consistent with the course of the disease (Table 1). The presence of silicone oil was confirmed with ultrasonography (Fig. 4 [Patient 1]). The high echogenicity matched that of silicone oil. No intervention was necessary in our group of patients, and the patients were observed without complications for the follow-up period (range, 0–13.9 months; median, 7.0 months).

**Discussion**

Intravitreal silicone oil droplets may occur after intravitreal injection. In our case series, there was no association with a specific agent. As shown in Table 1, 10 of 15 patients had received bevacizumab injections before silicone oil droplets were noted during examination. The other five patients had received injections

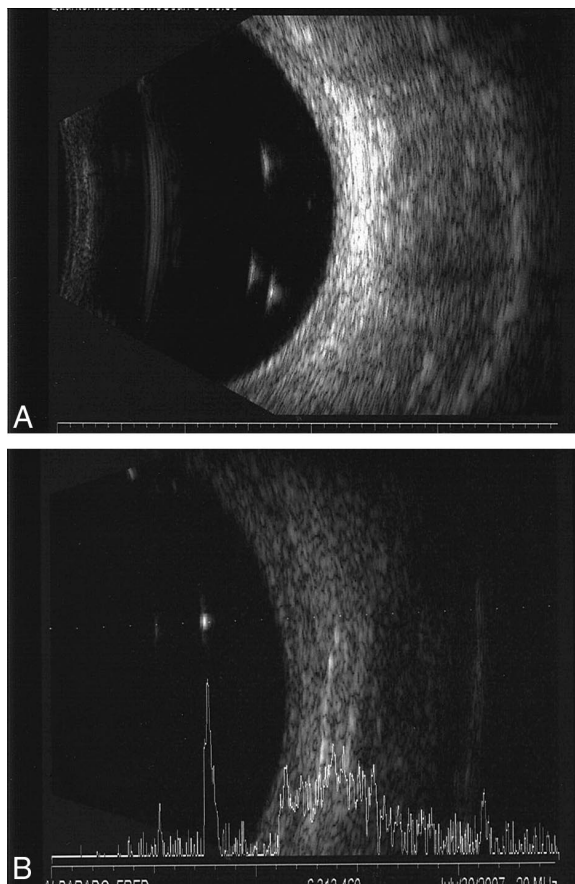


**Fig. 3.** Patient 5. A tiny silicone oil droplet noted in the vitreous cavity.

Table 1. Description of Patients With Intravitreal Silicone Oil Bubbles Seen During Examination

Patient	Disease	No. of Injections Before Silicone Oil Noted	Total No. of Injections Throughout Follow-up	Intravitreal Agent(s) Used Before Silicone Oil Noted	Intravitreal Agent(s) Used by Final Follow-up	Visual Acuity Before Silicone Oil Was Noted		Visual Acuity After Silicone Oil Was Noted		Duration (mo) of Follow-up After Silicone Oil Was Noted
						Visual Acuity Before Silicone Oil Was Noted	Visual Acuity After Silicone Oil Was Noted	Visual Acuity at Final Follow-up	Visual Acuity Follow-up	
1	CME due to hemi-CRVO	1	1	Bevacizumab	Bevacizumab × 1	20/20	20/20	20/25	20/25	5.6
2	CNV due to AMD	8	12	Bevacizumab, ranibizumab	Bevacizumab × 2; ranibizumab × 9; bevacizumab and triamcinolone	20/25	20/30	20/40	20/40	5.3
3	CME due to radiation retinopathy	3	8	Bevacizumab	Bevacizumab × 10; triamcinolone × 1	20/100	20/40	20/40	20/40	12.4
4	CNV due to AMD	7	12	Pegaptanib, ranibizumab	Pegaptanib × 3; ranibizumab × 9	20/25	20/30	20/25	20/25	5.4
5	CME due to CRVO	2	7	Bevacizumab	Bevacizumab × 7	20/40	20/40	20/40	20/40	13.7
6	CNV due to AMD	3	3	Pegaptanib	Pegaptanib × 3	20/20	20/20	20/30	20/30	3.3
7	CNV due to AMD	16	20	Pegaptanib, bevacizumab, ranibizumab	Pegaptanib × 3; bevacizumab × 7; ranibizumab × 10	20/40	20/30	20/80	20/80	5.1
8	CME due to BRVO	3	5	Bevacizumab	Bevacizumab × 5	20/50	20/30	20/30	20/30	5.6
9	CNV due to AMD	3	4	Pegaptanib, bevacizumab	Pegaptanib × 1; bevacizumab × 4	20/30	20/40	20/60	20/60	13.9
10	CNV due to AMD	4	10	Bevacizumab, ranibizumab	Bevacizumab × 2; ranibizumab × 5; bevacizumab × 3	20/100	20/150	20/100	20/100	7.4
11	CME due to BRVO	10	11	Bevacizumab	Bevacizumab × 11	20/40	20/50	20/50	20/50	0.0
12	CNV due to AMD	15	16	Pegaptanib, ranibizumab, dexamethasone	Pegaptanib × 6; ranibizumab × 8; dexamethasone × 1; bevacizumab × 1	20/50	20/40	20/40	20/40	0.0
13	CNV due to AMD	5	6	Ranibizumab	Ranibizumab × 6	20/50	20/40	20/40	20/40	0.0
14	CNV due to AMD	15	15	Pegaptanib, ranibizumab	Pegaptanib × 12; ranibizumab × 3	20/30	20/25	20/25	20/25	0.0
15	CME due to radiation retinopathy	6	7	Bevacizumab, triamcinolone	Bevacizumab × 2; triamcinolone × 5	20/60	20/70	20/70	20/70	2.4

CME, cystoid macular edema; CRVO, central retinal vein occlusion; CNV, choroidal neovascular membrane; AMD, age-related macular degeneration; BRVO, branch retinal vein occlusion.



**Fig. 4.** Patient 1. Silicone oil droplets shown by A-scan and B-scan ultrasonography. **A**, B-Scan showing three droplets of silicone oil in the vitreous cavity. **B**, A-Scan showing the highly echogenic pattern.

with pegaptanib, ranibizumab, or a combination. Because none of the patients had received triamcinolone alone, we cannot implicate this drug to be associated with this finding. The agents used did not have silicone oil in their drug vehicle. There were no adverse effects on vision, and there was no ocular inflammation during the follow-up period. Intravitreal silicone oil is used commonly in retinal detachment surgery, and its ocular adverse effects include migration of silicone oil into the anterior chamber, emulsification of silicone oil, and keratopathy. Other known side effects are more applicable in the presence of a near-complete silicone oil fill in the vitreous and include pupillary block, angle closure without pupillary block, and idiopathic open-angle glaucoma even with the absence of silicone oil in the anterior chamber.<sup>9</sup> None of these side effects were seen in our series.

Freund et al<sup>10</sup> described a series of three eyes of three patients where silicone oil was noted after intravitreal injections. Ultrasonography showed a highly echogenic pattern, characteristic of silicone oil. These

investigators questioned whether this is due to the silicone oil lubricant on the syringes or needles used for intravitreal injections. Pegaptanib is packaged in a sterile, 1-mL, USP type 1, graduated, prefilled glass syringe fitted with a sterile 27-gauge needle. All needles used in our series were of varying gauges, manufactured by Becton Dickinson and Company (Franklin Lakes, NJ). Triamcinolone is drawn up with a 20-gauge needle and injected with a 27-gauge needle. Ranibizumab is drawn up with a 19-gauge filter needle (5- $\mu$ m filter) and injected intravitreally using a 30-gauge 0.5-in needle (PrecisionGlide, Becton Dickinson and Company, Franklin Lakes, NJ). Bevacizumab is fractionated by our hospital pharmacy from a large vial into 0.15-mL doses supplied in a tuberculin syringe (Becton Dickinson and Company). Either a 30-gauge 0.5-in needle is placed on this or it is transferred into a 31-gauge needle attached to a syringe (Ultrafine II, Becton Dickinson and Company, Franklin Lakes, NJ). During the manufacturing process, these needles were extruded with silicone oil as well as lubricated. The tuberculin syringes were also lubricated with silicone oil. The lubricant used was most likely 365 Dow Corning surfactant according to a discussion with representatives from Becton Dickinson and Company. Material supplied by the Dow Corning Corporation states that the components of the surfactant and preservative package used in the emulsion are present at levels of fractions of a percent in the final product. They estimated that the product had 2% to 3% of silicone oil before application of the lubricant in the syringe. They report no adverse effects due to the extremely low levels of silicone oil. They further highlight that these additives are used in other industries that have human contact including food applications. They, however, recommend that users determine if these additives create a problem in their specific application.<sup>11</sup>

There have been many previous reports, especially in the diabetes literature, regarding the contamination of skin and insulin with silicone oil found on needles and syringes.<sup>12</sup> A granulomatous reaction was found in one series of three cases.<sup>13</sup> Miller et al<sup>14</sup> reported on the amount of silicone oil extruded from syringes after flushing with distilled water. They found that more silicone oil was flushed from 10-mL syringes when exhibiting accumulation of lubricant on the tips of plungers (10.7–11.3 mg) than when none was seen (0 mg). Most notably, the plunger tip was thought to have 24% of the silicone lubricant. This report also confirmed that washing the same syringe multiple times continued to provide an equal amount of silicone oil in each washing. Speculating that pumping the syringe back and forth caused more silicone oil to be added into the washings, Chantelau et al<sup>15</sup> in 1986

used syringes to draw insulin into a syringe and then pushed the plunger in to expel air droplets three times. They noted that 0.15 mg to 0.25 mg of silicone oil had been expelled from each syringe. Another report by Baldwin<sup>16</sup> speculated on how silicone oil became incorporated in insulin during vigorous pumping back and forth on the syringe. In the diabetes literature, there are also multiple instances when insulin contaminated with silicone oil was found to have less efficacy.<sup>16,17</sup>

Typically, to draw up a medication (e.g., ranibizumab or triamcinolone), a larger-bore needle is placed on the syringe, and the plunger is pulled back to withdraw more medication than is needed. Then the smaller-bore (e.g., 30-gauge) needle used for the intravitreal injection is placed on the syringe, and the plunger is pushed up to the amount needed, which also eliminates air droplets drawn up from the vial. If residual air droplets are seen, the syringe is tapped to force the droplets up toward the hub of the syringe. Compounded agents may have been subjected to being placed in more syringes, needles, and tubing, with more friction occurring between the agent and the syringe and needle.

On the basis of compelling evidence in the diabetes literature, the presence of silicone oil as a lubricant in our needle and syringes is most likely the source seen in our patients. Although the presence of silicone oil has not caused any adverse effects, there is a need to review the methods of injections and utilization of syringes to decrease the amount of silicone oil that is inadvertently injected. It has been previously reported that silicone oil when left in the eye for long periods (>12–18 months) can be engulfed by the trabecular meshwork and Müller cells of the retina.<sup>18</sup> Suggestions for reducing silicone oil contamination include pulling back the plunger as minimally as necessary to withdraw the drug to reduce the risk of unnecessary contamination by additional material. In addition, reducing the amount of manipulation and tubing that the drug is subjected to during repackaging or compounding may be important. It is also important to perform drug stability testing in new packaging, especially for prefilled syringes. The medication may interact with the silicone oil layer, and this may affect drug degradation. As previously discussed, silicone oil may detach from the syringe or plunger and form droplets in the medication. The use of syringes and needles with non-silicone-based lubricants is another option worth considering to eradicate this possible adverse effect.

Because this is a retrospective review of charts of patients seen in a busy clinic, it is possible that more patients had silicone oil droplets, which are difficult to see, than reported. The silicone oil droplets had been seen and noted incidentally when the patients were

examined with a 90-diopter or 78-diopter lens on a slit-lamp biomicroscope. The droplets were not specifically looked for. Therefore, we cannot adequately address the true prevalence of silicone oil droplets after intravitreal injections. These tiny droplets are difficult to see, and the amount of silicone oil is difficult to quantify; some droplets may be hidden from view anterior to the ora serrata. It is difficult to assess, on the basis of this case series, whether certain types of syringes are more likely to produce this adverse effect. Although we do have ultrasonographic evidence that this finding is consistent with silicone oil, we do not have any pathologic evidence, because no vitreous biopsies were done in any of our cases. However, we believe that this not necessary because there has been no effect on visual function to substantiate the risk of biopsy for these patients.

**Key words:** anti-vascular endothelial growth factor, bevacizumab (Avastin), droplet, intravitreal, injection, needle, pegaptanib, ranibizumab (Lucentis), silicone oil, syringe, triamcinolone.

## References

1. VEGF Inhibition Study in Ocular Neovascularization (VISION) Clinical Trial Group. Year 2 efficacy results of 2 randomized controlled clinical trials of pegaptanib for neovascular age-related macular degeneration. *Ophthalmology* 2006; 113:1508.
2. Rosenfeld PJ, Brown DM, Heier JS, et al. Ranibizumab for neovascular age-related macular degeneration. *N Engl J Med* 2006;355:1419–1431.
3. Brown DM, Kaiser PK, Michels M, et al. Ranibizumab versus verteporfin for neovascular age-related macular degeneration. *N Engl J Med* 2006;355:1432–1444.
4. Michels S, Prager F, Bakri SJ, Wachtlin J. Bevacizumab for ophthalmic diseases. *Expert Review of Ophthalmology* 2007; 2:369–378.
5. Ekdawi NS, Bakri SJ. Intravitreal triamcinolone and bevacizumab combination therapy for macular edema due to central retinal vein occlusion refractory to either treatment alone. *Eye* 2007;21:1128–1130.
6. Mohamed Q, McIntosh RL, Saw SM, et al. Interventions for central retinal vein occlusion: an evidence-based systematic review. *Ophthalmology* 2007;114:507–519.
7. Goff MJ, Jumper JM, Yang SS, et al. Intravitreal triamcinolone acetonide treatment of macular edema associated with central retinal vein occlusion. *Retina* 2006;26:896–901.
8. Gregori NZ, Rosenfeld PJ, Puliafito CA, et al. One-year safety and efficacy of intravitreal triamcinolone acetonide for the management of macular edema secondary to central retinal vein occlusion. *Retina* 2006;26:889–895.
9. Costarides AP, Alabata P, Bergstrom C. Elevated intraocular pressure following vitreoretinal surgery. *Ophthalmol Clin North Am* 2004;17:507–512.
10. Freund KB, Laud K, Eandi CM, Spaide RF. Silicone oil droplets following intravitreal injection. *Retina* 2006;26:701–703.

# Explore Litigation Insights

Docket Alarm provides insights to develop a more informed litigation strategy and the peace of mind of knowing you're on top of things.

## Real-Time Litigation Alerts



Keep your litigation team up-to-date with **real-time alerts** and advanced team management tools built for the enterprise, all while greatly reducing PACER spend.

Our comprehensive service means we can handle Federal, State, and Administrative courts across the country.

## Advanced Docket Research



With over 230 million records, Docket Alarm's cloud-native docket research platform finds what other services can't. Coverage includes Federal, State, plus PTAB, TTAB, ITC and NLRB decisions, all in one place.

Identify arguments that have been successful in the past with full text, pinpoint searching. Link to case law cited within any court document via Fastcase.

## Analytics At Your Fingertips



Learn what happened the last time a particular judge, opposing counsel or company faced cases similar to yours.

Advanced out-of-the-box PTAB and TTAB analytics are always at your fingertips.

## API

Docket Alarm offers a powerful API (application programming interface) to developers that want to integrate case filings into their apps.

## LAW FIRMS

Build custom dashboards for your attorneys and clients with live data direct from the court.

Automate many repetitive legal tasks like conflict checks, document management, and marketing.

## FINANCIAL INSTITUTIONS

Litigation and bankruptcy checks for companies and debtors.

## E-DISCOVERY AND LEGAL VENDORS

Sync your system to PACER to automate legal marketing.