

# Hypoxemia After Intraluminal Oxygen Line Obstruction During Cardiopulmonary Bypass

James A. Robblee, MD, Edward Crosby, MD, and Wilbert J. Keon, MD

Departments of Anaesthesia and Surgery, University of Ottawa Heart Institute, Ottawa Civic Hospital, Ottawa, Ontario, Canada

**A patient sustained an episode of hypoxemia during cardiopulmonary bypass. Investigation of the extracorporeal circuit after successful resolution of the problem showed that a white, crystalline substance later identified as mannitol occluded the oxygen supply line to a bubble oxygenator. The management and subsequent investigation of the problem are presented.**

*(Ann Thorac Surg 1989;48:575-6)*

The development and clinical utilization of extracorporeal cardiopulmonary bypass techniques constitute a major advance in modern medicine. In 50 years, procedures have advanced from the experimental laboratory to early clinical trials fraught with hazard and complexity to procedures that are common, generally safe, and effective. Clinical techniques have improved, as has the design of circuits and devices. The biomaterials in contact with the blood of the patient have also improved. At present, clinical use of blood oxygenators is generally safe. Although many different blood oxygenators are currently available, design defects do not appear to constitute a serious threat to patient safety. The incidence of harmful effects, errors, failures, or problems attributable to blood oxygenators is difficult to ascertain, but life-threatening complications are rare and episodic in nature. Considering the fundamental complexity of an extracorporeal circuit, the frequency of life-threatening complications is surprisingly low [1].

We present a case report, management, and subsequent investigation of a patient who developed a life-threatening complication during cardiopulmonary bypass; hypoxemia occurred because of obstruction of gas flow to a bubble oxygenator.

A 54-year-old man weighing 86 kg with triple-vessel coronary artery disease and left ventricular aneurysm underwent aortocoronary bypass grafting, left ventricular aneurysm resection, and insertion of intraaortic balloon pump. A Bentley BEN-10 B bubble oxygenator was used in the extracorporeal circuit. After an uneventful bypass, the patient was weaned at 70 minutes elapsed time. One gram of calcium chloride was administered to facilitate separation. Bypass had to be reinstated to permit repair of a distal graft anastomosis. At 50 minutes elapsed time

of the second bypass, the venous oxygen saturation suddenly decreased from 70% to 58%. The arterial blood was dark. Oxygen flow was increased from 2.5 to 6 L/min without improvement in color or saturation. The sound of gas being released through the pressure relief valve of the oxygen source was clearly audible. A decision was made to terminate bypass, and mechanical ventilation of the lungs with oxygen was started. Epinephrine (100 µg) was administered, and an infusion of dopamine (10 µg/kg/min) was started. The patient was separated from bypass, and adequate cardiac output was maintained with dopamine (10 µg/kg) and intraaortic balloon counterpulsation.

The oxygenator was examined after the procedure. A white crystalloid substance was obstructing the oxygen inlet port of the oxygenator. The length of the occlusion was 1 cm. Scattered deposits of the same material were visible on the walls of the oxygenator gas chamber and on the undersurface of the gas sparger plate. A sample of the material was subjected to infrared analysis and mass spectroscopy. A sagittal section of the oxygenator was obtained. Infrared analysis determined that the occlusive material was mannitol. This was confirmed by mass spectroscopy. Sagittal section of the oxygenator revealed that all gas and fluid chambers were intact and all fluid paths were patent.

These conditions were simulated in an unused discarded cardiopulmonary bypass circuit with a Bentley BEN-10 B bubble oxygenator. The circuit was primed with crystalloid solution. Mannitol was then added from the cardiotomy reservoir. The oxygen supply was disconnected at the source during the addition of mannitol. Mannitol flowed into the oxygen tubing. The line was reconnected, and oxygen flow was started. At five minutes, a white precipitate began to form (Fig 1). At 25 minutes, the precipitate was almost occlusive (Figs 2, 3).

## Comment

Hypoxemia during cardiopulmonary bypass may be a life-threatening event. Light anesthesia and inadequate muscle relaxation cause mild hypoxemia because of increased peripheral oxygen consumption [2]. Leaks in the oxygen supply line are a potential cause of hypoxemia, which may be mild or severe [3]. Oxygenator failure is a rare event, but design and manufacturing defects have been reported [1, 4]. Gas line obstruction is a potential cause of hypoxemia. Hypoxemia secondary to intraluminal obstruction of the oxygen supply has not been reported.

Accepted for publication Feb 15, 1989.

Address reprint requests to Dr Robblee, University of Ottawa Heart Institute, 4395 Jean Jacques Street, Ottawa, Ontario, Canada K1H 3L4.




Fig 1. Flocculant precipitate formed five minutes after oxygen flow in tubing containing mannitol was started.

association with cardiopulmonary bypass to enhance urine flow. Solutions of mannitol are chemically stable, but in concentrations of 15% or greater, mannitol may crystallize when exposed to low temperature or polyvinyl chloride surfaces. A heavy, white flocculant precipitate forms, acting as a nucleus for rapid rate crystallization. In our patient, 20% mannitol flowed into the oxygen tubing. This occurred at a time when the oxygen tubing was not connected to the oxygen source. The oxygen tubing was looped in such a way that the nadir of the tubing was lower than the cardiotomy return point of the oxygenator. The oxygen tubing was then properly connected, and gas

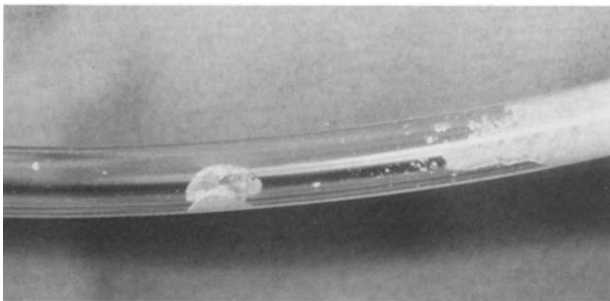


Fig 2. Near occlusion of oxygen tubing 25 minutes after oxygen flow was started.

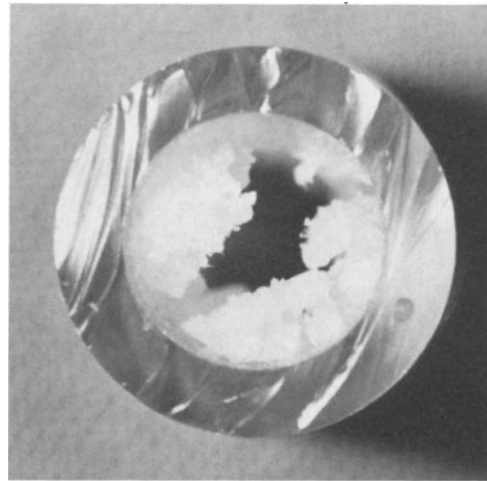


Fig 3. Cross-section of oxygen tubing at site of maximum precipitate formation.

flow was started through the tubing. Several hours after mannitol was added to the prime, crystallization occurred and occluded the oxygen tubing.

One may conclude from this near mishap that the routine preoperative check list of a cardiopulmonary bypass circuit should include a thorough examination of the oxygen supply line for leaks, disconnections, and the presence of substances in the tubing. Mannitol should be diluted before administration into the prime or should be administered into the circuit after cardiopulmonary bypass is started.

## References

1. Irish CL, Murkin JM, Cleland A, MacDonald JL, Mayer R. The influence of resting muscle tone on systemic oxygen consumption during hypothermic cardiopulmonary bypass. *Can Anaesth Soc J* 1988;35:S120.
2. Mortensen JD. Safety and efficacy of extracorporeal blood oxygenators: a review. *Med Instrum* 1978;12:128-32.
3. Gravlee GP, Wong AB, Charles DJ. Hypoxemia during cardiopulmonary bypass from leaks in the gas supply system. *Anesth Analg* 1985;64:649-50.
4. Warner SJ, Miller CD. Severe hypoxemia during cardiopulmonary bypass. *Anesthesiology* 1986;41:1266-7.