

RADIOLOGY

A MONTHLY JOURNAL DEVOTED TO CLINICAL RADIOLOGY AND ALLIED SCIENCES

EDITOR

Howard P. Doub, M.D.
Detroit, Michigan



Volume 85

July-December 1965

Owned and Published as its Official Journal by
THE RADIOLOGICAL SOCIETY OF NORTH AMERICA

Copyrighted, 1965, by the
Radiological Society of North America, Inc.

a monthly journal devoted to clinical radiology and allied sciences
PUBLISHED BY THE RADIOLOGICAL SOCIETY OF NORTH AMERICA, INC.

Guided Catheterization of the Bronchial Arteries

Part I: Technical Considerations¹

MANUEL VIAMONTE, JR., M.D., RAYMOND E. PARKS, M.D., and WILLIAM M. SMOAK, III, M.D.

SELECTIVE catheterization of small vascular branches is easily accomplished since the development of especially constructed catheters with minute tips, optimal torque control, and tip deflection by external manipulation (5). We have called this technic "guided angiography." Exploration of the bronchial arteries by this method has been prompted by recognition of the part these small arteries play in diseases of the bronchial tree and mediastinal organs and in abnormalities of the pulmonary arterial circulation. The procedure and preliminary findings in guided catheterization of the bronchial arteries were reported earlier (6). Our experience with a larger group of cases has enhanced our knowledge and technic, and it is the intent of this paper to expand on these technical considerations and mention some of the pitfalls encountered in the procedure and its interpretation.

TECHNICAL CONSIDERATIONS

Despite the variability in number and site of origin (Fig. 1), selective catheterization of bronchial arteries is easily accomplished, especially with the catheter-deflector assembly previously mentioned.

¹ From the Department of Radiology, University of Miami School of Medicine, Jackson Memorial Hospital, Miami, Fla. (M. V., Associate Professor of Radiology; R. E. P., Professor and Chairman of Radiology; W. M. S., Instructor of Radiology).

Presented in part at the Fiftieth Annual Meeting of the Radiological Society of North America, Chicago, Ill., Nov. 29-Dec. 4, 1964.

This work has been sponsored in part by NIH Grant No. HE 08546-01A1 and the American Cancer Society (W. M. S.).

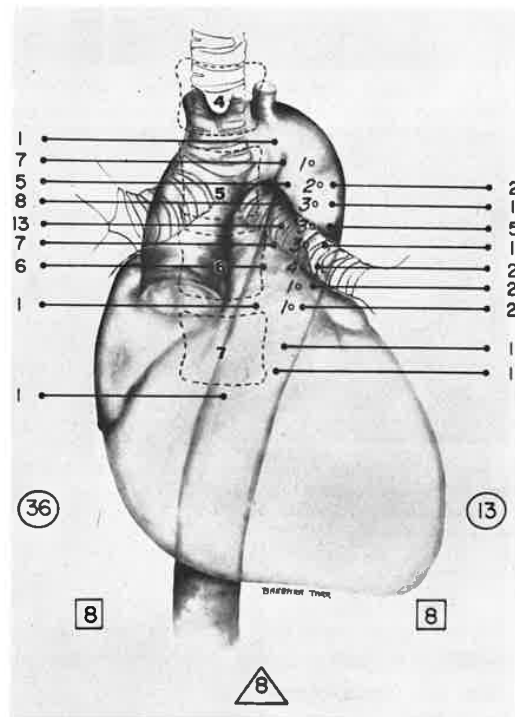


Fig. 1. Diagram showing levels of origin of the right and left bronchial arteries and of common trunks (central circles) that were studied. Lateral circles indicate the number of lesions studied on each side. In the squares are the number of bilateral lesions. In the triangles, the number of midline lesions is indicated.
NOTE: First 71 studies.

New Instruments for Catheterization and Angiocardiography¹

BJORN NORDENSTRÖM, M.D.

CONTINUOUS improvements of the instruments used in angiocardiography are of great importance for the extension of possibilities of examination and for the safety of such examination.

CATHETERS FOR THE INJECTION OF CONTRAST MEDIUM INTO THE RIGHT AND LEFT VENTRICLES

Some of the risks connected with the selective injection of contrast medium into the heart cavities have been discussed in earlier works (1, 3). Under certain conditions quick injections of contrast fluid into the heart cavities may result in a perforation of the heart wall by the jets of contrast material (4). This appears to be the case when a catheter with open terminal hole is used and its tip is resting against the wall of the heart. The axially flowing stream of fluid through the tip of the catheter seems to have considerable penetrative force. Further, the stream through the terminal hole may easily cause an appreciable recoil of the catheter, so that the contrast medium may be deposited at a point in the heart or in a vessel other than that intended. The recoil of the catheter, if it takes place in a ventricle, may also give rise to rhythm disturbances of the heart.

Such considerations led to the construction of the so-called recoil-proof catheter (2) with multiple lateral holes near the completely closed tip. In this way it was possible to practically eliminate the recoil of the catheter even with a quick injection of contrast medium. Because the tip of the catheter is closed, however, it is not possible to introduce it with the percutaneous catheterization technic of Seldinger (5). As the percutaneous catheterization technic has offered many advantages, the author has in recent years been using catheters with terminal hole and multiple

lateral holes near the tip, while the recoil-proof catheter with closed tip has been used only sporadically.

A possibility of closing the terminal hole of a catheter introduced percutaneously (Seldinger technic) has been communicated by Tornvall (6). He introduces in the lumen of the catheter a steel wire, terminally provided with a knob or cylinder occluding the terminal hole. The drawbacks of this device are: first, the wire occupies a part of the lumen, with consequent increased resistance to the injection of contrast medium and, second, the catheter will acquire a stiffness or rigidity which may imply a considerable disadvantage when introduced into a heart cavity. It would seem that catheters with too much stiffness cause rhythm disturbances more easily than do soft ones. They are probably also more apt to bring about valvular insufficiency through displacement of a valvular leaflet.

In order, if possible, to combine the advantages of the percutaneous catheterization technic with those of the recoil-proof catheter with closed tip, a new catheter made of radiodense Teflon has been constructed (Fig. 1, A). This is in the first place intended to be used for the injection of contrast medium into the right ventricle. It has a terminal hole and, about 6 cm proximal to this, a lateral hole. Behind the latter, the lumen of the catheter is occluded over a section a good centimeter in length. Proximal to this blocking the catheter is cleft longitudinally with two slits about 1.5 cm in length.

The catheter is introduced percutaneously in the fashion previously described by the author for the percutaneous introduction of balloon catheters (3). After the puncture of the femoral vein and the introduction of a flexible metal guide into the

¹From the Department of Roentgenology (Director: Björn Nordenström), Thoraxkliniken, Karolinska Sjukhuset, Stockholm, Sweden. Accepted for publication in March 1965.




Fig. 1. Recoil-proof catheter for percutaneous catheterization.

A. The catheter is intended for the injection of contrast medium into the right ventricle. The tip of the catheter is placed in the pulmonary artery and the injection of contrast fluid is made *via* two large slits, which are placed within the right ventricle. In front of the slits the lumen of the catheter is occluded. By this construction the risks of intramural contrast injection in the ventricular wall are practically eliminated, nor can disturbances in rhythm be caused by the catheter tip, which is placed in the pulmonary artery.

B. For the injection of contrast medium in the left ventricle a Teflon catheter is used. The instrument is provided with long slits which make the tip soft and prevent the occurrence of hard, thin, perforating jets of contrast fluid, such as may be frequently observed when catheters with small multiple lateral holes are employed.

vessel, the instrument is slipped on to the guide as shown in Figure 1, A. Its introduction into the vessel with the help of the guide is then easy. The catheter is provided with a relatively long tip to facilitate its exchange if required. In this event, it is necessary only to withdraw the catheter to the point at which the proximal lateral hole is visible in the puncture-hole in the skin. A new guide may then be introduced into the lumen of the vessel, after which the catheter may be withdrawn and a new one introduced with the help of the mandrin in place.

The intention here is that the tip of the catheter shall be pushed up to the pulmonary artery, while the slit-openings are placed in the right ventricle. When the tip of a heart catheter is resting in the right or left ventricle there is a tendency toward disturbances in rhythm; these generally cease when the tip of the instrument is introduced into the pulmonary artery. For this reason there may sometimes be an

advantage in injecting contrast medium into the ventricle with the tip of the catheter remaining in the pulmonary artery. With this device it should, furthermore, be possible to eliminate the risks of contrast injection into the myocardium. The catheter cannot be placed in any trabecular pocket or be wedged fast in the apex of the right ventricle. When the ventricle contracts around the catheter, the risk of perforation of the heart wall by the injection should be minimal. Because of the strong Teflon material relatively long slits are possible instead of small lateral holes. This reduces the risk of hard, thin, perforating jets of contrast medium.

The above-described catheter cannot be used for the retrograde catheterization of the left ventricle from the aorta, as the distance from the tip of the catheter to the slits is too great. In case of retrograde catheterization of the left ventricle with injection of contrast medium into the ventricle, a modified, simpler catheter has been

Explore Litigation Insights

Docket Alarm provides insights to develop a more informed litigation strategy and the peace of mind of knowing you're on top of things.

Real-Time Litigation Alerts



Keep your litigation team up-to-date with **real-time alerts** and advanced team management tools built for the enterprise, all while greatly reducing PACER spend.

Our comprehensive service means we can handle Federal, State, and Administrative courts across the country.

Advanced Docket Research



With over 230 million records, Docket Alarm's cloud-native docket research platform finds what other services can't. Coverage includes Federal, State, plus PTAB, TTAB, ITC and NLRB decisions, all in one place.

Identify arguments that have been successful in the past with full text, pinpoint searching. Link to case law cited within any court document via Fastcase.

Analytics At Your Fingertips



Learn what happened the last time a particular judge, opposing counsel or company faced cases similar to yours.

Advanced out-of-the-box PTAB and TTAB analytics are always at your fingertips.

API

Docket Alarm offers a powerful API (application programming interface) to developers that want to integrate case filings into their apps.

LAW FIRMS

Build custom dashboards for your attorneys and clients with live data direct from the court.

Automate many repetitive legal tasks like conflict checks, document management, and marketing.

FINANCIAL INSTITUTIONS

Litigation and bankruptcy checks for companies and debtors.

E-DISCOVERY AND LEGAL VENDORS

Sync your system to PACER to automate legal marketing.