
Grossman & Baim's Cardiac Catheterization, Angiography, and Intervention

EIGHTH EDITION

EDITOR

MAURO MOSCUCCI, MD, MBA

Professor of Medicine
Chairman, Department of Medicine (Acting)
Chief, Cardiovascular Division
University of Miami Miller School of Medicine
Miami, Florida



Wolters Kluwer | Lippincott Williams & Wilkins

Health

Philadelphia • Baltimore • New York • London
Buenos Aires • Hong Kong • Sydney • Tokyo

Acquisitions Editor: Julie Goolsby
Product Manager: Leanne Vandetty
Production Project Manager: David Orzechowski
Senior Manufacturing Manager: Beth Welsh
Design Coordinator: Joan Wendt
Production Service: Integra Software Services Pvt. Ltd

© 2014 by LIPPINCOTT WILLIAMS & WILKINS, a WOLTERS KLUWER business
Two Commerce Square
2001 Market Street
Philadelphia, PA 19103 USA
LWW.com

7th edition © 2006 by LIPPINCOTT WILLIAMS & WILKINS
6th edition © 2000 by LIPPINCOTT WILLIAMS & WILKINS
5th edition © 1996 by WILLIAMS & WILKINS

All rights reserved. This book is protected by copyright. No part of this book may be reproduced in any form by any means, including photocopying, or utilized by any information storage and retrieval system without written permission from the copyright owner, except for brief quotations embodied in critical articles and reviews. Materials appearing in this book prepared by individuals as part of their official duties as U.S. government employees are not covered by the above-mentioned copyright.
Printed in China

Library of Congress Cataloging-in-Publication Data

Cardiac catheterization, angiography, and intervention.

Grossman & Baim's cardiac catheterization, angiography, and intervention / editor, Mauro Moscucci, MD, MBA, professor of medicine, chairman, Department of Medicine, University of Miami Miller School of Medicine, Miami, Florida. — Eighth edition.

pages cm

Includes bibliographical references and index.

ISBN 978-1-4511-2740-9 (hardback)

1. Cardiac catheterization. 2. Angiography. I. Moscucci, Mauro, editor of compilation. II. Title. III. Title: Grossman and Baim's cardiac catheterization, angiography, and intervention.

RC683.5.C25C38 2013

616.1'20754—dc23

2013025399

Care has been taken to confirm the accuracy of the information presented and to describe generally accepted practices. However, the authors, editors, and publisher are not responsible for errors or omissions or for any consequences from application of the information in this book and make no warranty, expressed or implied, with respect to the currency, completeness, or accuracy of the contents of the publication. Application of the information in a particular situation remains the professional responsibility of the practitioner.

The authors, editors, and publisher have exerted every effort to ensure that drug selection and dosage set forth in this text are in accordance with current recommendations and practice at the time of publication. However, in view of ongoing research, changes in government regulations, and the constant flow of information relating to drug therapy and drug reactions, the reader is urged to check the package insert for each drug for any change in indications and dosage and for added warnings and precautions. This is particularly important when the recommended agent is a new or infrequently employed drug.

Some drugs and medical devices presented in the publication have Food and Drug Administration (FDA) clearance for limited use in restricted research settings. It is the responsibility of the health care provider to ascertain the FDA status of each drug or device planned for use in their clinical practice.

To purchase additional copies of this book, call our customer service department at (800) 638-3030 or fax orders to (301) 223-2320. International customers should call (301) 223-2300.

Visit Lippincott Williams & Wilkins on the Internet at: LWW.com. Lippincott Williams & Wilkins customer service representatives are available from 8:30 am to 6:00 pm, EST.

10 9 8 7 6 5 4

RRS1903

Contents

Contributors	vii
Preface to the Eighth Edition	xi
Preface to the Website to the Eighth Edition	xiii
Acknowledgments	xv

SECTION I GENERAL PRINCIPLES 1

1. Cardiac Catheterization History and Current Practice Standards 1
Mauro Moscucci
2. Cineangiographic Imaging, Radiation Safety, and Contrast Agents 17
Stephen Balter and Mauro Moscucci
3. Integrated Imaging Modalities in the Cardiac Catheterization Laboratory 44
Robert A. Quaife and John D. Carroll
4. Complications 77
Mauro Moscucci
5. Adjunctive Pharmacology for Cardiac Catheterization 106
Kevin Croce and Daniel I. Simon

SECTION II BASIC TECHNIQUES 139

6. Percutaneous Approach, Including Transseptal and Apical Puncture 139
Claudia A. Martinez and Mauro Moscucci
7. Radial Artery Approach 170
Mauricio G. Cohen and Sunil V. Rao
8. Cutdown Approach: Brachial, Femoral, Axillary, Aortic and Transapical 191
Ronald P. Caputo, G. Randall Green, and William Grossman
9. Diagnostic Catheterization in Childhood and Adult Congenital Heart Disease 208
Gabriele Egidy Assenza, James E. Lock, and Michael J. Landzberg

SECTION III HEMODYNAMIC PRINCIPLES 223

10. Pressure Measurement 223
Mauro Moscucci and William Grossman
11. Blood Flow Measurement: Cardiac Output and Vascular Resistance 245
Mauro Moscucci and William Grossman
12. Shunt Detection and Quantification 261
William Grossman and Mauro Moscucci
13. Calculation of Stenotic Valve Orifice Area 272
Blase A. Carabello and William Grossman

14. Pitfalls in the Evaluation of Hemodynamic Data 284
Zoltan G. Turi

SECTION IV ANGIOGRAPHIC TECHNIQUES 295

15. Coronary Angiography 295
Mauro Moscucci
16. Coronary Artery Anomalies 335
Paolo Angelini and Jorge Monge
17. Cardiac Ventriculography 354
Mauro Moscucci and Robert C. Hendel
18. Pulmonary Angiography 370
Kyung Cho and Nils Kucher
19. Angiography of the Aorta and Peripheral Arteries 399
Michael R. Jaff, John Rundback, and Kenneth Rosenfield

SECTION V EVALUATION OF CARDIAC FUNCTION 431

20. Stress Testing During Cardiac Catheterization: Exercise, Pacing,
and Dobutamine Challenge 431
William Grossman and Mauro Moscucci
21. Measurement of Ventricular Volumes, Ejection Fraction,
Mass, Wall Stress, and Regional Wall Motion 456
Michael A. Fifer and William Grossman
22. Evaluation of Systolic and Diastolic Function of the Ventricles
and Myocardium 467
William Grossman and Mauro Moscucci
23. Evaluation of Tamponade, Constrictive, and Restrictive Physiology 489
Mauro Moscucci and Barry A. Borlaug

SECTION VI SPECIAL CATHETER TECHNIQUES 505

24. Evaluation of Myocardial and Coronary Blood Flow
and Metabolism 505
Morton J. Kern and Michael J. Lim
25. Intravascular Imaging Techniques 545
Yasuhiro Honda, Peter J. Fitzgerald, and Paul G. Yock
26. Endomyocardial Biopsy 576
Sandra V. Chaparro and Mauro Moscucci
27. Percutaneous Circulatory Support: Intra-aortic Balloon Counterpulsation,
Impella, TandemHeart, and Extracorporeal Bypass 601
Daniel Burkhoff, Mauro Moscucci, and Jose P.S. Henriques

SECTION VII INTERVENTIONAL TECHNIQUES 627

28. Percutaneous Balloon Angioplasty and General Coronary Intervention 627
Abhiram Prasad and David R. Holmes
29. Atherectomy, Thrombectomy, and Distal Protection Devices 665
Robert N. Piana and Jeffrey J. Popma

30. Intervention for Acute Myocardial Infarction 697
William O'Neill
31. Coronary Stenting 710
Ajay J. Kirtane and Gregg W. Stone
32. General Overview of Interventions for Structural Heart Disease 760
Mauro Moscucci, John D. Carroll, and John G. Webb
33. Percutaneous Therapies for Valvular Heart Disease 772
Ted Feldman and Mauro Moscucci
34. Peripheral Intervention 805
Mehdi H. Shishehbor and Samir R. Kapadia
35. Intervention for Pediatric and Adult Congenital Heart Disease 838
Robert J. Sommer
36. Cardiac Cell-Based Therapy: Methods of Application and Delivery Systems 871
Joshua M. Hare, Arnon Blum, and Alan W. Heldman
37. Aortic Endovascular Grafting 891
Arash Bornak, Gilbert R. Upchurch, and Omaid C. Velazquez
38. Pericardial Interventions: Pericardiocentesis, Balloon Pericardiotomy, and Epicardial Approach to Cardiac Procedures 904
Mauro Moscucci and Juan F. Viles-Gonzalez
39. Interventions for Cardiac Arrhythmias 921
Haris M. Haqqani and Francis E. Marchlinski

SECTION VIII CLINICAL PROFILES 943

40. Profiles in Valvular Heart Disease 943
Ted Feldman, William Grossman, and Mauro Moscucci
41. Profiles in Coronary Artery Disease 970
Robert N. Piana and Aaron Kugelmass
42. Profiles in Pulmonary Hypertension and Pulmonary Embolism 991
Scott H. Visovatti and Vallerie V. McLaughlina
43. Profiles in Cardiomyopathy and Heart Failure 1011
James C. Fang and Barry A. Borlaug
44. Profiles in Pericardial Disease 1045
John F. Robb, Roger J. Laham, and Mauro Moscucci
45. Profiles in Congenital Heart Disease 1060
Gabriele Egidy Assenza, Robert J. Sommer, and Michael J. Landzberg
46. Profiles in Peripheral Arterial Disease 1078
Christopher J. White and Stephen R. Ramee

Index 1113

7

Radial Artery Approach

MAURICIO G. COHEN and SUNIL V. RAO

INTRODUCTION

In 1989, Lucien Campeau published his successful series of 100 coronary angiographies performed via the left radial artery with minimal occurrence of complications.¹ Subsequently in 1993, Kiemeneij performed percutaneous coronary interventions (PCI) using 6F guiding catheters in a time when most interventional procedures were performed with larger 8F catheters.² Since then, transradial access (TRA) has continued to gain popularity in some regions of Europe, Canada, South America, Japan, and other sites outside of the United States where TRA is used in more than 60% of the cases.³ The most compelling reason for adopting TRA is the increased patient safety that results from the virtual elimination of access site bleeding and vascular complications. In addition, TRA is associated with early sheath removal, improved patient comfort, faster recovery, and lower costs in comparison with transfemoral access.⁴⁻⁶ However, a relatively steep learning curve, increased radiation exposure, incompatibility of the radial artery with sheaths larger than 6F required for large rotablator burrs and complex bifurcation stenting, and higher access failure rates have been cited as reasons for not systematically adopting TRA.⁷⁻¹¹ An early analysis of the American College of Cardiology National Cardiovascular Data Registry (ACC/NCDR) of procedures performed between 2004 and 2007 demonstrated a minimal use of TRA in the United States, with almost 90% of centers performing less than 2% of cases using the radial artery approach.¹² However, interventional cardiologists have been more open to change and TRA has gained renewed momentum in the United States with the recognition of access site bleeding as a predictor of adverse outcomes post-PCI,¹³ wider access to training opportunities, and the inception of dedicated micropuncture needles, hydrophilic-coated sheaths, and radial hemostasis devices. A more recent analysis including 1,776,625 patients treated at more than 1,200 U.S. hospitals demonstrated a significant uptake in TRA use from 1.3% in 2007 to 12.7% in 2011.¹⁴

The ACC/AHA/SCAI guidelines now include TRA as a class IIA recommendation with a level of evidence A to decrease access site complications.¹⁵ A class IIA recommendation for TRA is also included in the most recent European guidelines for the management of acute ST segment elevation myocardial infarction in the setting of primary PCI, if performed by an experienced radial operator.¹⁶

ANATOMICAL CONSIDERATIONS

The radial artery arises together with the ulnar artery from the bifurcation of the brachial artery just below the bend of the elbow. The radial artery passes along the lateral side of the forearm from the neck of the radius to the forepart of the styloid process in the wrist and is smaller in caliber than the ulnar artery. It then winds backward, around the lateral side of the carpus. The distal portion of the artery in the forearm is superficial, being covered by the integument and the superficial and deep fascia, lying between the tendons of the brachioradialis and flexor carpi radialis over the prominence of the radius. With an average diameter of 2.8 mm in females and 3.1 mm in males, the radial artery is compatible with 6F sheaths. The artery is accompanied by a pair of venae comitantes throughout its whole course, which can be used to perform right heart catheterization (RHC).¹⁷⁻¹⁹

Several anatomic characteristics explain the marked safety advantage of the radial artery over the femoral artery approach. The flat, bony prominence of the radius provides ease of compression and hemostasis after sheath removal; the vast collateralization of the radial artery through the palmar arch prevents ischemia of the hand; because the puncture site is not overlying a joint, motion of the hand or the wrist does not increase the risk of bleeding; and because of the absence of major adjacent nerve structures, there is no risk of neurologic sequelae.²⁰ In contrast, the ulnar artery is deep lying mobile, adjacent to the ulnar nerve, and consequently no

ideal for first-line vascular access. Despite this, ulnar access has been used successfully for coronary procedures, without evidence of an increased rate of complications when compared with TRA.²⁴ The ulnar artery should not be used after a failed ipsilateral radial attempt because of a possible small risk of complete obstruction of circulation to the hand.

The interventional cardiologist should be aware of relatively uncommon anatomic anomalies that may impede the advancement of catheters to the aorta or increase the risk of failure or complications. Variations include tortuous radial configurations, stenoses, hypoplasia, radioulnar loops, aberrant right subclavian artery (arteria lusoria), and abnormal origin of the radial artery.^{22,23} In a series of 1,540 transradial procedures, anatomic anomalies were found in about 15% of cases. A high radial artery origin at the level of the mid or upper humerus was found in 7% of cases and was associated with a failure rate of 4.6%, a loop in the proximal radial artery was found in 2.3% of cases and associated with a high failure rate of 37.1%, severe tortuosity was found in 2%, and other miscellaneous anomalies in 2.5% of cases. These anomalies are usually unilateral, therefore vascular access crossover to the left radial artery may be indicated in cases of extreme tortuosity or angulated radial loops.²³ Significant subclavian or brachiocephalic tortuosity is present in about 10% of cases and is usually associated with advanced age, short stature, and long-standing history of hypertension. However, subclavian tortuosity is rarely a cause of procedural failure because it can be easily negotiated by the use of deep inspiration or supportive guidewires.¹¹ In rare cases (<1%), the right subclavian artery arises directly from the distal segment of the posterior aspect of the aortic arch and has a retroesophageal course toward the right upper extremity. This anomaly is known as arteria lusoria and represents a formidable challenge for advancing a catheter from the subclavian artery to the ascending aorta. This anomaly is mostly asymptomatic but can be associated with dysphagia.²²

TECHNICAL ASPECTS

Preprocedure Assessment—Testing for Dual Circulation to the Hand

All patients undergoing TRA procedures in the catheterization laboratory should be assessed and undergo preparation according to a standardized protocol. Depending on the operator's preference, the groins can be prepped along with the wrists. Placement of intravenous lines in the vicinity of the wrist should be avoided. Sedation is strongly recommended to decrease catecholamine release that can potentially contribute to radial spasm.

There is significant variability in the vascular anatomy of the hand. The superficial palmar arch that connects the ulnar and radial arteries is complete in approximately 80% of cases and the predominant blood supply to the hand is

thought to be from the ulnar artery in the majority of cases.²⁴ In 1929, Edgar Van Nuys Allen introduced a "compression test" to diagnose arterial occlusion resulting from thromboangiitis obliterans or Buerger disease. The test consists of simultaneously compressing the ulnar and the radial arteries at the level of the wrist for approximately 1 or 2 minutes, the patient closes the hand tightly to squeeze as much blood out as possible, then quickly opens the hand and extends the fingers; then the operator releases compression of the ulnar artery and waits for the hand to regain color. In individuals with integrity of the hand circulation and a patent palmar arch, the pallor of the hand is quickly replaced by blushing of higher intensity than normal in about 5 to 9 seconds. Because the Allen's test is largely subjective and yields more than 30% of falsely abnormal results, Barbeau and coworkers modified the test by attaching a pulse oximeter to the thumb to record oxygen saturation and plethysmography. In a study including 1,010 patients, Barbeau and colleagues described four reading patterns: no damping of the pulse waveform immediately after 2 minutes of radial compression, positive oximetry (Type A, frequency 15%); damping of the pulse waveform and positive oximetry, followed by complete recovery within 2 minutes of compression, (Type B, frequency 75%); loss of pulse waveform, negative oximetry, with partial progressive recovery of the pulse waveform and oximetry within 2 minutes of compression (Type C, frequency 5%); loss of pulse waveform, negative oximetry, without recovery of either pulse waveform or oximetry after 2 minutes of compression (Type D, frequency 5%) (Figure 7.1). After analyzing these patterns in the right and left wrists of the study participants, only 1.5% showed a bilateral Type D pattern and these patients did not undergo TRA procedures. In summary, this study suggests that almost all patients are eligible for TRA procedures without risk of ischemic complications to the hand.²⁵ Some operators have challenged the utility of testing the collateral circulation of the radial artery, stating that the presence of a rich collateral system and the presence of interosseous branches that supply circulation to the hand could possibly allow to tolerate concomitant radial and ulnar artery occlusion.²⁶ In addition, there is no evidence indicating that the modified Allen's test predicts hand ischemia after TRA procedures. However, as part of the catheterization laboratory routine in most sites, a modified Allen's test using pulse oximetry and plethysmography is usually performed and the results documented.

Patient Positioning—Right versus Left Radial Access

TRA can be performed through the left or the right radial artery. Due to ergonomic considerations, most operators prefer using right TRA. Regardless of the side of choice, a comfortable position for the patient and the operator is crucial for successfully performing TRA procedures. The patient is

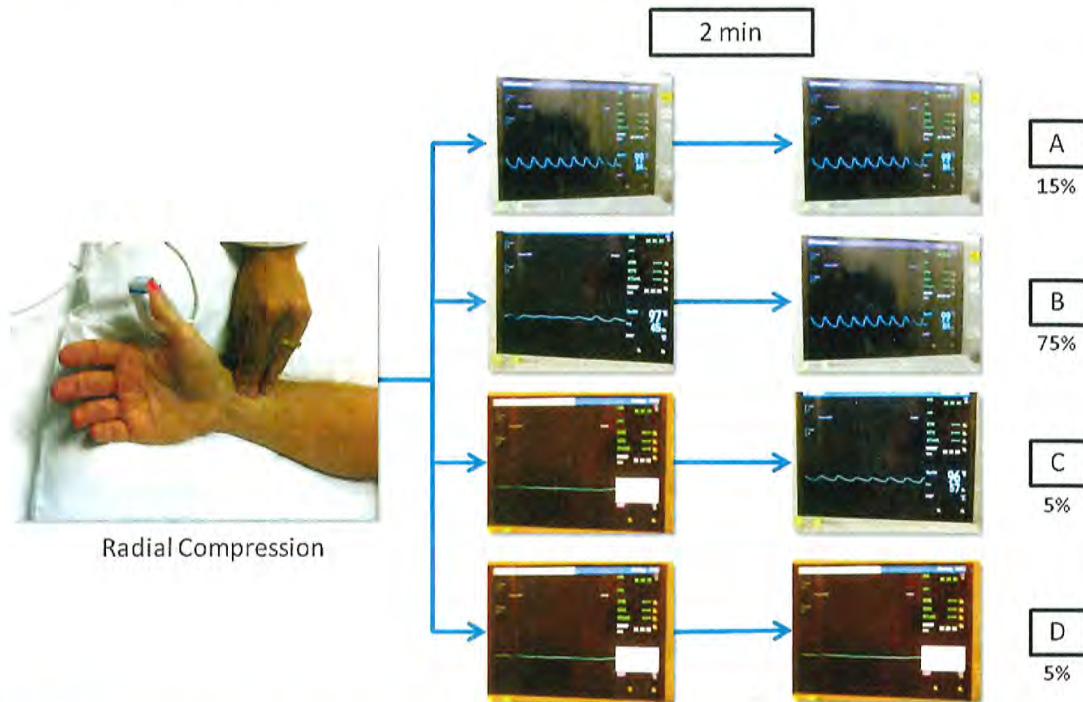


Figure 7.1 Testing for dual circulation to the hand. The Barbeau Grading System for assessment of collateral circulation of the palmar arch. The presence of an arterial waveform on plethysmography (even if delayed or with reduced amplitude) and an oxygen saturation above 90% (Grades A, B, and C) confirm the presence of dual circulation to the hand.

positioned supine on the angiographic table. With right-sided TRA, an arm board extension is attached to the right hand side of the table. Importantly, there should be a platform that extends from the distal portion of the patient's hand to the table controls so that equipment can be placed in this area. Arm boards are commercially available in different shapes and designs. Many laboratories have opted for trapezoid-shaped acrylic glass board, with the narrow end tucked under the mattress at the shoulder level and the broad area at the wrist level (Figure 7.2). The patient's right arm is placed on the board and abducted at a 30° angle. The right wrist is placed in a hyperextended position using commercially available splints or a rolled towel behind the wrist with the fingers taped to the arm board. A pulse oximeter probe can be placed in the right thumb for continuous monitoring of the circulation to the hand throughout the procedure (Figure 7.3). Both groins may be prepped as well, depending on the anticipated need for femoral access.

For left TRA, the setup is completely different and varies widely across catheterization laboratories. As with right TRA, the operator stands on the right side of the patient for left TRA to avoid disruption of the traditional laboratory setup.

The patient is positioned supine on the table and a custom arm rest, made of foam or pillow material, is attached to the left side of the table to elevate and pronate the left arm and guide the forearm toward the midsection of the patient's body and place the wrist over the leg where it can be strapped to a splint (Figure 7.2).

It has been shown that the prevalence of subclavian tortuosity and radial loops is three times higher in the right upper extremity.²⁷ With right TRA the catheter has to pass through the right subclavian artery and the brachiocephalic trunk before reaching the aortic root. These two areas of bifurcation can increase technical difficulty, especially when these vessels are atherosclerotic, tortuous, and calcified. Since the left subclavian artery arises directly from the aorta, the path followed by the catheter in the left radial route into the ascending aorta is more straightforward, often resulting in less complex catheter manipulation. In addition, left TRA should be strongly considered in patients who have undergone coronary artery bypass grafting (CABG), because it provides direct access to the left internal mammary artery (LIMA). Certainly, the LIMA can also be cannulated from the right radial route, but this

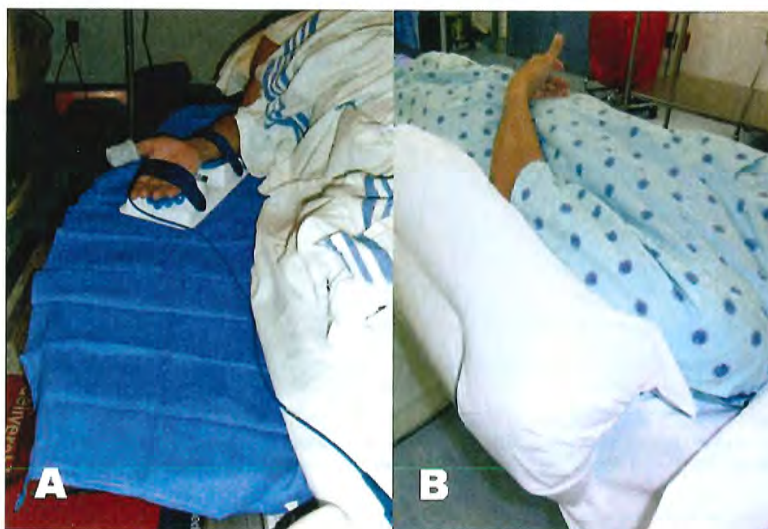

Figure 7.2 Positioning of the arm for right or left radial access. **A.** The right arm is placed on the board abducted at a 30° angle. **B.** The left arm rest on a large pillow placed on a regular arm board that guides the forearm towards the midsection of the patient's body, placing the left wrist on top of the left groin.

is significantly more challenging from a technical standpoint with a potential risk of embolic stroke due to catheter manipulation and exchanges in the aortic arch. Randomized data comparing right versus left radial access suggested that using left TRA during the learning curve may be advantageous as it allows novice operators to acquire the skills and confidence required for transradial procedures more quickly than the right radial route. In the TALENT trial (Transradial Approach [Left versus. Right] and Procedural Times during Percutaneous Coronary Procedures) 1,500 patients were randomized to right or left TRA. The study found that among trainees, left TRA was associated with a significantly shorter learning curve, with progressive reductions in cannulation and fluoroscopy times as the operator volume increased, compared to right TRA.^{28,29}

Radial Puncture

There are a number of TRA kits available in the market. In general, these kits include a micropuncture needle, a short 0.018 to 0.021 inch wire, and an arterial sheath with or without hydrophilic coating of shorter (10 to 13 cm) or longer (23 cm) length. Some operators advocate the use of longer sheaths to avoid difficulties with catheter manipulation should spasm occur, but a randomized trial comparing sheath lengths on arterial spasm showed no effect of longer sheaths on reducing spasm.³⁰ On the other hand, hydrophilic coating allows easier sheath removal and is clearly associated with less spasm and patient discomfort.³¹ However, in the past decade, Kozak and colleagues reported sterile abscesses in the wrist after the use of a particular transradial sheath brand. These abscesses were

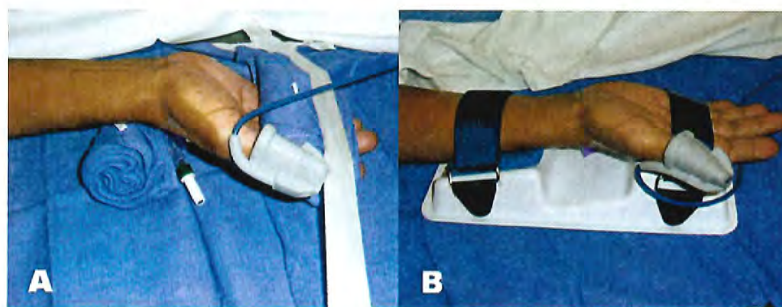


Figure 7.3 Positioning of the hand for transradial access. **A.** The hand is hyperextended with use of a rolled towel behind the wrist and tape holding the fingers, **B.** or with use of a dedicated positioning splint.

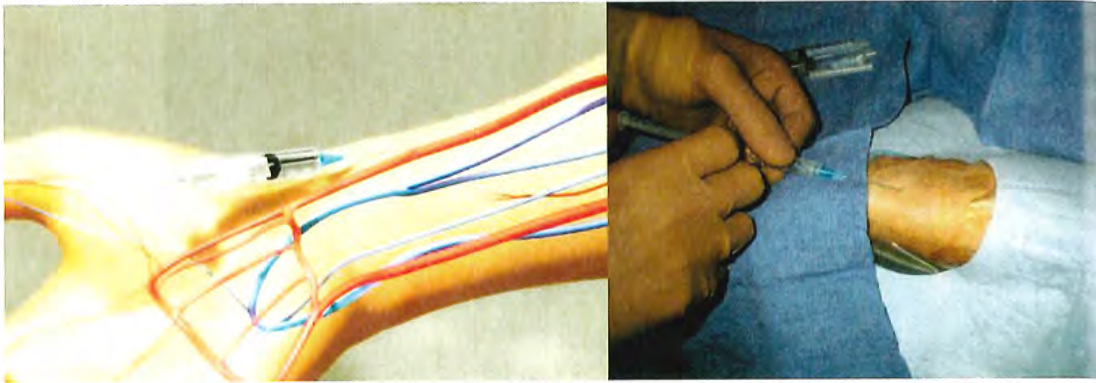


Figure 7.4 Transradial access technique (Step 1). After sterile preparation and draping, the wrist area is locally anesthetized with lidocaine using a 25G needle and a small 3 cc syringe.

later found to be a foreign-body reaction to the hydrophilic coating of the sheaths.³² Conservative management ruling out the presence of infection, local wound care with drainage in case of abscess formation, and reassurance are recommended for the management of this complication. Sterile abscesses are rarely found in contemporary practice as the hydrophilic coating causing the problem has been modified, although a recent isolated case of sterile abscess has been reported with new sheaths.³³ A recent study randomized 790 patients undergoing TRA PCI in a 2×2 factorial design to shorter (13 cm) or longer (23 cm) sheaths with or without hydrophilic coating. Hydrophilic-coated sheaths were associated with a significant reduction in radial spasm (19.0% versus 39.9%, $P < 0.001$) and patient discomfort (15.1% versus 28.5%, OR 2.27, $P < 0.001$), whereas sheath length did not have any effect in the occurrence of spasm or patient discomfort.³⁰ In addition, the operator may consider using smaller diameter sheaths as 5F sheaths are associated with lower incidence of radial artery

occlusion (RAO) than 6F sheaths.³⁴ Therefore, in current practice, shorter 5F hydrophilic-coated sheaths are preferred.

It is important to administer sedation to avoid the release of catecholamines associated with the emotional stress and fear that patients usually experience before the procedure, which can contribute to radial artery spasm. The site of access is approximately 2 cm proximal to the radial styloid process, not at the wrist. The radial artery is most superficial in this area. Once the patient is prepped in sterile fashion, this area is anesthetized with approximately 2 to 3 cc of 1% lidocaine injected with a small syringe and a 25G needle (Figure 7.4). Usually, the arterial puncture is performed with either a short 2.5 cm, stainless steel, 21G needle or a micropuncture IV catheter that consists of a fine metal needle and a 22G Teflon catheter that allow the passage of a 0.018 to 0.021 inch guidewire. While feeling the pulse with one hand, the operator advances the needle into the radial artery at a 30° angle with the other hand (Figure 7.5). Most operators prefer one of two different




Figure 7.5 Transradial access technique—front wall technique (Step 2). With the front wall technique, a short 2.5 cm 21G stainless-steel needle is used to puncture the radial artery.




Figure 7.6 Transradial access technique—front wall technique (Step 3). The needle is advanced into the radial artery. The blood return indicates the intraluminal needle position. The blood return is rarely pulsatile or brisk.

access techniques (single-wall versus double-wall or back-wall technique). With the single-wall technique, a stainless steel needle is advanced through the front wall of the artery into the lumen; once blood is noticed in the needle hub the wire can be advanced (Figure 7.6). Using this technique, the blood return is rarely brisk or pulsatile and sometimes the wire does not advance freely because the bevel may be directing the wire toward the vessel wall. If this happens, the operator should never force the wire because of the risk of arterial dissection. The needle should be carefully rotated clockwise or counter-clockwise until the wire can be easily advanced without resistance (Figure 7.7). With the dual-wall or back-wall technique, a micropuncture catheter is advanced through the front wall into the lumen of the artery until blood is noticed in the hub and then intentionally pushed through the back wall of the

artery (Figure 7.8). The fine needle is removed and the small Teflon microcatheter is slowly withdrawn until the appearance of brisk pulsatile flow (Figures 7.9 and 7.10). Then, the wire can be freely advanced and the microcatheter exchanged for the arterial sheath (Figure 7.11). The orifice in the back wall of the radial artery is sealed once the sheath is in place (Figure 7.12). This technique has not been reported to be associated with a higher incidence of wrist hematomas. Proponents of the back-wall technique argue that this method is simpler, more reproducible, easier to teach, allows easier advancement of the wire, and that the arterial pulsatile blood return is easier to recognize.

After several unsuccessful puncture attempts, there are instances in which the radial pulse disappears due to spasm. In this situation, the operator should reassess the sedation status of the patient, consider administering 200 to 400 mcg

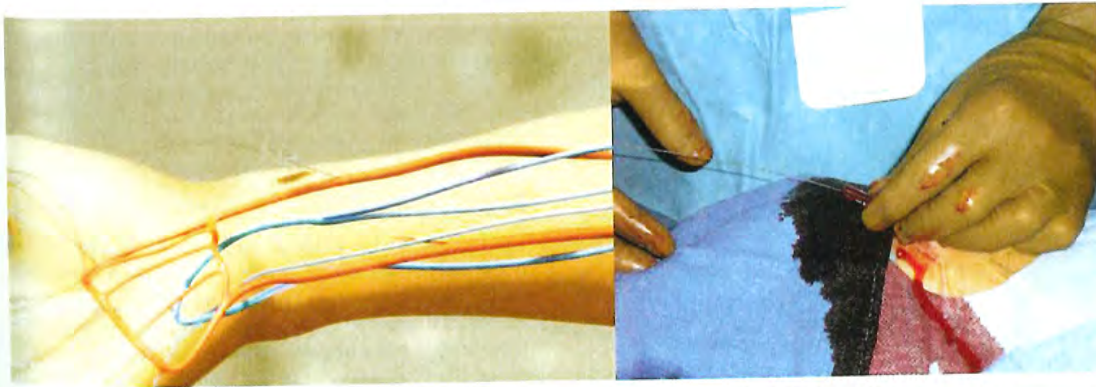


Figure 7.7 Transradial access technique—front wall technique (Step 4). A 0.018 inch short guidewire is advanced without resistance through the needle into the proximal radial artery. Then the needle is exchanged for a hydrophilic-coated sheath.

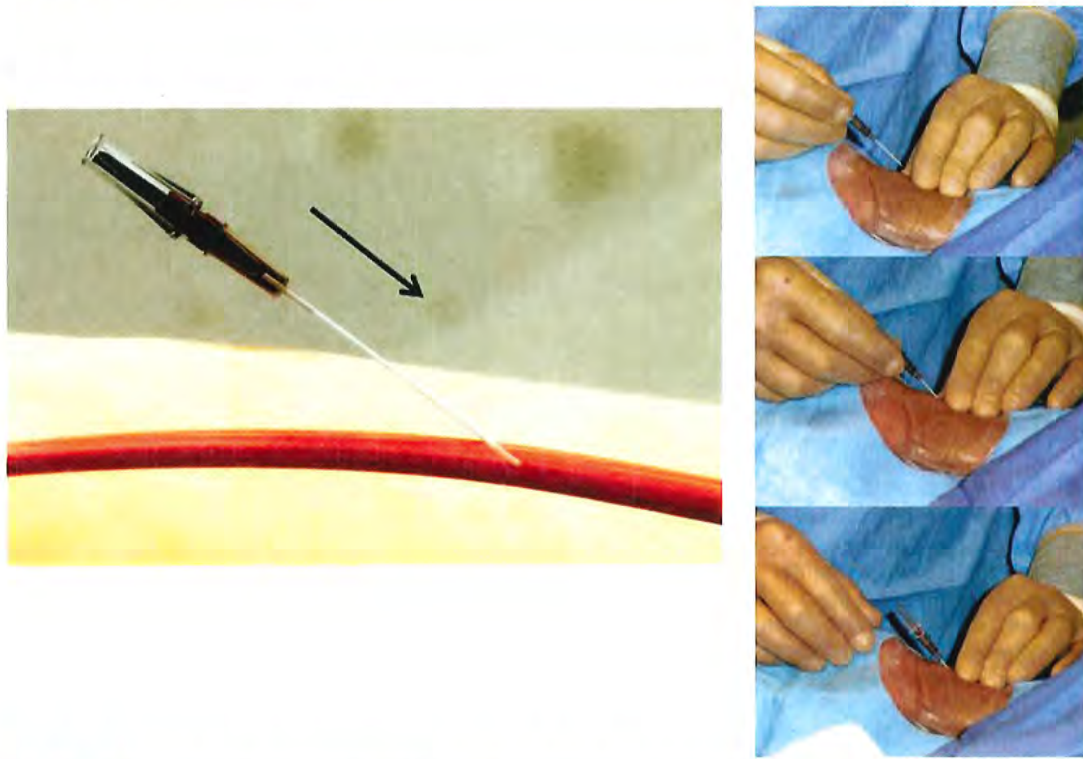


Figure 7.8 Transradial access technique—back-wall technique (Step 2). The microcatheter and needle are advanced in a 30° angle through the skin into the radial artery. The presence of blood in the hub of the needle indicates that the artery has been punctured. The needle is advanced forward through the back wall of the radial artery.

of subcutaneous nitroglycerin at the site of the lost radial pulse, and wait patiently for 5 to 10 minutes until the pulse reappears before attempting a new puncture.³⁵

Even though TRA procedures can be successfully completed in more than 95% of cases, inability to puncture the radial artery has been one of the most frequent mechanisms associated with TRA failure.¹¹ Therefore a consistent and meticulous radial artery puncture technique could not be emphasized more. A steep learning curve for TRA procedures has been well described. Spaulding et al., documented an initial access failure rate greater than 10% that decreased dramatically to about 2% after the first 80 cases. In addition, the time required for access and sheath insertion decreased from 10.2 ± 7.6 to 2.8 ± 2.5 minutes and the procedure time also decreased from 25.7 ± 12.9 to 17.4 ± 4.7 minutes after the first 80 cases.⁷ More recently, in a group of 28 operators, Ball and colleagues documented a stepwise reduction of TRA-PCI failure rates from 7% to 2% ($P = 0.01$), contrast volume use from 180 ± 79 to 168 ± 79 mL ($P = 0.05$), and fluoroscopy times from 15 ± 10 to 12 ± 9 minutes ($P = 0.02$)

with increasing procedural volumes. The odds of TRA procedural failure showed a steep decline up to 50 cases, and after 100 cases the learning curve flattened. Figure 7.13 shows that reasons for failure are different according to operator volume. It is clear that with experience, the operator can overcome most hurdles and the major reasons for failure remain radial artery spasm and extreme vascular tortuosity.⁹

Prevention of Radial Artery Spasm

The radial artery has a high propensity to develop spasm due to its smaller caliber, large muscular media, and higher receptor-mediated vasomotion in comparison with similar arteries.³⁶ Radial artery spasm is perhaps the most common TRA complication and a frequent reason for failure and crossover to transfemoral access.^{9,11} In the catheterization laboratory, spasm should be routinely prevented using a hydrophilic-coated sheath with the injection of a single vasodilator or a cocktail of vasodilators through the sidearm of the sheath immediately after obtaining access (Figure 7.14). Most




Figure 7.9 Transradial access technique—back-wall technique (Step 3). Once the tip of microcatheter and needle are through the back wall of the radial artery, the needle is removed and the microcatheter left in place across the radial artery.

commonly used vasodilators in order of frequency include the combination of verapamil and nitroglycerin, verapamil or nitroglycerin alone, nicardipine, lidocaine, and papaverine.^{37,38} Radial spasm manifests with severe forearm pain and unusually difficult manipulation of the catheters and the sheath. Independent predictors of radial spasm include the presence of radial artery anomalies, multiple catheter exchanges, pain during radial cannulation, larger catheter diameter, and small radial artery caliber.³⁹ In extreme cases, eversion radial endarterectomy has been reported after forceful removal of the radial sheath.⁴⁰ When spasm occurs, additional doses of intraarterial vasodilators, sedation, and use of smaller 4F to 5F catheters to complete the procedure are usually recommended. If after these measures the patient still complains of substantial pain and the catheters are difficult to manipulate, a limited upper extremity angiography is

recommended to rule out vascular anomalies such as a high radial origin in the proximal brachial artery or a radial loop. In case of catheter or sheath entrapment due to spasm, warm wet compresses can be applied over the skin of the upper extremity and the sheath or catheter slowly removed, or, in extremely severe cases, regional nerve block may be required.

Navigating the Upper Extremity Arterial System

Once arterial access is obtained, a 0.035 inch guidewire and a catheter of choice are advanced into the ascending aorta traversing the upper extremity arterial system. Choice of guidewires differs across operators and local practices. A J-tip wire may follow the path of larger vessels and may not selectively

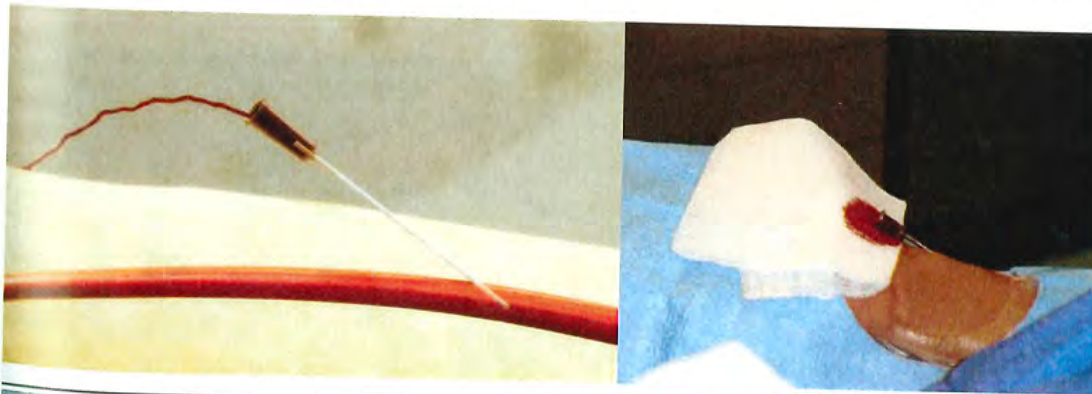


Figure 7.10 Transradial access technique—back-wall technique (Step 4). The microcatheter is retrieved very slowly until the appearance of brisk pulsatile blood return that confirms that the distal tip is in the lumen of the radial artery.

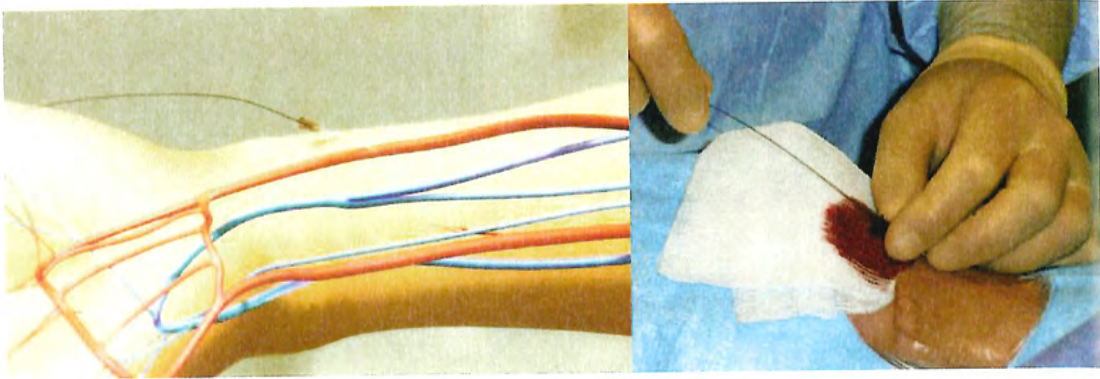


Figure 7.11 Transradial access technique-back-wall technique (Step 5). A short 0.018 inch wire, usually included in the micropuncture transradial access kit, is advanced without resistance through the microcatheter into the proximal radial artery. In case of resistance, a limited angiogram can be performed through the microcatheter to verify the intraluminal position and rule out the presence of vascular anomalies.

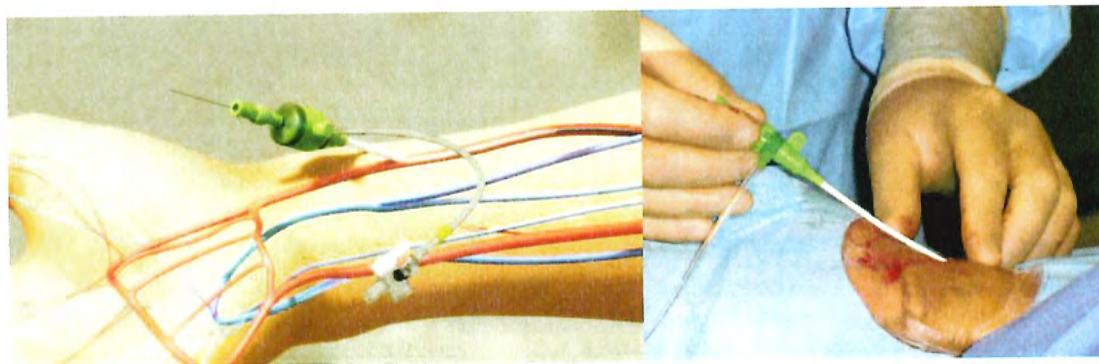
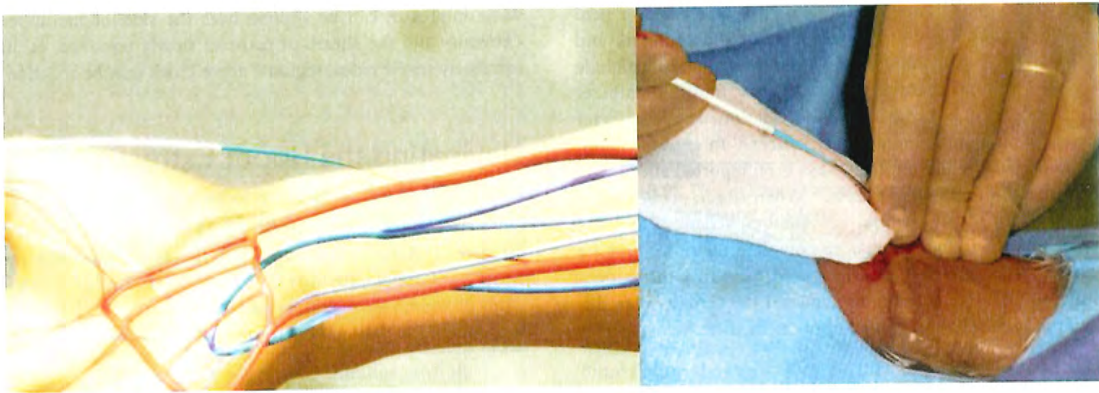


Figure 7.12 Transradial access technique (Step 6). The sheath, preferably hydrophilic-coated, is advanced over the wire.

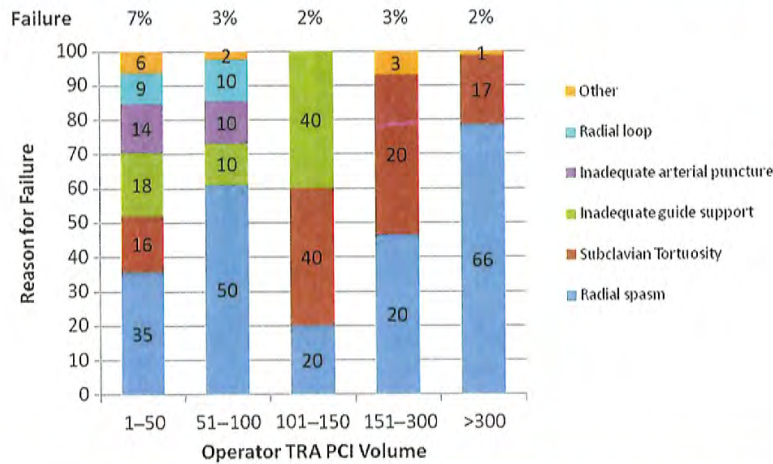


Figure 7.13 TRA experience and mechanisms of failure. (Adapted from Ball W, et al. *Circ Cardiovasc Interv* 2011;4:336-341.) PCI, percutaneous coronary interventions; TRA, transradial access.

enter into small radial or brachial branches, but the diameter of the J tip is usually larger than the diameter of the radial artery and may cause vasospasm. Angled-tip hydrophilic guidewires with stiff shafts are ideal for negotiating tortuous anatomy, especially in the subclavian artery and brachiocephalic trunk, but these wires need to be advanced under close fluoroscopic surveillance, as they may inadvertently enter into and perforate small branches of the radial or brachial arteries. As full anticoagulation is usually administered during transradial procedures, a small branch perforation can result in significant hematoma formation.

In a small proportion of cases, the transradial operator will encounter anatomic variations that may prevent the

advancement of guidewires or catheters into the ascending aorta. In these cases, the operator will meet resistance to the advancement of either guidewires or catheters. Due to the relatively small size of the upper extremity arterial system, the operator should never force any equipment against resistance. Instead, a limited retrograde angiographic assessment should be performed to identify a vascular anomaly or unusual tortuosity, plan a strategy, and avoid complications. Radioulnar loops and tortuosity in the radial or brachial arteries can be identified and negotiated with the 0.014 inch coronary wire of choice with the support of a 4F hydrophilic-coated Cobra or angled catheter compatible with a 0.035 inch guidewire. Once the tipped coronary wire is positioned




Figure 7.14 Transradial access technique—prevention of radial spasm. Once the sheath is in place, the spasmolytic cocktail is administered through the sidearm.

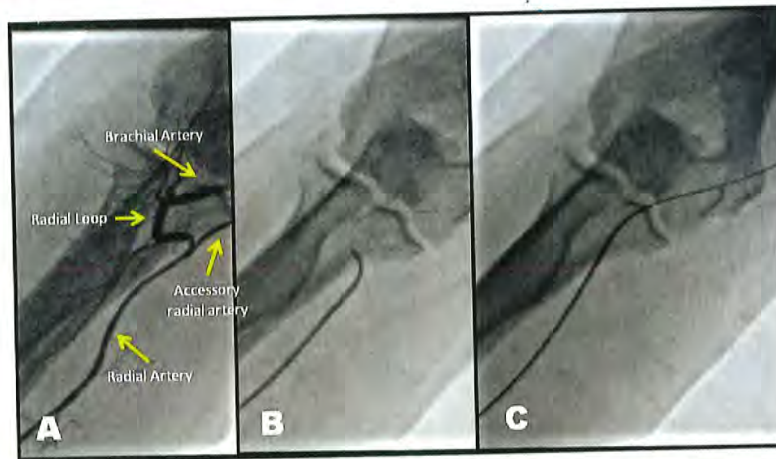


Figure 7.15 Negotiating a radial loop. **A.** shows the anatomy of a radial loop. **B.** shows how the loop can be negotiated by advancing an 0.014 inch coronary wire with the support of a short 4F hydrophilic-coated catheter. **C.** the catheter has already been advanced through the loop and the coronary wire exchanged for an 0.035 inch guidewire.

beyond the loop, the hydrophilic catheter is advanced farther in the brachial artery, and then the coronary wire is exchanged for a regular 0.035 inch guidewire. The loop usually straightens as the 0.035 inch wire passes through or with gentle pullback and counterclockwise torque of the entire system (Figure 7.15). In the presence of unusual difficulty in advancing a catheter through a loop or if the patient complains of significant pain, the operator may consider an alternative vascular access route.

Occasionally, in the presence of a radioulnar loop, the guidewire will advance through a small accessory communicating vessel between the loop and the proximal brachial artery without resistance (the so-called accessory radial artery). Under fluoroscopy the wire will appear as it follows the expected trajectory, but upon advancement of the catheter the operator will encounter unusual resistance and the patient will experience severe pain due to spasm. Once this problem is identified, the operator may opt for downsizing the catheter size, but should recognize that the accessory radial artery is often extremely small and advancement of catheters into the artery carries the risk of dissection or perforation. Instead, it is recommended that the operator negotiates the radioulnar loop in the forearm, or go to the other radial artery in order to complete the procedure.

A true high origin of the radial artery in the upper segment of the brachial artery may present additional challenges to the operator. In this case, diagnostic catheterization can be performed without much difficulty and minimal discomfort to the patient. However, when ad hoc PCI is planned, unusual resistance may be felt by the operator when the leading edge of the guiding catheter encounters the angulated origin of the anomalous radial artery. Forceful advancement of the catheter

will likely result in dissection, perforation, or avulsion. Faced with this situation, several options are available. One strategy is to maintain the guidewire in place, advance a long 125 cm 5F multipurpose or JR4 catheter through the guiding catheter to create a smooth transition between the wire and the guiding catheter eliminating the leading edge, and advance the whole assembly without resistance. Another option is to advance a 300 cm 0.014 inch coronary guidewire into the ascending aorta, then load a 2.0 × 15 mm angioplasty balloon on the wire through the guide with half of the balloon protruding from the distal end of the guide. The balloon is then deployed at nominal pressure and the entire assembly can be advanced through the arm (balloon-assisted tracking).⁴¹ With the guiding catheter across, the dissection or small perforation is usually sealed by the end of the procedure.

Significant subclavian tortuosity can be negotiated by careful manipulation of the catheter and the use of a stiff shaft hydrophilic-coated guidewire. Having the patient take a deep breath can also straighten the vessel. The tortuous segment usually straightens as the stiff part of the wire passes through. Maintaining the wire in the catheter while attempting to cannulate the coronaries can facilitate catheter manipulation and cannulation. The guidewire can be removed once the catheter is in stable position. It is emphasized that all catheter and wire manipulations to negotiate difficult anatomy must be performed under fluoroscopic guidance. The inexperienced operator may feel more comfortable using left TRA during the steep portion of the learning curve because the left subclavian artery is less tortuous with less areas of resistance compared with the right subclavian artery.

Forearm bleeding and hematoma formation should be suspected in the presence of significant pain and swelling

during or after the procedure. Awareness and early detection in the catheterization laboratory or the holding area is important to prevent compartment syndrome, one of the most feared complications. Circumferential compression to the forearm should be applied as soon as the diagnosis is suspected. This is usually accomplished by wrapping the forearm with an elastic bandage or a blood pressure cuff inflated up to 15 mmHg below the systolic blood pressure, until the coagulation parameters return to normal values, usually after 1 or 2 hours (Figure 7.16). A pulse oximeter should be placed in the ipsilateral thumb to monitor for hand ischemia. In cases of large perforations, vascular ultrasound is recommended to rule out the presence of a pseudoaneurysm in the forearm. In extreme cases, compartment syndrome can develop with need for surgical fasciotomy of the forearm.⁴²

CATHETER SELECTION

Judkins catheters provide the easiest way to start the transradial learning curve and train fellows. For the left coronary it is recommended to downsize the curve of the JL catheter from 4.0 to 3.5 and for the right coronary to use either a JR4 or JR5. All catheter exchanges for TRA procedures should be performed over exchange length (260 cm) guidewires, especially in patients with tortuous radial or subclavian anatomy. More experienced operators may choose a single-catheter technique to selectively engage both coronary arteries with a dedicated catheter shape, thus eliminating an exchange step and decreasing procedure and fluoroscopy time. Shapes for single-catheter approach include the multipurpose, Kimney, MAC, Tiger, Sarah, and Jacky catheters,

among others.⁴³ In severe aortic stenosis cases, the Amplatz Right (AR-1) catheter provides the best central positioning in the root of the aorta to cross the aortic valve with the wire. Regardless of catheter selection, manipulation for diagnostic or interventional TRA cases should always be performed with small, finger-based, clockwise and counterclockwise torquing movements and active catheter holding due to the multiple friction points in the subclavian artery and the aorta.

For patients with prior CABG, the left radial approach is preferred because it allows easy cannulation of the LIMA, usually with an IMA or a VB-1 catheter. Of note, the time of LIMA cannulation is much faster using TRA compared to transfemoral access. The technique is to advance the catheter proximal to the LIMA take-off, then slowly pull back with clockwise torque. In case of bilateral mammary grafts, the right-sided approach can be used with crossover to the left subclavian (Figure 7.17). For saphenous vein grafts, the left TRA approach is more straightforward than the right TRA approach. The multipurpose or JR4 catheters can be used to cannulate right-sided grafts. Amplatz left catheters are well suited for grafts arising from the anterior or left walls of the aorta.⁴⁴

TRANSRADIAL PERCUTANEOUS CORONARY INTERVENTION

For coronary interventions, the 3.5 extra-backup curves (EBU, XP, Voda) provide adequate support. Studies examining the physics of catheter engagement and positioning in the ascending aorta indicate that the Ikari catheter provides better and stabler support for PCI than Judkins catheters.⁴⁵

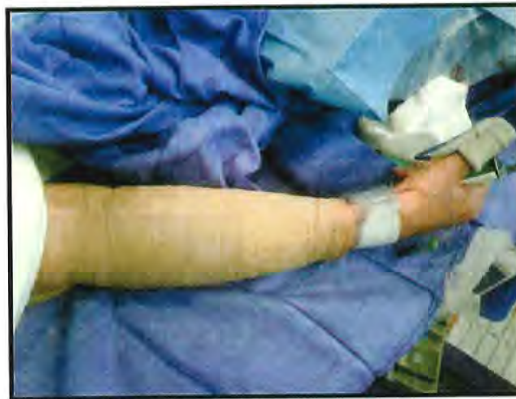

Figure 7.16 Prevention and treatment of compartment syndrome after forearm hematoma formation. After a vascular perforation in the forearm with early hematoma formation, the forearm can be wrapped with elastic bandage to prevent compartment syndrome. Once compartment syndrome develops, it is treated with fasciotomy.

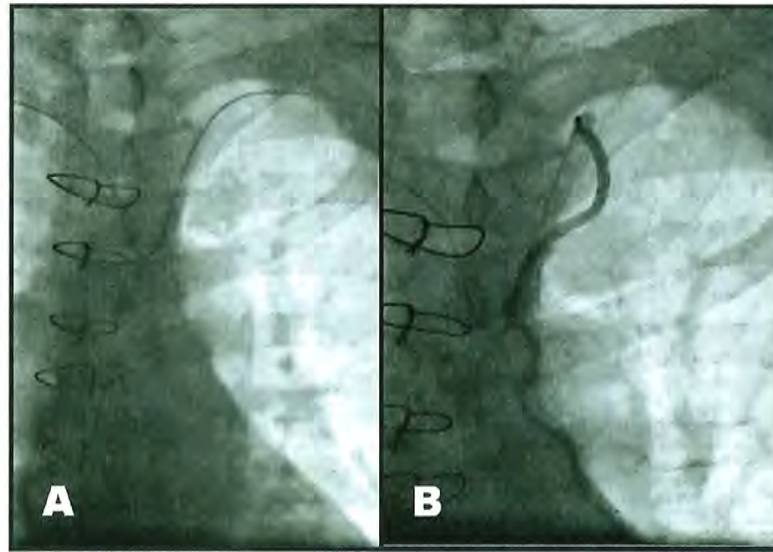

Figure 7.17 Engagement of left internal mammary artery through right radial approach. **A.** A 4F IMA catheter is advanced to the left subclavian artery over a regular hydrophilic wire. **B.** The wire is removed and the catheter is carefully pulled-back and torqued until the LIMA is selectively engaged. Then, the LIMA can be optimally injected and imaged.

An argument sometimes used against TRA PCI is the lack of catheter support and inability to perform complex procedures involving bifurcation stenting or large rotational atherectomy burrs. Lack of backup support can be easily overcome by using a guide catheter extension such as a Guideliner® (Vascular Solutions Inc., Minneapolis, Minnesota, United States), a 5F soft-tipped 20 cm flexible catheter that is telescoped through a 6F guiding catheter to deeply intubate the target vessel. This device does not add complexity to the intervention and provides extraordinary backup support for complex interventions.⁴⁶ Regarding the need for large bore catheters, it is important to keep in mind that most interventions nowadays can be performed through 6F guiding catheters, including complex bifurcations and calcified lesions requiring rotational atherectomy (maximum burr size ≤ 1.75 mm). However, in the minority of interventions that require simultaneous introduction of two stent delivery systems or rotational atherectomy burrs of 2.0 mm or larger, a 7F catheter can be introduced directly through the radial artery without an introducer sheath. This is possible because the outer diameter of a 7F guiding catheter is 2.31 mm, smaller than the outer diameter of a conventional 6F sheath (2.52 mm) (Figure 7.18). The sheathless technique can be performed using standard guiding catheters or specifically designed catheters with hydrophilic coating and a long central dilator that extends beyond the distal tip of the catheter and tapers down to the size of a 0.035 inch guidewire that allows for atraumatic and smooth insertion of the system through the skin.⁴⁷⁻⁵⁰ To apply this technique, radial access is obtained using best local

practice with a 5F sheath, then an exchange length 0.035 inch wire is advanced to the root of the aorta. Then the sheath is removed and directly exchanged for the dedicated sheathless catheter-introducer system over the wire. Once the system reaches the aorta, the introducer and wire are removed and the target vessel cannulated with standard technique. In the United States, where sheathless systems are not available, From and colleagues have successfully performed TRA interventions using large-bore standard guiding catheters. To facilitate insertion and to avoid trauma to the skin or the radial artery by the leading edge of the guiding catheter, a "pseudotaper" can be created with the insertion of a long (125 cm) 5F multipurpose diagnostic catheter or the dilator of a 110 cm Shuttle sheath through the 7F standard guiding catheter.^{47,48} Importantly, RAO is a significant limitation of using large-bore guiding catheters, even when using sheathless techniques.⁴⁹

RADIAL HEMOSTASIS—PREVENTION OF RADIAL ARTERY OCCLUSION

One important advantage of TRA is that the vascular sheath is always removed at the end of the procedure regardless of the intensity of anticoagulation or antiplatelet therapy. Multiple methods for radial hemostasis have been described. Gentle manual compression with one or two fingers at the arteriotomy site is an effective method. Alternatively, a rolled piece of gauze can be placed longitudinally at the arteriotomy




Figure 7.18 Sheathless transradial intervention using standard guide catheters. (From *Catheter Cardiovasc Interv* 2010;76(7):911–916. doi:10.1002/ccd.22742.)

site and wrapped with an elastic bandage or a hemoband around the wrist to maintain prolonged hemostatic pressure. The disadvantage of these methods is the complete interruption of arterial flow because of the inability to gauge the hemostatic pressure. It has been demonstrated that the longer the occlusive pressure the higher the rates of RAO.⁵¹ In contrast, balloon-based hemostatic devices that apply selective pressure to the radial artery, such as the TR Band (Terumo Medical, Somerset, NJ) allow fine adjustments of the hemostatic pressure and direct visualization of the arteriotomy site through the transparent balloon material. In addition, elastic bandages and hemobands interrupt venous return resulting in venous congestion of the hand. After a few minutes, the hand becomes swollen and bluish, usually alarming the patient and staff. Applying a pulse oximeter to the ipsilateral thumb provides reassurance by demonstrating intact arterial circulation.

RAO occurs in approximately 5% to 10% of transradial procedures, most likely due to vessel injury and thrombosis, and usually manifests as asymptomatic loss of radial pulse due to the extensive collateral circulation in the hand from the ulnar and interosseus arteries that prevent ischemia.⁵² However, hand ischemia after TRA procedures can occur and has been described in a handful of cases. In most of these, RAO was successfully treated with antegrade angioplasty.^{33,34} In one unfortunate case, RAO resulted in amputation of the index finger.⁵⁵ In other series, RAO has been associated with forearm and access site pain without hand ischemia. Empiric short courses of low-molecular weight heparin led to late recanalization.^{56,57} Lack of anticoagulation during the procedure, larger diameter sheaths, multiple procedures through the same radial artery, and prolonged occlusive compression for hemostasis increase the risk of RAO. However, approximately 25% to 50% of RAO cases recanalize spontaneously at 30 days.^{7,34,51}

RAO can be prevented by using full anticoagulation during the procedure, usually with 50 to 70 IU/Kg up to a maximum of 5,000 IU of unfractionated heparin, and by

applying minimum pressure for less than 2 hours during hemostasis.^{51,58} The “patent” nonocclusive hemostasis technique described by Pancholy to minimize the occurrence of RAO has become increasingly popular. With this technique, a balloon-based device is positioned around the wrist with the sheath in place and a pulse oximeter is attached to the ipsilateral thumb. Then, while the sheath is being removed, the balloon is fully inflated with 15 to 18 cc of air to completely occlude the radial artery. Subsequently, the device is slowly deflated while occlusive manual pressure is applied to the ulnar artery located at the Guyon canal, lateral to the pisiform bone. Patent hemostasis is achieved when oximetry becomes positive and a plethysmographic waveform can be visualized. This technique assures the presence of antegrade flow in the radial artery during hemostasis. Two hours later, 5 cc of air can be released every 15 minutes until the device is completely deflated and then removed. Using this technique, late occlusion rates can be reduced to approximately less than 5%.⁵⁹ As part of TRA best practices, radial artery patency should be confirmed with a reverse modified Allen’s test in all patients after hemostatic device removal and before patient discharge. In case of early RAO, occurring on the same day of the procedure and/or before discharge, Bernat and colleagues demonstrated that applying 1 hour of ulnar artery occlusive compression with a balloon-based hemostatic device can increase peak velocity flow into the radial artery with reestablishment of forward flow. In a study including 465 patients undergoing TRA catheterization, the rates of RAO were reduced from 5.9% to 2.9% in patients anticoagulated with 2,000 IU of unfractionated heparin and from 4.1% to 0.8% in patients anticoagulated with 5,000 IU of unfractionated heparin after applying ulnar compression. Hence, with intense procedural anticoagulation, meticulous patent hemostasis, and careful vigilance for early RAO managed with ulnar compression, RAO incidence can be reduced to less than 1%.^{60,61} (Figure 7.19). Even though most RAO

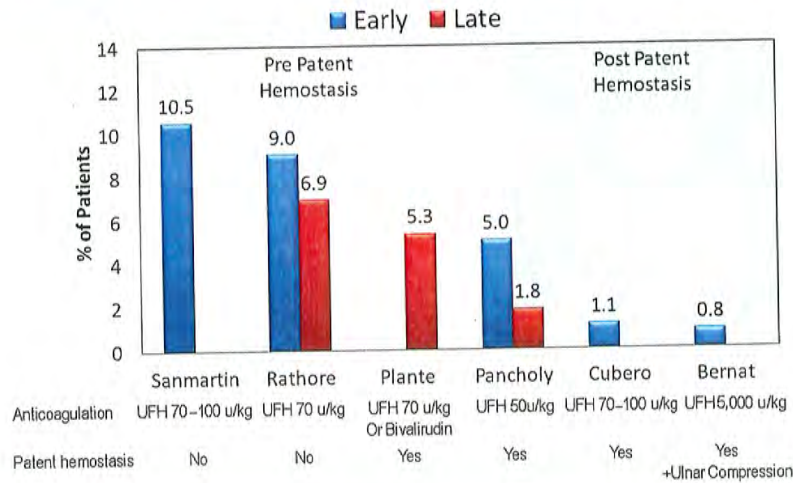


Figure 7.19 Radial occlusion rates improvement over time. (From Rao SV. *JACC: Cardiovasc Interv* 2012;5:44-46.)

cases are asymptomatic, institutional best practices should be implemented to prevent this complication mainly because it limits the possibilities for future transradial procedures, especially in patients with difficult arterial access, and the remote possibility of hand ischemia. Unfortunately, in current practice, radial patency before discharge is confirmed in less than 50% of cases and about a third of transradial operators are unaware of the RAO rates in their own practices.³⁸ Table 7.1 summarizes current strategies for RAO prevention.

TRANSRADIAL ACCESS AND RADIATION EXPOSURE

Even though procedural times tend to be similar between transradial and transfemoral procedures, most randomized trials have consistently shown longer fluoroscopy time (by approximately 1 to 2 minutes), and modestly increased radiation

exposure to patients and operators for transradial diagnostic and interventional procedures. However, most studies did not correct for improved procedural dexterity and the shorter fluoroscopy times that may be realized with greater experience.⁶² A large observational study including 5,954 cases adjusting for patient factors (obesity and gender), technical difficulty (presence of peripheral vascular disease or bypass grafts), and operator experience demonstrated that radial access was an independent determinant of patient radiation exposure with an increase in fluoroscopy time from 3.82 minutes with femoral access to 5.57 minutes with radial access. However, the radiation dose was still below the threshold for deterministic effects with either approach in this study.⁶³

Concerns have been raised about increased operator exposure with left TRA due to the position of the operator leaning forward over the patient and the radiation source located underneath the table to reach the left upper extremity. However, in the TALENT trial that randomized procedures to

Table 7.1 Strategies Associated with a Reduced Risk for Radial Artery Occlusion

Clearly Reduce Risk	Likely Reduce Risk	Limited Effect
Full anticoagulation	Enoxaparin	Sheath length
Patent hemostasis	Hydrophilic sheaths	Sheathless guide catheters
Smaller sheath diameter (5F)	Routine use of spasmolytic drugs	
Limiting the number of times the same radial artery is accessed	Limited duration of arterial compression	

the right or the left radial approach, the radiation exposure to the thyroid, trunk, and shoulder, were similar with either approach. Of note, there was increased radiation exposure to the wrist of the operator with right compared to left TRA.⁶⁴

In summary, the data consistently show slightly increased fluoroscopy times and radiation doses with radial compared with femoral access, but overall exposure remains well below recommended thresholds. Diagnostic cases may demand higher fluoroscopy times due to potential challenges in navigating the upper extremity vasculature and in finding the right catheter for selective cannulation of the coronary arteries. However, once a guiding catheter is well positioned in the coronary ostium, an interventional procedure can proceed as if performed via transfemoral access.⁶⁵ Radiation exposure to the operator can be further reduced with the use of a movable floor shield, a longer connecting tube between the manifold and the catheter, and by choosing left radial access in older patients and when procedures are performed by less experienced operators.²⁸

BRACHIAL VENOUS ACCESS FOR RIGHT HEART CATHETERIZATION

One of the arguments used against TRA catheterization is the need for concomitant RHC. Interventional cardiologists are used to performing percutaneous RHC through the femoral vein, and therefore feel that if the groin is already accessed, it just seems easier to perform left heart catheterization through the femoral artery. There may be some safety concerns with this approach in anticoagulated patients with high thromboembolic risk, such as those with prosthetic heart valves, hypercoagulable state, or atrial fibrillation. Bridging from oral to parenteral anticoagulants is cumbersome and associated with increased risks, costs, and longer length of hospital stay. Similar concerns

apply to cirrhotic patients with impaired coagulation who are usually catheterized in anticipation of liver transplant.

RHC through the upper extremity is a simple procedure and can be easily performed concomitantly with TRA left heart catheterization through one of the large veins located in the antecubital fossa. The operator needs to keep in mind that there is significant anatomic variability in the upper extremity venous system with multiple collaterals and redundant passages. In comparison with arteries, veins are distensible and spasm is not a problem.

Venous access with an 18G catheter can be obtained by a nurse in the holding area in anticipation of the procedure. In the catheterization laboratory, the IV catheter is exchanged for a 5F sheath using a short 0.021 inch wire. Then, a 5F 120 cm long balloon-tipped catheter is advanced into the superior vena cava with or without the use of a 0.025 inch guidewire. Once the tip of the catheter is located in the chest, the balloon can be inflated and the catheter is flow-directed into the pulmonary artery.^{19,66} Passage of the catheter is usually straightforward and can be performed without fluoroscopy by observing the hemodynamic waveforms. In case of venous anatomical variation or tortuosity, a 0.014 inch coronary guidewire can be used to facilitate catheter navigation. A comparison of right and left cardiac catheterizations performed through the femoral artery/vein versus radial artery/brachial vein showed that the latter vascular access approach was associated with significantly shorter procedural and fluoroscopy times with lower complication rates with the upper extremity approach.⁶⁷ In a case series of 81 cirrhotic patients with high INR values, the median fluoroscopy time was 8.3 minutes and the volume of contrast used was 90 mL.⁶⁸

If a peripheral vein cannot be cannulated before the procedure, the brachial vein can be punctured with a 2 inch long 18G stainless steel needle using ultrasound guidance in the catheterization laboratory (Figure 7.20). A tourniquet has to be placed in the upper arm to facilitate visualization of

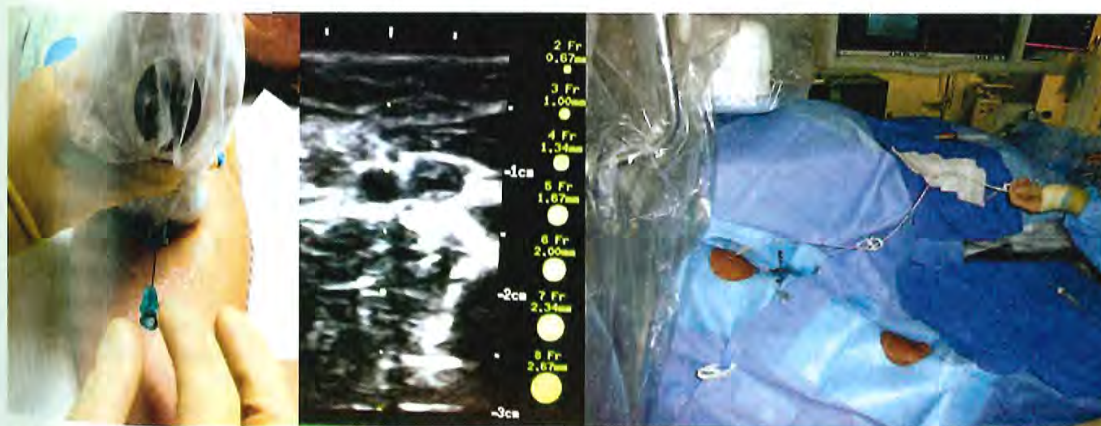


Figure 7.20 Ultrasound-guided access and setup for brachial venous transradial catheterization.

the vein with ultrasound. Usually two brachial veins can be identified in close proximity to the brachial artery. The vein is usually elliptical and easily compressible in contrast to the artery, which is round and pulsatile.

TRANSRADIAL ACCESS AND OUTCOMES

Over the past two decades, the treatment of coronary disease has evolved significantly and PCI has become an integral management component along with modern pharmacological therapies. In the appropriate setting, PCI is associated with a reduction in morbidity and mortality, in particular in higher-risk patients with acute coronary syndromes. Advances in technology and antithrombotic therapies have allowed the application of PCI to a wide range of patients across the spectrum of risk, with high procedural success and minimal ischemic complications.⁶⁹ Over the past decade, it has been recognized that bleeding after PCI has a significant unfavorable effect on short- and long-term outcomes. As a consequence, the management focus has shifted from the prevention of ischemic complications to the prevention of bleeding.⁷⁰ Access site is an important source of bleeding after diagnostic and interventional catheterization.^{71,72} A number of clinical trials of relatively modest sample size have consistently demonstrated significantly decreased bleeding risk and vascular complication rates with TRA in comparison with transfemoral access. An early systematic overview of 12 randomized trials ($n = 3,224$) demonstrated a significant reduction in vascular access complications with the radial approach (odds ratio [OR] 0.20; 95% confidence interval [CI] 0.09 to 0.42), yet significantly higher procedural failure compared with femoral access (OR 3.30; 95% CI 1.63 to 6.71).¹⁰ However, with advancements in vascular access equipment and catheter technologies, more contemporary trials have shown significantly decreased failure rates. A large Canadian observational registry of PCI for broad indications suggested a significant reduction in transfusion by approximately 40% with TRA associated with a decrease in mortality at 30 days (adjusted OR 0.71, 95% CI 0.61 to 0.82) and 1 year (adjusted OR 0.83, 95% CI 0.71 to 0.98).⁶ More recently, the international multicenter Radial Versus femoral access for coronary intervention (RIVAL) trial randomized a large patient population with acute coronary syndromes undergoing PCI to radial ($n = 3,507$) versus femoral access ($n = 3,514$). There were no significant differences in the primary outcome, a composite of death, myocardial infarction, stroke, or non-CABG bleeding at 30 days with radial compared with femoral access (3.7% versus 4.0%, $P = 0.50$). Of note, all procedures were performed by high-volume operators at high-volume centers with very low rates of major bleeding complication of 0.5% in both arms, significantly lower than the bleeding rates reported in similar populations recruited in observational studies. Major vascular complications were significantly lower with transradial versus transfemoral access (1.4% versus 3.7%, $P < 0.0001$). Interestingly,

subgroup analyses showed a statistical interaction for patients treated at the highest radial-per-operator volume centers (>146 PCI/year/operator) and ST-elevation myocardial infarction (STEMI) patients, favoring transradial over transfemoral access in these subgroups.⁷³

TRA has been also been tested in primary PCI for STEMI in a number of modestly sized studies that showed a similar mortality benefit as the RIVAL trial in this population.^{74,75} These results were confirmed in the Radial Versus Femoral Randomized Investigation in ST-Elevation Acute Coronary Syndrome (RIFLE STEACS) trial. A total of 1,001 patients with STEMI undergoing primary or rescue PCI were randomized to radial versus femoral access at 4 high-volume centers. Inclusion criteria for RIFLE STEACS were broad. Approximately 10% of the patients were in acute pulmonary edema or cardiogenic shock, and 8% required intraaortic balloon pumps. Door-to-balloon time was 7 minutes longer with TRA but the difference was not statistically significant (53 versus 60 minutes, $P = 0.175$), and 5F catheters were used more frequently with TRA than transfemoral access (18.2% versus 9.2%, $P < 0.001$). Access failure rates were 6% in the radial arm and 1% in the femoral arm. Final TIMI flow grade 2 or 3 was achieved in more than 95% with both vascular access strategies. The study primary endpoint, net adverse clinical events, a composite of death, myocardial infarction, stroke, target lesion revascularization and non-CABG bleeding, occurred in 13.6% of patients in the radial arm and 21% in the femoral arm ($P = 0.003$). Unlike other studies comparing radial versus femoral access, where the difference in composite endpoints is usually driven by the reduction of access site bleeding afforded by TRA, in the RIFLE STEACS trial, ischemic and bleeding endpoints were equally reduced. Major adverse cardiac and cerebrovascular events were 7.2% and 11.4%, with radial and femoral access, respectively ($P = 0.03$), while non-CABG bleeding rates were 7.8% and 12.2% respectively ($P = 0.03$). Moreover, there was a cardiac mortality difference favoring radial access (5.2% versus 9.2%, $P = 0.02$), which was attributed to the significant reduction in access-related bleeding.⁷⁶ Of note, in this trial, approximately 50% of bleeding events were not access related, similar to the bleeding patterns described in other studies including patients with acute coronary syndromes, who are usually exposed for longer time to potent anti-thrombotic agents.^{72,77}

In summary, outcome data suggests that TRA affords similar, if not better, PCI outcomes as transfemoral access. The benefit appears to concentrate in sicker patients, such as those with STEMI, and patient treated by operators at high-volume centers. It is expected that these results will translate into practice and more patients will be treated for STEMI using radial artery access. The potential concerns related to delays in obtaining radial access and cannulating the coronary arteries appear to be offset by the decreased incidence of major bleeding, vascular complications, and overall adverse effects. However, it is important to keep in mind that TRA for primary PCI in unstable patients should be performed by

operators experienced in this approach, and that the femoral artery access site should be prepared in case of need for left ventricular assist devices.

ECONOMIC ASPECTS—SAME-DAY DISCHARGE PERCUTANEOUS CORONARY INTERVENTIONS

It has been estimated that a severe bleeding event has an incremental cost of \$4,000 to \$6,000, a unit of blood transfusion an approximate cost of \$2,000, and a vascular complication a cost of \$6,400, adding 3 additional days of hospital stay.⁷⁸⁻⁸⁰ By decreasing access-related bleeding and vascular injury, TRA can save costs for the health care system. Dedicated cost analyses comparing vascular access sites have consistently shown a significant reduction in hospital costs with TRA. In an early randomized study including diagnostic catheterization procedures, TRA was associated with a cost saving of approximately \$290 per case, driven by lower nursing utilization and decreased pharmacy costs.⁴ The savings observed with diagnostic catheterization are even larger after PCI due to the higher risk of bleeding associated with potent antithrombotic therapies. In a small randomized study of 142 patients undergoing PCI for acute coronary syndromes, postprocedure length of stay was reduced by approximately 1.5 days and total hospital charges decreased from \$23,389 to \$20,476 with TRA.⁸¹ A recent metaanalysis including 14 studies examined the cost-benefit of TRA from the hospital standpoint. The main question was whether the savings associated with decreased procedural complications and shorter hemostasis times can offset the potentially higher cost of longer procedural times and higher access crossover rates observed with TRA. The overall result demonstrated that TRA resulted in an estimated cost saving of \$275 per patient, which was mainly driven by a reduction in complication costs. According to this analysis, the risks of transfemoral catheterization would have to be reduced by 60%, in order to be cost-equivalent to TRA.⁸²

In addition to direct cost savings, TRA can result in significant downstream savings by optimizing the flow and reducing the workload and staffing needs of the catheterization laboratory. Staffing requirements following TRA procedures can be reduced due to fewer access-related complications, immediate sheath removal, and faster and more independent patient mobilization.⁸³

An added value of short patient recovery associated with TRA is the possibility of safe same-day discharge after elective PCI. Interventional procedures have become safer and the hazard of complication decreases abruptly within the first 4 to 6 hours after the procedure.⁸⁴ Same-day discharge after transfemoral elective PCI has been studied in a Dutch study including 800 patients randomized to overnight stay versus same-day discharge after 4 hours of observation. Strict criteria established in the protocol to identify patients

requiring extended observation included angiographic complications, clinical instability, and problems with hemostasis. Of patients randomized to same-day discharge, 18% required extended observation. More importantly, after hospital discharge no events occurred within 24 hours in the same-day discharge group. Only one patient had to be readmitted for a femoral access-related complication (pseudoaneurysm). The same-day discharge strategy resulted in significant cost savings.⁸⁵ A Canadian study randomized 1,005 patients after TRA PCI to same-day discharge versus overnight stay. All patients were randomized after the procedure and received abciximab either as bolus alone or as bolus plus infusion. Same-day discharge patients were observed for 4 to 6 hours prior to discharge. All major bleeding events were unrelated to access and occurred in five (<0.5%) patients. Of patients assigned to same-day discharge, 88% were successfully discharged as planned and did not have higher repeat 30-day hospitalization rates compared to patients who stayed overnight (5% with same-day discharge versus 3% with overnight stay).⁸⁶ A very detailed economic analysis of this study showed that postprocedural hospital care was significantly less costly for the same-day discharge group (\$459) than the overnight stay group (\$1,618). There were no differences in follow-up costs, physician services, or medications. The overall cost difference was \$1,141 per patient and driven by the extra night stay post-PCI. This could result in over \$1 million in savings per 1,000 outpatients.⁸⁷ An analysis of Medicare beneficiaries including more than 100,000 stable patients demonstrated that across the United States, same-day discharge occurs very infrequently in only 1.25% of elective PCI cases. Of note, a higher proportion of patients discharged on the same day underwent TRA PCI or had vascular closure devices (3.14% versus 1.56%, $P < 0.001$).

In summary, implementation of a TRA catheterization offers significant cost-saving opportunities for individual institutions and the health care system as a whole.

CONCLUSION

TRA has become the standard approach for cardiac catheterization and PCI in many parts of the world, and is slowly gaining ground in the United States. TRA implementation requires a learning curve of approximately 50 to 100 cases and is associated with slightly increased fluoroscopy time and access crossover rates. However, once mastered and implemented as an institutional program, TRA is associated with less access-related bleeding, less vascular injury, improved patient comfort, and significant cost savings for the health care system.

Staff training and development of institutional policies and best practices are crucial for the implementation of a successful TRA program. A guidance document and multiple training opportunities are now available for established U.S. operators through efforts of professional societies.⁸⁸

REFERENCES

- Campeau L. Percutaneous radial artery approach for coronary angiography. *Cathet Cardiovasc Diagn* 1989;16:3-7.
- Kiemeneij F, Laarman GJ. Percutaneous transradial artery approach for coronary stent implantation. *Cathet Cardiovasc Diagn* 1993;30:173-178.
- Louvard Y, Kumar S, Lefevre T. Percentage of transradial approach for interventional cardiology in the world and learning the technique. *Ann Cardiol Angeiol (Paris)* 2009;58:327-32.
- Cooper CJ, El-Shiekh RA, Cohen DJ, et al. Effect of transradial access on quality of life and cost of cardiac catheterization: a randomized comparison. *Am Heart J* 1999;138:430-436.
- Jolly SS, Amlani S, Hamon M, Yusuf S, Mehta SR. Radial versus femoral access for coronary angiography or intervention and the impact on major bleeding and ischemic events: A systematic review and meta-analysis of randomized trials. *Am Heart J* 2009;157:132-140.
- Chase AJ, Fretz EB, Warburton WP, et al. Association of the arterial access site at angioplasty with transfusion and mortality: the m.O.R.T.A.L. study (mortality benefit of reduced transfusion after percutaneous coronary intervention via the arm or leg). *Heart (Br Cardiac Soc)* 2008;94:1019-1025.
- Spaulding C, Lefevre T, Funck F, et al. Left radial approach for coronary angiography: Results of a prospective study. *Cathet Cardiovasc Diagn* 1996;39:365-370.
- Brasselet C, Blanpain T, Tassan-Mangina S, et al. Comparison of operator radiation exposure with optimized radiation protection devices during coronary angiograms and ad hoc percutaneous coronary interventions by radial and femoral routes. *Eur Heart J* 2008;29:63-70.
- Ball WT, Sharieff W, Jolly SS, et al. Characterization of operator learning curve for transradial coronary interventions. *Circ Cardiovasc Interv* 2011;4:336-341.
- Agostoni P, Biondi-Zoccai GG, de Benedictis ML, et al. Radial versus femoral approach for percutaneous coronary diagnostic and interventional procedures: systematic overview and meta-analysis of randomized trials. *J Am Coll Cardiol* 2004;44:349-356.
- Dehghani P, Mohammad A, Bajaj R, et al. Mechanism and predictors of failed transradial approach for percutaneous coronary interventions. *JACC Cardiovasc Interv* 2009;2:1057-1064.
- Rao SV, Ou FS, Wang TY, et al. Trends in the prevalence and outcomes of radial and femoral approaches to percutaneous coronary intervention: a report from the national cardiovascular data registry. *JACC Cardiovasc Interv* 2008;1:379-386.
- Mehran R, Pocock SJ, Stone GW, et al. Associations of major bleeding and myocardial infarction with the incidence and timing of mortality in patients presenting with non-ST-elevation acute coronary syndromes: a risk model from the ACUITY trial. *Eur Heart J* 2009;30(12):1457-66.
- Feldman DN, Swaminathan RV, Kaltenbach LA et al. Adoption of radial access and comparison of outcomes to femoral access in percutaneous coronary intervention: an updated report from the national cardiovascular data registry (2007-2012). *Circulation* 2013;127:2295-306.
- Levine GN, Bates ER, Blankenship JC, et al. ACCF, AHA, SCAI 2011 ACCF/AHA/SCAI guideline for percutaneous coronary intervention: Executive summary: a report of the American College of Cardiology Foundation/American Heart Association Task Force on Practice Guidelines and the society for cardiovascular angiography and interventions. *Catheter Cardiovasc Interv* 2012;79:453-495.
- Steg PG, James SK, Atar D, et al. ESC guidelines for the management of acute myocardial infarction in patients presenting with ST-segment elevation: the task force on the management of ST-segment elevation. *Eur Heart J* 2012;33(20):2569-619.
- Saito S, Ikei H, Hosokawa G, Tanaka S. Influence of the ratio between radial artery inner diameter and sheath outer diameter on radial artery flow after transradial coronary intervention. *Catheter Cardiovasc Interv* 1999;46:173-178.
- Drake RL, Vogl W, Mitchell AWM, Gray H, Gray H. *Gray's Anatomy for Students*. Philadelphia, PA: Churchill Livingstone/Elsevier; 2010.
- Gilchrist IC, Kharabsheh S, Nickolaus MJ, Reddy R. Radial approach to right heart catheterization: Early experience with a promising technique. *Catheter Cardiovasc Interv* 2002;55:20-22.
- Cohen MG, Alfonso C. Starting a transradial vascular access program in the cardiac catheterization laboratory. *J Invasive Cardiol* 2009;21:11A-17A.
- Aptekar E, Pernes JM, Chabane-Chaouch M, et al. Translunar versus transradial artery approach for coronary angioplasty: the pevicuba study. *Catheter Cardiovasc Interv* 2006;67:711-720.
- Valsecchi O, Vassileva A, Musumeci G, et al. Failure of transradial approach during coronary interventions: anatomic considerations. *Catheter Cardiovasc Interv* 2006;67:870-878.
- Lo TS, Nolan J, Fountzopoulos E, et al. Radial artery anomaly and its influence on transradial coronary procedural outcome. *Heart (Br Cardiac Soc)* 2009;95:410-415.
- Wallach SG. Cannulation injury of the radial artery: diagnosis and treatment algorithm. *Am J Crit Care* 2004;13:315-319.
- Barbeau GR, Arsenault F, Dugas L, Simard S, Lariviere MM. Evaluation of the ulnopalmar arterial arches with pulse oximetry and plethysmography: comparison with the Allen's test in 1010 patients. *Am Heart J* 2004;147:489-493.
- Biondi-Zoccai G, Moretti C, Zuffi A, Agostoni P, Romagnoli E, Sangiorgi G. Transradial access without preliminary allen test—letter of comment on rhyne et al. *Catheter Cardiovasc Interv* 2011;78:662-664.
- Norgaz T, Gorgulu S, Dagdelen S. Arterial anatomic variations and its influence on transradial coronary procedural outcome. *J Interv Cardiol* 2012;25(4):418-24.
- Sciahbasi A, Romagnoli E, Burzotta F, et al. Transradial approach (left vs right) and procedural times during percutaneous coronary procedures: Talent study. *Am Heart J* 2011;161:172-179.
- Sciahbasi A, Romagnoli E, Trani C, et al. Evaluation of the "learning curve" for left and right radial approach during percutaneous coronary procedures. *Am J Cardiol* 2011;108:185-188.
- Rathore S, Stables RH, Pauriah M, et al. Impact of length and hydrophilic coating of the introducer sheath on radial artery spasm during transradial coronary intervention: a randomized study. *JACC Cardiovasc Interv* 2010;3:475-483.
- Kiemeneij F, Fraser D, Slagboom T, Laarman G, van der Wieken R. Hydrophilic coating aids radial sheath withdrawal and reduces patient discomfort following transradial coronary intervention: a randomized double-blind comparison of coated and uncoated sheaths. *Catheter Cardiovasc Interv* 2003;59:161-164.
- Kozak M, Adams DR, Ioffreda MD, et al. Sterile inflammation associated with transradial catheterization and hydrophilic sheaths. *Catheter Cardiovasc Interv* 2003;59:207-213.
- Swaminathan RV, Wong SC. Radial access site inflammatory reaction to a recently available hydrophilic coated sheath. *Catheter Cardiovasc Interv* 2011;77:1050-1053.
- Dahm JB, Vogelgesang D, Hummel A, Staudt A, Volzke H, Felix SB. A randomized trial of 5 vs. 6 french transradial percutaneous coronary interventions. *Catheter Cardiovasc Interv* 2002;57:172-176.
- Pancholy SB, Coppola J, Patel T. Subcutaneous administration of nitroglycerin to facilitate radial artery cannulation. *Catheter Cardiovasc Interv* 2006;68:389-391.
- He GW, Yang CQ. Radial artery has higher receptor-mediated contractility but similar endothelial function compared with mammary artery. *Ann Thorac Surg* 1997;63:1346-1352.
- Kiemeneij F. Prevention and management of radial artery spasm. *J Invasive Cardiol* 2006;18:159-160.
- Bertrand OF, Rao SV, Pancholy S, et al. Transradial approach for coronary angiography and interventions: results of the first international transradial practice survey. *JACC: Cardiovasc Interv* 2010;3:1022-1031.

39. Ruiz-Salmeron RJ, Mora R, Masotti M, Betriu A. Assessment of the efficacy of phentolamine to prevent radial artery spasm during cardiac catheterization procedures: A randomized study comparing phentolamine vs. verapamil. *Catheter Cardiovasc Interv* 2005;66:192-198.
40. Dieter RS, Akef A, Wolff M. Eversion endarterectomy complicating radial artery access for left heart catheterization. *Catheter Cardiovasc Interv* 2003;58:478-480.
41. Patel T, Shah S, Pancholy S. Balloon-assisted tracking of a guide catheter through difficult radial anatomy: a technical report. *Catheter Cardiovasc Interv* 2013; 81(5):E215-8.
42. Tizon-Marcos H, Barbeau GR. Incidence of compartment syndrome of the arm in a large series of transradial approach for coronary procedures. *J Interv Cardiol* 2008;21:380-384.
43. Kim SM, Kim DK, Kim DI, Kim DS, Joo SJ, Lee JW. Novel diagnostic catheter specifically designed for both coronary arteries via the right transradial approach. A prospective, randomized trial of tiger ii vs. Judkins catheters. *Int J Cardiovasc Imaging* 2006; 22:295-303.
44. Burzotta F, Trani C, Hamon M, Amoroso G, Kiemeneij F. Transradial approach for coronary angiography and interventions in patients with coronary bypass grafts: tips and tricks. *Catheter Cardiovasc Interv* 2008;72:263-272.
45. Ikari Y, Nagaoka M, Kim JY, Morino Y, Tanabe T. The physics of guiding catheters for the left coronary artery in transfemoral and transradial interventions. *J Invasive Cardiol* 2005;17:636-641.
46. Mamas MA, Fath-Ordoubadi F, Fraser DG. Distal stent delivery with guidewire catheter: First in man experience. *Catheter Cardiovasc Interv* 2010;76:102-111.
47. From AM, Gulati R, Prasad A, Rihal CS. Sheathless transradial intervention using standard guide catheters. *Catheter Cardiovasc Interv* 2010;76:911-916.
48. From AM, Bell MR, Rihal CS, Gulati R. Minimally invasive transradial intervention using sheathless standard guiding catheters. *Catheter Cardiovasc Interv* 2011;78:866-871.
49. Mamas MA, Fath-Ordoubadi F, Fraser DG. Atraumatic complex transradial intervention using large bore sheathless guide catheter. *Catheter Cardiovasc Interv* 2008;72:357-364.
50. Sciahbasi A, Mancone M, Cortese B, et al. Transradial percutaneous coronary interventions using sheathless guiding catheters: a multicenter registry. *J Interv Cardiol* 2011;24:407-412.
51. Pancholy SB, Patel TM. Effect of duration of hemostatic compression on radial artery occlusion after transradial access. *Catheter Cardiovasc Interv* 2012;79:78-81.
52. Rao SV. Observations from a transradial registry: our remedies oft in ourselves do lie. *JACC: Cardiovasc Interv* 2012;5:44-46.
53. Ruzsa Z, Pinter L, Kolvenbach R. Antegrade recanalisation of the radial artery followed by transradial angioplasty. *Cardiovasc Revasc Med* 2010;11:266 e1-4.
54. Rhyne D, Mann T. Hand ischemia resulting from a transradial intervention: Successful management with radial artery angioplasty. *Catheter Cardiovasc Interv* 2010;76:383-386.
55. de Bucourt M, Teichgraber U. Digital ischemia and consecutive amputation after emergency transradial cardiac catheter examination. *Cardiovasc Intervent Radiol* 2012;35(5):1242-4.
56. Zankl AR, Andrassy M, Volz C, et al. Radial artery thrombosis following transradial coronary angiography: incidence and rationale for treatment of symptomatic patients with low-molecular-weight heparins. *Clin Res Cardiol* 2010;99:841-7.
57. Uhlemann M, Mobius-Winkler S, Mende M, et al. The Leipzig prospective vascular ultrasound registry in radial artery catheterization: impact of sheath size on vascular complications. *JACC Cardiovasc Interv* 2012;5:36-43.
58. Schiano P, Barbou F, Chenilleau MC, Louembe J, Monsegu J. Adjusted weight anticoagulation for radial approach in elective coronarography: the AWARE coronarography study. *EuroIntervention* 2010;6:247-250.
59. Pancholy S, Coppola J, Patel T, Roke-Thomas M. Prevention of radial artery occlusion-patent hemostasis evaluation trial (PROPHET study): a randomized comparison of traditional versus patency documented hemostasis after transradial catheterization. *Catheter Cardiovasc Interv* 2008;72:335-340.
60. Bernat I, Bertrand OF, Rokyta R, et al. Efficacy and safety of transient ulnar artery compression to recanalize acute radial artery occlusion after transradial catheterization. *Am J Cardiol* 2011;107:1698-1701.
61. Cubero JM, Lombardo J, Pedrosa C, et al. Radial compression guided by mean artery pressure versus standard compression with a pneumatic device (RACOMAP). *Catheter Cardiovasc Interv* 2009; 73:467-72.
62. Rao SV, Bernat I, Bertrand OF. Clinical update: Remaining challenges and opportunities for improvement in percutaneous transradial coronary procedures. *Eur Heart J* 2012;33(20):2521-6.
63. Mercuri M, Mehta S, Xie C, Valettas N, Velianou JL, Natarajan MK. Radial artery access as a predictor of increased radiation exposure during a diagnostic cardiac catheterization procedure. *JACC Cardiovasc Interv* 2011;4:347-352.
64. Sciahbasi A, Romagnoli E, Trani C, et al. Operator radiation exposure during percutaneous coronary procedures through the left or right radial approach: the TALENT dosimetric substudy. *Circ Cardiovasc Interv* 2011;4:226-231.
65. Schaefele TG, Grunebaum JR, Lippe B, Breidenbach T, Von Hohenberg E. *Radial Access Versus Conventional Femoral Puncture: Outcome and Resource Effectiveness in Daily Routine. The Raptor Trial.* Presented at the Scientific Sessions of the American Heart Association 2009, Orlando, FL. http://directnews.americanheart.org/extras/sessions2009/slides/41_pslides.pdf (accessed 09 Aug 2010).
66. Lo TS, Buch AN, Hall IR, Hildick-Smith DJ, Nolan J. Percutaneous left and right heart catheterization in fully anticoagulated patients utilizing the radial artery and forearm vein: a two-center experience. *J Interv Cardiol* 2006;19:258-263.
67. Gilchrist IC, Moyer CD, Gascho JA. Transradial right and left heart catheterizations: A comparison to traditional femoral approach. *Catheter Cardiovasc Interv* 2006;67:585-588.
68. Jacobs E, Singh V, Warsch J, et al. Safety of transradial left-heart cardiac catheterization in patients with end-stage liver disease. *J Am Coll Cardiol* 2011;57:129 (supplement A).
69. Singh M, Rihal CS, Gersh BJ, et al. Twenty-five-year trends in in-hospital and long-term outcome after percutaneous coronary intervention: a single-institution experience. *Circulation* 2007;115:2835-2841.
70. Doyle BJ, Rihal CS, Gastineau DA, Holmes DR Jr. Bleeding, blood transfusion, and increased mortality after percutaneous coronary intervention: implications for contemporary practice. *J Am Coll Cardiol* 2009;53:2019-2027.
71. Kinnaird TD, Stabile E, Mintz GS, et al. Incidence, predictors, and prognostic implications of bleeding and blood transfusion following percutaneous coronary interventions. *Am J Cardiol* 2003;92:930-935.
72. Rao SV, Cohen MG, Kandzari DE, Bertrand OF, Gilchrist IC. The transradial approach to percutaneous coronary intervention: historical perspective, current concepts, and future directions. *J Am Coll Cardiol* 2010;55:2187-2195.
73. Jolly SS, Yusuf S, Cairns J, et al. Radial versus femoral access for coronary angiography and intervention in patients with acute coronary syndromes (RIVAL): a randomised, parallel group, multicentre trial. *Lancet* 2011;377:1409-1420.
74. Mamas MA, Ratib K, Routledge H, et al. Influence of access site selection on pci-related adverse events in patients with STEMI: meta-analysis of randomised controlled trials. *Heart (Br Cardiac Soc)* 2012;98:303-311.
75. Joyal D, Bertrand OF, Rinfret S, Shimony A, Eisenberg MJ. Meta-analysis of ten trials on the effectiveness of the radial versus the femoral approach in primary percutaneous coronary intervention. *Am J Cardiol* 2012;109:813-818.
76. Romagnoli E, Biondi-Zoccai G, Sciahbasi A, et al. Radial versus femoral randomized investigation in ST-segment elevation acute

- coronary syndrome: the RIFLE-STEACS (radial versus femoral randomized investigation in ST-elevation acute coronary syndrome) study. *J Am Coll Cardiol* 2012;60:2481-2489.
77. Verheugt FW, Steinhubl SR, Hamon M, et al. Incidence, prognostic impact, and influence of antithrombotic therapy on access and non-access site bleeding in percutaneous coronary intervention. *JACC Cardiovasc Interv* 2011;4:191-197.
 78. Kugelmass AD, Cohen DJ, Brown PP, Simon AW, Becker ER, Culler SD. Hospital resources consumed in treating complications associated with percutaneous coronary interventions. *Am J Cardiol* 2006;97:322-327.
 79. Rao SV. Implications of bleeding and blood transfusion in percutaneous coronary intervention. *Rev Cardiovasc Med* 2007;8(suppl 3):S18-S26.
 80. Cohen DJ, Lincoff AM, Lavelle TA, et al. Economic evaluation of bivalirudin with provisional glycoprotein iib/iiia inhibition versus heparin with routine glycoprotein iib/iiia inhibition for percutaneous coronary intervention: results from the replace-2 trial. *J Am Coll Cardiol* 2004;44:1792-1800.
 81. Mann T, Cubeddu G, Bowen J, et al. Stenting in acute coronary syndromes: A comparison of radial versus femoral access sites. *J Am Coll Cardiol* 1998;32:572-576.
 82. Mitchell MD, Hong JA, Lee BY, Umscheid CA, Bartsch SM, Don CW. Systematic review and cost-benefit analysis of radial artery access for coronary angiography and intervention. *Circ Cardiovasc Quality Outcomes* 2012;5:454-462.
 83. Amoroso G, Sarti M, Bellucci R, et al. Clinical and procedural predictors of nurse workload during and after invasive coronary procedures: the potential benefit of a systematic radial access. *Eur J Cardiovasc Nurs* 2005;4:234-241.
 84. Thel MC, Califf RM, Tardiff BE, et al. Timing of and risk factors for myocardial ischemic events after percutaneous coronary intervention (IMPACT-II). Integrilin to minimize platelet aggregation and coronary thrombosis. *Am J Cardiol* 2000;85:427-434.
 85. Heyde GS, Koch KT, de Winter RJ, et al. Randomized trial comparing same-day discharge with overnight hospital stay after percutaneous coronary intervention: results of the elective PCI in outpatient study (epos). *Circulation* 2007;115:2299-2306.
 86. Bertrand OF, De Larochelliere R, Rodes-Cabau J, et al. A randomized study comparing same-day home discharge and abciximab bolus only to overnight hospitalization and abciximab bolus and infusion after transradial coronary stent implantation. *Circulation* 2006;114:2636-2643.
 87. Rinfret S, Kennedy WA, Lachaine J, et al. Economic impact of same-day home discharge after uncomplicated transradial percutaneous coronary intervention and bolus-only abciximab regimen. *JACC Cardiovasc Interv* 2010;3:1011-1019.
 88. Caputo RP, Tremmel JA, Rao S, et al. Transradial arterial access for coronary and peripheral procedures: executive summary by the transradial committee of the SCAI. *Catheter Cardiovasc Interv* 2011;78:823-839.

Grossman & Baim's Cardiac Catheterization, Angiography, and Intervention

EIGHTH EDITION

EDITOR

MAURO MOSCUCCI, MD, MBA

Professor of Medicine
Chairman, Department of Medicine (Acting)
Chief, Cardiovascular Division
University of Miami Miller School of Medicine
Miami, Florida



Wolters Kluwer | Lippincott Williams & Wilkins

Health

Philadelphia • Baltimore • New York • London
Buenos Aires • Hong Kong • Sydney • Tokyo

Acquisitions Editor: Julie Goolsby
Product Manager: Leanne Vandetty
Production Project Manager: David Orzechowski
Senior Manufacturing Manager: Beth Welsh
Design Coordinator: Joan Wendt
Production Service: Integra Software Services Pvt. Ltd

© 2014 by LIPPINCOTT WILLIAMS & WILKINS, a WOLTERS KLUWER business
Two Commerce Square
2001 Market Street
Philadelphia, PA 19103 USA
LWW.com

7th edition © 2006 by LIPPINCOTT WILLIAMS & WILKINS
6th edition © 2000 by LIPPINCOTT WILLIAMS & WILKINS
5th edition © 1996 by WILLIAMS & WILKINS

All rights reserved. This book is protected by copyright. No part of this book may be reproduced in any form by any means, including photocopying, or utilized by any information storage and retrieval system without written permission from the copyright owner, except for brief quotations embodied in critical articles and reviews. Materials appearing in this book prepared by individuals as part of their official duties as U.S. government employees are not covered by the above-mentioned copyright.
Printed in China

Library of Congress Cataloging-in-Publication Data

Cardiac catheterization, angiography, and intervention.

Grossman & Baim's cardiac catheterization, angiography, and intervention / editor, Mauro Moscucci, MD, MBA, professor of medicine, chairman, Department of Medicine, University of Miami Miller School of Medicine, Miami, Florida. — Eighth edition.

pages cm

Includes bibliographical references and index.

ISBN 978-1-4511-2740-9 (hardback)

1. Cardiac catheterization. 2. Angiography. I. Moscucci, Mauro, editor of compilation. II. Title. III. Title: Grossman and Baim's cardiac catheterization, angiography, and intervention.

RC683.5.C25C38 2013

616.1'20754—dc23

2013025399

Care has been taken to confirm the accuracy of the information presented and to describe generally accepted practices. However, the authors, editors, and publisher are not responsible for errors or omissions or for any consequences from application of the information in this book and make no warranty, expressed or implied, with respect to the currency, completeness, or accuracy of the contents of the publication. Application of the information in a particular situation remains the professional responsibility of the practitioner.

The authors, editors, and publisher have exerted every effort to ensure that drug selection and dosage set forth in this text are in accordance with current recommendations and practice at the time of publication. However, in view of ongoing research, changes in government regulations, and the constant flow of information relating to drug therapy and drug reactions, the reader is urged to check the package insert for each drug for any change in indications and dosage and for added warnings and precautions. This is particularly important when the recommended agent is a new or infrequently employed drug.

Some drugs and medical devices presented in the publication have Food and Drug Administration (FDA) clearance for limited use in restricted research settings. It is the responsibility of the health care provider to ascertain the FDA status of each drug or device planned for use in their clinical practice.

To purchase additional copies of this book, call our customer service department at (800) 638-3030 or fax orders to (301) 223-2320. International customers should call (301) 223-2300.

Visit Lippincott Williams & Wilkins on the Internet at: LWW.com. Lippincott Williams & Wilkins customer service representatives are available from 8:30 am to 6:00 pm, EST.

10 9 8 7 6 5 4

RRS1903

Contents

Contributors	vii
Preface to the Eighth Edition	xi
Preface to the Website to the Eighth Edition	xiii
Acknowledgments	xv

SECTION I GENERAL PRINCIPLES 1

1. Cardiac Catheterization History and Current Practice Standards 1
Mauro Moscucci
2. Cineangiographic Imaging, Radiation Safety, and Contrast Agents 17
Stephen Balter and Mauro Moscucci
3. Integrated Imaging Modalities in the Cardiac Catheterization Laboratory 44
Robert A. Quaife and John D. Carroll
4. Complications 77
Mauro Moscucci
5. Adjunctive Pharmacology for Cardiac Catheterization 106
Kevin Croce and Daniel I. Simon

SECTION II BASIC TECHNIQUES 139

6. Percutaneous Approach, Including Transseptal and Apical Puncture 139
Claudia A. Martinez and Mauro Moscucci
7. Radial Artery Approach 170
Mauricio G. Cohen and Sunil V. Rao
8. Cutdown Approach: Brachial, Femoral, Axillary, Aortic and Transapical 191
Ronald P. Caputo, G. Randall Green, and William Grossman
9. Diagnostic Catheterization in Childhood and Adult Congenital Heart Disease 208
Gabriele Egidy Assenza, James E. Lock, and Michael J. Landzberg

SECTION III HEMODYNAMIC PRINCIPLES 223

10. Pressure Measurement 223
Mauro Moscucci and William Grossman
11. Blood Flow Measurement: Cardiac Output and Vascular Resistance 245
Mauro Moscucci and William Grossman
12. Shunt Detection and Quantification 261
William Grossman and Mauro Moscucci
13. Calculation of Stenotic Valve Orifice Area 272
Blase A. Carabello and William Grossman

14. Pitfalls in the Evaluation of Hemodynamic Data 284
Zoltan G. Turi

SECTION IV ANGIOGRAPHIC TECHNIQUES 295

15. Coronary Angiography 295
Mauro Moscucci
16. Coronary Artery Anomalies 335
Paolo Angelini and Jorge Monge
17. Cardiac Ventriculography 354
Mauro Moscucci and Robert C. Hendel
18. Pulmonary Angiography 370
Kyung Cho and Nils Kucher
19. Angiography of the Aorta and Peripheral Arteries 399
Michael R. Jaff, John Rundback, and Kenneth Rosenfield

SECTION V EVALUATION OF CARDIAC FUNCTION 431

20. Stress Testing During Cardiac Catheterization: Exercise, Pacing, and Dobutamine Challenge 431
William Grossman and Mauro Moscucci
21. Measurement of Ventricular Volumes, Ejection Fraction, Mass, Wall Stress, and Regional Wall Motion 456
Michael A. Fifer and William Grossman
22. Evaluation of Systolic and Diastolic Function of the Ventricles and Myocardium 467
William Grossman and Mauro Moscucci
23. Evaluation of Tamponade, Constrictive, and Restrictive Physiology 489
Mauro Moscucci and Barry A. Borlaug

SECTION VI SPECIAL CATHETER TECHNIQUES 505

24. Evaluation of Myocardial and Coronary Blood Flow and Metabolism 505
Morton J. Kern and Michael J. Lim
25. Intravascular Imaging Techniques 545
Yasuhiro Honda, Peter J. Fitzgerald, and Paul G. Yock
26. Endomyocardial Biopsy 576
Sandra V. Chaparro and Mauro Moscucci
27. Percutaneous Circulatory Support: Intra-aortic Balloon Counterpulsation, Impella, TandemHeart, and Extracorporeal Bypass 601
Daniel Burkhoff, Mauro Moscucci, and Jose P.S. Henriques

SECTION VII INTERVENTIONAL TECHNIQUES 627

28. Percutaneous Balloon Angioplasty and General Coronary Intervention 627
Abhiram Prasad and David R. Holmes
29. Atherectomy, Thrombectomy, and Distal Protection Devices 665
Robert N. Piana and Jeffrey J. Popma

30. Intervention for Acute Myocardial Infarction 697
William O'Neill
31. Coronary Stenting 710
Ajay J. Kirtane and Gregg W. Stone
32. General Overview of Interventions for Structural Heart Disease 760
Mauro Moscucci, John D. Carroll, and John G. Webb
33. Percutaneous Therapies for Valvular Heart Disease 772
Ted Feldman and Mauro Moscucci
34. Peripheral Intervention 805
Mehdi H. Shishehbor and Samir R. Kapadia
35. Intervention for Pediatric and Adult Congenital Heart Disease 838
Robert J. Sommer
36. Cardiac Cell-Based Therapy: Methods of Application and Delivery Systems 871
Joshua M. Hare, Arnon Blum, and Alan W. Heldman
37. Aortic Endovascular Grafting 891
Arash Bornak, Gilbert R. Upchurch, and Omaid C. Velazquez
38. Pericardial Interventions: Pericardiocentesis, Balloon Pericardiotomy, and Epicardial Approach to Cardiac Procedures 904
Mauro Moscucci and Juan F. Viles-Gonzalez
39. Interventions for Cardiac Arrhythmias 921
Haris M. Haqqani and Francis E. Marchlinski

SECTION VIII CLINICAL PROFILES 943

40. Profiles in Valvular Heart Disease 943
Ted Feldman, William Grossman, and Mauro Moscucci
41. Profiles in Coronary Artery Disease 970
Robert N. Piana and Aaron Kugelmass
42. Profiles in Pulmonary Hypertension and Pulmonary Embolism 991
Scott H. Visovatti and Vallerie V. Mclaughlina
43. Profiles in Cardiomyopathy and Heart Failure 1011
James C. Fang and Barry A. Borlaug
44. Profiles in Pericardial Disease 1045
John F. Robb, Roger J. Laham, and Mauro Moscucci
45. Profiles in Congenital Heart Disease 1060
Gabriele Egidy Assenza, Robert J. Sommer, and Michael J. Landzberg
46. Profiles in Peripheral Arterial Disease 1078
Christopher J. White and Stephen R. Ramee

Index 1113

Section VII

Interventional Techniques

28

Percutaneous Balloon Angioplasty and General Coronary Intervention

ABHIRAM PRASAD and DAVID R. HOLMES

Dotter and Judkins¹ were the first to propose the concept of transluminal angioplasty—enlargement of the lumen of a stenotic vessel by a catheter—technique in 1964. Their technique used a spring-coil guidewire over which a series of progressively larger rigid dilators were advanced to dilate the atherosclerotic arterial stenosis. While the Dotter technique proved effective in peripheral arteries, the need to insert large-caliber rigid dilators through the arterial puncture (and the high shear forces applied by the dilators as they crossed the atherosclerotic lesion) ultimately restricted its clinical application. Gruentzig's pioneering work in 1974² replaced the rigid dilators with an inflatable nonelastomeric balloon mounted on a comparatively smaller catheter shaft which could be introduced percutaneously, advanced across a vascular stenosis in its smaller (collapsed) state, and then inflated with sufficient force to enlarge the stenotic lumen. Although others had speculated about the possibility, Gruentzig was the first to refine balloon angioplasty into a usable clinical tool, through a series of experiments in animals, cadavers, peripheral arteries, and the coronary arteries of patients undergoing bypass surgery. This culminated in the first percutaneous

transluminal coronary angioplasty (PTCA) of a stenotic coronary artery in a conscious human (September 16, 1977).³

Balloon angioplasty remained the only catheter-based revascularization technique in widespread use until the mid-1990s, when other modalities including atherectomy and stents (see Chapters 29 and 31) were introduced. Accordingly, the technique is now more commonly referred to as percutaneous coronary intervention (PCI). This chapter will review the basic equipment, techniques, and results of coronary angioplasty as a historical and conceptual foundation for the entire field of catheter-based PCI.

HISTORY

Gruentzig's new technique of balloon angioplasty was initially met with a great deal of skepticism by many cardiologists, but a small group around the world recognized its great potential.⁴ In 1979, these early adopters met to form a registry of all coronary angioplasty cases worldwide under the sponsorship

627

of the National Heart, Lung, and Blood Institute (NHLBI) which had enrolled 3,000 cases by 1981. Over time, progressive improvements in equipment and technique have produced dramatic growth in PTCA and transformed it into the dominant form of coronary revascularization (Figure 28.1). In 2009, approximately 596,000 PCI (in-patient) procedures were performed in the United States⁵; also it is one of the most common procedures used worldwide.

Over the past 15 years or so, the role of balloon dilation has become much less prominent as a stand-alone treatment. In current practice, it serves predominantly as an *adjunctive* therapy for preparing (i.e., predilating) or optimizing (i.e., postdilating) stent placement. Despite the fact that PCI is being performed in increasingly more complex lesions and patients, the advent of the stents and other new interventional devices, as well as adjunctive antithrombotic pharmacology (see Chapter 5), has improved the procedural success rate of PCI to approximately 95%, the procedural mortality to approximately 1%, and the emergency bypass rate to <0.5% among an unselected cohort.⁶

EQUIPMENT

A coronary angioplasty system consists of three basic components (Figure 28.2): (a) a guiding catheter, which provides stable access to the coronary ostium, a route for contrast administration, and a conduit for the advancement of the equipment; (b) a guidewire that can be passed through the guiding catheter, across the target lesion into the distal coronary vasculature to provide a rail over which therapeutic devices can be advanced; and (c) a balloon dilatation catheter filled with contrast medium.

Guiding Catheters

The original guiding catheters were thick-walled 10F- or 11F-outer diameter tubular structures that had small lumens, minimal torque control, and traumatic edges. In contrast, current guiding catheter designs more closely emulate the performance of diagnostic coronary angiographic catheters. To allow passage of therapeutic instruments, however, guiding catheters must have a lumen diameter at least twice that of a typical diagnostic catheter (e.g., 0.076 inch [2 mm] versus 0.038 inch [1 mm]). To achieve this lumen in a catheter of outer diameter as small as 6F the catheter walls must be very thin (<0.12 mm, or 0.005 inch). Yet the catheter must still incorporate a Teflon liner to reduce friction, metal or plastic braid to transmit torque and provide sufficient stiffness to offer backup support during device advancement, and a smooth outer coating to resist thrombus formation. The complexity of this design goal requires use of special materials the properties of which are typically varied along the length of the catheter to optimize the balance between support and flexibility at each point. Most guiding catheters now

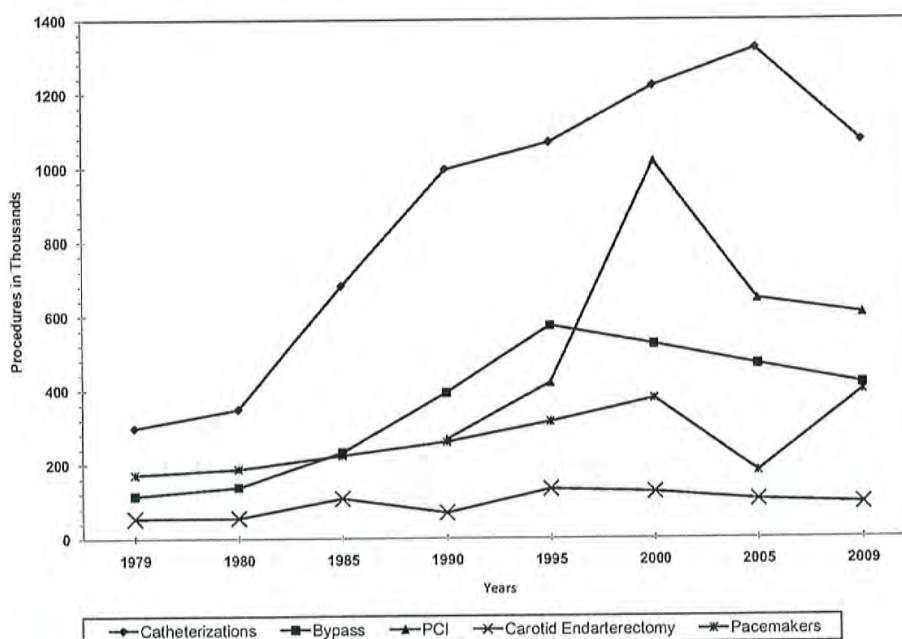
also include a very soft material in the most distal 2 mm of the catheter to reduce the chance of vessel trauma during engagement of the nontapered tip.

Guiding catheters are available in virtually all of the conventional Judkins and Amplatz curves, as well as in a wide range of custom shapes (extra backup (XB), hockey stick, multipurpose, Voda, etc.) designed to ease engagement or provide better support during balloon advancement. As thin-wall technology has improved and balloon shaft diameters have decreased, the size of the guiding catheters needed to perform PCI has fallen progressively. In the 1980s and 1990s, 9F and 8F/7F guiding catheters predominated, respectively. Although larger guiding catheters are sometimes still needed for rotational atherectomy, or treatment of bifurcation lesions (7F for kissing balloons and 8F for two stents) or chronic total occlusions, most procedures in current practice can be completed through 6F guiding catheters. Also available are 5F guiding catheters, but they offer no major advantage and are not routinely used.

To function adequately, the guiding catheter must be able to selectively engage the ostium. This requires the selection of an appropriate catheter shape and the ability to manipulate the catheter under fluoroscopic guidance (see Chapter 15). Engagement of the desired vessel, however, should not interfere with arterial inflow. This is routinely possible in the left coronary artery, but damping of the guiding catheter pressure when the right coronary artery ostium is engaged was once a common and vexing problem. This has been overcome by the smaller-diameter (e.g., 6F) guiding catheters and by the introduction of guiding catheters equipped with side holes that allow ongoing perfusion despite wedged engagement. Since the guiding catheter is also used to deliver small boluses of contrast medium into the target vessel (as needed to visualize vascular side branches and the target lesion for angioplasty), contrast flow out of such side holes may increase the total contrast volume used during a procedure. Also, use of catheters with side holes may provide a false sense of security by showing a normal pressure tracing in the face of reduced coronary perfusion. For these reasons, their use should be minimized.

A second important function of the guiding catheter is to provide adequate support for advancement of interventional devices across the target stenosis. This support is derived from the intrinsic stiffness of the guiding catheter, the shape that allows it to buttress against the opposite aortic wall, and deep engagement of the guiding catheter into the coronary ostium (Figure 28.3). While deep engagement of the guiding catheter is sometimes required in challenging cases, it is also well-recognized as a potential cause of complications (e.g., ostial or proximal coronary dissection). This complication has become far less frequent with incorporation of an atraumatic tip on most guiding catheters and the performance of deep engagement only by relying on coaxial advancement over the balloon catheter. After a deeply engaged guiding catheter has been used to position a dilatation balloon or other device across the lesion, it is important to then withdraw the guiding

Trends in cardiovascular procedures, United States: 1979–2009.



Writing Group Members et al. *Circulation* 2012;125:e2-e220

Figure 28.1 Trends in cardiovascular procedures, United States: 1979–2009. PCI indicates percutaneous coronary intervention. Note: Inpatient procedures only. Source: National Hospital Discharge Survey, National Center for Health Statistics, and National Heart, Lung, and Blood Institute. (Roger et al. Heart disease and stroke statistics—2012 update: a report from the American Heart Association. *Circulation* 2012;125:e12–e230.)

catheter back to avoid its migration into an even deeper position as the device is withdrawn. In this sense, the ability to actively use the guiding catheter constitutes one of the important skills required for effective management of the overall angioplasty equipment system.

Guidewires

The original dilatation balloon designed by Gruentzig had a short fixed segment of guidewire (spring coil) attached to its tip to lead the balloon in the vessel lumen and help avoid subintimal passage as the catheter was advanced across the stenosis (see Figure 28.2). These devices provided the operator no control over whether the catheter followed the desired path or was diverted into one or more side branches proximal to the lesion, because neither the shape nor the orientation of the leading wire could be modified. In the early 1980s, Simpson designed a *movable* guidewire system in which a 0.018 inch Teflon-coated wire extended and moved freely through a central lumen within a coaxial dilatation catheter.⁷

If this guidewire selected the desired vessel, it was advanced until it crossed the target lesion. If the guidewire instead selected a more proximal side branch, the balloon catheter was advanced to a point just before the side branch and the wire was withdrawn and reshaped in an effort to choose the desired path beyond. By a series of such iterative advancements of wire and dilatation catheter, many lesions could be crossed by the guidewire and then by the dilatation catheter. In 1983, this concept was advanced further with the introduction of the first *steerable* guidewires, the rotational orientation of which could be controlled precisely using a “torquer” (pin vise) attached to the proximal end of the wire.

In contrast to crude early guidewires, modern guidewires are designed to combine tip softness, trackability around curves, radiographic visibility, and precise torque control, which together allow the guidewire to be steered past vascular side branches and through tortuous or stenotic segments. With these refinements, crossing a subtotal lesion with the guidewire has become a task that takes seconds rather than minutes to hours, opening up all portions of the epicardial

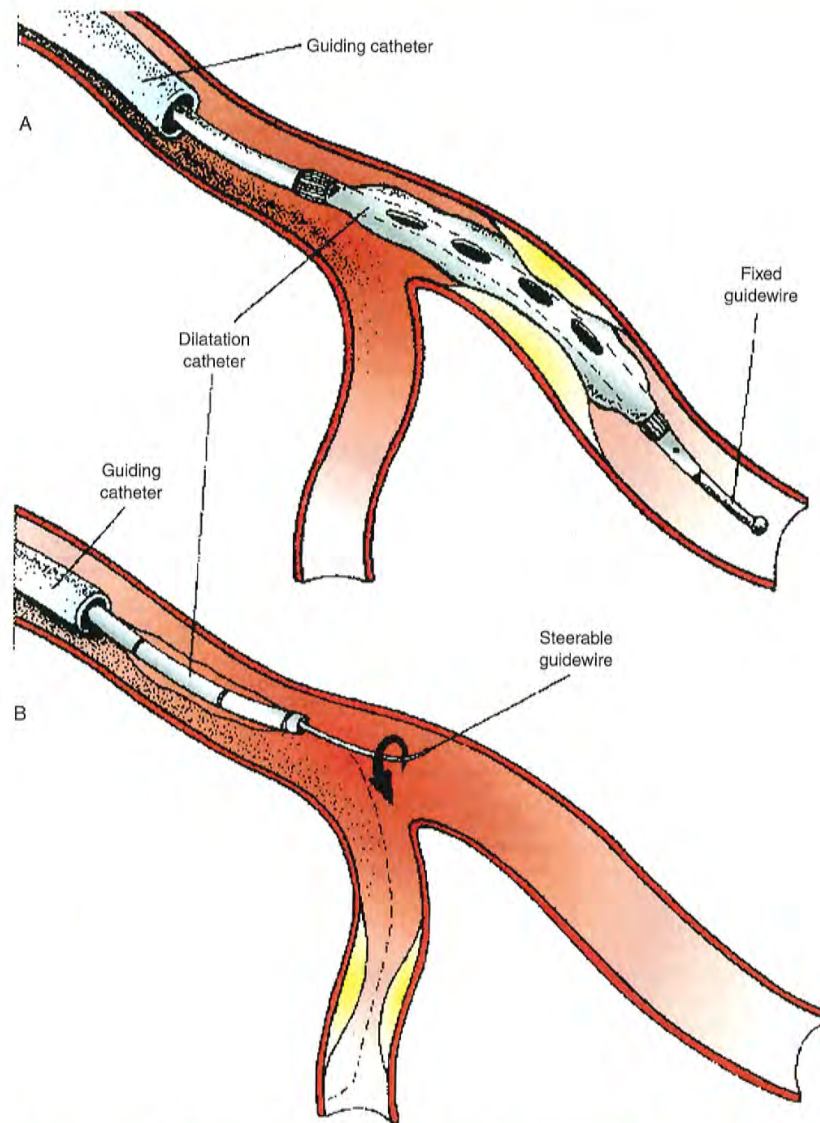


Figure 28.2 Components of the coronary angioplasty system. The original Gruentzig fixed guidewire balloon (A) is compared with the steerable guide wire system (B). Although both are advanced through a guiding catheter positioned in the coronary ostium, neither the wire shape nor its orientation could be changed once the original Gruentzig catheter was introduced, whereas the steerable design allows the guidewire to be advanced, withdrawn, and reshaped, and steered independently of the balloon catheter to select the desired vessel. Once in place in the distal vessel beyond the target lesion, the guidewire serves as a rail over which the angioplasty balloon or other device can be advanced.

coronary circulation to a variety of interventional devices. The basic guidewire consists of a solid core (stainless steel or superelastic nitinol) that is ground to a progressive taper in its distal portion. This taper helps retain torque control when

the wire is steered around the series of bends located in the guiding catheter and proximal coronary anatomy and allows the stiffer proximal portions of the wire to follow the soft tip into side branches. This core is generally covered by a spring

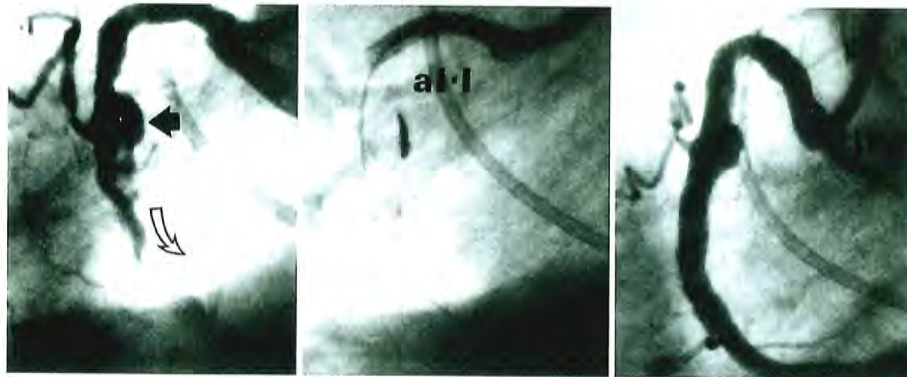


Figure 28.3 Use of deep guiding catheter engagement to facilitate coronary intervention. **Left.** Complex lesion in the right coronary artery including aneurysm (*dark arrow*) and diffuse distal disease (*open curved arrow*). **Center.** Left Amplatz guiding catheter (AL-1) is deeply engaged to provide optimal support for stent placement. **Right.** After stent placement, the vessel is widely patent, but replacement of the Amplatz catheter with a conventional right Judkins catheter (JR4) shows how effective the Amplatz has been in straightening out a severe upward bend (shepherd's hook) in the proximal right coronary artery. Although progressive improvement in device profile and trackability has made such deep engagement less necessary, the technique is still of great value in selected cases. Deep seating of the guiding catheter needs to be done with great care and by coaxial advancement of the guiding catheter over a balloon catheter to avoid injuring the proximal coronary artery.

coil, and a coating (e.g., Teflon, Silicone) is generally applied to the body of the wire. Radiopaque platinum is often applied to the distal 3 to 25 cm. A family of hydrophilic polymer covered tip guidewires are also available to aid in crossing vessels with extreme tortuosity, calcification, side branches through stent struts, and total occlusion. It must be remembered that hydrophilic wires allow reduced tactile feel and are more likely to cause dissections or perforations.

There is substantial choice of tip stiffness, driven by the way the tapered core wire is attached to the outer coil at the wire tip. In soft wires, the tapered core is generally welded to the coil via a flattened intermediary shaping ribbon that allows the operator to kink or bend the tip of the wire into a shape that is appropriate for navigating the vessel features it must pass while maintaining the required level of atraumatic softness. Even with soft "work horse" wires, it is still important to heed the advice of Dotter and Judkins¹ that "*the guidewire is passed across the atheromatous block more by the application of judgment than of force.*" Wires with preshaped tips are generally used for the majority of cases in contemporary practice, but the tips may be manually shaped, particularly to meet the challenges of anatomic navigation. Longer primary tips or a secondary bend are used for large-diameter arteries and for entering tortuous segments. Short and less-angulated tips are best suited for entering diffusely diseased and chronically occluded arteries.

When larger *probing force* is required (e.g., for crossing a chronic total occlusion), stiffer tip designs are available. These "core-to-tip" guidewires are often graded by the force

that the straight guidewire tip can apply to a strain gauge from a distance of 1 cm. Wires are available with force increments of 3, 4.5, 6, 9, and 12 g in the United States, though wires with even higher tip stiffness are available in other countries. The core-to-tip design also provides better torque control. Use of these stiff-tip guidewires requires a high degree of skill and feel to avoid unintentional vessel injury (dissection or perforation), and in general, less experienced operators are well advised to start with softer guidewires and work up to the stiffer wires progressively.

Independent of the tip stiffness, advancing certain devices around bends may take more *shaft support* from the guidewire. This is provided by extra-support wires, which have a thicker and firmer inner core. Alternatively, some operators prefer to place a second guidewire across the lesion in parallel (a "buddy" wire) to straighten vessel bends and facilitate device passage. With the wide variety of choices in 0.014 inch guidewires, it is currently rare to use larger-diameter guidewires in coronary work, although wires of 0.016 and 0.018 inch were previously used for this purpose (requiring, of course, the use of matching devices with larger internal lumen diameters). Guidewires with a diameter of <0.014 inch offer little advantage except with certain devices such as the 0.009 inch Rotablator wire (see Chapter 29), but some specialty chronic total occlusion guidewires have a tapered tip (0.014 inch to 0.009–0.012 inch) to help penetrate the plaque and find microchannels.

Standard coronary guidewires are approximately 190 cm long, that is, some 50 cm longer than the average balloon

catheter shaft. This allows the wire to be advanced across the lesion while the balloon catheter remains in the guiding catheter, but does not generally offer sufficient length for exchange of one "over-the-wire" (OTW) device for another. Most guidewires are therefore also available in a 300 cm exchange length, or are extendable to that length by attachment of an extension. Such wires can be passed through the guiding catheter and across the target lesion and remain in place as a series of OTW devices (balloons, rotational atherectomy burrs, stents) are delivered or removed without the need for recrossing the lesion.⁸ OTW devices have largely been replaced by rapid-exchange (Rx) or monorail balloon catheters and stent delivery systems compatible with shorter guidewires.

Dilatation Catheters

The dilatation catheters for coronary angioplasty have undergone radical evolution since 1977. As described above, the original Gruentzig catheters were designed with a short segment of guidewire permanently affixed to the catheter tip to decrease the risk of subintimal passage during advancement down the coronary tree. The shaft of these catheters had two lumens—one for inflation and deflation of the balloon and one for distal pressure measurement and/or contrast injection. This reflected the initial reliance on monitoring trans-stenotic (i.e., aortic root to distal coronary) pressure gradient as a way of assessing lesion severity, since it was very difficult to perform adequate contrast injections through small-lumen guiding catheters around the large (4.3F, 1.3 mm) shafts of early balloon catheters. In contrast, contemporary catheters are delivered over independently movable and/or steerable guidewires (see Figure 28.2). The central lumen of such dilatation catheters must have a sufficient caliber to allow free movement of the guidewire, but are no longer used for either pressure measurement or contrast injection. However, it is of interest that the measurement of trans-stenotic pressure gradients to evaluate the significance and completeness of correction of coronary stenoses has evolved into pressure measurement guidewires (see "Fractional Flow Reserve," Chapter 24).

An important characteristic of the dilatation catheter is the diameter of the smallest opening through which the deflated balloon can be passed (its *profile*). The original Gruentzig catheters had a 0.060 inch (1.5 mm) profile, but current dilatation catheters have profiles as small as 0.020 inch (0.5 mm). To preserve the best balloon profile, a "negative" or "aspiration" preparation should be performed in which a contrast-filled 20 mL syringe is attached to the balloon inflation hub, the plunger is pulled back to apply a vacuum, and gently released to allow the balloon to draw in a small volume of dilute (1:2 dilution with saline) contrast. The crossing profile increases significantly after a balloon is used, and this may be relevant when one attempts to reuse a previously inflated balloon to cross a second lesion and finds that the secondary (or rewrap) profile is far less satisfactory than the primary (prior to inflation) profile.

Balloon angioplasty catheters are available either as OTW catheters in which the guidewire runs through a central lumen in the shaft throughout its entire length or as *monorail* Rx catheters in which the wire is contained within the balloon shaft only over its distal 25 cm and then runs outside the balloon shaft more proximally. The latter type of catheters can be exchanged quickly by a single operator over a standard-length (190 cm) guidewire and generally have smaller shaft profiles to allow better contrast injection or simultaneous placement of two balloons for the treatment of bifurcation lesions. *Fixed-wire* devices, which consisted of a balloon mounted directly on a steerable wire core (deflated profile of 0.020 inch or 0.5 mm), were widely used in the late 1980s, but are no longer in use today.

Although profile is important, the ability of the balloon to bend so as to advance easily through tortuous vascular segments (*trackability*) and the presence of sufficient shaft stiffness (*pushability*) to force it through the stenosis are also important. Delivery of the balloon is also aided by the incorporation of a friction-resistant coating to improve surface lubricity. Specialized balloon catheters include perfusion balloon catheters, which have a series of side holes in the shaft proximal and distal to the balloon segment or a spiral channel within the balloon to allow ongoing antegrade blood flow and thereby mitigate myocardial ischemia during prolonged balloon inflations. In an era when stents provide definitive control of elastic recoil and dissection, however, the use of perfusion balloons has become rare except for controlling hemorrhage from a coronary perforation without producing severe distal myocardial ischemia (see Chapter 4). Some special balloons exploit the concept of *focused force angioplasty*, in which a wire (Angiosculpt balloon, AngioScore, Fremont, CA) or microblades on the balloon surface (cutting balloon, Boston Scientific, Natick, MA) concentrate the delivery of dilating force from the balloon to the lesion to lower stenosis resolution pressure and reduce balloon slippage forward or backward during inflation (the so-called watermelon seeding effect). These technologies have not, however, improved the long-term patency as compared with conventional PTCA,^{9,10} and the cutting balloon carries a small but real risk of perforation when oversized. These devices have been promoted for use in ostial lesions or in-stent restenosis owing to neointimal proliferation, but there is no definitive evidence that they improve procedural outcomes.

Other than these factors, the most important characteristic of the dilatation catheter is its ability to inflate to a precisely defined diameter despite application of pressures that average 10 to 16 atm. This was not possible with early balloons manufactured from polyvinyl chloride (PVC); their compliance led to balloon oversizing and rupture at pressures as low as 6 atm. More suitable performance can be readily achieved today using balloons manufactured from high-density polyethylene, polyethylene terephthalate (PET), or nylon, despite balloon wall thicknesses as low as 0.0003 to 0.0005 inch (7.62 to 12.7 μm). Based on material and wall thickness, each balloon has an individual compliance characteristic reflecting

the pressure at which the balloon reaches its specified (nominal) diameter and how much that diameter increases as the balloon is inflated to even higher pressures. More compliant balloon materials tend to reach their nominal diameter at 6 atm and then grow by $\leq 20\%$ above their nominal size (i.e., a 3.0 mm balloon growing to 3.5 mm) at 10 atm. Semicompliant balloon materials such as high-density polyethylene or nylon grow by $< 10\%$ over this pressure range, whereas truly noncompliant balloon materials such as PET can retain their defined diameter up to 20 atm to allow dilatation of calcific stenoses or full expansion of coronary stents (Figure 28.4).

Balloon compliance characteristics must be kept in mind especially when inflating a compliant or semicompliant balloon to pressures above nominal (usually roughly 6 to 10 atm) to avoid overdilating the adjacent normal vessel. Noncompliant balloons are desirable when high pressure inflation is needed (resistant lesions and postdilation of stents) so that the dilating force is applied to treat the stenosis rather than in enlarging the balloon.

Regardless of which balloon type is used, it is important to stay within the stated range of inflation pressures in order to avoid balloon rupture. This pressure range is specified in terms of the *rated burst pressure* (i.e., an inflation pressure at which the probability of balloon rupture is $< 0.1\%$). Taking any balloon catheter above its rated burst pressure (usually 16 to 20 atm) increases the risk of balloon rupture, with the potential for air embolization (if the balloon was incompletely purged), vessel rupture, local dissection, or difficulty in removing the balloon from an incompletely dilated lesion.¹¹ This risk grows further with pressures above the rated burst pressure to which the balloon is inflated, until it reaches 50% risk of rupture when the *maximum burst pressure* is reached. Instead of relying solely on high balloon inflation pressures, we recommend the use of rotational atherectomy for treating resistant lesions which are invariably associated with severe calcification. An uncommon exception to this rule is stent postdilatation in a calcified or fibrotic lesion that has not been adequately predilated or pretreated with rotational atherectomy before stent placement, and where there is no alternative for achieving full stent expansion.

Various manufacturers currently provide dilatation catheters that meet these design specifications with inflated diameters of 1.25, 1.5, 2.0, 2.5, 3.0, 3.5, and 4.0 mm to match the size of the coronary artery in which the stenosis is located. Larger balloons (i.e., 4.5, 5.0, and 6.0 mm) are occasionally needed for treatment of large right coronary arteries or saphenous vein grafts. Quarter-sized balloons (e.g., 2.25, 2.75, and 3.25 mm) are also available, but that degree of precision probably exceeds the operator's ability to gauge vessel size, and stocking quarter-sizes tends to unfavorably increase the size of a laboratory's balloon inventory. The typical lesion requires a predilatation balloon that is 12 to 15 mm long, but balloons are also available for shorter (8 mm for dilating or postdilating focal lesions) or longer (20 or 30 mm for dilation of a diffusely diseased segment) diffuse lesions.¹² Although most lesions can be dilated effectively with balloon catheters from

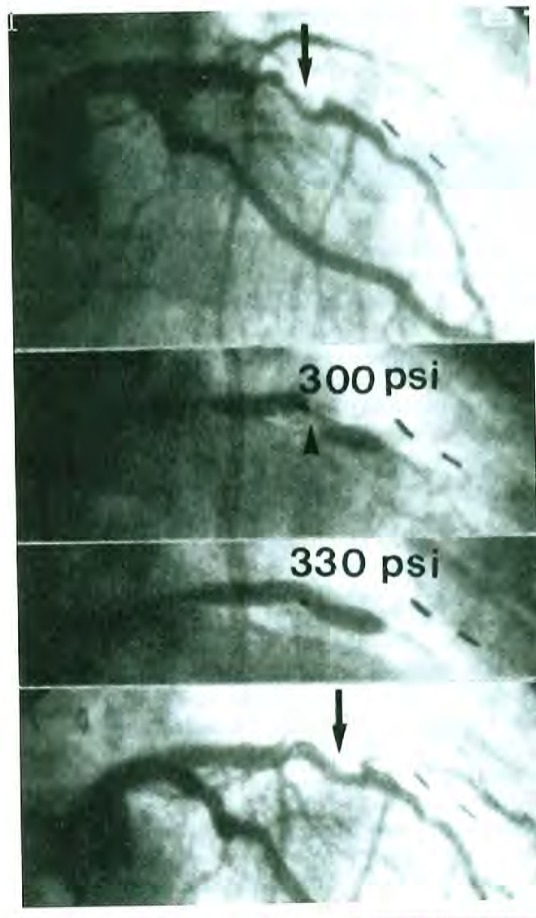


Figure 28.4 Successful dilatation of a rigid calcific lesion (*arrows*). This rigid lesion (**top**) in the midleft anterior descending coronary artery of a postbypass patient (note surgical clips) resisted dilatation at 300 lb/in² (20 atm), but yielded to an inflation pressure of 330 lb/in² (22 atm; **middle two views**) with reduction in the stenosis (**bottom**). Such pressures are obtainable only with high-pressure noncompliant balloons. In current practice, such "nondilatable" lesions would most appropriately be treated by rotational atherectomy (see Chapter 29).

any of the several manufacturers, subtle differences in performance characteristics can make the difference between success and failure; therefore, each interventional laboratory still needs to stock a variety of balloon types. Although balloon prices were once nearly \$700, competition and widespread use have brought current prices down to approximately \$150,

giving little incentive for resterilization and reuse, with the risk of infection, prolonged procedure time, and device failures with resterilized products.^{13,14}

PROCEDURE

A coronary angioplasty procedure bears a superficial resemblance to diagnostic cardiac catheterization in that catheters are introduced percutaneously under local anesthesia. However, since angioplasty involves selective cannulation of coronary arteries with guidewires and balloon catheters, temporary occlusion of antegrade coronary arterial flow, as well as manipulation of the culprit lesion by balloon inflation and/or stent deployment, the procedure is significantly more complicated and entails approximately 10-fold higher risk (i.e., 1% versus 0.1%) as compared with a diagnostic catheterization.¹⁵ However, the risks of coronary angioplasty vary widely with the baseline clinical condition of the patient, the characteristics of the lesion to be treated, and the techniques used (see "Complications" below and Chapter 4).

When obtaining informed consent, the estimated individual risks together with the potential benefits, alternatives, and goals should be discussed in detail with the patient and family prior to the procedure. To mitigate the very real risks of major complications, angioplasty should be attempted only by experienced personnel and generally only in a setting where full cardiac surgical and anesthesia support is available.¹⁶ One exception is the performance of primary PCI for the treatment of acute ST-elevation myocardial infarction (STEMI), where the need for rapid revascularization has led to the allowance of such procedures in approved catheterization laboratories staffed by experienced interventional operators, even when onsite cardiac surgery is not available. An expert consensus document from the Society for Cardiovascular Angiography and Interventions details the requirements for establishing a PCI program without onsite surgical backup.¹⁷ The practice of elective angioplasty without onsite surgery, however, remains outside the recommendations of PCI guidelines at this time, though it is performed in some hospitals in the United States and Europe that have appropriate program development using clinical and angiographic criteria for patient selection.^{16,18}

Historically patients were admitted the night before elective angioplasty, but currently elective patients are admitted on the morning of the procedure. Details of patient evaluation, informed consent, and preprocedure laboratory work will thus generally have been completed in a separate outpatient visit or be compressed into a very brief encounter immediately prior to the procedure. This is particularly true for patients who come to catheter-based intervention at the conclusion of what began as a diagnostic catheterization that progressed to coronary intervention (the so-called *ad hoc* PCI).¹⁹ Although a major proportion of PCI is now performed in the *ad hoc* fashion, consideration of staging is important in

case of the following situations: (a) high anticipated procedural risk or technical complexity (e.g., chronic total occlusion) making surgical consultation or additional discussions with the patient and family desirable before proceeding with a nonemergency intervention; (b) Nonavailability of PCI at the diagnostic catheterization facility; and (c) the likelihood of the combined procedure leading to a large volume of contrast being used. Similar considerations apply to the decision to stage a complex multivessel procedure into two or more sessions (e.g., patient tolerance, clinical stability, total contrast load, stability of the initial treatment results), but current techniques generally make staging (between diagnostic and interventional procedures, or between treatment of some lesions and others) an uncommon clinical necessity. Finally, patients should be counseled on the need for and risks of dual antiplatelet therapy before placement of intracoronary stents, especially drug eluting stents, and alternative therapies should be pursued if patients are unwilling or unable to comply with the recommended duration of dual antiplatelet therapy.

Oral intake should be restricted after midnight on the evening prior to the procedure, and the patient should be pretreated with *aspirin* 325 mg/day to diminish platelet deposition on the disrupted endothelium.²⁰ Patients not on aspirin therapy should be given nonenteric aspirin 325 mg, while those already taking daily aspirin therapy should receive 81 to 325 mg before PCI. In the aspirin-allergic patient requiring an elective PCI, a graded aspirin desensitization protocol²¹ may be considered prior to the procedure. An *oral platelet ADP-receptor antagonist* (such as clopidogrel, prasugrel, ticagrelor) should generally be administered prior to the procedure,²² supplemented by intravenous platelet glycoprotein IIb/IIIa receptor antagonists in patients with acute coronary syndromes,²³ to reduce the incidence of periprocedural myocardial infarction or repeat emergency revascularization for vessel closure or stent thrombosis. Since aspirin reduces late cardiac mortality in patients with coronary disease, it is generally continued indefinitely after the procedure. Similar data now exist for longer-term clopidogrel treatment, and hence *ADP-receptor antagonists* may be used as an alternative to aspirin in patients with aspirin allergy.²⁴ Statins appear to have some benefits when pretreatment is initiated from 7 days to just prior to PCI, especially in statin naïve patients. Hence, it is *reasonable* to administer a high dose of statin before PCI to reduce the risk of periprocedural MI.²⁵ Patients with a past history of an hypersensitivity reaction to contrast media should receive steroid and antihistamine prophylaxis; this prophylaxis is not beneficial in patients with a prior history of allergic reactions to shellfish or seafood.²⁶ Finally, patients should be assessed for risk of contrast-induced acute kidney injury (nephropathy). Important risk factors for contrast-induced acute kidney injury include advanced age, chronic kidney injury, diabetes mellitus, congestive heart failure, and the volume of contrast used during the procedure. The risk may be estimated using a scoring system.²⁷ Adequate hydration and minimizing the volume of contrast administered are

the only interventions demonstrated to reduce the risk of contrast-induced acute kidney injury (see Chapter 4). It is most important to do so in patients with creatinine clearance of <60 mL/minute. There is now good evidence demonstrating that administration of *N*-acetylcysteine is not beneficial.

The 2011 PCI guidelines advocate that a "time-out" is performed before all PCI to verify that the correct patient is having the intended procedure.¹⁶ The aim of this process is to improve patient care by collective discussion of the case immediately prior to the procedure. The timeout may be checklist driven or conversational, depending on each laboratory's established practice.²⁸

PCI is performed either via the femoral or via the radial approach, based on considerations about potential complications related to vascular access, as well as operator and patient preference. The 2011 PCI guidelines state that it is *reasonable* to use radial artery access to decrease access site complications. However, femoral access remains the most commonly used approach in the United States. Vascular complications via the femoral approach may be minimized by the use of fluoroscopic landmarks or ultrasound guidance. Low punctures are associated with hematomas and other vascular complications while high punctures increase the risk of retroperitoneal hemorrhage. Most catheter-based interventions are performed safely without right heart catheterization, but occasionally venous access is also required for the initiation of ventricular pacing, although placement of a prophylactic pacemaker is seldom needed except in cases of rotational atherectomy of the right coronary artery or rheolytic thrombectomy (see Chapter 29). In addition, there are some high-risk procedures in which measurement of right heart pressures may aid in fluid management.

After placement of the arterial sheath, intravenous anti-thrombin therapy is initiated (see Chapter 5). The most common agent is still *unfractionated heparin* (70 U/kg), which may be reduced to 50 U/kg when there is concomitant administration of a platelet glycoprotein IIb/IIIa receptor antagonist. Alternatives include *low-molecular weight heparin* (e.g., enoxaparin) in patients who have been on such agents pre-procedure²⁹ or a *direct thrombin antagonist* (e.g., bivalirudin [Angiomax, the Medicines Company, Parsippany, NJ]).^{30,31} If unfractionated heparin is used, it should be noted that there is wide patient-to-patient variability in heparin binding and activity. So, ACT (activated clotting time) should be measured and additional heparin administered as needed to prolong the ACT to 275 to 300 seconds (reduced to 250 seconds if a platelet glycoprotein IIb/IIIa receptor blocker is to be given) *before any angioplasty devices are introduced*. Additional doses or an infusion of the antithrombotic agent may be required to maintain the ACT at this level throughout the case—ACTs <250 seconds are associated with a marked increase in the incidence of occlusive complications unless an adjunctive IIb/IIIa receptor blocker is used, whereas ACTs >300 to 350 seconds tend to increase the risk of bleeding.³² ACTs may also be used to monitor the effect of direct thrombin inhibitors such as bivalirudin, which have found increasing use

during PCI based on more predictable dose–response characteristics than that of heparin, greater efficacy against clot-bound thrombin, reduced platelet activation, less bleeding, and lack of cross-reactivity in patients with heparin-induced thrombocytopenia (HIT, Chapter 5). Since low-molecular weight heparin has relatively more activity against factor Xa than against thrombin, it causes less prolongation of the ACT so that specialized anti-Xa assays are required to monitor low-molecular weight heparin effects.

Baseline angiograms are then obtained of one or both coronary arteries using either a standard diagnostic catheter or the angioplasty guiding catheter. Baseline angiography serves to (a) evaluate any potential changes in angiographic appearance (interval development of total occlusion, thrombus formation) since the previous diagnostic catheterization, (b) permit the selection of the angiographic views that allow optimal visualization of the stenoses, and (c) aid in planning of the detailed interventional strategy. Coronary injections should be repeated after the administration of sublingual or intracoronary nitroglycerin to demonstrate that spasm is not a significant component of the target stenosis and to minimize the occurrence of coronary spasm during the subsequent angioplasty. Occasionally, unnecessary intervention is avoided when the intended target of a catheter-based intervention resolves with nitroglycerin (coronary spasm)! This is more frequent with lesions of the ostium of the RCA. In this setting, at the time of diagnostic angiography catheter-induced spasm may occur. If the patient returns at a later time for intervention, this ostial "stenosis" may prove to have been unrecognized catheter spasm.

The best working views that show the target lesions and the adjacent side branches most clearly and with the least foreshortening are recorded and transferred to the roadmap monitor for reference during the procedure. The approximate reference diameter and length of each target lesion is estimated by comparing it to the diagnostic catheter (generally 5F or 1.65 mm) or selected guiding catheter. Decisions are then made regarding the sequence of lesions to be approached (integrating lesion severity, myocardial territory involved, and noninvasive test data) and the specific interventional approach that will be used. For example, a bifurcation lesion that may require kissing balloon inflations and/or a two-stent approach (see Chapter 31) may warrant use of a guiding catheter that is larger than 6F.

The appropriate guiding catheter is connected to the pressure manifold (see Chapter 15) by way of an extension tube and a rotating hemostatic valve (e.g., Tuohy–Borst valve), and positioned in the appropriate coronary ostium. The hemostatic valve contains an adjustable O-ring that allows introduction and free movement of the PCI devices while maintaining a sufficient seal around the shaft to permit pressure measurement and contrast injection while minimizing blood loss. The angioplasty guidewire is first introduced into the guiding catheter, either through a needlelike guidewire introducer (*bare-wire* technique for Rx systems) or, less frequently, loaded into an OTW balloon or support catheter,

and then steered across the target lesion. The guidewire is advanced across the lesion with the aid of puffs of contrast material through the guiding catheter as the vessel is imaged fluoroscopically in a projection that shows the desired path free of foreshortening or overlapping side branches. Once the position of the wire tip in the distal vasculature has been confirmed by contrast angiography, the desired angioplasty balloon or other device is selected.

Optimal stand-alone angioplasty results are obtained using a balloon with a diameter that closely approximates the diameter of a presumably nondiseased reference segment adjacent to the site being treated (balloon/artery ratio 0.9:1.1).^{33,34} Slightly larger balloons (approximately 1.1 to 1.2 times the size of the reference lumen) may be used if intravascular ultrasound (see Chapter 25) is used and shows that the outer vessel (external elastic membrane [EEM]) diameter in the reference segment is significantly larger than the reference lumen (diffuse disease without a true normal reference segment). On the other hand, slightly smaller initial balloons are used when it is difficult to estimate the correct reference size of a diffusely diseased or rapidly tapering vessel, when difficulty is anticipated in crossing the lesion, or if the risk of complications must be minimized in a patient who cannot receive a stent. In the era when stenting (especially drug-eluting stenting) has become the definitive treatment, however, it is routine to predilate the target lesion with a balloon that is slightly undersized relative to the reference vessel and roughly the same length as the target lesion (see Chapter 31). Modern low-profile stents can often be delivered without predilation of the target lesion (the so-called *direct stenting*), but predilation makes delivery and accurate placement of the stent within the lesion easier, facilitates the selection of the correct stent diameter and length (by comparison with the diameter and length of the inflated predilating balloon), and ensures that lesion compliance is sufficient to allow full expansion of the stent without pretreatment by rotational atherectomy (see Chapter 29). Predilation is particularly important if a short stent is used, to avoid "missing" the lesion during stenting if "watermelon seeding" is felt likely.

Once the dilatation catheter has been positioned within the target stenosis, the balloon is inflated progressively using a screw-powered hand-held inflation device equipped with a pressure dial. At low pressures (i.e., 2 to 4 atm), the balloon typically exhibits an hourglass appearance owing to central constriction by the coronary stenosis being treated. In soft lesions, this constriction (or "waist") may expand gradually as the inflation pressure is increased, allowing the balloon to assume its full cylindrical shape. In more rigid lesions, the constriction may remain prominent until the balloon expands abruptly at a *stenosis resolution pressure* that may be as high as 20 atm.³⁵ Some operators prefer to increase pressure rapidly until all balloon deformities resolve, but this increases the risk of dissection when a fibrotic or calcified plaque yields suddenly or when the ends of a somewhat compliant balloon grow to excessive diameter on either side of the resistant lesion. If a calcified plaque resists balloon expansion at 10 to

14 atm, one may thus prefer to consider use of a Rotablator (see Chapter 29) rather than inflating the balloon to the very high pressures (≥ 20 atm, Figure 28.4) that may be required for full dilation.

At the other extreme, elastic (usually eccentric) stenoses may allow full balloon expansion at low pressures but then tend to recoil promptly once the balloon is deflated. This type of lesion was once treated by repeated inflations, cautious use of oversized balloons, or directional atherectomy, but stent implantation is now the routine treatment. Focused force dilation (with a cutting balloon or the Angiosculpt balloon) may also be helpful in dilating the fibrotic or elastic lesion effectively (see below). There is little objective evidence that slower speed of inflation or prolonged (1 minute or more) inflations offer more benefit than offered by the 30-second inflations.³⁶

Whatever inflation strategy is adopted, the response of each lesion to balloon dilation must then be assessed individually so that the dilation protocol can be tailored to achieve the best possible result. The most common way to assess lesion response to balloon dilation is repeat angiography. Complete normalization of the vessel lumen would be the ideal end result of coronary angioplasty, but a typical result of even a successful angioplasty is a 30% residual diameter stenosis (i.e., a 1.9 mm lumen in a 3 mm vessel) with some degree of intimal disruption (reflected as localized haziness, filling defect, or dissection). Although this once created a dilemma about whether to persist with additional balloon inflations (weighed against the risk of creating a vessel dissection), the need to obtain a perfect result with balloon angioplasty is now moot in the stent era—*any lesion that can be stented is generally stented*. In the current view, the best position for stand-alone balloon angioplasty is thus in lesions that are poorly suited to stenting owing to vessel size below 2 mm or branch ostial disease where bifurcation stenting is not contemplated.

Given the importance of achieving the best acute angiographic result, and the uncertainty inherent in angiographic assessment of the irregular lumen postangioplasty, a number of other techniques have been used to grade the quality of an angioplasty result. Initially, PTCA operators relied heavily on the trans-stenotic gradient as an index of dilatation adequacy, seeking a postdilatation pressure difference of <15 mmHg between the aortic pressure (measured through the guiding catheter) and the distal coronary artery pressure (measured through the tip of the dilatation catheter). In practice, such measurements were complicated by the presence of the dilatation catheter within the stenosis and the small size of the dilatation catheter lumen, which led to abandonment of the gradient measurement by 1988.³⁷ There has been some recent reawakened interest based on the availability of newer solid state *pressure-measuring* guidewires that can be used to assess the trans-stenotic gradient at baseline flow and during maximal hyperemia³⁸ (see Chapter 24). The goal is to achieve a fractional flow reserve (FFR)—defined as the ratio of distal mean coronary pressure to aortic mean pressure during adenosine-induced hyperemia—of >0.95 in a successful

PCI. Physiologic assessment can also be done using Doppler flow-measuring guidewires to assess the coronary flow reserve (CFR) as an index of baseline lesion significance and a confirmation of adequate dilation. However, this technique is no longer used in PCI owing to the superiority of FFR as index of stenosis severity, which unlike CFR, is generally not impacted by the presence of microvascular dysfunction. Alternatively, *intravascular ultrasound* (IVUS; see Chapter 25) or optical coherence tomography (OCT) can more accurately measure lumen diameter and cross-sectional area after dilation, and can detect vessel dissection or hematoma more accurately. Although IVUS has provided important mechanistic insights into balloon angioplasty, it is not used in more than 5% to 10% of routine clinical cases because of the added procedural time and expense. In most laboratories, the postdilation angiogram thus remains the gold standard to assess whether or not an adequate result has been obtained.

Once adequate dilatation is deemed to have been achieved, it is common to withdraw the balloon catheter completely from the guiding catheter, leaving the guidewire across the dilated segment to allow observation of the treated vessel for signs of angiographic deterioration. With more predictable interventions such as stenting, however, a single set of postprocedure angiograms in orthogonal views with the guidewire removed is usually sufficient to document a suitable result in the treated lesion and the absence of dissections, branch occlusions, or guidewire perforations in the adjacent portions of the vessel. At that point, other significant lesions may be dilated, if needed, or the procedure may be concluded and the patient transferred to the recovery area.

Radiation safety is an integral component of PCI, and processes to minimize exposure of the patient and staff must be stringently followed³⁹ (see Chapter 2). The informed consent process ought to include a discussion on the potential adverse effects of radiation, particularly for those likely to receive high doses from complex procedures. Following the procedure, the patient's radiation dose (e.g., cumulative skin dose, fluoroscopy time, number of cine images) should be recorded. It is recommended that, for the management of patients who receive a high procedural radiation dose, each laboratory define a threshold dose above which follow-up protocols are initiated.

POSTPROCEDURE MANAGEMENT

Postprocedure management after PCI has been progressively streamlined.¹⁵ It was once common to leave the arterial sheath in place overnight with continued heparin infusion, while perfusing the sheath lumen and monitoring for distal limb ischemia. This practice allowed prompt vascular reaccess should delayed abrupt closure occur.⁴⁰ With the advent of stenting and glycoprotein IIb/IIIa receptor antagonists, such delayed abrupt closures occur so infrequently that the practice shifted to removal of the sheaths later the same day

as soon as the heparin effect wore off (ACT <160 seconds), with no postprocedure heparin infusion.^{41,42} In fact, now with the wide adoption of femoral puncture site closure devices and radial access, it is common to remove the arterial sheath in the catheterization laboratory at the end of the interventional procedure, despite a fully anticoagulated state.

After sheath removal, the patient typically remains at bed rest for 6 hours and then ambulates before discharge. The time to ambulation is reduced significantly, however, if a femoral closure device has been used. If a glycoprotein IIb/IIIa receptor antagonist is used intraprocedurally, it is commonly infused for approximately 18 hours postprocedure, though there is a trend toward shorter infusions in order to reduce the risk of bleeding.⁴³ Aspirin (81 to 325 mg/day) is continued indefinitely, and patients who have received a stent are given clopidogrel 600 mg (or Prasugrel 60 mg, Ticagrelor 180 mg) as a loading dose (300 mg with 24 hours of fibrinolytics) during or prior to the procedure. If Ticagrelor is used, typically the dose of aspirin is reduced (see Chapter 5). The duration of dual antiplatelet therapy varies depending on type of stent, technical factors (left main or bifurcation stenting), clinical factors (stable versus acute coronary syndrome), and the potential risk of bleeding^{16,22,24} (Table 28.1; see also Chapter 5). Patients should be counseled on the importance of compliance with dual antiplatelet therapy and that therapy should not be discontinued without consultation with their cardiologist. Proton pump inhibitors should be used in patients with a history of prior gastrointestinal bleeding who require dual antiplatelet therapy, and it is reasonable to prescribe those for patients at increased risk for bleeding. If the risk from bleeding outweighs the potential benefit of the recommended duration of dual antiplatelet therapy, earlier discontinuation is reasonable.¹⁶

With a good angiographic result in the treated lesions, marked relief of ischemic symptoms should be expected unless other significant disease has been left untreated. In the patient with significant multivessel disease (see below), it may thus be particularly helpful to measure the FFR across any indeterminate lesion using a pressure wire at the time of the procedure or perform a maximal exercise test in a few weeks after discharge. Earlier (i.e., pre-discharge) exercise testing was once performed on a routine basis, but has now been abandoned owing to the potential of groin rebleeding, delay of discharge, or the small risk of precipitating thrombotic closure of the dilatation site. Patients may return to full activity within 72 hours, by which time the groin puncture site should have healed sufficiently to allow even brisk physical activity.

Patients should expect to have no or minimal anginal symptoms early after discharge—ongoing anginal symptoms after discharge suggest persistent untreated disease or a poor result at the treatment site. A good initial result, with recurrent symptoms within the first weeks or 1 to 2 months may suggest *subacute stent thrombosis*, which usually presents as an acute STEMI requiring emergency recatheterization. On the other hand, initial symptomatic relief followed by recurrence

Table 28.1 Recommended Duration of Dual Antiplatelet Therapy Following Stent Implantation

- Bare-metal stent:
 - For stable coronary artery disease patients, a minimum of 1 mo and ideally up to 12 mo of clopidogrel 75 mg (unless the patient is at increased risk of bleeding, in which case it should be given for a minimum of 2 wk)^c.
 - For acute coronary syndrome, at least 12 mo after PCI. Options include clopidogrel 75 mg daily, prasugrel 10 mg daily^a, and ticagrelor 90 mg twice daily^b. If the risk of significant bleeding outweighs the anticipated benefit, earlier discontinuation should be considered^d.
- Drug-eluting stents:
 - For stable coronary artery disease patients, clopidogrel 75 mg daily for 12 mo, if patient not at high risk of bleeding.
 - For acute coronary syndrome, at least 12 months after PCI. Options include clopidogrel 75 mg daily, prasugrel 10 mg daily^a, and ticagrelor 90 mg twice daily^b.

^aPrasugrel should not be administered to patients with a prior history of stroke or transient ischemic attack.

^bUse with aspirin 81 mg daily.

^cUse of proton pump inhibitors is indicated in patients with a prior history of gastrointestinal bleeding, and reasonable for those at increased risk (e.g., advanced age, concomitant use of warfarin, steroids, NSAIDs, *Helicobacter pylori* infection).

Continuation of dual antiplatelet therapy beyond 12 months may be considered in a few patients undergoing DES implantation and in patients with left main and bifurcation (2 stent) stenting.

of symptoms between 2 and 6 months suggests restenosis of the dilated segment. (Clinically significant restenosis has been reduced markedly from 30% with PTCA to 15% with bare-metal stenting and to <5% with drug-eluting stenting.) When symptoms recur 1 or more years after successful angioplasty, it generally suggests progression of disease at another site.⁴¹

Along with educating the patient and family regarding these possibilities and their proposed management (including additional catheter intervention or bypass surgery, as needed), the acute angioplasty admission should also be viewed as an opportunity to educate about changes in lifestyle (smoking cessation, exercise, weight loss) or drug therapy (for hypertension and/or hyperlipidemia) to reduce the risk for the progression of atherosclerotic disease.⁴² Current lipid guidelines call for achieving a LDL level of <70 mg/dL in patients with proven coronary artery disease, as would be the case for the post-PCI patient.⁴⁶ Medically supervised exercise programs (cardiac rehabilitation) should be recommended to patients after PCI, particularly for patients at moderate to high risk. Treadmill exercise testing is reasonable for patients entering a formal cardiac rehabilitation program after PCI, but routine periodic stress testing of asymptomatic patients after PCI without specific clinical indications should not be performed.

MECHANISM OF PERCUTANEOUS TRANSLUMINAL CORONARY ANGIOPLASTY

According to the original explanation proposed by Dotter and Judkins¹ and by Gruentzig et al.,³ the enlargement of the vessel lumen following angioplasty was ascribed to *compression of the atheromatous plaque*—akin to footprints in the snow. In fact, true plaque compression accounts for a minority of

the observed improvement.⁴⁷ Extrusion of liquid components from the plaque does permit some compression of soft plaques but contributes minimally to improvement in more fibrotic lesions, even when balloon inflation is prolonged to 1 minute. In the absence of significant reduction in plaque volume, most of the luminal improvement following PTCA seems to result from *plaque redistribution*—more like footprints in wet sand. Some of this takes place by longitudinal displacement of plaque upstream and downstream from the lesion, but maximum improvement in the lumen following balloon angioplasty or stenting results from controlled overstretching of the entire vessel segment by the PTCA balloon. This stretching leads to fracture of the intimal plaque and partial disruption of the media and adventitia, with consequent enlargement of both the lumen and the overall outer diameter of the vessel⁴⁷ (Figure 28.5).

Although use of a full-sized balloon (balloon/artery ratio of 1:1) should theoretically eliminate all narrowing at the treatment site, the overstretched vessel wall invariably exhibits elastic recoil^{48,49} following balloon deflation and some degree of local vasospasm.⁵⁰ These processes typically leave the stretched vessel with a residual stenosis. A typical balloon angioplasty result also shows evidence of localized trauma to more superficial plaque components as an almost universal haziness of the lumen.⁵¹ Higher degrees of disruption are reflected by intimal filling defects (Figure 28.6), contrast caps outside the vessel lumen, or spiral dissections that may interfere with antegrade blood flow (Figure 28.7). Such local disruption has been seen on IVUS, angioscopy, and histologic examination of postmortem angioplasty specimens, and its extent correlates with the risk of an occlusive complication.⁵² In contrast, stenting or directional atherectomy reduces or even eliminates this elastic recoil, dissection, and vascular tone, and thereby provides lower (0% to 10% rather than 30%) postprocedural residual stenosis, and a smooth

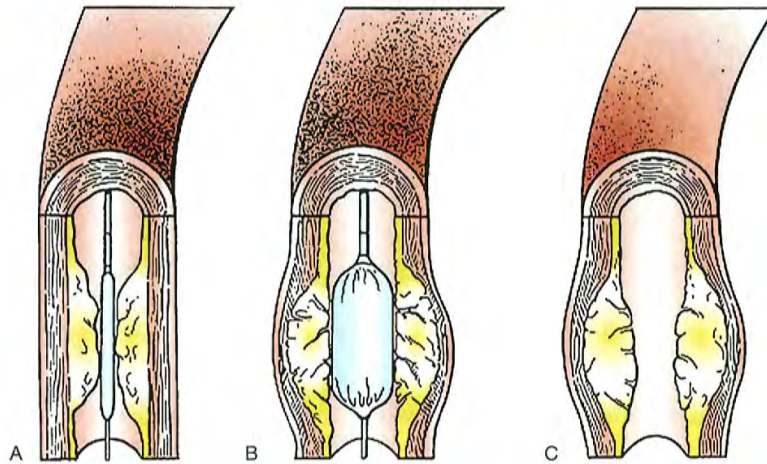


Figure 28.5 Proposed mechanism of angioplasty. **A.** Deflated balloon positioned across stenosis. **B.** Inflation of the balloon catheter within the stenotic segment causes cracking of the intimal plaque, stretching of the media and adventitia, and expansion of the outer diameter of the vessel. **C.** Following balloon deflation, there is partial elastic recoil of the vessel wall, leaving a residual stenosis and local plaque disruption that would be evident as haziness of the lumen contours on angiography.

and uniform lumen by angiography or IVUS, with less chance of acute or delayed closure.

Given the amount of vascular injury that takes place during balloon dilation, it is remarkable that dislodgment and clinically evident distal embolization of plaque fragments seem to be infrequent both in experimental studies³³ and in most clinical angioplasty procedures. There is increasing evidence, however, that subclinical distal atheroemboliza-

tion during balloon angioplasty and stent placement occurs frequently. This is most clearly established in patients undergoing dilatation of a saphenous vein bypass graft or patients with large thrombi adherent to the lesion. Distal embolization of large (>1 mm) plaque elements is usually manifest as an abrupt cutoff of flow in the embolized distal vessel.³⁴ In contrast, *micro*embolization of plaque debris or adherent thrombus may contribute to postprocedure chest pain, enzyme

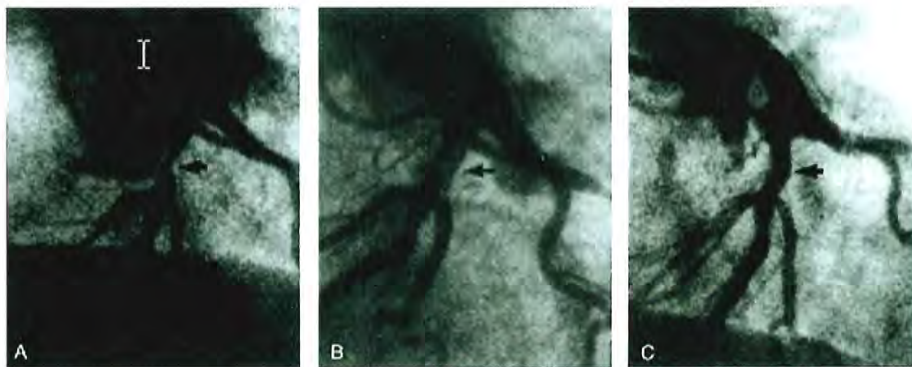


Figure 28.6 Normal healing of PTCA-related coronary dissection. As compared with the baseline angiogram (**A**), the immediate post-PTCA angiogram (**B**) shows enlargement of the left anterior descending (LAD) lumen with two small filling defects typical of an uncomplicated coronary dissection (*arrow*). Follow-up angiogram 3 months later (**C**) shows preservation of luminal caliber with complete healing of the localized dissection (*arrow*). (From Baim DS. Percutaneous transluminal coronary angioplasty. In Braunwald E, ed. *Harrison's Principles of Internal Medicine: Update VI*. New York: McGraw-Hill; 1985.)

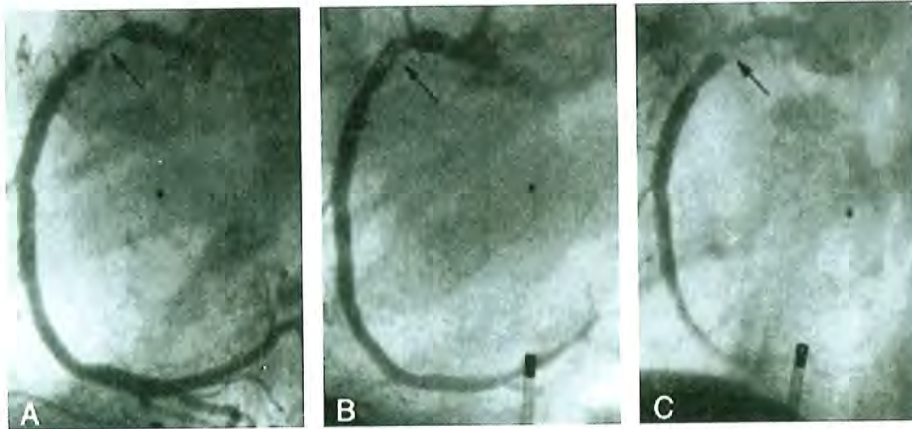


Figure 28.7 Coronary dissection leading to abrupt closure. The appearance of a right coronary stenosis prior to (A) and immediately following (B) coronary angioplasty, with an evident localized dissection. Within 15 minutes following removal of the dilatation catheter, the patient experienced chest pain associated with inferior ST-segment elevation and angiographic evidence of progressive dissection with impeded antegrade flow (C). Standard management in 1980 (when this case was done) consisted of emergency bypass surgery, which was accomplished without complication. Current practice is to attempt to recross the lesion and treat the dissection with angioplasty and stents. (From Baim DS. Percutaneous transluminal angioplasty—analysis of unsuccessful procedures as a guide toward improved results. *Cardiovasc Intervent Radiol* 1982;5:186.)

elevation, or the no-reflow phenomenon in which there is dramatic reduction in antegrade flow with manifestations of severe ischemia (chest pain and ST-segment elevation), in the absence of epicardial vessel stenosis, dissection, or macroembolic cutoff.⁵⁵ No-reflow can usually be improved by distal intracoronary injection of an arterial vasodilator (adenosine 12–60 µg; nitroprusside 100 µg; verapamil 100 µg; diltiazem 250 µg; nicardipine 200 µg—but not nitroglycerin, which is more of an epicardial than arteriolar vasodilator). But such treatment does not prevent periprocedural myocardial infarction. In contrast, the use of a distal embolic protection system in vein graft interventions (see Chapter 29) recovers atheroembolic debris and reduces the incidence of these complications by nearly half. The SAFER trial of vein graft stenting thus showed that such enzyme elevations occurred in 17% of lesions, with evidence of no-reflow in 8% of lesions, which were reduced to 9.7% and 3.3%, respectively, through the use of distal embolic protection.⁵⁶ Similar benefits have now been seen with distal embolic filter devices,⁵⁷ and in other vascular beds (carotid). However, they have not been shown to improve outcomes in native coronary arteries, but are selectively used by some interventionists in the presence of a large thrombus burden at the site of the culprit lesion.⁵⁸

Although it is a theoretical possibility with sufficient local stretching trauma, frank vessel rupture fortunately has turned out to be a rare consequence during conventional balloon angioplasty, barring the use of significantly oversized balloons.⁵⁹ Vessel perforation is actually more common (approximately 1% incidence) when atherectomy devices

are used⁶⁰ (see Chapter 29), when stents are postdilated at high pressure (>18 atm) with oversized (>1.1:1) balloons, or when stiff or hydrophilic wires are advanced into small distal branches. *Local vessel perforation or distal guidewire perforation in a patient treated with a glycoprotein IIb/IIIa antagonist usually constitutes a medical emergency* requiring prompt occlusion of the perforation site with a balloon, drainage of hemopericardium if cardiac tamponade is present, and definitive sealing of the perforation site with prolonged balloon inflation, a covered stent, an embolic coil, or emergency surgery^{60,61} (see Chapters 4 and 44).

ACUTE RESULTS OF ANGIOPLASTY

Early published data on coronary angioplasty success derive mostly from the 3,000-patient NHLBI Angioplasty Registry, which collected all procedures performed between 1977 and September of 1981.⁶² Although case selection in the registry focused on “ideal” PTCA candidates—those with proximal, discrete, concentric, subtotal, noncalcified stenoses of a single vessel—the primary success rate of 61% would be considered disappointing by current standards. The main explanations for the low primary success rate in the registry were failure to cross the lesion with the dilatation system (29% of cases) and failure to dilate the lesion adequately once having crossed (12% of cases). These failures were a result of two factors: the relative lack of experience of operators contributing cases to the

registry (the learning curve) and the use of original Gruentzig fixed-wire dilatation catheters with limited maneuverability, a comparatively high deflated balloon profile, and a low peak inflation pressure. Also sobering was the nearly 9% incidence of major complications, including a 6% incidence of emergency bypass surgery to treat abrupt vessel closure owing to local dissection, a 4.9% incidence of Q-wave myocardial infarction, and a 1.5% mortality rate.

Despite the inclusion of patients with more difficult coronary anatomy, progressive improvement in equipment (including the widespread availability of steerable guidewires since 1983) ensured that the second PTCA registry (1985–1986)^{63,64} had a success rate of 78%, with reduction in the incidence of major complications to 7%, including emergency bypass surgery 3.5%, Q-wave myocardial infarction 4.3%, and the mortality for patients with single-vessel disease (from 0.85% to 0.2%). Overall procedural mortality, however, remained close to 1% because of the inclusion of larger numbers of patients with multivessel disease in the 1985–1986 registry.

Following the introduction of stents and better anticoagulant and antiplatelet regimens, there has been a steady decline in major adverse event rates: Acute procedural success is approximately 95% and the rate of major adverse cardiac events has fallen to roughly 3% (death 1%, emergency surgery 0.3%, and Q-wave or large non-Q-wave MI 1.5%).⁶⁵ But it is important to remember that significant complications continue to occur, and the burden remains on the operator to select patients carefully, choose the best approach, execute it well, and respond quickly to evolving complications to minimize their ultimate scope and clinical impact.

COMPLICATIONS

As a specialized form of cardiac catheterization, coronary angioplasty is attended by the usual risks related to invasive cardiac procedures (see also Chapter 4). In contrast with diagnostic procedures, the larger-caliber guiding catheter used for angioplasty is more likely to result in damage to the proximal coronary artery and cause local bleeding complications at the catheter introduction site. Selective advancement of guidewires and dilatation catheters into diseased coronary arteries may lead to vessel injury if they are manipulated too aggressively.

Several systems have been devised to predict risk, which may be useful in preprocedural discussions with the patient and family or in monitoring how actual procedural outcomes over time compare with what is predicted (risk adjustment, looking at the observed versus expected complication rate ratio). The risk of procedural or in-hospital mortality is driven mostly by clinical factors such as age, cardiogenic shock, congestive heart failure, renal failure, and urgent or emergency PCI⁶⁶⁻⁶⁹ (Table 28.2). An example of a contemporary risk model for estimating the probability of cardiovascular

complications from PCI using clinical variables alone is shown in Figure 28.8. Procedure success and overall complications, however, tend to be driven by lesion-related features. The original AHA/ACC Type A, B, and C lesion categorization⁷⁰ (Table 28.3) was modified by Ellis⁷¹ to discriminate between B1 and B2 lesions (i.e., those with one or more than one B characteristic), but the continued validity of this classification scheme has come into question in the stent era. The Society for Cardiac Angiography and Intervention has thus proposed a simplification into four risk categories (based on whether or not the lesion has a type C feature and whether it is patent or occluded).⁷² This offers a somewhat better predictive value for both procedural success and major complications (death, myocardial infarction [CK elevation], emergency surgery, or emergency repeat angioplasty) and shows the potent effect of stenting in reducing those complications across the board (Figure 28.9).

The potential effect of stenting (and potentially of platelet glycoprotein IIb/IIIa antagonists) on reducing the need for emergency surgery is shown clearly in an analysis from the prospective Mayo Clinic registry report of 24,410 consecutive PCIs performed from 1979 through 2004.⁶ In the stent era, emergency surgery was required in approximately 0.5% of cases. The prevalence decreased from 1.6% of PCI in the early 1990s to 0.4% in 2003–2004 ($P < 0.001$), in parallel with increased stent use (Figure 28.10). Similarly, in-hospital major adverse cardiovascular events and death decreased from 5.1% to 4.0% and 2.6% to 1.8%, respectively, during the same time periods. In contrast, an increase in Q-wave myocardial infarction and stroke rates was noted: 0.9% to 1.8% and 0.2% to 0.6%, respectively. The reversal in the favorable trend, with an increase in these two endpoints, is a reflection of the fact that PCI is increasingly being performed in patients with greater acuity and more complex lesion anatomy, with the use of more potent adjunctive anticoagulant and antiplatelet therapies in contemporary practice. Nevertheless, the event rates in selected patients with stable coronary artery disease in current practice are exceedingly low with the rates for emergency CABG, in-hospital death, Q-wave myocardial infarction, stroke, and the composite of major adverse events being 0.3%, 0.1%, 0.1%, 0.2%, and 3.6%, respectively.⁷³

Periprocedural Myocardial Infarction

The universal definition of myocardial infarction defines PCI-related injury (type 4a) as an elevation of $>5 \times$ URL within 48-hours of the procedure together with either (i) evidence of prolonged (>20 minutes) ischemia as demonstrated by chest pain, or (ii) ischemic ST changes or new pathological Q waves, or (iii) angiographic evidence of a flow limiting complication, such as of loss of patency of a side branch, persistent slow-flow or no-reflow, embolization, or (iv) imaging evidence of new loss of viable myocardium or new regional wall motion abnormality and recommends that cardiac troponin be used as the preferred biomarker which, given the advent of high sensitivity assays, establishes the threshold for

Table 28.2 Multivariable Predictors of Mortality in Various Published Interventional Models

First Author	Hannan	Kimmel	Ellis	O'Connor	Moscucci	Shaw	Qureshi
Database source	New York	SCAI	5 US hospitals	NNE	8 Michigan hospitals	ACC-NCDR	Beaumont
Years of treatment	1991–1994	1992	1993–1994	1994–1996	1997–1999	1998–2000	1996–1998
Number of patients	62,670	10,622	12,985	15,331	10,729	100,253	9,954
Age	×	×	×	×	×	×	×
MI <24 h	×	×	×	×	×	×	× (14 d)
Shock	×	×	×	×	×	×	
LV function	×			×	×	×	
Female	×		×		×		
Lesion complexity		×	×	×		×	
Diabetes	×					×	
Renal failure	×			×	×	×	×
Left main disease						×	
Proximal LAD						×	
Urgent procedure				×		×	
Preprocedure IABP				×		×	
PVD	×			×	×		
Multivessel disease		×			×		×

For each model, the multivariable correlates of mortality found are indicated by the × symbol.

ACC-NCDR, American College of Cardiology–National Cardiovascular Device Registry; IABP, intraaortic balloon pump; LAD, left anterior descending; LV, left ventricular; MI, myocardial infarction; NNE, Northern New England; PVD, peripheral vascular disease; SCAI, Society for Cardiac Angiography and Intervention.

(From Cutlip DE, Ho KKL, Kuntz RE, Baim DS. Risk assessment for percutaneous coronary intervention—our version of the weather report? *J Am Coll Cardiol* 2003;42:1986–1989.)

PMI at very low levels of myonecrosis.⁷⁴ Based on this definition, 20% to 30% of patients have evidence of periprocedural myocardial infarction,⁷⁵ most of which occurs either due to side branch occlusion or due to distal microembolization. The definition is supported by studies correlating the magnitude of biomarker elevation to the extent of irreversible injury in the myocardium on magnetic resonance imaging and to worse in-hospital and long-term outcomes. However,

there is considerable evidence to suggest that in the majority of cases, the periprocedural infarction is a reflection of increased preprocedural risk (atherosclerosis burden and disease acuity) and hence the clinical significance of such periprocedural myocardial infarction and its management remain a matter of considerable controversy and uncertainty.⁷⁶ The definition of PCI-related myocardial infarction is likely to be modified in the future.

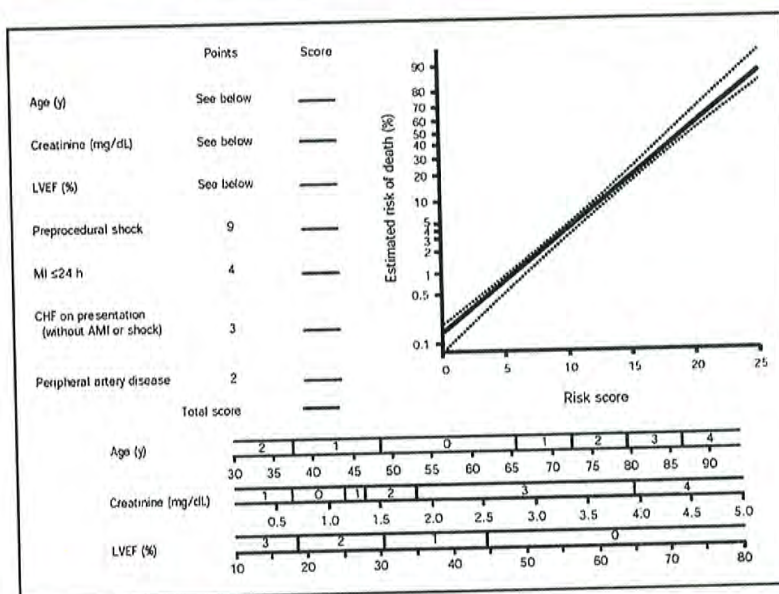


Figure 28.8 New Mayo Clinic risk model for prediction of in-hospital death. The coefficients for age, left ventricular ejection fraction (LVEF), and serum creatinine level can be determined from the nomograms at the bottom. Note that congestive heart failure (CHF) needs to be entered only for patients not presenting with myocardial infarction (MI) or shock. If LVEF is unavailable, enter 1 for the LVEF contribution if the patient presents with CHF; enter 0 otherwise. If serum creatinine level is unavailable, enter 1 for the creatinine contribution if the patient is a man presenting with CHF; enter 0 otherwise. (*Mayo Clin Proc* 2007;82(6):701–708, with permission.)

Until there is further clarity on the issue, our recommendation is that cardiac troponin levels be routinely measured prior to PCI. A normal preprocedural cardiac troponin value identifies those in whom PCI can be performed with very low risk and may be discharged early from hospital. Elevated preprocedure cardiac troponin identifies a higher risk cohort who may benefit from preprocedural initiation of therapies such as glycoprotein IIb/IIIa inhibitors and statins to improve outcomes. Post-PCI levels should be routinely measured in patients with complex procedures, suboptimal angiographic results, or procedural complications (e.g., large side-branch occlusion, flow-limiting dissection, no-reflow phenomenon, or coronary thrombosis), as well as in those who have symptoms, signs, or electrocardiographic evidence of myocardial ischemia, in order to quantify the extent of myocardial injury.⁷⁶ The current PCI guidelines do not recommend routine measurement of periprocedural biomarkers in patients with uncomplicated successful PCI. It is unlikely that clinically relevant additional information can be gained in these patients, independent of preprocedural risk. While there are no established cutoffs for cardiac troponin to define a “large” periprocedural myocardial infarction, CK-MB elevation of >5× the upper reference limit and/or new Q-waves identify patients with extensive injury. These patients should be monitored in the hospital for an additional period of time

because of an increased risk of arrhythmias, hemodynamic instability, heart failure, and death. For the purpose of preprocedural consent for PCI, it is the frequency of these large periprocedural myocardial infarctions (incidence <5%) that ought to be discussed; also, it must be reported to the patient, should they occur after the intervention.

Coronary Artery Dissection

Although plaque disruption and dissection may be caused by the guiding catheter or overly vigorous attempts to pass the guidewire through a tortuous stenotic lumen, most dissections are actually the by-product of the “controlled injury” induced intentionally by inflation of the dilatation catheter.⁴⁷ In fact, localized dissections can be found routinely in animal or cadaveric models of angioplasty and are evident angiographically in at least one half of patients immediately after balloon angioplasty.⁵¹ When these dissections are small and nonprogressive and do not interfere with antegrade flow in the distal vessel, they have no clinical consequence. Follow-up angiography as soon as 6 weeks after the angioplasty procedure usually demonstrates complete healing of the dissected segment (see Figure 28.6), although occasional localized formation of aneurysms has been described at the site of dissection.^{77,78} Clinically

Table 28.3 Lesion Morphologic Predictors of Procedure Success and Complication Based on the AHA/ACC Lesion Classification System

Characteristics of type A, B1, B2, and C lesions

Type A lesions (high success, >85%; low risk)
Discrete (<10 mm length)
Concentric
Readily accessible
Nonangulated segment <45°
Smooth contour
Little or no calcification
Less than totally occlusive
Not ostial in location
No major branch involvement
Absence of thrombus
Type B1 lesions (moderate success, 60–85%; moderate risk)
Tubular (10–20 mm length)
Eccentric
Moderate tortuosity of proximal segment
Moderately angulated segment, 45°–90°
Irregular contour
Moderate to heavy calcification
Ostial in location
Bifurcation lesions requiring double guidewires
Some thrombus present
Total occlusion <3 months old
Type B2 lesions (Ellis modification of AHA/AOC system)
Two or more type B characteristics
Type C lesions (low success, <60%; high risk)
Diffuse (>2 cm length)
Excessive tortuosity of proximal segment
Extremely angulated segment >90°
Inability to protect major side branches
Degenerated vein grafts with friable lesions
Total occlusion >3 months old

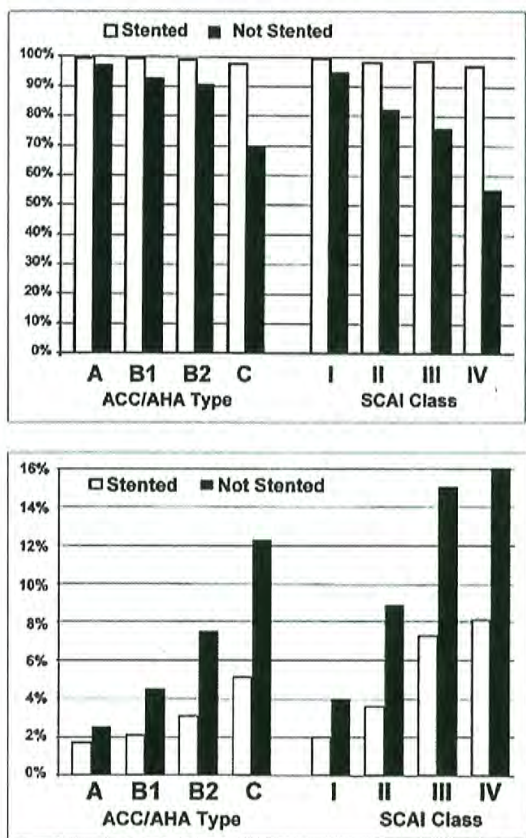


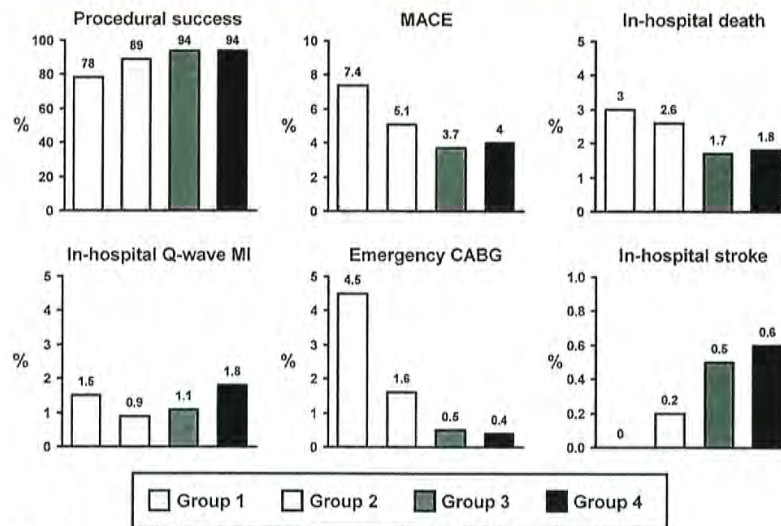
Figure 28.9 Lesion risk scores. **Top.** The probability of success by AHA type lesion (*left*) and the new SCAI class (*right*), treated with (*open bars*) and without (*closed bars*) coronary stenting. **Bottom.** The probability of a major complication based on AHA lesion type (*left*) and the new SCAI class (*right*), treated with (*open bars*) and without (*closed bars*) coronary stenting. The SCAI score, based simply on whether the vessel has one or more type C characteristics and is open or occluded, has a stronger predictive value for success and complications than that of the traditional AHA/ACC score. The beneficial effect of stenting on complications is evident (see also Table 28.3; From Krone RJ, Shaw RE, Klein LW, et al. Evaluation of the American College of Cardiology/American Heart Association and the Society for Coronary Angiography and Interventions lesion classification system in the current “stent era” of coronary interventions). (From the ACC-National Cardiovascular Data Registry. *Am J Cardiol* 2003;92:389–394, with permission.)

significant dissections in contemporary stent-based PCI are generally seen at either the proximal or the distal stent edge. These can be managed conservatively if minor, but may require treatment with an overlapping stent if abrupt closure is considered to be a significant possibility. Guide-induced dissections remain an infrequent but serious complication, generally occur in complex interventions, and invariably need to be treated with a stent.

Abrupt Closure

Prior to the widespread use of stents, large progressive dissections not uncommonly interfered with antegrade flow and led to total occlusion of the dilated segment (a phenomenon known as abrupt closure; see Figure 28.7). With balloon angioplasty alone (before the advent of new devices), abrupt closure occurred in roughly 5% of patients as the result of compression of the true lumen by the dissection flap,⁵² with superimposed thrombus formation, platelet adhesion, or vessel spasm. In one study,⁷⁹ postangioplasty dissections were evident angiographically in 40% of dilated lesions, with spiral (type D) dissections in 3.5% of patients. The presence of a type D dissection increased the risk of frank or “threatened” abrupt closure (residual stenosis >50%, with reduced antegrade flow) from a baseline of 6.1% to 28%. This finding supports the earlier findings of Ellis et al.⁸⁰ showing a fivefold increase in abrupt closure with postprocedure dissection and stressing the relative importance of the postprocedure result (as opposed to preprocedure clinical or angiographic variables) on the risk of abrupt closure. Most abrupt closures after stand-alone balloon angioplasty developed within minutes of the final balloon inflation, so that it became the routine practice to observe the lesion for 10 minutes after the last balloon inflation, before leaving the catheterization laboratory. But abrupt closure also occurred up to several hours later (in 0.5% to 1% of cases) as the heparin anticoagulation wore off (particularly prior to the use of IIb/IIIa receptor antagonist infusions in patients with marginal angiographic results of stand-alone balloon angioplasty).

Before 1985, most patients who experienced abrupt closure of a major epicardial coronary artery went directly to emergency surgery, in an effort to minimize the amount of consequent myocardial damage. The rate of emergency surgery within 90 minutes of the onset of vessel occlusion, up to 50% of patients sustained a Q-wave myocardial infarction.⁸¹ The development of perfusion catheters—infusion catheters or angioplasty balloons with multiple side holes along their distal shaft to allow 40 to 60 mL/minute of blood to enter proximal to the site of occlusion, flow through the central lumen, and re-exit into the lumen distal to the point of occlusion—allowed patients to go to the operating room in a nonischemic state (Figure 28.11), and was shown to reduce the incidence of transmural infarction during emergency surgery to approximately 10%.⁸² Once it was realized that many



Singh M et al. *Circulation* 2007;115:2835-2841

Figure 28.10

The Mayo Clinic experience from 1979 through 2004 shows the progressive trends in procedural success and in-hospital outcomes. Group 1, 1979–1989; group 2, 1990–1996; group 3, 1996 to February 2003; and group 4, March 2003 to 2004. Group 1 consisted of patients who principally underwent PTCA alone. Group 2 consisted of patients in whom stents were used mainly as a bailout strategy, with aggressive periprocedural anticoagulation. Group 3 included patients who regularly received bare-metal stents and frequent adjunctive glycoprotein IIb/IIIa inhibitors, accompanied by dual oral antiplatelet therapy. Group 4 consisted of patients whose PCI reflected contemporary practice and included treatment with DES. (From Singh et al. twenty-five-year trends in in-hospital and long-term outcome after percutaneous coronary intervention. *Circulation* 2007;115:2835–2841, with permission.)

abrupt closures can be reversed by simply readvancing the balloon dilatation catheter across the lesion to “tack up” the dissection via repeated balloon inflation, the emergency surgery rate fell in half to roughly 3%. Prolonged balloon inflations (up to 20 minutes, using an autoperfusion balloon to limit ongoing development of ischemia) further improved the ability to reverse abrupt closure.⁸³

Since 1993, however, the availability of coronary stents has made the certainty of reversing abrupt closure >90%.⁸⁴ This success has made it routine to stent any patient with a large postprocedure dissection as a preemptive treatment for threatened abrupt closure even when flow compromise is not apparent. Of course, with elective stenting of >90% of interventional procedures, this problem has been largely eliminated, with emergency surgery rates having fallen to <0.5%.⁶

Beyond the mechanical issues of residual stenosis and local dissection, it is now clear that platelet-rich clots contribute significantly to the abrupt closure process. The presence of thrombus, reflected as a globular filling defect, increases the risk of abrupt closure from 7.2% to 27.8%.⁷⁹ The role of thrombus in abrupt closure is further supported by an increased risk of abrupt closure in patients with a subtherapeutic ACT and the reduction of ischemic endpoints

seen in patients treated with glycoprotein IIb/IIIa inhibitors (see Chapter 5).²³ Although platelets may adhere to a damaged vessel wall through a variety of receptors, activation of the glycoprotein IIb/IIIa receptors represents the final common pathway that allows them to bind avidly to fibrin to cause platelet aggregation and thrombosis (see Chapter 5). Vessels with moderate local dissection but preserved antegrade flow are thus more likely to stay patent in the presence of potent antiplatelet therapy (e.g., glycoprotein IIb/IIIa antagonists or pretreatment with thienopyridines), thereby reducing the incidence of emergency surgery. These agents also significantly reduce the incidence of periprocedural myocardial infarction, and particularly the incidence of biomarker elevations (non-Q-wave myocardial infarctions) that are seen in 20% to 30% of patients undergoing coronary intervention.

Branch Vessel Occlusion

Occlusion of a side branch originating from within the stenotic segment occurs in 14% of vessels at risk during angioplasty of the main vessel. This is generally owing to shifting of plaque which is sometimes referred to as the *snowplow effect*.⁸⁵ If the branch vessel is small, this event usually has no significant

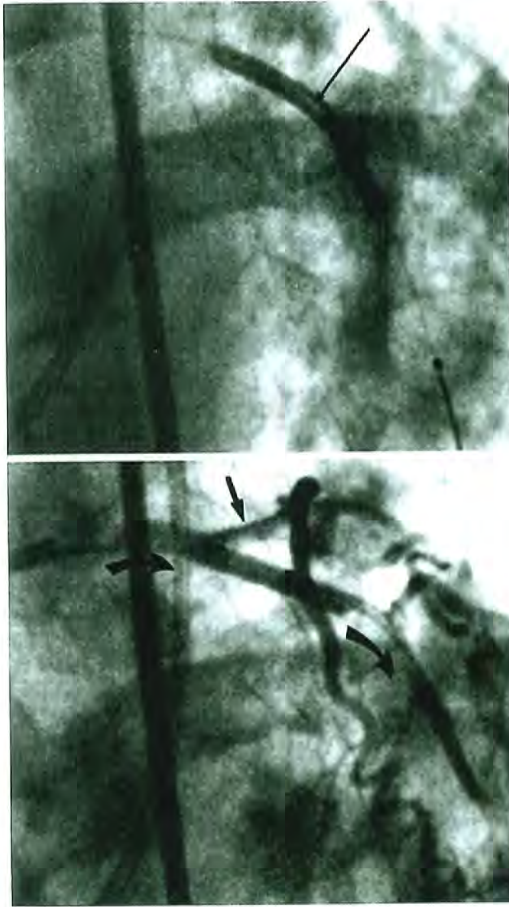


Figure 28.11 Use of a perfusion balloon catheter. **Top.** The inflated perfusion balloon (*arrow*) is shown in the left anterior descending artery and can be recognized by the presence of the non-contrast-filled (*white*) perfusion lumen running through the center of the balloon. **Bottom.** Injection through the guiding catheter (*left curved arrow*) shows direct opacification of the circumflex (*straight arrow*) as well as contrast flow into the distal left anterior descending. This flow enters through proximal side holes, passes through the perfusion lumen within the balloon, and flows out into the distal vessel (*right curved arrow*). The 40- to 60-mL/minute flow to the distal vessel through the perfusion lumen helps mitigate myocardial ischemia during prolonged balloon inflations. However, this device is no longer used in contemporary PCI practice since routine use of stents has made persistent abrupt closure a rare event.

clinical sequelae and should not discourage attempted angioplasty. On the other hand, if a large branch vessel originates from within the stenotic segment, simultaneous dilatation of the main vessel and the involved branch with two separate dilatation systems (the kissing-balloon technique) may be required for preservation of both vessels.⁸⁶ This originally utilized two guidewires that could be inserted through a single guiding catheter (one guidewire placed into the main vessel and the other one into the involved side branch) to allow alternating advancement of a balloon catheter into one and then the other vessel.⁸⁷ Current large-lumen guiding catheters and low-profile dilatation systems, however, now allow kissing balloon inflations through a single 7F or even 6F guiding catheter. The effective side-by-side balloon diameter in the proximal vessel can be estimated as the square root of the sum of the squares of the individual balloon diameters (two 3.0 balloons have an effective combined diameter of 4.25 mm [square root of $18 = 9 + 9$]). Multiple studies have evaluated different bifurcation strategies, and in general have concluded that provisional stenting is the best, with stent placement in the main branch and stenting of the side branch only if needed. The results of PCI for some true bifurcation lesions can be improved, however, by the use of various bifurcation stent strategies (see Chapter 31) or atherectomy of both the parent and branch vessel⁸⁸ (see Chapter 29).

Coronary Perforation

Guidewire-induced perforation occurs rarely; is typically seen in complex cases, especially during PCI for chronic total occlusions; and does not necessarily have dire consequences, unless a device is passed over the wire or the wire perforation takes place in a patient receiving a platelet IIb/IIIa receptor antagonist. Frank rupture of the coronary artery owing to the use of too large a dilatation balloon or the use of an atherectomy device can also cause vessel perforation that leads to rapid tamponade and hemodynamic collapse.^{60,61} Perforations may be classified based on angiographic appearance as type I—extra-luminal crater without extravasation; type II—pericardial and myocardial blush without contrast jet extravasation; and type III—extravasation through a frank (1 mm) perforation. In the absence of extravasation (type III), most perforations may be effectively managed without urgent surgical intervention. Even type III perforations can be managed nonoperatively with the combination of pericardiocentesis, reversal of anticoagulation, and either prolonged balloon inflation at the site of perforation or deployment of a covered stent. If these approaches are not successful, perforations usually require surgical repair.

Tamponade also may result from perforation of the right atrium or right ventricle during placement of temporary pacemaker electrode catheters, particularly in angioplasty patients who are receiving antiplatelet therapy in addition to full anticoagulation. This potential complication and the infrequency (<1%) of severe bradycardic complications support the recommendation against prophylactic pacing during

coronary angioplasty,¹⁶ although such pacing is required for certain atherectomy and thrombectomy procedures (see Chapter 29). Ventricular fibrillation occurs in approximately 1% of angioplasty procedures,⁶² usually as the result of prolonged ischemia during balloon advancement or inflation. In addition to causing electrical instability, ischemia during balloon inflation may cause marked electrocardiographic changes,⁸⁹ abnormalities in regional left ventricular systolic and diastolic function.^{90,91}

Bleeding

Periprocedural bleeding is increasingly recognized as a risk factor for mortality, and its risk should be assessed prior to the procedure using one of several published risk scores.⁹²⁻⁹⁷ The incidence of periprocedural bleeding ranges from 3% to 6% depending on the patient population and the definition used. Several definitions, derived from clinical trials, are summarized in Table 28.4. Recently, the Bleeding Academic Research Consortium (BARC) has published a consensus classification that is likely to be helpful for standardizing definitions in clinical trials, but its value in routine practice is unclear.⁹⁸

The adverse effects of bleeding may be either owing to the direct consequence of the bleed or secondary to the ischemic complications that may occur owing to the discontinuation of the essential antiplatelet or anticoagulant therapies. Bleeding may also be a marker of comorbidities associated with worse prognosis (e.g., frailty, gastrointestinal pathology, malignancy). Risk factors for bleeding include patient factors (e.g., advanced age, gender, low body mass index, preprocedural anemia, chronic kidney disease, acuity of presentation), potency of the anticoagulant and antiplatelet regimen used, vascular access

site, and sheath size. Strategies to reduce the risks of bleeding include (a) the use of anticoagulation regimens associated with the optimal risk–benefit profile, (b) weight-based dosing of heparin and other agents, (c) use of activated clotting times to guide unfractionated heparin dosing, (d) avoidance of excess anticoagulation, (e) dosing adjustments in patients with chronic kidney disease, (f) use of radial artery access, and (e) avoidance of inadvertent femoral vein cannulation.

Device Failures

Although guidewires and balloon catheters are extremely reliable, device failure can infrequently occur when any device is subjected to severe operating stresses (e.g., when a guidewire is rotated repeatedly in a single direction while its tip is held fixed in a total occlusion or when a balloon catheter is inflated past its operating pressure range in an attempt to dilate a resistant stenosis). In a small percentage of cases, this may lead to detachment of a part of the wire or dilatation catheter, with a fragment remaining in the coronary artery.⁹⁹ In the stent era, this also includes dislodgment of the stent from its delivery balloon or failure of the stent delivery balloon to inflate or deflate properly. To avoid the need for surgical removal, the angioplasty operator should be familiar with various techniques (baskets, biotomes, intertwined guidewires) for catheter retrieval.¹⁰⁰ Although hard to remember in the heat of the moment, any failed products should be saved, sealed in a bag, and returned to the manufacturer for structural analysis, which may disclose a root-cause manufacturing flaw. Device failures should also be reported to the Food and Drug Administration's (FDA's) Manufacturer and User Facility Device

Table 28.4 Definitions of Major Bleeding

TIMI (1988)	GUSTO (1997)	ACUITY (2006)	REPLACE-2 (2007)	HORIZONS AMI (2009)
Intracranial bleed	Intracranial bleed	Intracranial or intraocular	Intracranial, intraocular, or retroperitoneal	Intracranial or intraocular
↓Hgb >5 g/dL or ↓Hct >15%		↓Hgb ≥3 g/dL with overt bleeding Any ↓Hgb ≥4 g/dL	↓Hgb ≥3 g/dL with overt bleeding Any ↓Hgb ≥4 g/dL	↓Hgb ≥3 g/dL with overt bleeding Any ↓Hgb ≥4 g/dL
		Any transfusion	Transfusion ≥2 units of PRBCs	Any transfusion
	Hemodynamic compromise requiring intervention	Access site bleeding requiring intervention Hematoma ≥5 cm Reoperation for bleeding		Access site bleeding requiring intervention Hematoma ≥5 cm Reoperation for bleeding

TIMI and GUSTO trials were in patients receiving fibrinolytic therapy for acute myocardial infarction. ACUITY, REPLACE-2, and HORIZONS trial recruited patients undergoing percutaneous coronary intervention.

Experience (MAUDE) database (online at www.accessdata.fda.gov/scripts/medwatch) to facilitate the recognition and tracking of patterns that may otherwise appear as just a random device failure event to a single operator.

THE HEALING RESPONSE TO CORONARY ANGIOPLASTY—RESTENOSIS

Following successful balloon angioplasty, the body attempts to repair the damage caused by the procedure-related mechanical injury.¹⁰¹ Within minutes, a layer of platelets and fibrin is deposited. Within hour to days, inflammatory cells infiltrate the site, cytokines are released, and vascular smooth muscle cells migrate from the media toward the lumen. These smooth muscle cells and fibroblasts transform into a synthetic phenotype and remain in this state as they undergo hypertrophy, proliferate, and begin to secrete extensive extracellular matrix (Figure 28.12). The luminal surface is simultaneously colonized by endothelial cells that slowly regain their normal barrier function and secretory functions (e.g., tissue plasminogen activator (t-PA) and nitric oxide synthesis). Along with this proliferative neointimal response, there may also be further elastic recoil and fibrotic contraction of the vessel wall (i.e., negative vessel remodeling) during this period. The extent of proliferation and remodeling appears to vary according to the artery and type of intervention—for example, obstruction within stents is predominantly caused by neointimal hyperplasia, whereas significant amount of late narrowing following stand-alone angioplasty occurs owing to contraction of the vessel wall.¹⁰² Although vessel recoil is eliminated by coronary stenting, *incomplete stent expansion* at the time of implantation is an important mechanism for recurrent stenosis, especially in calcified and fibrotic lesions. *Stent fracture* owing to mechanical fatigue caused by repetitive cardiac contraction that causes compression, torsion, bending, and shear stress may also account for some cases of recurrent stenosis (at least 4%).¹⁰³ *Hypersensitivity* to one or more components (e.g., Nickel) of the implanted stent has been proposed as a potential mechanism¹⁰⁴ although the evidence for this is limited. There are also significant patient-to-patient variations in the late healing response after coronary intervention, reflected in variable amounts of late loss in lumen diameter between the completion of the intervention and the time when the repair process stabilizes (~6 to 12 months). Follow-up angiography shows continued maintenance of lumen diameter at the treated site beyond this period in the majority of patients.¹⁰⁵

If the healing response is excessive, however, most or all of the gain in lumen diameter produced by the initial intervention may be lost to the healing process. This causes the return of a severe stenosis and ischemic symptoms—a phenomenon known as *restenosis* of the dilated segment (Figure 28.13). Throughout the 1980s, restenosis was considered a dichotomous outcome (like death) that either did

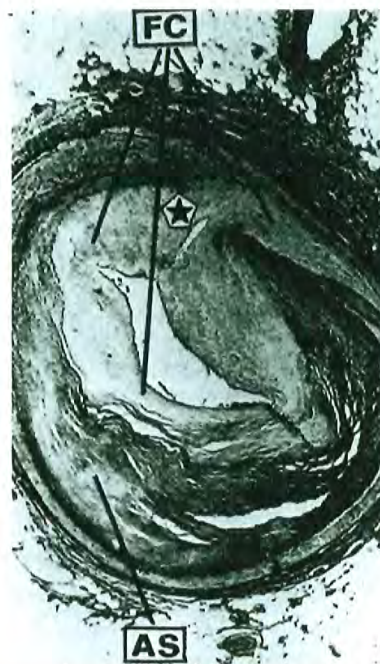

Figure 28.12 Mechanisms of restenosis: Cross section of a restenotic lesion in the left anterior descending artery 5 months after initial coronary angioplasty shows the original atherosclerotic plaque (AS), the crack in the medial layer induced by the original procedure (*star*), and the proliferation of fibrocellular tissues (FC) that constitutes the restenotic lesion. In stent restenosis, the mechanism is purely such proliferation, whereas in nonstent interventions such as balloon angioplasty there is frequently an additional component owing to shrinkage of the overall vessel diameter (unfavorable remodeling) at the treatment site. (From Serruys PW, et al. Assessment of percutaneous transluminal coronary angioplasty by quantitative coronary angiography: diameter versus videodensitometric area measurements. *Am J Cardiol* 1984;54:482.)

or did not develop. Although a great deal was learned about restenosis from the study of conventional angioplasty patients (e.g., its time course, histology, and various clinical factors that correlated with an increased incidence of restenosis),¹⁰⁶ data derived from stent and atherectomy procedures led to a new paradigm for evaluating restenosis.¹⁰⁷ In this paradigm, restenosis was considered as a continuous variable,

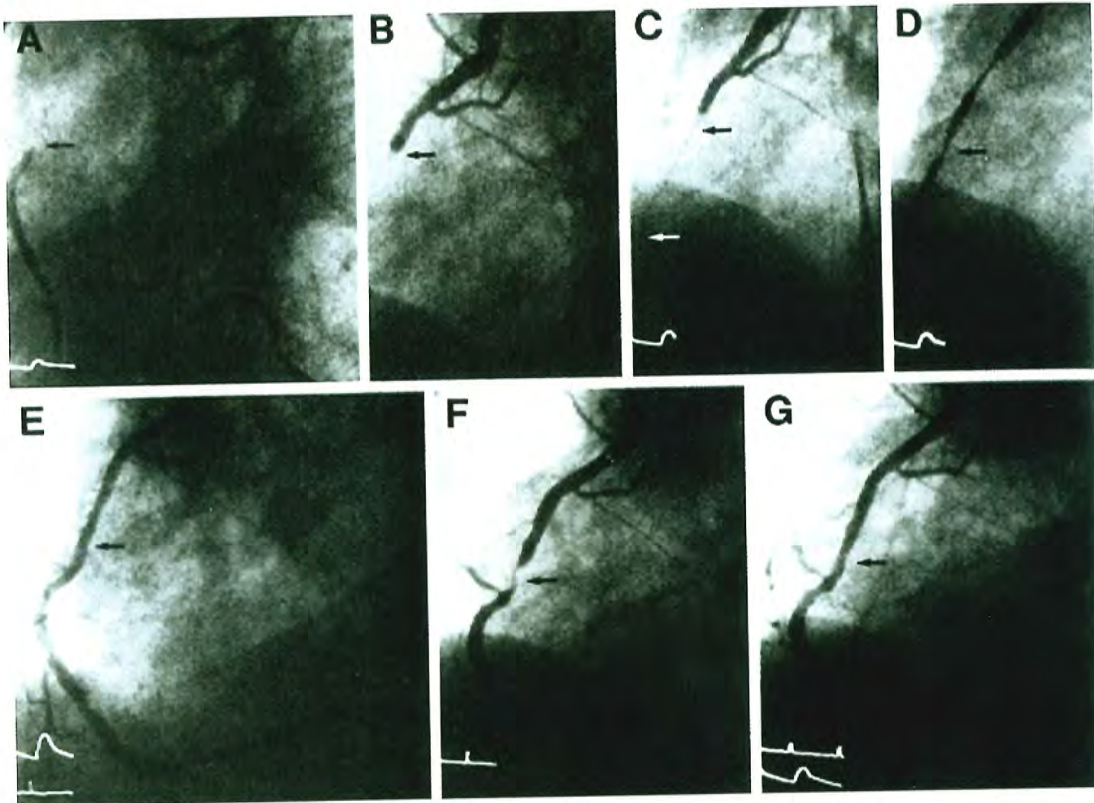


Figure 28.13 Clinical restenosis. **A–D.** A totally occluded right coronary artery with filling of the distal vessel by way of left to right collaterals. **E.** The essentially normal appearance of the right coronary artery following successful angioplasty. **F.** The appearance 6 weeks later when angina had recurred. **G.** The appearance following successful re-PTCA. Restenosis developed again 6 weeks following the second PTCA, but the patient was then asymptomatic for more than 6 years after a third PTCA procedure. (From Dervan JP, Baim DS, Cherniles J, Grossman W. Transluminal angioplasty of occluded coronary arteries: use of a movable guide wire system. *Circulation* 1983;68:776.)

and cumulative distribution curves were used to show the ranked population distribution of the late result (expressed as either late lumen diameter or late percent diameter stenosis) for the whole treated population (Figure 28.14). On the diameter stenosis curve, the percentage of the population that has a late diameter stenosis of >50% (binary restenosis) serves as a useful benchmark for comparing the angiographic restenosis rates between different populations or treatment groups. Target lesion revascularization owing to recurrent ischemia is an index of restenosis that is clinically significant, and its incidence is approximately 50% of angiographic restenosis.

Every treated lesion undergoes some degree of *late loss*, but fortunately late loss usually negates only part (roughly half) of the acute gain, so that a long-term net gain in lumen diameter results with alleviation of myocardial ischemia. In

fact, there tends to be a roughly linear relationship between the acute gain in lumen diameter caused by the intervention and late loss in lumen diameter (caused by the proliferative and fibrotic reaction of the artery during the healing phase), with a slope (the *loss index*) of roughly 0.5 for most interventions. This means that larger lumen diameters immediately after intervention translate into larger lumen diameters at 6-month angiographic restudy (the “bigger is better” dictum). Prior to drug-eluting stents (see below), all new mechanical devices that have been able to deliver a lower restenosis rate than that of balloon angioplasty have done so by providing a larger acute lumen diameter (more acute gain), rather than by reducing the loss index (Figure 28.15). Angiographic restenosis following balloon angioplasty alone is common (up to 50%), is less frequent with bare-metal stents (20% to 30%), and is least often seen with drug-eluting stents (5% to 10%).

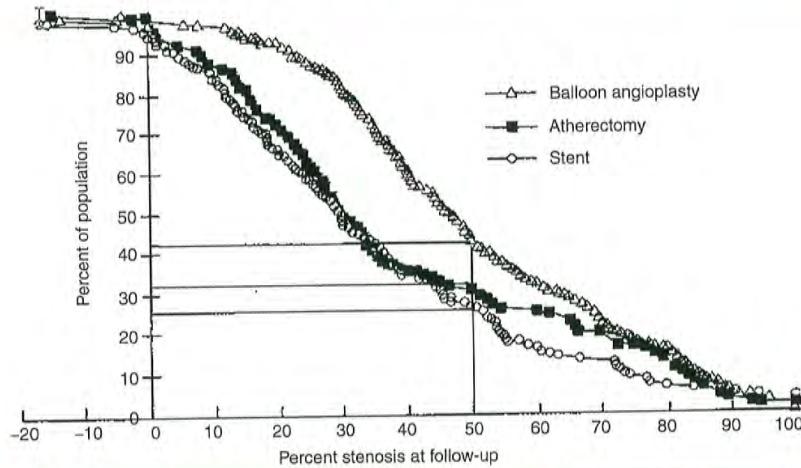


Figure 28.14

The view of restenosis as a continuous process that takes place to some degree in every treated segment favors displaying the late result (here, percent stenosis at follow-up) for the whole treated population. For patients treated by balloon angioplasty, directional atherectomy, or stenting, the Y axis shows the percent of patients who have a stenosis larger than the stenosis value on the X axis. The ability of stenting and atherectomy to lower restenosis is shown by a shift of their cumulative distribution function curves to the left. If a dichotomous definition of restenosis is applied, the intersection of each curve with a late diameter stenosis of 50% (vertical line) corresponds to a dichotomous restenosis rate of 43% for angioplasty, 31% for atherectomy, and 26% for stenting. (From Kuntz RE, et al. Novel approach to the analysis of restenosis. *J Am Coll Cardiol* 1992;19:1493.)

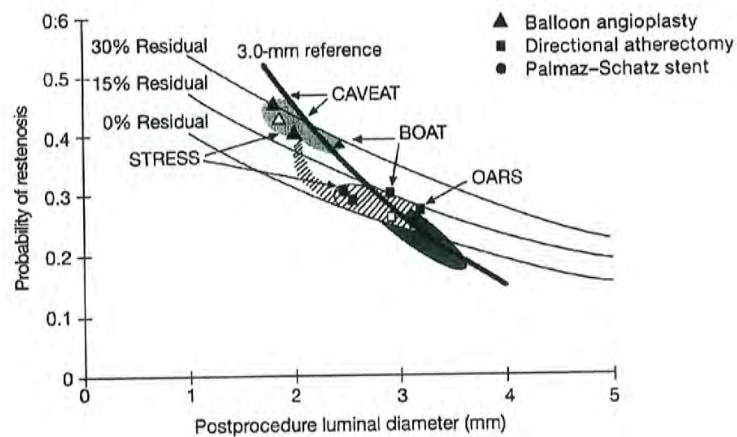


Figure 28.15

Except for antiproliferative therapies (e.g., drug-eluting stents and brachytherapy), the strongest determinants of the probability of restenosis (late diameter stenosis of >50%) are a large postprocedure lumen diameter and a low residual percent stenosis. Once these variables are taken into account, it no longer matters which device had been used—it is the result and not the device that matters. Balloon angioplasty (triangles) thus has a 2- to 2.3-mm lumen with a 40% restenosis rate, whereas stenting has a 2.9- to 3.2-mm lumen with a 20% restenosis rate (slightly worse results with stenting in the STRESS study are shown, as well). Directional atherectomy (squares) has an angioplastylike result in CAVEAT but a more stentlike result in BOAT and OARS (see Chapters 29 and 31). (Modified from Kuntz RE, et al. A generalized model of restenosis following conventional balloon angioplasty, stenting, and directional atherectomy. *J Am Coll Cardiol* 1993;21:15.)

The central importance of the acute postprocedure geometry to the late result, however, does not reduce the importance of factors that modulate the loss index. Clinical factors such as diabetes mellitus have a major effect on increasing loss index and restenosis for any given postprocedure result. The risk of restenosis may be estimated using models entirely dependent on clinical variables. One example is the Mid-America Heart Institute model, which uses the following characteristics: age >55 years, male gender, diabetes mellitus, acute myocardial infarction, severity of angina, previous PCI, and multivessel coronary artery disease. The range for the restenosis scores is 0 to 19. Scores in the ranges of 0 to 4, 5 to 8, and 9 to 19 have an estimated risk of restenosis of 15%, 23%, and 44%, respectively, with bare-metal stents in the year following the procedure.¹⁰⁸ Although such a model is helpful, it is limited by the fact that it does not include *lesion* (e.g., length, vessel diameter, type C lesion, calcification, restenotic lesion, chronic total occlusion, and severe tortuosity), and *procedural* (e.g., minimal lumen diameter post PCI, type of stent) characteristics that strongly influence the likelihood of restenosis. A model for restenosis with drug-eluting stents has also been derived and validated from the EVENT registry using the following variables: age <60 years, prior PCI, unprotected left main PCI, saphenous vein graft PCI, minimum stent diameter ≤ 2.5 mm, and total stent length ≥ 40 mm.¹⁰⁹ Scores of 0, 2, and 5 to 10 were associated with restenosis rates of 2.2%, 4.3%, and 7.5%, respectively.

There has been a relentless search for drugs or procedural variations that could decrease the late loss index. Although manipulating procedure-related variables (such as duration of conventional balloon inflation) has been unrewarding and trials of numerous systemic drug regimens (aspirin, nifedipine, ticlopidine, steroids, prolonged heparin administration, fish oil, mevinolin, ketanserin, etc.) have shown little or no beneficial effect against restenosis, two modalities (brachytherapy and drug-eluting stents) have shown important benefits against late loss and consequently, restenosis.

Brachytherapy

Coronary brachytherapy was used in clinical practice for a short period of time in the past, but is no longer performed given the superiority of drug-eluting stents in preventing and treating restenosis. The therapy was based on the fact that delivery of 2,000 centigray of either beta¹¹⁰ or gamma¹¹¹ radiation to the tissues of the coronary arterial wall greatly retards intimal proliferation and recurrent restenosis within bare-metal coronary stents. Thus, the combination of mechanical dilation plus coronary brachytherapy was shown to be an effective treatment for in-stent restenosis, though much of the benefit, in later studies, was found to be lost by 5-year follow-up. Trials of primary radiation at the time of stenting for *de novo* lesions were less impressive. As with drug-eluting stents, the inhibition of stent endothelialization by radiation treatment was associated with an increased risk of delayed stent thrombosis which had to be mitigated by long-term dual antiplatelet therapy.

Drug-Eluting Stents

Contrary to the inability of systemic therapy to inhibit restenosis after angioplasty or stenting, the local release of antiproliferative drugs (e.g., sirolimus, paclitaxel, zotarolimus, everolimus) from a polymer matrix over the first few months after stent implantation can substantially reduce inflammation and smooth muscle cell proliferation within a stent (see Chapter 31). In this context, an effective drug reduces in-stent late loss from the usual 1 mm (500 μ m on each side of the stent) to as little as 0.2 mm (100 μ m on each side of the stent).¹¹² This dramatically reduces the restenosis rate after initial stent implantation or after secondary implantation of a drug-eluting stent within an in-stent restenosis. To provide maximal benefit, the length of such drug-eluting stents should generally be somewhat (approximately 10 mm) longer than that of the lesion being treated to prevent injured but nontreated diseased areas at each end of a shorter stent. Since drug-eluting stents have delayed endothelialization as compared with bare-metal stents, the duration of dual antiplatelet therapy must be extended (minimum 12 months). Thus, it is important to carefully consider the appropriateness of using these stents in each case and review the need for, the duration of, and the ability of the patient to comply with dual antiplatelet therapy prior to the implantation. Drug-eluting stents are appropriate as an alternative to bare-metal stents in cases in which the risk of restenosis is higher (Table 28.5). In contrast, bare-metal stents or PTCA alone should be considered in patients who have a high bleeding risk, inability to comply with prolonged dual antiplatelet therapy, or have the potential need for a planned surgical procedure following the PCI which will require interruption of the dual antiplatelet therapy (Table 28.5).

CURRENT INDICATIONS

With the improvements in equipment and technique described above, PCI has become the dominant form of coronary revascularization (596,000 PCI versus 416,000 CABG procedures in the United States in 2009).⁵ However, the previous trend of steady rise in PCI volumes in the United States has reversed; the numbers of diagnostic cardiac catheterization and PCI being performed have gradually decreased since the mid 2000s onward^{5,113} (Figure 28.1). Potential reasons for the decline include (a) reduction in smoking and improved treatment of cardiovascular risk factors, (b) use of drug-eluting stents and the associated reduction in in-stent restenosis, and (c) potential impact of the COURAGE trial demonstrating similar outcomes for both medical therapy and PCI in a select population with stable coronary artery disease.¹¹⁴

Key issues that need to be addressed in patient selection for PCI include the following: (a) clinical justification for revascularization, (b) disease complexity which impacts the safety and efficacy of PCI, (c) potential advantages

Table 28.5 Clinical Situations Associated with DES or BMS Selection Preference

DES Generally Preferred Over BMS (Efficacy Considerations)	BMS Preferred Over DES (Safety Considerations)
<ul style="list-style-type: none"> ■ Left main disease ■ Small vessels ■ In-stent restenosis ■ Bifurcations ■ Diabetes ■ Long lesions ■ Multiple lesions ■ Saphenous vein grafts 	<ul style="list-style-type: none"> ■ Unable to tolerate or comply with DAPT ■ Anticipated surgery requiring discontinuation of DAPT within 12 mo ■ High risk of bleeding

BMS indicates bare-metal stent(s); DAPT, dual antiplatelet therapy; and DES drug-eluting stent(s).

(From Levine GN, Bates ER, Blankenship JC, et al. 2011 ACCF/AHA/SCAI Guideline for Percutaneous Coronary Intervention: a report of the American College of Cardiology Foundation/American Heart Association Task Force on Practice Guidelines and the Society for Cardiovascular Angiography and Interventions. *Circulation* 2012;125(8):e412.)

and disadvantages of PCI as compared to other therapeutic options such as medical therapy or bypass surgery, and (d) what combination of interventional devices would offer the best short- and long-term outcomes. This evaluation process thus involves integration of complex clinical, angiographic, pathophysiologic, and procedural knowledge, and constitutes an important component of operator training (see Chapter 1). The current guidelines recommend that this function be executed in stable patients with unprotected left main and complex disease (e.g., SYNTAX score >22) via a multidisciplinary approach by establishing a "Heart Team" that is composed of an interventional cardiologist, a cardiac surgeon, and (often) the patient's general cardiologist. Support for this strategy comes from studies showing that patients with complex CAD referred for revascularization in concurrent trial registries have lower mortality rates than those randomly assigned to PCI or CABG in the trials.¹¹⁵ Moreover the guidelines state that it is reasonable to use the STS and SYNTAX scores to assist making decisions regarding revascularization.¹¹⁶⁻¹¹⁹ The advantage of the SYNTAX score is that it is a unique tool that allows quantification of the angiographic complexity of coronary artery disease. However, it is complex to calculate and that introduces the potential for significant error. It may be calculated using an online calculator available at <http://www.syntaxscore.com>. The STS score is based on clinical characteristics and as such is easier to use and can also be derived from an online calculator at <http://209.220.160.181/STSTWebRiskCalc261/de.aspx>

With the rapid growth of PCI, there has been a series of guidelines and position papers published in Europe and the United States.¹⁶⁻¹⁸ The ACC/AHA first published Angioplasty Guidelines in 1988, updating them in 1993, 2001, 2005, and 2007. A comprehensive revision was published in 2011. These statements are useful compilations that outline some well-accepted indications and contraindications for PCI and are available online at <http://www.cardiosource.org/science>

and-quality.aspx. It is beyond the scope of this chapter to review these guidelines in detail, and the reader is referred to this excellent source of material and summaries.¹⁶ The discussion below includes some general commentary on specific situations.

Percutaneous Coronary Intervention to Improve Survival in Stable Disease

The 2011 guidelines do not give a class I recommendation for patients with left main stenosis. They recommend that PCI for this purpose is *reasonable* (class IIa), as an alternative to CABG, in selected *stable* patients with significant ($\geq 50\%$ diameter stenosis) unprotected left main disease with (1) anatomic conditions associated with a low risk of PCI procedural complications and a high likelihood of good long-term outcome (e.g., a low SYNTAX score [< 22], ostial or trunk left main stenosis); and (2) clinical characteristics that predict a significantly increased risk of adverse surgical outcomes (e.g., STS-predicted risk of operative mortality $> 5\%$; Table 28.6).¹⁶ In patients with unstable angina/non-ST-elevation myocardial infarction, PCI is *reasonable* when an unprotected left main coronary artery is the culprit lesion and the patient is not a candidate for CABG. Finally, in patients with acute STEMI, PCI is reasonable for an unprotected left main coronary artery that hosts the culprit lesion causing decreased blood flow (Thrombolysis In Myocardial Infarction [TIMI] grade < 3), and PCI can be performed more rapidly and safely than CABG.¹⁶

The only recommendation for PCI to improve survival in patients without left main disease is for those who survive sudden cardiac death with presumed ischemia-mediated ventricular tachycardia caused by significant ($> 70\%$ diameter) stenosis in a major coronary artery Table 28.6.¹⁶ This is a class I recommendation for which either PCI or CABG may be performed, as considered appropriate.

Table 28.6

ACCF/AHA/SCAI Guidelines on Revascularization to Improve Survival as Compared to Medical Therapy

Anatomic Setting	COR	LOE
UPLM or complex CAD		
CABG and PCI	I—Heart Team approach recommended	C
CABG and PCI	IIa—Calculation of STS and SYNTAX scores	B
UPLM*		
CABG	I	B
PCI	IIa—For SIHD when <i>both</i> of the following are present <ul style="list-style-type: none"> ■ Anatomic conditions associated with a low risk of PCI procedural complications and a high likelihood of good long-term outcome (e.g., a low SYNTAX score of ≤ 22, ostial or trunk left main CAD) ■ Clinical characteristics that predict a significantly increased risk of adverse surgical outcomes (e.g., STS-predicted risk of operative mortality $\geq 5\%$) 	B
	IIa—For UA/NSTEMI if not a CABG candidate	B
	IIa—For STEMI when distal coronary flow is TIMI flow grade < 3 and PCI can be performed more rapidly and safely than CABG	C
	IIb—For SIHD when <i>both</i> of the following are present <ul style="list-style-type: none"> ■ Anatomic conditions associated with a low to intermediate risk of PCI procedural complications and an intermediate to high likelihood of good long-term outcome (e.g., low-intermediate SYNTAX score of < 33, bifurcation left main CAD) ■ Clinical characteristics that predict an increased risk of adverse surgical outcomes (e.g., moderate-severe COPD, disability from prior stroke, or prior cardiac surgery; STS-predicted risk of operative mortality $> 2\%$) 	B
	III: Harm—For SIHD in patients (versus performing CABG) with unfavorable anatomy for PCI and who are good candidates for CABG	B
3-vessel disease with or without proximal LAD artery disease*		
CABG	I	B
	IIa—It is reasonable to choose CABG over PCI in patients with complex 3-vessel CAD (e.g., SYNTAX score > 22) who are good candidates for CABG	B
PCI	IIb—Of uncertain benefit	B
2-vessel disease with proximal LAD artery disease*		
CABG	I	B
PCI	IIb—Of uncertain benefit	B
2-vessel disease without proximal LAD artery disease*		

Table 28.6 Continued

Anatomic Setting	COR	LOE
CABG	Ila—With extensive ischemia	B
	Ilb—Of uncertain benefit without extensive ischemia	C
PCI	Ilb—Of uncertain benefit	B
1-vessel proximal LAD artery disease		
CABG	Ila—With LIMA for long-term benefit	B
PCI	Ilb—Of uncertain benefit	B
1-vessel disease without proximal LAD artery involvement		
CABG	III: Harm	B
PCI	III: Harm	B
LV dysfunction		
CABG	Ila—EF 35–50%	B
CABG	Ilb—EF <35% without significant left main CAD	B
PCI	Insufficient data	
Survivors of sudden cardiac death with presumed ischemia-mediated VT		
CABG	I	B
PCI	I	C
No anatomic or physiologic criteria for revascularization		
CABG	III: Harm	B
PCI	III: Harm	B

*In patients with multivessel disease who also have diabetes, it is reasonable to choose CABG (with LIMA) over PCI^{92,94–95} (Class Ila; LOE: B). CABG indicates coronary artery bypass graft; CAD, coronary artery disease; COPD, chronic obstructive pulmonary disease; COR, class of recommendation; EF, ejection fraction; LAD, left anterior descending; LIMA, left internal mammary artery; LOE, level of evidence; LV, left ventricular; N/A, not applicable; PCI, percutaneous coronary intervention; SIHD, stable ischemic heart disease; STEMI, ST-elevation myocardial infarction; STS, Society of Thoracic Surgeons; SYNTAX, Synergy between Percutaneous Coronary Intervention with TAXUS and Cardiac Surgery; TIMI, Thrombolysis in Myocardial Infarction; UA/NSTEMI, unstable angina/non-ST-elevation myocardial infarction; UPLM, unprotected left main disease; and VT, ventricular tachycardia. (With permission from Levine GN, Bates ER, Blankenship JC, et al. 2011 ACCF/AHA/SCAI Guideline for Percutaneous Coronary Intervention: a report of the American College of Cardiology Foundation/American Heart Association Task Force on Practice Guidelines and the Society for Cardiovascular Angiography and Interventions. *Circulation* 2012;125(8):e412.)

Percutaneous Coronary Intervention to Improve Symptoms

PCI is more often performed to relieve symptoms than improve survival. For this purpose, the 2011 guidelines state that PCI (or CABG) is *beneficial* in patients with one or more significant (>70% diameter) coronary artery stenoses amenable to revascularization and unacceptable angina

despite guideline-directed medical therapy Table 28.7.¹⁶ A lower level of indication (class Ila) is given by the guidelines for PCI (or CABG) to improve symptoms in patients with one or more significant (>70% diameter) coronary artery stenoses and unacceptable angina for whom guideline-directed medical therapy cannot be implemented because of medication contraindications, adverse effects, or patient preferences. Similarly, PCI is *reasonable* in patients with previous CABG,

Table 28.7

ACCF/AHA/SCAI Guidelines on Use of Revascularization to Improve Symptoms as Compared to Medical Therapy

Clinical Setting	COR	LOE
≥1 significant stenoses amenable to revascularization and unacceptable angina despite GDMT	I—CABG	A
	I—PCI	
≥1 significant stenoses and unacceptable angina in whom GDMT cannot be implemented because of medication contraindications, adverse effects, or patient preferences	Ila—CABG	C
	Ila—PCI	
Previous CABG with ≥1 significant stenoses associated with ischemia and unacceptable angina despite GDMT	Ila—PCI	C
	Ilb—CABG	C
Complex 3-vessel CAD (e.g., SYNTAX score >22) with or without involvement of the proximal LAD artery and a good candidate for CABG	Ila—CABG preferred over PCI	B
Viable ischemic myocardium that is perfused by coronary arteries that are not amenable to grafting	Ilb—TMR as an adjunct to CABG	B
No anatomic or physiologic criteria for revascularization	III: Harm—CABG	C
	III: Harm—PCI	

CABG indicates coronary artery bypass graft; CAD, coronary artery disease; COR, class of recommendation; FFR, fractional flow reserve; GDMT, guideline-directed medical therapy; LOE, level of evidence; N/A, not applicable; PCI, percutaneous coronary intervention; SYNTAX, Synergy between Percutaneous Coronary Intervention with TAXUS and Cardiac Surgery; and TMR, transmyocardial laser revascularization.

(With permission from Levine GN, Bates ER, Blankenship JC, et al. 2011 ACCF/AHA/SCAI Guideline for Percutaneous Coronary Intervention: a report of the American College of Cardiology Foundation/American Heart Association Task Force on Practice Guidelines and the Society for Cardiovascular Angiography and Interventions. *Circulation* 2012;125(8):e412.)

one or more significant (>70% diameter) coronary artery stenoses associated with ischemia, and unacceptable angina despite guideline-directed medical therapy.

Percutaneous Coronary Intervention in Acute Coronary Syndromes

A detailed discussion on the application of PCI in patients with non-ST-elevation acute coronary syndrome or STEMI is provided in Chapter 30. The purpose of angiography and revascularization, if needed, in non-ST-elevation acute coronary syndrome is to relieve ischemia and symptoms as well as reducing the risk of death and (recurrent) myocardial infarction. Selection of patients for an early invasive strategy (i.e.,

diagnostic angiography with intent to perform revascularization) is based on risk stratification. Patients in whom this approach is indicated are individuals without serious comorbidities or contraindications to the procedures, who either have an elevated risk for clinical events or have refractory angina/hemodynamic compromise/electrical instability.¹²⁰ The selection of PCI or CABG as the means of revascularization should generally be based on the same considerations as those for patients without ACS.¹²¹ The indications for angiography in STEMI are summarized in Table 28.8.

Hybrid Coronary Revascularization

Hybrid revascularization is defined as the combination of planned minimally invasive CABG with a left internal

Table 28.8 Indications for Coronary Angiography in STEMI

Indications	COR	LOE
Immediate coronary angiography		
Candidate for primary PCI	I	A
Severe heart failure or cardiogenic shock (if suitable revascularization candidate)	I	B
Moderate to large area of myocardium at risk and evidence of failed fibrinolysis	IIa	B
Coronary angiography 3–24 h after fibrinolysis		
Hemodynamically stable patients with evidence for successful fibrinolysis	IIa	A
Coronary angiography before hospital discharge		
Stable patients	IIb	C
Coronary angiography at any time		
Patients in whom the risks of revascularization are likely to outweigh the benefits or the patient or designee does not want invasive care	III: No Benefit	C

COR indicates class of recommendation; LOE, level of evidence; N/A, not applicable; PCI, percutaneous coronary intervention; and STEMI, ST-elevation myocardial infarction.

(With permission from Levine GN, Bates ER, Blankenship JC, et al. 2011 ACCF/AHA/SCAI Guideline for Percutaneous Coronary Intervention: a report of the American College of Cardiology Foundation/American Heart Association Task Force on Practice Guidelines and the Society for Cardiovascular Angiography and Interventions. *Circulation* 2012;125(8):e412.)

mammary (LIMA) graft to the left anterior descending (LAD) artery and PCI in one or more non-LAD coronary arteries. The available data on this topic are too limited to allow definitive recommendations, and no randomized trial has compared the hybrid strategy with PCI or CABG alone. Small observational studies have reported low mortality rates (0% to 2%) and acceptable event-free survival rates (83% to 92% at 6 to 12 months), and similar outcomes for conventional CABG at 30 days and 6 months.¹²²⁻¹²⁶ The goal of hybrid revascularization is to combine the advantages (durability and survival benefit) of the LIMA graft with the relative simplicity of PCI in patients who have multivessel disease involving the LAD. Hybrid revascularization is *reasonable* in patients in whom technical or anatomic limitations to performing one form of revascularization alone are present (e.g., lack of suitable graft conduits, heavily calcified ascending aorta, a non-LAD coronary artery unsuitable for bypass but amenable to PCI, nonfeasibility of PCI of the LAD). The procedures may be performed in a hybrid suite in one operative setting or as a staged procedure (typically during the same hospital stay)

when CABG is performed before PCI in order to document the patency of the LIMA graft during subsequent angiography and to avoid the risk of perioperative bleeding in patients requiring dual antiplatelet therapy. Angiography of grafts placed during minimally invasive surgery is generally recommended because of the lower graft patency rates as compared with traditional surgery through a midline sternotomy.

Complete Revascularization

CABG more often results in complete or near complete revascularization than does PCI. There are no data from any randomized trial comparing complete and incomplete revascularization. The extent to which initial incomplete revascularization influences outcomes is unclear. In a retrospective analysis from the BARI trial comparing CABG to PCI with bare-metal stents, there was no independent survival advantage from complete as compared to incomplete revascularization. The authors concluded that construction of more than one graft to any system other than the LAD conferred no long-term advantage.¹²⁷

In a contemporary single-center retrospective study of 1914 consecutive patients with multivessel coronary disease undergoing drug-eluting stent implantation (1,400 patients) or coronary artery bypass graft surgery (514 patients), the frequency of complete revascularization ranged from 40.9% to 56.6% for PCI and 66.9% to 78.2% for CABG depending on the definition of complete revascularization.¹²⁸ Anatomically complete revascularization did not improve the long-term clinical outcomes after either PCI or CABG. In patients with extensive coronary artery disease, however, multivessel incomplete revascularization was associated with unfavorable long-term clinical outcomes. In general, as one would expect, the need for subsequent CABG is usually higher in those with initial incomplete revascularization with PCI.

APPROPRIATENESS CRITERIA FOR USE OF PERCUTANEOUS CORONARY INTERVENTION IN CORONARY REVASCUARIZATION

As described in this chapter, PCI is associated with significant benefits which are accompanied by inherent risks and costs. Advances in technique and widespread availability allow PCI

to be performed in a wide spectrum of patients. However, medical therapy and CABG are often viable alternatives, and in some cases, superior options. Thus, assessing the appropriateness of PCI in clinical practice, as with any diagnostic or therapeutic modality, may provide a process to facilitate communication between patients and physician, identification of procedural overuse, quality improvement, education, and potential cost savings. Recently, appropriate-use criteria for coronary revascularization have been developed by consensus among six professional organizations¹²⁹ with subsequent minor revisions.¹³⁶ The criteria are based on the acuity of disease (stable versus acute coronary syndrome), assessment of ischemic burden by a stress test, severity of symptoms, adequacy of medical therapy, and angiographic complexity of the coronary atherosclerosis (Figures 28.16 and 28.17). They are intended to provide guidance rather than be a substitute for good clinical judgment and experience, and acknowledge the difficulty or uncertainty that often exists in clinical decision-making. While the role of these criteria in clinical practice remain to be established, a recent study from a large multicenter national registry reported that 98.6% of all PCI performed in the United States for acute indications (STEMI and high-risk non-ST-elevation acute coronary syndrome) was for appropriate indications. In contrast, among PCI performed for non-acute indications, 50.4% was

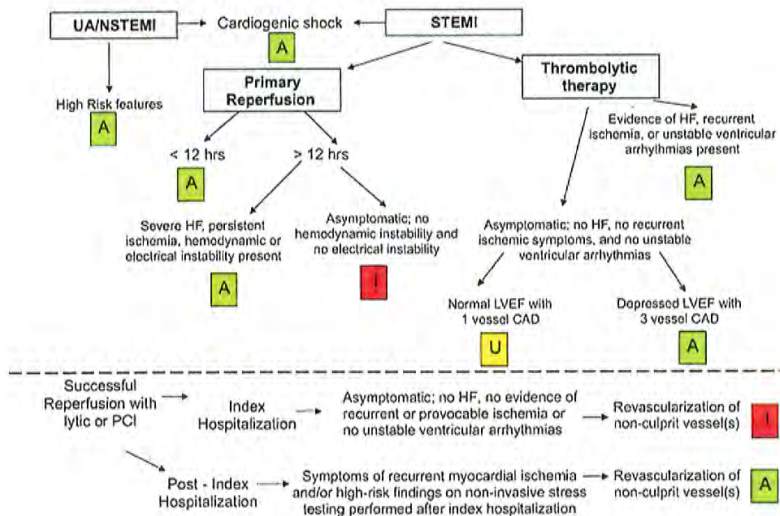


Figure 28.16 Appropriateness criteria for acute coronary syndromes. A indicates appropriate; CAD, coronary artery disease; HF, heart failure; I, inappropriate; LVEF, left ventricular ejection fraction; PCI, percutaneous coronary intervention; STEMI, ST-elevation myocardial infarction; U, uncertain; and UA/NSTEMI, unstable angina/non-ST-elevation myocardial infarction. (From Patel M et al. Appropriateness Criteria for Coronary Revascularization: a report by the American College of Cardiology Foundation Appropriateness Criteria Task Force, Society for Cardiovascular Angiography and Interventions, Society of Thoracic Surgeons, American Association for Thoracic Surgery, American Heart Association, and the American Society of Nuclear Cardiology Endorsed by the American Society of Echocardiography, the Heart Failure Society of America, and the Society of Cardiovascular Computed Tomography. *Circulation* 2009;119:1330-1352.)

Low-Risk Findings on Noninvasive Study						Asymptomatic					
Symptoms						Stress Test Med. Rx					
Med. Rx											
Class III or IV Max Rx	U	A	A	A	A	High Risk Max Rx	U	A	A	A	A
Class I or II Max Rx	U	U	A	A	A	High Risk No/min Rx	U	U	A	A	A
Asymptomatic Max Rx	I	I	U	U	U	Int. Risk Max Rx	U	U	U	U	A
Class III or IV No/min Rx	I	U	A	A	A	Int. Risk No/min Rx	I	I	U	U	A
Class I or II No/min Rx	I	I	U	U	U	Low Risk Max Rx	I	I	U	U	U
Asymptomatic No/min Rx	I	I	U	U	U	Low Risk No/min Rx	I	I	U	U	U
Coronary Anatomy	CTO of 1 vz.; no other disease	1-2 vz. disease; no Prox. LAD	1 vz. disease of Prox. LAD	2 vz. disease with Prox. LAD	3 vz. disease; no Left Main	Coronary Anatomy	CTO of 1 vz.; no other disease	1-2 vz. disease; no Prox. LAD	1 vz. disease of Prox. LAD	2 vz. disease with Prox. LAD	3 vz. disease; no Left Main
Intermediate-Risk Findings on Noninvasive Study						CCS Class I or II Angina					
Symptoms						Stress Test Med. Rx					
Med. Rx											
Class III or IV Max Rx	A	A	A	A	A	High Risk Max Rx	A	A	A	A	A
Class I or II Max Rx	U	A	A	A	A	High Risk No/min Rx	U	A	A	A	A
Asymptomatic Max Rx	U	U	U	U	A	Int. Risk Max Rx	U	A	A	A	A
Class III or IV No/min Rx	U	U	A	A	A	Int. Risk No/min Rx	U	U	U	A	A
Class I or II No/min Rx	U	U	U	A	A	Low Risk Max Rx	U	U	A	A	A
Asymptomatic No/min Rx	I	I	U	U	A	Low Risk No/min Rx	I	I	U	U	U
Coronary Anatomy	CTO of 1 vz.; no other disease	1-2 vz. disease; no Prox. LAD	1 vz. disease of Prox. LAD	2 vz. disease with Prox. LAD	3 vz. disease; no Left Main	Coronary Anatomy	CTO of 1 vz.; no other disease	1-2 vz. disease; no Prox. LAD	1 vz. disease of Prox. LAD	2 vz. disease with Prox. LAD	3 vz. disease; no Left Main
High-Risk Findings on Noninvasive Study						CCS Class III or IV Angina					
Symptoms						Stress Test Med. Rx					
Med. Rx											
Class III or IV Max Rx	A	A	A	A	A	High Risk Max Rx	A	A	A	A	A
Class I or II Max Rx	A	A	A	A	A	High Risk No/min Rx	A	A	A	A	A
Asymptomatic Max Rx	U	A	A	A	A	Int. Risk Max Rx	A	A	A	A	A
Class III or IV No/min Rx	A	A	A	A	A	Int. Risk No/min Rx	U	U	A	A	A
Class I or II No/min Rx	U	A	A	A	A	Low Risk Max Rx	U	A	A	A	A
Asymptomatic No/min Rx	U	U	A	A	A	Low Risk No/min Rx	I	U	A	A	A
Coronary Anatomy	CTO of 1 vz.; no other disease	1-2 vz. disease; no Prox. LAD	1 vz. disease of Prox. LAD	2 vz. disease with Prox. LAD	3 vz. disease; no Left Main	Coronary Anatomy	CTO of 1 vz.; no other disease	1-2 vz. disease; no Prox. LAD	1 vz. disease of Prox. LAD	2 vz. disease with Prox. LAD	3 vz. disease; no Left Main

Figure 28.17

Appropriateness criteria for patients with stable coronary artery disease without prior bypass surgery who have low-risk findings on noninvasive imaging (top left panel), are asymptomatic (top right panel), have intermediate-risk findings on noninvasive imaging study (middle left panel), CCS Class I or II angina (middle right panel), high-risk findings on noninvasive imaging (bottom left panel), and CCS Class III or IV angina (bottom right panel). A indicates appropriate; CTO, chronic total occlusion; I, inappropriate; Int., intervention; Med., medical; Prox. LAD, proximal left anterior descending artery; Rx, treatment; U, uncertain; and vz., vessel. (From Patel M, et al. Appropriateness Criteria for Coronary Revascularization: a report by the American College of Cardiology Foundation Appropriateness Criteria Task Force, Society for Cardiovascular Angiography and Interventions, Society of Thoracic Surgeons, American Association for Thoracic Surgery, American Heart Association, and the American Society of Nuclear Cardiology Endorsed by the American Society of Echocardiography, the Heart Failure Society of America, and the Society of Cardiovascular Computed Tomography. *Circulation* 2009;119:1330-1352.)

classified as appropriate, 38.0% as uncertain, and 11.6% as inappropriate. The majority of inappropriate PCIs for non-acute indications were performed in patients without angina, with low-risk ischemia on stress testing, or with suboptimal (≤ 1 medication) antianginal therapy.¹³⁰ The findings suggest that the great majority of procedures in contemporary practice are performed for appropriate indications and that there appears to be substantial variation among hospitals in the rate of “inappropriate” procedures for non-acute indications (median 10.8%; interquartile range 6.0% to 16.7%).

QUALITY AND REGULATORY CONSIDERATIONS

The 2011 PCI guidelines recommend that every PCI program operate a quality improvement program that routinely (a) reviews quality and outcomes of the entire program; (b) reviews results of individual operators; (c) includes risk adjustment; (d) provides peer review of difficult or complicated cases; and (e) performs random case reviews. In addition, every PCI program should participate in a regional or national PCI registry for the purpose of benchmarking outcomes against current national norms.¹⁶ PCI quality and performance considerations are defined by attributes related to *structure* (e.g., equipment, supplies, staffing, institutional and operator-level volumes, and the availability of electronic medical records, processes, and risk-adjusted outcomes) and *processes* (protocols for pre- and postprocedural care, appropriate procedural execution and management of complications, participation in databases and registries). *Risk-adjusted outcomes* are the consequence of these structural and procedural elements of care, and when available are more reliable measures of quality than are the institutional or individual operator volumes. These data can be used for internal quality-improvement efforts and public reporting.

Early in the development of coronary angioplasty, physicians active in diagnostic catheterization learned to perform angioplasty by attending live demonstration courses and watching or assisting on a small number of procedures (e.g., 10 to 20) under the guidance of a knowledgeable operator. Given the ever-increasing complexity of the procedure, however, virtually all new PCI operators since the mid-1980s have received formal training consisting of a third (and often fourth) year of interventional fellowship beyond completion of their training in diagnostic coronary angiography. These fellowships are now approved by the Accreditation Council for Graduate Medical Education (ACGME; see Chapter 1) and require the interventional trainee to perform a minimum of 250 procedures.¹³¹ It is reasonable for all physicians who perform PCI to participate in the American Board of Internal Medicine interventional cardiology board certification and maintenance of certification programs.

Broadly speaking there is a volume–outcome relationship at both the institutional and operator level.^{132,133}

However, this relationship is complex and inconsistent across low-volume institutions or operators. Operator experience may modify the volume–outcome relationship, and hence risk-adjusted outcomes is the preferred metric.^{134,135} The 2011 PCI guidelines recognize that there is controversy on this topic, and recommend the following operator and individual volumes for maintaining competency:¹⁶ Elective/urgent PCI should be performed by operators with an annual volume of >75 procedures at high-volume centers (>400 procedures) with on-site cardiac surgery with outcomes that meet national benchmarks. The guidelines allow some flexibility by stating that it is reasonable for operators with >75 PCI/year to perform elective/urgent PCI at low-volume centers (200 to 400 PCI procedures per year) with on-site cardiac surgery. Also, it is reasonable that low-volume operators (<75 PCI/per year) perform elective/urgent PCI at high-volume centers (>400 PCI procedures per year) with on-site cardiac surgery. Ideally, operators with an annual procedure volume of <75 should only work at institutions with an activity level of >600 procedures per year, and should develop a defined mentoring relationship with a highly experienced operator who has an annual procedural volume of at least 150 procedures per year. Finally, primary PCI for STEMI should be performed by experienced operators who perform >75 elective PCI procedures per year and, ideally, at least 11 PCI procedures for STEMI per year. Ideally, these procedures should be performed in institutions that perform >400 elective PCI per year and >36 primary PCI procedures for STEMI per year. These recommendations for operator volume may change in the future.¹³⁷

REFERENCES

- Dotter CT, Judkins MP. Transluminal treatment of arteriosclerotic obstruction: description of a new technique and a preliminary report of its application. *Circulation* 1964;30:654.
- Gruentzig A, Kumpe DA. Technique of percutaneous transluminal angioplasty with the Gruentzig balloon catheter. *AJ R Am J Roentgenol* 1979;132:547.
- Gruentzig AR, Senning A, Siegenthaler WE. Non-operative dilatation of coronary artery stenosis—percutaneous transluminal coronary angioplasty. *N Engl J Med* 1979;301:61.
- King SB. Angioplasty from bench to bedside. *Circulation* 1996;93:1621.
- American Heart Association. 2012 Heart and Stroke Statistical Update. Dallas, TX; American Heart Association. *Circulation* 2012;125:e12–e230.
- Singh M, Rihal CS, Gersh BJ, et al. Twenty-five-year trends in in-hospital and long-term outcome after percutaneous coronary intervention: a single-institution experience. *Circulation* 2007;115:2835–2841.
- Simpson JB, Baim DS, Robert EW, Harrison DC. A new catheter system for coronary angioplasty. *Am J Cardiol* 1982;49:1216.
- Dervan JR, McKay RG, Baim DS. The use of an exchange wire in coronary angioplasty. *Cathet Cardiovasc Diagn* 1985;11:207.
- Mauri L, Bonan R, Weiner BH, et al. Cutting balloon angioplasty for the prevention of restenosis: results of the Cutting Balloon Global Randomized Trial. *Am J Cardiol* 2002;90:1079–1083.
- Albiero R, Silber S, Di Mario C, et al.; RESCUT Investigators. Cutting balloon versus conventional balloon angioplasty for the treatment

- of in-stent restenosis: results of the restenosis cutting balloon evaluation trial (RESCUT). *J Am Coll Cardiol* 2004;43:943-949.
11. Carell ES, Schroth G, Ali A. Circumferential balloon rupture and catheter fracture due to entrapment in a calcified coronary stenosis. *Cathet Cardiovasc Diagn* 1994;32:346.
 12. Tenaglia AN, Zidar JP, Jackman JD Jr, et al. Treatment of long coronary artery narrowings with long angioplasty balloon catheters. *Am J Cardiol* 1993;71:1274.
 13. Plante S, Strauss BH, Goulet G, et al. Reuse of balloon catheters for coronary angioplasty: a potential cost-saving strategy? *J Am Coll Cardiol* 1994;24:1475.
 14. Smith JJ, Henderson JA, Baim DS. The Food and Drug Administration and reprocessing of single-use medical devices: a revised policy and new questions. *J Vasc Interv Radiol* 2002;13:1179-1182.
 15. Levine GN, Kern MJ, Berger PB, et al.; American Heart Association Diagnostic and Interventional Catheterization Committee and Council on Clinical Cardiology. Management of patients undergoing percutaneous coronary revascularization. *Ann Intern Med* 2003;139:123-136.
 16. Levine GN, Bates ER, Blankenship JC, et al. 2011 ACCF/AHA/SCAI guideline for percutaneous coronary intervention: a report of the American College of Cardiology Foundation/American Heart Association Task Force on Practice Guidelines and the Society for Cardiovascular Angiography and Interventions. *Circulation* 2011;124:2574-2609.
 17. Dehmer GJ, Blankenship J, Wharton TP Jr, et al. The current status and future direction of percutaneous coronary intervention without on-site surgical backup: an expert consensus document from the Society for Cardiovascular Angiography and Interventions. *Catheter Cardiovasc Interv* 2007;69:471-478.
 18. Wennberg DE, Lucas FL, Siewers AF, et al. Outcomes of percutaneous coronary interventions performed at centers without and with onsite coronary bypass graft surgery. *JAMA* 2004;292:1961-1968.
 19. Blankenship JC, Klein LW, Laskey WK, et al. SCAI statement on ad hoc versus the separate performance of diagnostic cardiac catheterization and coronary intervention. *Cathet Cardiovasc Interv* 2004;63:444-451.
 20. Fuster V, Dyken ML, Vokonas PS, Hennekens C. Aspirin as a therapeutic agent in cardiovascular disease: AHA medical scientific statement. *Circulation* 1993;87:659.
 21. Solensky R. Drug allergy: desensitization and treatment of reactions to antibiotics and aspirin. *Clin Allergy Immunol* 2004;18:585-606.
 22. Steven R, Steinhubl, MD; Peter B. Berger, MD et al. for the CREDO Investigators. Early and sustained dual oral antiplatelet therapy following percutaneous coronary intervention: a randomized controlled trial. *JAMA* 2002;288:2411-2420.
 23. Kong DF, Califf RA, Miller DP, et al. Outcomes of therapeutic agents that block the platelet glycoprotein IIb/IIIa integrin in ischemic heart disease. *Circulation* 1998;98:2829.
 24. Shamir R, Mehta, Salim Yusuf, Ron J G Peters et al. for the Clopidogrel in Unstable angina to prevent Recurrent Events trial (CURE) Investigators. Effects of pretreatment with clopidogrel and aspirin followed by long-term therapy in patients undergoing percutaneous coronary intervention: the PCI-CURE study. *Lancet* 2001;358:527-533.
 25. Zhang F, Dong L, Ge J. Effect of statins pretreatment on periprocedural myocardial infarction in patients undergoing percutaneous coronary intervention: a meta-analysis. *Ann Med* 2010;42:171-177.
 26. Klein LW, Sheldon MW, Brinker J, et al. The use of radiographic contrast media during PCI: a focused review: a position statement of the Society of Cardiovascular Angiography and Interventions. *Catheter Cardiovasc Interv* 2009;74:728-746.
 27. Mehran R, Aymong ED, Nikolsky E, et al. A simple risk score for prediction of contrast-induced nephropathy after percutaneous coronary intervention: development and initial validation. *J Am Coll Cardiol* 2004;44:1393-1399.
 28. Nundy S, Mukherjee A, Sexton JB, et al. Impact of preoperative briefings on operating room delays: a preliminary report. *Arch Surg* 2008;143:1068-1072.
 29. Wong GC, Giugliano RP, Antman EM. Use of low-molecular-weight heparins in the management of acute coronary artery syndromes and percutaneous coronary intervention. *JAMA* 2003;289:331-342.
 30. Lincoff AM, Kleiman NS, Kereiakes DJ, et al. Long-term efficacy of bivalirudin and provisional glycoprotein IIb/IIIa blockade vs heparin and planned glycoprotein IIb/IIIa blockade during percutaneous coronary revascularization: REPLACE-2 randomized trial. *JAMA* 2004;292:696-703.
 31. Gurm HS, Rajagopal V, Fathi R, et al. Effectiveness and safety of Bivalirudin during percutaneous coronary intervention in a single medical center. *Am J Cardiol* 2005;95:716-721.
 32. Ferguson JJ, Dougherty KG, Gaos CM, et al. Relation between procedural activated coagulation time and the outcome after percutaneous transluminal coronary angioplasty. *J Am Coll Cardiol* 1994;23:1061.
 33. Roubin GS, Douglas JS Jr, King SB 3rd, et al. Influence of balloon size on initial success, acute complications, and restenosis after percutaneous transluminal coronary angioplasty. *Circulation* 1988;78:557.
 34. Nichols AB, Smith R, Berke AD, et al. Importance of balloon size in coronary angioplasty. *J Am Coll Cardiol* 1989;13:1094.
 35. Chenu P, Zakhia R, Marchandise B, et al. Resistance of the atherosclerotic plaque during coronary angioplasty: a multivariable analysis of clinical and angiographic variables. *Cathet Cardiovasc Diagn* 1993;29:203.
 36. Blankenship JC, Kruckoff MJ, Werns SW, et al. Comparison of slow oscillating versus fast balloon inflation strategies for coronary angioplasty. *Am J Cardiol* 1999;83:675.
 37. Anderson HV, Roubin GS, Leimgruber PP, et al. Measurement of transstenotic pressure gradient during percutaneous transluminal coronary angioplasty. *Circulation* 1986;73:1223.
 38. Bech GJW, Pijls NHJ, DeBruyne B, et al. Usefulness of fractional flow reserve to predict clinical outcome after balloon angioplasty. *Circulation* 1999;99:883.
 39. Chambers C, Fetterly K, Holzer R, et al. Radiation safety program for the cardiac catheterization laboratory. *Catheter Cardiovasc Interv* 2011;77:546-556.
 40. Sempendorfer C, Belardi J, Bellamy G, et al. Frequency, management and follow-up of patients with acute coronary occlusions after percutaneous transluminal coronary angioplasty. *Am J Cardiol* 1987;59:267.
 41. Rabah M, Mason D, Muller DW, et al. Heparin after percutaneous intervention (HAPI): a prospective multicenter randomized trial of three heparin regimens after successful coronary intervention. *J Am Coll Cardiol* 1999;34:461-467.
 42. Friedman HZ, Cragg DR, Glazier SM, et al. Randomized prospective evaluation of prolonged versus abbreviated intravenous heparin therapy after coronary angioplasty. *J Am Coll Cardiol* 1994;24:1214.
 43. Fung AY, Saw J, Starovoytov A, et al. Abbreviated infusion of eptifibatid after successful coronary intervention. The BRIEF-PCI (Brief Infusion of Eptifibatid Following Percutaneous Coronary Intervention) randomized trial. *JACC* 2009;53:837-845.
 44. Cutlip DE, Chhabra A, Baim DS, et al. Beyond restenosis—five year clinical outcomes from second-generation coronary stent trials. *Circulation* 2004;110:1226-1230.
 45. Herrmann HC. Prevention of cardiovascular events after percutaneous coronary intervention. *N Engl J Med* 2004;350:2708-2710.
 46. Grundy SM, Cleeman JI, Barley Merz CN, et al. Implications of recent clinical trials for the National Cholesterol Educational Program Adult Treatment Panel III Guidelines. *Circulation* 2004;110:227-239.
 47. Sanborn TA, Faxon DP, Haudenschild CC, Gottsman SB, Ryan TJ. The mechanism of transluminal angioplasty: evidence for

- formation of aneurysms in experimental atherosclerosis. *Circulation* 1983;68:1136.
48. Rensig BJ, Hermans WR, Bequ KJ, et al. Quantitative angiographic assessment of elastic recoil after percutaneous transluminal coronary angioplasty. *Am J Cardiol* 1990;66:1039.
 49. Rozenman Y, Gilon D, Welber S, Sapoznikov D, Gotsman MS. Clinical and angiographic predictors of immediate recoil after successful coronary angioplasty and relation to late restenosis. *Am J Cardiol* 1993;72:1020.
 50. Fischell TA, Derby G, Tse TM, Stadius ML. Coronary artery vasoconstriction after percutaneous transluminal coronary angioplasty: a quantitative arteriographic analysis. *Circulation* 1988;78:1323.
 51. Holmes DR Jr, Vlietstra RE, Mock MB, et al. Angiographic changes produced by percutaneous transluminal coronary angioplasty. *Am J Cardiol* 1983;51:676.
 52. Black AJR, Namay DL, Niederman AL, et al. Tear or dissection after coronary angioplasty—morphologic correlates of an ischemic complication. *Circulation* 1989;79:1035.
 53. Sanborn TA, Faxon DP, Waugh D, et al. Transluminal angioplasty in experimental atherosclerosis: analysis for embolization using an in vitro perfusion system. *Circulation* 1982;66:917.
 54. Saber RS, Edwards WD, Bailey KR, et al. Coronary embolization after balloon angioplasty or thrombolytic therapy—an autopsy study of 32 cases. *J Am Coll Cardiol* 1994;22:1283.
 55. Piana R, Paik GY, Moscucci M, et al. Incidence and treatment of "no reflow" after percutaneous coronary intervention. *Circulation* 1994;89:2514.
 56. Baim DS, Wahr D, George B, et al. Randomized trial of a distal embolic protection device during percutaneous intervention of saphenous vein aorto-coronary bypass grafts. *Circulation* 2002;105:1285-1290.
 57. Stone GW, Rogers C, Hermiller J, et al. Randomized comparison of distal protection with a filter-based catheter and a balloon occlusion and aspiration system during percutaneous intervention of diseased saphenous vein aortocoronary bypass grafts. *Circulation* 2003;108:548-553.
 58. Bavry AA, Kumbhani DJ, Bhatt DL. Role of adjunctive thrombectomy and embolic protection devices in acute myocardial infarction: a comprehensive meta-analysis of randomized trials. *Eur Heart J* 2008;29:2989-3001.
 59. Saffitz JE, Rose TE, Oaks JB, Roberts WC. Coronary artery rupture during coronary angioplasty. *Am J Cardiol* 1983;51:902.
 60. Ellis SG, Ajluni S, Arnold AZ, et al. Increased coronary perforation in the new device era: incidence, classification, management, and outcome. *Circulation* 1994;90:2725.
 61. Fejka M, Simon R, Dixon SR, et al. Diagnosis, management, and clinical outcome of cardiac tamponade complicating percutaneous coronary intervention. *Am J Cardiol* 2002;90:1183-1186.
 62. Kent KM, Mullin SM, Passamani ER. Proceedings of the National Heart, Lung, and Blood Institute Workshop on the Outcome of Percutaneous Transluminal Angioplasty, June 7-8, 1983. *Am J Cardiol* 1984;53:1C.
 63. Detre K, Holubkov R, Kelsey S, et al. Percutaneous transluminal coronary angioplasty in 1985-1986 and 1977-1981: the NHLBI Registry. *N Engl J Med* 1988;318:265.
 64. Holmes DR Jr, Holubkov R, Vlietstra RE, et al. Comparison of complications during percutaneous transluminal coronary angioplasty from 1977 to 1981 and from 1985 to 1986: the NHLBI PTCA Registry. *J Am Coll Cardiol* 1988;12:1149.
 65. Anderson HV, Shaw RE, Brindis RG, et al. A contemporary overview of percutaneous coronary interventions: The American College of Cardiology-National Cardiovascular Data Registry (ACC-NCDR). *J Am Coll Cardiol* 2002;39:1096-1103.
 66. Cutlip DE, Ho KKL, Kuntz RE, Baim DS. Risk assessment for percutaneous coronary intervention—our version of the weather report? *J Am Coll Cardiol* 2003;42:1986-1989.
 67. Shaw RE, Anderson HV, Brindis RG, et al. Development of a risk adjustment mortality model using the American College of Cardiology-National Cardiovascular Data Registry (ACC-NCDR) experience: 1998-2000. *J Am Coll Cardiol* 2002;39:1104-1112.
 68. Singh M, Lennon RJ, Holmes DR Jr, Bell MR, Rihal CS. Correlates of procedural complications and a simple integer risk score for percutaneous coronary intervention. *J Am Coll Cardiol* 2002;40:387-393.
 69. Queshi MA, Safian RD, Grines CL, et al. Simplified scoring system for predicting mortality after percutaneous coronary intervention. *J Am Coll Cardiol* 2003;42:1890-1895.
 70. Ryan T, Bauman WB, Kennedy JW, et al. Guidelines for percutaneous transluminal coronary angioplasty. A report of the American College of Cardiology/American Heart Association Task Force (Subcommittee on Percutaneous Transluminal Coronary Angioplasty). *J Am Coll Cardiol* 1988;12:529-545.
 71. Ellis SG, Vandormael MG, Cowley MJ, and the POSCH Group. Coronary morphologic and clinical determinates of procedural outcome with angioplasty for multivessel coronary disease: implications for patient selection. *Circulation* 1990;82:1193-1202.
 72. Krone RJ, Shaw RE, Klein LW, et al. Evaluation of the American College of Cardiology/American Heart Association and the Society for Coronary Angiography and Interventions lesion classification system in the current "stent era" of coronary interventions (from the ACC-National Cardiovascular Data Registry). *Am J Cardiol* 2003;92:389-394.
 73. Hilliard A, From AM, Lennon RJ, et al. Percutaneous revascularization for stable coronary artery disease: temporal trends and impact of drug eluting stents. *J Am Coll Cardiol Intv* 2010;3:172-179.
 74. Thygesen K, Alpert JS, Jaffe AS, Simoons ML, Chaitman BR, White HD. Third universal definition of myocardial infarction. *J Am Coll Cardiol* 2012;60:1581-1598.
 75. Prasad A, Rihal CS, Lennon RJ, et al. Significance of periprocedural myonecrosis on outcomes after percutaneous coronary intervention: an analysis of preintervention and post intervention troponin T levels in 5487 patients. *Circ Cardiovasc Interv* 2008;1:10-19.
 76. Prasad A, Herrmann J. Myocardial infarction due to percutaneous coronary intervention. *N Engl J Med* 2011;364:453-464.
 77. Hill JA, Margolis JR, Feldman RL, et al. Coronary arterial aneurysm formation after balloon angioplasty. *Am J Cardiol* 1983;52:261.
 78. Vassanelli C, Turri M, Morando G, et al. Coronary artery aneurysm formation after PTCA—a not uncommon finding at follow-up angiography. *Int J Cardiol* 1989;22:151.
 79. Ferguson JJ, Barasch E, Wilson JM, et al. The relation of clinical outcome to dissection and thrombus formation during coronary angioplasty. *J Invasive Cardiol* 1995;7:2.
 80. Ellis SG, Roubin GS, King SB 3rd, et al. Angiographic and clinical predictors of acute closure after native vessel coronary angioplasty. *Circulation* 1988;77:372.
 81. Talley JD, Jones EL, Weintraub WS, et al. Coronary artery bypass surgery after failed elective percutaneous transluminal coronary angioplasty—a status report. *Circulation* 1989;79:1126.
 82. Paik GY, Kuntz RE, Baim DS. Perfusion therapy to resolve myocardial ischemia en route to emergency bypass grafting for failed percutaneous transluminal angioplasty. *J Intervent Cardiol* 1995;8:319.
 83. de Muinck ED, den Heijer P, van Dijk RB, et al. Autoperfusion balloon versus stent for acute or threatened closure during percutaneous transluminal coronary angioplasty. *Am J Cardiol* 1994;74:1002.
 84. George BS, Voorhees WD 3rd, Roubin GS, et al. Multicenter investigation of coronary stenting to treat acute or threatened closure after percutaneous transluminal coronary angioplasty: clinical and angiographic outcomes. *J Am Coll Cardiol* 1993;22:135.
 85. Meier B, Gruentzig AR, King SB 3rd, et al. Risk of side branch occlusion during coronary angioplasty. *Am J Cardiol* 1984;53:10.
 86. Meier B. Kissing balloon coronary angioplasty. *Am J Cardiol* 1984;54:918.
 87. Osterle SN, McAuley BJ, Buchbinder M, Simpson JB. Angioplasty at coronary bifurcations: single-guide, two-wire technique. *Cathet Cardiovasc Diagn* 1986;12:57.

88. Dauerman HL, Higgins PJ, Sparano AM, et al. Mechanical debulking versus balloon angioplasty for the treatment of true bifurcation lesions. *J Am Coll Cardiol* 1998;32:1845.
89. Wohlgeleitner D, Cleman M, Highman HA, et al. Regional myocardial dysfunction during coronary angioplasty: evaluation by two-dimensional echocardiography and 12 lead electrocardiography. *J Am Coll Cardiol* 1986;7:1245.
90. Bertrand ME, Leblanche JM, Fourrier JL, et al. Left ventricular systolic and diastolic dysfunction during acute coronary artery balloon occlusion in humans. *J Am Coll Cardiol* 1988;12:341.
91. Serruys PW, Wijns W, van den Brand M, et al. Left ventricular performance, regional blood flow, wall motion, and lactate metabolism during transluminal angioplasty. *Circulation* 1984;70:25.
92. Feit F, Voeltz MD, Attubato MJ, et al. Predictors and impact of major hemorrhage on mortality following percutaneous coronary intervention from the REPLACE-2 Trial. *Am J Cardiol* 2007;100:1364-1369.
93. Manoukian SV, Feit F, Mehran R, et al. Impact of major bleeding on 30-day mortality and clinical outcomes in patients with acute coronary syndromes: an analysis from the ACUITY Trial. *J Am Coll Cardiol* 2007;49:1362-1368.
94. Mehran R, Pocock SJ, Nikolksy E, et al. A risk score to predict bleeding in patients with acute coronary syndromes. *J Am Coll Cardiol* 2010;55:2556-2566.
95. Nikolksy E, Mehran R, Dangas G, et al. Development and validation of a prognostic risk score for major bleeding in patients undergoing percutaneous coronary intervention via the femoral approach. *Eur Heart J* 2007;28:1936-1945.
96. Subherwal S, Bach RG, Chen AY, et al. Baseline risk of major bleeding in non-ST-segment-elevation myocardial infarction: the CRUSADE (Can Rapid risk stratification of Unstable angina patients Suppress Adverse outcomes with Early implementation of the ACC/AHA Guidelines) Bleeding Score. *Circulation* 2009;119:1873-1882.
97. Mehta SK, Frutkin AD, Lindsey JB, et al. Bleeding in patients undergoing percutaneous coronary intervention: the development of a clinical risk algorithm from the National Cardiovascular Data Registry. *Circulation* 2009;120:222-229.
98. Mehran R, Rao SV, Bhatt DL, et al. Standardized bleeding definitions for cardiovascular clinical trials: a consensus report from the Bleeding Academic Research Consortium. *Circulation* 2011;123:2736.
99. Hartzler GO, Rutherford BD, McConahay DR. Retained percutaneous transluminal coronary angioplasty equipment components and their management. *Am J Cardiol* 1987;60:1260.
100. Serota H, Deligonul U, Lew B, et al. Improved method for transcatheter retrieval of intracoronary detached angioplasty guidewire segments. *Cathet Cardiovasc Diagn* 1989;17:248.
101. McBride W, Lange RA, Hillis LD. Restenosis after successful coronary angioplasty. *N Engl J Med* 1988;318:1734.
102. Mintz GS, Popma JJ, Pichard AD, et al. Arterial remodeling after coronary angioplasty—a serial intravascular ultrasound study. *Circulation* 1996;94:35.
103. Chakravarty T, White AJ, Buch M, et al. Meta-analysis of incidence, clinical characteristics and implications of stent fracture. *Am J Cardiol* 2010;106:1075-1080.
104. Köster R, Vieluf D, Kiehn M, et al. Nickel and molybdenum contact allergies in patients with coronary in-stent restenosis. *Lancet* 2000;356:1895-1897.
105. Serruys PW, Luijten HE, Beatt KJ, et al. Incidence of restenosis after successful coronary angioplasty: a time related phenomenon—a quantitative angiographic follow-up study of 342 patients. *Circulation* 1988;77:361.
106. Hirshfeld JW Jr, Schwartz JS, Jugo R, et al. Restenosis after coronary angioplasty: a multivariable statistical model to relate lesion and procedure variables to restenosis. *J Am Coll Cardiol* 1991;18:647.
107. Kuntz RE, Baim DS. Defining coronary restenosis: newer clinical and angiographic paradigms. *Circulation* 1993;88:1310.
108. Kettelkamp R, House J, Garg M, et al. Using the risk of restenosis as a guide to triaging patients between surgical and percutaneous coronary revascularization. *Circulation* 2004;110:1150-1154.
109. Stolker JM, et al. Predicting restenosis of drug-eluting stents placed in real-world clinical practice: derivation and validation of a risk model from the EVENT registry. *Circ Cardiovasc Interv* 2010;3:327-334.
110. Popma JJ, Suntharalingam M, Lansky AJ, et al. Randomized trial of 90Sr/90Y beta-radiation versus placebo control for treatment of in-stent restenosis. *Circulation* 2002;106:1090-1096.
111. Leon MB, Teirstein PS, Moses JW, et al. Localized intracoronary gamma-radiation therapy to inhibit the recurrence of restenosis after stenting. *N Engl J Med* 2001;344:250-256.
112. Lemos PA, Mercado N, van Domburg RT, Kuntz RE, O'Neill WW, Serruys PW. Comparison of late luminal loss response pattern after sirolimus-eluting stent implantation or conventional stenting. *Circulation* 2004;110:3199-3205.
113. Riley RF, Don CW, Powell W, et al. Trends in coronary revascularization in the United States from 2001 to 2009: recent declines in percutaneous coronary intervention volumes. *Cardiovasc Qual Outcomes* 2011;4:193-197.
114. Boden W, O'Rourke R, Teo K, et al. Optimal medical therapy with or without PCI for stable coronary disease. *N Engl J Med* 2007;356:1503-1516.
115. Feit F, Brooks MM, Sopko G, et al. Long-term clinical outcome in the Bypass Angioplasty Revascularization Investigation Registry: comparison with the randomized trial. BARI Investigators. *Circulation* 2000;101:2795-2802.
116. Morice MC, Serruys PW, Kappetein AP, et al. Outcomes in patients with de novo left main disease treated with either percutaneous coronary intervention using paclitaxel-eluting stents or coronary artery bypass graft treatment in the Synergy between Percutaneous Coronary Intervention with TAXUS and Cardiac Surgery (SYNTAX) trial. *Circulation* 2010;121:2645-2653.
117. Serruys PW, Morice MC, Kappetein AP, et al. Percutaneous coronary intervention versus coronary-artery bypass grafting for severe coronary artery disease. *N Engl J Med* 2009;360:961-972.
118. Shahian DM, O'Brien SM, Filardo G, et al. The Society of Thoracic Surgeons 2008 cardiac surgery risk models: part 1—coronary artery bypass grafting surgery. *Ann Thorac Surg* 2009;88:S2-S22.
119. Shahian DM, O'Brien SM, Normand SL, et al. Association of hospital coronary artery bypass volume with processes of care, mortality, morbidity, and the Society of Thoracic Surgeons composite quality score. *J Thorac Cardiovasc Surg* 2010;139:273-282.
120. Guidelines on Myocardial Revascularization. The Task Force on Myocardial Revascularization of the European Society of Cardiology (ESC) and the European Association for Cardio-Thoracic Surgery (EACTS). *Eur Heart J* 2010;31:2501-2555.
121. Fox KA, Clayton TC, Damman P, et al. Long-term outcome of a routine versus selective invasive strategy in patients with non-ST-segment elevation acute coronary syndrome: a meta-analysis of individual patient data. *J Am Coll Cardiol* 2010;55:2435-2445.
122. Holzhey DM, Jacobs S, Mochalski M, et al. Minimally invasive hybrid coronary artery revascularization. *Ann Thorac Surg* 2008;86:1856-1860.
123. Kon ZN, Brown EN, Tran R, et al. Simultaneous hybrid coronary revascularization reduces postoperative morbidity compared with results from conventional off-pump coronary artery bypass. *J Thorac Cardiovasc Surg* 2008;135:367-375.
124. Reicher B, Poston RS, Mehra MR, et al. Simultaneous "hybrid" percutaneous coronary intervention and minimally invasive surgical bypass grafting: feasibility, safety, and clinical outcomes. *Am Heart J* 2008;155:661-667.
125. Vassiliades TA Jr, Douglas JS, Morris D, et al. Integrated coronary revascularization with drug-eluting stents: immediate and seven-month outcome. *J Thorac Cardiovasc Surg* 2006;131:956-962.
126. Zhao DX, Leacche M, Balaguer JM, et al. Routine intraoperative completion angiography after coronary artery bypass grafting and

- 1-stop hybrid revascularization results from a fully integrated hybrid catheterization laboratory/operating room. *J Am Coll Cardiol* 2009;53:232–241.
127. Vander Salm TJ, Kip KE, Jones RH, et al. What constitutes optimal surgical revascularization? Answers from the Bypass Angioplasty Revascularization Investigation (BARI). *J Am Coll Card* 2002;39:565–572.
128. Kim YH, Park DW, Lee JY, et al. Impact of angiographic complete revascularization after drug-eluting stent implantation or coronary artery bypass graft surgery for multivessel coronary artery disease. *Circulation* 2011;123:2373–2381.
129. Patel MR, Dehmer GJ, Hirshfeld JW, et al. ACCF/SCAI/STS/AATS/AHA/ASNC 2009 Appropriateness Criteria for Coronary Revascularization: a report by the American College of Cardiology Foundation Appropriateness Criteria Task Force, Society for Cardiovascular Angiography and Interventions, Society of Thoracic Surgeons, American Association for Thoracic Surgery, American Heart Association, and the American Society of Nuclear Cardiology Endorsed by the American Society of Echocardiography, the Heart Failure Society of America, and the Society of Cardiovascular Computed Tomography. *J Am Coll Cardiol* 2009;53:530–553.
130. Chan PS, Patel MR, Klein LW, et al. Appropriateness of percutaneous coronary intervention. *JAMA* 2011;306:53–61.
131. Hirshfeld JW, Banas JS, Brundage BH, et al. American College of Cardiology training statement on recommendations for the structure of an optimal adult interventional cardiology training program: a report of the American College of Cardiology task force on clinical expert consensus documents. *J Am Coll Cardiol* 1999;34:2141–2147.
132. Post PN, Kuijpers M, Ebels T, et al. The relation between volume and outcome of coronary interventions: a systematic review and meta-analysis. *Eur Heart J* 2010;31:1985–1992.
133. Hannan EL, Wu C, Walford G, et al. Volume-outcome relationships for percutaneous coronary interventions in the stent era. *Circulation* 2005;112:1171–1179.
134. Srinivas VS, Hailpern SM, Koss E, et al. Effect of physician volume on the relationship between hospital volume and mortality during primary angioplasty. *J Am Coll Cardiol* 2009;53:574–579.
135. Kumbhani DJ, Cannon CP, Fonarow GC, et al. Association of hospital primary angioplasty volume in ST-segment elevation myocardial infarction with quality and outcomes. *JAMA* 2009;302:2207–2213.
136. Patel MR, Dehmer GJ, Hirshfeld JW, Smith PK, Spertus JA. ACCF/SCAI/STS/AATS/AHA/ASNC/HFSA/SCCT 2012 appropriate use criteria for coronary revascularization focused update: a report of the American College of Cardiology Foundation Appropriate Use Criteria Task Force, Society for Cardiovascular Angiography and Interventions, Society of Thoracic Surgeons, American Association for Thoracic Surgery, American Heart Association, American Society of Nuclear Cardiology, and the Society of Cardiovascular Computed Tomography. *J Am Coll Cardiol* 2012;59:857–881.
137. Harold JG, Bass TA, Bashore TM, et al. ACCF/AHA/SCAI 2013 Update of the Clinical Competence Statement on Coronary Artery Interventional Procedures. *Journal of the American College of Cardiology* (2013), doi: 10.1016/j.jacc.2013.05.002.

Grossman & Baim's Cardiac Catheterization, Angiography, and Intervention

EIGHTH EDITION

EDITOR

MAURO MOSCUCCI, MD, MBA

Professor of Medicine
Chairman, Department of Medicine (Acting)
Chief, Cardiovascular Division
University of Miami Miller School of Medicine
Miami, Florida



Wolters Kluwer | Lippincott Williams & Wilkins

Health

Philadelphia • Baltimore • New York • London
Buenos Aires • Hong Kong • Sydney • Tokyo

Acquisitions Editor: Julie Goolsby
Product Manager: Leanne Vandetty
Production Project Manager: David Orzechowski
Senior Manufacturing Manager: Beth Welsh
Design Coordinator: Joan Wendt
Production Service: Integra Software Services Pvt. Ltd

© 2014 by LIPPINCOTT WILLIAMS & WILKINS, a WOLTERS KLUWER business
Two Commerce Square
2001 Market Street
Philadelphia, PA 19103 USA
LWW.com

7th edition © 2006 by LIPPINCOTT WILLIAMS & WILKINS
6th edition © 2000 by LIPPINCOTT WILLIAMS & WILKINS
5th edition © 1996 by WILLIAMS & WILKINS

All rights reserved. This book is protected by copyright. No part of this book may be reproduced in any form by any means, including photocopying, or utilized by any information storage and retrieval system without written permission from the copyright owner, except for brief quotations embodied in critical articles and reviews. Materials appearing in this book prepared by individuals as part of their official duties as U.S. government employees are not covered by the above-mentioned copyright.
Printed in China

Library of Congress Cataloging-in-Publication Data

Cardiac catheterization, angiography, and intervention.

Grossman & Baim's cardiac catheterization, angiography, and intervention / editor, Mauro Moscucci, MD, MBA, professor of medicine, chairman, Department of Medicine, University of Miami Miller School of Medicine, Miami, Florida. — Eighth edition.

pages cm

Includes bibliographical references and index.

ISBN 978-1-4511-2740-9 (hardback)

1. Cardiac catheterization. 2. Angiography. I. Moscucci, Mauro, editor of compilation. II. Title. III. Title: Grossman and Baim's cardiac catheterization, angiography, and intervention.

RC683.5.C25C38 2013

616.1'20754—dc23

2013025399

Care has been taken to confirm the accuracy of the information presented and to describe generally accepted practices. However, the authors, editors, and publisher are not responsible for errors or omissions or for any consequences from application of the information in this book and make no warranty, expressed or implied, with respect to the currency, completeness, or accuracy of the contents of the publication. Application of the information in a particular situation remains the professional responsibility of the practitioner.

The authors, editors, and publisher have exerted every effort to ensure that drug selection and dosage set forth in this text are in accordance with current recommendations and practice at the time of publication. However, in view of ongoing research, changes in government regulations, and the constant flow of information relating to drug therapy and drug reactions, the reader is urged to check the package insert for each drug for any change in indications and dosage and for added warnings and precautions. This is particularly important when the recommended agent is a new or infrequently employed drug.

Some drugs and medical devices presented in the publication have Food and Drug Administration (FDA) clearance for limited use in restricted research settings. It is the responsibility of the health care provider to ascertain the FDA status of each drug or device planned for use in their clinical practice.

To purchase additional copies of this book, call our customer service department at (800) 638-3030 or fax orders to (301) 223-2320. International customers should call (301) 223-2300.

Visit Lippincott Williams & Wilkins on the Internet at: LWW.com. Lippincott Williams & Wilkins customer service representatives are available from 8:30 am to 6:00 pm, EST.

10 9 8 7 6 5 4

RRS1903

Contents

Contributors vii
Preface to the Eighth Edition xi
Preface to the Website to the Eighth Edition xiii
Acknowledgments xv

SECTION I GENERAL PRINCIPLES 1

1. Cardiac Catheterization History and Current Practice Standards 1
Mauro Moscucci
2. Cineangiographic Imaging, Radiation Safety, and Contrast Agents 17
Stephen Balter and Mauro Moscucci
3. Integrated Imaging Modalities in the Cardiac Catheterization Laboratory 44
Robert A. Quaife and John D. Carroll
4. Complications 77
Mauro Moscucci
5. Adjunctive Pharmacology for Cardiac Catheterization 106
Kevin Croce and Daniel I. Simon

SECTION II BASIC TECHNIQUES 139

6. Percutaneous Approach, Including Transseptal and Apical Puncture 139
Claudia A. Martinez and Mauro Moscucci
7. Radial Artery Approach 170
Mauricio G. Cohen and Sunil V. Rao
8. Cutdown Approach: Brachial, Femoral, Axillary, Aortic and Transapical 191
Ronald P. Caputo, G. Randall Green, and William Grossman
9. Diagnostic Catheterization in Childhood and Adult Congenital Heart Disease 208
Gabriele Egidy Assenza, James E. Lock, and Michael J. Landzberg

SECTION III HEMODYNAMIC PRINCIPLES 223

10. Pressure Measurement 223
Mauro Moscucci and William Grossman
11. Blood Flow Measurement: Cardiac Output and Vascular Resistance 245
Mauro Moscucci and William Grossman
12. Shunt Detection and Quantification 261
William Grossman and Mauro Moscucci
13. Calculation of Stenotic Valve Orifice Area 272
Blase A. Carabello and William Grossman

14. Pitfalls in the Evaluation of Hemodynamic Data 284
Zoltan G. Turi

SECTION IV ANGIOGRAPHIC TECHNIQUES 295

15. Coronary Angiography 295
Mauro Moscucci
16. Coronary Artery Anomalies 335
Paolo Angelini and Jorge Monge
17. Cardiac Ventriculography 354
Mauro Moscucci and Robert C. Hendel
18. Pulmonary Angiography 370
Kyung Cho and Nils Kucher
19. Angiography of the Aorta and Peripheral Arteries 399
Michael R. Jaff, John Rundback, and Kenneth Rosenfield

SECTION V EVALUATION OF CARDIAC FUNCTION 431

20. Stress Testing During Cardiac Catheterization: Exercise, Pacing, and Dobutamine Challenge 431
William Grossman and Mauro Moscucci
21. Measurement of Ventricular Volumes, Ejection Fraction, Mass, Wall Stress, and Regional Wall Motion 456
Michael A. Fifer and William Grossman
22. Evaluation of Systolic and Diastolic Function of the Ventricles and Myocardium 467
William Grossman and Mauro Moscucci
23. Evaluation of Tamponade, Constrictive, and Restrictive Physiology 489
Mauro Moscucci and Barry A. Borlaug

SECTION VI SPECIAL CATHETER TECHNIQUES 505

24. Evaluation of Myocardial and Coronary Blood Flow and Metabolism 505
Morton J. Kern and Michael J. Lim
25. Intravascular Imaging Techniques 545
Yasuhiro Honda, Peter J. Fitzgerald, and Paul G. Yock
26. Endomyocardial Biopsy 576
Sandra V. Chaparro and Mauro Moscucci
27. Percutaneous Circulatory Support: Intra-aortic Balloon Counterpulsation, Impella, TandemHeart, and Extracorporeal Bypass 601
Daniel Burkhoff, Mauro Moscucci, and Jose P.S. Henriques

SECTION VII INTERVENTIONAL TECHNIQUES 627

28. Percutaneous Balloon Angioplasty and General Coronary Intervention 627
Abhiram Prasad and David R. Holmes
29. Atherectomy, Thrombectomy, and Distal Protection Devices 665
Robert N. Piana and Jeffrey J. Popma

30. Intervention for Acute Myocardial Infarction 697
William O'Neill
31. Coronary Stenting 710
Ajay J. Kirtane and Gregg W. Stone
32. General Overview of Interventions for Structural Heart Disease 760
Mauro Moscucci, John D. Carroll, and John G. Webb
33. Percutaneous Therapies for Valvular Heart Disease 772
Ted Feldman and Mauro Moscucci
34. Peripheral Intervention 805
Mehdi H. Shishehbor and Samir R. Kapadia
35. Intervention for Pediatric and Adult Congenital Heart Disease 838
Robert J. Sommer
36. Cardiac Cell-Based Therapy: Methods of Application and Delivery Systems 871
Joshua M. Hare, Arnon Blum, and Alan W. Heldman
37. Aortic Endovascular Grafting 891
Arash Bornak, Gilbert R. Upchurch, and Omaid C. Velazquez
38. Pericardial Interventions: Pericardiocentesis, Balloon Pericardiotomy, and Epicardial Approach to Cardiac Procedures 904
Mauro Moscucci and Juan F. Viles-Gonzalez
39. Interventions for Cardiac Arrhythmias 921
Haris M. Haqqani and Francis E. Marchlinski

SECTION VIII CLINICAL PROFILES 943

40. Profiles in Valvular Heart Disease 943
Ted Feldman, William Grossman, and Mauro Moscucci
41. Profiles in Coronary Artery Disease 970
Robert N. Piana and Aaron Kugelmass
42. Profiles in Pulmonary Hypertension and Pulmonary Embolism 991
Scott H. Visovatti and Vallerie V. Mclaughlina
43. Profiles in Cardiomyopathy and Heart Failure 1011
James C. Fang and Barry A. Borlaug
44. Profiles in Pericardial Disease 1045
John F. Robb, Roger J. Laham, and Mauro Moscucci
45. Profiles in Congenital Heart Disease 1060
Gabriele Egidy Assenza, Robert J. Sommer, and Michael J. Landzberg
46. Profiles in Peripheral Arterial Disease 1078
Christopher J. White and Stephen R. Ramee

Index 1113

31

Coronary Stenting

AJAY J. KIRTANE and GREGG W. STONE

Stents are metallic scaffolds that are deployed within diseased segments of coronary arteries to establish and maintain wide luminal patency. Currently, stent-assisted coronary intervention is the most common revascularization modality in patients with coronary artery disease. The acute and late results of stent implantation, however, vary greatly depending on the clinical risk profile of the patient, the complexity of the coronary lesion and interventional procedure, and the specific stent device that is used. A broad range of evidence is available from clinical trials conducted over the past two decades to guide appropriate stent usage in most situations. The present chapter traces the evolution and development of the coronary stent from its initial applications to treat balloon angioplasty failures to its widespread global adoption for the treatment of patients with ischemic coronary heart disease.

BARE-METAL STENT OVERVIEW

Limitations of Balloon Angioplasty

While the performance of the first successful balloon angioplasty on September 16, 1977, in Zurich, Switzerland, set the stage for the millions of percutaneous coronary intervention (PCI) procedures that have since taken place, stand-alone balloon angioplasty as performed by Andreas Gruentzig and other early pioneers was a highly unpredictable experience. The mechanism of balloon angioplasty involves plaque fracture (dissection) into the deep media, with expansion of the external elastic lamina, as well as partial axial plaque redistribution along the length of the treated vessel. The majority of vessels undergoing balloon angioplasty tolerate balloon dilatation and heal sufficiently to result in an adequate lumen; however, balloon-mediated injury to the vessel wall can at times be uncontrolled and excessive, resulting in balloon angioplasty's two major limitations: abrupt closure (occurring acutely, or within the first several days after angioplasty)

and restenosis (occurring later, within months after the procedure due to a combination of acute recoil and chronic constrictive remodeling). The coronary stent was thus devised as an endoluminal scaffold to create a larger initial lumen, to seal dissections, and to resist recoil and late vascular remodeling, thereby improving upon the early and late results of balloon angioplasty.

Development of the Coronary Stent

The term "stent" derives from a dental prosthesis developed by the London dentist Charles Stent (1807–1885) and is now used to indicate any device used for "extending, stretching, or fixing in an expanded state".¹ The first stents were implanted in human coronary arteries in 1986 by Ulrich Sigwart, Jacques Puel, and colleagues, who placed the Wallstent sheathed self-expanding metallic mesh scaffold (Medinvent, Lausanne, Switzerland) in the peripheral and coronary arteries of eight patients.² Further experience with this device demonstrated high rates of thrombotic occlusion and late mortality,³ although patients without thrombosis had a 6-month angiographic restenosis rate of only 14%, suggesting for the first time that stenting could improve late patency in addition to stabilizing the acute results obtained after conventional balloon angioplasty. Another early stent platform developed contemporaneously by Cesare Gianturco and Gary Roubin was a balloon-expandable coil stent consisting of a wrapped stainless steel wire resembling a clamshell (Figure 31.1, left). A phase II study evaluating the Gianturco-Roubin stent to reverse postangioplasty acute or threatened vessel closure was started in 1988,⁴ ultimately leading to United States Food and Drug Administration (FDA) approval for this indication in June 1993.

While these stents were being developed and tested, Julio Palmaz designed a balloon-expandable slotted tube stainless steel stent in which rectangular slots were cut into thin-walled stainless steel tubing and deformed into diamond-shaped windows during expansion by an underlying delivery




Figure 31.1 Left. The Gianturco-Roubin Stent. Stainless steel sutures were wound around a cylindrical rod using pegs to shape the wire, resulting in a clamshell design. Right. The Palmaz-Schatz Stent. Note the articulation between the two slotted tubes.

balloon. While this design allowed for relatively straightforward deployment, the rigidity of this initial stent design made it difficult to deliver this device to the coronary vasculature. In 1989 a design modification was made by Richard Schatz, consisting of the placement of a 1 mm central articulating bridge connecting the two rigid 7 mm slotted segments,⁵ creating the 15 mm Palmaz-Schatz stent (Johnson and Johnson Interventional Systems, Warren, NJ) (Figure 31.1, right). The first coronary Palmaz-Schatz stent was placed in a patient by Eduardo Sousa in São Paulo, Brazil in 1987 with a US pilot study started in 1988.

In 1989, enrollment commenced in two randomized multicenter studies (STRESS and BENESTENT) comparing balloon angioplasty alone to elective Palmaz-Schatz stenting. In these studies, the use of the Palmaz-Schatz stent was associated with a 20% to 30% reduction in clinical and angiographic restenosis compared with conventional balloon angioplasty (Figure 31.2).^{6,7} The Palmaz-Schatz stent also resulted in markedly improved initial angiographic results, with a larger postprocedural minimal luminal diameter and fewer residual dissections, which translated into a lower rate of subacute vessel closure. These results led to approval

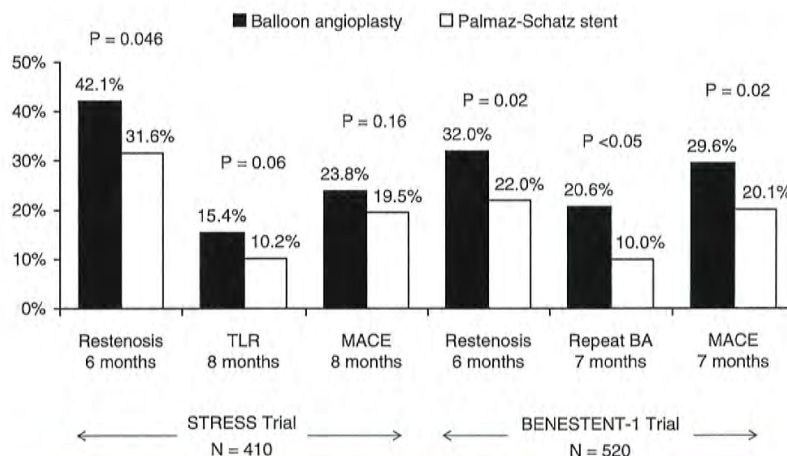


Figure 31.2 Results of STRESS and BENESTENT-1 landmark trials of the Palmaz-Schatz stent, which provided the evidence base for FDA approval of the Palmaz-Schatz stent for the prevention of restenosis in de novo lesions. BA, balloon angioplasty; TLR, target lesion revascularization; MACE, major adverse cardiac events.

of the Palmaz-Schatz stent by the FDA in 1994. Long-term follow-up up to 15 years has subsequently demonstrated few late clinical or angiographic recurrences from years 1 to 5 after coronary stent implantation,^{8,9} with slight and progressive decrements in luminal size thereafter extending beyond 10 years.¹⁰ The mechanisms of this late progression of disease are not entirely known, but have been hypothesized to be related to the development of new atherosclerosis within the originally stented segment rather than clot formation, as overall stent thrombosis rates have remained low (1.5% at 15 years).¹⁰

Despite the impressive acute and long-term results with the Palmaz-Schatz stent which became the dominant stent design for coronary use, widespread adoption of stent technology was initially hindered by the perceived need for an intense anticoagulation regimen (consisting of aspirin, dipyridamole, heparin, dextran, and warfarin) to inhibit stent thrombosis (which nonetheless occurred in approximately 3% of patients). This profound degree of anticoagulation, however, resulted in a marked increase in hemorrhagic and vascular complications. It was not until further refinements in stent deployment technique and the utilization of dual antiplatelet therapy demonstrated reductions in these complications that stent usage became more widespread. Pioneers such as Antonio Colombo demonstrated reduced rates of stent thrombosis with more aggressive intravascular ultrasound (IVUS)-guided deployment techniques including routine high-pressure adjunctive dilatation (>14 atmospheres),¹¹ along with the use of aspirin and a second antiplatelet agent (thienopyridine, ticlopidine) rather than prolonged warfarin therapy. These modifications significantly reduced the

incidence of stent thrombosis to ~1% to 2%, and concomitantly reduced bleeding and femoral arterial complications.¹² The confirmation of Colombo's initial findings in several randomized clinical trials (Figure 31.3) definitively established the superiority of dual antiplatelet therapy (with aspirin and ticlopidine) over an anticoagulation-based approach for prevention of stent thrombosis, and facilitated widespread adoption for coronary stenting by the late 1990s.¹³⁻¹⁶

Stent Design: Impact on Performance and Clinical Outcomes

Classification

Coronary stents may be classified based on their composition (e.g., metallic or polymeric), configuration (e.g., slotted tube versus coiled wire), bioabsorption (either inert (biostable or durable) or degradable [bioabsorbable]), coatings (either none, passive such as heparin or polytetrafluoroethylene, PTFE), or bioactive (such as those eluting rapamycin or paclitaxel), and mode of implantation (e.g., self-expanding or balloon-expandable). The ideal stent would be made of a nonthrombogenic material and have sufficient flexibility in its unexpanded state to permit ready passage through guiding catheters and tortuous vessels, and yet have an expanded configuration providing uniform scaffolding of the vessel wall with low recoil and maximal radial strength while conforming to vessel bends. In addition, the ideal stent would be sufficiently radiopaque to allow fluoroscopic visualization to guide accurate placement and management of in-stent restenosis, but not so opaque as to obscure important angiographic vessel

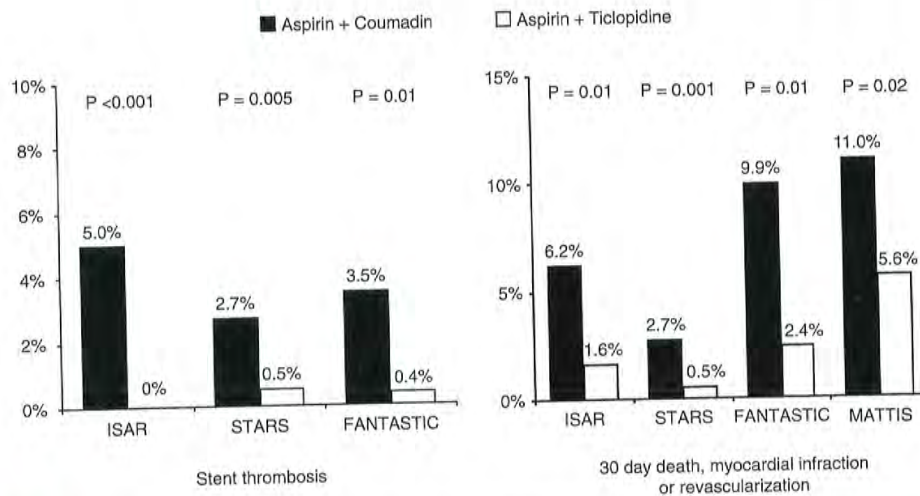


Figure 31.3

Benefits of dual antiplatelet therapy in reducing clinical events post stenting. Shown are the results from four landmark trials demonstrating the efficacy of antiplatelet (over antithrombotic) therapy.

details. In recent years, the importance of the stent delivery system to device profile, flexibility, and trackability around tortuous and calcific coronary vessels has received increasing appreciation. For balloon-expandable stents, the stent must be tightly crimped to the delivery balloon to avoid dislodgment, and the overhang of the balloon beyond the ends of the stent should be minimized (<1 mm) to avoid vessel trauma outside the stent margins. Stent delivery balloons must be able to withstand high pressures (>18 atm) without rupture, and should take into account a balance between deliverability versus a desire for low compliance to facilitate predictable sizing and avoid excessive growth outside the stent edges.

Stent Composition

Until recently, the most widely used stent material was 316L stainless steel. Cobalt chromium and platinum chromium alloys have been employed in more recent stent designs in order to allow lower-profile thin stent struts (~75 μm , versus 100 to 150 μm in most stainless steel stents) that still maintain radial strength and visibility. Most self-expanding stents utilize nitinol, a nickel/titanium alloy that has superelastic and thermal shape memory properties that allow it to be set into a particular expanded shape by baking at high temperature. Nitinol stents can then be squeezed down and constrained on the delivery system, able to return to that set shape when released in the coronary artery.

Other than gold (which has been shown to increase restenosis), there is little evidence that thrombosis or restenosis rates vary with the specific stent metal, though the final stages of surface finishing, smoothing, and purification or passivation may affect early thrombotic and late restenotic processes.¹⁷ There is a burgeoning interest in biodegradable stents, which theoretically offer the advantages of increased longitudinal flexibility (though at the expense of radial force), compatibility with noninvasive imaging, and complete bioabsorption over a period of months to a year or longer, thereby restoring underlying vascular reactivity. Bioabsorbable stents (or bioabsorbable scaffolds) are typically either polymeric in nature (e.g., using proprietary biodegradable polymers or poly-L-lactic acid (PLLA), which is degraded via the Krebs cycle to carbon dioxide and water) or nonpolymeric (e.g., magnesium-based).

Stent Configuration and Design

Stents can be assigned to one of three subgroups, based on construction: wire coils, slotted tubes/multicellular, and modular designs. After early experiences with wire coil stents (e.g., the Gianturco-Roubin stent), these types of stent designs rapidly fell out of favor because they in general lacked axial and radial strength, and due to lesser strut coverage predisposed to plaque prolapse. Thus, the vast majority of stents in current use are either slotted tube/multicellular or modular in design. In an effort to preserve the radial strength and wall coverage of the original tubular designs (e.g. the Palmaz

stent) but improve flexibility in their collapsed states, several generations of slotted tube and multicellular stents have been introduced by various manufacturers. Each is laser cut from a metallic tube into a unique pattern that increases the overall flexibility of the stent by distributing bending throughout the stent length without compromising radial strength or elastic recoil in the expanded state. The newer stents are manufactured in a broad range of stent lengths (8 to 48 mm) and diameters (2.25 to 6.0 mm and above for peripheral applications) to facilitate stenting of long lesions, small vessels, saphenous vein grafts (SVGs), and distal lesions. To eliminate the need for a protective sheath, various mechanical, balloon-wrapping, and heat-curing processes have been developed to tightly crimp the stent onto the balloon until it is deployed. This bare mounting onto the delivery balloon has greatly reduced stent delivery profiles, comparable with the best angioplasty balloons of the late 1990s, and has kept stent embolization rates below approximately 1 to 3 per 1,000 procedures.

Despite their enhanced flexibility, even the latest-generation slotted tube stents are sometimes difficult to deliver through tortuous and noncompliant vessels. In an effort to enhance flexibility and deliverability without sacrificing the excellent scaffolding of the slotted tube stents, modular or hybrid stents have been created by flexibly joining multiple short repeating modules to each other. The initial modular stent was the Arterial Vascular Engineering MicroStent (subsequently purchased by Medtronic Corp., Santa Rosa, CA), which had a series of 4-mm-long, rounded stainless steel corrugated ring subunits welded to each other. Subsequent designs have incorporated an elliptorectangular (rounded) strut profile and progressively reduced the length of the individual modules, with progressive reductions in crossing profile and increased surface area coverage. Additionally, variation in the location and frequency of the weld-points has been used to engineer flexibility without attempting to sacrifice radial and axial strength.

Depending on the cellular configuration, multicellular stents can be broadly subclassified as either open cell or closed cell. Open cell designs tend to have varying cell sizes and shapes along the stent, and provide increased flexibility, deliverability, and side branch access by staggering the cross-linking elements to provide radial strength. Open cell designs thus tend to conform better on bends, though the cell area may open excessively on the outer curve of an angulated segment. Closed cell designs typically incorporate a repeating unicellular element that provides more uniform wall coverage with less tendency for plaque prolapse, at the expense of reduced flexibility and side branch access. Closed cell designs also tend to straighten vessel bends more than open cell designs.

Stent design may significantly impact acute and late vascular responses. Stents that possess better conformability, less rigidity, and greater circularity experimentally produce less vascular injury, thrombosis, and neointimal hyperplasia.^{18,19} Ex-vivo and clinical studies have suggested that thin stent

struts may be associated with reduced neointimal hyperplasia and lower rates of restenosis,²⁰ in addition to inherently less thrombogenicity.²¹

Due to the recent emphasis upon thin-strutted and more flexible stent designs in order to facilitate deliverability as well as other adverse vascular responses to stent implantation, there have been some concerns regarding the integrity of modern stent platforms. While thin-strutted stents have obvious advantages, some of these stent platforms have been associated with a greater tendency for recoil (radial) or orthogonally, for axial (or "longitudinal") deformation and/or compression.^{22,23} In the instance of axially oriented deformation, this phenomenon has been described to occur specifically when implanted stents are subjected to repeated stresses, such as multiple balloon exchanges and guide-stent interactions.²⁴ Engineering modifications can be employed

to maintain flexibility and deliverability without sacrificing axial and radial strength. As such, further investigations of stent-specific differences based upon these characteristics are required.

Stent Coatings

A variety of coatings have been used to attempt to reduce the thrombogenicity and/or propensity for restenosis of metallic stents (Table 31.1). Experimental studies have demonstrated that coating stents with inert polymers may reduce surface reactivity and thrombosis,^{19,21} though until recently, most polymers used were found to provoke intense inflammatory reactions.²⁵ With the advent of the drug-eluting stents (DES) came a renewed interest in the study of stent coatings, primarily to act as drug-carrier vehicles. However, concerns

Table 31.1 Stent Coatings Designed to Reduce Thrombogenicity

Heparin
- Multiple formulations incorporating heparin bonding through covalent bonding, ionic bonds, or heparin complexes [Carmeda BioActive Surface (CBAS) covalently heparin-bonded Palmaz-Schatz and Bx Velocity stents, Jomed Corline Heparin Surface (CHS) heparin-coated Jostent]
Carbon
- Turbostratic (Sorin Carbostent)
- Silicon carbide (Biotronik Tenax)
- Diamond-like films (Phytis Diamond and Plasmachem Biodiamond)
Phosphorylcholine
- Biocompatibles BiodivYsio stent
- Medtronic Endeavor drug-eluting stent
Fluorinated copolymer (Xience V and Promus Element drug-eluting stents)
Ionic Oxygen penetration into stent (Iberhospitex Bionert)
CD34 Antibody to capture endothelial progenitor cells (Orbus-Neich Genous)
Trifluoroethanol (Polyzene-F coated stent)
Nanolayer protein coating (SurModics Finale coating on Protex stent)
Nitric oxide scavengers including titanium-nitric oxide (Hexacath Titan stent)
Single Knitted PET Fiber Mesh (MGuard)
Biolinx Polymer (Medtronic Resolute drug-eluting stent)
Abciximab and other glycoprotein IIb/IIIa inhibitors
Activated protein C
Hirudin and bivalirudin
Prostacyclin
Gold
Turmeric

regarding the long-term safety of DES and the requirement for extended duration dual antiplatelet therapy have led to a renewed interest in biocompatible stent coatings. A number of novel stent coatings are currently under investigation. Additionally, covered stents (metallic stents covered by a distensible microporous PTFE membrane) are of unquestioned clinical utility in treating life-threatening perforations (see Chapter 4). They are also used for excluding giant aneurysms, pseudoaneurysms, or clinically significant fistulae.

Balloon-Expandable Versus Self-Expanding Stents

Balloon-expandable stents are mounted onto a delivery balloon and delivered into the coronary artery in their collapsed state. Once the stent is in the desired location, inflation of the delivery balloon expands the stent and embeds it into the arterial wall, following which the stent delivery system is removed. Balloon-expandable stents are typically chosen to be 1 to 1.1 times the reference arterial diameter, with a length several millimeters longer than the lesion. Almost all stents implanted in human coronary arteries are balloon expandable.

Self-expanding stents incorporate either specific geometric designs or nitinol shape-retaining metal to achieve a preset diameter. The stent is mounted onto the delivery system in its collapsed state and constrained by a restraining membrane or sheath. Retraction of the membrane allows the stent to resume its unconstrained (expanded) geometry. Self-expanding stents are typically selected to have an unconstrained diameter 0.5 to 1.0 mm greater than the adjacent reference segment to ensure contact with the vessel wall and adequate expansile force to resist vessel recoil. Still, final optimization of stent expansion usually requires additional dilatation within the stent using a high-pressure, noncompliant angioplasty balloon. While self-expanding stents are flexible and often easier to deliver compared to their balloon-expandable counterparts, restenosis has remained a concern, limiting their use in coronary arteries.²⁶ Moreover, difficulties relating to accurate sizing and precise placement of self-expanding stents necessitate a longer operator learning curve and render these devices unsuitable for treating ostial lesions or stenoses adjacent to side branches. Recently, a renewed interest in self-expanding stents with reduced outward expansion force for treatment of patients with acute coronary syndromes or vulnerable plaque has surfaced.²⁷

Comparisons Between Bare-Metal Stents

Following early demonstrations of superiority of the originally introduced bare-metal stents (BMS) over balloon angioplasty, a series of stent versus stent trials ensued, either initiated by the industry for regulatory purposes or by independent investigators to assess stent performance in

more complex patients and lesions. The present applicability of these early trials is limited, as virtually all of the stents studied in these trials are no longer in clinical use. Once receiving FDA approval, newer, more advanced stent designs typically replaced earlier-generation stents in the marketplace because of enhanced deliverability and/or radiopacity, rather than because of any perception of improved acute or late outcomes. Several investigator-initiated studies did nevertheless demonstrate the superiority of thinner-strutted stent platforms over thicker-strut stents, not just in terms of deliverability, but also with respect to restenosis.^{20,28} However, particularly following the introduction of DES, the anti-restenotic effects of which in general dwarf design-specific differences in BMS (see below), the majority of studies with present BMS platforms have been either comparative DES versus BMS studies or nonrandomized approval registries of iterative BMS technologies.

INDICATIONS FOR CORONARY STENTING

Stents may be used either on a routine (planned) basis or after failed balloon angioplasty for acute or threatened vessel closure ("bail-out" stenting). One of the major benefits of stenting is the ability to reverse abrupt closure due to dissection and recoil, thus eliminating the need for high-risk emergency bypass surgery.²⁹ These data, coupled with the fact that routine stent implantation compared to balloon angioplasty provides superior acute results and greater event-free survival in almost every patient and lesion subtype studied to date has for the most part relegated balloon dilation to the rare lesion that is too small (<2.0 mm) for stenting, or to which a stent cannot be delivered because of excessive vessel tortuosity or calcification, or in patients in whom thienopyridines are contraindicated.

The utility of routine stent implantation as a modality to reduce acute vessel closure and late restenosis was first demonstrated in the STRESS and BENESTENT-1 trials, which enrolled patients undergoing PCI of discrete, focal lesions.^{6,7} As a result, the types of lesions treated in these trials (discrete de novo lesions coverable by one stent, with reference vessel diameter [RVD] 3.0 to 4.0 mm) became known as "Stress/Benestent" lesions, to differentiate them from more complex stenoses. Despite initial concerns regarding potentially diminished efficacy of coronary stents (which were more costly than balloon angioplasty alone) with more generalized use of these devices,³⁰ abundant randomized and non-randomized data now exist comparing stenting to balloon angioplasty across a range of patient and lesion subsets, and they almost universally demonstrate an advantage to coronary stenting over conventional balloon angioplasty or other approaches using procedures such as atherectomy.³¹⁻³³ As a result, stents are used in the vast majority of PCI procedures

performed today, and balloon angioplasty alone is reserved for cases where stents cannot be delivered, where stents are too big for the target lesion, or for rare niche indications (e.g. ostial side branch disease at a bifurcation, some cases of in-stent restenosis, or cases where patients cannot tolerate the antiplatelet regimens required after stent implantation).

DRUG-ELUTING STENT OVERVIEW

Limitations of Bare-Metal Stents

Stent implantation has been the prevailing treatment for most patients with coronary artery disease since the late 1990s as a result of the more predictable acute and late angiographic results of stenting compared with conventional balloon angioplasty and other adjunctive technologies such as atherectomy. With improvements in stent deliverability and reductions in stent thrombosis through modifications of technique and adjunctive pharmacotherapy, the primary limitation of BMS as the default adjunctive therapy to balloon angioplasty for patients undergoing coronary revascularization by PCI was in-stent restenosis. While coronary stents increase acute luminal diameters to a greater extent than balloon angioplasty (leading to greater acute luminal gain), the vascular injury caused by stent implantation elicits an exaggerated degree of neointimal hyperplasia, resulting in greater decreases in luminal diameter (late lumen loss) compared to balloon angioplasty alone.^{6,7} While these two factors can offset each other, the mean incremental gain in luminal dimensions with stenting compared with balloon angioplasty alone is greater than the mean incremental increase in late loss, resulting in a larger net gain in minimal luminal dimensions over the follow-up period. This observation was formulated as the “bigger is better” concept by Kuntz and colleagues, who demonstrated an association between better acute results following stent placement with a lower rate of subsequent restenosis—a finding that was replicated independent of the stent device selected.^{34,35} Nonetheless, despite attempts to maximize acute gain through an upfront “bigger is better” stent optimization strategy, rates of clinical restenosis following BMS implantation approached 20% to 40% within 6 to 12 months, with even higher rates observed among the highest-risk patient and lesion subsets. As such, coronary restenosis became known as the “Achilles’ heel” of coronary stenting, with significant resources devoted to the study of its prevention and treatment.

DES, which maintain the mechanical advantages of BMS while delivering an antirestenotic pharmacologic therapy locally to the arterial wall, have been shown to effectively and safely reduce the amount of in-stent tissue that accumulates after stent implantation, resulting in significantly reduced rates of clinical and angiographic restenosis. In numerous randomized trials, the reduction in neointimal hyperplasia that occurs with DES compared to that with BMS has been

shown to result in a marked reduction in binary angiographic restenosis and target lesion revascularization (TLR).^{36,38} The initial results of the pivotal randomized trials that led to device approval have been replicated and validated in numerous subsequent trials and real-world registries across the spectrum of disease and lesion subtypes.^{39,40} As a result, DES are currently implanted in the majority of the >2 million patients undergoing PCI each year.

Components of Drug-Eluting Stents

The three critical components of a DES that must be optimized to ensure its safety and efficacy are (1) the *stent* itself (including its delivery system); (2) the *pharmacologic agent* being delivered; and (3) the *drug carrier*, which controls the drug dose and pharmacokinetic release rate (Figure 31.4).

Stent Design

The stent component of DES has typically consisted of a predicate BMS without specific modifications. Indeed, first-generation DES designs often appropriated “off-the shelf” stent designs in order to expedite device development and regulatory approval. Subsequent DES have incorporated newer, more flexible designs, with resultant improvements in device delivery and performance.^{41,42} Ideally, stent geometry should be optimized for homogeneous drug distribution (which involves considerations of closed versus open cell designs, interstrut distances, etc.). Consistent circumferential stent-to-vessel wall contact should be ensured to ensure drug delivery. As a result, the stent should be conformable to angulated segments, while at the same time minimize geometric distortion. The stent should also have sufficient radiopacity to facilitate precise lesion coverage (while avoiding excessive stent overlap or interstent gaps). Side branch access should be maintained, and the stent should be low profile, flexible, and deliverable to reach and treat complex anatomies. Additionally, newer dedicated DES designs have included modifications aimed at either optimizing local drug delivery while reducing total drug dose (e.g. abluminal wells engineered into the stent struts), or modifying the stent surface to facilitate direct drug delivery and/or arterial healing following implantation (without a drug carrier vehicle per se).

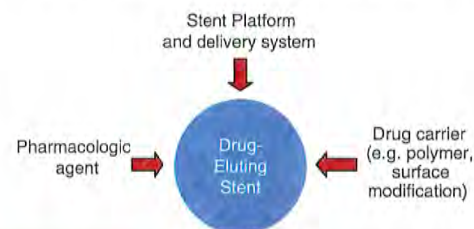

Figure 31.4 Components of drug-eluting stents.

Pharmacology

Following promising cell culture and in vitro development, the antirestenotic properties of a wide range of pharmacologic agents have been tested in humans (Figure 31.5). The two most clinically effective classes of agents have been the “rapamycin-analogue” (or “-limus”) family of drugs and paclitaxel. The principal mechanism of action of rapamycin (also known as sirolimus), and its analogues (including zotarolimus, everolimus, biolimus A9, novolimus, and amphili-mus) is inhibition of the mammalian target of rapamycin (mTOR), which prevents cell cycle progression from the G1 to S phase.⁴³ Two other rapamycin analogues that have been used on DES platforms—tacrolimus and pimecrolimus—have a different mechanism of action, binding directly to FK-binding protein (FKBP)-506 and thereby inhibiting the calcineurin receptor with downregulation of cytokines and inhibition of smooth muscle cell activity⁴⁴; unlike the mTOR inhibitors, these agents have not been demonstrated to be beneficial. The other agent that has been used effectively in coronary DES (and more widely now in drug-eluting balloons and in peripheral DES applications) is paclitaxel. By interfering with microtubule function, paclitaxel has multifunctional antiproliferative and antiinflammatory properties, prevents smooth muscle migration, blocks cytokine and growth factor release and activity, interferes with secretory processes, is antiangiogenic, and impacts signal transduction.⁴⁵⁻⁴⁷ At low doses (similar to those in DES), paclitaxel affects the G0-G1 and G1-S phases (G1 arrest) resulting in cytostasis without cell death.^{45,48}

Polymers and Drug Delivery Systems

Early DES programs were plagued by the inability to predictably deliver a specific dose of active drug over the right time frame to the arterial wall.⁴⁹ In order to more effectively regulate the dosing of antirestenotic agents, a *drug carrier* vehicle became necessary. In many respects, formulating and optimizing the drug carrier vehicle have proven even more complex than identification of the drug itself. Properties that must be considered for a controlled release vehicle include its biocompatibility, solubility, diffusivity and porosity, molecular size, weight and distribution, elongation, functional requirements, degradation products, durability, relative hydrophobicity, purity, availability, adhesion, crystallinity, sterilization, solvent solubility, biostability, miscibility, bioabsorbable versus permanent nature, evaporation rate, thermal properties, resistance to humidity and temperature extremes, compatibility with specific drugs, approval for implant use, processability (which relates to shelf life), and packaging requirements.

Numerous polymer-based drug delivery systems have since been developed, and are DES-specific (discussed below). While the polymer is instrumental in regulating the pharmacokinetics of drug delivery to the arterial wall (which is necessary for reduced neointimal hyperplasia), the polymer may also elicit deleterious vascular responses. Specifically, histopathologic studies have demonstrated hypersensitivity and eosinophilic inflammatory reactions and delayed endothelialization with first-generation DES that were not previously seen with BMS.³⁰⁻³² Whether these vascular responses in humans are directly related to the polymer or to toxicity from the drug

Anti-Inflammatory, Immunomodulators	Anti-Proliferative	Smooth Muscle Cell Migration Inhibitors, Extracellular Matrix Modulators	Promoters of Healing and Re-Endothelialization
Sirolimus (and analogues) Paclitaxel, Taxane Dexamethasone M-prednisolone Interferon γ -1b Leflunomide Tacrolimus Mycophenolic acid Mizoribine Cyclosporine Tranilast Biorest	Sirolimus (and analogues) Paclitaxel, Taxane Actinomycin D Methothrexate Angiopeptin Vincristine Mitomycine Statins C MYC antisense RestenASE 2-Chloro-deoxyadenosine PCNA Ribozyme	Batimastat Prolyl hydroxylase inhibitors Halofuginone C-proteinase inhibitors Probucol	BCP671 VEGF Estradiols Nitric oxide donors Endothelial progenitor cell antibodies Biorest Advanced coatings
<div style="border: 1px solid black; padding: 5px; width: fit-content; margin: 0 auto;"> <p>Many agents have Multiple actions</p> </div>			

Figure 31.5 Potential antirestenotic agents for use with drug-eluting stents.

itself is not well known, but in animal models these effects can be attenuated by modification of the polymer vehicle.⁵³ It is believed that inflammation and delayed endothelialization play a role in the development of late stent malapposition, aneurysm formation, stent thrombosis and restenosis.^{50,54,55} For these reasons, there has been great interest in developing inert and biocompatible polymers, bioabsorbable/biodegradable polymers, and even polymer-free DES.

Generations of Drug-Eluting Stents

DES are often classified into several generations of development (Table 31.2). First-generation devices include the two DES that were initially approved for clinical use by most regulatory bodies, each of which utilized an early (currently outdated) BMS stent platform with early durable polymers (not specifically designed for biocompatibility) in order to deliver either sirolimus or paclitaxel. Second-generation devices

(currently used in the vast majority of DES procedures) have incorporated more deliverable, thinner-strut stents with polymers that have been designed for biologic compatibility. Most second-generation DES utilize -limus (rapamycin) analogues. Future-generation DES will continue to undergo iteration, with further modifications of the base stent and use of biodegradable/bioabsorbable or polymer-free drug-carrier vehicles.

FIRST GENERATION DRUG-ELUTING STENTS

The Cypher™ Sirolimus-Eluting Stent

The first DES to attain approval for human use was the Cypher™ stent (Cordis, Johnson and Johnson), with initial first-in-human studies as well as subsequent clinical trials

Table 31.2 Generational Classification of Drug-Eluting Stents

Generation	Drug	Polymer	Stent
First	Sirolimus or Paclitaxel	Not Specifically Designed for Biocompatibility	Early BMS Platforms
Cypher™	Sirolimus	Biostable mix of poly-n-butyl methacrylate and polyethylene-vinyl acetate	Bx Velocity™
TAXUS™ Express	Paclitaxel	Styrene-isobutylene-styrene (SIBS)	Express
TAXUS™ Liberté	Paclitaxel	Styrene-isobutylene-styrene (SIBS)	Liberté ^a
ION™ (TAXUS™ ELEMENT)	Paclitaxel	Styrene-isobutylene-styrene (SIBS)	Element (platinum-chromium) ^a
Second	Limus Analogues	Biocompatible Polymers	More Flexible, Thinner-Strut BMS
Endeavor™	Zotarolimus	Phosphorylcholine	Driver (cobalt alloy)
Xience V™ and Xience PRIME™	Everolimus	Vinylidene fluoride and hexafluoropropylene	Multi-Link Vision and Multi-Link 8 (cobalt-chromium)
Promus Element™	Everolimus	Vinylidene fluoride and hexafluoropropylene	Element (platinum-chromium)
Resolute™	Zotarolimus	Biolinx polymer	Integrity (cobalt alloy)
Biomatrix™	Biolimus A9	Abluminal poly-L-lactic acid (bioabsorbable)	Juno (stainless steel)
Nobori™	Biolimus A9	Abluminal poly-L-lactic acid (bioabsorbable)	S-stent

^aLiberté and, in particular, Element BMS platforms are newer BMS platforms but are included in the first-generation due to the presence of the original TAXUS™ polymer.

leading to its approval in Europe in 2002 and in the United States in 2003. Production of this stent was recently halted, but some description of the technology and initial studies that led to device approval is of historical interest, as the introduction of this stent ushered in the DES era of interventional cardiology. Sirolimus (rapamycin) is a highly lipophilic, naturally occurring macrocyclic lactone, which was first isolated from *Streptomyces hygroscopicus* found in a soil sample from Easter Island (also known as Rapa Nui) and was initially developed as an antifungal agent. Shortly thereafter, it became apparent that this agent also was a potent immunosuppressive, and was initially approved by the FDA (as Rapamune) for prevention of renal transplant rejection in 1999. The primary mechanism of action of inhibition of neointimal hyperplasia in sirolimus is thought to be related to its ability to bind to FKBP-12 in cells; the sirolimus-FKBP-12 complex then binds to and inhibits activation of mTOR, preventing progression in the cell cycle from the late G1 to S phase.⁴³ Sirolimus has been demonstrated to have a marked effect on suppression of neointimal hyperplasia with low toxicity following sirolimus-eluting stent (SES) implantation in initial small and large animal studies.^{36,37}

The stent platform for the Cypher™ SES was the Bx Velocity™ stent, a thick-strutted slotted tube with a closed cell design constructed from 316L stainless steel. The stent was coated with biostable (nonerodible) polymers consisting of poly-n-butyl methacrylate and polyethylene-vinyl acetate that are loaded with 140 µg/cm² sirolimus. The slow-release (SR) formulation of the Cypher™ SES employed in clinical

practice used a basecoat of blended polymers loaded with sirolimus as well as a topcoat of polymer alone (without sirolimus) that acted as a diffusion barrier, controlling the rate of drug release from the basecoat into the vessel wall. Approximately 80% of the sirolimus loaded on the stent was released within the first month after stent implantation.

In 1999, human experience with the Cypher™ SES was initiated at the Institute Dante Pazzanese of Cardiology in São Paulo, Brazil, and the Thoraxcenter, Rotterdam, The Netherlands, with the first-in-man (FIM) study in 45 patients with symptomatic de novo native coronary lesions <18 mm in length with RVD 3.0 to 3.5 mm. In this study, SES demonstrated marked suppression of neointimal hyperplasia measured by IVUS and quantitative coronary angiography at 4 months, and 1, 2, and 4 years.³⁸ Serial angiography and IVUS have now been performed at 7 years, showing continued vessel patency without further late loss (Figure 31.6). These data led to the conduct of the larger RAVEL trial, in which 238 patients outside the United States with relatively simple de novo coronary lesions were randomized to either the Cypher™ SES or the uncoated Bx Velocity stent.³⁶ The SES essentially eliminated late loss compared with BMS (mean of -0.01 mm versus 0.80 mm, $P < 0.001$), with a corresponding reduction in the rate of angiographic restenosis (0% versus 26%, $P < 0.001$).

On the basis of these data, the larger pivotal SIRIUS trial was conducted in the United States.³⁹ SIRIUS was a 1058-patient randomized trial comparing the Cypher™ SES to the uncoated Bx Velocity in patients with vessel diameters

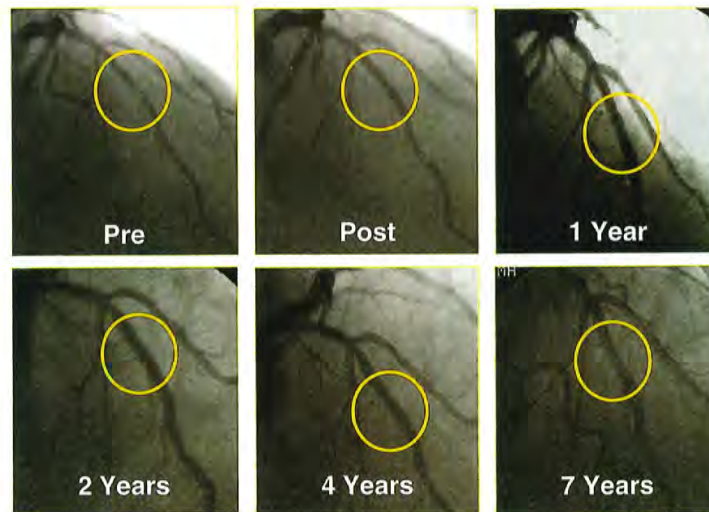


Figure 31.6 Seven-year follow-up of one of the initial sirolimus-eluting stent implantations from Institute Dante Pazzanese of Cardiology in São Paulo, Brazil, demonstrating sustained patency of the initially stented segment.

of 2.5 to 3.5 mm and lesion lengths of 15 to 30 mm. The primary endpoint, the rate of target vessel failure (TVF; a composite of cardiac death, myocardial infarction [MI], or target vessel revascularization [TVR]) at 9 months, was markedly lower among SES-treated patients (8.6% versus 21.0%, $P < 0.001$) (Figure 31.7). Additionally, SES resulted in a 60% to 80% relative reduction in composite adverse events in all examined subgroups in the trial. Among the 703 patients in whom 8-month routine angiographic follow-up was performed, mean in-stent late loss was markedly lower with SES (0.17 mm versus 1.00 mm, $P < 0.001$). By IVUS, the in-stent percent volumetric obstruction at 8 months was reduced from 33.4% with the Bx Velocity to 3.1% with the SES ($P < 0.001$), although late stent malapposition was present in 9.7% of Cypher™ SES patients versus 0% of Bx Velocity patients ($P = 0.02$).

On the basis of these results, in April 2003 the Cypher™ SES became the first DES approved by the FDA, and this stent became one of the most studied devices in modern history, with a multitude of randomized trials and observational studies assessing its efficacy and safety. In their aggregate, these data demonstrate extremely low levels of in-stent late loss with SES (averaging ~0.15 mm across studies), with an approximate 70% to 80% reduction in angiographic restenosis and clinical revascularization of the target lesion (TLR) compared to BMS. Longer-term follow-up with this device extending to 5 years and beyond has confirmed these findings. In these analyses, treatment with SES has resulted in sustained reductions in clinical restenosis endpoints with similar rates of death,

MI, and stent thrombosis compared with BMS.⁶⁰ In part due to the availability of newer stent platforms and designs, the manufacturer of this stent recently announced that the device would no longer be manufactured and sold, ending the stent's tenure as the oldest DES in current clinical use.

The Taxus™ Paclitaxel-Eluting Stent

The other first-generation DES that came to market soon after approval of SES was the TAXUS™ paclitaxel-eluting stent (PES). Paclitaxel, a highly lipophilic diterpenoid compound, was first isolated in 1963 from the pacific yew tree (*Taxus brevifolius*) and developed for its potent antineoplastic properties. Its principal action is to interfere with microtubule dynamics, preventing their depolymerization. This leads to widespread dose-dependent multicellular activity of the drug, including antiproliferative and antiinflammatory properties, reduced smooth muscle migration, blocking of cytokine and growth factor release and activity, interference with secretory processes, antiangiogenic effects, and impaired signal transduction.⁴⁵⁻⁴⁷ At low doses (similar to those in DES applications), paclitaxel affects the G0-G1 and G1-S phases (G1 arrest) resulting in cytostasis without cell death (probably via induction of p53/p21 tumor suppression genes).^{45,48} Systemic paclitaxel was shown to inhibit restenosis in a rat carotid injury model at levels more than 100-fold lower than that required for tumor cytotoxicity.⁴⁶ Neointimal area was greatly reduced in a rabbit balloon-injury experiment using local paclitaxel administration,⁴⁹ and stent-based paclitaxel elution from polymer-based systems has been shown to profoundly reduce intimal hyperplasia in rabbit iliac arteries for up to 6 months with dose-dependent efficacy and toxicity.^{61,62}

The TAXUS™ PES (Boston Scientific, Natick, MA) consists of paclitaxel contained within a polyolefin derivative biostable polymer (styrene-isobutylene-styrene, referred to as SIBS (Translute™)), originally coated on the Nir stent and subsequently on the Express open-cell slotted tube stainless steel stent platform (PES(E), the device from which most of the randomized clinical trial data for this stent was derived). The base BMS has further evolved from the Express stent to the newer Liberté stent (PES(L), a more flexible, thinner-strutted open-cell stainless steel slotted tube stent, and finally to a platinum-chromium Element stent. Depending on the relative ratio of paclitaxel to polymer, the stent may be formulated with varying release kinetics. The clinically available formulation of the TAXUS™ PES is the SR formulation, although the moderate-release (MR) formulation has also been tested in moderate-sized clinical trials. The SR stent has relatively more polymer to drug (paclitaxel concentration of 1 $\mu\text{g}/\text{mm}^2$), with a coat thickness 18 μm , and approximately 8% in vivo paclitaxel elution in 30 days. The drug is eluted in a rapid burst phase over the initial 48 hours, followed by a slow, sustained release for the next 10 to 30 days, with the remainder sequestered in the bulk of the polymer matrix below the surface without pathways to the external environment (thus permanently retained on the stent).

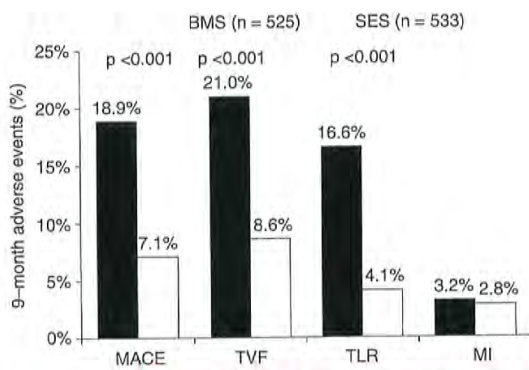


Figure 31.7 Primary results of the SIRIUS trial, the pivotal approval trial of the sirolimus-eluting stent, demonstrating superiority of the sirolimus-eluting stent in reducing restenosis-related endpoints. SES, sirolimus-eluting stent; BMS, bare-metal stent; MACE, major adverse cardiac events; TVF, target vessel failure; TLR, target lesion revascularization; MI, myocardial infarction.

The TAXUS clinical program evaluated the clinical safety and efficacy of the TAXUS™ PES in several clinical trials.⁶³⁻⁶⁷ TAXUS I and II evaluated the performance of the PES on the Nir stent platform in focal de novo disease, whereas TAXUS IV, V, and VI investigated the PES(E) stent in more complex lesions. All studies have used the SR formulation, except for one arm of the TAXUS II trial and TAXUS VI. Collectively, these trials demonstrate a marked decrease of binary restenosis with PES compared to BMS, with an approximate 60% to 75% reduction in the need for TLR, an effect that has been consistent across a range of patient and lesion subtypes. The study that ultimately led to device approval in the United States in 2004 was the TAXUS IV trial,⁶⁵ which enrolled 1,314 patients with single de novo lesions with visually estimated lengths of 10 to 28 mm in native coronary arteries with an RVD of 2.5 to 3.75 mm. Patients were assigned to either a PES(E) stent or Express BMS control. The primary endpoint of TVR assessed at 9 months was reduced with the PES(E) from 12.0% to 4.7% ($P < 0.001$) (Figure 31.8). Follow-up angiography at 9 months demonstrated marked reductions in mean in-stent late loss (0.39 versus 0.92 mm, $P < 0.001$), and the rate of binary in-segment restenosis (7.9% versus 26.6%, $P < 0.001$). By IVUS, the in-stent percent volumetric obstruction at 8 months was reduced from 29.4% with the BMS to 12.2% with PES(E) ($P < 0.001$), and late stent malapposition at 9 months was present in 1.1% of PES(E) patients versus 2.2% of BMS patients ($P = 0.62$).

The PES(E) has been studied in numerous randomized trials and observational analyses, across a range of

patient indications and lesion subsets. These studies have demonstrated consistent reductions in measures of neointimal hyperplasia and resultant reductions in clinical restenosis endpoints compared with BMS. Longer-term follow-up with this device has extended to 5 years and beyond, confirming the sustained efficacy of this stent.⁶⁵ In these analyses, treatment with PES has resulted in sustained reductions in clinical restenosis endpoints, with similar rates of death, MI, and stent thrombosis with PES and BMS. Additionally, a series of comparisons between the first two approved devices (SES and PES) was reported in order to determine whether superiority could be established for a particular DES. In summary, the totality of evidence appears to indicate similar performance of SES and PES in routine de novo coronary artery lesions, despite a lower amount of neointimal hyperplasia with SES as assessed by IVUS and angiography.⁶⁶⁻⁷¹ Given the greater degree of late loss suppression with the SES, it was hypothesized that in the highest restenotic risk patients and lesions, this stent would hold an advantage over PES. Without a large-scale adequately powered randomized trial, however, these potential benefits remain unproven.

The commercially available PES has undergone several iterations, but is still generally considered a “first-generation” DES due to its use of an original polymer to elute paclitaxel. The PES(L) stent (using the same drug and polymer formulation as the PES(E), but with an improved stent platform) was approved for clinical use based upon the TAXUS ATLAS program, in which nonrandomized data from several PES(L) single-arm studies were compared to the treatment arms from prior TAXUS trials with the PES(E).⁷² More recently, the PES(L) has been replaced by the TAXUS™ Element stent (again, using the same drug and polymer formulation as the original TAXUS™ Express SR, but with an iterated stent platform using a platinum chromium alloy). The TAXUS™ Element stent (or ION stent) is the current commercially available version of PES in the United States. Approval of this stent required completion of the PERSEUS trial, which evaluated 1,262 patients with de novo “workhorse” atherosclerotic coronary lesions allocated in a 3:1 randomization to TAXUS™ Element versus PES(E).⁷³ The TAXUS™ Element was demonstrated to be noninferior to PES(E) with respect to the primary endpoint of 12-month target lesion failure (TLF: 5.6% versus 6.1%, respectively) as well as the secondary endpoint of percentage diameter stenosis at 9-month angiographic follow-up (3.1% versus 3.1%, respectively). No differences in clinical outcomes were observed between the two randomized groups in this trial. The TAXUS™ Element stent has additionally been evaluated in smaller vessels in a prospective, single-arm trial comparing 224 patients treated with this stent with 125 lesion-matched historical Express BMS control subjects from the TAXUS V trial.⁷⁴ In this analysis, the TAXUS™ Element was superior to the Express BMS with respect to late lumen loss (0.38 mm versus 0.80 mm, $P < 0.001$), and TLF (7.3% versus 19.5%, $P < 0.001$).

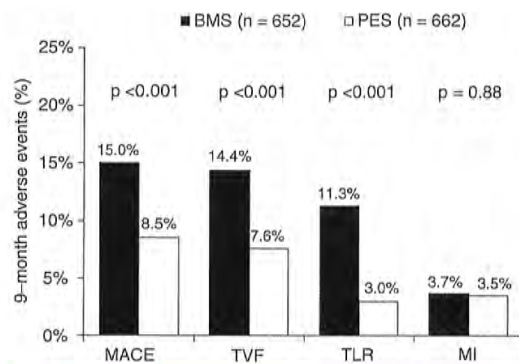


Figure 31.8 Primary results of the TAXUS-IV trial, the pivotal approval trial of the paclitaxel-eluting stent, demonstrating superiority of the paclitaxel-eluting stent in reducing restenosis-related endpoints. PES, paclitaxel-eluting stent; BMS, bare-metal stent; MACE, major adverse cardiac events; TVF, target vessel failure; TLR, target lesion revascularization; MI, myocardial infarction.

SECOND-GENERATION DRUG-ELUTING STENTS

Despite the demonstrated efficacy of first-generation SES and PES as observed in the initial and subsequent randomized trials of these devices, late reactions to first-generation DES polymers as well as delayed endothelialization and adverse vessel responses were described,^{54,75} potentially resulting in the most devastating complication of stent placement, namely late stent thrombosis. In order to mitigate some of the abnormal vessel responses associated with first-generation DES, several new devices have been introduced, with specific modifications implemented upon first-generation technology. These so-called second-generation DES (currently used in the majority of PCI) have incorporated more deliverable, thinner-strut stents with polymers that have been specifically designed for biologic compatibility. Discussed below are clinical data relating to the most-studied second-generation devices, namely, everolimus-eluting stents (EES; Xience V/Promus and everolimus-eluting platinum chromium stent (Promus Element)); zotarolimus-eluting stents (ZES; Endeavor and Resolute); and biolimus A9-eluting stents (BES; Biomatrix).

Everolimus-Eluting Stents (Xience V™/Promus™)

In the EES (manufactured by Abbott Vascular (Santa Clara, CA) and distributed as the Xience V and now Xience PRIME stents, and also originally distributed by Boston Scientific as the Promus stent), everolimus (100 µg/cm²) is released from a thin (7.8 µm), nonadhesive, durable, biocompatible, fluorocopolymer consisting of vinylidene fluoride and hexafluoropropylene monomers, coated onto a low-profile (81 µm strut thickness), flexible, cobalt chromium stent. (The original Xience V base stent platform has been updated in the Xience PRIME stent to the Multi-link 8 BMS platform, a more deliverable version of the Vision platform). The release kinetics of EES are similar to that seen with sirolimus from the SES (~80% of the drug released at 30 days, with none detectable after 120 days). The polymer is elastomeric, and experiences minimal bonding, webbing, or tearing upon expansion. Fluoropolymers have additionally been shown to resist platelet and thrombus deposition in blood-contact applications.^{21,76,77} The EES polymer has also been demonstrated to be noninflammatory in porcine experiments. Preclinical studies have demonstrated more rapid coverage of the stent struts with functional endothelialization with EES compared to SES, PES, or ZES.⁵³

In the small SPIRIT First trial, the EES was shown to markedly reduce the extent of angiographic late loss at 6 and 12 months compared to the otherwise identical cobalt chromium Vision BMS.⁷⁸ Subsequently, the EES has been studied in multiple randomized trials comparing this device to PES (the predominant comparator), SES, ZES, and BMS

(Table 31.3).^{42,79-89} The large SPIRIT IV trial,⁴² enrolling 3,687 patients with stable coronary artery disease undergoing PCI of up to three lesions in three vessels, was a pivotal FDA approval study of the EES, randomizing patients to EES versus PES(E). While this study had broader inclusion criteria than first-generation DES approval studies, patients with unstable acute coronary syndromes, MI, thrombus, chronic occlusions, vein graft lesions, and true bifurcation lesions were excluded. The primary endpoint of TLF (a composite of cardiac death, target-vessel MI, or ischemia-driven TLR) was significantly lower at 1 year with EES compared to PES (3.9% versus 6.6%, $P = 0.0008$). Rates of stent thrombosis (0.3% versus 1.1%, $P = 0.003$), MI (1.9% versus 3.1%, $P = 0.02$), and TLR (2.3% versus 4.5%, $P = 0.0008$) were also lower with EES compared to PES. Longer-term follow-up of SPIRIT IV to 3 years⁸⁵ has demonstrated sustained reductions in TLF, MI, and stent thrombosis with EES over PES (0.8% versus 1.9%), but narrowing of the initially observed difference in TLR with each stent (6.2% versus 7.8%, $P = 0.06$). However, both all-cause mortality (3.2% versus 5.1%, $P = 0.02$) and death or MI (5.9% versus 9.1%, $P = 0.001$) were reduced with EES compared to PES. These data from SPIRIT IV parallel results from the unrestricted "all-comer" COMPARE trial, in which 1,800 patients were randomized to EES versus PES(L). The primary endpoint of MACE at 1 year (death, MI, or TVR) was lower with EES compared to PES (6.2% versus 9.1%, $P = 0.02$), driven by reductions in stent thrombosis (0.7% versus 2.6%, $P = 0.002$), MI (2.8% versus 5.4%, $P = 0.007$), and TLR (1.7% versus 4.8%, $P = 0.0002$). Notably, between 1 and 3 years in this high-risk study cohort (in which only ~15% of patients were maintained on dual antiplatelet therapy), fewer stent thrombosis, MI, and TLR events occurred with EES compared to PES.⁸⁰

In contrast to the marked differences observed between EES and PES, smaller differences have been observed between EES and SES in several randomized trials. In the SORT OUT IV trial,⁸⁷ 2,774 unselected patients were randomized to EES versus SES and followed through the Danish Civil Registration System. Similar 9-month outcomes were observed between EES- and SES-treated patients although definite stent thrombosis occurred in fewer EES- than SES-treated patients at both 9 and 18 months (18 months: 0.2% versus 0.9%). In the 2,314-patient BASKET-PROVE multicenter trial comparing EES, SES, and BMS (the otherwise identical cobalt chromium Vision BMS) in large coronary arteries requiring >3.0 mm stents,⁹³ EES, SES, and BMS were associated with similar rates of cardiac death or nonfatal MI at 2 years and the rate of TVR was similar between EES and SES. However, the rate of TVR was significantly lower with both EES and SES compared to BMS (3.1% for EES, 3.7% for SES, 8.9% for BMS), even in larger arteries with low rates of restenosis. The majority of comparative trials between EES and SES have demonstrated largely similar angiographic outcomes with EES and SES^{89,94,96} except for the ESSENCE-DIABETES trial,⁸⁸ in which EES was associated with lower rates of angiographic late loss and binary restenosis in diabetic patients at 8 months compared

Table 31.3 Randomized Controlled Trials of Everolimus-Eluting Stents

Trial Acronym and Reference	Study Cohort	EES Versus	Number Randomized (Planned Angiographic Follow-Up)	Latest Follow-Up to Date	Principal Findings
SPIRIT First ^{78,80}	Noncomplex CAD	BMS	60 (all)	5 y	EES versus BMS resulted in markedly reduced late loss and neointimal volume obstruction.
SPIRIT II ⁸²	Noncomplex CAD; up to 2 lesions	PES(E)	300 (all)	5 y	EES versus PES(E) resulted in lower 6-month angiographic in-stent late loss (0.11 ± 0.27 mm versus 0.36 ± 0.39 mm, $P < 0.0001$).
SPIRIT III ^{83,91}	Noncomplex CAD; up to 2 lesions	PES(E)	1,002 (564)	5 y	EES versus PES(E) resulted in lower 8-month angiographic in-segment late loss (0.14 ± 0.41 mm versus 0.28 ± 0.48 mm, $P = 0.004$), noninferior 9-mo rates of TVF (7.2% versus 9.0%, $P = 0.31$), and reduced rates of MACE at 1 y (5.9% versus 9.9%, $P = 0.02$) and 5 y (13.7% versus 20.2%, $P = 0.007$).
SPIRIT IV ^{42,85}	Noncomplex CAD; up to 3 lesions	PES(E)	3,687 (none)	3 y	EES versus PES(E) resulted in lower 1-y rates of TLF (3.9% versus 6.6%, $P = 0.0008$) and ischemia-driven TLR (2.3% versus 4.5%, $P = 0.0008$), with similar rates of cardiac death or target-vessel MI (2.2% versus 3.2%, $P = 0.09$). EES also resulted in lower rates of MI and stent thrombosis. At 3 y, these results were maintained although the difference in TLR was no longer significant (6.2% versus 7.8%, $P = 0.06$). 3-y mortality and death or MI were reduced with EES compared to PES (text).
COMPARE ^{80,92}	All-comers	PES(L)	1,800 (none)	3 y	EES versus PES(L) resulted in lower 1-y rates of the primary composite endpoint death, MI or TVR (6.2% versus 9.1%, $P = 0.02$). EES also resulted in lower rates of MI, stent thrombosis, and TLR (text). Between 1 and 3 y, EES resulted in less stent thrombosis, MI, and TLR events.
SPIRIT V Diabetes ⁷⁹	Diabetes	PES(L)	324 (all)	1 y	EES versus PES(L) resulted in lower 9-mo rates of angiographic in-stent late loss (0.19 ± 0.37 mm versus 0.39 ± 0.49 mm, $P = 0.0001$).

(Continued)

Table 31.3 Randomized Controlled Trials of Everolimus-Eluting Stents (*Continued*)

Trial Acronym and Reference	Study Cohort	EES Versus	Number Randomized (Planned Angiographic Follow-Up)	Latest Follow-Up to Date	Principal Findings
BASKET-PROVE ⁹³	Large coronary arteries (≥ 3.0 mm stents)	SES, BMS	2,314 (none)	2 y	EES and SES resulted in lower rates of TVR compared to BMS (3.1% and 3.7% respectively versus 8.9%). There were no differences between the three stent types in the rates of death, MI, or stent thrombosis at 2 y.
EXECUTIVE ⁹¹	MVD, otherwise noncomplex CAD	PES(L)	200 (all)	9 mo	EES versus PES(L) resulted in lower 9-mo angiographic in-stent late loss (0.11 ± 0.27 mm versus 0.36 ± 0.39 mm, $P = 0.008$).
ISAR-TEST-4 ^{96,94}	Simple and complex CAD	SES	1,304 (all)	3 y	EES versus SES resulted in nonsignificantly different rates of in-segment late loss at 24 mo (0.29 ± 0.51 mm versus 0.31 ± 0.58 mm, $P = 0.59$). At 3 y, the rates of clinical outcomes were similar between EES and SES (for TLR: 12.8% versus 15.5%, $P = 0.15$).
SORT OUT IV ⁹⁷	Unselected patients	SES	2,774 (none)	18 mo	EES versus SES resulted in similar rates of the composite endpoint of death, MI, stent thrombosis, or clinically driven TVR at 9 and 18 mo (7.2% versus 7.6%, $P = 0.64$). Definite stent thrombosis at 18 mo was lower with EES (0.2% versus 0.9%, $P = 0.03$).
EXAMINATION ⁹⁵	STEMI	BMS	1,504 (none)	1 y	EES versus BMS resulted in similar rates of composite death, MI, or revascularization, but lower rates of TLR (2.2% versus 5.1%, $P = 0.003$). Definite/probable stent thrombosis at 1 y was lower in EES patients (0.9% versus 2.6%; $P = 0.01$).
EXCELLENT ⁹⁹	Noncomplex CAD	SES	1,443 (all)	9 mo	EES versus SES resulted in similar in-segment late loss at 9 mo (0.10 mm versus 0.05 mm, P for noninferiority = 0.02). Low rates of MACE were seen in both groups.

Table 31.3 Continued

Trial Acronym and Reference	Study Cohort	EES Versus	Number Randomized (Planned Angiographic Follow-Up)	Latest Follow-Up to Date	Principal Findings
LONG-DES-III ⁹⁶	Long (≥ 25 mm) native coronary lesions	SES	450 (all)	9 m	EES versus SES resulted in higher in-segment late loss (0.17 mm versus 0.09 mm, $P = 0.046$), but similar in-stent late loss and in-stent binary restenosis as well as other clinical endpoints at 9 mo.
ESSENCE-DIABETES ⁹⁸	Diabetes	SES	300 (all)	1 y	EES versus SES resulted in lower 8-mo angiographic in-segment late loss (mean 0.23 mm versus 0.37 mm, $P = 0.02$) and lower binary restenosis (0.9% versus 6.5%, $P = 0.04$). There were no differences in clinical outcomes between the two stents.
RESOLUTE All-Comers ^{84,97}	Unselected patients	ZES(R)	2,292 (460)	2 y	EES versus ZES(R) resulted in comparable 1-y rates of TLF (8.3% versus 8.2%, $P = 0.92$) and TLR (3.4% versus 3.9%, $P = 0.50$), although less definite stent thrombosis (0.3% versus 1.2%, $P = 0.01$) and definite/probable stent thrombosis (0.7% versus 1.6%, $P = 0.05$) were noted at 1 y. At 2 y, similar rates of clinical endpoints were observed, with a trend toward less definite/probable stent thrombosis (1.0% versus 1.9%, $P = 0.077$).
TWENTE ⁹⁸	Unselected patients	ZES(R)	1,391 (none)	1 y	EES versus ZES(R) resulted in similar rates of TVR (8.1% versus 8.2%, $P = 0.94$) and other clinical endpoints including stent thrombosis at 1 year.
PLATINUM ⁹⁹	1 or 2 de novo native lesions	Pt-Cr EES	1,530 (none)	1 y	EES versus Pt-Cr EES resulted in similar rates of TLF (2.9% versus 3.4%, $P = 0.60$) as well as other clinical endpoints at 1 y.

EES, everolimus-eluting stents (Xience V/Promus); BMS, bare-metal stents; PES(E), paclitaxel-eluting stents (Taxus Express platform); PES(L), paclitaxel-eluting stents (Taxus Liberté platform); ZES(R), zotarolimus-eluting stents (Resolute platform); Pt-Cr EES, platinum chromium EES; CAD, coronary artery disease; MVD, multivessel disease; MI, myocardial infarction; TLR, target lesion revascularization; TVR, target vessel revascularization; TLF, target lesion failure (cardiac death, target-vessel MI, or TLR); TVF, target vessel failure (cardiac death, MI, or TVR); MACE, major adverse cardiac events (cardiac death, MI, or TLR).

to SES. Excepting this trial's results, whether clinically apparent efficacy differences between EES and SES are manifest in the highest-risk patient and lesion subsets remains unknown.

One intriguing attribute of EES that has emerged is the low rate of stent thrombosis observed with this stent. First demonstrated in SPIRIT IV and COMPARE, these findings have also been validated in several other studies, summarized in a metaanalysis of 13 randomized EES trials ($N = 17,101$) that demonstrated lower rates of ST with EES compared to non-EES DES.¹⁰⁰ These data, combined with further observational validation of these findings,¹⁰¹ support the use of the second-generation EES over previously existing first-generation DES with respect to a safety advantage (in addition to efficacy). Further, whether EES can achieve lower or noninferior overall rates of stent thrombosis compared to BMS is an area of active interest, piqued by both preclinical data as well as studies such as the randomized EXAMINATION trial of 1,504 patients with ST-segment elevation myocardial infarction (STEMI),⁹⁹ in which the rate of definite/probable stent thrombosis at 1 year was significantly lower in EES-treated patients compared to those treated with BMS (0.9% versus 2.6%; $P = 0.01$). Similarly, in a large network metaanalysis of head-to-head DES trials (49 trials, $N = 50,844$), the use of EES was associated with statistically significant reductions in 1- and 2-year stent thrombosis compared to other DES, as well as BMS.¹⁰² Whether EES can definitely reduce stent thrombosis compared to BMS is being actively tested in the randomized controlled HORIZONS-II trial.

Another iteration of EES has involved the use of everolimus eluted by the same stable fluoropolymer as in the original EES, but on a platinum chromium stent platform (Promus Element, Boston Scientific, Natick, MA). This stent was evaluated in the randomized PLATINUM trial,⁹⁹ which randomized 1,530 patients undergoing PCI of one or two de novo native lesions to treatment with the standard EES versus the Promus Element stent. The rates of efficacy and safety outcomes were very similar with both stents in this trial, which ultimately led to FDA approval of this EES platform.

In summary, in a broad cross-section of patients undergoing PCI, EES have shown significant improvements in safety and efficacy outcomes over first-generation DES. The finding of lower rates of stent thrombosis with EES, particularly compared to predecessor DES systems and in some cases even compared to BMS is notable, and suggests that this stent may have set a new standard for DES safety, if these findings can be further validated in larger adequately powered clinical trials.

Zotarolimus-Eluting Stents

Endeavor

Although studied contemporaneously with first-generation SES and PES, the zotarolimus-eluting Endeavor stent (ZES(E), Medtronic, Santa Rosa, CA) was originally conceived as a "second-generation DES," rapidly eluting zotarolimus (10 µg per 1 mm stent length) from a thin layer (5.3 µm) of

the biocompatible polymer phosphorylcholine from a flexible, low-profile (91 µm strut thickness) cobalt chromium stent. Phosphorylcholine is a naturally occurring phospholipid found in the membrane of red blood cells, and is resistant to platelet adhesion.¹⁰³ The potencies of zotarolimus, everolimus, and sirolimus are roughly comparable, and zotarolimus is somewhat more lipophilic. However, the release rate of zotarolimus from Endeavor (~90% within 7 days, 100% within 30 days) is significantly faster than everolimus and sirolimus are released from EES and SES stents respectively.

In the Endeavor I FIM study,¹⁰⁴ ZES(E) was demonstrated to have a low rate of TLR (1%), despite a mean in-stent late lumen loss of 0.61 mm at 12 months. The ZES(E) was subsequently compared to its base BMS in the ENDEAVOR II randomized trial,^{105,106} conducted in 1,197 patients with noncomplex lesions. In this trial, ZES(E) was associated with lower rates of TVF and TLR at 9 months compared to BMS; these results were sustained at follow-up up to 5 years. Once again, 9-month angiographic in-stent late loss (at 0.61 mm) in this trial was greater than previously seen with either SES or PES, but compared to BMS, in-segment binary restenosis was reduced from 35.0% to 13.2% ($P < 0.0001$).

A series of head-to-head DES studies in the ENDEAVOR clinical trial program was launched with a 436-patient angiographic trial, ENDEAVOR III, which was designed to demonstrate noninferiority of ZES(E) to the Cypher SES. In this trial, the amounts of late loss and rate of restenosis at angiographic follow-up were significantly greater with ZES(E) compared to SES.¹⁰⁷ Despite these findings, the overall rates of clinical restenosis endpoints were not dissimilar between treatment arms in this trial, and as such, the larger ENDEAVOR IV trial ($N = 1,548$) was conducted with a primary clinical endpoint (rather than an angiographic one). In this trial, which randomized patients with noncomplex coronary lesions to treatment with ZES(E) versus PES, despite greater late loss and angiographic restenosis with ZES(E) compared to PES, ZES(E) had noninferior 9-month rates of TVF and comparable 12-month rates of TLR.⁴¹ Rates of TLR were lowest and in fact indistinguishable between both stents particularly among patients who were assigned to receive clinical follow-up alone (rather than routine angiographic follow-up) (Figure 31.9), emphasizing a somewhat "artificial" clinical trial phenomenon previously described as the "oculostenotic reflex".¹⁰⁸ The ENDEAVOR IV findings ultimately led to device approval of ZES(E) in the United States. The 5-year follow-up of this trial has been recently presented,¹⁰⁹ demonstrating comparable rates of TLR for ZES(E) compared with PES (7.7% versus 8.6%; $P = 0.70$). More notably, the ZES(E) demonstrated a superior late safety profile with lower very late stent thrombosis (0.4% versus 1.8%; $P = 0.012$) and a lower overall incidence of cardiac death or MI (6.4% versus 9.1%; $P = 0.048$) compared to PES at 5 years.

Several trials have compared ZES(E) to other DES in unrestricted patient populations. In the SORT OUT III trial,¹¹⁰ a trial notable for a design that employed follow-up through a nationwide clinical registry in Denmark, 2,333 patients

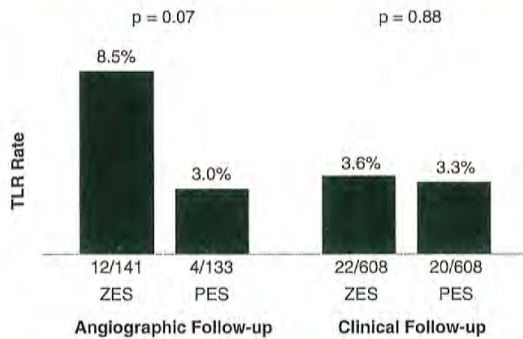


Figure 31.9 Rates of target lesion revascularization in the ENDEAVOR IV trial according to the performance of angiographic follow-up. The differences between stents are minimized among the majority of patients undergoing clinical follow-up alone. TLR, target lesion revascularization; ZES, zotarolimus-eluting stent; BMS, bare-metal stent.

(nearly 50% of whom presented with acute coronary syndromes) were randomized to ZES(E) versus SES. In this trial, treatment with ZES(E) was associated with higher rates of 9-month major adverse cardiac events (MACE: cardiac death, MI, or TVR: 6% versus 3%, $P = 0.0002$), as well as endpoints of MI, stent thrombosis, and TLR, differences which persisted at 18 months (with the exception of stent thrombosis). The ISAR-TEST-2 trial was a three-way 1:1:1 randomized trial in 1,007 patients of an investigational combination sirolimus/probucol-eluting stent versus ZES(E) versus SES.^{111,112} Compared to SES, ZES(E) resulted in higher rates of late loss, angiographic restenosis (the primary endpoint), and TLR at 6 to 8 months, with similar rates of death, MI, and stent thrombosis. A larger study, the ZEST trial, randomized 2,645 patients with simple and complex coronary artery disease to ZES(E), SES, or PES.^{113,114} In this trial, while SES demonstrated the lowest degree of late loss and binary restenosis, ZES(E) was intermediate between SES and PES with respect to rates of MACE, TVR, and TLR. There were no significant differences in the 2-year rates of death, MI, or stent thrombosis between the two stents.

Overall, both the pivotal approval trials within the ENDEAVOR clinical program as well as the investigator-initiated clinical trials of ZES(E) demonstrate lesser neointimal suppression with this stent compared to either SES or PES, resulting in lesser performance of this stent with respect to angiographically measured trial endpoints. However, ZES(E) is clearly superior in efficacy to BMS, and likely comparable to other stent platforms in reducing clinical restenosis in less complex lesions, particularly in the absence of routine angiographic follow-up. The findings of very low rates of late adverse safety events including very late stent thrombosis as

well as cardiac death or MI¹¹⁵ with ZES(E) is a notable positive attribute of this stent, particularly in light of the potential ongoing thrombotic risks of SES and PES.¹¹⁶ In this regard the large, randomized PROTECT trial has completed enrollment of 8,800 patients to ZES(E) versus SES, and is the first clinical DES study powered to demonstrate a difference in stent thrombosis between two stent platforms (with ascertainment of the primary endpoint at 3 years).

Resolute

The Resolute stent (Medtronic Inc.) is similar to the Endeavor stent in that zotarolimus is eluted from the thin-strut cobalt-alloy BMS platform (in this case, the updated and more deliverable Integrity cobalt-alloy BMS). However, instead of the phosphorylcholine coating of the Endeavor stent, the Resolute stent employs the BioLinx tripolymer coating, consisting of a hydrophilic endoluminal component and a hydrophobic component adjacent to the metal stent surface. This polymer serves to slow the elution of zotarolimus, such that 60% of the drug is eluted by 30 days and 100% by 180 days, making this the slowest rapamycin analogue-eluting DES.

In the single-arm RESOLUTE trial, ZES(R),¹¹⁷ the primary endpoint of in-stent late lumen loss at 9-months was 0.22 mm, and the in-segment binary restenosis rate was 2.1%, both significantly less than seen with other studies of ZES(E) or BMS. Low rates of MACE, TLR, and ARC definite/probable stent thrombosis were observed. Two-year data from this study have demonstrated TLR, TVR, and TVF rates of 1.4%, 1.4%, and 7.9%, respectively, with no late stent thrombosis events.¹¹⁸

The large RESOLUTE All-Comers randomized trial of ZES(R) versus EES was conducted in 2,292 patients⁹⁴; this trial sought to enroll a more unselected patient population than in prior pivotal DES trials. The rate of the primary endpoint of TLF at 1 year was similar to ZES(R) and EES (8.2% versus 8.3%, P for noninferiority < 0.001). In this trial, the rates of death, cardiac death, MI, and TLR were similar with both stents, but both definite and definite or probable stent thrombosis occurred less frequently with EES at 1 year. In-segment late loss at 13 months (after ascertainment of the primary clinical endpoints) was slightly greater with ZES(R) compared to EES (0.15 mm versus 0.06 mm, $P = 0.04$), but there were no differences in rates of binary restenosis among the 460 patients undergoing angiographic follow-up. At 2 years, similar rates of clinical endpoints including TLF, TVF, MI, TLR, and TVR were observed, with a trend toward less stent thrombosis with EES (1.0% versus 1.9%, $P = 0.077$), predominantly driven by events within the first year.⁹⁷ Three patients in each group (0.3%) had very late stent thrombosis (thrombosis occurring beyond 1 year). One additional investigator-initiated randomized trial of ZES(R) and EES has been reported; in the TWENTY trial⁹⁸ 1,391 unselected patients were randomized between these two stents. Notably, "off-label" indications occurred in $>75\%$ of patients enrolled. At 1 year, the primary endpoint of TVF was similar with both

stents (8.1% versus 8.2%, $P = 0.94$), with no observed differences in other clinical endpoints, including stent thrombosis (definite/probable: 0.9% for ZES(R) versus 1.2% for EES).

In summary, the ZES (Resolute platform) is the first stent to demonstrate comparable overall safety and efficacy to the EES, although slight differences in angiographic and clinical outcomes between these stent platforms may exist. Larger studies and longer-term follow-up are required to assess whether these device-specific performance characteristics influence outcomes in actual clinical practice, and whether the long-term safety of this stent is maintained.

Biolimus A9-Eluting Stents (BioMatrix)

The BioMatrix (Biosensors International, Switzerland) stent (BES) elutes biolimus A9 (concentration 15.6 $\mu\text{g}/\text{mm}$), a semi-synthetic rapamycin analogue with similar potency but greater lipophilicity than sirolimus, from a stainless steel platform. The stent platform that originally was the S-stent is currently the Juno BMS platform, in the BioMatrix Flex iteration of BES. Of note, the Nobori DES (Terumo Medical Corporation, Japan) is a similar BES that releases biolimus using the same polymer system with a different BMS platform. The Nobori DES has demonstrated favorable results compared to PES and SES in three modest-sized randomized trials.¹¹⁹⁻¹²¹ BES are unique, especially compared to the previously described first- and second-generation DES, in that biolimus A9 is eluted from PLLA, a biodegradable polymer which is applied solely to the abluminal stent surface. The biolimus A9 and PLLA are coreleased, and the polymer is converted via the Krebs cycle into carbon dioxide and water after a 6- to 9-month period. Conceptually, such a stent might not be prone to late inflammatory reactions as are occasionally seen with durable polymers, and thus result in improved outcomes after 1 year.

The BioMatrix BES was first tested in the randomized STEALTH trial in which 120 patients with single de novo coronary lesions received either a BES or a bare-metal S-stent.¹²² Treatment with BES resulted in lower in-stent late loss at 6 months (0.26 mm versus 0.74 mm for BMS, $P < 0.001$). The largest trial examining the safety and efficacy of BES was the LEADERS trial, which randomized 1,707 "all-comer" patients (55% of whom had acute coronary syndromes) to BES versus SES.¹²³ Similar rates of all clinical endpoints were observed at 9 months with both BES and SES, including the primary study endpoint, which was the composite of cardiac death, MI, or TVR (9.2% versus 10.5%, $P = 0.39$). Among the 427 patients allocated to angiographic follow-up at 9 months, in-stent late loss and binary restenosis were similar with both stents. Longer-term follow-up of LEADERS to 4 years has been recently reported (Figure 31.10).¹²⁴ Over the entire follow-up period, the rate of the composite primary endpoint of cardiac death, MI, or clinically indicated TVR was lower with BES compared to SES (19% versus 23%, $P = 0.039$), with gradual separation of respective event curves over time. Additionally, while overall definite/probable stent thrombosis rates were not significantly different (3% for BES versus 5% for SES, $P = 0.20$), the rate of very late definite/probable stent thrombosis was significantly lower with BES (6 events (1%) versus 20 events (2%), $P = 0.005$). Similar results were observed when assessing the endpoint of definite stent thrombosis.

Collectively, these data demonstrate that BES has similar efficacy as the first-generation devices, with a favorable safety profile that emerges particularly beyond 1 year. However, much larger and adequately powered studies will be required to determine whether BES, or other devices with bioabsorbable polymers, offer true and sustained clinical advantages to the best-in-class second-generation DES with durable polymers. Several studies investigating these hypotheses are ongoing.

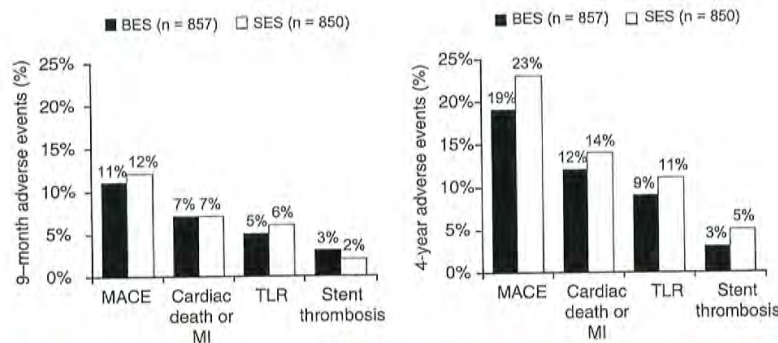


Figure 31.10 Principal clinical endpoints at 1 year (left) and 4 years (right) from the randomized all-comers LEADERS trial of a biolimus A9-eluting stent compared to a sirolimus-eluting stent. BES, biolimus A9-eluting stent; SES, sirolimus-eluting stent; MACE (major adverse cardiac events) denotes cardiac death, myocardial infarction (MI), or clinically indicated target vessel revascularization; stent thrombosis refers to Academic Research Consortium (ARC) definite or probable events.

CONCERNS REGARDING SAFETY OF DRUG-ELUTING STENTS AND POOLED COMPARISONS OF DRUG-ELUTING STENTS AND BARE-METAL STENTS

The evidence base for initial DES approvals by the FDA consisted primarily of randomized controlled trials enrolling largely stable patients with relatively noncomplex, single, de novo coronary artery lesions. Data from these early studies demonstrated similar rates of death and MI among DES and BMS-treated patients.^{39,125} Yet, due to their potent efficacy, DES are used “off label” (in higher-risk patients and in more complex lesions) in 60% to 70% of cases,¹²⁶ leading to concerns about the safety and appropriateness of the routine use of DES in the “real world.” Moreover, most randomized studies (especially those conducted early in the DES era) included primary outcomes of interest that focused upon stent efficacy, rather than absolute safety. As such, evidence of the safety of DES has come from two sources—randomized controlled trials, which are usually small to modest in size, and typically underpowered to assess safety endpoints such as death, MI, and stent thrombosis, as well as large-scale observational

studies, which provide a broader look at the real-world use of DES and allow more generalizability and power.

A number of analyses have amalgamated trial data across clinical studies to increase overall sample size. In particular, these studies have attempted to address one of the prominent limitations of individual DES studies, namely the limited power to detect differences in low-frequency safety endpoints. In the largest and most comprehensive metaanalysis of first-generation DES versus BMS studies (including 9,470 patients from 22 randomized trials and 182,901 patients from 34 observational studies), the use of DES in randomized trials was associated with comparable rates of mortality and MI, with a 55% relative reduction in TVR (Figure 31.11).³⁹ In the observational studies included separately in this analysis (Figure 31.12), significant heterogeneity was observed, and treatment with DES was in fact associated with significant reductions in overall death, MI, as well as TVR. The differences observed between the findings of randomized trials and observational studies included in this analysis highlight the difficulty in assessing nonrandomized active treatment comparisons through an observational study design. In another metaanalysis, Stettler and colleagues incorporated comparative data from SES versus BMS trials, PES versus BMS trials, and SES versus PES trials in a statistical “network” of trials to discern treatment effects across all

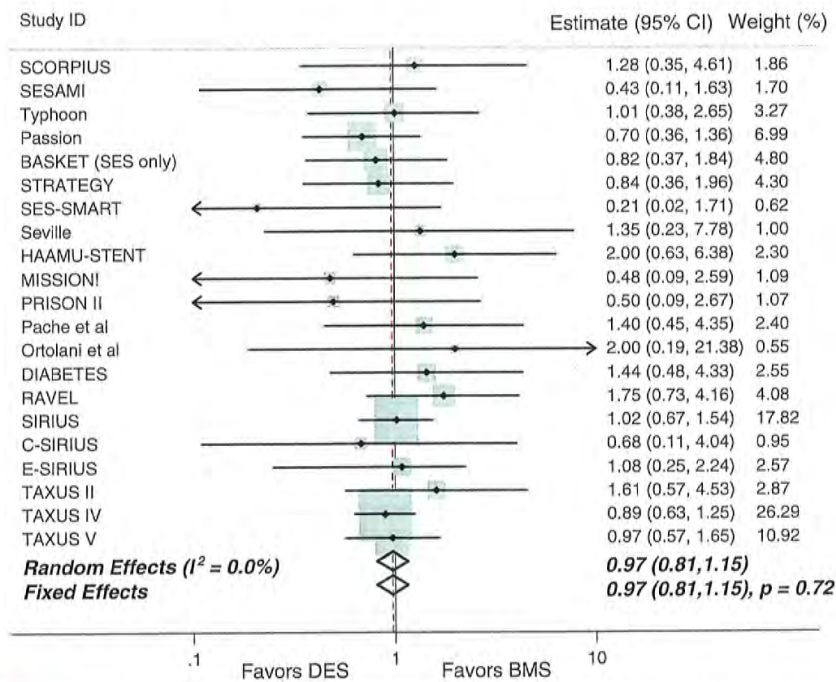


Figure 31.11 Mortality in randomized trials comparing drug-eluting stents to bare-metal stents (from Kirtane et al., *Circulation* 2009), demonstrating similar overall mortality of both stent types. DES, drug-eluting stent; BMS, bare-metal stent.

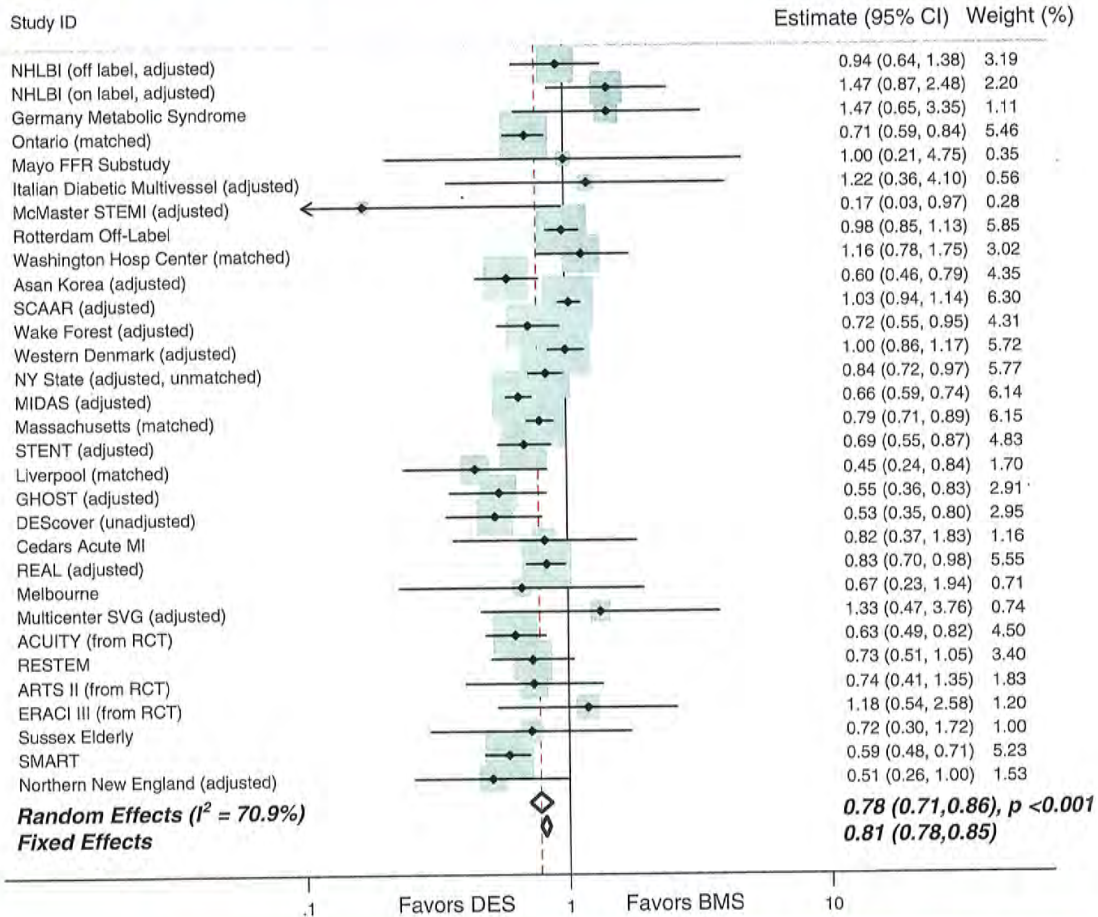


Figure 31.12 Mortality in observational studies comparing drug-eluting stents to bare-metal stents (from Kirtane et al., *Circulation* 2009), demonstrating a reduction in mortality with drug-eluting stents. DES, drug-eluting stent; BMS, bare-metal stent.

included trials.¹²⁷ In this analysis of 38 trials including data from 18,023 patients, TLR was lower with SES and PES compared to BMS, with similar mortality among patients treated with SES, PES, and BMS. In this analysis, a reduction in the hazard of MI was observed with SES compared to both BMS (hazard ratio [HR] 0.81, 95% credibility interval 0.66 to 0.97, $P = 0.030$) and PES (HR 0.83, 0.71 to 1.00, $P = 0.045$).

In addition to these and other analyses, numerous observational studies have focused upon the examination of low-frequency safety endpoints when comparing first-generation DES to BMS, across a wide range of clinical indications. More than 50 nonrandomized comparisons between DES and BMS have been published and/or presented to date. Aside from the initial publication of data from SCAAR registry¹²⁸ that was subsequently revised with the addition of longer term follow-up,¹²⁹ the majority of these studies have demonstrated

favorable safety for DES compared to BMS. For example, in the largest such analysis of DES safety, which was conducted using data from 262,700 Medicare beneficiaries in the United States, the use of DES was associated with lower rates of death (13.5% versus 16.5%, $P < 0.001$) and MI (7.5% versus 8.9%, $P < 0.001$) with minimal differences in bleeding.¹³⁰

Despite the reassuring findings from these and other observational registries of unselected DES use, it is our opinion that data from these nonrandomized comparisons of DES versus BMS should be considered exploratory at best, and potentially misleading. This opinion is based upon several factors: (1) Nonrandomized treatment comparisons are subject to significant unmeasured confounding that cannot be adequately accounted for using conventional statistical methodology; (2) Mortality reductions have never been observed in randomized trials comparing first-generation

DES to BMS; and (3) In propensity-matched observational analyses comparing DES to BMS, the majority of benefit of DES compared with BMS was evident within the first 30 days after implantation,¹³¹ a difference that does not appear to have an adequate pathophysiologic explanation. These limitations notwithstanding, the abundance of randomized trial and observational data with DES has been reassuring, demonstrating efficacy of DES in reducing clinical restenosis, and with no major safety concerns compared to BMS. As described in the earlier sections on second-generation DES, there are now emerging data demonstrating improvements in safety outcomes with ZES(E), EES, and BES compared to first-generation DES and even compared to BMS. These findings, in conjunction with superior and/or similar efficacy of second-generation DES, suggest that the comparison between the second generation DES and BMS may be hypothetically even more favorable than prior studies comparing first-generation DES to BMS. At present, however, this remains unproven as direct comparisons between second-generation DES and BMS are scant.

BIOABSORBABLE DRUG-ELUTING STENTS

All BMS and DES platforms in clinical practice today are permanent coronary prostheses. As described above, in order to mitigate adverse vascular responses to older DES, newer DES platforms have tried to achieve BMS-like biocompatibility through either inert durable polymers or bioabsorbable polymers. Building further upon this approach is the concept of a completely bioabsorbable scaffold (or bioabsorbable stent). This concept had been investigated prior to the DES era,¹³² but remained largely dormant until recent efforts to combine a bioabsorbable platform with the antirestenotic efficacy of DES.

Several bioabsorbable DES are currently undergoing clinical trials. The stent at the most advanced stage of investigation and with the most clinical data is the Bioabsorbable Vascular Solutions EES (BVS-EES, Abbott Vascular, Santa Clara, CA). The BVS-EES (Figure 31.13) is a polymeric bioabsorbable scaffold constructed of PLLA with a thin mixture of poly-D, L-lactic acid (PDLLA) that serves as the drug-carrier vehicle for everolimus at a concentration of 8.2 mcg/mm. The PDLLA enables controlled release of everolimus, with 80% elution by 30 days. The BVS-EES has an overall strut thickness of 150 μm in order to maintain structural integrity of the stent in coronary applications.

The BVS-EES was initially investigated in the ABSORB FIM study (ABSORB Cohort A) completed in 2006.¹³³ In this nonrandomized, open-label study of 30 patients receiving BVS-EES in noncomplex de novo coronary lesions, device success was 94% with a MACE rate of 3.3% (one MI event and no TLR). Although a comparative study with cobalt chromium EES demonstrated similar acute recoil with BVS-EES to EES,¹³⁴ in ABSORB, angiographic in-stent late loss was 0.44 mm, and appeared to be related in large part to late recoil of the scaffold¹³⁵ rather than neointimal hyperplasia. Nonetheless, follow-up to




Figure 31.13 Bioabsorbable Scaffold (BVS, Abbott Vascular). (Courtesy of Abbott Vascular. ©2013 Abbott. All Rights Reserved.)

5 years has demonstrated a persistently low MACE rate (3.4%) without any further occurrence of late complications.¹³⁶ After a manufacturing and design modification to the BVS-EES (in order to improve strut strength and enabling storage at room temperature), enrollment in Cohort B of the ABSORB trial ensued.¹³⁷ The Cohort B patients (total of 101 patients) represent two separate groups of patients undergoing various modes of invasive and noninvasive follow-up (including angiography, IVUS, optical coherence tomography (OCT), and multislice computed tomography) at different timepoints (6 months and 24 months, and 12 months and 36 months). The cumulative rate of MACE at 18 months was reported to be 6.7%, comprising 3 MI events and 4 TLR events.¹³⁸ There have been no observed stent thrombosis events in either cohort of the ABSORB trial. Furthermore, OCT analyses from Cohort B have demonstrated persistence of the mechanical scaffolding properties of BVS-EES despite evidence of reductions in strut core area.¹³⁹ Strut malapposition has been rare, and strut coverage occurred in almost 97% of struts at 12 months. The ongoing ABSORB EXTEND trial in up to 1,000 patients with up to two de novo coronary lesions will further expand the clinical evidence base of the BVS-EES.

Aside from the intuitive appeal of fully bioabsorbable scaffolds, other potential advantages of this technology relate to a restoration of normal arterial vasomotion and arterial function (including resolution of side branch jailing and obstruction), visualization of coronary arteries via noninvasive means, and potential facilitation of repeat interventions, if needed. These advantages would theoretically come in addition to mitigating any adverse effects of existing permanent stent platforms (both DES and BMS).

DRUG-ELUTING STENT SUMMARY

In summary, significant progress has been made with second-generation DES compared to their first-generation counterparts in terms of enhanced deliverability (through

thin-strutted cobalt alloy, cobalt-chromium, and platinum-chromium platforms), safety (including ZES(E), EES, and BES), and antirestenotic efficacy (EES, ZES(R), and BES). Ongoing and future studies with these stents as well as future third-generation DES and even bioabsorbable scaffolds are needed to determine whether these benefits will constitute further incremental improvements over BMS, particularly regarding safety.

STENT IMPLANTATION TECHNIQUE

Achieving optimal stent outcomes requires operator skill in guide catheter, guidewire, and stent selection and usage. Understanding the utility of adjunctive imaging and physiologic lesion assessment catheters (e.g., IVUS, fractional flow reserve [FFR], OCT; see Chapters 24 and 25), lesion modification devices (e.g., atherectomy, thrombectomy), and distal protection devices (see Chapter 29) is also critical to optimizing stent results. Perhaps most important, however, intimate knowledge is required regarding the appropriate indications for stent implantation versus alternative medical therapy or surgical revascularization, identification and treatment of high-risk patients and lesions, appropriate use of adjunct pharmacotherapy, and the recognition and management of stent-related complications (see Chapters 4 and 5).

Technical Aspects of Coronary Stent Implantation

Guide Catheter and Guidewire Selection

Optimal guide catheter selection is critical for the successful completion of most stent procedures and requires the operator to consider *prior to the case* the amount of backup support required and the luminal dimensions of the guide to accommodate the devices likely to be used. Stenting of noncomplex lesions is typically performed through 6F or even smaller (e.g. 5F) guiding catheters. Smaller-diameter guides, however, provide reduced backup support, a disadvantage that may necessitate active guide catheter manipulation (deep guide intubation), a technique that is usually safe when performed by experienced operators, although it may occasionally result in proximal coronary dissection requiring placement of additional stents.

If significant guide catheter backup support is anticipated (e.g., fibrocalcific or tortuous vessels, distal lesions, or chronic total occlusions [CTO]), or simultaneous delivery of multiple wires, stents, or use of atherectomy devices is planned, *larger-dimension guiding catheters* (typically 7F or 8F) or those with specialized shapes (e.g., Extra-Back Up or Voda shapes for the left coronary artery, and hockey stick or Amplatz shapes for the right coronary artery and SVGs) should be chosen. Larger guiding catheters may also

be required for stenting of bifurcation lesions when a two-stent technique that requires contemporaneous delivery of both stents is required. An alternative to larger guide sizes to increase support is the use of a "mother-daughter" technique, or coaxial deployment of a smaller catheter through an existing guide catheter system.

Floppy wires should be used for most stent implant procedures, although at least medium shaft support is required to advance most stents. More complex guide-anchoring techniques or a second parallel ("buddy") wire placed alongside the wire being used may be considered further aids to deliver the stent when difficulty advancing the stent over an extra-support wire is still encountered.

Stent Selection and Techniques to Optimize Acute and Long-Term Outcomes

Optimal stent selection and implantation technique will minimize procedural complications, reduce the risk of stent thrombosis, and enhance long-term freedom from restenosis. Key issues include selection of the appropriate stent (including stent diameter and length), implantation pressure, the decision whether to predilate versus direct stent, and whether to postdilate or implant additional stents to achieve an optimal result (Table 31.4). Balloon-expandable rather than self-expanding stents are almost universally used for coronary applications, given their simplicity and accuracy in positioning. Open cell designs are generally more trackable than closed cell stents and may be favored in tortuous vessels where conformability on bends is important or when stenting across bifurcation lesions (to reduce the risk of side branch closure and preserve side branch access). Closed cell designs, in contrast, may be desirable when uniform or optimal scaffolding is required, such as in ostial lesions. Excessive force should *never* be applied in trying to pass a stent across a rigid, nondilated lesion; such efforts are likely to be unsuccessful and increase the risk of stripping the stent from the balloon. If guide support is adequate and the stent does not easily pass across the lesion, it should be carefully withdrawn back into the guide catheter under fluoroscopic visualization and the lesion should be aggressively predilated before an attempt to readvance the stent is made.

The optimal pressure for stent implantation has been a matter of some debate. Colombo first demonstrated that high-pressure stent implantation techniques were important to achieve optimal stent expansion and to appose the stent completely to the vessel wall. Although Colombo initially achieved these results with the use of adjunctive IVUS imaging,¹² acceptable results were also demonstrated with moderate-pressure implantation techniques without IVUS imaging.¹⁴⁰ In a randomized trial of high (mean 16.9 atm) versus moderate (mean 11.1 atm) pressure for stent implantation in 934 patients, similar rates of stent thrombosis and restenosis were observed.¹⁴¹ In contrast, in a second randomized

Table 31.4 Guidelines for Optimal Stent Selection and Implantation

1. Choose the optimal stent length

- A. Ensure adequate lesion coverage while avoiding excessively long stents, as stent length is a risk factor for periprocedural myonecrosis, stent thrombosis, and restenosis.
- B. Implant the stent from normal reference to normal reference if possible (starting 2 mm before and after the lesion shoulder), which will avoid edge dissections. An edge dissection, unless mild, often requires treatment with an additional short (8–10 mm) overlapping stent.
- C. In diffusely diseased vessels, a normal reference segment often cannot be identified. The most severe atherosclerotic segments should be stented so there are no major inflow or outflow lesions proximal or distal to any stenosis. Spot stenting is likely preferable to the “full metal jacket.” Avoid stenting over potential graft anastomosis site (e.g. mid-distal LAD).
- D. For long lesions, use one long stent if possible. If multiple stents are required, they should overlap by ~2 mm to ensure complete lesion coverage but minimizing the total length of overlap.

2. Choose the optimal stent diameter

- A. Size the stent diameter with a ratio of 1.0–1.1:1 to the *distal* reference vessel diameter. Be cognizant that the size of the distal vessel can be underestimated due to proximal severe disease or spasm (e.g. in the setting of acute myocardial infarction).
- B. If the vessel is tapering, a larger noncompliant balloon can then be used to more fully expand the proximal stent segments.
- C. Be aware that within the same stent line, different-sized stents exist for different-diameter vessels. Oversizing stents designed for small vessels will lead to inadequate scaffolding and possibly strut fracture.

3. Predilatation versus direct stenting

- A. Direct stenting may be considered when guide catheter support is good to excellent. Lesions not generally amendable for direct stenting include those with excessive vessel or lesion tortuosity or calcification, diffuse disease or subtotal stenoses, bifurcations, acute myocardial infarction, or chronic total occlusions. While direct stenting is faster than predilatation prior to stenting, recognition of the potential for inadequate expansion is critical prior to deploying a stent that then cannot be expanded, which is a major risk factor for stent thrombosis and/or restenosis.
- B. If direct stenting is not feasible, predilatation should be performed with balloons undersized to the reference diameter by 0.5 mm, and with length shorter than the lesion so as to not extend the length of stenosis requiring stenting. If this degree of predilatation does not allow stent passage, larger and/or higher-pressure balloon inflations may be required.

4. Implant and postdilate the stent at adequate pressure

- A. Most stents (except those mounted on a very compliant delivery system) should be implanted using at least 12 atm of inflation pressure.
- B. Higher routine implantation pressures and/or requisite high-pressure postdilation with a noncompliant balloon (16–18 atm or greater) are preferred by many to optimize stent expansion and are often required in fibrocalcific lesions.
- C. In diffusely diseased vessels, consider implanting the stent at 10–12 atm to avoid edge dissections, and then postdilate the stent at higher pressures using a short noncompliant balloon positioned within the stent margins.

5. Strive for an optimal angiographic stent result, defined as

- A. A residual stenosis <10%
- B. No edge dissection greater than NHLBI type A
- C. TIMI grade 3 flow
- D. Patency of all side branches ≥ 2.0 mm in diameter
- E. Absence of distal thromboemboli, perforation, or other angiographic complications with associated chest pain, electrocardiographic changes, or hemodynamic instability

NHLBI, National Heart, Lung, and Blood Institute; TIMI, Thrombolysis in Myocardial Infarction.

trial, routine high-pressure (17.0 atm) versus low-pressure (9.9 atm) stent implantation resulted in greater initial and 6-month follow-up minimal stent cross-sectional areas.¹⁴²

More important than the actual deployment pressure is the overall degree of expansion of the stent itself. Inadequate stent expansion has been linked to both stent thrombosis as well as restenosis.^{75,143,144} The use of compliance charts supplied by stent manufacturers can be misleading, as they reflect *ex vivo* sizing; *in vivo*, stent size is determined not only by the inflation pressure but also by the compliance of the vessel, and systematic undersizing of stents has been observed when stents are assumed to be sized based upon manufacturers' compliance charts.¹⁴⁵ Complete lesion coverage without edge dissections is also believed to be important, as is the elimination of inflow and outflow stenoses that can compromise flow and lead to stent thrombosis. Implantation of additional short stents may be required to cover edge dissections and achieve optimal lumen dimensions.¹⁴⁶ With optimal stent implantation technique, stent thrombosis should occur in no greater than 1% of patients.¹⁴⁷ Although routine high-pressure stent implantation and high balloon-to-artery ratios result in greater stent expansion and optimize late outcomes, care must be taken to avoid edge dissections and perforation.

The use of adjunctive imaging technologies including IVUS and OCT (see Chapter 25) can often be helpful to the operator in real time. These invasive imaging technologies facilitate the accurate assessment of true (media-to-media) vessel size prior to stent implantation, and can be useful post deployment in assessing how well the stent has expanded and whether there is any malapposition of stent struts. The prospective data on the use of IVUS-guided stent implantation, however, is mixed,¹⁴⁸⁻¹⁵¹ partially due to the high level of experience of operators enrolling in trials of IVUS-guidance (these operators' stent implantation techniques are often modified even in the *absence of IVUS* based upon their knowledge of IVUS-based parameters of stent implantation). There are emerging data on the use of other imaging technologies including OCT as an adjunct to stent implantation. At present, IVUS (and/or OCT) is currently used in <10% of patients undergoing stent implantation in the United States, a reflection of the learning curve this technique requires, difficulties in incorporating the information IVUS provides into treatment decisions, logistic issues, and lack of widespread reimbursement.

Like adjunctive imaging technologies, physiologic lesion assessment (measurement of either coronary flow reserve or FFR) has utility during coronary stent implant procedures (see Chapter 24). FFR can be used to identify the hemodynamic significance of intermediate lesions, thereby providing direct physiologic evidence to the operator who can then address the suitability of the lesion for treatment.^{152,153} The use of an FFR-guided strategy of stent implantation for patients with multivessel disease has been shown to improve outcomes over an angiography-alone guided strategy in a randomized clinical trial.¹⁵⁴ The use of FFR in the FAME trial was not only

associated with a lower rate of adverse events, but was also less costly due to a greater number of deferred lesions in the FFR-guided group.¹⁵⁵ FFR can also be used to determine the adequacy of stent implantation; an FFR of < 0.95 correlates with an underdeployed stent by IVUS.¹⁵⁶ Finally, FFR may also be useful in provisional stenting approaches to identify cases where distal or side-branch disease may be left alone, thereby avoiding the use of an additional stent.¹⁵⁷

Role of Plaque Modification Prior to Coronary Stent Implantation

The amount of plaque present prior to and after stent implantation has been shown to be a strong determinant of subsequent restenosis,¹⁵⁸ leading to the hypothesis that plaque debulking using either directional or rotational atherectomy devices prior to stenting would enhance event-free survival. Similarly, the circumferential extent of calcium is a strong determinant of inadequate stent expansion,¹⁵⁹ and pilot studies initially demonstrated greater stent dimensions when stenting was preceded by high-speed rotational atherectomy.^{160,161} Unfortunately, randomized trials have been unable to demonstrate improved clinical or angiographic outcomes with atherectomy prior to stent implantation compared with stenting alone,^{162,163} particularly in light of the profound effects of DES on reduction of restenosis.

At present, rotational atherectomy prior to stenting is used in "niche" indications, primarily to treat heavily calcified lesions or those resistant to balloon crossing or predilatation. In these cases, if rotational atherectomy is applied safely and with good operator technique, this technique can markedly improve the deliverability of coronary stents to the target lesion. Directional atherectomy may still play a role in selected cases of stenting in ostial, bifurcation, or left main lesions to reduce plaque shift and subsequent side-branch compromise (see Chapter 29), but at present, this technique is reserved almost exclusively for the treatment of peripheral arterial lesions (see Chapter 34). Similarly, the major contemporary role for excimer laser angioplasty is in the treatment of peripheral arterial lesions and in rare cases for recalcitrant coronary lesions or refractory stent underexpansion.

COMPLICATIONS OF CORONARY STENTING

Stent Thrombosis

The most feared complication following stent placement is stent thrombosis, which while fortunately rare (occurring in ~0.5% to 1% of patients within 1 year), in more than 80% of patients presents as acute MI. Treatment for stent thrombosis is almost always emergent repeat PCI, although optimal reperfusion is only achieved in two-thirds of patients.¹⁶⁴ As a result, stent thrombosis has been associated with 30-day

mortality rates of 10% to 25%.^{165,166} Moreover, approximately 20% of patients with a first stent thrombosis experience a recurrent stent thrombosis episode within 2 years.¹⁶⁷ Thus, understanding and preventing this complication is of paramount importance.

The most widely utilized definition and timing classification of stent thrombosis was developed by the Academic Research Consortium (ARC),¹⁶⁸ with definite or probable stent thrombosis considered the best tradeoff between sensitivity and specificity (Table 31.5). Stent thrombosis is also classified as primary if it is directly related to an implanted stent, or secondary if it occurs at the stent site after an intervening TLR event. Primary stent thrombosis after BMS typically occurs within the first 30 days after implantation, although rarely can occur later.¹⁶⁹ In contrast, primary stent thrombosis after DES can occur years afterward, with an annual incidence of 0.2% to 0.3% in patients with noncomplex coronary artery disease,^{170,171} and 0.4% to 0.6% after unrestricted use, particularly with first-generation DES (Figure 31.14).^{101,116} Thus, primary stent thrombosis rates during long-term follow-up are higher with most DES than BMS, with the differences emerging predominately beyond the first year after implant.¹⁷² However, after taking into account secondary stent thrombotic events after TLR procedures for restenosis (which occur more commonly after BMS than DES), the overall incidence of stent thrombosis (primary plus secondary) does not seem to be increased with DES compared to BMS,¹⁷³ and the overall late rates of death and MI have been similar with DES and BMS.³⁹ From a clinical perspective, the benefits of DES in reducing restenosis and subsequent MACE have been demonstrated to offset the small excess risk of late primary stent thrombosis with DES in an analysis of patients enrolled in the pivotal PES approval trials.¹⁷⁴ Additionally, given the results

of longer-term follow-up with second-generation devices including EES, ZES(E), and BES, which have demonstrated low rates of stent thrombosis compared to first-generation DES, whether these devices have the ability to further reduce stent thrombosis rates compared to BMS¹⁰² is an area of active investigation.

The mechanisms underlying stent thrombosis are multifactorial (Table 31.6), and include patient-related factors, procedural factors (including stent choice), and postprocedural factors (including type and duration of antiplatelet therapy).¹⁷⁵ Stent thrombosis occurs more frequently in complex patients and lesions, especially in patients with acute coronary syndromes and thrombotic lesions, diabetes, renal insufficiency, diffuse disease, small vessels, and bifurcation lesions requiring multiple stents.^{147,165,166,176-178} Variability in the antiplatelet response to clopidogrel (either identified through loss-of-function mutations to the enzyme responsible for conversion of clopidogrel to its active metabolite¹⁷⁹ or through testing of platelet responsiveness¹⁸⁰) has been identified as an independent risk factor for early stent thrombosis. While more potent dual antiplatelet therapies such as higher-dose clopidogrel, prasugrel, or ticagrelor can reduce the incidence of stent thrombosis, particularly in those at risk for resistance,¹⁸¹⁻¹⁸³ these regimens are also associated with a greater risk of bleeding complications, and their use in unselected patients undergoing PCI is at present unproven.¹⁸⁴ It is thus essential to carefully consider the individual patient's risk of stent thrombosis (and MI) compared to bleeding before using these regimens.

Procedural factors associated with stent thrombosis include the stent type selected (whether BMS or DES, and even the specific DES used), as well as whether the stent is adequately expanded and apposed to the vessel wall and is

Table 31.5 Academic Research Consortium Definitions of Stent Thrombosis

Classification	
Definite	An acute coronary syndrome with angiographic or autopsy evidence of thrombus or occlusion within or adjacent to a stent.
Probable	Unexplained death within 30 d after stent implantation or acute myocardial infarction involving the target-vessel territory without angiographic confirmation.
Possible	Any unexplained death beyond 30 d after the procedure.
Timing	
Acute	Within 24 h (excludes events within the catheterization laboratory)
Subacute	1–30 d
Early	Within 30 d
Late	30 d–1 y
Very late	After 1 y

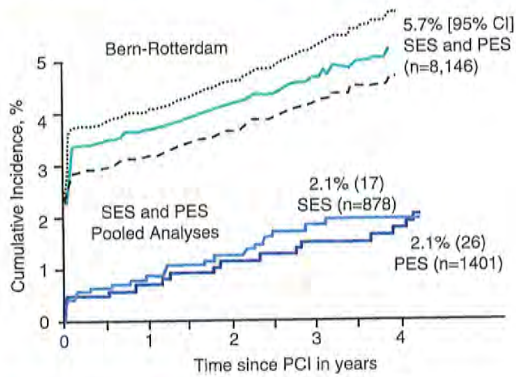


Figure 31.14 Cumulative Incidence of ARC Definite/Probable Stent Thrombosis over 4 years after first-generation drug-eluting stents. Data are shown from pivotal “on-label” analyses (denoted by “SES and PES pooled analyses,” Mauri et al., *NEJM* 2997) as well as from unselected use from two clinical centers (denoted by “Bern-Rotterdam,” Wenaweser et al., *JACC* 2008). SES, sirolimus-eluting stent; PES, paclitaxel-eluting stent.

placed in a vessel with sufficient “runoff” to support adequate flow through the stent.¹⁸⁵⁻¹⁸⁷ Hypersensitivity reactions to the DES polymer and vascular inflammation have been associated with stent thrombosis.^{52,188} Some DES polymers (particularly those not specifically designed for biocompatibility) may be inherently thrombogenic, and prone to webbing and peeling, serving as a nidus for thrombosis. Strut fractures (which occur most commonly with stainless steel closed cell stent designs, such as SES, especially with overlapping stents in the right coronary artery^{189,190} have been pathologically and occasionally clinically linked to stent thrombosis.¹⁹¹ Whether late acquired stent malapposition is a cause of late stent thrombosis, or merely a reflection of underlying vascular toxicity to the drug or polymer with positive vessel remodeling is uncertain.^{192,193} It is also uncertain whether malapposition alone (in the absence of underexpansion) is a determinant of late stent thrombosis. The most commonly proposed explanation underlying the increased rate of very late primary stent thrombosis with DES compared to BMS is delayed or absent endothelialization of stent struts. Virmani et al. first observed from autopsy studies that BMS strut endothelialization is 100% complete by 6 months, whereas DES never achieve >50% endothelial cell strut coverage, even beyond 3 years after implantation.¹⁹⁴ Similar findings have been reported in vivo with angiography¹⁹⁵ as well as by OCT.⁵⁵ Finally, a recently reported observation is that some cases of very late stent thrombosis may be due to the development of neoatherosclerosis within stents with new plaque rupture.¹⁹⁶

The rates of stent thrombosis may be decreasing with improvements in stent technology, imaging, and adjunct pharmacology. A large nonrandomized propensity-controlled study has suggested that IVUS guidance may reduce stent thrombosis at both 30 days and 1 year.¹⁹⁷ As discussed above, less reactive and biocompatible polymers and improvements in stent design have significantly reduced the rates of early (EES) and late (EES, ZES(E), and BES) stent thrombosis. The role of potent antiplatelet therapy for the prevention of stent thrombosis, particularly in the early phase, is well established.^{13-16,198-200} While observational studies have uniformly documented that premature thienopyridine discontinuation within 6 months after DES placement is strongly associated with stent thrombosis,^{201,202} whether prolonged dual antiplatelet therapy beyond this time reduces stent thrombosis and/or death and MI is unknown, with some studies in support of this hypothesis²⁰²⁻²⁰⁴ and others against.^{201,205} In this regard the potential benefits of prolonged dual antiplatelet therapy, including the prevention of stent-related and non-stent atherosclerosis-related adverse events must be weighed against the persistent risk of ongoing major bleeding with combination therapy.

Three published randomized trials have tested this hypothesis (Figure 31.15). In the pooled REAL-LATE/ZEST-LATE trial, 2,701 patients who were MACE-free for at least 1 year after DES (SES, PES, or ZES) were randomized to an additional 2 years of clopidogrel along with aspirin or aspirin alone.²⁰⁶ There were no significant differences between the two groups in the late occurrence of the primary endpoint or cardiac death or MI, or of definite stent thrombosis, and paradoxically the composite endpoint of all-cause death, MI, or stroke was increased with prolonged clopidogrel use. The PRODIGY trial randomized 2,013 stented patients (treated with BMS, ZES(E), SES, or PES) to 6 versus 24 months of dual antiplatelet therapy with aspirin and clopidogrel, and demonstrated similar rates of adverse ischemic events (including stent thrombosis) with both strategies, and a greater incidence of hemorrhagic complications with extended duration therapy.²⁰⁷ Finally, the EXCELLENT trial randomized 1,443 patients after DES implantation (with SES or EES) to 6 versus 12 months of dual antiplatelet therapy, and also demonstrated similar rates of ischemic events, including stent thrombosis, with both strategies.²⁰⁸ The event rates from each of these studies, however, are small, and therefore none of these studies are adequately powered to demonstrate definitively the most optimal duration of dual antiplatelet therapy following DES implantation. Several additional randomized trials are ongoing to address the relative safety and efficacy of prolonged dual antiplatelet therapy, the largest and most meaningful of which is the Dual Antiplatelet Therapy (DAPT) Study, in which 20,645 patients free from MACE 1 year after SES, PES, EES, or ZES implantation are being randomized to aspirin alone or aspirin plus a thienopyridine (either clopidogrel or prasugrel), with follow-up for an additional 18 months.²⁰⁹

Table 31.6 Potential Mechanisms of Stent Thrombosis

Patient-related factors relating to increased thrombogenicity:

- Smoking
- Diabetes
- Chronic kidney disease
- Acute coronary syndrome presentation
- Thrombocytosis
- High posttreatment platelet reactivity
- Premature discontinuation or cessation of dual antiplatelet therapy
- Surgical procedures (unrelated to the PCI)

Lesion-based factors relating to adverse rheology/thrombogenicity within stents:

- Diffuse coronary artery disease with long-stented segments
- Small vessel disease
- Bifurcation disease
- Thrombus-containing lesions
- Significant inflow or outflow lesions proximal or distal to the stented segment

Stent-related factors:

- Poor stent expansion
- Edge dissections limiting inflow or outflow
- Delayed or absent endothelialization of stent struts
- Thicker stent struts
- Hypersensitivity/inflammatory and/or thrombotic reactions to specific DES polymers (N.B. specific polymers may have a protective effect)
- Strut fractures
- Late malapposition/aneurysm formation
- Development of neoatherosclerosis within stents with new plaque rupture

Treatment of Stent Thrombosis

Prompt reperfusion is critical when treating stent thrombosis, particularly when it presents as acute ST-elevation MI. While stent thrombotic events can be treated with fibrinolytic therapy, emergent PCI is typically the rule. Stent thrombosis may be treated with emergent thrombectomy (either aspiration or mechanical) or with balloon angioplasty alone, often in conjunction with administration of more potent antiplatelet regimens including glycoprotein IIb/IIIa inhibitors.²¹⁰ The placement of additional stents should usually be avoided unless a mechanical reason for the initial thrombotic event is ascertained (e.g. edge dissection or residual untreated disease). The use of adjunctive imaging such as IVUS or OCT will often reveal a possible cause of stent thrombosis, such

as stent underexpansion or malapposition, residual dissection, or significant inflow or outflow stenosis, and is thus recommended following thrombectomy. In the absence of a mechanical cause, hematologic evaluation should be performed to exclude a hypercoagulable state (including resistance to aspirin or clopidogrel) or thrombocytosis. Maintenance antiplatelet therapy is typically escalated in cases of stent thrombosis (e.g. clopidogrel is switched to prasugrel or ticagrelor, or cilostazol is added).

Restenosis

Restenosis is most commonly defined as renarrowing to a diameter stenosis >50%, either within the stent or within

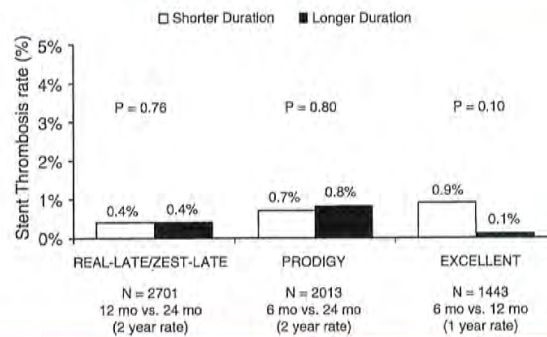


Figure 31.15 Outcomes in three randomized trials of extended-duration dual antiplatelet therapy versus standard-duration therapy after stenting.

5 mm proximal or distal to the stent margin. By increasing acute luminal gain^{34,35} and eliminating late recoil and negative vessel remodeling,²¹¹ BMS reduce the rates of restenosis compared to balloon angioplasty.^{6,7} However, stents induce more arterial injury than stand-alone balloon angioplasty, and therefore elicit a greater absolute amount of neointimal hyperplasia developing over the first 6 to 12 months after the procedure.²¹² As a result, BMS result in binary angiographic restenosis in 20% to 40% of lesions (with even higher rates observed depending on patient and lesion complexity). While restenosis most commonly presents with stable angina and exercise-induced ischemia within 1 year of stent implantation, it has become increasingly recognized that restenosis presents as an acute coronary syndrome in as many as 25% of patients, occasionally even with STEMI.^{212,213}

The causes of restenosis after stent implantation are multifactorial. In addition to excessive late neointimal hyperplasia, restenosis after BMS and DES has been associated with stent underexpansion,²¹⁴⁻²¹⁶ edge dissections, and residual untreated disease,^{217,218} geographic miss,²¹⁹ and strut fractures.^{189,190,220} Some²²¹ but not all^{222,223} studies have found an association between nickel allergy and restenosis after BMS or DES. Genetic mutations in the genes encoding mTOR or polymorphisms in the genes encoding proteins involved in paclitaxel metabolism may result in resistance to SES and PES respectively.^{224,225} Other genetic polymorphisms have also been associated with restenosis.^{226,227} Excessive inflammation from first-generation DES polymers (specifically eosinophilic reactions to PES and granulomatous reactions to SES) may provoke late restenosis.^{51,228}

Numerous studies have demonstrated that the most reproducible determinates of restenosis after BMS implantation are the presence of diabetes mellitus (especially if insulin is required), small RVD, and long lesion length.²²⁹⁻²³⁴ Other factors associated with restenosis are treatment of ostial and/or calcified lesions, true bifurcation lesions requiring main vessel and side branch stents, CTOs, and SVGs.²³⁵ The same factors are associated with (relatively) higher rates of DES

restenosis, although to a lesser absolute scale because of the profound effects of DES in limiting the intimal hyperplastic response to stent implantation. Angiographic and clinical restenosis (as well as death, MI, and stent thrombosis) after DES occurs less frequently in FDA-approved "on-label" lesions (generally noncomplex lesions for which safety and efficacy have been established by large-scale randomized trials) than in less studied and more complex "off-label" lesions,^{126,236} although in nearly all cases DES have been shown to reduce TLR compared to BMS.^{39,237,238} As discussed above, newer DES platforms (especially EES, ZES(R), and BES) have been shown to possess improved efficacy and safety. In addition, by facilitating the operator's ability to achieve larger lumen areas, IVUS may reduce restenosis and improve clinical outcomes after BMS.^{239,240} No randomized trial has been adequately powered to demonstrate a reduction in TLR with IVUS after DES implantation, although the recently reported AVIO trial demonstrated that the postprocedural minimal luminal diameter was significantly greater with IVUS guidance.¹⁵¹

The incidence of angiographic restenosis after BMS implantation peaks within approximately 6 months; thereafter, continued organization of the extracellular matrix results in slight luminal enlargement, and serial angiographic and IVUS studies have rarely shown late restenosis.^{241,242} More recently late neoatherosclerosis with plaque rupture *within the stented segment* has been described as a possible cause of restenosis occurring years after BMS.²⁴³ In contrast, a small amount of incremental angiographic late loss has been described for several years after SES and EES implantation, although reports on very late loss after PES have been conflicting.^{106,244-248} These observations imply the existence of low-grade chronic vascular inflammation from either the polymer or lack of healing. However, when compared to their BMS counterparts (or with EES versus PES in the SPIRIT trials), there has been little evidence demonstrating late loss to be of clinical relevance during extended follow-up of 2 to 5 years.^{111,116,170,244,249-251} In the largest randomized trial examining the issue of "late catch-up" (SIRTAX), 1,012 patients

were randomized to PES versus SES and followed for 5 years, with angiographic follow-up performed systematically at 8 months and 5 years.²⁵⁰ Incremental late loss between these two time periods occurred with both stents, although more so with SES than PES. At 1 year the rate of TLR was less with SES than PES, a benefit that was somewhat mitigated at 5 years. However, because routine angiographic follow-up was performed at regular intervals in this trial, the degree to which routine angiographic follow-up itself (rather than true clinical restenosis events) triggered late TLR procedures is unknown.¹⁰⁸ Nonetheless, a small degree of angiographic late loss may be expected with durable polymer-based DES, and may contribute to late adverse events in a small proportion of patients.

Patients who develop in-stent restenosis are at high risk for recurrence after percutaneous treatment, especially if the pattern of restenosis is diffuse.^{252,253} IVUS and/or OCT imaging is highly useful in patients with restenosis to differentiate neointimal hyperplasia from stent underexpansion, geographic miss, strut fracture, and other rare occurrences such as chronic recoil and stent embolization which require directed approaches to successfully manage.²⁵⁴ Isolated restenosis at the stent edge can often be effectively treated with balloon angioplasty only or an additional short stent. Treatment options for diffuse BMS restenosis due to neointimal hyperplasia have been extensively studied. In the BMS era, neither cutting balloons, directional or rotational atherectomy, nor repeat BMS proved better than balloon angioplasty for diffuse in-stent restenosis.²⁵⁵ However, in selected cases, the use of a cutting balloon or another force-focused device may be useful in that it minimizes balloon slipping and potentially affords a better initial angiographic result. Vascular brachytherapy with either locally applied beta or gamma radiation was effective in reducing recurrent restenosis within 1 year,^{256,257} but was logistically complex, and the resultant vascular toxicity with prolonged inflammation and obliteration of normal cell lines resulted in high rates of late stent thrombosis (especially when new BMS were implanted) and restenosis.^{258,259} Following the introduction of DES, two multicenter randomized trials demonstrated that SES and PES significantly reduced angiographic restenosis and improved event-free survival compared to either beta or gamma vascular brachytherapy in patients with BMS restenosis.²⁶⁰⁻²⁶³ Treatment of in-stent restenosis with DES has been shown to be superior to balloon angioplasty alone in the randomized ISAR-DESIRE trial.²⁶⁴ Angiographic follow-up at 6 months demonstrated recurrent restenosis after balloon angioplasty in 44.6% of patients versus 14.3% for SES ($P < 0.001$) and 21.7% for PES ($P = 0.001$), with TVR rates of 33%, 8%, and 19% respectively ($P < 0.001$ and $P = 0.02$ compared to balloon angioplasty, respectively). Based on the results of this and other trials, DES (with either PES or -limus analogue stents) has become the standard of care for nearly all cases of BMS restenosis due to intimal hyperplasia. For patients who are refractory to PCI-based strategies to treat restenosis, coronary artery bypass grafting (CABG) should be considered.

The optimal treatment for DES restenosis typically involves treatment with a second DES. (An emerging strategy to treat both BMS and DES restenosis is the use of drug-eluting balloons, which are presently not approved for use in the United States²⁶⁵). Compared to BMS restenosis, DES restenosis (particularly with more potent DES) tends to be focal and is diffuse in less than one-quarter of patients. If the stenosis is isolated to the margin or the stent, or is focal within the stent, either balloon angioplasty or implantation of a short DES is often selected. Management of diffuse DES restenosis has been less studied. In the CRISTAL trial, 197 patients with diffuse restenosis (mean length ~14 mm) of either an SES or PES were randomized to treatment with SES versus balloon angioplasty.²⁶⁶ Follow-up at 12 months demonstrated a significantly larger minimal lumen diameter (MLD) with SES compared to balloon angioplasty only (2.14 ± 0.62 mm versus 1.71 ± 0.55 mm, $P < 0.0001$), with a trend toward less TLR (5.9% versus 13.1%, $P = 0.10$). Many operators consider diffuse in-stent restenosis after DES (if IVUS demonstrates adequate stent expansion) to represent "drug failure" and will treat with a different class of agent (e.g. PES after SES failure). However, in the ISAR-DESIRE-2 trial, 450 patients with SES restenosis were randomized to SES versus PES.²⁶⁷ At 6 to 8-month follow-up there were no differences between SES and PES in late loss (0.40 ± 0.65 mm versus 0.38 ± 0.59 mm; $P = 0.85$), binary restenosis (19.6% versus 20.6%; $P = 0.69$), or TLR (16.6% versus 14.6%; $P = 0.52$).

Some operators have adopted a strategy of balloon angioplasty for focal restenotic lesions, and DES use for more diffuse restenotic lesions. In a randomized trial ($N = 162$ patients) of cutting balloon angioplasty versus SES for focal (≤ 10 mm) restenotic lesions and SES versus EES for diffuse (> 10 mm) restenotic lesions, use of SES was shown to reduce restenosis compared to cutting balloon angioplasty (3.1% versus 20.6%, $P = 0.06$) for focal lesions, with no differences observed between SES and EES for more diffuse lesions.²⁶⁸ Finally, recurrent diffuse DES restenosis represents a major clinical challenge. Options that may be considered include cilostazol,²⁶⁹ brachytherapy,²⁷⁰ and oral rapamycin.²⁷¹ Ultimately, CABG surgery may be required in patients with recurrent DES restenosis.

Other Complications of Coronary Stent Implantation

A review of all complications that can occur during or after PCI is beyond the scope of this chapter (see Chapters 4 and 28). However, several risks that are unique to or are increased in frequency with coronary stenting compared with balloon angioplasty should be appreciated.

Side Branch Compromise/Occlusion

Side branch compromise after stent implantation most commonly results from shifting of plaque during stent deployment

or high-pressure dilatation (though coronary spasm may contribute). This has been termed the "snowplow" effect. The incidence of side branch compromise after coronary stent implantation is greater than after balloon angioplasty alone.²⁷²⁻²⁷⁴ Side branch compromise and/or occlusion occurs with a greater frequency when both the parent vessel and side branch are diseased.²⁷⁵ Stent-induced occlusion of a large side branch may result in significant myocardial ischemia and infarction, though in most patients the long-term prognosis is excellent, and most initially occluded side branches are patent at late angiographic follow-up.^{273,274}

Side branch compromise and/or occlusion should be anticipated whenever a stent is placed across a bifurcation. If the side branch is large (≥ 2.5 mm in diameter), or is ≥ 2.0 mm in diameter and diseased at its ostium, it should be protected with a second guidewire prior to PCI. Many operators elect to wire and protect all side branches ≥ 1.5 to 2.0 mm using a "keep-it-open" strategy in order to avoid loss of any side branches. If the origin of the branch is narrowed, it is often beneficial to predilate it prior to stent implantation in the main branch, although this approach can increase the necessity of a second stent in the side branch, particularly if it results in dissection of the side branch ostium. Predilation of bifurcations are most commonly performed with conventional balloon angioplasty, but alternatives include use of focused force devices or debulking techniques such as atherectomy, although these approaches have not been clearly shown to preserve side branch patency beyond that achieved by balloon angioplasty alone. Once the side branch is protected with a second wire (and predilated if necessary), a stent may be placed in the main vessel across the branch origin, temporarily "jailing" the wire. This usually preserves patency of the side branch should occlusion otherwise occur and serves as a locator for the side branch origin.²⁷⁶ If additional angioplasty is planned, a third wire should then be passed through the stent struts into the narrowed side branch, after which the jailed wire is removed. The likelihood of a jailed wire becoming "stuck" is rare if the parent vessel stent is implanted at ≤ 12 atm of pressure, but jailing a long segment of wire in the parent vessel should be avoided, and hydrophilic wires should be used cautiously because of the risk of stripping the polymer coating on its withdrawal. Alternatively, if there is minimal narrowing at the origin of the side branch at baseline or after balloon dilatation, a stent may be placed in the main vessel across the side branch origin with the option of wiring the side branch should it become compromised after stent placement.

If the side branch significantly narrows after predilatation of either limb of the bifurcation, or the result is not acceptable after predilatation (which typically depends on the plaque burden, extent of calcification, and angle or origin of the side branch from the parent), a second stent should be implanted in the side branch using one of numerous techniques. With all these dual-stent techniques, however, the stent thrombosis rate is increased compared with a single-stent approach, and the restenosis rate within the second

stent at the side branch origin is increased compared relative to the main branch (even with DES). As such, the single-stent strategy is preferable if an acceptable balloon-only (or simple jailed wire) result in the side branch can be obtained.²⁷⁷

Stent Embolization

Embolization of the stent from the stent delivery system may occur during antegrade passage in a fibrocalcific or tortuous vessel, or upon withdrawal of the device after failure to cross a lesion (often when the edge of the stent snags on the tip of the guide catheter or on another plaque proximal to the lesion itself). Risk factors for stent embolization include heavy vessel calcification, pronounced vessel tortuosity, diffuse disease, and attempting to deliver a stent to a distal lesion through a previously implanted proximal stent.²⁷⁸ When the original Palmaz-Schatz stent was hand-mounted on a conventional angioplasty balloon and no sheath was used, stent embolization occurred in 8.4% of patients.⁷ Over the years, the development of tighter stent-to-balloon crimping processes in concert with lower-profile, more flexible devices has resulted in the incidence of this complication decreasing to $<1\%$ to 2%.^{279,280} Stent embolization into the peripheral vasculature usually has no adverse clinical sequelae, but may rarely cause limb ischemia or a cerebrovascular event. Conversely, intracoronary stent embolization is associated with significant rates of coronary thrombosis, coronary artery occlusion, and subsequent MI, with mortality rates as high as 17%. If the stent can be removed through percutaneous (nonsurgical) techniques, the majority of patients have a satisfactory outcome.^{281,282}

Success rates for percutaneous retrieval of lost stents from the coronary tree have ranged from 40% to 70% of patients in contemporary series.^{279,280,282} There are several basic strategies that can be employed to address stent embolization. If the coronary guidewire is still through the stent and has been maintained in the distal coronary artery, a low-profile balloon can sometimes be advanced through the stent, allowing the stent to be repositioned across the target lesion and expanded. If the stent cannot be repositioned, the balloon can be placed distal to the stent and inflated to trap the stent between the balloon and guiding catheter, and then all components can be withdrawn together into the femoral sheath. If guidewire position has been lost and the unexpanded stent is located in a proximal portion of the coronary artery or has embolized into a peripheral artery, it can sometimes be removed using snare devices or forceps. If the stent is displaced from the wire more distally within the artery, a snare or series of wires can be wrapped around it to attempt to ensnare it. Alternatively, a second stent may be expanded adjacent to the dislodged stent to trap and crush it against the vessel wall, effectively excluding it from the lumen. If the stent cannot be removed or effectively "excluded" from the coronary lumen, strong consideration should be given to coronary artery bypass surgery (with possible retrieval of the stent), although high mortality rates have been described in this situation.

Coronary Perforation

Although the routine use of high-pressure postdilatation improves stent expansion, the significant barotrauma imparted to the vessel may result in frank perforation, particularly if oversized or particularly compliant balloons are used either for deployment or postdilatation. In a retrospective analysis, Ellis and colleagues documented a 0.5% incidence of perforation among 12,900 procedures.²⁸³ From most contemporary series with stents, perforation has been reported in 0.2% to 1.0% of patients, though mild perforations are likely underreported. Risk factors for perforation include female gender, advanced age, lesion calcification and angulation, CTOs, and adjunctive atherectomy use.²⁸³ Device oversizing is also a risk for perforation; Colombo reported that the use of markedly oversized balloons (balloon-to-artery ratio >1.2 in the absence of IVUS guidance) has a risk of perforation and vessel rupture ranging from 1.2% to 3.0%.¹²

An angiographic classification of the severity of coronary artery perforation has proven useful in determining prognosis and guiding treatment.¹² A *type I* or concealed perforation is the most common type, and usually requires observation in case delayed tamponade occurs, but no additional specific therapeutic measures. A *type II* or limited perforation usually appears as a stain or blush at the site of the arterial tear, and can usually be managed with prolonged balloon inflations with or without reversal of anticoagulation. Serial echocardiography, both immediately postprocedure and 24 hours later is indicated to ensure the absence of a growing pericardial effusion. Of note, patients with a history of prior bypass surgery usually have extensive mediastinal adhesions, and perforations are rarely greater than type II. *Type III* or free-flowing perforations typically appear as continuous jetlike dye extravasation and may rapidly result in hypotension and tamponade requiring emergency pericardiocentesis. When a type III perforation is visualized, the angioplasty balloon should immediately be inflated at the site of coronary rupture to obtain immediate hemostasis.

Most small perforations can be sealed with prolonged balloon inflations and reversal of unfractionated heparin anticoagulation with protamine, unless a platelet glycoprotein IIb/IIIa receptor antagonist has been given.²⁸⁴ If the perforation is not readily closed with these measures and is severe, pericardiocentesis with drain placement should be performed to treat/prevent pericardial tamponade, and deployment of PTFE-covered stents provides reliable sealing, usually obviating the need for emergency surgery. Given their porous nature, two overlapping PTFE-covered stent grafts may occasionally be required for hemostasis. Additionally, because these devices are prone to higher rates of restenosis and/or stent thrombosis, high-pressure postdilatation is critical to optimize their results, even if the perforation is sealed. If a stent graft is unable to be delivered to the site of the perforation (as these are bulky devices), emergency surgery is usually required, though the associated rates of morbidity and mortality in this setting are high.

Infectious Endarteritis

Placement of a foreign body endovascular prosthesis carries the rare, albeit theoretical, risk of bacterial endarteritis. In an experimental porcine model, following the induction of transient bacteremia, a significant number of recently placed coronary stents cultured positive for bacteria.²⁸⁵ The risk of suppurative endarteritis in stented coronary arteries is extremely rare, however, with only a handful of documented cases in the literature.^{286,287} Although periprocedural antibiotic therapy is thus not routinely recommended, antibiotic prophylaxis may be considered if sterile technique has been breached or if the patient requires invasive procedures associated with transient bacteremia during the first 4 weeks following stenting, though the utility of this approach has never been demonstrated.

Allergic Reactions

Allergic reactions following coronary stent implantation are rare, and can result from allergy to either contrast dye used during the stent procedure, the antiplatelet regimen administered, or in even rarer cases, to the stent device itself. The majority of allergic reactions to contrast dye and the antiplatelet regimen can be managed with the use of antihistamines and corticosteroids; in the case of allergy to the antiplatelet regimen, there is a low rate of cross-reactivity between agents, and switching to a different agent (e.g. prasugrel or ticagrelor) can eliminate the symptoms. With respect to the stent device itself, there do not appear to be adverse reactions to stent implantation even in patients with a history of a metal allergy. In a series of 29 allergic patients who underwent coronary stent implantation, similar rates of adverse clinical outcomes were observed when compared to a matched patient population without metal allergy.²⁸⁸

STENT USAGE IN SPECIFIC PATIENTS AND LESIONS

Acute ST-Segment Elevation Myocardial Infarction (See Chapter 30)

Prompt reperfusion with either fibrinolytic therapy or PCI has been demonstrated to improve myocardial salvage and reduce mortality for patients with acute STEMI. Compared to fibrinolytic therapy, timely reperfusion with PCI results in improved myocardial salvage and reduced rates of recurrent ischemia, reinfarction, stroke, and death.²⁸⁹ Several studies have examined the use of stents compared to balloon angioplasty in patients with STEMI. In a metaanalysis of studies comparing the use of BMS with balloon angioplasty alone, implantation of BMS in STEMI was shown to result in similar rates of mortality and reinfarction, but reduced rates of TVR (Figure 31.16).²⁹⁰ In light of these results and the fact

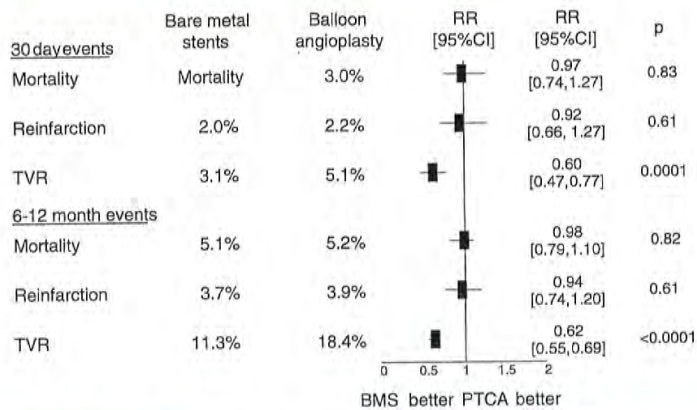


Figure 31.16 Metaanalysis from 13 randomized controlled trials of bare-metal stents compared to balloon angioplasty in acute myocardial infarction in 6,922 patients (adapted from De Luca et al., *Int J Cardiol* 2008). TVR, target vessel revascularization.

that stent implantation can optimize acute procedural results (maximizing lumen gain, and reducing abrupt closure and/or recoil), stents are used in the vast majority of cases of PCI for STEMI today. However, stent implantation within or adjacent to a fibroatheroma may result in delayed endothelialization,²⁹¹ and appropriate stent sizing can be difficult in cases of STEMI due to recent occlusion of the vessel with resulting layering thrombus, distal vessel spasm, and a desire to not oversize stents for fear of no reflow and distal embolization. These factors, combined with the heightened thrombotic state of patients with STEMI, are potential explanations for the relatively higher rates of stent thrombosis that have been reported after stent implantation in STEMI,^{292,293} although this risk can be somewhat ameliorated with more potent antiplatelet agents.^{199,200}

Following the introduction of DES, there have been at least 15 randomized trials comparing the use of DES versus BMS in patients with STEMI. The largest of these trials was the HORIZONS-AMI trial, which randomized 3,002 patients with evolving STEMI to PES(E) versus BMS at 123 international centers.²⁹⁴⁻²⁹⁶ The primary efficacy and safety endpoints were the 12-month rates of ischemia-driven TLR and MACE (a composite of death, reinfarction, stroke, or stent thrombosis), respectively. Routine angiographic follow-up at 13 months (beyond the primary endpoint) was performed in 1,249 patients. At 12 months, PES compared to BMS reduced the rates of ischemia-driven TLR (4.5% versus 7.5%, HR (95% confidence interval [CI]) = 0.59 [0.43, 0.83], $P = 0.002$) with similar rates of MACE (8.1% versus 8.0%, HR [95% CI] = 1.02 [0.76, 1.36], $P = 0.92$). The 13-month rates of angiographic binary restenosis were reduced from 22.9% with BMS to 10.0% with PES (RR [95% CI] = 0.44 [0.33, 0.57], $P < 0.001$). In-stent late loss was reduced with PES from 0.82 ± 0.70 mm to 0.41 ± 0.64 mm ($P < 0.001$),

with comparable rates of infarct artery reocclusion, ulceration, ectasia, and aneurysm formation between the two stent types. The greatest reduction in TLR was evident in patients with one or more risk factors for restenosis (RVD < 3.0 mm, lesion length > 30 mm, or insulin-treated diabetes mellitus), whereas patients without any of these variables had similarly low rates of TLR with BMS as with PES.²⁹⁶ Clinical follow-up from HORIZONS-AMI at 3 years has been reported,²⁹⁴ and demonstrated nonsignificantly different rates of death, reinfarction, stent thrombosis, and MACE with PES and BMS. At 3 years TLR was reduced from 15.1% with BMS to 9.4% with PES (HR [95% CI] = 0.60 [0.48, 0.76], $P < 0.001$), although the absolute benefit of PES was less pronounced in patients in whom routine angiographic follow-up was not performed (12.7% with BMS versus 8.7% with PES, HR [95% CI] = 0.67 [0.48, 0.93], $P = 0.01$).

The findings from HORIZONS-AMI parallel the amalgamated experience of randomized trials of DES versus BMS in STEMI. Collectively enrolling almost 8,000 patients, and with follow-up ranging from 3 to 5 years, these trials have demonstrated similar rates of death, reinfarction, and stent thrombosis with both stent types, and relative reductions in TVR with DES compared to BMS.^{297,298} Of note, the most updated metaanalysis of these trials demonstrated a significant interaction between DES versus BMS use and time with respect to the endpoint of stent thrombosis: DES were associated with a greater risk of very late (but not overall) stent thrombosis.²⁹⁸ Additionally, while the rates of angiographic and clinical restenosis (TLR or TVR) have been consistently reduced with DES compared to BMS in STEMI,²⁹⁷ many of these studies incorporated routine angiographic follow-up, which may artificially overestimate the absolute benefits of DES compared to BMS (the "oculostenotic reflex").^{108,299} Further, the overall rates of events related to restenosis are

typically lower among patients with STEMI, partly due to the lesion composition (favoring thrombus over plaque) and also because restenosis in an infarcted territory is less likely to manifest clinically. As such, the overall clinical benefit of DES relative to BMS is somewhat attenuated on an absolute level, and is determined by the patient's baseline risk of restenosis (Figure 31.17).²⁹⁶ Due to the thrombotic risk of these patients, maintenance of dual antiplatelet therapy is of particular importance among STEMI patients, in whom future adherence with antiplatelet medications may be difficult to assess. Premature discontinuation of dual antiplatelet therapy within 1 year after DES implantation in STEMI has been strongly associated with subsequent mortality.³⁰⁰ As such, a detailed risk-benefit analysis of DES versus BMS use in STEMI is warranted.

Patients with Diabetes Mellitus

Patients with diabetes have higher rates of angiographic and clinical restenosis than those without diabetes.^{230,233} In general, the pivotal trials in which DES were randomized to BMS revealed comparable relative safety and efficacy with DES in patients with diabetes compared to those without diabetes, although with greater absolute reductions in TLR and TVR in diabetic patients given their higher baseline risk.³⁰¹⁻³⁰³ As a result, DES are typically favored for coronary revascularization over BMS, if PCI is chosen as a revascularization strategy.

The most appropriate choice of specific DES among patients with diabetes is unknown. Most prior studies have shown comparable rates of in-stent late loss with PES in patients with diabetes versus those without diabetes,³⁰⁴ suggesting that the multiple pathways with which paclitaxel interferes with restenosis (by affecting microtubular function) makes its action relatively independent of the diabetic state.³⁰⁵

Considerable controversy has existed, however, whether the greater suppression of late loss from stents which elute potent –limus analogue is preserved in patients with diabetes, given that the effect of rapamycin in interfering with the cell cycle is regulated by glycosylation-dependent enzymes.³⁰⁶ In this regard, several small-to-moderate sized studies have provided conflicting results. For example, among 379 patients with diabetes randomized to SES versus PES(E) in the REALITY trial, the rates of restenosis and clinical events were comparable with both stents.³⁰⁷ In contrast, in the randomized 250-patient ISAR-Diabetes trial, SES compared to PES resulted in a greater reduction in late loss at 6 months, but nonsignificantly different rates of TLR at 9 months.³⁰⁸

This issue has more recently been addressed in a pooled patient-level analysis of 1,869 patients from the SPIRIT II, SPIRIT III, SPIRIT IV, and COMPARE trials of EES versus PES.³⁰⁹ In this analysis, while EES was associated with superior outcomes compared to PES among nondiabetic patients, in patients with diabetes, the rates of composite adverse events at 1 year (and their components) were almost identical between the two stent types. A strongly positive interaction ($P < 0.0001$) was present between diabetes and the stent platform with respect to 1-year events, confirming the observation of a statistically superior effect of EES over PES in nondiabetic patients (and similar outcomes in diabetic patients). While there are limited randomized data in diabetic patients with other –limus analogue DES, the ZES(R) recently received a specific FDA indication for use in patients with diabetes based upon the overall performance of the stent in patients with diabetes. Pooling the results of the ZES(R) clinical trial program, 878 patients with diabetes were treated with ZES(R), with a 12-month rate of target vessel failure of 7.8%, which was superior to a historical performance goal of 14.5%.³¹⁰ Thus, potent rapamycin analogue-eluting stents have been demonstrated to be effective in patients with diabetes.

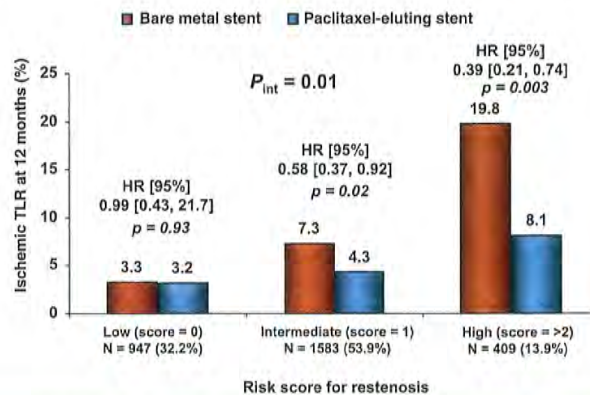


Figure 31.17 HORIZONS-AMI: Rates of 12-month ischemic target lesion revascularization according to risk strata (from Stone et al., *JACC* 2010). The risk of ischemic target lesion revascularization is similar in both stents in patients at low risk for restenosis but more pronounced among patients at intermediate and high risk. HR, hazard ratio.

Often the most critical revascularization decision in patients with diabetes mellitus is the mode of revascularization, i.e., whether to perform PCI or CABG. A metaanalysis of four randomized trials has demonstrated comparable 5-year rates of death, MI, or stroke in patients with diabetes treated with BMS or CABG; however, the rate of repeat revascularization procedures was significantly greater among BMS-treated patients.³¹¹ In the CARDia trial, 510 patients with diabetes mellitus and multivessel disease were randomized to PCI (with either BMS (31%) or SES (69%) – DES were used after SES became available) versus CABG.³¹² The primary endpoint of all-cause death, MI, or stroke at 1 year occurred in 10.5% of patients treated with CABG versus 13.0% of patients treated with PCI (HR [95% CI] = 1.25 [0.75 to 2.09], $P = 0.39$). When comparing patients treated during the time in which SES were available, the 1-year event rates were 12.4% versus 11.6% for CABG versus SES (HR [95% CI] = 0.93 [0.51 to 1.71], $P = 0.82$). Whereas CARDia was too underpowered to be definitive and has only reported 1-year follow-up, the ongoing FREEDOM trial,³¹³ which is enrolling more than 2,000 diabetic patients to SES or PES versus CABG with a follow-up of 6.75 years, will provide important evidence-based guidance for this high-risk subgroup of patients with multivessel disease.

For patients with diabetes who undergo PCI, specific issues that require foresight by the operator include the treatment of diffuse disease and disease in small vessels. Because the relative and absolute risks of restenosis and stent thrombosis are higher in diabetic patients, assiduous attention to procedural technique and details is critical. Specific attention should be paid to appropriate stent length (using the least amount of stent length in order to cover obstructive lesions) and optimization of stent lumen area to minimize the effects of a more aggressive intimal hyperplastic response.

Multivessel and Left Main Disease

Although they are distinctly different conditions, revascularization decisions for patients with left main and multivessel disease are often considered together because historically the default strategy for these lesion subtypes has been CABG. Patients with multivessel disease treated with PCI have higher rates of restenosis and stent thrombosis than those with single-vessel disease, especially when diffuse disease, small vessels, CTOs, and bifurcation lesions requiring treatment are present. In contrast, while restenosis and thrombosis are relatively rare after stenting the relatively short, large-caliber left main segment, PCI failure in the left main jeopardizes a sufficiently large amount of myocardium to entail a high risk of mortality.

While there have been several trials examining the use of PCI versus CABG for multivessel disease, the majority of these trials have been conducted prior to the introduction of DES. A widely cited metaanalysis by Hlatky et al.³¹⁴ was performed using individual patient data from 10 randomized trials of PCI versus CABG in 7,812 total patients with

multivessel disease. However, the majority of included trials were of balloon angioplasty alone compared to CABG; BMS were used in only four of these trials, and no study included in this analysis utilized DES. Among patients enrolled in trials using BMS, follow-up up to 5 years has demonstrated comparable rates of death, MI, or stroke between BMS and CABG (16.7% versus 16.9%, $P = 0.69$), with no heterogeneity noted in patients with diabetes versus those without diabetes or with double- versus triple-vessel disease.³⁰⁷ However, the 5-year rates of unplanned revascularization were significantly higher with BMS compared to CABG (29.0% versus 7.9%, $P < 0.001$).

Prior to the introduction of DES, there had been no randomized trials of PCI versus CABG in patients with unprotected left main disease, because observational studies had shown a high rate of procedural failure and late sudden cardiac death with balloon angioplasty,³¹⁵ and unacceptably high restenosis and MACE rates with BMS in this anatomic subgroup.³¹⁶ In a small prospective trial, Erglis et al.³¹⁷ randomized 103 patients with left main disease to BMS versus PES, and demonstrated that PES resulted in significantly lower 6-month rates of binary restenosis (6% versus 22%, $P = 0.02$) and MACE (13% versus 30%, $P = 0.04$). The ISAR left main investigators then randomized 650 patients with left main disease to PES versus SES,³¹⁸ and found comparable 1-year rates of composite death, MI, or TLR (13.6% versus 15.8%, $P = 0.44$), definite stent thrombosis (0.3% versus 0.7%, $P = 0.57$), and restenosis (16.0% versus 19.4% $P = 0.30$) with the two stent types. In another small randomized trial, the LEMANS investigators assigned 105 patients to either PCI with BMS or DES (the latter used in only 35% of patients) versus CABG.³¹⁹ The primary endpoint of change in LVEF 12 months after the procedure was significantly greater with PCI than with CABG. PCI also had a significantly better early safety profile.

The most contemporary and relevant examination of the relative safety and efficacy of DES versus CABG in multivessel and left main coronary artery disease is the SYNTAX trial, which randomized 1,800 patients with either triple vessel disease ($N = 1,095$) and/or left main disease ($N = 705$) to PES(E) versus CABG, with the primary aim of demonstrating noninferiority of PES to CABG.³²⁰ The primary endpoint of SYNTAX, the 1-year composite rate of all-cause mortality, stroke, MI, or unplanned repeat revascularization, however, occurred significantly less commonly with CABG than with PES, and thus noninferiority could not be claimed (Figure 31.18, left). However, the major differences in the primary study endpoint were driven by greater rates of repeat revascularization with PCI compared to CABG (although the difference between PCI and CABG was greatly reduced with PES than in the earlier era with BMS). When considering the composite endpoint of death, MI, or stroke, there were no differences between the two study arms, and similarly, the rates of death or MI individually were similar between PCI and CABG. However, the 1-year rate of stroke was significantly lower with PCI than

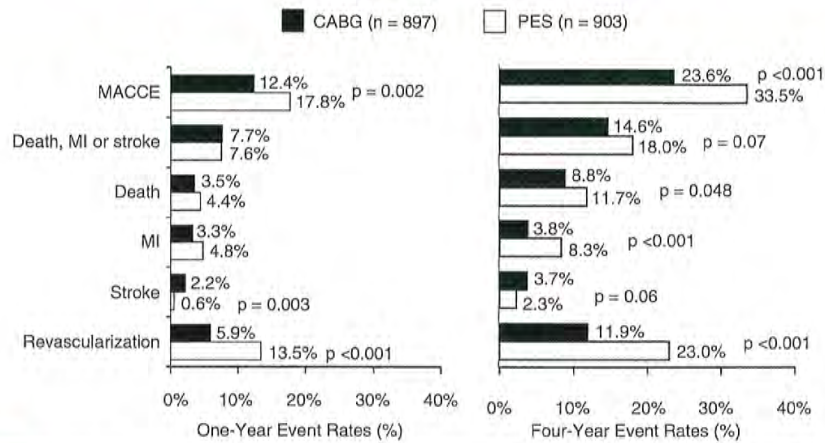


Figure 31.18 1-year (left) and 4-year (right) results from the SYNTAX trial in which 1,800 patients with triple vessel and/or left main disease were randomized to paclitaxel-eluting stents versus coronary artery bypass graft surgery. CABG, coronary artery bypass grafting; PES, paclitaxel-eluting stent; MACCE, major adverse cardiac or cerebrovascular events including death, myocardial infarction (MI), stroke, or unplanned repeat revascularization. $P = NS$ unless otherwise noted.

with CABG. Longer-term follow-up of the SYNTAX trial is ongoing to 5 years; 4-year results have been reported on 819 patients in the CABG arm (91.3%) and 879 patients in the PCI arm (97.3%), with 78 CABG patients and 24 PCI patients lost to follow-up.³²¹ In this analysis (Figure 31.18, right), the benefit of CABG over PCI with respect to the primary composite endpoint has persisted with the largest difference between treatment arms observed in the rate of repeat revascularization procedures. However, a trend toward lower rates of death, stroke, or MI has also emerged between the two groups (14.6% with CABG versus 18.0% with PCI, $P = 0.07$). Patients treated with CABG had a significantly lower all-cause mortality when compared to PCI (8.8% versus 11.7%, $P = 0.048$) and MI was significantly lower as well (3.8 versus 8.3%; $P < 0.001$). Of particular concern related to this difference in MI is the overall rate of definite/probable stent thrombosis in the PES arm, which was 8.8% at 4 years.

A borderline interaction ($P_{int} = 0.11$) was present between the randomization arm and the primary 1-year endpoint for patients with left main versus triple-vessel disease in SYNTAX, such that the primary major adverse cardiac and cerebrovascular event (MACCE) endpoint was improved in triple-vessel disease patients randomized to CABG, where there were no significant differences in composite adverse events between PES and CABG for left main patients.³²⁰ Moreover, the selection of the most appropriate revascularization modality in these complex patients may be further discriminated by use of the SYNTAX score (www.syntaxscore.com), an anatomic-based risk score that was prospectively defined prior to patient enrollment. Patients undergoing PCI had

progressively higher MACCE rates with high SYNTAX scores, where MACCE outcomes after CABG were independent of SYNTAX score. The 4-year outcomes from the SYNTAX trial according to the presence of left main disease and SYNTAX score tertile appear in Table 31.7.^{322,323} These data suggest that CABG might be favored for patients with triple-vessel disease and high or intermediate SYNTAX score, or left main disease and high SYNTAX score. Conversely, the 4-year results were equally good or better with PES compared to CABG in patients with triple-vessel disease and low SYNTAX score, and in particular for left main disease and low or intermediate SYNTAX score. However, given the modest sample sizes of these post hoc subgroups, these impressions should be considered hypothesis-generating only. Moreover, whether other scores incorporating clinical risk factors would have superior discrimination to the SYNTAX score has not been prospectively validated.^{324,325}

Nonetheless, on the basis of the SYNTAX trial, the most recent US and EU guidelines have elevated PCI of the left main to either a class IIb recommendation (US guidelines), or IIa or IIb (EU guidelines) depending on the relative risk and complexity for PCI versus CABG.^{325,326} The results of PCI in patients with complex coronary artery disease may be further optimized by use of better stents and pharmacotherapy than were employed in SYNTAX,^{42,327} and with the regular use of IVUS and FFR guidance,^{154,328} which were rarely utilized in SYNTAX. Many of these issues are being addressed in the ongoing EXCEL trial, in which 3,100 patients with unprotected left main disease and a low to moderate SYNTAX score are being randomized to PCI with EES versus CABG.

Table 31.7 Four-Year Outcomes from the SYNTAX Trial, Stratified by Triple Vessel Versus Left Main Disease, According to Syntax Score Tertile

	Low SYNTAX Tertile			Intermediate SYNTAX Tertile			High SYNTAX Tertile		
	PES	CABG	P value	PES	CABG	P value	PES	CABG	P value
Triple vessel disease	n=181	n=171		n=207	n=208		n=155	n=166	
MACCE	30.4%	24.7%	0.27	33.3%	17.9%	<0.001	37.9%	21.2%	<0.001
- Death, MI, or stroke	15.8%	14.8%	-	18.6%	12.4%	-	22.3%	11.0%	0.008
- Death	9.0%	8.7%	-	18.6%	12.4%	0.048	14.5%	6.5%	0.02
- MI	8.2%	4.9%	-	10.5%	3.1%	0.004	7.9%	1.9%	0.01
- Stroke	1.2%	3.9%	-	2.5%	3.6%	-	5.1%	2.6%	0.31
- Revascularization	21.2%	11.6%	0.02	21.0%	8.3%	<0.001	26.7%	11.2%	<0.001
Left main disease	n=118	n=104		n=103	n=92		n=135	n=149	
MACCE	26.0%	28.4%	0.60	29.5%	29.7%	0.90	42.6%	26.3%	<0.003
- Death, MI, or stroke	12.3%	14.2%	-	14.8%	20.3%	-	23.1%	18.5%	-
- Death	7.1%	9.2%	-	8.0%	14.7%	-	17.9%	10.5%	0.06
- MI	4.3%	3.1%	-	6.0%	4.6%	-	10.9%	6.1%	-
- Stroke	1.8%	4.1%	-	1.0%	3.6%	-	1.6%	4.9%	-
- Revascularization	18.2%	16.8%	-	20.2%	17.0%	-	31.3%	11.8%	<0.001

MI, myocardial infarction; MACCE, major adverse cardiac or cerebrovascular events (death, MI, stroke, or revascularization); PES, paclitaxel-eluting stents; CABG, coronary artery bypass graft surgery.

Chronic Total Occlusions

Clinical and angiographic restenosis rates after both balloon angioplasty and stent implantation are increased following PCI of CTO compared to nonoccluded stenoses, due principally to an increased incidence of diabetes, greater lesion length, plaque mass, and calcification.^{329,330} Additionally, during crossing of CTO lesions, wires and devices are sometimes advanced in the subintimal space; without stenting, these segments are likely to reocclude. Stenting of CTO lesions has thus become the default strategy when PCI is planned, and the use of DES is preferred. In a 200-patient randomized trial of SES versus BMS, the use of SES resulted in significant reductions in binary angiographic restenosis (7% versus 36%, $P < 0.001$) and TLR (4% versus 19%, $P < 0.001$), with reductions in clinical restenosis maintained at up to 4 years of clinical follow-up.³³¹ A large number of retrospective, nonrandomized, and historically controlled comparisons of DES and BMS have similarly demonstrated approximately 60% reductions in clinical restenosis endpoints with DES compared

to BMS. However, despite similar hazards of mortality and MI with DES compared to BMS in a metaanalysis aggregating this data, a trend toward increased stent thrombosis was observed with first-generation DES (RR: 2.79, 95% CI: 0.98-7.97, $P = 0.06$), meriting some concern.³³² Additionally, SES has been associated with a 16% rate of stent fracture when used in CTO lesions, particularly in long overlapping segments of disease.¹⁹⁰ Studies are ongoing to determine whether these results may be improved upon by second-generation stents which are more fracture-resistant, such as EES and ZES(R).³³³

A number of advances in CTO technique have renewed the interest in tackling these lesions, which historically have had the lowest rates of procedural success among all lesions undergoing PCI. Critical issues related to stenting of CTO lesions include adequate selection of CTOs that are in viable and/or ischemic myocardial territories, minimizing stent overlap and overall stented length as much as possible, avoidance of stent implantation in diffusely diseased distal territories, and optimization of lumen area in vessels that are chronically underfilled (and therefore can appear smaller

than they actually are in the reperfused state). Finally, prior to CTO recanalization and stent implantation, it is critical to ascertain the ability of a patient to adhere to dual antiplatelet therapy because stent thrombosis of recanalized CTO lesions will likely result in acute MI due to regression of collaterals supplying the CTO territory.³³⁴

Bifurcation Lesions

Bifurcation lesions represent 20% or more of stenoses undergoing angioplasty, and PCI of coronary bifurcation lesions is associated with increased procedural complications and worsened long-term outcomes. Due to the higher rates of clinical restenosis at bifurcation lesions, the use of DES for the main vessel of a bifurcation lesion has become the standard of care for bifurcation disease. For true bifurcation lesions (atherosclerotic involvement of both the parent and side branch), the major decision is whether to undertake a provisional or dual-stent strategy. With *provisional stenting*, the main vessel is stented (often after optimal predilatation of the side branch), and the side branch is dilated or stented only for a truly unacceptable result (typically a diameter stenosis >50% or severe dissection). A strategy of provisional stenting of the side branch is the generally accepted current approach to bifurcation disease unless there is significant high-grade and lengthy disease within the side branch.^{335,336} This approach is also usually preferred if the parent vessel is large and the side branch relatively small. Alternatively, when both the parent vessel and side branch are large (≥ 2.5 mm), especially when the side branch arises at a shallow angle, planned stenting of both branches may be considered. Various approaches to dual stenting of bifurcation lesions have been developed and are briefly outlined below (Figure 31.19).³³⁷

T-Stent Technique

A stent is deployed at the ostium of the side branch, followed by a second stent in the parent vessel. Unless the angle of origin of the side branch is 90°, however, the operator is faced with the dilemma of whether it is better to leave a portion of the ostial side-branch lesion unstented or risk having part of the stent protrude into the parent vessel (making subsequent advancement of the parent vessel stent difficult or impossible). A modification of this technique to maximize ostial side branch coverage is the T-and-protrusion technique, where the main branch stent is deployed first, followed by stenting of the side branch with a balloon angioplasty catheter in the main vessel. The side-branch stent is brought back to protrude slightly into the main branch to maximize ostial coverage, and is then deployed, impinging on the main branch balloon, making a “T.” A kissing balloon inflation (into the main branch and side branch simultaneously) is then performed to ensure adequate flow into both branches without compromise.

“Culotte” Stent Technique

A stent is deployed into the side branch with extension into the proximal aspect of the parent vessel. A wire is then passed through the side struts of this stent and into the distal parent vessel. After balloon dilatation, a second stent is passed through the side struts into the distal, so that the proximal ends of the first and second stents overlap in the proximal vessel. This technique is the most technically complex, but offers excellent scaffolding and coverage of the bifurcation.

“Crush” Stent Techniques

After predilatation of both limbs, two stents are positioned simultaneously in the side branch and main branch. The side-branch stent extends into the proximal main vessel 2 to 3 mm (or less in the “mini-crush”); the parent branch stent extends at least several millimeters more proximally. The side-branch stent is inflated first, trapping the main-branch stent delivery system. After confirmation of patency without dissection in the side branch, the side-branch guidewire and stent delivery system are removed, and the main-branch stent is implanted, “crushing” the side-branch stent. Following this, the side-branch stent is rewired and simultaneous kissing balloon inflations are performed (it is generally recommended that all bifurcation stent techniques be completed by kissing balloon technique). There have been many modifications of this technique, including modified sequences of stent implantation such as in the “reverse crush,” which is applicable when side-branch stenting was not initially planned. In this case, after main branch implantation, a second stent is placed in the side branch extending into the proximal parent vessel (within the previously placed stent), and a balloon angioplasty catheter is placed in the main vessel. The side-branch stent is then deployed, impinging on the balloon. After removal of the side-branch stent delivery system and wire, the main-branch balloon is then inflated to crush the proximal portion of the side-branch stent, and a final kissing balloon inflation is performed. Balloon crushing of the side-branch stent can also be used as the initial approach (prior to main branch deployment) in the “step crush” technique, a technique that is useful when smaller guide and sheath sizes are used). Other modifications include performance of additional kissing balloon inflations prior to main branch deployment (e.g. “double-kissing crush” technique) which can improve procedural outcomes.³³⁸

The crush technique is simpler than the culotte technique and affords excellent coverage of the carina; however, a randomized trial of the two techniques demonstrated a trend toward more frequent periprocedural enzymatic elevation with the crush technique but similar rates of late events with both techniques.³³⁹ Recrossing the crushed side-branch stent with a guidewire and balloon can be challenging and time consuming, however, but is essential because late outcomes are significantly improved following a simultaneous kissing balloon inflation with this technique.³⁴⁰

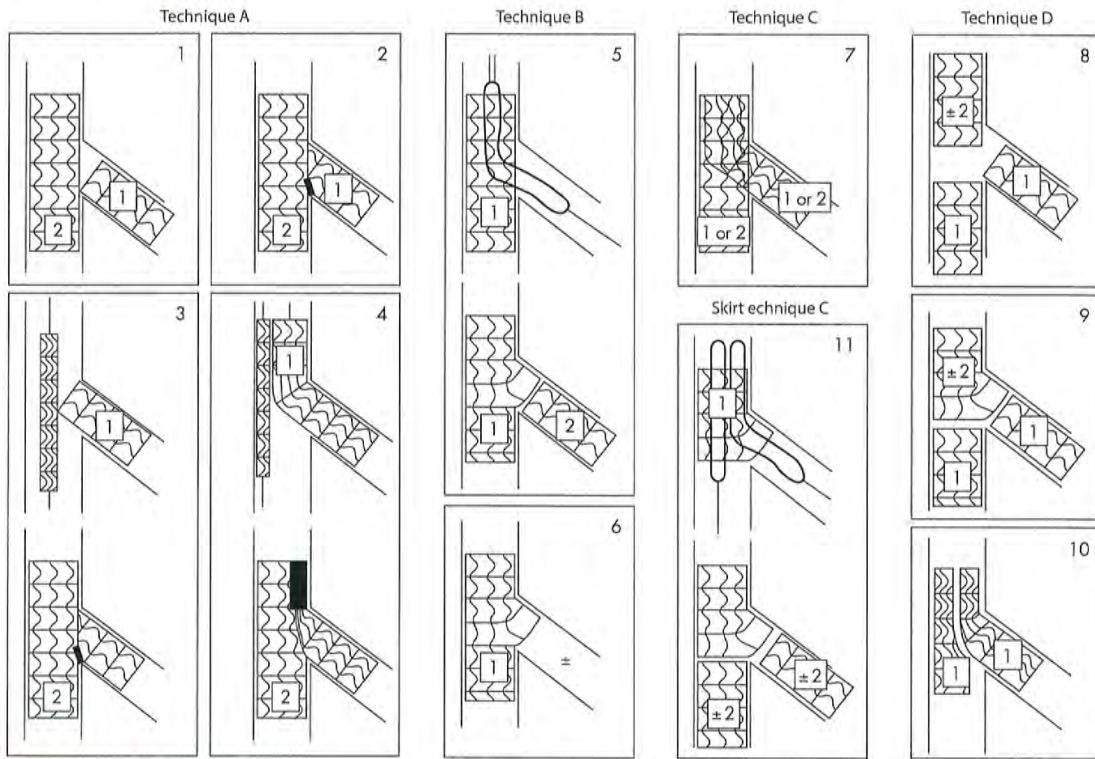


Figure 31.19 Strategies for the treatment of bifurcation disease (from Louvard et al., *Heart* 2004). 1 and 2. Classic T-stenting beginning with side branch stenting. 3. Modified T-stenting. 4. “Crush” technique. 5. Classic T-stenting beginning with main branch stenting. 6. Provisional T-stenting. 7. “Culotte” or “trousers” technique. 8. Touching stents completed or not as Y technique. 9. “Trouser legs and seat” technique, a classic touching stents technique completed proximally by a “skirt” technique. 10. Kissing stents technique. 11. “Skirt” technique.

Simultaneous Kissing Stents/V-Stenting

Two stents are deployed simultaneously over separate guide-wires: one in the parent vessel and one in the side branch. For simultaneous kissing stents, both stents extend side by side in the main vessel proximal to the bifurcation (for V-stenting, these stents are deployed at the ostia of both branches, minimizing the length of the “carina”). Although this technique offers the advantage of simplicity and control of both vessels, a new, more proximal carina is created in the center of the proximal parent vessel, which is unlikely to endothelialize fully and can be very difficult to wire if repeat PCI is required. Also, placement of an additional stent is problematic should a proximal dissection occur.

Bifurcation Summary

An exhaustive review of the pros and cons of these techniques is beyond the scope of this chapter. However, as a

general rule, a provisional strategy to bifurcation lesions is preferred as it can result in safer procedural outcomes, and, by minimizing the amount of stent at the carina, can minimize the risks of subsequent stent thrombosis. When treating bifurcation lesions provisionally, it is generally recommended to wire and protect all side branches ≥ 1.5 to 2.0 mm using a “keep-it-open” strategy in order to prevent and/or facilitate management of side branch compromise and occlusion (see stent complications section above). If an upfront two-stent strategy is selected, a familiarity with the techniques is necessary, because the majority of these dual-stent techniques are technically complex, require use of a larger (7F or 8F) guiding catheter, and can pose difficulty in reaccessing the parent vessel or side branch through overlapping metallic elements.

A variety of novel strategies for the treatment of bifurcation disease with drug-eluting balloons is also currently

undergoing evaluation,^{341,342} but current data using drug-eluting balloons in native coronary stenoses have been mixed. Additionally, several dedicated drug-eluting bifurcation stent systems have been designed and are under investigation. Bifurcation stent systems can be classified as those that facilitate access to the side branch to simplify the PCI procedure, versus novel stents designed to address the unique geometric challenges of the bifurcated stenosis. Initial experiences with the Axxess™ self-expanding nitinol stent (Biosensors International, Switzerland) (coated with the bioabsorbable polymer PLLA which elutes the antiproliferative rapamycin analogue biolimus A9) have demonstrated low rates of restenosis of both the main vessel and side branch in both true bifurcation lesions as well as in the distal bifurcation of the left main coronary artery.^{343,344} This “reverse cone” stent is designed to adapt to and cover the main parent vessel and the bifurcation carina, and is used in conjunction with dedicated DES of one or both branches when necessary. Preliminary data have also been published on the use of the Stentys™ paclitaxel-eluting side branch access stent³⁴⁵ and the Taxus Petal™ dedicated bifurcation stent³⁴⁶; further clinical data are awaited in order to determine the long-term advantages of these stents for the treatment of bifurcation disease.

Saphenous Vein Grafts

The most common cause of recurrent ischemia following CABG surgery is atheromatous degeneration within the body of an SVG, and BMS have been associated with improved outcomes compared to balloon angioplasty in SVG intervention.^{347,348} While DES have the potential to further lower rates of restenosis of the target lesion within SVGs, disease progression at nontarget sites within SVGs is frequent, and additionally, due to the large caliber of most SVGs, the “tolerated late loss” within SVG lesions is typically greater than in native coronary vessels. Two small randomized trials of DES versus BMS for critical SVG stenoses were conducted early in the DES experience, and demonstrated lower rates of angiographic restenosis with DES.^{349,350} With extended follow-up to a median of 32 months in one of these studies, however, the antirestenotic advantage of SES compared to BMS was lost, and SES was associated with higher mortality.³⁵¹ A more recent larger randomized trial, the ISAR-CABG trial, randomized 610 patients to either BMS, SES, PES, or biodegradable polymer SES.³⁵² At 1 year, the use of all DES versus BMS was associated with reductions in TLR (7% versus 13%, $P = 0.01$) as well as composite death, MI, and TLR (15% versus 22%, $P = 0.02$), with no differences observed in overall mortality or stent thrombosis. Further follow-up of this trial will help to critically assess the occurrence of late safety outcomes.

At present, for patients that can tolerate longer-term regimens of dual antiplatelet therapy, DES are typically preferred for either focal disease in large graft conduits or for diffuse graft degeneration (if native coronary artery PCI or repeat surgery is not an option). Notably, a small pilot study of

prophylactic “sealing” of moderate, noncritical SVG lesions with PES in order to prevent disease progression within SVGs was superior to medical therapy alone, suggesting a possible preventive role for DES in degenerating SVG lesions prior to their becoming critical.³⁵³ A large randomized trial is required, however, before such an approach is undertaken.

CONCLUSION: CURRENT PERSPECTIVES AND FUTURE DIRECTIONS

The development and evolution of the coronary stent has resulted in remarkable progress in the lesser invasive treatment of coronary artery disease. Over the past two decades, coronary stenting has emerged as the dominant technology for catheter-based coronary revascularization. The availability of stents with excellent deliverability and scaffolding, the demonstration that stenting improves acute and long-term outcomes in a wide variety of lesion types, the development of effective and better-tolerated pharmacologic regimens to prevent stent thrombosis, and now the marked suppression of restenosis with antiproliferative bioactive coatings have facilitated the application of stenting to almost every patient and lesion subset. However, although infrequent, stent thrombosis and restenosis still occur with even the best DES, and the reliance on long-term, dual antiplatelet therapy is a major limitation for many patients. Novel DES approaches aimed at tackling this issue under active development and current study include further investigation of second- and third-generation durable polymer platforms with the ability to passivate the vascular endothelium, dual-agent DES that may also confer improved safety and/or efficacy, biodegradable polymer and polymer-free stents designed to minimize reactions to the drug carrier, and finally, fully bioabsorbable scaffolds that offer the potential to eliminate late stent thrombosis. Further enhancements to stent design will additionally allow these devices to continue to improve with respect to deliverability and ease of use, and novel adjunctive drugs and devices may further facilitate the use of PCI for the most complex patients and coronary anatomies. As such, the coronary stent is certain to remain the foundation for the minimally invasive treatment of coronary atherosclerosis for the foreseeable future.

REFERENCES

1. Mulliken JB, Goldwyn RM. Impressions of Charles Stent. *Plast Reconstr Surg* 1978;62:173–176.
2. Sigwart U, Puel J, Mirkovitch V, Joffre F, Kappenberger L. Intravascular stents to prevent occlusion and restenosis after transluminal angioplasty. *N Engl J Med* 1987;316:701–706.
3. Serruys PW, Strauss BH, Beatt KJ, et al. Angiographic follow-up after placement of a self-expanding coronary-artery stent. *N Engl J Med* 1991;324:13–17.

4. George BS, Voorhees WD 3rd, Roubin GS, et al. Multicenter investigation of coronary stenting to treat acute or threatened closure after percutaneous transluminal coronary angioplasty: clinical and angiographic outcomes. *J Am Coll Cardiol* 1993; 22:135-143.
5. Schatz RA, Baim DS, Leon M, et al. Clinical experience with the Palmaz-Schatz coronary stent. Initial results of a multicenter study. *Circulation* 1991;83:148-161.
6. Fischman DL, Leon MB, Baim DS, et al. A randomized comparison of coronary-stent placement and balloon angioplasty in the treatment of coronary artery disease. Stent Restenosis Study Investigators. *N Engl J Med* 1994;331:496-501.
7. Serruys PW, de Jaegere P, Kiemeneij F, et al. A comparison of balloon-expandable-stent implantation with balloon angioplasty in patients with coronary artery disease. Benestent Study Group. *N Engl J Med* 1994;331:489-495.
8. Cutlip DE, Chhabra AG, Baim DS, et al. Beyond restenosis: five-year clinical outcomes from second-generation coronary stent trials. *Circulation* 2004;110:1226-1230.
9. Kimura T, Abe K, Shizuta S, et al. Long-term clinical and angiographic follow-up after coronary stent placement in native coronary arteries. *Circulation* 2002;105:2986-2991.
10. Yamaji K, Kimura T, Morimoto T, et al. Very long-term (15 to 20 years) clinical and angiographic outcome after coronary bare metal stent implantation/clinical perspective. *Circ Cardiovasc Interv* 2010;3:468-475.
11. Nakamura S, Colombo A, Gaglione A, et al. Intracoronary ultrasound observations during stent implantation. *Circulation* 1994;89:2026-2034.
12. Colombo A, Hall P, Nakamura S, et al. Intracoronary stenting without anticoagulation accomplished with intravascular ultrasound guidance. *Circulation* 1995;91:1676-1688.
13. Bertrand ME, Legrand V, Boland J, et al. Randomized multicenter comparison of conventional anticoagulation versus antiplatelet therapy in unplanned and elective coronary stenting. The full anticoagulation versus aspirin and ticlopidine (fantastic) study. *Circulation* 1998;98:1597-1603.
14. Leon MB, Baim DS, Popma JJ, et al. A clinical trial comparing three antithrombotic-drug regimens after coronary-artery stenting. Stent Anticoagulation Restenosis Study Investigators. *N Engl J Med* 1998;339:1665-1671.
15. Schomig A, Neumann FJ, Kastrati A, et al. A randomized comparison of antiplatelet and anticoagulation therapy after the placement of coronary-artery stents. *N Engl J Med* 1996;334:1084-1089.
16. Urban P, Macaya C, Rupprecht HJ, et al. Randomized evaluation of anticoagulation versus antiplatelet therapy after coronary stent implantation in high-risk patients: the multicenter aspirin and ticlopidine trial after intracoronary stenting (MATTIS). *Circulation* 1998;98:2126-2132.
17. Hehrlein C, Zimmermann M, Metz J, Ensinger W, Kubler W. Influence of surface texture and charge on the biocompatibility of endovascular stents. *Coron Artery Dis* 1995;6:581-586.
18. Garasic JM, Edelman ER, Squire JC, Seifert P, Williams MS, Rogers C. Stent and artery geometry determine intimal thickening independent of arterial injury. *Circulation* 2000;101:812-818.
19. Rogers C, Edelman ER. Endovascular stent design dictates experimental restenosis and thrombosis. *Circulation* 1995;91:2995-3001.
20. Kastrati A, Mehilli J, Dirschinger J, et al. Intracoronary stenting and angiographic results: strut thickness effect on restenosis outcome (ISAR-STEREO) trial. *Circulation* 2001;103:2816-2821.
21. Kolaivalu K, Swaminathan R, Gibson WJ, et al. Stent thrombogenicity early in high-risk interventional settings is driven by stent design and deployment and protected by polymer-drug coatings. *Circulation* 2011;123:1400-1409.
22. Ormiston JA, Webber B, Webster MW. Stent longitudinal integrity: bench insights into a clinical problem. *JACC Cardiovasc Interv* 2011;4:1310-1317.
23. Prabhu S, Schikorr T, Mahmoud T, Jacobs J, Potgieter A, Simonton C. Engineering assessment of the longitudinal compression behaviour of contemporary coronary stents. *EuroIntervention* 2012;8(2): 275-281.
24. Williams PD, Mamas MA, Morgan KP, et al. Longitudinal stent deformation: a retrospective analysis of frequency and mechanisms. *EuroIntervention* 2012;8(2):267-274.
25. van der Giessen WJ, Lincoff AM, Schwartz RS, et al. Marked inflammatory sequelae to implantation of biodegradable and non-biodegradable polymers in porcine coronary arteries. *Circulation* 1996;94:1690-1697.
26. Han RO, Schwartz RS, Kobayashi Y, et al. Comparison of self-expanding and balloon-expandable stents for the reduction of restenosis. *Am J Cardiol* 2001;88:253-259.
27. Shin ES, Garcia-Garcia HM, Okamura T, et al. Comparison of acute vessel wall injury after self-expanding stent and conventional balloon-expandable stent implantation: a study with optical coherence tomography. *J Invasive Cardiol* 2010;22:435-439.
28. Pache J, Kastrati A, Mehilli J, et al. Intracoronary stenting and angiographic results: strut thickness effect on restenosis outcome (ISAR-STEREO-2) trial. *J Am Coll Cardiol* 2003;41:1283-1288.
29. Haude M, Hopp HW, Rupprecht HJ, et al. Immediate stent implantation versus conventional techniques for the treatment of abrupt vessel closure or symptomatic dissections after coronary balloon angioplasty. *Am Heart J* 2000;140:e26.
30. Antoniucci D, Valenti R, Santoro GM, et al. Restenosis after coronary stenting in current clinical practice. *Am Heart J* 1998;135:510-518.
31. Agostoni P, Biondi-Zoccai GG, Gasparini GL, et al. Is bare-metal stenting superior to balloon angioplasty for small vessel coronary artery disease? Evidence from a meta-analysis of randomized trials. *Eur Heart J* 2005;26:881-889.
32. Nordmann AJ, Hengstler P, Leimenstoll BM, Harr T, Young J, Bucher HC. Clinical outcomes of stents versus balloon angioplasty in non-acute coronary artery disease. A meta-analysis of randomized controlled trials. *Eur Heart J* 2004;25:69-80.
33. Al Suwaidi J, Berger PB, Holmes DR Jr. Coronary artery stents. *JAMA* 2000;284:1828-1836.
34. Kuntz RE, Safian RD, Carrozza JP, Fishman RE, Mansour M, Baim DS. The importance of acute luminal diameter in determining restenosis after coronary atherectomy or stenting. *Circulation* 1992;86:1827-1835.
35. Kuntz RE, Gibson CM, Nobuyoshi M, Baim DS. Generalized model of restenosis after conventional balloon angioplasty, stenting and directional atherectomy. *J Am Coll Cardiol* 1993;21:15-25.
36. Morice MC, Serruys PW, Sousa JE, et al. A randomized comparison of a sirolimus-eluting stent with a standard stent for coronary revascularization. *N Engl J Med* 2002;346:1773-1780.
37. Moses JW, Leon MB, Popma JJ, et al. Sirolimus-eluting stents versus standard stents in patients with stenosis in a native coronary artery. *N Engl J Med* 2003;349:1315-1323.
38. Stone GW, Ellis SG, Cox DA, et al. A Polymer-Based, Paclitaxel-Eluting Stent in Patients with Coronary Artery Disease. *N Engl J Med* 2004;350:221-231.
39. Kirtane AJ, Gupta A, Iyengar S, et al. Safety and efficacy of drug-eluting and bare metal stents: comprehensive meta-analysis of randomized trials and observational studies. *Circulation* 2009;119:3198-3206.
40. Leon MB, Kandzari DE, Eisenstein EL, et al. Late safety, efficacy, and cost-effectiveness of a zotarolimus-eluting stent compared with a paclitaxel-eluting stent in patients with de novo coronary lesions: 2-year follow-up from the ENDEAVOR IV trial (Randomized, Controlled Trial of the Medtronic Endeavor Drug [ABT-578] Eluting Coronary Stent System Versus the Taxus Paclitaxel-Eluting Coronary Stent System in De Novo Native Coronary Artery Lesions). *JACC Cardiovasc Interv* 2009;2:1208-1218.
41. Leon MB, Mauri L, Popma JJ, et al. A randomized comparison of the ENDEAVOR zotarolimus-eluting stent versus the TAXUS paclitaxel-eluting stent in de novo native coronary lesions 12-month

- outcomes from the ENDEAVOR IV trial. *J Am Coll Cardiol* 2010; 55:543-554.
42. Stone GW, Rizvi A, Newman W, et al. Everolimus-eluting versus paclitaxel-eluting stents in coronary artery disease. *N Engl J Med* 2010;362:1663-1674.
 43. Marx SO, Marks AR. Bench to bedside: the development of rapamycin and its application to stent restenosis. *Circulation* 2001; 104:852-855.
 44. Daemen J, Serruys PW. Drug-eluting stent update 2007: part I. A survey of current and future generation drug-eluting stents: meaningful advances or more of the same? *Circulation* 2007;116:316-328.
 45. Axel DI, Kunert W, Goggelmann C, et al. Paclitaxel inhibits arterial smooth muscle cell proliferation and migration in vitro and in vivo using local drug delivery. *Circulation* 1997;96:636-645.
 46. Sollott SJ, Cheng L, Pauly RR, et al. Taxol inhibits neointimal smooth muscle cell accumulation after angioplasty in the rat. *J Clin Invest* 1995;95:1869-1876.
 47. Belotti D, Vergani V, Drudis T, et al. The microtubule-affecting drug paclitaxel has antiangiogenic activity. *Clin Cancer Res* 1996;2:1843-1849.
 48. Hui A, Min WX, Tang J, Cruz TF. Inhibition of activator protein 1 activity by paclitaxel suppresses interleukin-1-induced collagenase and stromelysin expression by bovine chondrocytes. *Arthritis Rheum* 1998;41:869-876.
 49. Lansky AJ, Costa RA, Mintz GS, et al. Non-polymer-based paclitaxel-coated coronary stents for the treatment of patients with de novo coronary lesions: angiographic follow-up of the DELIVER clinical trial. *Circulation* 2004;109:1948-1954.
 50. Finn AV, Joner M, Nakazawa G, et al. Pathological correlates of late drug-eluting stent thrombosis: strut coverage as a marker of endothelialization. *Circulation* 2007;115:2435-2441.
 51. Finn AV, Kolodgie FD, Harnek J, et al. Differential response of delayed healing and persistent inflammation at sites of overlapping sirolimus- or paclitaxel-eluting stents. *Circulation* 2005;112:270-278.
 52. Virmani R, Guagliumi G, Farb A, et al. Localized hypersensitivity and late coronary thrombosis secondary to a sirolimus-eluting stent: should we be cautious? *Circulation* 2004;109:701-705.
 53. Joner M, Nakazawa G, Finn AV, et al. Endothelial cell recovery between comparator polymer-based drug-eluting stents. *J Am Coll Cardiol* 2008;52:333-342.
 54. Cook S, Ladich E, Nakazawa G, et al. Correlation of intravascular ultrasound findings with histopathological analysis of thrombus aspirates in patients with very late drug-eluting stent thrombosis. *Circulation* 2009;120:391-399.
 55. Guagliumi G, Sirbu V, Musumeci G, et al. Examination of the in vivo mechanisms of late drug-eluting stent thrombosis: findings from optical coherence tomography and intravascular ultrasound imaging. *JACC Cardiovasc Interv* 2012;5:12-20.
 56. Gallo R, Padurean A, Jayaraman T, et al. Inhibition of intimal thickening after balloon angioplasty in porcine coronary arteries by targeting regulators of the cell cycle. *Circulation* 1999;99:2164-2170.
 57. Suzuki T, Kopia G, Hayashi S-I, et al. Stent-based delivery of sirolimus reduces neointimal formation in a porcine coronary model. *Circulation* 2001;104:1188-1193.
 58. Sousa JE, Costa MA, Abizaid A, et al. Four-year angiographic and intravascular ultrasound follow-up of patients treated with sirolimus-eluting stents. *Circulation* 2005;111:2326-2329.
 59. Moses JW, Leon MB, Popma JJ, et al. Sirolimus-eluting stents versus standard stents in patients with stenosis in a native coronary artery. *N Engl J Med* 2003;349:1315-1323.
 60. Caixeta A, Leon MB, Lansky AJ, et al. 5-year clinical outcomes after sirolimus-eluting stent implantation insights from a patient-level pooled analysis of 4 randomized trials comparing sirolimus-eluting stents with bare-metal stents. *J Am Coll Cardiol* 2009;54:894-902.
 61. Drachman DE, Edelman ER, Seifert P, et al. Neointimal thickening after stent delivery of paclitaxel: change in composition and arrest of growth over six months. *J Am Coll Cardiol* 2000;36:2325-2332.
 62. Farb A, Heller PF, Shroff S, et al. Pathological analysis of local delivery of paclitaxel via a polymer-coated stent. *Circulation* 2001;104:473-479.
 63. Grube E, Silber S, Hauptmann KE, et al. TAXUS I: six- and twelve-month results from a randomized, double-blind trial on a slow-release paclitaxel-eluting stent for de novo coronary lesions. *Circulation* 2003;107:38-42.
 64. Colombo A, Drzewiecki J, Banning A, et al. Randomized study to assess the effectiveness of slow- and moderate-release polymer-based paclitaxel-eluting stents for coronary artery lesions. *Circulation* 2003;108:788-794.
 65. Stone GW, Ellis SG, Cox DA, et al. A polymer-based, paclitaxel-eluting stent in patients with coronary artery disease. *N Engl J Med* 2004;350:221-231.
 66. Stone GW, Ellis SG, Cannon L, et al. Comparison of a polymer-based paclitaxel-eluting stent with a bare metal stent in patients with complex coronary artery disease: a randomized controlled trial. *JAMA* 2005;294:1215-1223.
 67. Dawkins KD, Grube E, Guagliumi G, et al. Clinical efficacy of polymer-based paclitaxel-eluting stents in the treatment of complex, long coronary artery lesions from a multicenter, randomized trial: support for the use of drug-eluting stents in contemporary clinical practice. *Circulation* 2005;112:3306-3313.
 68. Morice M-C, Colombo A, Meier B, et al. Sirolimus- vs paclitaxel-eluting stents in De Novo Coronary Artery Lesions: The REALITY Trial: A Randomized Controlled Trial. *JAMA* 2006;295:895-904.
 69. Lee SW, Park SW, Kim YH, et al. A randomized comparison of sirolimus- versus Paclitaxel-eluting stent implantation in patients with diabetes mellitus. *J Am Coll Cardiol* 2008;52:727-733.
 70. Galloe AM, Thuesen L, Kelbaek H, et al. Comparison of Paclitaxel- and Sirolimus-Eluting Stents in Everyday Clinical Practice: The SORT OUT II Randomized Trial. *JAMA* 2008;299:409-416.
 71. Petronio AS, De Carlo M, Branchitta G, et al. randomized comparison of sirolimus and paclitaxel drug-eluting stents for long lesions in the left anterior descending artery: an intravascular ultrasound study. *J Am Coll Cardiol* 2007;49:539-546.
 72. Turco MA, Ormiston JA, Popma JJ, et al. Polymer-based, paclitaxel-eluting TAXUS Liberté stent in de novo lesions: the pivotal TAXUS ATLAS trial. *J Am Coll Cardiol* 2007;49:1676-1683.
 73. Kereiakes DJ, Cannon LA, Feldman RL, et al. Clinical and angiographic outcomes after treatment of de novo coronary stenoses with a novel platinum chromium thin-strut stent: primary results of the PERSEUS (Prospective Evaluation in a Randomized Trial of the Safety and Efficacy of the Use of the TAXUS Element Paclitaxel-Eluting Coronary Stent System) trial. *J Am Coll Cardiol* 2010;56:264-271.
 74. Cannon LA, Kereiakes DJ, Mann T, et al. A prospective evaluation of the safety and efficacy of TAXUS Element paclitaxel-eluting coronary stent implantation for the treatment of de novo coronary artery lesions in small vessels: the PERSEUS Small Vessel trial. *EuroIntervention* 2011;6:920-927, 1-2.
 75. Cook S, Wenaweser P, Togni M, et al. Incomplete stent apposition and very late stent thrombosis after drug-eluting stent implantation. *Circulation* 2007;115:2426-2434.
 76. Liu T-Y, Lin W-C, Huang L-Y, Chen S-Y, Yang M-C. Surface characteristics and hemocompatibility of PAN/PVDF blend membranes. *Polymers Adv Technol* 2005;16:413-419.
 77. Lin JC, Tiong SL, Chen CY. Surface characterization and platelet adhesion studies on fluorocarbons prepared by plasma-induced graft polymerization. *J Biomater Sci Polym Ed* 2000;11:701-714.
 78. Serruys PW, Ong AT, Piek JJ, et al. A randomized comparison of a durable polymer Everolimus-eluting stent with a bare metal coronary stent: The SPIRIT first trial. *EuroIntervention* 2005;1:58-65.
 79. Grube E. SPIRIT V Diabetic RCT: 9 Month Angiographic and 1 Year Clinical Follow-Up. Washington, DC: Transcatheter Cardiovascular Therapeutics; 2010.

80. Smits PC. *COMPARE Trial: 3-Year Follow-Up*. San Francisco, CA: Transcatheter Cardiovascular Therapeutics; 2011.
81. Ribichini F. *EXECUTIVE: A Prospective Randomized Trial of Everolimus-Eluting Stents Compared to Paclitaxel-Eluting Stents in Patients with Multivessel Coronary Artery Disease*. Washington, DC: Transcatheter Cardiovascular Therapeutics; 2010.
82. Serruys PW, Ruygrok P, Neuzner J, et al. A randomised comparison of an everolimus-eluting coronary stent with a paclitaxel-eluting coronary stent: the SPIRIT II trial. *EuroIntervention* 2006;2:286-294.
83. Stone GW, Midei M, Newman W, et al. Comparison of an everolimus-eluting stent and a paclitaxel-eluting stent in patients with coronary artery disease: a randomized trial. *JAMA* 2008;299:1903-1913.
84. Serruys PW, Silber S, Garg S, et al. Comparison of zotarolimus-eluting and everolimus-eluting coronary stents. *N Engl J Med* 2010;363:136-146.
85. Stone GW. *A Large Scale Randomized Comparison of Everolimus-Eluting and Paclitaxel-Eluting Stents: Three-Year Outcomes from the SPIRIT IV Trial*. San Francisco, CA: Transcatheter Cardiovascular Therapeutics; 2011.
86. Byrne RA, Kastrati A, Kufner S, et al. Randomized, non-inferiority trial of three limus agent-eluting stents with different polymer coatings: the Intracoronary Stenting and Angiographic Results: Test Efficacy of 3 Limus-Eluting Stents (ISAR-TEST-4) Trial. *Eur Heart J* 2009;30:2441-2449.
87. Jensen LO, Thayssen P, Hansen HS, et al. Randomized comparison of everolimus-eluting and sirolimus-eluting stents in patients treated with percutaneous coronary intervention (The SORT OUT IV Trial). *Circulation* 2012;125(10):1246-1255.
88. Kim WJ, Lee SW, Park SW, et al. Randomized comparison of everolimus-eluting stent versus sirolimus-eluting stent implantation for de novo coronary artery disease in patients with diabetes mellitus (ESSENCE-DIABETES): results from the ESSENCE-DIABETES trial. *Circulation* 2011;124:886-892.
89. Park KW, Chae IH, Lim DS, et al. Everolimus-eluting versus sirolimus-eluting stents in patients undergoing percutaneous coronary intervention: the EXCELLENT (Efficacy of Xience/Promus Versus Cypher to Reduce Late Loss After Stenting) randomized trial. *J Am Coll Cardiol* 2011;58:1844-1854.
90. Wiemer M, Serruys PW, Miquel-Hebert K, et al. Five-year long-term clinical follow-up of the XIENCE V everolimus eluting coronary stent system in the treatment of patients with de novo coronary artery lesions: the SPIRIT FIRST trial. *Catheter Cardiovasc Interv* 2010;75:997-1003.
91. Stone GW. *Comparison of Everolimus-Eluting and Paclitaxel-Eluting Stents: First Report of the Five-Year Clinical Outcomes from the SPIRIT III Trial*. San Francisco, CA: Transcatheter Cardiovascular Therapeutics; 2011.
92. Kedhi E. *COMPARE-AMI: Two-Year Outcomes from a Prospective Randomized Trial of Everolimus-Eluting Stents Compared to Paclitaxel-Eluting Stents in Patients with STEMI*. Washington, DC: Transcatheter Cardiovascular Therapeutics; 2010.
93. Kaiser C, Galatius S, Erne P, et al. Drug-eluting versus bare-metal stents in large coronary arteries. *N Engl J Med* 2010;363:2310-2319.
94. Byrne RA, Kastrati A, Massberg S, et al. Biodegradable polymer versus permanent polymer drug-eluting stents and everolimus- versus sirolimus-eluting stents in patients with coronary artery disease: 3-year outcomes from a randomized clinical trial. *J Am Coll Cardiol* 2011;58:1325-1331.
95. Sabate M, Cequier A, Iniguez A, et al. Rationale and design of the EXAMINATION trial: a randomised comparison between everolimus-eluting stents and cobalt-chromium bare-metal stents in ST-elevation myocardial infarction. *EuroIntervention* 2011;7:977-984.
96. Park DW, Kim YH, Song HG, et al. Comparison of everolimus- and sirolimus-eluting stents in patients with long coronary artery lesions: a randomized LONG-DES-III (Percutaneous Treatment of LONG Native Coronary Lesions With Drug-Eluting Stent-III) Trial. *JACC Cardiovasc Interv* 2011;4:1096-1103.
97. Silber S, Windecker S, Vranckx P, Serruys PW. Unrestricted randomised use of two new generation drug-eluting coronary stents: 2-year patient-related versus stent-related outcomes from the RESOLUTE All Comers trial. *Lancet* 2011;377:1241-1247.
98. von Birgelen C, Basalus MWZ, Tandjung K, et al. A randomized controlled trial in second-generation zotarolimus-eluting resolute stents versus everolimus-eluting xience v stents in real-world patients: The TWENTE Trial. *J Am Coll Cardiol* 2012;59(15):1350-1361.
99. Stone GW, Teirstein PS, Meredith IT, et al. A prospective, randomized evaluation of a novel everolimus-eluting coronary stent: the PLATINUM (a Prospective, Randomized, Multicenter Trial to Assess an Everolimus-Eluting Coronary Stent System [PROMUS Element] for the Treatment of Up to Two de novo Coronary Artery Lesions) trial. *J Am Coll Cardiol* 2011;57:1700-1708.
100. Baber U, Mehran R, Sharma SK, et al. Impact of the everolimus-eluting stent on stent thrombosis: a meta-analysis of 13 randomized trials. *J Am Coll Cardiol* 2011;58:1569-1577.
101. Raber L, Magro M, Stefanini GG, et al. Very late coronary stent thrombosis of a newer generation everolimus-eluting stent compared with early generation drug-eluting stents: a prospective cohort study. *Circulation* 2012;125(9):1110-1121.
102. Palmerini T, Biondi-Zoccai G, Riva DD, et al. Stent thrombosis with drug-eluting and bare-metal stents: evidence from a comprehensive network meta-analysis. *Lancet* 2012;379(9824):1393-1402.
103. Whelan DM, van der Giessen WJ, Krabbendam SC, et al. Biocompatibility of phosphorylcholine coated stents in normal porcine coronary arteries. *Heart* 2000;83:338-345.
104. Meredith IT, Ormiston J, Whitbourn R, et al. First-in-human study of the Endeavor ABT-578-eluting phosphorylcholine-encapsulated stent system in de novo native coronary artery lesions: Endeavor I Trial. *EuroIntervention* 2005;1:157-164.
105. Eisenstein EL, Wijns W, Fajadet J, et al. Long-term clinical and economic analysis of the Endeavor drug-eluting stent versus the Driver bare-metal stent: 4-year results from the ENDEAVOR II trial (Randomized Controlled Trial to Evaluate the Safety and Efficacy of the Medtronic AVE ABT-578 Eluting Driver Coronary Stent in De Novo Native Coronary Artery Lesions). *JACC Cardiovasc Interv* 2009;2:1178-1187.
106. Fajadet J, Wijns W, Laarman GJ, et al. Randomized, double-blind, multicenter study of the Endeavor zotarolimus-eluting phosphorylcholine-encapsulated stent for treatment of native coronary artery lesions. Clinical and angiographic results of the ENDEAVOR II Trial. *Minerva Cardioangiol* 2007;55:1-18.
107. Kandzari DE, Leon MB, Popma JJ, et al. Comparison of zotarolimus-eluting and sirolimus-eluting stents in patients with native coronary artery disease: a randomized controlled trial. *J Am Coll Cardiol* 2006;48:2440-2447.
108. Pinto DS, Stone GW, Ellis SG, et al. Impact of routine angiographic follow-up on the clinical benefits of paclitaxel-eluting stents: results from the TAXUS-IV trial. *J Am Coll Cardiol* 2006;48:32-36.
109. Kandzari D. The "Final" Five-Year Follow-up from the ENDEAVOR IV Trial. *Comparing a Zotarolimus-Eluting Stent with a Paclitaxel-Eluting Stent*. San Francisco, CA: Transcatheter Cardiovascular Therapeutics; 2011.
110. Rasmussen K, Maeng M, Kaltoft A, et al. Efficacy and safety of zotarolimus-eluting and sirolimus-eluting coronary stents in routine clinical care (SORT OUT III): a randomised controlled superiority trial. *Lancet* 2010;375:1090-1099.
111. Byrne RA, Kastrati A, Tiroch K, et al. 2-year clinical and angiographic outcomes from a randomized trial of polymer-free dual drug-eluting stents versus polymer-based Cypher and Endeavor [corrected] drug-eluting stents. *J Am Coll Cardiol* 2010;55:2536-2543.
112. Byrne RA, Mehilli J, Iijima R, et al. A polymer-free dual drug-eluting stent in patients with coronary artery disease: a randomized trial vs. polymer-based drug-eluting stents. *Eur Heart J* 2009;30:923-931.

113. Park SJ. *The ZEST Trial: 2-Year Final Outcomes*. Washington, DC: Transcatheter Cardiovascular Therapeutics; 2010.
114. Park DW, Kim YH, Yun SC, et al. Comparison of zotarolimus-eluting stents with sirolimus- and paclitaxel-eluting stents for coronary revascularization: the ZEST (comparison of the efficacy and safety of zotarolimus-eluting stent with sirolimus-eluting and paclitaxel-eluting stent for coronary lesions) randomized trial. *J Am Coll Cardiol* 2010;56:1187-1195.
115. Mauri L, Massaro JM, Jiang S, et al. Long-term clinical outcomes with zotarolimus-eluting versus bare-metal coronary stents. *JACC Cardiovasc Interv* 2010;3:1240-1249.
116. Wenaweser P, Daemen J, Zwahlen M, et al. Incidence and correlates of drug-eluting stent thrombosis in routine clinical practice. 4-year results from a large 2-institutional cohort study. *J Am Coll Cardiol* 2008;52:1134-1140.
117. Meredith IT, Worthley S, Whitbourn R, et al. Clinical and angiographic results with the next-generation resolute stent system: a prospective, multicenter, first-in-human trial. *JACC Cardiovasc Interv* 2009;2:977-985.
118. Meredith IT, Worthley SG, Whitbourn R, et al. Long-term clinical outcomes with the next-generation Resolute Stent System: a report of the two-year follow-up from the RESOLUTE clinical trial. *Eurointervention* 2010;5:692-697.
119. Chevalier B, Silber S, Park SJ, et al. Randomized comparison of the Nobori Biolimus A9-eluting coronary stent with the Taxus Liberte paclitaxel-eluting coronary stent in patients with stenosis in native coronary arteries: the NOBORI 1 trial-Phase 2. *Circ Cardiovasc Interv* 2009;2:188-195.
120. Ostojic M, Sagic D, Beleslin B, et al. First clinical comparison of Nobori -Biolimus A9 eluting stents with Cypher- Sirolimus eluting stents: Nobori Core nine months angiographic and one year clinical outcomes. *Eurointervention* 2008;3:574-579.
121. Kadota K, Muramatsu T, Iwabuchi M, et al. Randomized comparison of the nobori biolimus A9-eluting stent with the sirolimus-eluting stent in patients with stenosis in native coronary arteries. *Catheter Cardiovasc Interv* 2012;80(5):789-796.
122. Grube E, Hauptmann KE, Buellesfeld L, Lim V, Abizaid A. Six-month results of a randomized study to evaluate safety and efficacy of a Biolimus A9 eluting stent with a biodegradable polymer coating. *EuroIntervention* 2005;1:53-57.
123. Windecker S, Serruys PW, Wandel S, et al. Biolimus-eluting stent with biodegradable polymer versus sirolimus-eluting stent with durable polymer for coronary revascularisation (LEADERS): a randomised non-inferiority trial. *Lancet* 2008;372:1163-1173.
124. Stefanini GG, Kalesan B, Serruys PW, et al. Long-term clinical outcomes of biodegradable polymer biolimus-eluting stents versus durable polymer sirolimus-eluting stents in patients with coronary artery disease (LEADERS): 4 year follow-up of a randomised non-inferiority trial. *Lancet* 2011;378:1940-1948.
125. Stone GW, Moses JW, Ellis SG, et al. Safety and efficacy of sirolimus- and paclitaxel-eluting coronary stents. *N Engl J Med* 2007;356:998-1008.
126. Win HK, Caldera AE, Maresk K, et al. Clinical outcomes and stent thrombosis following off-label use of drug-eluting stents. *JAMA* 2007;297:2001-2009.
127. Stettler C, Wandel S, Allemann S, et al. Outcomes associated with drug-eluting and bare-metal stents: a collaborative network meta-analysis. *Lancet* 2007;370:937-948.
128. Lagerqvist B, James SK, Stenestrand U, et al. Long-term outcomes with drug-eluting stents versus bare-metal stents in Sweden. *N Engl J Med* 2007;356:1009-1019.
129. James SK, Stenestrand U, Lindback J, et al. Long-term safety and efficacy of drug-eluting versus bare-metal stents in Sweden. *N Engl J Med* 2009;360:1933-1945.
130. Douglas PS, Brennan JM, Anstrom KJ, et al. Clinical effectiveness of coronary stents in elderly persons: results from 262,700 Medicare patients in the American College of Cardiology-National Cardiovascular Data Registry. *J Am Coll Cardiol* 2009;53:1629-1641.
131. Mauri L, Silbaugh TS, Garg P, et al. Drug-eluting or bare-metal stents for acute myocardial infarction. *N Engl J Med* 2008;359:1330-1342.
132. Tamaï H, Igaki K, Kyo E, et al. Initial and 6-month results of biodegradable poly-L-lactic acid coronary stents in humans. *Circulation* 2000;102:399-404.
133. Ormiston JA, Serruys PW, Regar E, et al. A bioabsorbable everolimus-eluting coronary stent system for patients with single de-novo coronary artery lesions (ABSORB): a prospective open-label trial. *Lancet* 2008;371:899-907.
134. Tanimoto S, Serruys PW, Thuesen L, et al. Comparison of in vivo acute stent recoil between the bioabsorbable everolimus-eluting coronary stent and the everolimus-eluting cobalt chromium coronary stent: insights from the ABSORB and SPIRIT trials. *Catheter Cardiovasc Interv* 2007;70:515-523.
135. Tanimoto S, Bruining N, van Domburg RT, et al. Late stent recoil of the bioabsorbable everolimus-eluting coronary stent and its relationship with plaque morphology. *J Am Coll Cardiol* 2008;52:1616-1620.
136. Nieman K, Dudek D, Ormiston J, Thuesen L, Serruys PW. ABSORB Cohort A Trial: Five Year Clinical and MSCT Results of the ABSORB Bioresorbable Everolimus Eluting Vascular Scaffold. Orlando, FL: American Heart Association Scientific Sessions; 2011.
137. Serruys PW, Onuma Y, Ormiston JA, et al. Evaluation of the second generation of a bioresorbable everolimus drug-eluting vascular scaffold for treatment of de novo coronary artery stenosis: six-month clinical and imaging outcomes. *Circulation* 2010;122:2301-2312.
138. Serruys PW, Nieman K, Onuma Y. ABSORB Cohort B Trial: 18 Month Clinical and MSCT Results of the ABSORB Bioresorbable Everolimus Eluting Vascular Scaffold. San Francisco, CA: Transcatheter Cardiovascular Therapeutics; 2011.
139. Serruys PW, Onuma Y, Dudek D, et al. Evaluation of the second generation of a bioresorbable everolimus-eluting vascular scaffold for the treatment of de novo coronary artery stenosis: 12-month clinical and imaging outcomes. *J Am Coll Cardiol* 2011;58:1578-1588.
140. Karrison GJ, Morice MC, Benveniste E, et al. Intracoronary stent implantation without ultrasound guidance and with replacement of conventional anticoagulation by antiplatelet therapy. 30-day clinical outcome of the French Multicenter Registry. *Circulation* 1996;94:1519-1527.
141. Dirschinger J, Kastrati A, Neumann FJ, et al. Influence of balloon pressure during stent placement in native coronary arteries on early and late angiographic and clinical outcome: A randomized evaluation of high-pressure inflation. *Circulation* 1999;100:918-923.
142. Hoffmann R, Haager P, Mintz GS, et al. The impact of high pressure vs low pressure stent implantation on intimal hyperplasia and follow-up lumen dimensions; results of a randomized trial. *Eur Heart J* 2001;22:2015-2024.
143. Fujii K, Carlier SG, Mintz GS, et al. Stent underexpansion and residual reference segment stenosis are related to stent thrombosis after sirolimus-eluting stent implantation: An intravascular ultrasound study. *J Am Coll Cardiol* 2005;45:995-998.
144. Fujii K, Mintz GS, Kobayashi Y, et al. Contribution of stent underexpansion to recurrence after sirolimus-eluting stent implantation for in-stent restenosis. *Circulation* 2004;109:1085-1088.
145. de Ribamar Costa J Jr, Mintz GS, Carlier SG, et al. Intravascular ultrasonic assessment of stent diameters derived from manufacturer's compliance charts. *Am J Cardiol* 2005;96:74-78.
146. Moussa I, Di Mario C, Reimers B, Akiyama T, Tobis J, Colombo A. Subacute stent thrombosis in the era of intravascular ultrasound-guided coronary stenting without anticoagulation: frequency, predictors and clinical outcome. *J Am Coll Cardiol* 1997;29:6-12.
147. Cutlip DE, Baim DS, Ho KK, et al. Stent thrombosis in the modern era: a pooled analysis of multicenter coronary stent clinical trials. *Circulation* 2001;103:1967-1971.

148. Fitzgerald PJ, Oshima A, Hayase M, et al. Final results of the Can Routine Ultrasound Influence Stent Expansion (CRUISE) study. *Circulation* 2000;102:523-530.
149. Mudra H, di Mario C, de Jaegere P, et al. Randomized comparison of coronary stent implantation under ultrasound or angiographic guidance to reduce stent restenosis (OPTICUS Study). *Circulation* 2001;104:1343-1349.
150. Oemrawsingh PV, Mintz GS, Schlij MJ, Zwiderman AH, Jukema JW, van der Wall EE. Intravascular ultrasound guidance improves angiographic and clinical outcome of stent implantation for long coronary artery stenoses: final results of a randomized comparison with angiographic guidance (TULIP Study). *Circulation* 2003;107:62-67.
151. Colombo A. *AVIO: A Prospective Randomized Trial of Intravascular Ultrasound-Guided Compared to Angiography-Guided Stent Implantation in Complex Coronary Lesions*. Washington, DC: Transcatheter Cardiovascular Therapeutics; 2010.
152. Pijls NHJ, van Schaardenburgh P, Manoharan G, et al. Percutaneous coronary intervention of functionally nonsignificant stenosis: 5-year follow-up of the DEFER study. *J Am Coll Cardiol* 2007;49:2105-2111.
153. Tonino PAL, De Bruyne B, Pijls NHJ, et al. Fractional flow reserve versus angiography for guiding percutaneous coronary intervention. *N Engl J Med* 2009;360:213-224.
154. Tonino PA, De Bruyne B, Pijls NH, et al. Fractional flow reserve versus angiography for guiding percutaneous coronary intervention. *N Engl J Med* 2009;360:213-224.
155. Fearon WF, Bornschein B, Tonino PA, et al. Economic evaluation of fractional flow reserve-guided percutaneous coronary intervention in patients with multivessel disease. *Circulation* 2010;122:2545-2550.
156. Hanekamp CE, Koolen JJ, Pijls NH, Michels HR, Bonnier HJ. Comparison of quantitative coronary angiography, intravascular ultrasound, and coronary pressure measurement to assess optimum stent deployment. *Circulation* 1999;99:1015-1021.
157. Koo BK, Kang HJ, Youn TJ, et al. Physiologic assessment of jailed side branch lesions using fractional flow reserve. *J Am Coll Cardiol* 2005;46:633-637.
158. Prati F, Di Mario C, Moussa I, et al. In-stent neointimal proliferation correlates with the amount of residual plaque burden outside the stent: an intravascular ultrasound study. *Circulation* 1999;99:1011-1014.
159. Hoffmann R, Mintz GS, Popma JJ, et al. Treatment of calcified coronary lesions with Palmaz-Schatz stents. An intravascular ultrasound study. *Eur Heart J* 1998;19:1224-1231.
160. Hoffmann R, Mintz GS, Kent KM, et al. Comparative early and nine-month results of rotational atherectomy, stents, and the combination of both for calcified lesions in large coronary arteries. *Am J Cardiol* 1998;81:552-557.
161. Henneke KH, Regar E, Konig A, et al. Impact of target lesion calcification on coronary stent expansion after rotational atherectomy. *Am Heart J* 1999;137:93-99.
162. Stankovic G, Colombo A, Bersin R, et al. Comparison of directional coronary atherectomy and stenting versus stenting alone for the treatment of de novo and restenotic coronary artery narrowing. *Am J Cardiol* 2004;93:953-958.
163. Richardt G. *ROTAXUS: A Prospective, Randomized Trial of High-Speed Rotational Atherectomy Prior to Paclitaxel-Eluting Stent Implantation in Complex Calcified Coronary Artery Lesions*. San Francisco, CA: Transcatheter Cardiovascular Therapeutics; 2011.
164. Burzotta F, Parma A, Pristipino C, et al. Angiographic and clinical outcome of invasively managed patients with thrombosed coronary bare metal or drug-eluting stents: the OPTIMIST study. *Eur Heart J* 2008;29:3011-3021.
165. Holmes DR, Jr., Kereiakes DJ, Garg S, et al. Stent thrombosis. *J Am Coll Cardiol* 2010;56:1357-1365.
166. Iakovou I, Schmidt T, Bonizzoni E, et al. Incidence, predictors, and outcome of thrombosis after successful implantation of drug-eluting stents. *JAMA* 2005;293:2126-2130.
167. van Werkum JW, Heestermaas AA, de Korte FJ, et al. Long-term clinical outcome after a first angiographically confirmed coronary stent thrombosis: an analysis of 431 cases. *Circulation* 2009;119:828-834.
168. Cutlip DE, Windecker S, Mehran R, et al. Clinical end points in coronary stent trials: a case for standardized definitions. *Circulation* 2007;115:2344-2351.
169. Doyle B, Rihal CS, O'Sullivan CJ, et al. Outcomes of stent thrombosis and restenosis during extended follow-up of patients treated with bare-metal coronary stents. *Circulation* 2007;116:2391-2398.
170. Ellis SG, Stone GW, Cox DA, et al. Long-term safety and efficacy with paclitaxel-eluting stents: 5-year final results of the TAXUS IV clinical trial (TAXUS IV-SR: Treatment of De Novo Coronary Disease Using a Single Paclitaxel-Eluting Stent). *JACC Cardiovasc Interv* 2009;2:1248-1259.
171. Weisz G, Leon MB, Holmes DR Jr, et al. Five-year follow-up after sirolimus-eluting stent implantation results of the SIRIUS (Sirolimus-Eluting Stent in De-Novo Native Coronary Lesions) Trial. *J Am Coll Cardiol* 2009;53:1488-1497.
172. Stone GW, Moses JW, Ellis SG, et al. Safety and efficacy of sirolimus- and paclitaxel-eluting coronary stents. *N Engl J Med* 2007;356:998-1008.
173. Mauri L, Hsieh WH, Massaro JM, Ho KK, D'Agostino R, Cutlip DE. Stent thrombosis in randomized clinical trials of drug-eluting stents. *N Engl J Med* 2007;356:1020-1029.
174. Stone GW, Ellis SG, Colombo A, et al. Offsetting impact of thrombosis and restenosis on the occurrence of death and myocardial infarction after paclitaxel-eluting and bare metal stent implantation. *Circulation* 2007;115:2842-2847.
175. Kirtane AJ, Stone GW. How to minimize stent thrombosis. *Circulation* 2011;124:1283-1287.
176. Aoki J, Lansky AJ, Mehran R, et al. Early stent thrombosis in patients with acute coronary syndromes treated with drug-eluting and bare metal stents: the Acute Catheterization and Urgent Intervention Triage Strategy trial. *Circulation* 2009;119:687-698.
177. Kuchulakanti PK, Chu WW, Torguson R, et al. Correlates and long-term outcomes of angiographically proven stent thrombosis with sirolimus- and paclitaxel-eluting stents. *Circulation* 2006;113:1108-1113.
178. Mishkel GJ, Moore AL, Markwell S, Shelton ME. Correlates of late and very late thrombosis of drug eluting stents. *Am Heart J* 2008;156:141-147.
179. Cayla G, Hulot JS, O'Connor SA, et al. Clinical, angiographic, and genetic factors associated with early coronary stent thrombosis. *JAMA* 2011;306:1765-1774.
180. Stone GW. *ADAPT-DES: A Large-Scale, Prospective, Multicenter Registry Examining the Relationship of Platelet Responsiveness to Stent Thrombosis After DES Implantation*. San Francisco, CA: Transcatheter Cardiovascular Therapeutics; 2011.
181. Wiviott SD, Braunwald E, McCabe CH, et al. Prasugrel versus clopidogrel in patients with acute coronary syndromes. *N Engl J Med* 2007;357:2001-2015.
182. Wallentin L, Becker RC, Budaj A, et al. Ticagrelor versus clopidogrel in patients with acute coronary syndromes. *N Engl J Med* 2009;361:1045-1057.
183. Mehta SR, Tanguay JF, Eikelboom JW, et al. Double-dose versus standard-dose clopidogrel and high-dose versus low-dose aspirin in individuals undergoing percutaneous coronary intervention for acute coronary syndromes (CURRENT-OASIS 7): a randomised factorial trial. *Lancet* 2010;376:1233-1243.
184. Price MJ, Berger PB, Teirstein PS, et al. Standard- vs high-dose clopidogrel based on platelet function testing after percutaneous coronary intervention: the GRAVITAS randomized trial. *JAMA* 2011;305:1097-1105.
185. Fujii K, Carlier SG, Mintz GS, et al. Stent underexpansion and residual reference segment stenosis are related to stent thrombosis after sirolimus-eluting stent implantation: an intravascular ultrasound study. *J Am Coll Cardiol* 2005;45:995-998.

186. Liu X, Doi H, Maehara A, et al. A volumetric intravascular ultrasound comparison of early drug-eluting stent thrombosis versus restenosis. *JACC Cardiovasc Interv* 2009;2:428-434.
187. Okabe T, Mintz GS, Buch AN, et al. Intravascular ultrasound parameters associated with stent thrombosis after drug-eluting stent deployment. *Am J Cardiol* 2007;100:615-620.
188. Cook S, Ladich E, Nakazawa G, et al. Correlation of intravascular ultrasound findings with histopathological analysis of thrombus aspirates in patients with very late drug-eluting stent thrombosis. *Circulation* 2009;120:391-399.
189. Aoki J, Nakazawa G, Tanabe K, et al. Incidence and clinical impact of coronary stent fracture after sirolimus-eluting stent implantation. *Catheter Cardiovasc Interv* 2007;69:380-386.
190. Kandzari DE, Rao SV, Moses JW, et al. Clinical and angiographic outcomes with sirolimus-eluting stents in total coronary occlusions: the ACROSS/TOSCA-4 (Approaches to Chronic Occlusions With Sirolimus-Eluting Stents/Total Occlusion Study of Coronary Arteries-4) trial. *JACC Cardiovasc Interv* 2009;2:97-106.
191. Nakazawa G, Finn AV, Vorpahl M, et al. Incidence and predictors of drug-eluting stent fracture in human coronary artery a pathologic analysis. *J Am Coll Cardiol* 2009;54:1924-1931.
192. Cook S, Wenaweser P, Togni M, et al. Incomplete stent apposition and very late stent thrombosis after drug-eluting stent implantation. *Circulation* 2007;115:2426-2434.
193. Hassan AK, Bergeheanu SC, Stijnen T, et al. Late stent malapposition risk is higher after drug-eluting stent compared with bare-metal stent implantation and associates with late stent thrombosis. *Eur Heart J* 2010;31:1172-1180.
194. Joner M, Finn AV, Farb A, et al. Pathology of drug-eluting stents in humans: delayed healing and late thrombotic risk. *J Am Coll Cardiol* 2006;48:193-202.
195. Kotani J, Awata M, Nanto S, et al. Incomplete neointimal coverage of sirolimus-eluting stents: angioscopic findings. *J Am Coll Cardiol* 2006;47:2108-2111.
196. Higo T, Ueda Y, Oyabu J, et al. Atherosclerotic and thrombogenic neointima formed over sirolimus drug-eluting stent: an angioscopic study. *JACC Cardiovasc Imaging* 2009;2:616-624.
197. Roy P, Steinberg DH, Sushinsky SJ, et al. The potential clinical utility of intravascular ultrasound guidance in patients undergoing percutaneous coronary intervention with drug-eluting stents. *Eur Heart J* 2008;29:1851-1857.
198. Hall P, Nakamura S, Matello L, et al. A randomized comparison of combined ticlopidine and aspirin therapy versus aspirin therapy alone after successful intravascular ultrasound-guided stent implantation. *Circulation* 1996;93:215-222.
199. Cannon CP, Harrington RA, James S, et al. Comparison of ticagrelor with clopidogrel in patients with a planned invasive strategy for acute coronary syndromes (PLATO): a randomised double-blind study. *Lancet* 2010;375:283-293.
200. Montalescot G, Wiwiot SD, Braunwald E, et al. Prasugrel compared with clopidogrel in patients undergoing percutaneous coronary intervention for ST-elevation myocardial infarction (TRITON-TIMI 38): double-blind, randomised controlled trial. *Lancet* 2009;373:723-731.
201. Airolidi F, Colombo A, Morici N, et al. Incidence and predictors of drug-eluting stent thrombosis during and after discontinuation of thienopyridine treatment. *Circulation* 2007;116:745-754.
202. van Werkum JW, Heestermans AA, Zomer AC, et al. Predictors of coronary stent thrombosis: the Dutch Stent Thrombosis Registry. *J Am Coll Cardiol* 2009;53:1399-1409.
203. Brar SS, Kim J, Brar SK, et al. Long-term outcomes by clopidogrel duration and stent type in a diabetic population with de novo coronary artery lesions. *J Am Coll Cardiol* 2008;51:2220-2227.
204. Eisenstein EL, Anstrom KJ, Kong DF, et al. Clopidogrel use and long-term clinical outcomes after drug-eluting stent implantation. *JAMA* 2007;297:159-168.
205. Harjai KJ, Shenoy C, Orshaw P, Boura J. Dual antiplatelet therapy for more than 12 months after percutaneous coronary intervention: insights from the Guthrie PCI Registry. *Heart* 2009;95:1579-1586.
206. Park SJ, Park DW, Kim YH, et al. Duration of dual antiplatelet therapy after implantation of drug-eluting stents. *N Engl J Med* 2010;362:1374-1382.
207. Valgimigli M, Campo G, Monti M, et al. Short-versus long-term duration of dual antiplatelet therapy after coronary stenting: a randomized multicentre trial. *Circulation* 2012.
208. Gwon HC, Hahn JY, Park KW, et al. Six-month versus 12-month dual antiplatelet therapy after implantation of drug-eluting stents: The Efficacy of Xience/Promus Versus Cypher to Reduce Late Loss After Stenting (EXCELLENT) Randomized, Multicenter Study. *Circulation* 2012;125:505-513.
209. Mauri L, Kereiakes DJ, Normand SL, et al. Rationale and design of the dual antiplatelet therapy study, a prospective, multicenter, randomized, double-blind trial to assess the effectiveness and safety of 12 versus 30 months of dual antiplatelet therapy in subjects undergoing percutaneous coronary intervention with either drug-eluting stent or bare metal stent placement for the treatment of coronary artery lesions. *Am Heart J* 2010;160:1035-1041, 1041 e1.
210. Rinfret S, Cutlip DE, Katsiyannis PT, et al. Rheolytic thrombectomy and platelet glycoprotein IIb/IIIa blockade for stent thrombosis. *Catheter Cardiovasc Interv* 2002;57:24-30.
211. Mintz GS, Popma JJ, Hong MK, et al. Intravascular ultrasound to discern device-specific effects and mechanisms of restenosis. *Am J Cardiol* 1996;78:18-22.
212. Chen MS, John JM, Chew DP, Lee DS, Ellis SG, Bhatt DL. Bare metal stent restenosis is not a benign clinical entity. *Am Heart J* 2006;151:1260-1264.
213. Nayak AK, Kawamura A, Nesto RW, et al. Myocardial infarction as a presentation of clinical in-stent restenosis. *Circ J* 2006;70:1026-1029.
214. Doi H, Maehara A, Mintz GS, et al. Impact of post-intervention minimal stent area on 9-month follow-up patency of paclitaxel-eluting stents: an integrated intravascular ultrasound analysis from the TAXUS IV, V, and VI and TAXUS ATLAS Workhorse, Long Lesion, and Direct Stent Trials. *JACC Cardiovasc Interv* 2009;2:1269-1275.
215. Morino Y, Honda Y, Okura H, et al. An optimal diagnostic threshold for minimal stent area to predict target lesion revascularization following stent implantation in native coronary lesions. *Am J Cardiol* 2001;88:301-303.
216. Sonoda S, Morino Y, Ako J, et al. Impact of final stent dimensions on long-term results following sirolimus-eluting stent implantation: serial intravascular ultrasound analysis from the SIRIUS trial. *J Am Coll Cardiol* 2004;43:1959-1963.
217. Liu J, Maehara A, Mintz GS, et al. An integrated TAXUS IV, V, and VI intravascular ultrasound analysis of the predictors of edge restenosis after bare metal or paclitaxel-eluting stents. *Am J Cardiol* 2009;103:501-506.
218. Sakurai R, Ako J, Morino Y, et al. Predictors of edge stenosis following sirolimus-eluting stent deployment (a quantitative intravascular ultrasound analysis from the SIRIUS trial). *Am J Cardiol* 2005;96:1251-1253.
219. Costa MA, Angiolillo DJ, Tannenbaum M, et al. Impact of stent deployment procedural factors on long-term effectiveness and safety of sirolimus-eluting stents (final results of the multicenter prospective STLLR trial). *Am J Cardiol* 2008;101:1704-1711.
220. Popma JJ, Tiroch K, Almonacid A, Cohen S, Kandzari DE, Leon MB. A qualitative and quantitative angiographic analysis of stent fracture late following sirolimus-eluting stent implantation. *Am J Cardiol* 2009;103:923-929.
221. Koster R, Vieluf D, Kiehn M, et al. Nickel and molybdenum contact allergies in patients with coronary in-stent restenosis. *Lancet* 2000;356:1895-1897.

222. Nakazawa G, Tanabe K, Aoki J, et al. Sirolimus-eluting stents suppress neointimal formation irrespective of metallic allergy. *Circ J* 2008;72:893–896.
223. Norgaz T, Hobikoglu G, Serdar ZA, et al. Is there a link between nickel allergy and coronary stent restenosis? *Tohoku J Exp Med* 2005;206:243–246.
224. Hanioka N, Matsumoto K, Saito Y, Narimatsu S. Functional characterization of CYP2C8.13 and CYP2C8.14: catalytic activities toward paclitaxel. *Basic Clin Pharmacol Toxicol* 2010;107:565–569.
225. Huang S, Houghton PJ. Mechanisms of resistance to rapamycins. *Drug Resist Update* 2001;4:378–391.
226. Monraats PS, de Vries FJ, de Jong LW, et al. Inflammation and apoptosis genes and the risk of restenosis after percutaneous coronary intervention. *Pharmacogenet Genomics* 2006;16:747–754.
227. Vogiatzi K, Apostolakis S, Voudris V, Thomopoulou S, Kochiadakis GE, Spandidos DA. Interleukin 8 gene polymorphisms and susceptibility to restenosis after percutaneous coronary intervention. *J Thromb Thrombolysis* 2010;29:134–140.
228. Nakazawa G, Ladich E, Finn AV, Virmani R. Pathophysiology of vascular healing and stent mediated arterial injury. *EuroIntervention* 2008;4(suppl C):C7–C10.
229. Cutlip DE, Chauhan MS, Baim DS, et al. Clinical restenosis after coronary stenting: perspectives from multicenter clinical trials. *J Am Coll Cardiol* 2002;40:2082–2089.
230. Elezi S, Kastrati A, Pache J, et al. Diabetes mellitus and the clinical and angiographic outcome after coronary stent placement. *J Am Coll Cardiol* 1998;32:1866–1873.
231. Kastrati A, Schomig A, Elezi S, et al. Predictive factors of restenosis after coronary stent placement. *J Am Coll Cardiol* 1997;30:1428–1436.
232. Mercado N, Boersma E, Wijns W, et al. Clinical and quantitative coronary angiographic predictors of coronary restenosis: a comparative analysis from the balloon-to-stent era. *J Am Coll Cardiol* 2001;38:645–652.
233. Singh M, Gersh BJ, McClelland RL, et al. Clinical and angiographic predictors of restenosis after percutaneous coronary intervention: insights from the Prevention of Restenosis With TraniLAST and Its Outcomes (PRESTO) trial. *Circulation* 2004;109:2727–2731.
234. West NE, Ruygrok PN, Disco CM, et al. Clinical and angiographic predictors of restenosis after stent deployment in diabetic patients. *Circulation* 2004;109:867–873.
235. Lemos PA, Hoye A, Goedhart D, et al. Clinical, angiographic, and procedural predictors of angiographic restenosis after sirolimus-eluting stent implantation in complex patients: an evaluation from the Rapamycin-Eluting Stent Evaluated At Rotterdam Cardiology Hospital (RESEARCH) study. *Circulation* 2004;109:1366–1370.
236. Beohar N, Davidson CJ, Kip KE, et al. Outcomes and complications associated with off-label and untested use of drug-eluting stents. *JAMA* 2007;297:1992–2000.
237. Ko DT, Chiu M, Guo H, et al. Safety and effectiveness of drug-eluting and bare-metal stents for patients with off- and on-label indications. *J Am Coll Cardiol* 2009;53:1773–1782.
238. Marroquin OC, Selzer F, Mulukutla SR, et al. A comparison of bare-metal and drug-eluting stents for off-label indications. *N Engl J Med* 2008;358:342–352.
239. Sanidas E, Mintz G, Maehara A, et al. Intracoronary ultrasound for optimizing stent implantation. *Curr Cardiovasc Imaging Rep* 2010;3:230–236.
240. Parise H, Maehara A, Stone GW, Leon MB, Mintz GS. Meta-analysis of randomized studies comparing intravascular ultrasound versus angiographic guidance of percutaneous coronary intervention in pre-drug-eluting stent era. *Am J Cardiol* 2011;107:374–382.
241. Kimura T, Yokoi H, Nakagawa Y, et al. Three-year follow-up after implantation of metallic coronary-artery stents. *N Engl J Med* 1996;334:561–566.
242. Mintz GS, Weissman NJ. Intravascular ultrasound in the drug-eluting stent era. *J Am Coll Cardiol* 2006;48:421–429.
243. Hasegawa K, Ito M, Oda M, et al. Intravascular ultrasonic imaging of vulnerable plaque in a bare metal stent 10 years after implantation. *Circulation* 2010;122:1341.
244. Byrne RA. ISAR-TEST-4: Two-Year Clinical and Angiographic Outcomes from a Prospective Randomized Trial of Everolimus-Eluting Stents and Sirolimus-Eluting Stents in Patients with Coronary Artery Disease. Washington, DC: Transcatheter Cardiovascular Therapeutics; 2010.
245. Claessen BE, Beijk MA, Legrand V, et al. Two-year clinical, angiographic, and intravascular ultrasound follow-up of the XIENCE V everolimus-eluting stent in the treatment of patients with de novo native coronary artery lesions: the SPIRIT II trial. *Circ Cardiovasc Interv* 2009;2:339–347.
246. Raber L. SIRTAX-LATE: Five-Year Clinical and Angiographic Follow-up from a Prospective Randomized Trial of Sirolimus-Eluting and Paclitaxel-Eluting Stents. Washington, DC: Transcatheter Cardiovascular Therapeutics; 2010.
247. Tsuchida K, Piek JJ, Neumann FJ, et al. One-year results of a durable polymer everolimus-eluting stent in de novo coronary narrowings (The SPIRIT FIRST Trial). *EuroIntervention* 2005;1:266–272.
248. Tsuchida K, Serruys PW, Bruining N, et al. Two-year serial coronary angiographic and intravascular ultrasound analysis of in-stent angiographic late lumen loss and ultrasonic neointimal volume from the TAXUS II trial. *Am J Cardiol* 2007;99:607–615.
249. Caixeta A, Lansky AJ, Serruys PW. Clinical follow-up 3 years after everolimus-eluting and paclitaxel-eluting stents. *J Am Coll Cardiol Intv* 2010;In Press.
250. Raber L. SIRTAX-LATE: Five-Year Clinical and Angiographic Follow-up from a Prospective Randomized Trial of Sirolimus-Eluting and Paclitaxel-Eluting Stents. San Francisco, CA: Transcatheter Cardiovascular Therapeutics; 2009.
251. Stone GW. SPIRIT IV: Two-Year Results from a Prospective Randomized Trial of Everolimus-Eluting Stents Compared to Paclitaxel-Eluting Stents in Patients with Coronary Artery Disease. Washington, DC: Transcatheter Cardiovascular Therapeutics; 2010.
252. Elezi S, Kastrati A, Hadamitzky M, Dirschinger J, Neumann FJ, Schomig A. Clinical and angiographic follow-up after balloon angioplasty with provisional stenting for coronary in-stent restenosis. *Catheter Cardiovasc Interv* 1999;48:151–156.
253. Mehran R, Dangas G, Abizaid AS, et al. Angiographic patterns of in-stent restenosis: classification and implications for long-term outcome. *Circulation* 1999;100:1872–1878.
254. Mintz GS. Features and parameters of drug-eluting stent deployment discoverable by intravascular ultrasound. *Am J Cardiol* 2007;100:26M–35M.
255. Mintz GS, Mehran R, Waksman R, et al. Treatment of in-stent restenosis. *Semin Interv Cardiol* 1998;3:117–121.
256. Leon MB, Teirstein PS, Moses JW, et al. Localized intracoronary gamma-radiation therapy to inhibit the recurrence of restenosis after stenting. *N Engl J Med* 2001;344:250–256.
257. Waksman R, Raizner AE, Yeung AC, Lansky AJ, Vandertie L. Use of localized intracoronary beta radiation in treatment of in-stent restenosis: the INHIBIT randomised controlled trial. *Lancet* 2002;359:551–557.
258. Grise MA, Massullo V, Jani S, et al. Five-year clinical follow-up after intracoronary radiation: results of a randomized clinical trial. *Circulation* 2002;105:2737–2740.
259. Waksman R, Ajani AE, White RL, et al. Five-year follow-up after intracoronary gamma radiation therapy for in-stent restenosis. *Circulation* 2004;109:340–344.
260. Holmes DR, Jr., Teirstein P, Satler L, et al. Sirolimus-eluting stents vs vascular brachytherapy for in-stent restenosis within bare-metal stents: the SISR randomized trial. *JAMA* 2006;295:1264–1273.
261. Stone GW, Ellis SG, O'Shaughnessy CD, et al. Paclitaxel-eluting stents vs vascular brachytherapy for in-stent restenosis within bare-metal stents: the TAXUS V ISR randomized trial. *JAMA* 2006;295:1253–1263.

262. Ellis SG, O'Shaughnessy CD, Martin SL, et al. Two-year clinical outcomes after paclitaxel-eluting stent or brachytherapy treatment for bare metal stent restenosis: the TAXUS V ISR trial. *Eur Heart J* 2008;29:1625-1634.
263. Holmes DR, Jr, Teirstein PS, Satler L, et al. 3-year follow-up of the SISR (Sirolimus-Eluting Stents Versus Vascular Brachytherapy for In-Stent Restenosis) trial. *JACC Cardiovasc Interv* 2008;1:439-448.
264. Kastrati A, Mehilli J, von Beckerath N, et al. Sirolimus-eluting stent or paclitaxel-eluting stent vs balloon angioplasty for prevention of recurrences in patients with coronary in-stent restenosis: a randomized controlled trial. *JAMA* 2005;293:165-171.
265. Rittger H, Brachmann J, Sinha AM, et al. A randomized, multicenter, single-blinded trial comparing paclitaxel-coated balloon angioplasty with plain balloon angioplasty in drug-eluting stent restenosis: The PEPCAD-DES Study. *J Am Coll Cardiol* 2012 Apr 10;59(15):1377-82.
266. Chevalier B. *CRISTAL: A Prospective Randomized Trial of Sirolimus-Eluting Stents Compared to Balloon Angioplasty for Restenosis of Drug-Eluting Coronary Stents*. Washington, DC: Transcatheter Cardiovascular Therapeutics; 2010.
267. Mehilli J, Byrne RA, Tiroch K, et al. Randomized trial of paclitaxel- versus sirolimus-eluting stents for treatment of coronary restenosis in sirolimus-eluting stents: the ISAR-DESIRE 2 (Intracoronary Stenting and Angiographic Results: Drug Eluting Stents for In-Stent Restenosis 2) study. *J Am Coll Cardiol* 2010;55:2710-2716.
268. Song HG, Park DW, Kim YH, et al. Randomized trial of optimal treatment strategies for in-stent restenosis after drug-eluting stent implantation. *J Am Coll Cardiol* 2012;59:1093-1100.
269. Tamhane U, Meier P, Chetcuti S, et al. Efficacy of cilostazol in reducing restenosis in patients undergoing contemporary stent based PCI: a meta-analysis of randomised controlled trials. *EuroIntervention* 2009;5:384-393.
270. Bonello L, Kaneshige K, De Labriolle A, et al. Vascular brachytherapy for patients with drug-eluting stent restenosis. *J Intervent Cardiol* 2008;21:528-534.
271. Rodriguez AE, Granada JF, Rodriguez-Alemparte M, et al. Oral rapamycin after coronary bare-metal stent implantation to prevent restenosis: the Prospective, Randomized Oral Rapamycin in Argentina (ORAR II) Study. *J Am Coll Cardiol* 2006;47:1522-1529.
272. Fischman DL, Savage MP, Leon MB, et al. Fate of lesion-related side branches after coronary artery stenting. *J Am Coll Cardiol* 1993;22:1641-1646.
273. Aliabadi D, Tilli FV, Bowers TR, et al. Incidence and angiographic predictors of side branch occlusion following high-pressure intracoronary stenting. *Am J Cardiol* 1997;80:994-997.
274. Poerner TC, Králev S, Voelker W, et al. Natural history of small and medium-sized side branches after coronary stent implantation. *Am Heart J* 2002;143:627-635.
275. Lefevre T, Louvard Y, Morice MC, et al. Stenting of bifurcation lesions: classification, treatments, and results. *Catheter Cardiovasc Interv* 2000;49:274-283.
276. Brunel P, Lefevre T, Darremont O, Louvard Y. Provisional T-stenting and kissing balloon in the treatment of coronary bifurcation lesions: results of the French multicenter "TULIPE" study. *Catheter Cardiovasc Interv* 2006;68:67-73.
277. Steigen TK, Maeng M, Wiseth R, et al. Randomized study on simple versus complex stenting of coronary artery bifurcation lesions: The Nordic Bifurcation Study. *Circulation* 2006;114:1955-1961.
278. Holmes DR Jr, Garratt KN, Popma J. Stent Complications. *J Invasive Cardiol* 1998;10:385-395.
279. Kozman H, Wiseman AH, Cook JR. Long-term outcome following coronary stent embolization or misdeployment. *Am J Cardiol* 2001;88:630-634.
280. Alfonso F, Martinez D, Hernandez R, et al. Stent embolization during intracoronary stenting. *Am J Cardiol* 1996;78:833-835.
281. Bolte J, Neumann U, Pfafferoth C, et al. Incidence, management, and outcome of stent loss during intracoronary stenting. *Am J Cardiol* 2001;88:565-567.
282. Eggebrecht H, Haude M, von Birgelen C, et al. Nonsurgical retrieval of embolized coronary stents. *Catheter Cardiovasc Interv* 2000;51:432-440.
283. Ellis SG, Ajluni S, Arnold AZ, et al. Increased coronary perforation in the new device era. Incidence, classification, management, and outcome. *Circulation* 1994;90:2725-2730.
284. Dippel EJ, Kereiakes DJ, Tramuta DA, et al. Coronary perforation during percutaneous coronary intervention in the era of abciximab platelet glycoprotein IIb/IIIa blockade: an algorithm for percutaneous management. *Catheter Cardiovasc Interv* 2001;52:279-286.
285. Thibodeaux LC, James KV, Lohr JM, Welling RE, Roberts WH. Infection of endovascular stents in a swine model. *Am J Surg* 1996;172:151-154.
286. Leroy O, Martin E, Prat A, et al. Fatal infection of coronary stent implantation. *Cathet Cardiovasc Diagn* 1996;39:168-170; discussion 171.
287. Dieter RS. Coronary artery stent infection. *Clin Cardiol* 2000;23:808-810.
288. Romero-Brufau S, Best PJ, Holmes DR Jr, et al. Outcomes After Coronary Stent Implantation in Patients With Metal Allergy. *Circ Cardiovasc Interv* 2012 Apr;5(2):220-6.
289. Keeley EC, Boura JA, Grines CL. Primary angioplasty versus intravenous thrombolytic therapy for acute myocardial infarction: a quantitative review of 23 randomised trials. *Lancet* 2003;361:13-20.
290. De Luca G, Suryapranata H, Stone GW, et al. Coronary stenting versus balloon angioplasty for acute myocardial infarction: a meta-regression analysis of randomized trials. *Int J Cardiol* 2008;126:37-44.
291. Nakazawa G, Finn AV, Joner M, et al. Delayed arterial healing and increased late stent thrombosis at culprit sites after drug-eluting stent placement for acute myocardial infarction patients: an autopsy study. *Circulation* 2008;118:1138-1145.
292. Stone GW, Witzenbichler B, Guagliumi G, et al. Bivalirudin during primary PCI in acute myocardial infarction. *N Engl J Med* 2008;358:2218-2230.
293. Sianos G, Papafaklis MI, Daemen J, et al. Angiographic stent thrombosis after routine use of drug-eluting stents in st-segment elevation myocardial infarction: the importance of thrombus burden. *J Am Coll Cardiol* 2007;50:573-583.
294. Stone GW. *HORIZONS-AMI: Three-Year Follow-up from a Prospective Randomized Trial of Antithrombin Strategies and Drug-Eluting Stents in Patients with Acute Myocardial Infarction Undergoing Primary Angioplasty*. Washington, DC: Transcatheter Cardiovascular Therapeutics; 2010.
295. Stone GW, Lansky AJ, Pocock SJ, et al. Paclitaxel-eluting stents versus bare-metal stents in acute myocardial infarction. *N Engl J Med* 2009;360:1946-1959.
296. Stone GW, Parise H, Witzenbichler B, et al. Selection criteria for drug-eluting versus bare-metal stents and the impact of routine angiographic follow-up: 2-year insights from the HORIZONS-AMI (Harmonizing Outcomes With Revascularization and Stents in Acute Myocardial Infarction) trial. *J Am Coll Cardiol* 2010;56:1597-1604.
297. Brar SS, Leon MB, Stone GW, et al. Use of drug-eluting stents in acute myocardial infarction: a systematic review and meta-analysis. *J Am Coll Cardiol* 2009;53:1677-1689.
298. Kalesan B, Pilgrim T, Heinemann K, et al. Comparison of drug-eluting stents with bare metal stents in patients with ST-segment elevation myocardial infarction. *Eur Heart J* 2012.
299. Topol EJ. Coronary angioplasty for acute myocardial infarction. *Ann Intern Med* 1988;109:970-980.
300. Spertus JA, Kettelkamp R, Vance C, et al. Prevalence, predictors, and outcomes of premature discontinuation of thienopyridine therapy after drug-eluting stent placement: results from the PREMIER registry. *Circulation* 2006;113:2803-2809.

301. Fajadet J, Wijns W, Laarman GJ, et al. Randomized, double-blind, multicenter study of the Endeavor zotarolimus-eluting phosphorylcholine-encapsulated stent for treatment of native coronary artery lesions: clinical and angiographic results of the ENDEAVOR II trial. *Circulation* 2006;114:798-806.
302. Hermiller JB, Raizner A, Cannon L, et al. Outcomes with the polymer-based paclitaxel-eluting TAXUS stent in patients with diabetes mellitus: the TAXUS-IV trial. *J Am Coll Cardiol* 2005;45:1172-1179.
303. Moussa I, Leon MB, Baim DS, et al. Impact of sirolimus-eluting stents on outcome in diabetic patients: a SIRIUS (SIrolImUS-coated Bx Velocity balloon-expandable stent in the treatment of patients with de novo coronary artery lesions) substudy. *Circulation* 2004;109:2273-2278.
304. Dawkins KD, Stone GW, Colombo A, et al. Integrated analysis of medically treated diabetic patients in the TAXUS(R) program: benefits across stent platforms, paclitaxel release formulations, and diabetic treatments. *EuroIntervention* 2006;2:61-68.
305. Mitsuuchi Y, Johnson SW, Selvakumaran M, Williams SJ, Hamilton TC, Testa JR. The phosphatidylinositol 3-kinase/AKT signal transduction pathway plays a critical role in the expression of p21WAF1/CIP1/SDI1 induced by cisplatin and paclitaxel. *Cancer Res* 2000;60:5390-5394.
306. Rocic P. Differential phosphoinositide 3-kinase signaling: implications for PTCA? *Am J Physiol Heart Circ Physiol* 2009;297:H1970-H1971.
307. Morice MC, Colombo A, Meier B, et al. Sirolimus- vs paclitaxel-eluting stents in de novo coronary artery lesions: the REALITY trial: a randomized controlled trial. *JAMA* 2006;295:895-904.
308. Dibra A, Kastrati A, Mehilli J, et al. Paclitaxel-eluting or sirolimus-eluting stents to prevent restenosis in diabetic patients. *N Engl J Med* 2005;353:663-670.
309. Stone GW, Kedhi E, Kereiakes DJ, et al. Differential clinical responses to everolimus-eluting and Paclitaxel-eluting coronary stents in patients with and without diabetes mellitus. *Circulation*. 2011 Aug 23;124(8):893-900.
310. *Instructions for Use: Resolute Integrity Zotarolimus-Eluting Coronary Stent System*; 2012. Medtronic, Santa Rosa, CA
311. Daemen J, Boersma E, Flather M, et al. Long-term safety and efficacy of percutaneous coronary intervention with stenting and coronary artery bypass surgery for multivessel coronary artery disease: a meta-analysis with 5-year patient-level data from the ARTS, ERACI-II, MASS-II, and SoS trials. *Circulation* 2008;118:1146-1154.
312. Kapur A, Hall RJ, Malik IS, et al. Randomized comparison of percutaneous coronary intervention with coronary artery bypass grafting in diabetic patients. 1-year results of the CARDia (Coronary Artery Revascularization in Diabetes) trial. *J Am Coll Cardiol* 2010;55:432-440.
313. Farkouh ME, Dangas G, Leon MB, et al. Design of the Future Revascularization Evaluation in patients with Diabetes mellitus: Optimal management of Multivessel disease (FREEDOM) Trial. *Am Heart J* 2008;155:215-223.
314. Hlatky MA, Boothroyd DB, Bravata DM, et al. Coronary artery bypass surgery compared with percutaneous coronary interventions for multivessel disease: a collaborative analysis of individual patient data from ten randomised trials. *Lancet* 2009;373:1190-1197.
315. O'Keefe JH Jr, Hartzler GO, Rutherford BD, et al. Left main coronary angioplasty: early and late results of 127 acute and elective procedures. *Am J Cardiol* 1989;64:144-147.
316. Tan WA, Tamai H, Park SJ, et al. Long-term clinical outcomes after unprotected left main trunk percutaneous revascularization in 279 patients. *Circulation* 2001;104:1609-1614.
317. Erglis A, Narbutė I, Kumsars I, et al. A randomized comparison of paclitaxel-eluting stents versus bare-metal stents for treatment of unprotected left main coronary artery stenosis. *J Am Coll Cardiol* 2007;50:491-497.
318. Mehilli J, Kastrati A, Byrne RA, et al. Paclitaxel- versus sirolimus-eluting stents for unprotected left main coronary artery disease. *J Am Coll Cardiol* 2009;53:1760-1768.
319. Buszman PE, Kiesz SR, Bochenek A, et al. Acute and late outcomes of unprotected left main stenting in comparison with surgical revascularization. *J Am Coll Cardiol* 2008;51:538-545.
320. Serruys PW, Morice MC, Kappetein AP, et al. Percutaneous coronary intervention versus coronary-artery bypass grafting for severe coronary artery disease. *N Engl J Med* 2009;360:961-972.
321. Serruys P. *Optimal Revascularization Strategy in Patients with Three-vessel Disease and/or Left Main Disease*. The 4-year Outcomes of the SYNTAX Trial. 25th EACTS Annual Meeting, Lisbon, Portugal; 2011.
322. Morice MC. *The 4-year Outcomes of the SYNTAX Trial in the Subset of Patients with Left Main Disease*. San Francisco, CA: Transcatheter Cardiovascular Therapeutics; 2011.
323. Serruys PW. *DES in Complex Multivessel Disease: The Syntax Trial at 4 Years: Overall Results and Breakdown of the 3VD Cohort*. San Francisco, CA: Transcatheter Cardiovascular Therapeutics; 2011.
324. Chen SL, Chen JP, Mintz G, et al. Comparison between the NERS (New Risk Stratification) score and the SYNTAX (Synergy between Percutaneous Coronary Intervention with Taxus and Cardiac Surgery) score in outcome prediction for unprotected left main stenting. *JACC Cardiovasc Interv* 2010;3:632-641.
325. Garg S, Sarno G, Garcia-Garcia HM, et al. A new tool for the risk stratification of patients with complex coronary artery disease: the Clinical SYNTAX Score. *Circ Cardiovasc Interv* 2010;3:317-326.
326. Wijns W, Kolh P, Danchin N, et al. Guidelines on myocardial revascularization: The Task Force on Myocardial Revascularization of the European Society of Cardiology (ESC) and the European Association for Cardio-Thoracic Surgery (EACTS). *Eur Heart J* 2010;31:2501-2555.
327. Rassen JA, Mittleman MA, Glynn RJ, Alan Brookhart M, Schneeweiss S. Safety and effectiveness of bivalirudin in routine care of patients undergoing percutaneous coronary intervention. *Eur Heart J* 2010;31:561-572.
328. Park SJ, Kim YH, Park DW, et al. Impact of intravascular ultrasound guidance on long-term mortality in stenting for unprotected left main coronary artery stenosis. *Circ Cardiovasc Interv* 2009;2:167-177.
329. Stone GW, Kandzari DE, Mehran R, et al. Percutaneous recanalization of chronically occluded coronary arteries: a consensus document: part I. *Circulation* 2005;112:2364-2372.
330. Stone GW, Reifart NJ, Moussa I, et al. Percutaneous recanalization of chronically occluded coronary arteries: a consensus document: part II. *Circulation* 2005;112:2530-2537.
331. Suttrop MJ, Laarman GJ, Rahel BM, et al. Primary Stenting of Totally Occluded Native Coronary Arteries II (PRISON II): a randomized comparison of bare metal stent implantation with sirolimus-eluting stent implantation for the treatment of total coronary occlusions. *Circulation* 2006;114:921-928.
332. Colmenarez HJ, Escaned J, Fernandez C, et al. Efficacy and safety of drug-eluting stents in chronic total coronary occlusion recanalization: a systematic review and meta-analysis. *J Am Coll Cardiol* 2010;55:1854-1866.
333. Park HJ, Kim HY, Lee JM, et al. Randomized comparison of the efficacy and safety of zotarolimus-eluting stents vs. sirolimus-eluting stents for percutaneous coronary intervention in chronic total occlusion. *Circ J* 2012;76:868-875.
334. Werner GS, Emig U, Mutschke O, Schwarz G, Bahrman P, Figulla HR. Regression of collateral function after recanalization of chronic total coronary occlusions: a serial assessment by intracoronary pressure and Doppler recordings. *Circulation* 2003;108:2877-2882.
335. American College of Cardiology/American Heart Association Task Force on Practice Guidelines, Evidence WG:RN, Update the ACC/AHA/SCAI Guideline Update for Percutaneous Coronary Intervention WoBotWC, et al. 2007 Focused Update of the ACC/AHA/SCAI 2005 Guideline Update for Percutaneous Coronary Intervention. *J Am Coll Cardiol* 2008;51:172-209.
336. Brar SS, Gray WA, Dangas G, et al. Bifurcation stenting with drug-eluting stents: a systematic review and meta-analysis of randomised trials. *EuroIntervention* 2009;5:475-484.

337. Louvard Y, Lefevre T, Morice MC. Percutaneous coronary intervention for bifurcation coronary disease. *Heart* 2004;90:713–722.
338. Chen S, Zhang J, Ye F, et al. DK crush (double-kissing and double-crush) technique for treatment of true coronary bifurcation lesions: illustration and comparison with classic crush. *J Invasive Cardiol* 2007;19:189–193.
339. Erglis A, Kumsars I, Niemela M, et al. Randomized comparison of coronary bifurcation stenting with the crush versus the culotte technique using sirolimus eluting stents: The Nordic Stent Technique Study. *Circ Cardiovasc Interv* 2009;2:27–34.
340. Ge L, Airoidi F, Iakovou I, et al. Clinical and angiographic outcome after implantation of drug-eluting stents in bifurcation lesions with the crush stent technique: importance of final kissing balloon post-dilation. *J Am Coll Cardiol* 2005;46:613–620.
341. Fanggiday JC, Stella PR, Guyomi SH, Doevendans PA. Safety and efficacy of drug-eluting balloons in percutaneous treatment of bifurcation lesions the DEBIUT (drug-eluting balloon in bifurcation utrecht) registry. *Catheter Cardiovasc Interv* 2008;71:629–635.
342. Stella PR. *Are Drug-Eluting Balloons Likely to Assist Bifurcation Stenting? Rationale and the DEBIUT Experience*. Washington, DC: Transcatheter Cardiovascular Therapeutics; 2010.
343. Hasegawa T, Ako J, Koo BK, et al. Analysis of left main coronary artery bifurcation lesions treated with biolimus-eluting DEVAX AXCESS plus nitinol self-expanding stent: intravascular ultrasound results of the AXXENT trial. *Catheter Cardiovasc Interv* 2009;73:34–41.
344. Verheye S, Agostoni P, Dubois CL, et al. 9-month clinical, angiographic, and intravascular ultrasound results of a prospective evaluation of the Axxess self-expanding biolimus A9-eluting stent in coronary bifurcation lesions: the DIVERGE (Drug-Eluting Stent Intervention for Treating Side Branches Effectively) study. *J Am Coll Cardiol* 2009;53:1031–1039.
345. Verheye S, Grube E, Ramcharitar S, et al. First-in-man (FIM) study of the Stentys bifurcation stent—30 days results. *EuroIntervention* 2009;4:566–571.
346. Ormiston JA, Lefevre T, Grube E, Allocco DJ, Dawkins KD. First human use of the TAXUS Petal paclitaxel-eluting bifurcation stent. *EuroIntervention* 2010;6:46–53.
347. Hanekamp CE, Koolen JJ, Den Heijer P, et al. Randomized study to compare balloon angioplasty and elective stent implantation in venous bypass grafts: the Venestent study. *Catheter Cardiovasc Interv* 2003;60:452–457.
348. Savage MP, Douglas JS Jr, Fischman DL, et al. Stent placement compared with balloon angioplasty for obstructed coronary bypass grafts. Saphenous Vein De Novo Trial Investigators. *N Engl J Med* 1997;337:740–747.
349. Brilakis ES, Lichtenwalter C, de Lemos JA, et al. A randomized controlled trial of a paclitaxel-eluting stent versus a similar bare-metal stent in saphenous vein graft lesions the SOS (Stenting of Saphenous Vein Grafts) trial. *J Am Coll Cardiol* 2009;53:919–928.
350. Vermeersch P, Agostoni P, Verheye S, et al. Randomized double-blind comparison of sirolimus-eluting stent versus bare-metal stent implantation in diseased saphenous vein grafts: six-month angiographic, intravascular ultrasound, and clinical follow-up of the RRISC Trial. *J Am Coll Cardiol* 2006;48:2423–2431.
351. Vermeersch P, Agostoni P, Verheye S, et al. Increased late mortality after sirolimus-eluting stents versus bare-metal stents in diseased saphenous vein grafts: results from the randomized DELAYED RRISC Trial. *J Am Coll Cardiol* 2007;50:261–267.
352. Mehilli J, Pache J, Abdel-Wahab M, et al. Drug-eluting versus bare-metal stents in saphenous vein graft lesions (ISAR-CABG): a randomised controlled superiority trial. *Lancet* 2011;378:1071–1078.
353. Rodes-Cabau J, Bertrand OF, Larose E, et al. Comparison of plaque sealing with paclitaxel-eluting stents versus medical therapy for the treatment of moderate nonsignificant saphenous vein graft lesions: the moderate vein graft lesion stenting with the taxus stent and intravascular ultrasound (VELETI) pilot trial. *Circulation* 2009;120:1978–1986.

Grossman & Baim's Cardiac Catheterization, Angiography, and Intervention

EIGHTH EDITION

EDITOR

MAURO MOSCUCCI, MD, MBA

Professor of Medicine
Chairman, Department of Medicine (Acting)
Chief, Cardiovascular Division
University of Miami Miller School of Medicine
Miami, Florida



Wolters Kluwer | Lippincott Williams & Wilkins

Health

Philadelphia • Baltimore • New York • London
Buenos Aires • Hong Kong • Sydney • Tokyo

Acquisitions Editor: Julie Goolsby
Product Manager: Leanne Vandetty
Production Project Manager: David Orzechowski
Senior Manufacturing Manager: Beth Welsh
Design Coordinator: Joan Wendt
Production Service: Integra Software Services Pvt. Ltd

© 2014 by LIPPINCOTT WILLIAMS & WILKINS, a WOLTERS KLUWER business
Two Commerce Square
2001 Market Street
Philadelphia, PA 19103 USA
LWW.com

7th edition © 2006 by LIPPINCOTT WILLIAMS & WILKINS
6th edition © 2000 by LIPPINCOTT WILLIAMS & WILKINS
5th edition © 1996 by WILLIAMS & WILKINS

All rights reserved. This book is protected by copyright. No part of this book may be reproduced in any form by any means, including photocopying, or utilized by any information storage and retrieval system without written permission from the copyright owner, except for brief quotations embodied in critical articles and reviews. Materials appearing in this book prepared by individuals as part of their official duties as U.S. government employees are not covered by the above-mentioned copyright.
Printed in China

Library of Congress Cataloging-in-Publication Data

Cardiac catheterization, angiography, and intervention.

Grossman & Baim's cardiac catheterization, angiography, and intervention / editor, Mauro Moscucci, MD, MBA, professor of medicine, chairman, Department of Medicine, University of Miami Miller School of Medicine, Miami, Florida. — Eighth edition.

pages cm

Includes bibliographical references and index.

ISBN 978-1-4511-2740-9 (hardback)

I. Cardiac catheterization. 2. Angiography. I. Moscucci, Mauro, editor of compilation. II. Title. III. Title: Grossman and Baim's cardiac catheterization, angiography, and intervention.

RC683.5.C25C38 2013

616.1'20754—dc23

2013025399

Care has been taken to confirm the accuracy of the information presented and to describe generally accepted practices. However, the authors, editors, and publisher are not responsible for errors or omissions or for any consequences from application of the information in this book and make no warranty, expressed or implied, with respect to the currency, completeness, or accuracy of the contents of the publication. Application of the information in a particular situation remains the professional responsibility of the practitioner.

The authors, editors, and publisher have exerted every effort to ensure that drug selection and dosage set forth in this text are in accordance with current recommendations and practice at the time of publication. However, in view of ongoing research, changes in government regulations, and the constant flow of information relating to drug therapy and drug reactions, the reader is urged to check the package insert for each drug for any change in indications and dosage and for added warnings and precautions. This is particularly important when the recommended agent is a new or infrequently employed drug.

Some drugs and medical devices presented in the publication have Food and Drug Administration (FDA) clearance for limited use in restricted research settings. It is the responsibility of the health care provider to ascertain the FDA status of each drug or device planned for use in their clinical practice.

To purchase additional copies of this book, call our customer service department at (800) 638-3030 or fax orders to (301) 223-2320. International customers should call (301) 223-2300.

Visit Lippincott Williams & Wilkins on the Internet at: LWW.com. Lippincott Williams & Wilkins customer service representatives are available from 8:30 am to 6:00 pm, EST.

10 9 8 7 6 5 4

RRS1903

Contents

Contributors vii
Preface to the Eighth Edition xi
Preface to the Website to the Eighth Edition xiii
Acknowledgments xv

SECTION I GENERAL PRINCIPLES 1

1. Cardiac Catheterization History and Current Practice Standards 1
Mauro Moscucci
2. Cineangiographic Imaging, Radiation Safety, and Contrast Agents 17
Stephen Balter and Mauro Moscucci
3. Integrated Imaging Modalities in the Cardiac Catheterization Laboratory 44
Robert A. Quaife and John D. Carroll
4. Complications 77
Mauro Moscucci
5. Adjunctive Pharmacology for Cardiac Catheterization 106
Kevin Croce and Daniel I. Simon

SECTION II BASIC TECHNIQUES 139

6. Percutaneous Approach, Including Transseptal and Apical Puncture 139
Claudia A. Martinez and Mauro Moscucci
7. Radial Artery Approach 170
Mauricio G. Cohen and Sunil V. Rao
8. Cutdown Approach: Brachial, Femoral, Axillary, Aortic and Transapical 191
Ronald P. Caputo, G. Randall Green, and William Grossman
9. Diagnostic Catheterization in Childhood and Adult Congenital Heart Disease 208
Gabriele Egidy Assenza, James E. Lock, and Michael J. Landzberg

SECTION III HEMODYNAMIC PRINCIPLES 223

10. Pressure Measurement 223
Mauro Moscucci and William Grossman
11. Blood Flow Measurement: Cardiac Output and Vascular Resistance 245
Mauro Moscucci and William Grossman
12. Shunt Detection and Quantification 261
William Grossman and Mauro Moscucci
13. Calculation of Stenotic Valve Orifice Area 272
Blase A. Carabello and William Grossman

14. Pitfalls in the Evaluation of Hemodynamic Data 284
Zoltan G. Turi

SECTION IV ANGIOGRAPHIC TECHNIQUES 295

15. Coronary Angiography 295
Mauro Moscucci
16. Coronary Artery Anomalies 335
Paolo Angelini and Jorge Monge
17. Cardiac Ventriculography 354
Mauro Moscucci and Robert C. Hendel
18. Pulmonary Angiography 370
Kyung Cho and Nils Kucher
19. Angiography of the Aorta and Peripheral Arteries 399
Michael R. Jaff, John Rundback, and Kenneth Rosenfield

SECTION V EVALUATION OF CARDIAC FUNCTION 431

20. Stress Testing During Cardiac Catheterization: Exercise, Pacing,
and Dobutamine Challenge 431
William Grossman and Mauro Moscucci
21. Measurement of Ventricular Volumes, Ejection Fraction,
Mass, Wall Stress, and Regional Wall Motion 456
Michael A. Fifer and William Grossman
22. Evaluation of Systolic and Diastolic Function of the Ventricles
and Myocardium 467
William Grossman and Mauro Moscucci
23. Evaluation of Tamponade, Constrictive, and Restrictive Physiology 489
Mauro Moscucci and Barry A. Borlaug

SECTION VI SPECIAL CATHETER TECHNIQUES 505

24. Evaluation of Myocardial and Coronary Blood Flow
and Metabolism 505
Morton J. Kern and Michael J. Lim
25. Intravascular Imaging Techniques 545
Yasuhiro Honda, Peter J. Fitzgerald, and Paul G. Yock
26. Endomyocardial Biopsy 576
Sandra V. Chaparro and Mauro Moscucci
27. Percutaneous Circulatory Support: Intra-aortic Balloon Counterpulsation,
Impella, TandemHeart, and Extracorporeal Bypass 601
Daniel Burkhoff, Mauro Moscucci, and Jose P.S. Henriques

SECTION VII INTERVENTIONAL TECHNIQUES 627

28. Percutaneous Balloon Angioplasty and General Coronary Intervention 627
Abhiram Prasad and David R. Holmes
29. Atherectomy, Thrombectomy, and Distal Protection Devices 665
Robert N. Piana and Jeffrey J. Popma

30. Intervention for Acute Myocardial Infarction 697
William O'Neill
31. Coronary Stenting 710
Ajay J. Kirtane and Gregg W. Stone
32. General Overview of Interventions for Structural Heart Disease 760
Mauro Moscucci, John D. Carroll, and John G. Webb
33. Percutaneous Therapies for Valvular Heart Disease 772
Ted Feldman and Mauro Moscucci
34. Peripheral Intervention 805
Mehdi H. Shishehbor and Samir R. Kapadia
35. Intervention for Pediatric and Adult Congenital Heart Disease 838
Robert J. Sommer
36. Cardiac Cell-Based Therapy: Methods of Application and Delivery Systems 871
Joshua M. Hare, Arnon Blum, and Alan W. Heldman
37. Aortic Endovascular Grafting 891
Arash Bornak, Gilbert R. Upchurch, and Omaid C. Velazquez
38. Pericardial Interventions: Pericardiocentesis, Balloon Pericardiotomy, and Epicardial Approach to Cardiac Procedures 904
Mauro Moscucci and Juan F. Viles-Gonzalez
39. Interventions for Cardiac Arrhythmias 921
Haris M. Haqqani and Francis E. Marchlinski

SECTION VIII CLINICAL PROFILES 943

40. Profiles in Valvular Heart Disease 943
Ted Feldman, William Grossman, and Mauro Moscucci
41. Profiles in Coronary Artery Disease 970
Robert N. Piana and Aaron Kugelmass
42. Profiles in Pulmonary Hypertension and Pulmonary Embolism 991
Scott H. Visovatti and Vallerie V. Mclaughlina
43. Profiles in Cardiomyopathy and Heart Failure 1011
James C. Fang and Barry A. Borlaug
44. Profiles in Pericardial Disease 1045
John F. Robb, Roger J. Laham, and Mauro Moscucci
45. Profiles in Congenital Heart Disease 1060
Gabriele Egidy Assenza, Robert J. Sommer, and Michael J. Landzberg
46. Profiles in Peripheral Arterial Disease 1078
Christopher J. White and Stephen R. Ramee

Index 1113

41

Profiles in Coronary Artery Disease

ROBERT N. PIANA and AARON KUGELMASS

Atherosclerotic coronary artery disease (CAD) continues to be the most frequent cause of death in the United States and other developed nations.¹⁻³ Besides mortality, coronary artery disease accounts for substantial morbidity and disability. Diagnostic and therapeutic procedures for coronary disease have evolved rapidly over the last 40 years, and in parallel with advancements in medical therapy, have resulted in a significant decrease in both morbidity and mortality.⁴ The medical and procedural progress in the treatment of CAD represents one of the major accomplishments of modern medicine.

Cardiologists play a crucial role in identifying clinical CAD and developing a cogent treatment plan for an individual patient. The cardiovascular physician is charged with applying evidence and guideline-based diagnostic and treatment regimens that are individualized around anatomic and clinical characteristics. Though technical in basis, these approaches must also consider patient and family preference, and thus incorporate cultural, emotional, and value-based considerations on a background of clinical science.

This chapter is designed to provide examples of patient-centered therapy of CAD based on individual clinical and angiographic profiles. These case-based examples have been selected to demonstrate the application of clinical evidence and guideline recommendations of percutaneous coronary intervention (PCI) in the contemporary management of CAD.⁵

STABLE CORONARY ARTERY DISEASE

In patients with symptoms of stable angina, it is critical to establish a diagnosis of coronary artery insufficiency. While this may be based solely on functional noninvasive testing, coronary angiography using cardiac catheterization⁶ and, in

selected cases, coronary computed tomographic angiography (CTA)⁷ are indicated in patients with high-risk functional testing, or in whom diagnostic certainty is critical.⁶ The objective of therapy for stable CAD is to reduce not only mortality, but also prevent further progression, anginal pain, and disability.

For the majority of patients with clinically stable, symptomatic CAD, guideline-directed medical therapy (GDMT),⁸ including aspirin, beta blockade, hypertension control, and HMG-coA reductase inhibitors (statin) if tolerated, and lifestyle modification constitute the primary proven treatment modality at this time.^{9,10} In advanced CAD, significant left main CAD, and three-vessel CAD with diminished left ventricular systolic function, surgical revascularization with coronary artery bypass graft surgery (CABG) has demonstrated survival benefit over historic (limited) medical therapy.

The Clinical Outcomes Utilizing Revascularization and Aggressive DruG Evaluation (COURAGE) trial randomized patients with stable coronary artery disease (single-vessel and low-risk multivessel) to GDMT versus GDMT and PCI.¹¹ This trial demonstrated no significant reduction in cardiac mortality, myocardial infarction, need for revascularization, or long-term angina symptoms in those patients treated with PCI. These trial findings have remained controversial, but pending more contemporary trials that utilize advanced imaging techniques and drug-eluting stents (DESS), an initial therapeutic approach of guideline-directed medical therapy (GDMT) has been deemed appropriate.^{8,10} More recently, the Fractional Flow Reserve-Guided PCI versus Medical Therapy in Stable Coronary Disease (FAME 2) trial suggested that in patients with stable CAD, FFR-guided PCI of lesions (FFR < 0.80) in addition to optimal medical therapy can reduce the incidence of urgent revascularization.¹² Whether this approach will be adopted in clinical guidelines or practice remains to be determined.

For those patients who continue to experience lifestyle limiting angina despite guideline-directed medical therapy, coronary revascularization is an option. For patients with single-vessel CAD, PCI is an option and class I indication⁸ when GDMT fails in relieving symptoms. For patients with

Jeffrey J. Popma and Judith L. Meadows authored this chapter in the prior edition.

multivessel CAD, PCI and bypass surgery have been shown to have similar 5-year rates of myocardial infarction and death.¹³ However, the need for repeat revascularization is higher in patients undergoing PCI. Stratification of multivessel CAD patients for PCI on the basis of angiographic complexity can, however, select patients in whom this risk is minimal.¹⁴ In addition, a note of caution should be applied regarding the choice of revascularization for the subgroup of patients with diabetes mellitus. The Bypass Angioplasty Revascularization Investigation (BARI) trial suggested a survival benefit of CABG when compared to PCI in patients with multivessel disease and diabetes mellitus, thus raising an initial concern in this patient population.¹⁵ This concern has been confirmed by several subsequent clinical trials and registry analyses and by a meta-analysis summarizing 10 randomized clinical trials.¹⁶ More recently, in the Future Revascularization Evaluation in Patients with Diabetes Mellitus: Optimal Management of Multivessel Disease (FREEDOM) trial, patients with diabetes mellitus and multivessel coronary artery disease were randomized to revascularization with CABG or with contemporary PCI utilizing drug-eluting stents.¹⁷ The primary outcome was a combined endpoint including death from any cause, nonfatal myocardial infarction, and nonfatal stroke at 5 years. At 5-year follow-up, the primary endpoint occurred more frequently in patients undergoing PCI when compared to patients undergoing CABG. The difference between PCI and CABG was driven by a higher rate of death from any cause and nonfatal myocardial infarction in the PCI group when compared to the CABG group.¹⁷ Thus, when considering revascularization for patients with multivessel CAD, the revascularization modality should be established on the basis

of patient preference, clinical and angiographic characteristics that are determinant of acute and long-term success, and the presence of diabetes mellitus. As such, for patients with multivessel CAD requiring revascularization, collaborative, evidence-driven decision-making by cardiologists and cardiac surgeons, based on clinical and angiographic determinants of acute and long-term benefit, is essential.⁸

Invasive, as well as CT based, coronary angiography is effective in identifying fixed stenosis of coronary arteries. While important in establishing a diagnosis of CAD with attendant need for secondary prevention, it is the functional significance of individual coronary stenosis that is critical in developing a patient-centered therapeutic strategy. Physiologic stress testing, both exercise and pharmacologic, provides the physiologic basis for CAD treatment, especially revascularization. Similarly, fractional flow reserve (FFR) can provide critical functional information in the cardiac catheterization lab. This invasive technique (see Chapter 24) provides the opportunity to further assess the functional significance of specific coronary stenoses in order to direct therapy at the time of angiography. FFR has been shown to be similar to perfusion stress testing in predicting clinical events associated with a given stenosis. Conversely, FFR has been shown to be effective in identifying coronary stenoses that do not require revascularization in order to prevent CAD-related events.^{12,18,19} Like all procedures, FFR should be used judiciously. For those patients with a severe stenosis that corresponds to a territory of ischemia identified with functional testing, there is no need to perform FFR. However, in the case of intermediate stenoses, or stenoses that do not appear to be related to ischemia by functional testing, FFR should be performed in order to assess functional significance.

CASE STUDIES

CASE 41.1 A 45-year-old man with a history of hypertension, hyperlipidemia, and cigarette smoking presented to his physician with exertional dyspnea and vague chest discomfort. He was being treated with a statin, beta blockers, and an ACE inhibitor. Exercise stress testing with sestamibi scintigraphy, to 9 METS, demonstrated severe reversible perfusion defects of the inferior, inferoapical, anterior, and anteroapical segments. Rest ejection fraction was 52%, but declined to 33% during stress. There was transient left ventricular dilation. Nitrates and aspirin were added to his medical regimen. The patient was referred for coronary angiography (Figure 41.1). This demonstrated severe three-vessel CAD, with discrete lesions in the proximal right coronary and proximal to mid left anterior descending arteries. There was a more diffuse lesion in the small mid circumflex artery. Stress testing was consistent with a high risk of future events and the patient was symptomatic, despite medical therapy, necessitating revascularization. The angiographic complexity of the coronary arteries'

stenoses was limited, suggesting a successful outcome with percutaneous revascularization. A 3.0 × 20 mm drug-eluting stent was deployed in the left anterior descending artery, with excellent angiographic result. Subsequently, a 3.0 × 12 mm drug eluting stent was deployed in the right coronary artery, also with excellent result. Given the limited distribution of the left circumflex artery, and the absence of detectable ischemia in that distribution, revascularization of this artery was deferred. The patient had an uncomplicated clinical course and was discharged with dual antiplatelet therapy for 1 year.

Commentary: This case was selected to demonstrate clinical decision-making in stable coronary artery disease. The patient's left ventricular compromise and ongoing symptoms despite medical therapy were the indications for revascularization. While the patient had multivessel coronary artery disease, the angiographic complexity was limited. This suggested a favorable outcome with a percutaneous approach utilizing drug-eluting stents.

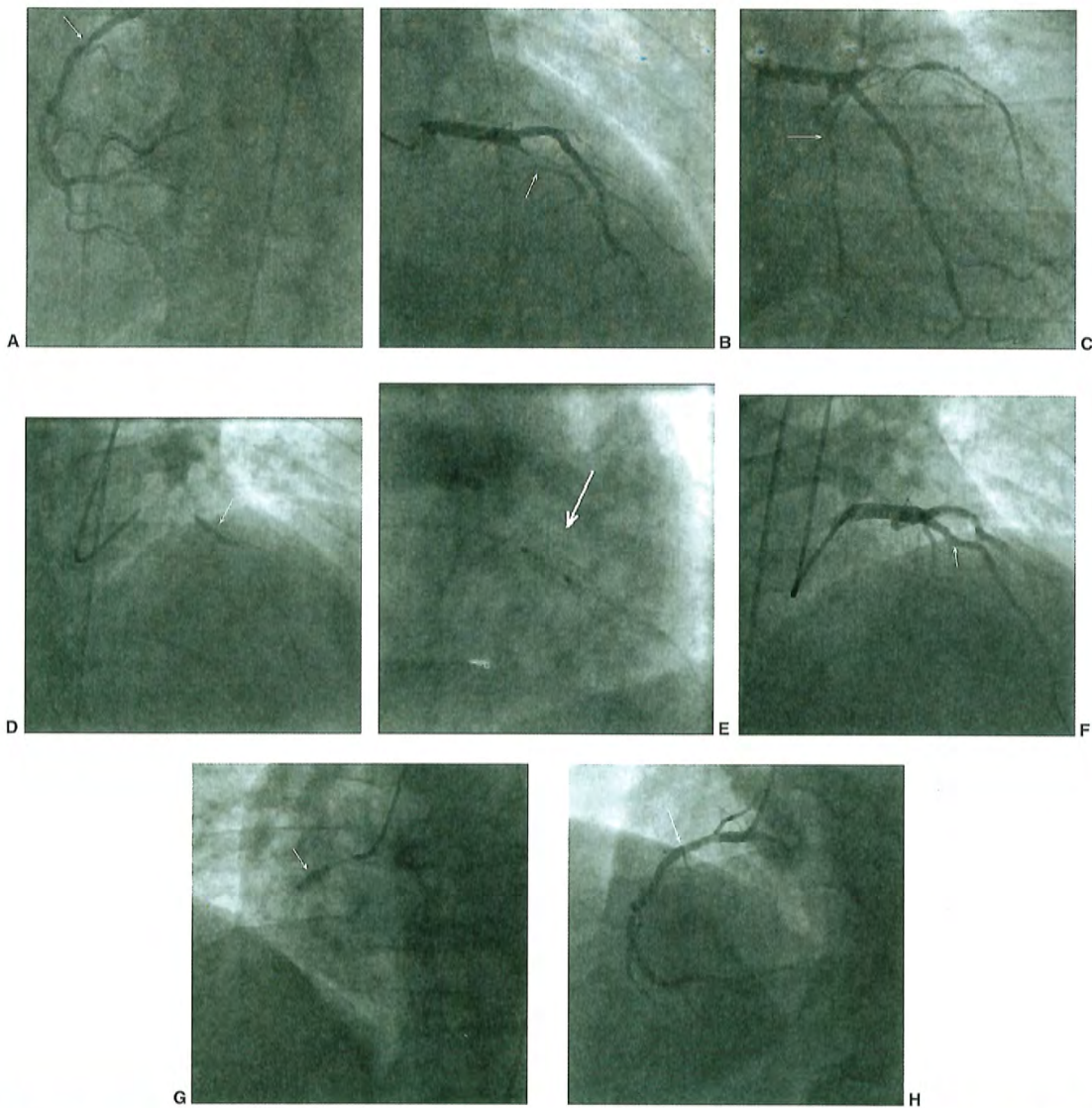


Figure 41.1 Stable coronary artery disease. **A.** Angiography of the right coronary artery in the left anterior oblique view demonstrates a severe stenosis of the proximal segment (*arrow*). **B.** Right anterior oblique with cranial angulation demonstrates severe stenosis of the proximal and mid left anterior descending artery (*arrow*). **C.** Right anterior oblique with caudal angulation demonstrates severe stenosis of the circumflex artery (*arrow*), as well as of the proximal and mid left anterior descending artery. **D.** Deployment of a 3.0×20 mm drug-eluting stent in the left anterior descending artery (*arrow*). **E.** Postdilatation with a 3.5×15 mm balloon in the left anterior descending artery stent (*arrow*). **F.** Excellent angiographic appearance of the left anterior descending artery (*arrow*). **G.** Deployment of a 3.0×12 mm drug-eluting stent in the right coronary artery (*arrow*). **H.** Excellent angiographic appearance of the right coronary artery stent (*arrow*).

ACUTE CORONARY SYNDROMES ST SEGMENT ELEVATION MYOCARDIAL INFARCTION

Indications for Angiography and Percutaneous Coronary Intervention

It has been estimated that annually 610,000 Americans will have a new myocardial infarction (MI) and 325,000 will have a recurrent MI.³ While the incidence of ST segment elevation myocardial infarction (STEMI) has been declining, the incidence of non-ST segment elevation myocardial infarction (NSTEMI) has increased.²⁰ It has been suggested that the increase in the incidence of NSTEMI might be related to improved detection with the use of more sensitive biomarkers. Over the past six decades, the annual death rate for coronary artery disease has declined progressively,^{3,21} and it is today >50% lower than it was in 1950. This reduction is owing to a combination of factors including the institution of ICU care and EMS services, the decline in the rate of STEMI,^{3,20} improved primary and secondary prevention through GDMT²⁰ and, more recently, by further evolution of reperfusion therapy for STEMI. Reperfusion therapy, by which coronary blood flow is reestablished through pharmacologic (thrombolytic) or mechanical (primary PCI) means, is the hallmark of therapy for STEMI. Primary PCI, when available in a timely fashion, is more effective than thrombolytic therapy for the treatment of STEMI (see Chapter 30), and it is associated with a significant reduction in mortality, reinfarction, and stroke. Despite these differences, the key to STEMI management depends on the timely establishment of reperfusion. Current ACC/AHA Guidelines place primary PCI as a Class I indication, when performed within 12 hours of symptom onset, when it can be performed in a timely fashion (goal within 90 minutes of medical contact), in patients ineligible for thrombolytic therapy, and in patients presenting with heart failure and/or cardiogenic shock.^{8,22} Thrombolytic therapy remains a viable and Class I indication for those patients who are unable to receive primary PCI within 120 minutes from first medical contact (FMC).²²

Technical Considerations

Angiography and PCI should be performed expeditiously, with the goal to minimize the time to successful reperfusion. To this end, as described in Chapter 30, most operators routinely perform a diagnostic angiography of the “non-culprit” vessel initially, based upon ECG localization, and then perform angiography of the culprit vessel with a guide catheter. In vessels in which thrombotic obstruction persists, initial wiring attempts with a soft, hydrophobic wire are advisable, as most lesions are soft and easily crossed. Upon crossing the lesion, confirmation of intraluminal position, either based on angiography or in the event of persistent

occlusion, by Dottering with a balloon to allow some distal flow, is advised. In patients with persistent obstruction, the balloon may be advanced distal to the obstruction and the wire removed, and careful, manual injection of contrast through the wire lumen can confirm intraluminal position. Thereafter balloon inflation of the thrombotic occlusion can proceed. In patients with large visible thrombi, or proximal occlusions, many operators will proceed initially with aspiration thrombectomy. The TAPAS trial demonstrated an acute improvement in coronary blood flow and a reduced incidence at 1 year of cardiac death and the composite of death and nonfatal reinfarction with aspiration thrombectomy.²³ This approach carries a level IIa indication in current guidelines.²² Stent implantation can then follow. Both bare-metal and drug-eluting stents have been shown to be effective. Decisions about stent type remain operator dependent and should be based on vessel size and other angiographic factors, as well as clinical variables, including likelihood of patient compliance with dual antiplatelet therapy. In all cases, proper vessel sizing is critical in order to ensure adequate stent expansion and strut apposition, thereby reducing the risk of stent thrombosis.

STEMI often occurs in patients with multivessel CAD, with significant lesions in “non-culprit” vessels. Current guidelines argue against immediate treatment of “non-culprit” lesions at the time of primary PCI⁸ (Class III indication). The guidelines are supported by several registry analyses and randomized clinical trials, as well as by a recent large meta-analysis showing that in the setting of primary PCI for acute myocardial infarction, staged PCI is associated with lower short- and long-term mortality when compared with simultaneous culprit vessel PCI and multivessel PCI.²⁴

CASE 41.2 A 45-year-old man with no prior cardiac history and risk factors limited to cigarette smoking presented to a rural hospital emergency room with 3 hours of worsening substernal chest discomfort. Initial EKG was consistent with acute anterior wall myocardial infarction (Figure 41.2). The patient was administered aspirin, prasugrel, and unfractionated heparin per protocol.

Expedited transfer to a nearby primary PCI center was arranged with a transport time of 20 minutes. Coronary angiography was performed (Figure 41.3). This demonstrated a culprit lesion in the mid segment of the left anterior descending artery, highly suggestive of a large intraluminal thrombus. The lesion was crossed with a soft wire and aspiration thrombectomy was performed with evident thrombus aspiration (Figure 41.4). Subsequently a drug-eluting stent was deployed in “direct” fashion.

The patient had a stable postprocedural course. Medical therapy at discharge included indefinite aspirin therapy, prasugrel for 12 months, an ACE inhibitor, and a beta blocker. Smoking cessation was initiated in the hospital and continued in cardiac rehabilitation.

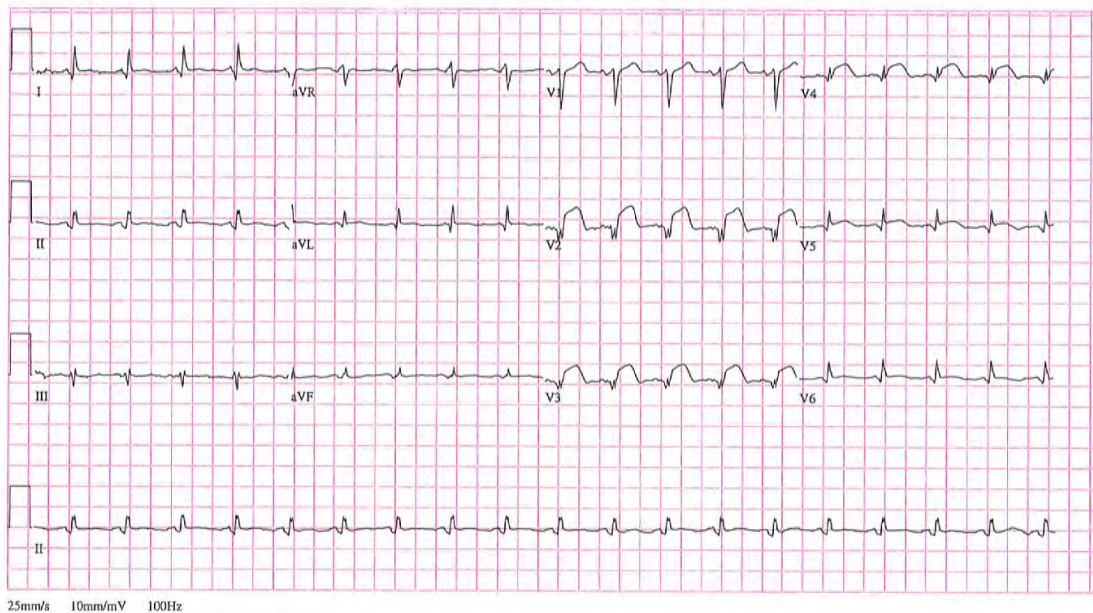


Figure 41.2 ST segment elevation myocardial infarction. Twelve-lead electrocardiogram demonstrating ST segment elevation leads V2–V6.

Commentary: This case was selected to demonstrate the importance of rapid reperfusion therapy in management of ST segment elevation myocardial infarction. Primary PCI was selected given its rapid availability owing to a coordinated system of care in this rural region.²² Had this been lacking, or had transport time to a PCI-capable facility been longer, initial treatment with thrombolytic therapy would have been appropriate, as would have been had the patient's presentation been closer to symptom onset, despite the availability of PCI. The significant thrombus burden favored the initial employment of aspiration thrombectomy prior to stent deployment.

NON-ST SEGMENT ELEVATION ACUTE CORONARY SYNDROME

Indications for Angiography and Percutaneous Coronary Intervention

Coronary angiography, with an intent of revascularization (surgical or percutaneous), is a Class I recommendation for patients presenting with non-ST segment elevation acute coronary syndrome, unstable angina, or myocardial infarction. Patients with refractory ischemia—including angina, or hemodynamic or electrical instability—or more stable patients

at higher risk for future clinical events should undergo early angiography, and if indicated PCI.⁸ Large randomized clinical trials utilizing a background of contemporary antithrombotic therapy demonstrated that an initial strategy of angiography followed by appropriate revascularization reduced the incidence of death and recurrent myocardial infarction, as compared to a more conservative initial approach of medical therapy and noninvasive risk stratification.²⁵⁻²⁷ Early angiography and subsequent revascularization (6 to 24 hours), as compared to “cooling off,” with later angiography and revascularization, reduce clinical events (composite of death, myocardial infarction, or CVA in high-risk Acute Coronary Syndrome (ACS) patients).

In ACS patients undergoing coronary angiography, the determination of revascularization strategy (PCI versus CABG) should be similar to that for patients with stable CAD. The patient's angiographic profile, likelihood of success, clinical variables, and patient preference should all be considered.

Management

For patients with non-ST elevation ACS, appropriate medical management including aspirin, ADP receptor blockers, and anticoagulation with either unfractionated or low molecular weight heparin is mandatory (see Chapter 5). Additional

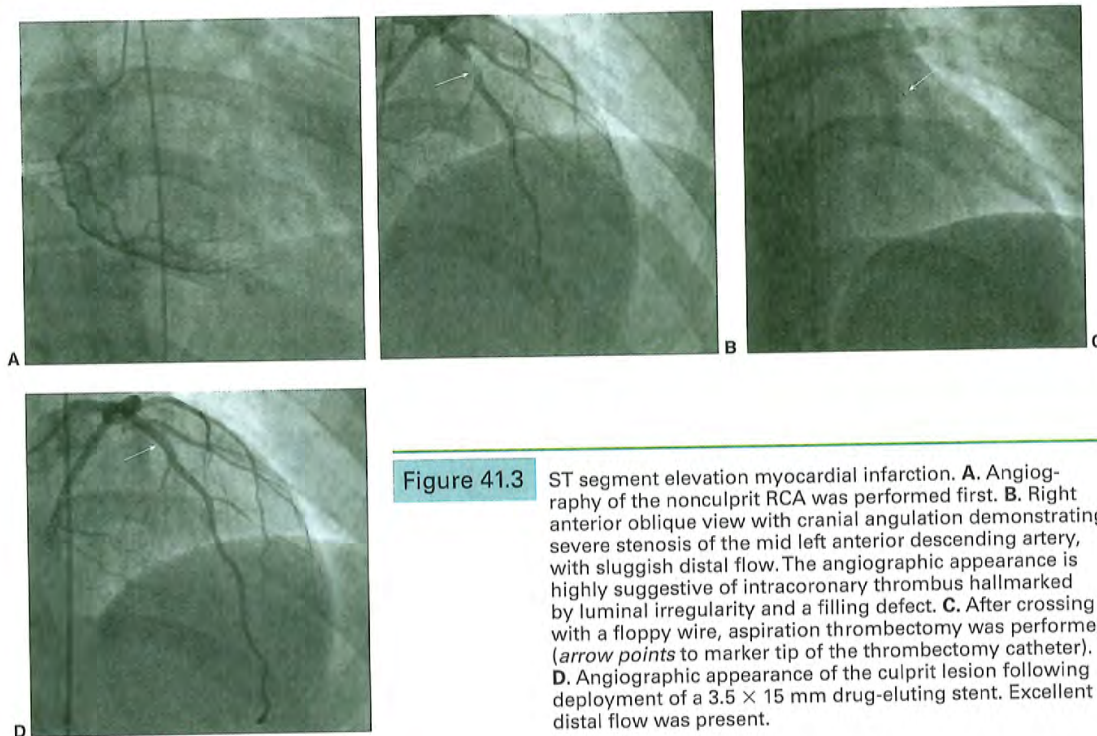


Figure 41.3 ST segment elevation myocardial infarction. **A.** Angiography of the nonculprit RCA was performed first. **B.** Right anterior oblique view with cranial angulation demonstrating severe stenosis of the mid left anterior descending artery, with sluggish distal flow. The angiographic appearance is highly suggestive of intracoronary thrombus hallmarked by luminal irregularity and a filling defect. **C.** After crossing with a floppy wire, aspiration thrombectomy was performed (*arrow points* to marker tip of the thrombectomy catheter). **D.** Angiographic appearance of the culprit lesion following deployment of a 3.5×15 mm drug-eluting stent. Excellent distal flow was present.

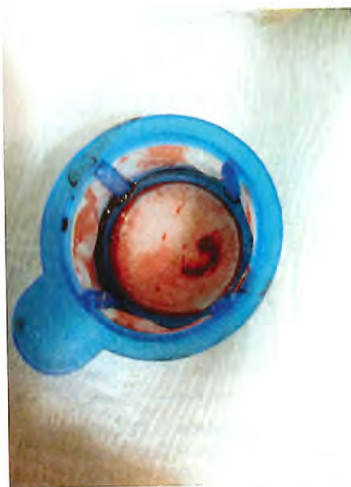


Figure 41.4 Thrombus obtained via aspiration thrombectomy.

medical therapy including beta-blockers and blood pressure control in conjunction with aggressive lipid lowering therapy with statins is also indicated.^{28,29}

Approaches to PCI should be based on anatomic and clinical factors. Both bare-metal and drug-eluting stents can be utilized. As in the setting of STEMI, stent choice should be predicated on risk of restenosis, stent thrombosis, patient compliance, and other technical and clinical considerations. With fourth-generation drug-eluting stents being widely employed, stent delivery is rarely a consideration in determining if a bare or coated stent is to be employed. In patients with multivessel CAD undergoing PCI, multivessel intervention in a single setting is commonplace. That said, consideration of contrast burden and risk of contrast-induced nephropathy (CIN), radiation dose, initial lesion result, the extent of myocardium at risk, and other patient-specific factors should guide whether staging of secondary lesions should be considered.

CASE 41.3 An 82-year-old man with a history of coronary artery disease presented with severe chest pain and diaphoresis. Electrocardiography demonstrated dynamic anterolateral T-wave inversions, and cardiac markers (troponin) were borderline. The patient was stabilized with aspirin, unfractionated heparin, beta blocker, and nitrates. The patient had undergone coronary angiography and placement

of bare-metal stents in the proximal and middle left anterior descending artery 2 years earlier. Shortly after stent placement the patient developed recurrent episodes of both gastrointestinal and genitourinary bleeding requiring transfusion. Clopidogrel had been stopped at that time and was not restarted during the current admission. Prior to angiography the patient expressed that he was adamantly opposed to coronary artery bypass surgery owing to the need for prolonged recovery and risk of stroke, both of which would prevent his wife from living independently.

The patient underwent coronary angiography (Figure 41.5), which demonstrated a culprit lesion in the middle left anterior descending artery at the site of the earlier

stent. In addition, there were high-grade stenosis in the right and circumflex arteries. The limited angiographic complexity (low SYNTAX score) and preserved systolic function, suggested that PCI would afford a good outcome and meet the patient's desire to avoid surgery. However, the patient's poor candidacy for long-term dual antiplatelet therapy precluded multiple drug-eluting stents. Fractional flow reserve was performed on the right coronary (FFR = 0.84) and circumflex (FFR = 0.91) arteries. Accordingly, revascularization of these lesions was deferred. Given the discreet segmental nature of the in-stent restenosis of the middle left anterior descending lesion and the patient's bleeding risk, conventional balloon angioplasty with a 2.5×12 mm balloon was

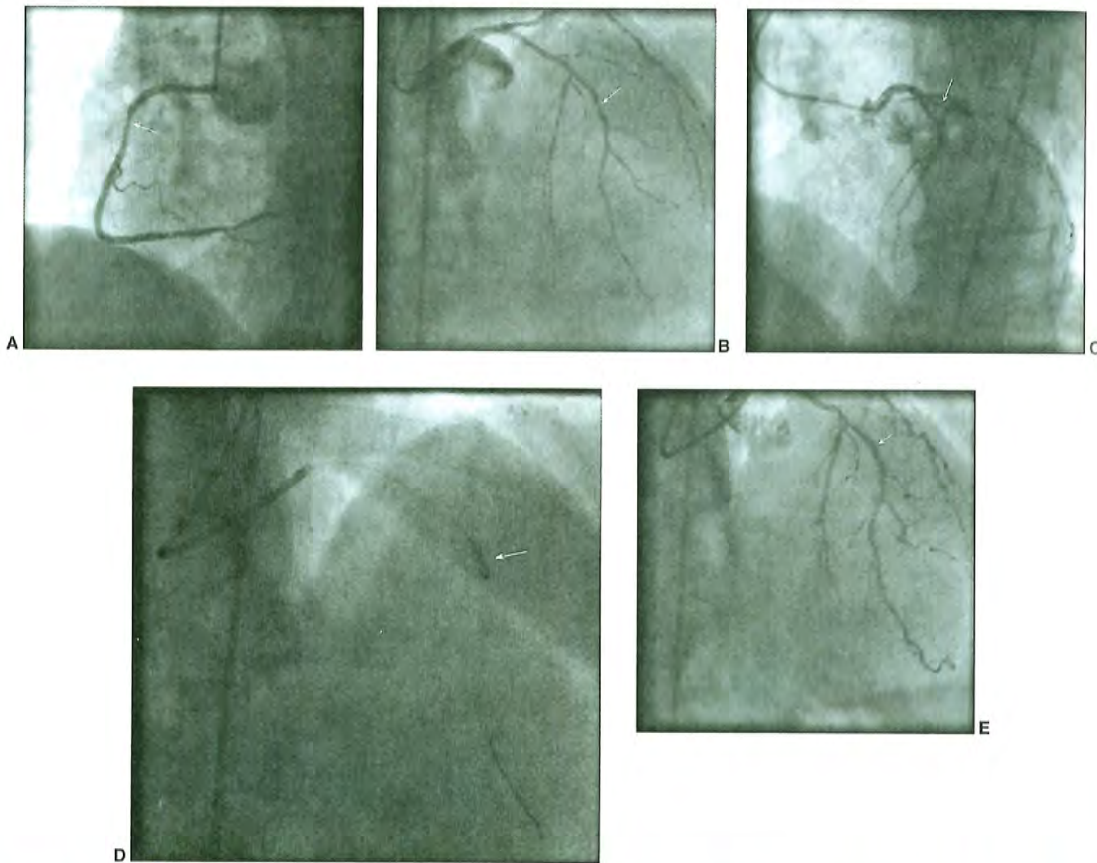


Figure 41.5 Non-ST segment elevation acute coronary syndrome. **A.** Angiography of the right coronary artery in the left anterior oblique angle demonstrates a severe stenosis of the proximal segment (*arrow*). **B.** Right anterior oblique view with cranial angulation demonstrates severe stenosis of the mid left anterior descending artery, at the site of a previous stent (*arrow*). **C.** Left anterior oblique view with cranial angulation demonstrates moderate to severe stenosis of the proximal circumflex artery (*arrow*). **D.** Balloon angioplasty of mid left anterior descending in-stent restenosis with a 2.5×12 mm balloon (*arrow*). **E.** Excellent angiographic result of mid left anterior descending artery in-stent restenosis (*arrow*).

performed. This resulted in an excellent angiographic result. The patient was discharged with a limited course of dual antiplatelet therapy and optimal medical therapy for his residual coronary disease. He had an excellent long-term outcome.

Commentary: This case was selected to show complex, patient-centered decision-making in a patient with acute coronary syndrome. An early invasive stratification strategy was employed. Consideration of the patient's preferences and hemorrhagic risk was central in choosing the revascularization approach. Fractional flow reserve provided physiologic insight into lesions that angiographically appeared severe, thereby mitigating the need for multivessel revascularization and playing a key role in evidence-based revascularization that met the patient's personal and clinical needs.

CASE 41.4 The patient is a 79-year-old female with a history of hypertension and diabetes mellitus. In addition, she has had angina for many years, which has been stable and is controlled with beta blocker, amlodipine, long-acting nitrates, a statin, and aspirin. She presented to the emergency room with the acute onset of severe left-sided chest pain and left arm numbness at rest. Initial EKG was unremarkable; however, the initial troponin was elevated. She was treated with intravenous nitrates, clopidogrel, and low molecular weight heparin. Her chest pain abated upon initiation of her therapy, and she remained pain free; however, her troponin peaked at 12. She was referred for coronary angiography and further therapy.

Coronary angiography demonstrated severe three-vessel coronary artery disease with bifurcation stenosis of the mid left anterior descending artery involving the ostium of the diagonal branch (Figure 41.6), a stenosis of the proximal segment of a large-branching obtuse marginal branch of the circumflex artery, and a subsequent bifurcation lesion of the vessel involving both the ostia of both terminal vessel branches. The angiogram also demonstrated moderate to severe stenosis of the distal segment of the right coronary artery. Left ventriculography demonstrated markedly reduced systolic function, with an ejection fraction of approximately 30% and with anterior and inferior hypokinesis and apical dyskinesis. The study was completed and revascularization options were considered in a collaborative heart team meeting of the clinical and interventional cardiologists and a cardiac surgeon. The diminished left ventricular function, as well as the angiographic complexity of the coronary artery disease (numerous lesions including multiple, complex bifurcation stenosis, with the resultant need for many stents), led the group to favor CABG. The patient's high functional status and lack of other major morbidities were felt to support this choice clinically. After consultation with the patient and her family, CABG (with five grafts including an internal mammary artery graft) was performed. The patient had an uneventful postoperative course.

Commentary: In this case, while percutaneous coronary intervention was technically possible, the complexity of the patient's coronary anatomy, as well as the significant reduction in left ventricular function, favored surgical revascularization, which was chosen.

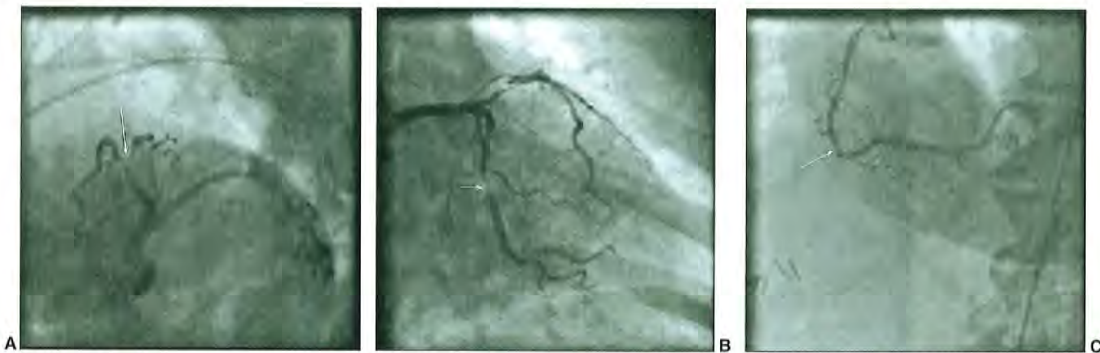

Figure 41.6 Non-ST segment elevation acute coronary syndrome. **A.** Left anterior oblique view with caudal angulation demonstrates a bifurcation lesion of the middle left anterior descending artery involving the ostium of the diagonal branch (*arrow*). **B.** Right anterior oblique view with caudal angulation demonstrates severe stenosis of the proximal segment of the large branching obtuse marginal branch. There is additional stenosis of the distal vessel as it bifurcates into terminal branches, involving the ostia of both branches (*arrow*). **C.** Angiography of the right coronary artery in the left anterior oblique view demonstrates a moderate to severe stenosis of the distal segment (*arrow*).

UNPROTECTED LEFT MAIN CORONARY ARTERY DISEASE

CASE 41.5 A 70-year-old man with known severe occlusive peripheral vascular disease and chronic obstructive pulmonary disease (forced expiratory volume = 700 mL) developed pulmonary edema requiring intubation and ventilatory support. During an episode of atrial fibrillation with a rapid ventricular response, the patient developed deep precordial ST-segment depression and hypotension. Owing to ongoing ischemia despite maximal medical therapy and ongoing ventilator dependence, coronary arteriography was performed from the right radial approach. Diagnostic angiography demonstrated an 80% ostial left main stenosis. Surgical consultation recommended that he was not a candidate for CABG owing to his severe pulmonary disease, and the left main lesion was corrected by balloon predilatation and implantation of a drug-eluting stent.

CASE 41.6 A 62-year-old woman with severe iliofemoral vascular disease underwent CABG for 80% ostial left main stenosis and 95% stenosis of the second marginal. The mammary artery was not suitable for CABG, and she received vein grafts to the left anterior descending and the marginal branch. Five months later she developed recurrent angina. Angiography demonstrated preserved left ventricular function and occlusion of the bypass grafts, an 80% ostial left main stenosis, and an occluded marginal (Figure 41.7A). Her surgeon referred her for percutaneous revascularization. Hemodynamic support was initiated using an Impella device, which was successfully advanced through an iliac stent (Figure 41.7B). The marginal artery was recanalized and stented, and the ostial left main was also stented (Figure 41.8).

CASE 41.7 An 85-year-old man with severe pulmonary fibrosis on home oxygen presented with atrial fibrillation with rapid ventricular response, pulmonary edema, and non-ST elevation myocardial infarction. Coronary angiography demonstrated critical distal left main disease involving the ostium of the LAD, LCX, and ramus intermedius (Figure 41.9). The ejection fraction was 20%. After being declined for CABG, he was referred for consideration of high-risk coronary intervention. Given the complexity of the stenosis and the severely reduced left ventricular systolic performance, prior to the intervention hemodynamic support with TandemHeart was initiated. The trifurcation lesion was managed successfully by stent implantation and the patient was symptom-free at 2-year follow-up (Figure 41.10).

Commentary: Diagnostic coronary angiography uncovers significant unprotected left main coronary artery (ULMCA) stenosis in 5% to 7% of cases.^{30,31} Coronary artery bypass graft (CABG) surgery has historically reigned as the standard of care for these high-risk patients based on the improved survival as compared to medical therapy observed in the Veterans Administration Cooperative Study and in the Collaborative Study in Coronary Artery Surgery.³²⁻³⁴ With improved pharmacologic therapy and the dramatic reduction in restenosis afforded by DES, enthusiasm for tackling ULMCA lesions with interventional techniques has mounted. Important data from clinical trials are now available to help guide decision-making for such high-risk interventions.

The multicenter, nonrandomized Revascularization for Unprotected LM Coronary Artery Stenosis: Comparison of Percutaneous Coronary Angioplasty versus Surgical Revascularization (MAIN-COMPARE) registry examined long-term outcomes after PCI (DES = 784; BMS = 318) or CABG ($n = 1,138$) for ULMCA stenosis.³⁵ After propensity matching, there was no difference in death or the composite of death, MI, and stroke. However, repeat revascularization was




Figure 41.7 A. Anteroposterior caudal angiogram of the left coronary artery. Left main ostial 80% stenosis (*white arrow*) and the occluded mid circumflex/marginal (*double white arrow*) are shown. B. Impella device advanced through iliac stent.

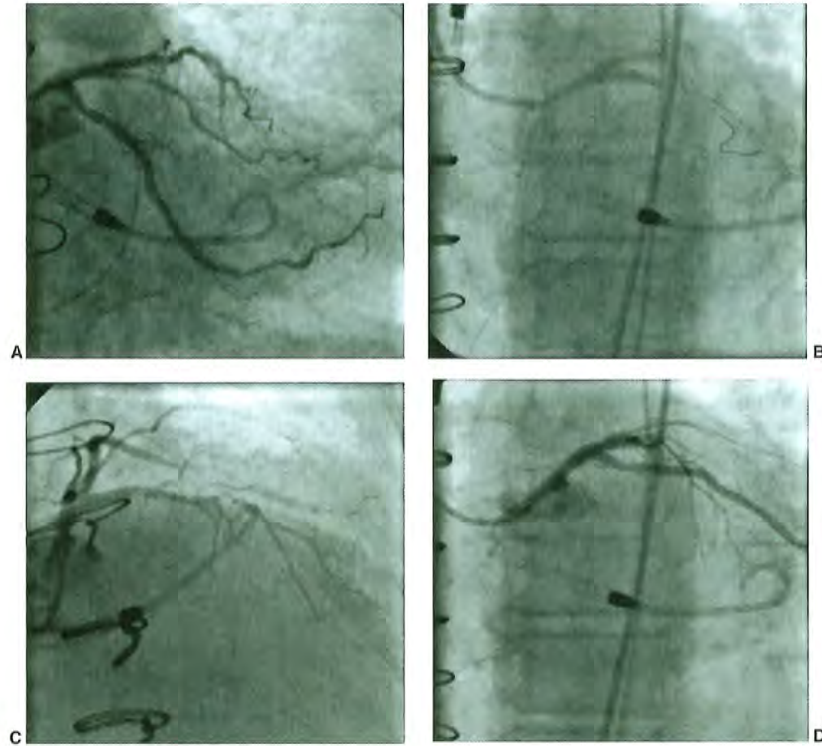


Figure 41.8 A. Totally occluded left circumflex (LCX) marginal is recanalized and stented. B. Left main (LM) was very short, and ostial left main stent was placed extending into the left anterior descending artery (LAD), followed by kissing balloons in the LM/LAD and LCX. C. Right anterior oblique cranial view of final result showing the LAD to be a small diffusely diseased vessel mid and distal. D. Anteroposterior caudal view showing the final results in the LM ostium and LCX.

significantly higher after PCI with a hazard ratio of 4.76 at 3 years ($P < 0.001$).

The Premier of Randomized Comparison of Bypass Surgery versus Angioplasty Using Sirolimus-Eluting Stent in Patients with Left Main Coronary Artery Disease (PRECOMBAT) trial randomized 600 patients with ULMCA stenosis to CABG versus PCI with a sirolimus DES in a noninferiority trial.³⁶ Surveillance angiography was performed at 8 to 10 months after PCI or for symptoms. At 1 year the primary endpoint of death, MI, stroke, or ischemia-driven target vessel revascularization was reached in 8.7% of PCI and 6.7% of CABG patients, meeting the wide noninferiority margin set for this study. The composite event rates at 2 years were not statistically different (12.2% PCI versus 8.1% CABG), but there was a significant increase in ischemia-driven target lesion revascularization after PCI as compared to CABG (9.0% versus 4.2%). Outcomes favored PCI in isolated left main or left main plus single-vessel disease, whereas more complex anatomy favored CABG. The overall low event rates in this study are notable, and it is unclear if surveillance

angiography drove higher repeat revascularization rates in the PCI group.

The Synergy between PCI with Taxus and Cardiac Surgery (SYNTAX) study randomized 1,800 patients with multi-vessel or left main CAD to PCI with a paclitaxel-eluting stent versus CABG. As the overall study failed to demonstrate non-inferiority of PCI, subgroup analyses from this trial are considered hypothesis generating. In the ULMCA subgroup (705 patients), similar 1 year major adverse cardiac and cerebrovascular events were found (15.8% versus 12.7%; $P = 0.44$). The incidence of stroke was significantly higher after CABG (0.3% versus 2.7%; $P = 0.009$), whereas repeat revascularization was higher with PCI (11.8% versus 6.5%; $P = 0.02$). Outcomes with the two strategies appeared to depend in part on the SYNTAX score, a measure that incorporates lesion location, lesion complexity, and number of lesions. Composite outcomes were similar for PCI and CABG in patients with low or intermediate SYNTAX scores. However, patients with high (>32) scores had a significantly higher rate of the primary outcome with PCI (25.3% versus 12.9%).³⁷ Recent




Figure 41.9 A. Left anterior oblique caudal angiogram showing critical distal LM stenosis (*arrow*) involving the origin of the LAD, ramus, and LCX. B. Through an 8F guide, the LAD, ramus, and LCX are wired (*arrows*). Cardiac support with TandemHeart is initiated. Left atrial cannula of the TandemHeart is seen in the left atrium (*double arrow*).

5-year outcome data on the ULMCA cohort from SYNTAX show similar outcomes for PCI and CABG (MACCE of 36.9% versus 31%; $p = 0.12$). The outcomes were again best in low and intermediate SYNTAX score patients, and in those with single- or double-vessel CAD. In those with three-vessel CAD and high SYNTAX scores, the outcomes appear to continue to favor CABG.

The Evaluation of Xience Prime or Xience V versus Coronary Artery Bypass Surgery for Effectiveness of Left Main Revascularization (EXCEL) trial is currently enrolling patients with left main disease and a SYNTAX score of ≤ 32 to evaluate patients with less complex coronary artery disease than found in those enrolled in SYNTAX.³⁸ This will allow

an assessment of second-generation DES for the treatment of ULMCA.

Technical Considerations

Mechanical support (Intraaortic balloon pump, TandemHeart, Impella, ECMO) is generally not required in hemodynamically stable patients undergoing ULMCA PCI. In unstable patients mechanical support may be considered in advance, and vascular access for these devices should be assessed. Objective lesion assessment with fractional flow reserve (FFR < 0.80) or intravascular ultrasound (IVUS; minimal luminal area $< 6 \text{ mm}^2$) may help confirm the functional significance

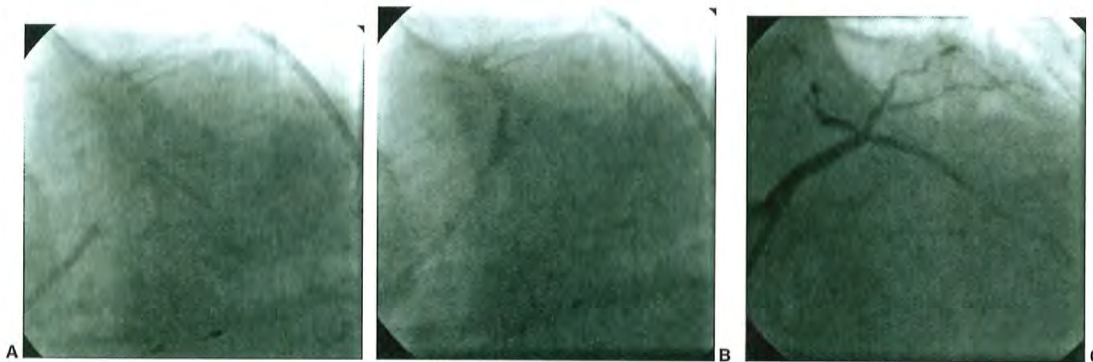


Figure 41.10 A. Origin of LCX is "T stented" with a $2.5 \times 18 \text{ mm}$ Endeavor using a balloon in the left main to ensure that the stent does not protrude back into the left main and impede access to the ramus and LAD for additional intervention. The stent is postdilated to 2.75 mm. B. The LAD and ramus are treated using a $3.0 \times 12 \text{ mm}$ Endeavor DES (Ramus) and $3.0 \times 15 \text{ mm}$ Endeavor DES (LAD) deployed in simultaneous kissing stent fashion. Both are postdilated to 3.5 mm. C. Right anterior oblique cranial view of the final result after stenting the LAD, ramus, and LCX.

of a lesion. Heavy endoluminal calcification by IVUS suggests the need for rotational atherectomy to facilitate stent expansion. Speed is of the essence in PCI of ULMCA. Given the large volume of myocardium subtended, balloons and stents are all readied prior to critical steps, inflation durations are minimized, and bailout equipment for side branch occlusion or perforation is on standby. While PCI is generally performed on the most distal lesion first, ULMCA lesions may require treatment first in order to work distally later without inducing global ischemia.

The location of the stenosis within the left main coronary artery will generally determine the complexity of the PCI (see Chapters 28 and 31). About 30% of stenoses involve the ostium or body of the left main.³⁹ Focal, ostial/body left main lesions can generally be treated with short, large-diameter stents with a minimum of peri-PCI ischemia. Coaxial guiding catheter support allows positioning of the proximal portion of the stent just 1 to 2 mm within the aorta and fully covering the ostial left main stenosis. A nonaggressive guide (e.g., Judkins left) may facilitate controlled guide disengagement to allow precise positioning of the ostial stent. Short, high-pressure balloon inflations minimize ischemia time and provide full stent expansion.

Left main lesions involving the distal left main bifurcation account for roughly 60% of ULMCA stenoses.³⁹ These generally require placing the distal portion of the stent within either the left anterior descending (LAD) or the left circumflex coronary artery, or both. One large observational study of LMCA bifurcation stenting found that a one-stent technique was associated with reduced MACE at 2 years as compared to a two-stents technique (propensity-adjusted hazard ratio for the risk of 2-year MACE was 0.53 (95% CI: 0.37 to 0.76)).⁴⁰ Restenosis rates in left main bifurcation lesions are higher than for isolated ostial/body lesions, with the most common site of restenosis being the circumflex ostium.⁴⁰ The distal LMCA bifurcation angle generally dictates the technique employed. Angles of ~90 degrees allow T stenting or one of its variants—techniques that minimize stent overlap. More acute angles are generally treated with single-vessel provisional stenting or other techniques (crush, Culotte, V stenting, T and Protrusion). Completion kissing balloon angioplasty is recommended to optimize stent geometry.

For elective intervention, current U.S. guidelines provide a class IIa recommendation for LMCA PCI when the lesion is $\geq 50\%$, the anatomy is consistent with low acute complications and favorable long-term outcome (e.g., SYNTAX score ≤ 22 , ostial or body location), and there is increased surgical mortality risk (e.g., STS mortality prediction of $\geq 5\%$).⁸ The recommendation is IIb for a similar situation with a low-to-intermediate risk of acute complications and an intermediate-to-high likelihood of favorable long-term outcome (e.g., SYNTAX score ≤ 33 , bifurcation left main lesion). PCI should not be performed in ULMCA for patients with unfavorable anatomy for PCI and low surgical risk. Given the enormous stakes for patients with ULMCA, the importance of a heart team approach to decision-making in stable patients cannot be overemphasized.⁸

CHRONIC TOTAL OCCLUSION

CASE 41.8 A 59-year-old man with premature CAD, prior CABG, and multiple prior PCIs of the native vessel presented with severe exertional angina that developed with exercise and was relieved with rest, despite maximum medical therapy. Exercise stress testing demonstrated reversible inferior wall ischemia (Figure 41.11). Coronary arteriography demonstrated a patent left internal mammary artery to the LAD and occluded SVGs to the diagonal branch and posterior descending branches. The native left coronary artery had a patent left circumflex coronary artery and diffuse disease of the LAD and diagonal branches. The right coronary artery was ectatic and was patent to the posterior descending artery. Just distal to the crux, there was a total occlusion of the distal continuation of the RCA (Figure 41.12). A large right posterolateral branch was being filled by left-to-right and right-to-right collaterals. Conventional coronary guidewires were unsuccessful in crossing the occlusion. The Intraluminal Therapeutics Safe Steer RF coronary guidewire was then used to cross the occlusion using optical coherence reflectometry guidance, to confirm the intraluminal position of the guidewire, and radiofrequency energy to cross the occluded segment. Once successful wire crossing was obtained, coronary stent placement was performed with normal flow into the large posterolateral branch.

Indications for Coronary Arteriography and Percutaneous Revascularization

Defined as a complete occlusion of ≥ 3 months duration, CTOs are found in up to 50% of patients with significant obstructive coronary artery disease ($\geq 70\%$) at catheterization.⁴¹ Despite this prevalence, historically only 8% to 15% of patients with CTO has undergone PCI.⁸ In fact, the presence of CTO is a major predictor of advising against PCI⁴¹ in favor of medical therapy or CABG.⁴¹ This practice pattern likely reflects uncertainty regarding the clinical benefit of CTO PCI, as well as the significant technical challenges with this procedure. Fortunately, recent marked advances in equipment and procedural technique have rendered CTOs less daunting in experienced hands. The challenge for interventionalists is to determine when to tackle these complex lesions and how to achieve effective revascularization safely and expeditiously when PCI is attempted.

There are no randomized trials comparing CTO PCI to medical therapy. The Occluded Artery Trial (OAT) compared PCI to medical therapy for total occlusion of the culprit vessel ≤ 28 days after acute myocardial infarction in *stable* patients with high-risk features (proximal vessel occlusion or ejection fraction $< 50\%$).⁴² PCI did not reduce the incidence of death, reinfarction, or Class IV heart failure up to 4 years

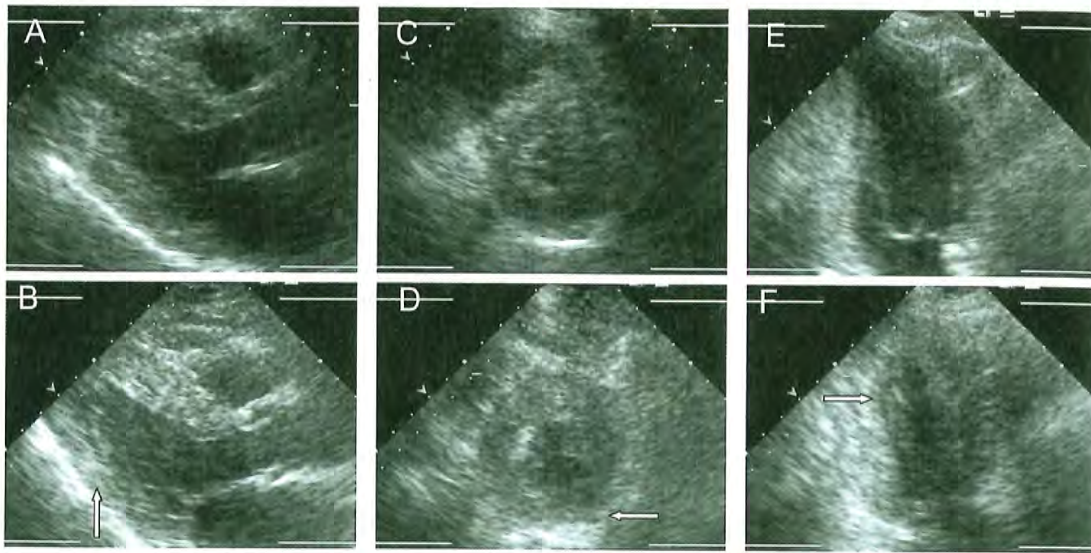


Figure 41.11 Stress echocardiogram demonstrating inferior-posterior hypokinesia with exercise (arrows). **A.** Parasternal long-axis rest. **B.** Parasternal long-axis stress. **C.** Parasternal short-axis rest. **D.** Parasternal short-axis stress. **E.** Apical two-chamber rest. **F.** Apical two-chamber stress. (Courtesy of Noninvasive Cardiac Laboratory, Brigham and Women's Hospital, Boston, MA.)

as compared to medical therapy (17.2% versus 15.6%), but the clinical context (recent MI) and the coronary anatomy (recent thrombotic occlusion) in OAT were far different from those of the CTO population. In true CTOs, successful PCI has been associated with improved left ventricular function,^{43,44} reduced angina and need for CABG,⁴⁵ and even improved survival^{46,47} when compared to failed procedures. Other observational data have suggested an adverse prognostic effect of untreated CTO. Fractional flow reserve of the collateral circulation to CTOs is reliably <0.80 , consistent with ischemia in the CTO territory even in the presence of large collaterals.⁴⁶ Following primary PCI, nonrevascularized CTO of a non-infarct related artery at 30 days is associated with increased long-term mortality.⁴⁹ Among unselected PCI patients the presence of unattempted CTO in two vessels appears to define the population at highest risk for subsequent death and myocardial infarction.⁵⁰

It is possible that the observed favorable effects of successful CTO PCI in fact reflect the fact that patients with failed or unattempted CTO PCI may represent a sicker population or, more ominously, that failed attempted CTO PCI actually confers harm. Studies in Europe and Asia are currently randomizing CTO patients to PCI versus medical therapy, but at present we are left to make our best clinical judgment. Current guidelines provide a Class IIa recommendation that PCI of the CTO is reasonable in patients with appropriate clinical indications and suitable anatomy when performed by

operators with appropriate expertise.⁸ A Heart Team approach is emphasized, with specific input from cardiothoracic surgery, as is an individualized risk-benefit analysis encompassing clinical, angiographic, and technical considerations.

Technical Considerations

Several consensus documents have attempted to formalize a systematic approach to CTO intervention.⁵¹⁻⁵⁴ Operator experience and commitment to the technique are considered critical to the success of complex CTO intervention. Ad hoc PCI of complex CTOs is discouraged to allow for intensive review of the angiographic and clinical data and to utilize the Heart Team approach. Bilateral simultaneous coronary angiography is recommended with minimal panning in low magnification, injecting the contralateral vessel first, followed by the CTO vessel to optimize vessel assessment. Septal collaterals are best assessed in the RAO cranial and caudal views. Critical angiographic characteristics to review include (i) the proximal cap location and morphology, (ii) lesion length, (iii) size and quality of the target at the distal cap, and (iv) the collateral vessels.⁵⁴ A clear entry into the proximal cap and a lesion length >20 mm favor success with a standard antegrade approach. When the proximal cap has no clear entry point, or the distal target is poor, or there are favorable collaterals, a retrograde approach may be preferable. Epicardial collaterals should be avoided in the retrograde approach owing to

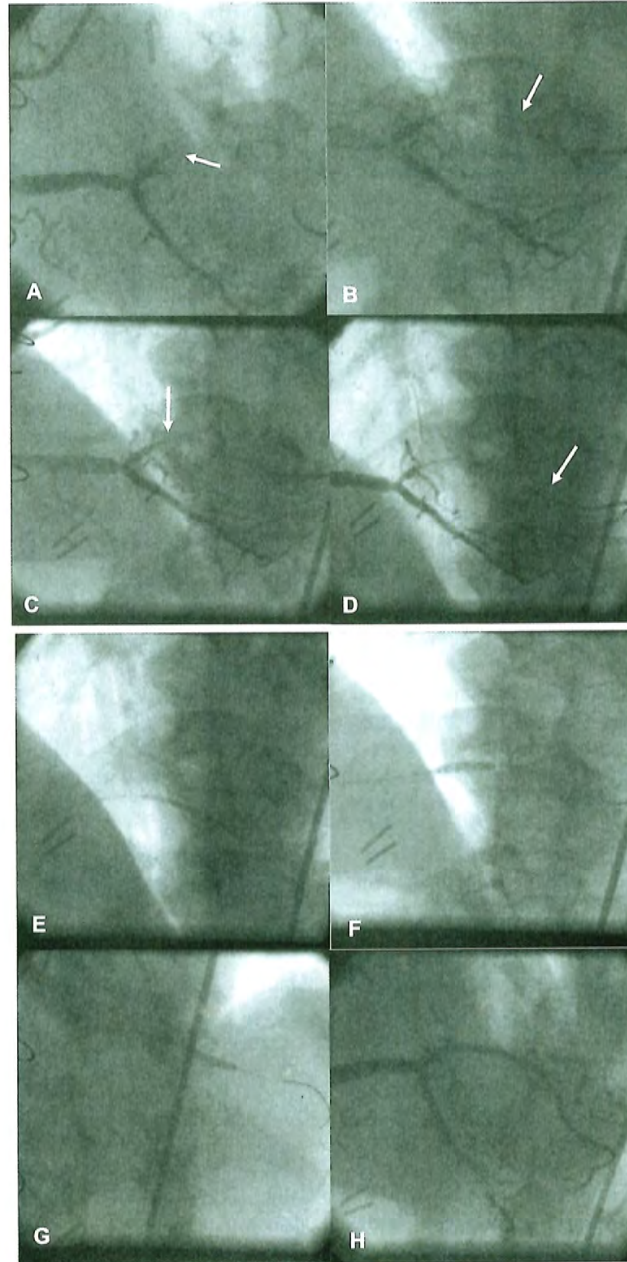


Figure 41.12 Recanalization of a total coronary occlusion. **A.** A flush occlusion of the distal continuation of the right coronary artery (*arrow*). **B.** Initial attempts at crossing the occlusion with a hydrophilic coronary guidewire result in the creation of a false lumen and parallel tract to the right posterolateral branch (*arrow*). **C.** The Intraluminal Therapeutics SafeSteer coronary guidewire is used to advance the wire into the true lumen using optical coherence reflectometry (*arrow*). **D.** Using this method, the guidewire is advanced into the distal portion of the right posterolateral branch. **E.** A 2.0 mm balloon is used to dilate the occlusion initially. **F.** This is followed by stent placement in the very distal right coronary artery. **G.** An additional balloon inflation is performed in the distal right posterolateral branch. **H.** The final angiographic result demonstrates no residual stenosis and normal flow into the distal vessel.

perforation risk. Success of retrograde PCI is enhanced if the collaterals have minimal tortuosity and enter the distal vessel far enough beyond the distal cap to allow wire purchase. If the collateral is the sole source of perfusion to the occluded vessel, the risk of acute intraprocedural ischemia increases.

Anticoagulation with unfractionated heparin is favored over bivalirudin for PCI on CTO, as it can be reversed in the case of perforation. Similarly, glycoprotein IIb/IIIa inhibitors are avoided. Equipment for pericardiocentesis, embolization coils, and covered stents should be readily available to manage perforation. An activated clotting time of >350 seconds is recommended during retrograde procedures to minimize the risk of thrombosis in the instrumented collateral vessels.⁵³ Routine use of a two-guide technique is advocated—one guide for antegrade injection in the CTO vessel and a second shorter guide (≤ 90 cm) in the contralateral coronary to facilitate retrograde techniques. Large-caliber guides enhance support and allow exchange of bulky devices or balloon-trapping techniques, while long-access sheaths help overcome peripheral vascular tortuosity that may otherwise hinder guide performance. Techniques to minimize radiation exposure to the patient and the operator (reducing cine and fluoroscopy frame rates, using “store” fluoroscopy rather than cineangiography when appropriate, and using additional protective shielding) should be employed for these potentially long procedures.

Successful CTO intervention requires familiarity with a significant number of niche wires and devices. Hydrophilic 0.014 inch wires with 0.009 inch tapered tips of low stiffness are available to probe the entry cap for microchannels in the antegrade approach. If unsuccessful, and if the pathway to the distal lumen is clear, escalation to increasingly stiff, nontapered wires is appropriate. A wire-directed retrograde through collaterals to the distal cap can provide a target for antegrade approach. Alternatively, an antegrade subintimal dissection approach can be attempted, using a knuckled wire or a blunt-tip metal microcatheter (CrossBoss, BridgePoint Medical, Plymouth, MN). The wire or catheter is advanced parallel to the true lumen up to the distal cap. With a microcatheter in the subintimal space for support, reentry into the distal true lumen is attempted with a stiff wire. The Stingray system (BridgePoint Medical) can be advanced over a wire into the subintimal space. When inflated, the balloon assumes a flat shape with an exit port on either side. A 0.0025 inch wire is then advanced into the appropriate port facing the true lumen to achieve reentry.

Once successful antegrade wiring is achieved, low-profile balloons are used to cross the occlusion to establish a channel for stenting. If balloons cannot cross, guide support can be enhanced with a GuideLiner (Vascular Solutions, Minneapolis, MN) and wire support can be augmented with various balloon-trapping techniques. Finally, a Tornus microcatheter (Asahi Intecc) can be used. This device is counterlocked over the wire to screw through the lesion. Stents are superior to balloon angioplasty for CTO intervention, and DES are superior to BMS.⁵⁵⁻⁵⁷

In the retrograde approaches, access to the distal target vessel via a bypass graft is preferred to a septal collateral, and access via an epicardial collateral is generally avoided due to increased risk of perforation. Generally a low-profile over-the-wire balloon or a microcatheter is used to support a long hydrophilic wire. Once the wire is negotiated into the distal target vessel, retrograde to the distal cap, the septal is dilated with a small balloon (~ 1.5 mm) at low pressure or using the Corsair septal dilator microcatheter (Abbott Vascular) to avoid equipment entrapment in the collateral. A microcatheter is advanced to the distal cap and the occlusion is traversed using one of multiple techniques, such as antegrade puncture with the retrograde wire as a target, retrograde puncture, or reverse subintimal dissection and reentry. If the lesion is crossed retrograde, subsequent treatment of the lesion is most easily accomplished by crossing this new lumen antegrade and completing the procedure in a standard antegrade fashion. Externalization of the retrograde wire using a snare is also possible. In this approach, maintaining microcatheter position through the septal collaterals is critical to prevent septal injury during the wire manipulations. The externalized rail can then be used to complete the procedure in an antegrade fashion.

In specialized CTO centers, CTO intervention is successful in up to 85% of cases,⁵⁸ with substantially lower success rates in less experienced hands. Similarly, rates of perforation and mortality are <1%.⁵¹ With DES, target lesion revascularization rates are <10%.⁵¹ Although a randomized trial of PCI versus CABG or medical therapy for CTO is sorely needed, at this time CTO intervention is a reasonable alternative in appropriately selected patients when performed in experienced centers.

SAPHENOUS VEIN GRAFT DISEASE

CASE 41.9 A 60-year-old man with a history of coronary artery disease and prior CABG presented with an acute inferior-wall myocardial infarction. The EKG demonstrated an inferior-wall myocardial infarction, manifest by ST-segment elevation of leads II, III, and AvL (Figure 41.13). Coronary arteriography demonstrated a patent left internal mammary artery (LIMA) to the LAD, patent SVG to the obtuse marginal and diagonal branches, ostial left main and RCA occlusions, and a recently occluded SVG to the posterior descending artery (PDA; Figure 41.14). The occluded SVG to the PDA was crossed with a 0.014 inch BMW wire, and a distal injection demonstrated abundant thrombus and a focal stenosis in the midportion of the SVG. A 0.014 inch FilterWire EZ (Boston Scientific, Natick, MA) was placed across the stenosis, and the FilterWire was deployed in a smooth portion of the SVG. A 5F AngioJet XVG catheter was used to remove the residual thrombus. Following this, two 3.5 × 33 mm CYPHER stents were placed in the proximal and mid SVG. The SVG was post-dilated with a 4.0 mm postdilatation balloon. The FilterWire was then removed, and normal flow was found in the distal RCA and its branches.

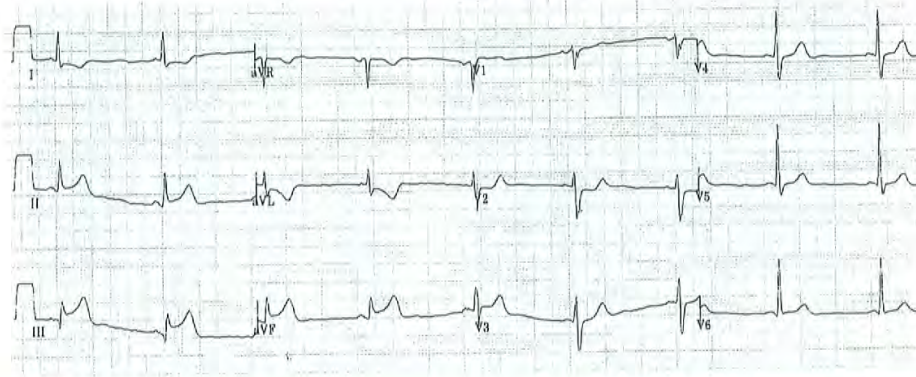


Figure 41.13 ECG demonstrating acute inferior-wall ST-segment elevation myocardial infarction.

CASE 41.10 A 55-year-old man with prior bypass surgery, including a vein graft to the first marginal, presents with unstable angina. The proximal portion of the graft has been previously stented and angiography demonstrates a severe in-stent restenosis (Figure 41.15A). The in-stent lesion is deemed low-risk for distal embolization and no-reflow at the time of intervention, and stenting of the lesion is performed without distal protection. The lesion is successfully treated, but there is now a distal cutoff in the subtended marginal branch (Figure 41.15B). Balloon angioplasty is performed at the site of distal cutoff with restoration of brisk antegrade flow with no residual obstruction (Figure 41.15B).

Indications for Coronary Arteriography and Percutaneous Revascularization

Even with excellent surgical techniques, SVGs are at risk for deterioration owing to progressive degeneration in the higher-pressure arterial environment. It is thus estimated that >50% of SVGs become diseased or occlude within the first decade after CABG. Repeat CABG for SVG failure, particularly when there is a patent LIMA to the LAD, is associated with lower success rates and less symptomatic benefit than those of the initial procedure.

Technical Considerations

Anticoagulation for percutaneous intervention on SVGs is typically achieved with unfractionated heparin or bivalirudin. Procedural success with current techniques generally exceeds 90%⁵⁹ depending in part on the presence of graft degeneration and lesion location. The major risk of SVG intervention is the occurrence of distal embolization.⁶⁰ The

degree of risk for embolization relates to the extent of SVG degeneration, which includes an estimate of the percentage of graft irregularity and ectasia, friability, presence of thrombus, and number of discrete or diffuse lesions (>50% stenosis) located within the graft. Case selection is therefore critical. Severely diffusely degenerated grafts with poor distal outflow and chronic total SVG occlusions are generally avoided, particularly if an option for revascularization via the native coronary circulation exists. Glycoprotein IIb/IIIa antagonists are not beneficial in this regard and do not improve overall outcomes of SVG intervention. Although atherectomy and thrombectomy have been tried to prevent embolization and its attendant complications, only the use of embolic protection devices has resulted in a reduction of adverse clinical events (see Chapter 29).⁶¹

Three general classes of embolic protection devices have been approved for clinical use: occlusion systems that use a low-pressure balloon to occlude flow during intervention, embolic entrapment filters that permit flow through the distal filter, and proximal occlusion systems. The PercuSurge Guardwire (Medtronic Vascular, Santa Rosa, CA) device is a low-profile system (0.014 inch guidewire) with a balloon that is inflated at low pressures to occlude flow once it is positioned distal to the target lesion. Any debris liberated by intervention remains trapped in the stagnant column of blood and is subsequently aspirated with a different catheter before the occlusion balloon is deflated to restore antegrade flow. The 801-patient SAFER trial, in which patients undergoing SVG intervention were randomized to stenting using this distal protection device versus a conventional guidewire, demonstrated a substantial reduction in 30-day major adverse clinical events (16.9% to 9.6%) and no-reflow (8.3% to 3.3%) using the device.⁵⁹ Subsequent trials with distal filters (e.g., FilterWire, Boston Scientific, Natick, MA; SpiderFX, ev3 Endovascular, Inc., Plymouth, MN) and proximal occlusion

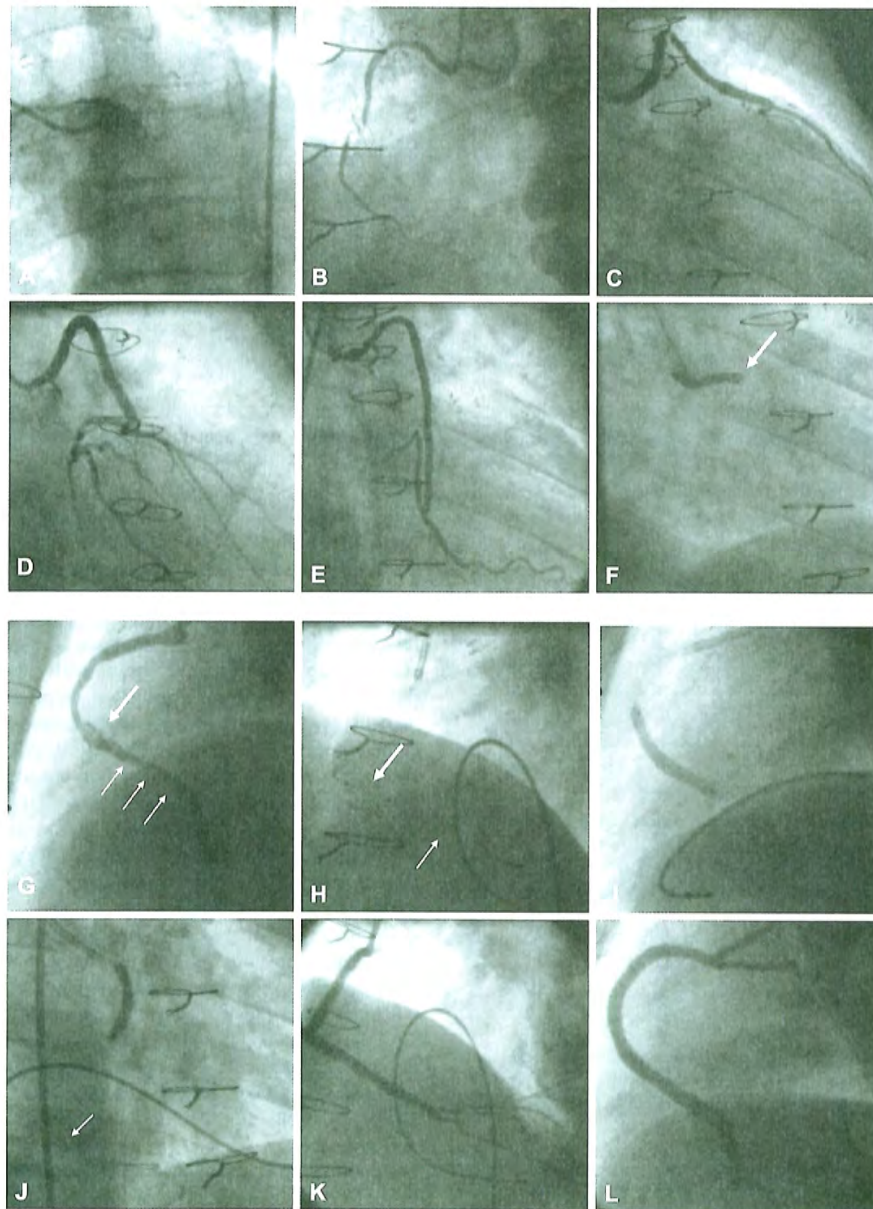


Figure 41.14 Saphenous vein graft intervention (SVG). **A.** The left main coronary artery is occluded at its origin. **B.** The right coronary artery is occluded and fills faintly by right-to-right bridging collaterals. **C.** The SVG to the diagonal branch is patent. **D.** The SVG to the ramus branch is patent. **E.** The SVG to an obtuse marginal branch is patent. **F.** The SVG to the posterior descending branch is acutely occluded (*arrow*). **G.** After wire recanalization, a large thrombus is seen in the midsegment of the SVG (*large arrow*) that extends more distally within the SVG (*small arrows*). **H.** An XVG AngioJet catheter (*large arrow*) is used to remove the thrombus after placement of a distal protection FilterWire (*small arrow*). **I.** A 3.5 × 33 mm CYPHER stent is placed in the distal portion of the SVG. **J.** Another 3.5 × 33 mm CYPHER stent is positioned in the proximal portion of the SVG. **K.** After removal of the FilterWire, the left anterior oblique projection demonstrates patency of a cascade of posterior descending and posterolateral branches. **L.** Complete stent expansion is confirmed in the left lateral projection.

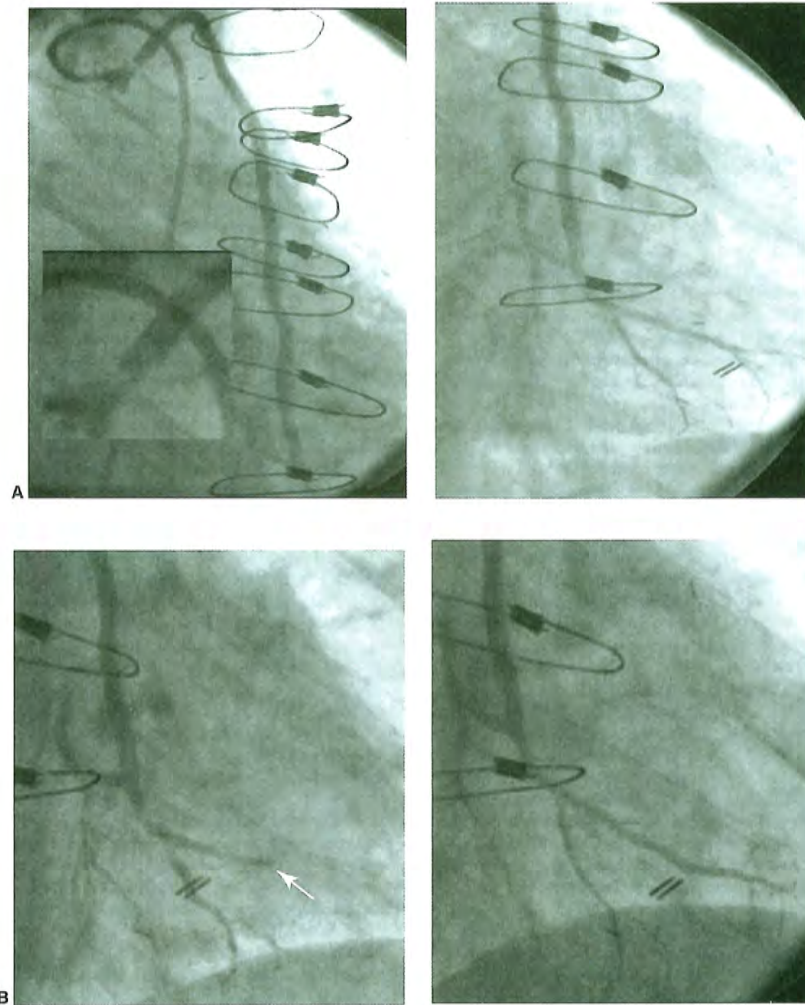


Figure 41.15

A. Left panel shows a very proximal lesion owing to in-stent restenosis in a saphenous vein graft to the obtuse marginal system. The magnified view of the lesion demonstrates a critical lesion followed by a filling defect just beyond the obstruction. The right panel shows the subtended marginal system. **B.** Left panel shows distinct cutoff (*white arrow*) of the upper branch of the obtuse marginal owing to distal embolization during stenting of the ostial lesion without embolic protection. Right panel shows restoration of flow after balloon angioplasty of the cutoff site. (Reproduced with permission from: EV Haddad, Piana RN. No-reflow, distal embolization and embolic protection. In: Moscucci M, ed. *Complications of Cardiovascular Procedures: Risk Factors, Management and Bailout Techniques*. Lippincott & Wilkins, 2011.)

devices (Proxis Embolic Protection System, St Jude Medical, Maple Grove, MN) have been noninferiority trials demonstrating similar outcomes.⁶²⁻⁶⁴ Given our inability to predict which patients will develop an embolic complication, embolic protection devices should be used in all suitable patients undergoing SVG intervention. Despite this Class I recommendation

in the 2011 ACC/AHA/SCAI PCI guidelines, embolic protection is used in only ~23% of eligible patients.⁶⁵

Microvascular (arteriolar) spasm and dislodgement of platelet aggregates are also causes of periprocedural myocardial infarction (MI). In addition to appropriate antiplatelet and antithrombotic therapy, agents to treat microvascular

spasm (nitroprusside, adenosine, verapamil, nicardipine) are therefore typically employed when treating vein grafts.⁶⁶

A meta-analysis of 19 studies demonstrated a 41% relative reduction in target vessel revascularization with DES as compared to BMS for SVG intervention without an increase in the risk of death, MI, or stent thrombosis.⁶⁷ Two ongoing trials are comparing DES with BMS in SVGs.⁶¹

REFERENCES

- Roger VL, Go AS, Lloyd-Jones DM, et al. Heart disease and stroke statistics—2012 update: A report from the American Heart Association. *Circulation* 2012;125:e2–e220.
- Go AS, Mozaffarian D, Roger VL, et al. Heart disease and stroke statistics—2013 update: a report from the American Heart Association. *Circulation* 2013;127:e6–e245.
- Roger VL, Go AS, Lloyd-Jones DM, et al. Heart disease and stroke statistics—2011 update: a report from the American Heart Association. *Circulation* 2011;123:e18–e209.
- Fox KA, Steg PG, Eagle KA, et al. Decline in rates of death and heart failure in acute coronary syndromes, 1999–2006. *JAMA* 2007;297:1892–1900.
- Levine GN, Bates ER, Blankenship JC, et al. 2011 ACCF/AHA/SCAI guideline for percutaneous coronary intervention: executive summary: a report of the American College of Cardiology Foundation/American Heart Association Task Force on Practice Guidelines and the Society for Cardiovascular Angiography and Interventions. *Circulation* 2011;124:2574–2609.
- Patel MR, Bailey SR, Bonow RO, et al. ACCF/SCAI/AATS/AHA/ASE/ASNC/HFSA/HRS/SCCM/SCCT/SCMR/STS 2012 appropriate use criteria for diagnostic catheterization: a report of the American College of Cardiology Foundation Appropriate Use Criteria Task Force, Society for Cardiovascular Angiography and Interventions, American Association for Thoracic Surgery, American Heart Association, American Society of Echocardiography, American Society of Nuclear Cardiology, Heart Failure Society of America, Heart Rhythm Society, Society of Critical Care Medicine, Society of Cardiovascular Computed Tomography, Society for Cardiovascular Magnetic Resonance, and Society of Thoracic Surgeons. *J Am Coll Cardiol* 2012;59:1995–2027.
- Raff GL, Abidov A, Achenbach S, et al. SCCT guidelines for the interpretation and reporting of coronary computed tomographic angiography. *J Cardiovasc Comput Tomogr* 2009;3:122–136.
- Levine GN, Bates ER, Blankenship JC, et al. 2011 ACCF/AHA/SCAI guideline for percutaneous coronary intervention. A report of the American College of Cardiology Foundation/American Heart Association Task Force on Practice Guidelines and the Society for Cardiovascular Angiography and Interventions. *J Am Coll Cardiol* 2011;58:e44–e122.
- Fraker TD Jr, Fihn SD, Gibbons RJ, et al. 2007 chronic angina focused update of the ACC/AHA 2002 guidelines for the management of patients with chronic stable angina: a report of the American College of Cardiology/American Heart Association Task Force on Practice Guidelines Writing Group to develop the focused update of the 2002 guidelines for the management of patients with chronic stable angina. *Circulation* 2007;116:2762–2772.
- Fihn SD, Gardin JM, Abrams J, et al. 2012 ACCF/AHA/ACP/AATS/PCNA/SCAI/STS guideline for the diagnosis and management of patients with stable ischemic heart disease: A report of the American College of Cardiology Foundation/American Heart Association Task Force on Practice Guidelines, and the American College of Physicians, American Association for Thoracic Surgery, Preventive Cardiovascular Nurses Association, Society for Cardiovascular Angiography and Interventions, and Society of Thoracic Surgeons. *Circulation* 2012;126:e354–e471.
- Boden WE, O'Rourke RA, Teo KK, et al. Optimal medical therapy with or without PCI for stable coronary disease. *N Engl J Med* 2007;356:1503–1516.
- De Bruyne B, Pijls NH, Kalesan B, et al. Fractional flow reserve-guided PCI versus medical therapy in stable coronary disease. *N Engl J Med* 2012;367:991–1001.
- Bravata DM, Gienger AL, McDonald KM, et al. Systematic review: the comparative effectiveness of percutaneous coronary interventions and coronary artery bypass graft surgery. *Ann Intern Med* 2007;147:703–716.
- Serruys PW, Morice MC, Kappetein AP, et al. Percutaneous coronary intervention versus coronary-artery bypass grafting for severe coronary artery disease. *N Engl J Med* 2009;360:961–972.
- The Bypass Angioplasty Revascularization Investigation (BARI) Investigators. Comparison of coronary bypass surgery with angioplasty in patients with multivessel disease. *N Engl J Med* 1996;335:217–225.
- Hlatky MA, Boothroyd DB, Bravata DM, et al. Coronary artery bypass surgery compared with percutaneous coronary interventions for multivessel disease: a collaborative analysis of individual patient data from ten randomised trials. *Lancet* 2009;373:1190–1197.
- Farkouh ME, Domanski M, Sleeper LA, et al. Strategies for multivessel revascularization in patients with diabetes. *N Engl J Med* 2012;367:2375–2384.
- Pijls NH, van Schaardenburgh P, Manoharan G, et al. Percutaneous coronary intervention of functionally nonsignificant stenosis: 5-year follow-up of the DEFER study. *J Am Coll Cardiol* 2007;49:2105–2111.
- Pijls NH, Fearon WF, Tonino PA, et al. Fractional flow reserve versus angiography for guiding percutaneous coronary intervention in patients with multivessel coronary artery disease: 2-year follow-up of the FAME (fractional flow reserve versus angiography for multivessel evaluation) study. *J Am Coll Cardiol* 2010;56:177–184.
- Yeh RW, Sidney S, Chandra M, Sorel M, Selby JV, Go AS. Population trends in the incidence and outcomes of acute myocardial infarction. *N Engl J Med* 2010;362:2155–2165.
- Fox CS, Evans JC, Larson MG, Kannel WB, Levy D. Temporal trends in coronary heart disease mortality and sudden cardiac death from 1950 to 1999: The Framingham Heart Study. *Circulation* 2004;110:522–527.
- O'Gara PT, Kushner FG, Ascheim DD, et al. 2013 ACCF/AHA guideline for the management of st-elevation myocardial infarction: a report of the American College of Cardiology Foundation/American Heart Association Task Force on Practice Guidelines. *J Am Coll Cardiol* 2013;61:e78–e140.
- Vlaar PJ, Svilaas T, van der Horst IC, et al. Cardiac death and reinfarction after 1 year in the thrombus aspiration during percutaneous coronary intervention in acute myocardial infarction study (TAPAS): a 1-year follow-up study. *Lancet* 2008;371:1915–1920.
- Vlaar PJ, Mahmoud KD, Holmes DR Jr, et al. Culprit vessel only versus multivessel and staged percutaneous coronary intervention for multivessel disease in patients presenting with ST-segment elevation myocardial infarction: a pairwise and network meta-analysis. *J Am Coll Cardiol* 2011;58:692–703.
- Cannon CP, Weintraub WS, Demopoulos LA, et al. Comparison of early invasive and conservative strategies in patients with unstable coronary syndromes treated with the glycoprotein IIb/IIIa inhibitor tirofiban. *N Engl J Med* 2001;344:1879–1887.
- Fox KA, Poole-Wilson PA, Henderson RA, et al. Interventional versus conservative treatment for patients with unstable angina or non-ST-elevation myocardial infarction: the British Heart Foundation RITA 3 randomised trial. Randomized intervention trial of unstable angina. *Lancet* 2002;360:743–751.
- Fragmin and Fast Revascularisation During Instability in Coronary Artery Disease Investigators. Invasive compared with non-invasive treatment in unstable coronary-artery disease: FRISC II prospective randomised multicentre study. *Lancet* 1999;354:708–715.
- Anderson JL, Adams CD, Antman EM, et al. 2011 ACCF/AHA focused update incorporated into the ACC/AHA 2007 guidelines

- for the management of patients with unstable angina/non-ST-elevation myocardial infarction: a report of the American College of Cardiology Foundation/American Heart Association Task Force on Practice Guidelines. *Circulation* 2011;123:e426–e579.
29. Anderson JL, Adams CD, Antman EM, et al. ACC/AHA 2007 guidelines for the management of patients with unstable angina/non ST-elevation myocardial infarction: a report of the American College of Cardiology/American Heart Association Task Force on Practice Guidelines (writing committee to revise the 2002 guidelines for the management of patients with unstable angina/non ST-elevation myocardial infarction): developed in collaboration with the American College of Emergency Physicians, the Society for Cardiovascular Angiography and Interventions, and the Society of Thoracic Surgeons: Endorsed by the American Association of Cardiovascular and Pulmonary Rehabilitation and the Society for Academic Emergency Medicine. *Circulation* 2007;116:e148–e304.
 30. DeMots H, Rosch J, McAnulty JH, Rahimtoola SH. Left main coronary artery disease. *Cardiovasc Clin* 1977;8:201–211.
 31. Fajadet J, Chieffo A. Current management of left main coronary artery disease. *Eur Heart J* 2012;33:36–50b.
 32. Takaro T, Peduzzi P, Detre KM, et al. Survival in subgroups of patients with left main coronary artery disease. Veterans administration cooperative study of surgery for coronary arterial occlusive disease. *Circulation* 1982;66:14–22.
 33. Chaitman BR, Fisher LD, Bourassa MG, et al. Effect of coronary bypass surgery on survival patterns in subsets of patients with left main coronary artery disease. Report of the collaborative study in coronary artery surgery (CASS). *Am J Cardiol* 1981;48:765–777.
 34. Caracciolo EA, Davis KB, Sopko G, et al. Comparison of surgical and medical group survival in patients with left main coronary artery disease. Long-term CASS experience. *Circulation* 1995;91:2325–2334.
 35. Seung KB, Park DW, Kim YH, et al. Stents versus coronary-artery bypass grafting for left main coronary artery disease. *N Engl J Med* 2008;358:1781–1792.
 36. Park SJ, Kim YH, Park DW, et al. Randomized trial of stents versus bypass surgery for left main coronary artery disease. *N Engl J Med* 2011;364:1718–1727.
 37. Morice MC, Serruys PW, Kappetein AP, et al. Outcomes in patients with de novo left main disease treated with either percutaneous coronary intervention using paclitaxel-eluting stents or coronary artery bypass graft treatment in the synergy between percutaneous coronary intervention with taxus and cardiac surgery (SYNTAX) trial. *Circulation* 2010;121:2645–2653.
 38. Capodanno D, Tamburino C. Unraveling the EXCEL: promises and challenges of the next trial of left main percutaneous coronary intervention. *Int J Cardiol* 2012;156:1–3.
 39. Mehilli J, Kastrati A, Byrne RA, et al. Paclitaxel- versus Sirolimus-eluting stents for unprotected left main coronary artery disease. *J Am Coll Cardiol* 2009;53:1760–1768.
 40. Palmerini T, Marzocchi A, Tamburino C, et al. Impact of bifurcation technique on 2-year clinical outcomes in 773 patients with distal unprotected left main coronary artery stenosis treated with drug-eluting stents. *Circ Cardiovasc Interv* 2008;1:185–192.
 41. Christofferson RD, Lehmann KG, Martin GV, Every N, Caldwell JH, Kapadia SR. Effect of chronic total coronary occlusion on treatment strategy. *Am J Cardiol* 2005;95:1088–1091.
 42. Hochman JS, Lamas GA, Buller CE, et al. Coronary intervention for persistent occlusion after myocardial infarction. *N Engl J Med* 2006;355:2395–2407.
 43. Baks T, van Geuns RJ, Duncker DJ, et al. Prediction of left ventricular function after drug-eluting stent implantation for chronic total coronary occlusions. *J Am Coll Cardiol* 2006;47:721–725.
 44. Kirschbaum SW, Baks T, van den Ent M, et al. Evaluation of left ventricular function three years after percutaneous recanalization of chronic total coronary occlusions. *Am J Cardiol* 2008;101:179–185.
 45. Olivari Z, Rubartelli P, Piscione F, et al. Immediate results and one-year clinical outcome after percutaneous coronary interventions in chronic total occlusions: data from a multicenter, prospective, observational study (TOAST-GISE). *J Am Coll Cardiol* 2003;41:1672–1678.
 46. Jones DA, Weerackody R, Rathod K, et al. Successful recanalization of chronic total occlusions is associated with improved long-term survival. *JACC Cardiovasc Interv* 2012;5:380–388.
 47. Valenti R, Migliorini A, Signorini U, et al. Impact of complete revascularization with percutaneous coronary intervention on survival in patients with at least one chronic total occlusion. *Eur Heart J* 2008;29:2336–2342.
 48. Werner GS, Surber R, Ferrari M, Fritzenwanger M, Figulla HR. The functional reserve of collaterals supplying long-term chronic total coronary occlusions in patients without prior myocardial infarction. *Eur Heart J* 2006;27:2406–2412.
 49. Claessen BE, van der Schaaf RJ, Verouden NJ, et al. Evaluation of the effect of a concurrent chronic total occlusion on long-term mortality and left ventricular function in patients after primary percutaneous coronary intervention. *JACC Cardiovasc Interv* 2009;2:1128–1134.
 50. Hannan EL, Wu C, Walford G, et al. Incomplete revascularization in the era of drug-eluting stents: Impact on adverse outcomes. *JACC Cardiovasc Interv* 2009;2:17–25.
 51. Hoye A. Management of chronic total occlusion by percutaneous coronary intervention. *Heart* 2012;98:822–828.
 52. Joyal D, Thompson CA, Grantham JA, Buller CE, Rinfret S. The retrograde technique for recanalization of chronic total occlusions: a step-by-step approach. *JACC Cardiovasc Interv* 2012;5:1–11.
 53. Brilakis ES, Grantham JA, Thompson CA, et al. The retrograde approach to coronary artery chronic total occlusions: a practical approach. *Catheter Cardiovasc Interv: Off J Soc Cardiac Angiogr Interv* 2012;79:3–19.
 54. Brilakis ES, Grantham JA, Rinfret S, et al. A percutaneous treatment algorithm for crossing coronary chronic total occlusions. *JACC Cardiovasc Interv* 2012;5:367–379.
 55. Suttorp MJ, Laarman GJ, Rahel BM, et al. Primary stenting of totally occluded native coronary arteries II (PRISON II): a randomized comparison of bare metal stent implantation with Sirolimus-eluting stent implantation for the treatment of total coronary occlusions. *Circulation* 2006;114:921–928.
 56. Saeed B, Mazloum H, Askar M. Spontaneous remission of post-transplant recurrent focal and segmental glomerulosclerosis. *Saudi J Kidney Dis Transplant: Off Publ Saudi Center Organ Transpl, Saudi Arabia* 2011;22:1219–1222.
 57. Colmenarez HJ, Escaned J, Fernandez C, et al. Efficacy and safety of drug-eluting stents in chronic total coronary occlusion recanalization: a systematic review and meta-analysis. *J Am Coll Cardiol* 2010;55:1854–1866.
 58. Rathore S, Matsuo H, Terashima M, et al. Procedural and in-hospital outcomes after percutaneous coronary intervention for chronic total occlusions of coronary arteries 2002 to 2008: Impact of novel guidewire techniques. *JACC Cardiovasc Interv* 2009;2:489–497.
 59. Baim DS, Wahr D, George B, et al. Randomized trial of a distal embolic protection device during percutaneous intervention of saphenous vein aorto-coronary bypass grafts. *Circulation* 2002;105:1285–1290.
 60. Auero F, Gruentzig A. Distal embolization of a coronary artery bypass graft atheroma during percutaneous transluminal coronary angioplasty. *Am J Cardiol* 1984;53:953–954.
 61. Lee MS, Park SJ, Kandzari DE, et al. Saphenous vein graft intervention. *JACC Cardiovasc Interv* 2011;4:831–843.
 62. Caputo R. Itraconazole (sporanox) in superficial and systemic fungal infections. *Expert Rev Anti-Infective Ther* 2003;1:531–542.
 63. Dixon SR, Grines CL, O'Neill WW. The year in interventional cardiology. *J Am Coll Cardiol* 2006;47:1689–1706.
 64. Mauri L, Cox D, Hermiller J, et al. The proximal trial: Proximal protection during saphenous vein graft intervention using the proxis

- embolic protection system: a randomized, prospective, multicenter clinical trial. *J Am Coll Cardiol* 2007;50:1442-1449.
65. Brilakis ES, Wang TY, Rao SV, et al. Frequency and predictors of drug-eluting stent use in saphenous vein bypass graft percutaneous coronary interventions: a report from the American College of Cardiology National Cardiovascular Data CathPCI Registry. *JACC: Cardiovasc Interv* 2010;3:1068-1073.
66. Piana RN, Paik GY, Moscucci M, et al. Incidence and treatment of 'no-reflow' after percutaneous coronary intervention. *Circulation* 1994;89:2514-2518.
67. Lee MS, Yang T, Kandzari DE, Tobis JM, Liao H, Mahmud E. Comparison by meta-analysis of drug-eluting stents and bare metal stents for saphenous vein graft intervention. *Am J Cardiol* 2010;105:1076-1082.