

NASAL ADMINISTRATION OF NALOXONE FOR DETECTION OF OPIATE DEPENDENCE

NORBERT LOIMER, PETER HOFMANN and HAROON RASHID CHAUDHRY*

Psychiatrische Universitätsklinik Wien, Waehringer Guertel 18-20 A-1090 Vienna, Austria and *King Edward
Medical College, Punjab University, Lahore, Pakistan

(Received 14 January 1991; accepted in final form 7 August 1991)

Summary—In clinical trials, nasally applied naloxone was used to identify opiate dependence in humans for the first time. Withdrawal distress was recorded, and pupillary response, pulse rate and blood pressure measured. A significant increase in withdrawal distress and pupillary dilation was observed after nasal administration of 1mg (1mg/400 μ l) naloxone in all subjects who also showed opiate-positive urine samples. In control subjects, no reaction to naloxone was observed. It may be concluded that the nasal route for naloxone administration is as effective as the parenteral route. This test is sensitive enough to identify the physically-dependent opiate user and might have a role in emergency medicine and withdrawal treatment.

Introduction

UP TILL the present time, naloxone has been used intravenously, intramuscularly or subcutaneously for a variety of indications, e.g. as diagnostic tool for opiate dependence (Wang, Wiesen, Lamid, & Roth, 1974; Peachey & Lei, 1988), for emergency use, for opiate detoxification treatment, for shock treatment and in the management of postoperative narcotic depression and narcotic overdosage (Martin, 1976). The most rapid onset of action is achieved by intravenous administration. Unfortunately, the oral route, which is the least invasive and most acceptable method for administering a drug, is ineffective because of rapid hepatic elimination, e.g. first pass effect (Fishman, Roffwarg, & Hellman, 1973; Weinstein, Pfeffer, & Schor, 1973). Conjunctival administration of naloxone was unsuccessful as a test of opiate dependence (Loimer, Grünberger, Linzmayer, & Schmid, 1990).

During a search for another approach, increased bioavailability of naloxone was identified after buccal administration (Hussain, Aungst, Kearney, & Shefter, 1987). Reviewing the earlier literature we have so far been unable to find any alternative route of administering naloxone in humans, providing the same benefits as the intravenous route e.g., rapid onset, high bioavailability and short duration of action, without any of the risks associated with vessel puncture. With the advent of AIDS, it has become very important to identify a noninvasive alternative method of drug administration in intravenous drug users which can be used routinely for diagnostic and therapeutic purposes. Based on encouraging findings in animal studies by Hussain, Kimura, Huang, and Kashihara (1984), we report a simple, but effective method of overcoming this problem.

Patients and Methods

Patients

At the central hospital of Lahore district jail, 30 consecutive volunteer patients were investigated immediately after admission to prison hospital prior to routine gradual detoxification. The procedure had been explained to them and they had given informed consent. Twenty-two male prisoners satisfied DSM-III-R opiate-dependence criteria (age 20–50 years; drug addiction history 3–15 years, bodyweight 48–70 kg, height 160–178 cm, daily heroin dose 2–5 g (all inhaling). The control group consisted of 8 male prisoners (age 22–50 years; bodyweight 50–65 kg, height 166–176 cm).

To control drug abuse, urine samples of all subjects were screened for drugs of abuse, by means of EMIT-dau™. All patients were free of systemic illness and medication.

Measurement of naloxone effect

The severity of withdrawal symptoms after nasal naloxene application (the naloxone nasal spray, 1mg/400 µl, was freshly prepared by CURAMED[®] in isotonic phosphate buffer, pH=6.5) in each patient was assessed by means of a modified rating scale (Kolb & Himmelsbach, 1938). This clinical evaluation scale included: uncontrollable yawning, running nose, lacrimation, profuse sweating, shivering, abdominal cramps, piloerection, hand tremors, muscular twitches, restlessness, vomiting and diarrhoea. Clinical ratings were carried out before nasal naloxone instillation, and 1, 5, 10, 15, 30 min thereafter. Heart rate and blood pressure were measured, before naloxene instillation and 10 and 30 min thereafter. Clinical ratings were performed by physicians blind to the patient's diagnosis.

Pupillary response was assessed photographically by means of a Polaroid photo (Type Polaroid CU-5 land camera, USA—specially equipped with a fixed photocell pupil distance, and two-fold enlargement) of the left eye before instillation of naloxone and 10 and 30 min thereafter. The procedure was carried out under constant conditions of reduced ambient lightening in an illuminated room (200 lux; size: 7 x 9 m) after an adaptation period of 10 min. Changes in pupillary diameter are best detected by comparison of the pupil/iris ratios (Creighton & Ghodse, 1989). The diameters of iris and pupil were measured and the ratio between them calculated.

Statistical analysis included univariant analysis of variance, the Newman–Keuls test and the Duncan test.

Results

Comparing group A (addicted patients, n = 22) and group B (control group, n = 8) with respect to clinical rating scale, there was no difference in rating score before naloxone was instilled ($F = 2.196$, n.s.; $D = 1.48$, n.s.). After 1 min, the difference reached a level of statistical significance ($F = 5.021$, $p < 0.05$; $D = 2.24$, $p < 0.05$). After 5 min: $F = 19.181$, $p < 0.01$; $D = 4.38$, $p < 0.01$; 10 min rating: $F = 22.943$, $p < 0.01$; $D = 4.79$, $p < 0.01$. The 15 min rating showed: $F = 27.373$, $p < 0.01$; $D = 5.23$, $p < 0.01$. The final rating after 30 min showed: $F = 10.162$, $p < 0.01$; $D = 3.19$, $p < 0.01$.

As shown in Fig. 1, clinical rating reveals no changes reaching the level of significance,

throughout the observation period. In contrast, the changes in group A between the first and subsequent ratings did reach a level of significance.

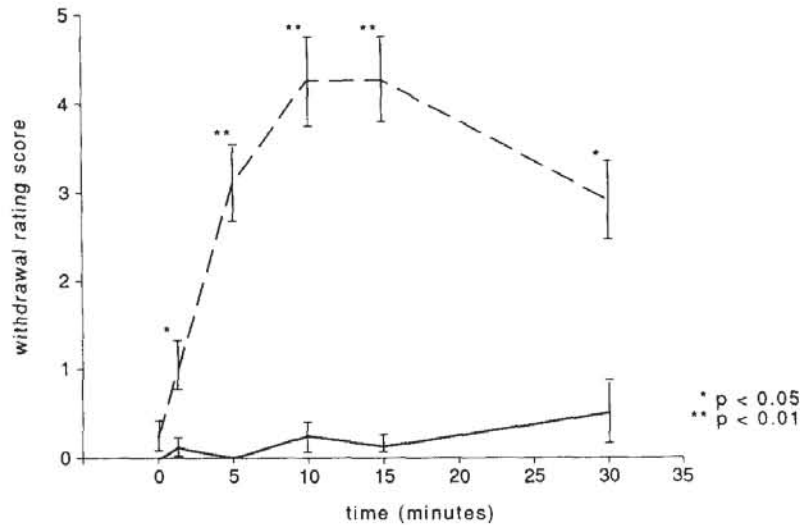


Figure 1. Changes in clinical ratings in addicted (---) and nonaddicted subjects (—).

Heart rate and blood pressure (Table 1) showed no statistically significant change either within groups or comparing the two groups. The measurement of iris-pupil ratio in group B (two-way ANOVA, Duncan test) revealed no changes reaching the level of significance

Table 1
Vital signs, in response to nasal administration of 1 mg naloxone

Time	Baseline	10 min	30 min
Heart rate			
group A	82.95	83.91	86.77
SD	(9.01)	(11.17)	(14.47)
group B	80.63	79.63	80.75
SD	(13.66)	(8.8)	(14.06)
Systolic blood pressure			
group A	112.27	114.32	115.68
SD	(13.86)	(15.22)	(15.30)
group B	108.13	108.75	109.38
SD	(8.84)	(9.91)	(10.16)
Diastolic blood pressure			
group A	74.55	78.41	79.09
SD	(9.5)	(13.57)	(10.87)
group B	75.63	74.38	76.25
SD	(11.16)	(11.16)	(5.18)

throughout the observation period. In group A, pupillary dilation of statistically significant levels 10 min (Newman-Keuls $-3,63$, $p < 0.01$) after naloxone administration. After 30 min no statistically significant difference could be detected. Comparing the two groups before naloxone application, a significant difference was observed ($F = 6.558$, $p < 0.05$; $D = 2.56$, $p < 0.05$). In subsequent observations no statistically significant differences between the two groups were detected (Fig. 2). Urine analyses revealed recent use of opiates only in group A; in both groups, no other classes of drug could be detected.

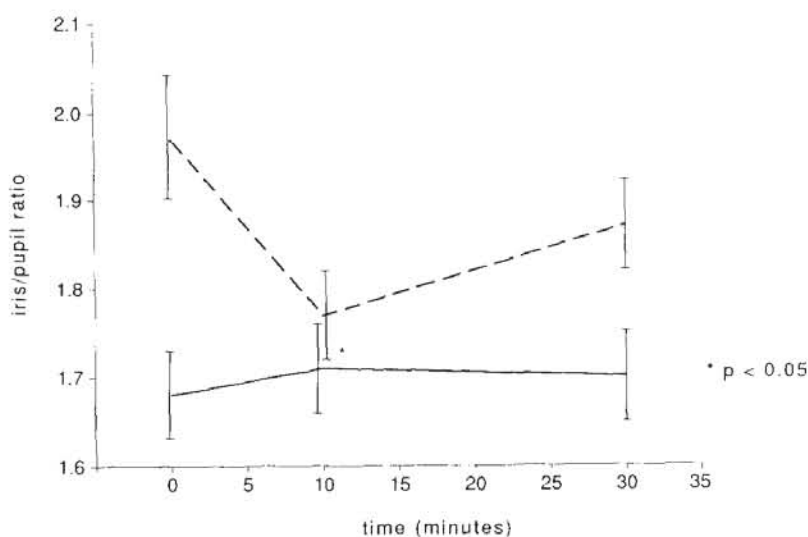


Figure 2. Mean iris/pupil ratio in addicted (---) and nonaddicted subjects (—).

Discussion

According to the clinical rating scores, naloxone was found to be absorbed rapidly from the nasal cavity. The onset of withdrawal distress in opiate addicts was nearly as rapid as after intravenous administration of naloxone. Withdrawal distress reached a climax after 10 min and showed a significant decline thereafter (Fig. 1). As expected, there was a significant difference in diameter of the pupil between the two groups before naloxone was administered. This difference disappeared after naloxone-induced pupillary dilation in group A. Clinical evaluation of withdrawal distress symptoms was supported by parallel pupillary changes induced by naloxone in opiate addicts! The administration of 1 mg naloxone did not lead to any changes in vital signs, and this approach appears to offer a substantial safety margin. The clinical response to naloxone was paralleled by findings in the urine samples. Mydriasis and withdrawal distress in response to intranasal naloxone administration indicates chronic exposure to opiate agonists and therefore physical dependence (Creighton & Ghodse, 1989). However, naloxone has already been used successfully as a tool for predicting treatment outcome (Jacobsen & Kosten, 1989). As sniffing is commonly used for heroin self administration, it is interesting that naloxone

has never been employed in this manner until now. These data suggest that nasal administration of naloxone is as effective as intravenous administration. Thus, the use of a nasal naloxone spray is proposed for the detection of physical dependency, not only for methadone programs but also for forensic problems, for the prevention of acute relapse avoiding long term naltrexone treatment, for noninvasive detoxification treatment procedures, for treating emergency cases, for neonatal intensive care and for other indications.

Acknowledgements—We thank Polaroid, CuraMed for assistance and Prof. J. Grünberger for statistical analysis. Thanks to the IG-prison of Punjab Hafiz M. Qasim, the superintendent of Lahore prison, S. Kahn, and Prof. M. R. Chaudhry and Prof. P. Berner, who supported our study.

References

- Creighton, F. J., & Ghodse, A. H. (1989). Naloxone applied to conjunctiva as a test for physical opiate dependence. *Lancet*, *1*, 748–750.
- Fishman, J., Roffwarg, H., & Hellman, L. (1973). Disposition of naloxone 7, 8-H in normal and narcotic dependent men. *Journal of Pharmacology and Experimental Therapeutics*, *187*, 575–580.
- Hussain, A., Kimura, R., Huang, C. H., & Kashihara, T. (1984). Nasal absorption of naloxone and buprenorphine in rats. *International Journal of Pharmaceutics*, *21*, 233–237.
- Hussain, M. A., Aungst, B. J., Kearney, A., & Shefter, E. (1987). Buccal and oral bioavailability of naloxone and naltrexone in rats. *International Journal of Pharmaceutics*, *36*, 127–130.
- Jacobsen, L. K., & Kosten, T. R. (1989). Naloxone challenge as a biological predictor of treatment–outcome in opiate addicts. *American Journal of Drug and Alcohol Abuse*, *15*, 355–366.
- Kolb, L., & Himmelsbach, C. K. (1938). A critical review of the withdrawal treatments with method of evaluating abstinence syndromes. *American Journal of Psychiatry*, *94*, 759–799.
- Loimer, N., Grünberger, J., Linzmayer, L., & Schmid, R. (1990). Conjunctival naloxone is no decision aid in opioid addiction. *Lancet*, *335*, 1107–1108.
- Martin, W. R. (1976). Naloxone. *Annals of Internal Medicine*, *85*, 765–768.
- Peachey, J. E., & Lei, H. (1988). Assessment of opioid dependence with naloxone. *British Journal of Addiction*, *83*, 193–201.
- Wang, R. I. H., Wiesen, R. L., Lamid, S., & Roth, B. L. (1974). Rating the presence of opiate dependence. *Clinical Pharmacology and Therapeutics*, *16*, 653–658.
- Weinstein, S. H., Pfeffer, M., & Schor, J. M. (1973). Metabolism and pharmacokinetics of naloxone. *Advances in Biochemical Psychopharmacology*, *8*, 525–535.