


Pitfalls of Intranasal Naloxone


Matthew Zuckerman MD, Stacy N. Weisberg MPH, MD, FACEP & Edward W. Boyer MD, PhD, FACEP

To cite this article: Matthew Zuckerman MD, Stacy N. Weisberg MPH, MD, FACEP & Edward W. Boyer MD, PhD, FACEP (2014) Pitfalls of Intranasal Naloxone, Prehospital Emergency Care, 18:4, 550-554, DOI: [10.3109/10903127.2014.896961](https://doi.org/10.3109/10903127.2014.896961)



To link to this article: <http://dx.doi.org/10.3109/10903127.2014.896961>

 Published online: 15 May 2014.

 Submit your article to this journal 

 Article views: 577

 View related articles 

 View Crossmark data 

Full Terms & Conditions of access and use can be found at
<http://www.tandfonline.com/action/journalInformation?journalCode=ipec20>

Download by: [NIH Library]

Date: 15 March 2016, At: 14:40

CASE CONFERENCES

PITFALLS OF INTRANASAL NALOXONE

Matthew Zuckerman, MD, Stacy N. Weisberg, MPH, MD, FACEP,
Edward W. Boyer, MD, PhD, FACEP

ABSTRACT

We present a case of failed prehospital treatment of fentanyl induced apnea with intranasal (IN) naloxone. While IN administration of naloxone is becoming more common in both lay and pre-hospital settings, older EMS protocols utilized intravenous (IV) administration. Longer-acting, higher potency opioids, such as fentanyl, may not be as easily reversed as heroin, and studies evaluating IN administration in this population are lacking. In order to contribute to our understanding of the strengths and limitations of IN administration of naloxone, we present a case where it failed to restore ventilation. We also describe peer reviewed literature that supports the use of IV naloxone following heroin overdose and explore possible limitations of generalizing this literature to opioids other than heroin and to IN routes of administration. **Key words:** prescription opioids, overdose, intranasal naloxone

PREHOSPITAL EMERGENCY CARE 2014;18:550-554

INTRODUCTION

Every 14 minutes another young adult dies from drug overdose in the United States.¹ Closer inspection reveals that opioid analgesics are driving this epidemic.² Over half of drug overdose deaths involve prescription pharmaceuticals, and opioid analgesics are involved in approximately 3 of every 4 pharmaceutical overdose deaths. Though prescription of opioids varies

largely by region, the overall trend is ever increasing with some areas showing a 500% increase from 2000 to 2010.³ As prescriptions for opioids increase, nonmedical use and opioid-related death also increase.⁴

Public health policy experts respond to this epidemic by calling for primary prevention that monitors for "doctor shopping," statewide prescription monitoring programs, and prescribing guidelines to curtail the inappropriate use of opioid medications. Meanwhile, secondary prevention has focused on naloxone as a means of reducing the morbidity and mortality associated with nonmedical use of opioids. Initial studies focused on use of intramuscular naloxone to prevent death from heroin abuse.^{5,6} More recently intranasal naloxone has become available and more attractive to both prehospital providers and nonmedical personnel. The initial benefit of intranasal administration of naloxone appeared to be ease of use by nonmedical providers. Due to concerns over delays in achieving intravenous access and reducing body fluid exposure, some EMS (emergency medical services) systems have started utilizing intranasal naloxone as first-line therapy for opioid overdose.^{7,8} While intranasal naloxone has allowed for needle-less bystander opioid overdose rescue, issues regarding bioavailability, titratability, effectiveness in cases of nonheroin overdose, and ultimately whether this delivery method is appropriate for first-line EMS response remain unclear. As with any therapeutic intervention, previously published case reports highlight successful use of intranasal naloxone, but reporting bias may lead to an underestimation of treatment failures. We present a case where intranasal (IN) naloxone failed to achieve the desired effect of improved ventilation, requiring the administration of intravenous (IV) naloxone.

CASE

The patient was a 26-year-old male with history of opioid abuse who was found with agonal respirations, decreased mental status, and miotic pupils after intentionally masticating two 25- μ g fentanyl

Received November 8, 2013 from the Department of Emergency Medicine, University of Massachusetts Medical School, Worcester, Massachusetts. Revision received January 14, 2014; accepted for publication February 4, 2014.

The authors report no conflicts of interest. The authors alone are responsible for the content and writing of the paper.

Address correspondence to Stacy N. Weisberg, MPH, MD, FACEP, Department of Emergency Medicine, University of Massachusetts Medical School, 55 Lake Avenue North, Worcester, MA 01655, USA. e-mail: Stacy.Weisberg@umassmemorial.org

doi: 10.3109/10903127.2014.896961

patches. He was found by his wife who called 9-1-1. Paramedics noted that the patient had heart rate of 56 beats per minute, respiratory rate of 6 breaths per minute, and pulse oximetry of 89% with clammy skin. Paramedics recognized a possible opiate overdose and administered 1 mg naloxone atomizer in each nostril with no change in respiratory rate over the subsequent 11 minutes. Paramedics then placed a peripheral IV line and administered naloxone 1 mg intravenously; this resulted in the desired endpoint of normalization of respirations and improvement in mental status. Following administration of intravenous naloxone, the patient was tremulous and nauseated. Upon arrival in the emergency department, the patient had a respiratory rate of 20, oxygen saturation of 94% on 100% O₂ via nonrebreather, pulse 150 beats per minute, blood pressure 176/151 mmHg, and oral temperature of 35.8°C. The patient at this time also had 5-mm reactive pupils bilaterally. Within 15 minutes of arrival, however, the patient required two additional doses of naloxone 0.4 mg IV. Serum ethanol level upon admission was undetectable. Urine toxicology via GCMS was positive for nicotine and metabolites, caffeine, fentanyl and metabolites, chlorpheniramine, and citalopram. The patient was observed overnight on a cardiopulmonary monitor for recurrence of apnea or hypoventilation, but did not require any further administration of naloxone.

DISCUSSION

This case highlights the potential pitfalls of using intranasal naloxone for rescue in an undifferentiated opioid overdose. Naloxone has previously been adminis-

tered parenterally in medical settings to reverse heroin overdose. More recently, take-home naloxone (THN) programs utilizing bystander IN naloxone along with intensive overdose education campaigns have been associated with decreased mortality from overdose in particular populations.⁹ Such studies are limited by a lack of reporting on individual cases and a study design that often classifies all administrations as “life saved,” potentially minimizing unsuccessful administrations and adverse outcomes. At the same time, utilization of IN naloxone by EMS provides more detailed reporting. This may include important information on vital signs and physical exam gathered by trained medical staff, as well as documentation that may indicate whether IN naloxone was successful. Before implementing widespread use of EMS-administered IN naloxone, it is important to understand if prior studies that focused on heroin overdose are generalizable to patients abusing other agents, as well as whether studies focusing on bystander intervention are generalizable to paramedics.

During much of the twentieth century, naloxone was administered largely in response to heroin overdose; this pattern has changed as opioid related deaths are five times as likely to be due to prescription opioid analgesics rather than heroin.¹⁰ Data from the Drug Abuse Warning Network suggests that nonmedical use of oxycodone, hydrocodone, methadone, and fentanyl are on the rise, with a 149% increase in ED visits related to narcotic pain medications^{11,12} (Figure 1). A 2013 review of opioid related deaths in Ontario, Canada demonstrated that heroin was associated with less than 2% of all deaths, while the most common opioids implicated were oxycodone, morphine, methadone,

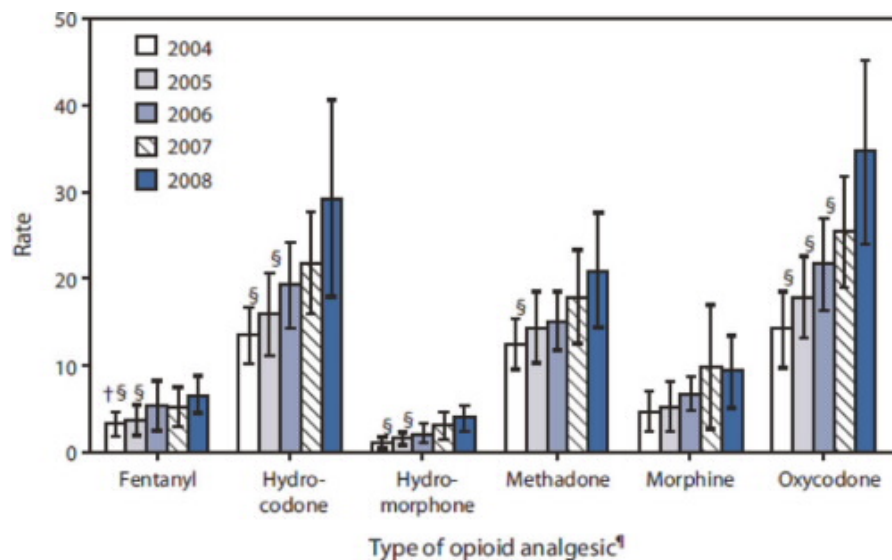


FIGURE 1. Pattern of prescription opioid abuse 2004–2008.

codeine, and fentanyl.¹³ It is unclear whether current dosing regimens of IN naloxone are as effective in treating longer-acting, higher-potency opioids.

These medications have different pharmacokinetics and pharmacodynamics than heroin. The fact that the opioid in this case was fentanyl, abused as a transdermal patch, probably contributed to toxicity. Fentanyl is an opioid derivative 600 times as lipid soluble and 100 times as potent as morphine. Fentanyl patches are notable for a prolonged duration of effect, even when used appropriately. Following removal of dermal patches, continued effects of respiratory depression and miosis may be seen for up to 24 hours.¹⁴ Route of exposure may also effect toxicity, and ingestion of fentanyl patches is an independent risk factor for overdose. Notable cases of fentanyl patch toxicity have required intubation, high-dose naloxone infusion, and resulted in death.¹⁵ A retrospective multisite case review determined that the most common related signs were coma, lethargy, and respiratory depression.¹⁶ The majority required naloxone treatment. Of note, 5.3% of these cases signed out against medical advice. Altered pharmacodynamics and pharmacokinetics may contribute to the staggering mortality associated with methadone, which represents 3% of opiate prescriptions but is responsible for almost a third of opioid-related deaths.¹⁷ This is highlighted in the graph below, illustrating that the duration of effects of opioid medications can range from hours to days, while the duration of effect of heroin rarely exceeds 30 minutes¹⁸ (Figure 2).

Another issue with intranasal administration of naloxone relates to poor bioavailability and unpredictable absorption and clinical effects. Intranasal naloxone has a 4% bioavailability, significantly reducing serum levels. Typical intranasal administration protocols call for a one-size-fits-all (1 mg per nostril)

dosing. When medical providers administer IV naloxone, dosing may be adjusted to provide just enough antagonism to reverse apnea without precipitating withdrawal. Focus groups with IVDU report that they have a fear of precipitating “dope sickness” following administration of home naloxone.¹⁹ These users report that they would likely redose themselves with opioid medications to treat such withdrawal symptoms. Such behavior can be lethal. Death from overdose increases dramatically following recovery from nonfatal overdose; opioid withdrawal triggered by intranasal naloxone may be a powerful motivator to reuse and cause more harm than good.²⁰

The use of home naloxone to avoid involving medical professionals is a recurring theme, with THN participants exclaiming “No one called 9-1-1 for the guy who was overdosing. They called me instead.”²¹ Recipients of bystander initiated naloxone call 9-1-1 about 31% of the time.²² Though often instructed to do so, this may not occur due to fear of legal repercussions or a misperception that once the person has woken up, they are safe.²¹ Many observers may ask if such avoidance is a problem if the patient has safely “recovered” from their overdose with a single dose of home naloxone. Unfortunately, current recommendations for staying with the patient “until they have woken up” underestimate the long duration of effect of commonly abused opiates, the short duration of effect of naloxone, and the risk of recurrence of apnea. An opioid-naïve patient suffering the effects of a long acting opioid, such as methadone, may be at risk for respiratory depression several hours after the initial administration of naloxone. When the primary use of naloxone was in heroin overdose, it may have been reasonable to set a 1-hour observation period; however, the changing face of an opioid overdose epidemic fueled by longer-acting opioids (with duration of effects from

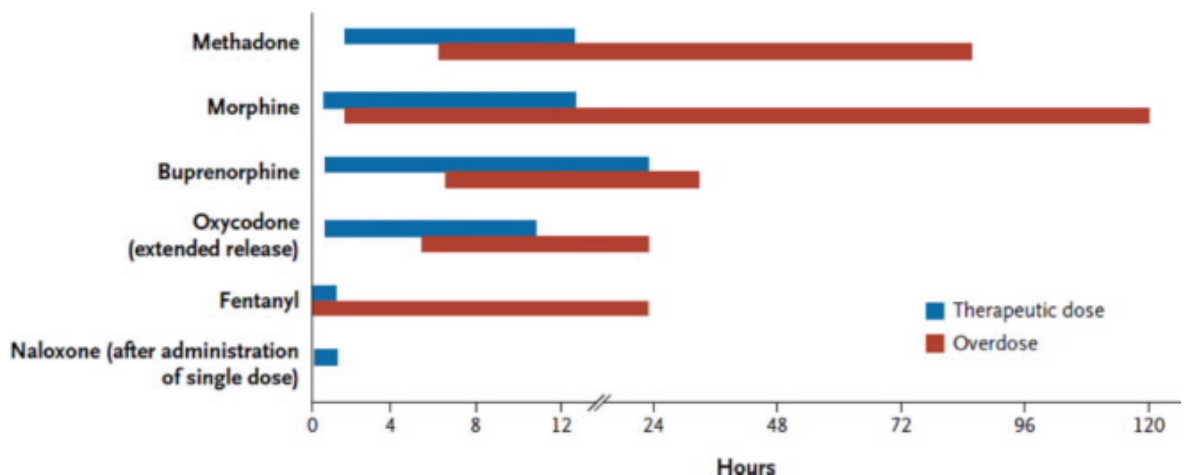


FIGURE 2. Duration of effect of opioid medications in therapeutic use vs. overdose.

4 hours to 4 days) has led to a revision of post naloxone observation periods to a minimum of 4–6 hours.¹⁸

Patients who are left unobserved following home naloxone administration may at be increased risk. Extrapolations may be made from prior studies that explored the sequelae of patients refusing hospital transport following out-of-hospital naloxone. Most of these studies have found no immediate deaths.^{23,24} Unfortunately, the inherent limitations in these study designs (review of local medical examiner records) may miss nonlethal morbidity and readministration of out of hospital naloxone. More rigorous follow-up of such patients is therefore needed. Though Wampler et al.²³ report no deaths within 48 hours of receiving naloxone in patients who refused hospital transport, there was almost a 2% 30-day mortality rate. This is a dramatically higher mortality rate than the general population, and an even higher mortality rate than injection drug users as a group. The etiology of these deaths is unfortunately not listed but major sources of mortality in injection drug users include overdose, trauma, self-harm, and medical complications (pneumonia, hepatitis, renal failure, etc.).²⁵ It is possible that subsequent evaluation by a medical provider may have provided an opportunity for medical screening and intervention to prevent these deaths. Like any medical emergency, overdose is an opportunity for medical providers to intervene with at-risk individuals who might otherwise not be susceptible to counseling and intervention.²⁶ The use of home naloxone by nonmedical providers may inadvertently prevent this encounter, robbing patients of an opportunity for intervention.

Even more concerning in this case is the ever-increasing use of intranasal naloxone by trained paramedic responders. The argument may be made that intranasal home naloxone provides a simple way for non-medical providers to provide a life-saving intervention. However, every EMT has training in achieving IV access, which allows for careful parenteral administration and titration of naloxone. The uniform dosing common to intranasal naloxone administration as well as the resultant avoidance of intravenous access do not seem to help the patient. Analogously, oral administration of furosemide may be more convenient for EMS personnel, but medical professionals recognize the advantages of parenteral administration in terms of dosing and effectiveness. A similar view must be taken of EMS administration of naloxone. A robust review of the use of intranasal naloxone by Kerr et al. discusses some of the promise of intranasal naloxone, but stops short of recommending its widespread acceptance by EMS providers in the prehospital setting.²⁷ In one retrospective review of a California EMS registry, 18% of IN naloxone recipients required additional doses and 6% required IV naloxone while failing to affect the rate of needle stick

exposures.⁷ Further research via EMS registries may provide reliable insight into the strengths and limitations of IN naloxone, especially given the variety of opioids that continue to appear. As recently as March 2013, the unprecedented appearance of acetylfentanyl in Rhode Island and Pennsylvania resulted in opioid overdoses that required higher doses of naloxone.²⁸

CONCLUSION

In conclusion, this case is presented as an example where administration of intranasal naloxone failed to resolve apnea and respiratory distress in the setting of fentanyl patch exposure. The choice of using intranasal naloxone when intravenous naloxone is readily available to EMS providers may have delayed definitive therapy. Additionally, enthusiasm for home naloxone programs as a panacea for treatment of the opioid overdose epidemic must be tempered with a better understanding of what we are treating. Early research into the success of bystander home-naloxone programs is promising, yet these programs focused largely on patients who had overdosed on short-acting heroin. The authors encourage, therefore, providers to be aware of the drawbacks in using intranasal naloxone in the setting of nonheroin opioid overdose and to continue to attempt titrated administration of parenteral naloxone by a medical provider. This is particularly important as deaths from drug overdose continue to mount, while heroin overdose becomes relatively less commonplace. Bottom line: Not every opioid overdose is the same.

References

1. Jones CM, Mack KA, Paulozzi LJ. Pharmaceutical overdose deaths, United States, 2010. *JAMA*. 2013;309(7):657–9.
2. Centers for Disease C, Prevention. CDC grand rounds: prescription drug overdoses – a U.S. epidemic. *MMWR Morb Mortal Wkly Rep*. 2012;61(1):10–3.
3. McDonald DC, Carlson K, Izrael D. Geographic variation in opioid prescribing in the U.S. *J Pain*. 2012;13(10):988–96.
4. Bohnert AS, Valenstein M, Bair MJ, Ganoczy D, McCarthy JF, Ilgen MA, Blow FC. Association between opioid prescribing patterns and opioid overdose-related deaths. *JAMA*. 2011;305(13):1315–21.
5. Baca CT, Grant KJ. Take-home naloxone to reduce heroin death. *Addiction*. 2005;100(12):1823–31.
6. Sporer KA, Kral AH. Prescription naloxone: a novel approach to heroin overdose prevention. *Ann Emerg Med*. 2007;49(2):172–7.
7. Robertson TM, Hendey GW, Stroh G, Shalit M. Intranasal naloxone is a viable alternative to intravenous naloxone for prehospital narcotic overdose. *Prehosp Emerg Care*. 2009;13(4):512–5.
8. Barton ED, Colwell CB, Wolfe T, Fosnocht D, Gravitz C, Bryan T, Dunn W, Benson J, Bailey J. Efficacy of intranasal naloxone as a needleless alternative for treatment of opioid overdose in the prehospital setting. *J Emerg Med*. 2005;29(3):265–71.
9. Walley AY, Xuan Z, Hackman HH, Quinn E, Doe-Simkins M, Sorensen-Alawad A, Ruiz S, Ozonoff A. Opioid overdose rates

Explore Litigation Insights

Docket Alarm provides insights to develop a more informed litigation strategy and the peace of mind of knowing you're on top of things.

Real-Time Litigation Alerts



Keep your litigation team up-to-date with **real-time alerts** and advanced team management tools built for the enterprise, all while greatly reducing PACER spend.

Our comprehensive service means we can handle Federal, State, and Administrative courts across the country.

Advanced Docket Research



With over 230 million records, Docket Alarm's cloud-native docket research platform finds what other services can't. Coverage includes Federal, State, plus PTAB, TTAB, ITC and NLRB decisions, all in one place.

Identify arguments that have been successful in the past with full text, pinpoint searching. Link to case law cited within any court document via Fastcase.

Analytics At Your Fingertips



Learn what happened the last time a particular judge, opposing counsel or company faced cases similar to yours.

Advanced out-of-the-box PTAB and TTAB analytics are always at your fingertips.

API

Docket Alarm offers a powerful API (application programming interface) to developers that want to integrate case filings into their apps.

LAW FIRMS

Build custom dashboards for your attorneys and clients with live data direct from the court.

Automate many repetitive legal tasks like conflict checks, document management, and marketing.

FINANCIAL INSTITUTIONS

Litigation and bankruptcy checks for companies and debtors.

E-DISCOVERY AND LEGAL VENDORS

Sync your system to PACER to automate legal marketing.