Henry Gray

THIRTY-EIGHTH
EDITION

GRAY'S ANATOMY

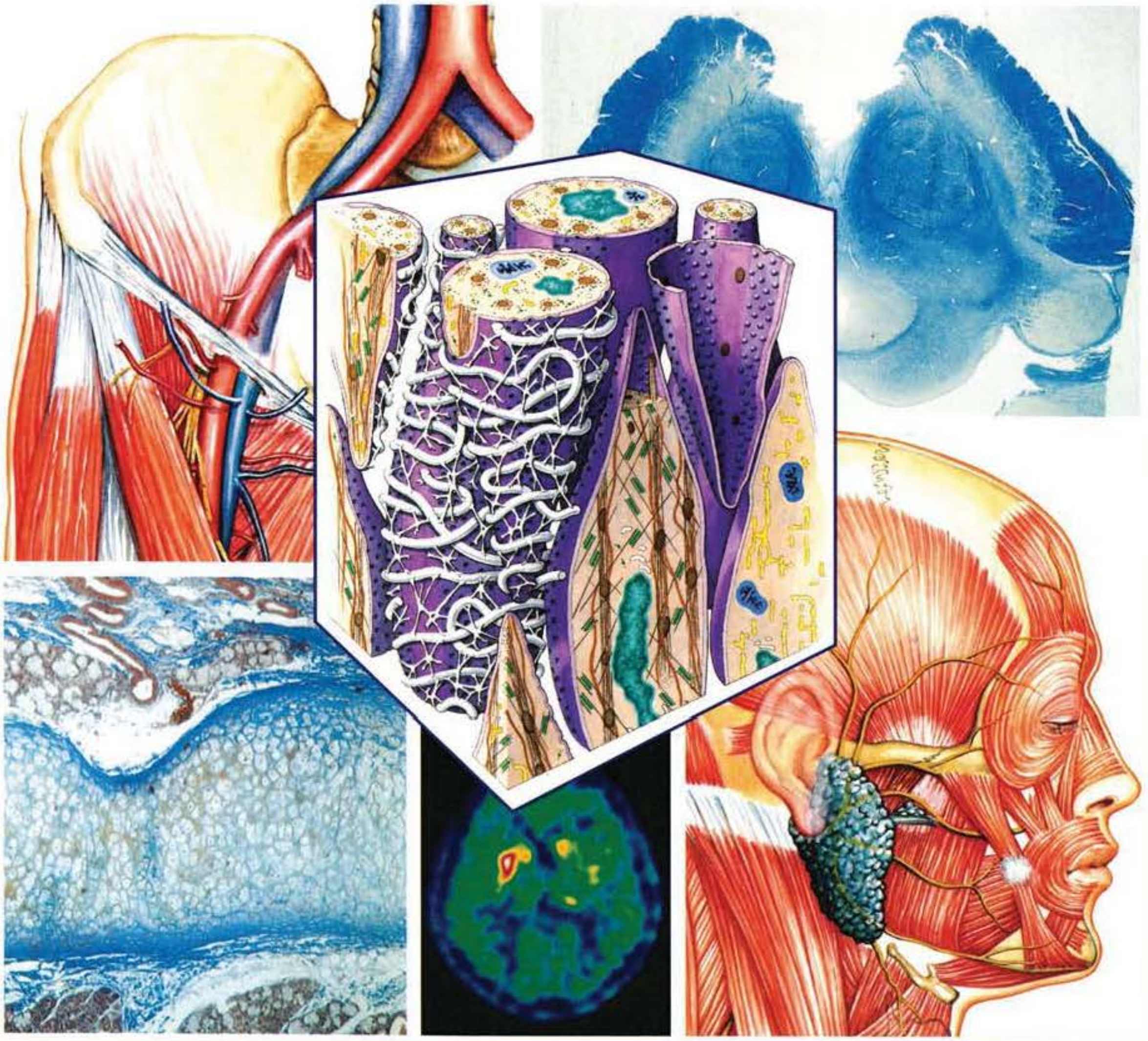

CHURCHILL LIVINGSTONE

THIRTY-EIGHTH
EDITION

GRAY'S ANATOMY

THE ANATOMICAL BASIS OF MEDICINE AND SURGERY

CHAIRMAN OF THE EDITORIAL BOARD

The late **Peter L. Williams** DSc (Lond) MA MB BChir (Cantab) FRCS (Eng)

Emeritus Professor, University of London
Formerly Professor of Anatomy, Guy's Hospital Medical School, London

EDITORIAL BOARD

Lawrence H. Bannister
Martin M. Berry
Patricia Collins
Mary Dyson
Julian E. Dussek
Mark W. J. Ferguson

CHURCHILL LIVINGSTONE
EDINBURGH LONDON NEW YORK PHILADELPHIA SYDNEY TORONTO 1995

CHURCHILL LIVINGSTONE
An imprint of Harcourt Brace and Company Limited

Thirty-eighth edition first published 1995
Reprinted 1999

Standard edition ISBN 0 443 04560 7

International edition ISBN 0 443 05717 6

British Library Cataloguing in Publication Data
A catalogue record for this book is available from the British Library.

Library of Congress Cataloging in Publication Data
A catalog record for this book is available from the Library of Congress.

The Publishers have made every effort to trace holders of copyright in original material and to seek permission for its use in *Gray's Anatomy*. Should this have proved impossible then copyright holders are asked to contact the Publishers so that suitable acknowledgement can be made at the first opportunity.

For Churchill Livingstone

Commissioning Editor: Timothy Horne
Project Editors: Julia Merrick, Dilys Jones
Copy Editors: Therese Duriez, Kathleen Orr
Project Assistants: Graham Birnie, Isobel Black, Kim Craven, Nicola Haig, Alison Nicoll, Janice Urquhart
Project Controllers: Kay Hunston, Nancy Arnott
Design Management: Ian Dick
Design Direction: Erik Bigland
Proofreaders: Susan Ranson, Andrew Johnston, Elizabeth Lightfoot, Ian Ross, Russell Roy, Keith Whettam
Sales Promotion: Duncan Jones

Illustrators who have contributed new artwork

Andrew Bezear
Robert Britton
Peter Cox
Marks Creative
Patrick Elliott
Jenny Halstead
Dr A. A. van Horssen
Peter Jack
Peter Lamb
Gillian Lee
Paul Richardson
Lesley J. Skeates
Denise Smith
Philip Wilson

Photographers

Sarah-Jane Smith
Kevin Fitzpatrick

Printed in Great Britain

GRAY'S ANATOMY

CONTENTS

PREFACE ix

CONTRIBUTORS xi

HISTORICAL ACCOUNT xv
Biography of Henry Gray xv
Brief history of *Gray's Anatomy* xvii

1
INTRODUCTION TO HUMAN ANATOMY 1
Edited by Lawrence H. Bannister

What is anatomy? 2
Origin of life on Earth 3
Evolution of life on Earth 3
Primate and human evolution 7
Anatomical nomenclature 13

2
CELLS AND TISSUES 17
Edited by Lawrence H. Bannister

- Cell structure 21
  - Cytoplasm 23
  - Cytoskeleton 36
  - Nucleus 46
  - Reproduction of cells 56
- Tissues 67
  - Epithelium 67
  - Unilaminar epithelia 67
  - Multilaminar epithelia 71
  - Glands 73
  - Connective tissues 75

3
EMBRYOLOGY AND DEVELOPMENT 91
Edited by Patricia Collins

- Developmental biology 102
- Early human development 121
- Development of individual systems 173
  - Respiratory and gastrointestinal systems 174
  - Urinary and reproductive systems 199
  - Nervous system and special sense organs 217
  - Musculoskeletal system 264
  - Cardiovascular system 298
- Prenatal growth in form and size 328

4
NEONATAL ANATOMY AND GROWTH 343
Edited by Patricia Collins

- Neonatal anatomy 344
  - Individual systems in the neonate 346
- Growth 365

5
INTEGUMENTAL SYSTEM 375
Edited by Lawrence H. Bannister

- Skin 376
  - Introduction 376
  - Epidermis 381
  - Dermis 395
  - Nerves 399
  - Blood vessels 398
  - Age-related changes 411
  - Repair 412
- Breasts (mammae) 417
  - Female breasts 418
  - Male breasts 424

6
SKELETAL SYSTEM 425
Edited by Roger W. Soames

- Morphology of the human skeleton 426
- Skeletal connective tissues 443
- The scope of arthrology 484
- Axial skeleton 510
  - Vertebral column 511
  - Ribs 539
  - Thorax 545
  - Skull 547
- Appendicular skeleton 613
  - Upper limb 615
  - Wrist and hand 646
  - Lower limb 662
  - Ankle and foot 712

7
MUSCLE 737
Edited by Stanley Salmons

- Introduction 738
- Brief survey of the major types of muscle 738
- Skeletal muscle 738
- Cardiac muscle 764
- Smooth muscle 771
- Attachments of skeletal muscles 781
- Form and function in skeletal muscles 783
  - Form and fibre architecture 783
  - Functional implications of form 783
  - Muscles and movement 785
- Muscles and fasciae of the head 789
  - Craniofacial muscles 789
  - Masticatory muscles 799
- Anterolateral muscles and fasciae of the neck 802
  - Superficial and lateral cervical muscles 804
  - Suprahyoid muscles 806
  - Infrahyoid muscles 807

  - Anterior vertebral muscles 807
  - Lateral vertebral muscles 808
- Muscles and fasciae of the trunk 809
  - Deep muscles of the back 809
  - Suboccipital muscles 813
  - Muscles of the thorax 813
  - Muscles of the abdomen 819
  - Muscles and fasciae of the pelvis 829
  - Muscles and fasciae of the perineum 832
- Muscles and fasciae of the upper limb 835
  - Muscles connecting the upper limb with the vertebral column 835
  - Muscles connecting the upper limb with the thoracic wall 838
  - Muscles of the scapula 840
  - Muscles of the upper arm 842
  - Muscles of the forearm 844
  - Muscles of the hand 858
- Muscle and fasciae of the lower limb 868
  - Muscles of the iliac region 868
  - Muscles of the thigh and gluteal region 870
  - Muscles of the leg 881
  - Muscles of the foot 889

8

NERVOUS SYSTEM 901

Edited by Martin M. Berry, Susan M. Standring, Lawrence H. Bannister

- Introduction to the nervous system 902
- Cytology of the nervous system 921
- Regional organization of the central nervous system 974
  - Spinal medulla or cord 975
  - Rhombencephalon 1011
  - Mesencephalon 1066
  - Diencephalon 1079
  - Telencephalon 1107
  - Basal nuclei 1186
  - Fluid compartments and fluid balance in the central nervous system 1202
- Peripheral nervous system 1224
  - Cranial nerves 1225
  - Spinal nerves 1258
  - Autonomic nervous system 1292
- Peripheral apparatus of the special senses 1312
  - Gustatory apparatus 1312
  - Olfactory apparatus 1315
  - Peripheral visual apparatus 1321
  - Accessory visual apparatus 1353
  - Auditory and vestibular apparatus 1367

9

HAEMOLYMPHOID SYSTEM 1399

Edited by Lawrence H. Bannister

- Haemal cells and tissue 1400
- Haemopoiesis 1407
- Lymphoid cells and tissues 1417
  - Lymphocytes 1417
  - Thymus 1423
  - Lymph nodes 1431
  - Spleen 1437
  - Mucosa-associated lymphoid tissue 1442

10

CARDIOVASCULAR SYSTEM 1451

Edited by Giorgio Gabella

- Blood vessels 1452
- Thoracic cavity and heart 1470
- Arterial system 1504
  - Aorta 1505
  - Carotid system of arteries 1513
  - Subclavian system of arteries 1529
  - Arteries of the trunk 1545
  - Arteries of the lower limbs 1564
- Venous system 1574
  - Cardiac veins 1575
  - Veins of the head and neck 1576
  - Veins of the upper limbs 1589
  - Veins of the thorax 1591
  - Veins of the lower limbs 1595
  - Veins of the abdomen and pelvis 1598
- Lymphatic system 1605

11

RESPIRATORY SYSTEM 1627

Edited by Lawrence H. Bannister

- Introduction 1628
- Nose and paranasal sinuses 1631
- Larynx 1637
- Trachea and bronchi 1653
- Lungs 1657
- Pleurae 1662
- Mediastinum 1676

12

ALIMENTARY SYSTEM 1683

Edited by Lawrence H. Bannister

- Introduction 1684
- Oral cavity and related structure 1686
  - Palate 1688
  - Salivary glands 1691
  - Teeth 1699
  - Tongue 1721
  - Pharynx 1725
- Abdomen 1733
  - Peritoneum 1734
- Oesophagus to anus 1746
  - Introduction 1746
  - Enteric nervous system 1749
  - Oesophagus 1751
  - Stomach 1753
  - Small intestine 1763
  - Large intestine 1774
  - Gastro-entero-pancreatic endocrine system 1787
  - Hernia 1788
  - Pancreas 1790
  - Liver 1795
  - Liver transplantation 1808
  - Biliary ducts and gallbladder 1809

13

URINARY SYSTEM 1813

Edited by Mary Dyson

- Kidneys 1815
  - Renal microstructure 1819
  - Juxtaglomerular apparatus 1824
  - Renal vessels and nerves 1826
  - Renal blood vessels 1826
  - Upper urinary tract 1827
- Ureters 1828
- Kidney transplantation 1834
- Urinary bladder 1837
- Male urethra 1842
- Female urethra 1843

14

REPRODUCTIVE SYSTEM 1847

Edited by Lawrence H. Bannister and Mary Dyson

- Reproductive organs of the male 1848
  - Testes and epididymes 1848
  - Ductus deferens (vas deferens) 1855
  - Spermatic cord 1856

  Scrotum 1856
  Penis 1857
  Prostate 1859
Reproductive organs of the female 1861
  Ovaries 1861
  Uterine tubes 1867
  Uterus 1869
  Vagina 1875
  Female external organs 1876

15
ENDOCRINE SYSTEM 1881
Edited by Mary Dyson

Adenohypophysis 1883
Neurohypophysis 1886
Pineal gland 1888
Thyroid gland 1891
Parathyroid glands 1897
Chromaffin system 1898
Diffuse neuroendocrine system 1898
Suprarenal (adrenal) glands 1900
Paraganglia 1905
Para-aortic bodies 1906
Tympanic body 1906
Coccygeal body 1906

16
SURFACE ANATOMY 1909
Edited by Harold Ellis and Julian E. Dussek

Head 1911
Neck 1914
Thorax 1915
Abdomen 1918
Perineum 1920
Back 1921
Upper limb 1923
Lower limb 1929

BIBLIOGRAPHY 1937

INDEX 2045

but all movements, active or not, can be made passively when the muscles concerned are relaxed; the term 'accessory' will be used for all movements impossible in the absence of resistance (Salter 1955).

Limitation of movements. This is due to several factors, of which tension in ligaments is prominent, as is obvious in attempted hyperextension of the unfixed cadaveric knee or hip. Increasing ligamentous tension, balanced by increased compression between opposed articular surfaces, are integral factors in producing close-packing, limiting most habitual movements. But tension of antagonistic muscles is equally important, involving both *passive elastic components* of muscles (and other structures around the joint) and *reflex contraction* when stimulation of mechanoreceptors in articular and periarticular tissues reaches a critical level. Muscles as limiting factors are exemplified in flexion at the hip; with the knee extended it is much more limited in range; with the knee flexed the hamstring muscles are relaxed allowing flexion of the thigh to the abdominal wall, such *approximation of the soft parts* being a third factor in some movements, for example flexion at the elbow and knee. Contact (occlusion) of teeth obviously limits mandibular elevation.

In synovial joints, where bones are connected only by ligaments and muscles, parts of articular surfaces are in constant apposition in all positions. (Some maintain that 'apposition' implies a fine film of synovial fluid, of 10 µm or less, between adjacent surfaces.) Apposition is assisted by atmospheric pressure and cohesion between surfaces, but these are subsidiary to balanced contraction of muscle groups around the joint. When these contract, the force generated is vectorially resolvable into components (p. 787). Some maintain or alter positions of bones ('swing' and 'spin' components) and oppose internal and external resistances, including gravity. Another component is *transarticular* ('shunt' component), which increases compression between articular surfaces and helps apposition in various postures and movements (p. 786). Effects of external compressive or tensile forces, including gravity, vary with body posture and the direction of applied force. Thus gravity or load-bearing may sometimes provide a *distractive force*, tending to separate conarticular surfaces, or may exert a largely *translatory/swing force* between them. They often exert a considerable *compressive force* at surfaces.

Summary. The preceding remarks are merely an introduction to the main concepts of kinesiology. Brief references to myokinetics are on p. 785. For further analyses the references given should be consulted. (Readers with greater facility in mathematics and physics may be interested in attempts to present a 'generalized mechanics of articular swing', ranging from Aristotelian and Newtonian physics to the relativity theory and quantum mechanics; MacConaill 1978a,b,c.)

Blood supply and lymphatics of joints

Joints receive blood from periarticular arterial *plexuses* whose numerous rami pierce capsules to form subsynovial vascular plexuses. Some synovial vessels end near articular margins in an anastomotic fringe, the *circulus articularis vasculosus* (p. 470). A lymphatic plexus in the synovial subintima drains along blood vessels to the regional deep lymph nodes.

Nerve supply of joints

Movable joints are innervated in general by nerves supplying their muscles, probably establishing local reflex loops involved in movement and posture. Although the branches concerned vary, each innervates a specific capsular region but their territories freely overlap. The region made taut by muscular contraction is usually innervated by nerves supplying antagonists (Gardner 1948a,b). For example, the hip joint's capsule, on stretch inferiorly in abduction, is here supplied by the obturator nerve, tension in it thus producing reflex contraction of the adductors, usually enough to prevent damage. However, this is not so at the shoulder, where the axillary nerve innervates the anteroinferior capsular region.

Myelinated fibres in articular nerves have Ruffini endings, lamellated articular corpuscles and some like the neurotendinous organs of Golgi. Simple endings are numerous at the attachments of capsule and ligaments; they are terminals of non-myelinated and finely myelinated fibres believed to mediate pain (Gardner 1950). Ruffini end organs are variably orientated in the knee joint's capsule, principally in its flexor region, responding to stretch and adapting slowly. Lamellated corpuscles, less numerous than Ruffini endings, are sited laterally and adapt rapidly since they respond to rapid movement and vibration; both register speed and direction of movement. Golgi end organs, with the largest myelinated nerve fibres (10–15 µm diameter), are like those at neuromuscular junctions and slow to adapt (Boyd & Roberts 1953; Boyd 1954; Skoglund 1956); they mediate position sense (Stopford 1921; Mountcastle & Powell 1959a,b; Gardner 1967) and are concerned in stereognosis, i.e. recognition of shape in objects held (Renfrew & Melville 1960). Many non-myelinated fibres are sympathetic, ending near vascular non-striated muscle and believed to be vasomotor or vasosensory, although evidence is sparse. In synovial membrane no special end organs or even simple endings occur, except near blood vessels, the membrane being relatively insensitive to pain (Kellgren & Samuel 1950; Barnett et al 1961). For a review concerned with receptors and sensation see Wyke (1981); for histological and functional details and classification of articular nerve endings see page 969.

AXIAL SKELETON

INTRODUCTION

Dividing the skeleton into axial and appendicular sections is not merely a convention. The axial structures, cranium and vertebral column and associated ribs and sternum, are primary; the appendicular elements in fins, limbs or wings were subsequent though early additions. Both primary and secondary elements are concerned in elaboration of locomotion. An axial endoskeleton, first a notochord and then a vertebral column, is the basic feature of *Chordata* and their subphylum, the *Vertebrata*, including mankind. A stiff but flexible axis, in bilaterally symmetrical animals that show an early tendency to elongation, prevents telescoping of the body during waves of contraction in successive segmental muscles to produce the sinuous movements, especially in the tail, which are the basic mode of locomotion in aquatic vertebrates. A chain of bones, connected by discs of deformable substance, developed around and largely replaced the notochord. However, notochordal vestiges occur in vertebrae of many fish, amphibians and reptiles, and centrally in mammalian intervertebral discs. This replacement is repeated in every vertebrate embryo. These new vertebral elements are complex and variable in pattern in earlier vertebrates but from reptiles onwards the most basic part is the *centrum*, forming most of the vertebral body, ventral to the spinal cord (spinal medulla). In a typical vertebra a *neural arch*, encircling the spinal cord, fuses ventrally with the centrum and usually bears a median dorsal *spinous process* and paired lateral *transverse processes* just dorsal to the neurocentral junctions. This enclosure isolates the spinal cord from the axial musculature and protects it from external forces, thus insulating its vessels from extraneous compression.

The centrum and each half neural arch ossify from separate centres; when these extend through cartilaginous precursors to meet and fuse, the dorsolateral parts of the vertebral body are formed from the ventral ends of the neural arch. Centrum and body are therefore **not** synonyms, nor is the *vertebral arch* exactly equal to a neural arch. A centrum is somewhat less than a vertebral body, a neural somewhat more than a vertebral arch (p. 532).

Segmental muscles flexing the vertebral axis are only in part attached to vertebrae; in connective tissue septa (*myocommata*) between adjacent myotomes ribs evolve as levers for such attachments. Such costal struts first appeared **dorsally** in the axial musculature and extended ventrally into the body wall in early vertebrates. In fish **ventral** ribs also appeared, which enclosed caudal vessels in the tail. It is generally agreed that ribs of land tetrapods correspond to the dorsal piscine series (Romer 1970).

Ribs are thus intersegmental, and segmental muscles, derived basically from myotomes, bend the vertebral column; vertebrae also become intersegmental, though their embryonic pattern (p. 265) is primarily segmental. In early vertebrates dorsal ribs adjoin most vertebrae, showing little regional adaptation except in the postnatal tail. In land vertebrates, with the elaboration of appendages for locomotion, the vertebral column is adapted to new patterns of force in the distribution of weight and muscular tensions.

In hindlimbs the pelvic girdle articulates with several vertebrae, which fuse with each other and with costal elements to form a *sacrum*. Sacral vertebrae lose *individual* movement; in mammals there are three to five *fused sacral vertebrae*, and distal to these a variable number of *caudal vertebrae*, reduced to four degenerate elements fused into a *coccyx* in adult humans. Some movement persists, however, between the fused sacral mass and neighbouring vertebrae, as well as between the sacrum and pelvic girdle.

Mammalian presacral vertebrae vary in number and differentiation but can be grouped into *cervical* (neck), *thoracic* (where ribs persist) and *lumbar* vertebrae (devoid of mobile ribs) by distinguishing features. Cervical ribs are small or 'absent' (but see below); their disappearance in cervical and lumbar regions is linked to the change from breathing by gills to lungs, and to development of independent movements of the head. There is no neck in fish, the postcranial region being occupied by the branchial apparatus. Caudal shift of the respiratory apparatus in land vertebrates necessarily preceded development of a neck. Cervical vertebrae were early stabilized to seven in mammals (except tree sloths and manatees), even in such extremes as whales and giraffes. With respiratory adaptation of ribs in land animals and development of a diaphragm in mammals, well-formed ribs, articulating with but separate from vertebrae, are limited to thoracic levels. But ribs do **not** disappear completely in *cervical* and post-thoracic regions: vestigial *costal elements* are combined with transverse processes of all such vertebrae (see **3**.134, **6**.89).

The total number of vertebrae, excluding the tail, is reduced from the lemuroid and tarsloid to the anthropoid primates. Monkeys, apes and hominids (extinct and extant) show some uniformity. The cervical, thoracic, lumbar and sacral vertebrae number respectively 7, 11–15, 4 to 7, and 3–6, human values being 7, 12, 5 and 5. Caudal vertebrae vary much in number.

VERTEBRAL COLUMN

GENERAL VERTEBRAL FEATURES

A vertebra (**6**.87) essentially has a ventral *body* and a dorsal *vertebral* (*neural*) *arch*, extended by lever-like processes, together enclosing a *vertebral foramen*, occupied by the spinal cord, meninges and their vessels. Opposed surfaces of adjacent bodies are bound together by *intervertebral discs* of fibrocartilage. The complete column of bodies and discs forms a strong but flexible central axis of the body supporting, in bipeds, the full weight of the head and trunk. It also transmits even greater forces due to muscles attached to it directly and indirectly. The foramina form a *vertebral canal* for the spinal cord, and between adjoining neural arches, near their junctions with vertebral bodies, *intervertebral foramina* transmit mixed spinal nerves, smaller recurrent nerves and blood and lymphatic vessels (see also p. 1258).

The cylindroid *vertebral body* varies in size, shape and proportions in different regions and more so in different species. Its junctional aspects vary from approximately flat (but not parallel) to sellar, with a raised peripheral smooth zone formed from the 'annular' epiphyseal disc (p. 532), within which the surface is rough. These differences in texture are due to variations in early structure of intervertebral discs (p. 265). In the horizontal plane the profiles of most bodies are convex anteriorly, but concave posteriorly where they complete the vertebral foramen. Most vertical profiles are concave anteriorly but flat posteriorly. Small vascular foramina appear on the front and sides, but posteriorly there are small arterial foramina (Willis 1949) and a large irregular orifice (sometimes double) for the exit of basivertebral veins (**6**.88). The adult vertebral **body** is **not** coextensive with the developmental **centrum** (p. 532) but includes, posterolaterally, parts of the neural arch, as already noted.

The vertebral arch has on each side a vertically narrower ventral part, the pedicle, and dorsally a broader lamina. Projecting from their junctions are paired transverse, superior and inferior articular processes; dorsally is a median spinous process.

Pedicles are short, thick, rounded dorsal projections from the superior part of the body at the junction of its lateral and dorsal surfaces, so that the concavity formed by its curved superior border is shallower than the inferior one (**6**.84). Adjacent *vertebral notches* contribute to an *intervertebral foramen* when vertebrae articulate by the intervertebral disc and zygapophyseal joints. The complete perimeter of an intervertebral foramen consists, therefore, of the notches, the dorsolateral aspects of parts of adjacent vertebral bodies and intervening disc, and the capsule of the synovial zygapophyseal joint.

Laminae, directly continuous with pedicles, are vertically flattened and curve dorsomedially to complete, with the base of the spinous process, a vertebral foramen.

The *spinous process* (*spine*) projects dorsally and often caudally from the junction of the laminae. Spines vary much in size, shape and direction. They act as levers for muscles which control posture and active movements (flexion/extension, lateral flexion and rotation) of the vertebral column.

The paired superior and inferior *articular processes* (*zygapophyses*) arise from the vertebral arch at the pediculolaminar junctions. The *superior processes* project cranially, bearing dorsal facets which may also have a lateral or medial inclination, depending on level. *Inferior processes* bulge caudally with articular facets directed ventrally, again with medial or lateral inclination depending on vertebral level. Articular processes of adjoining vertebrae thus form small synovial

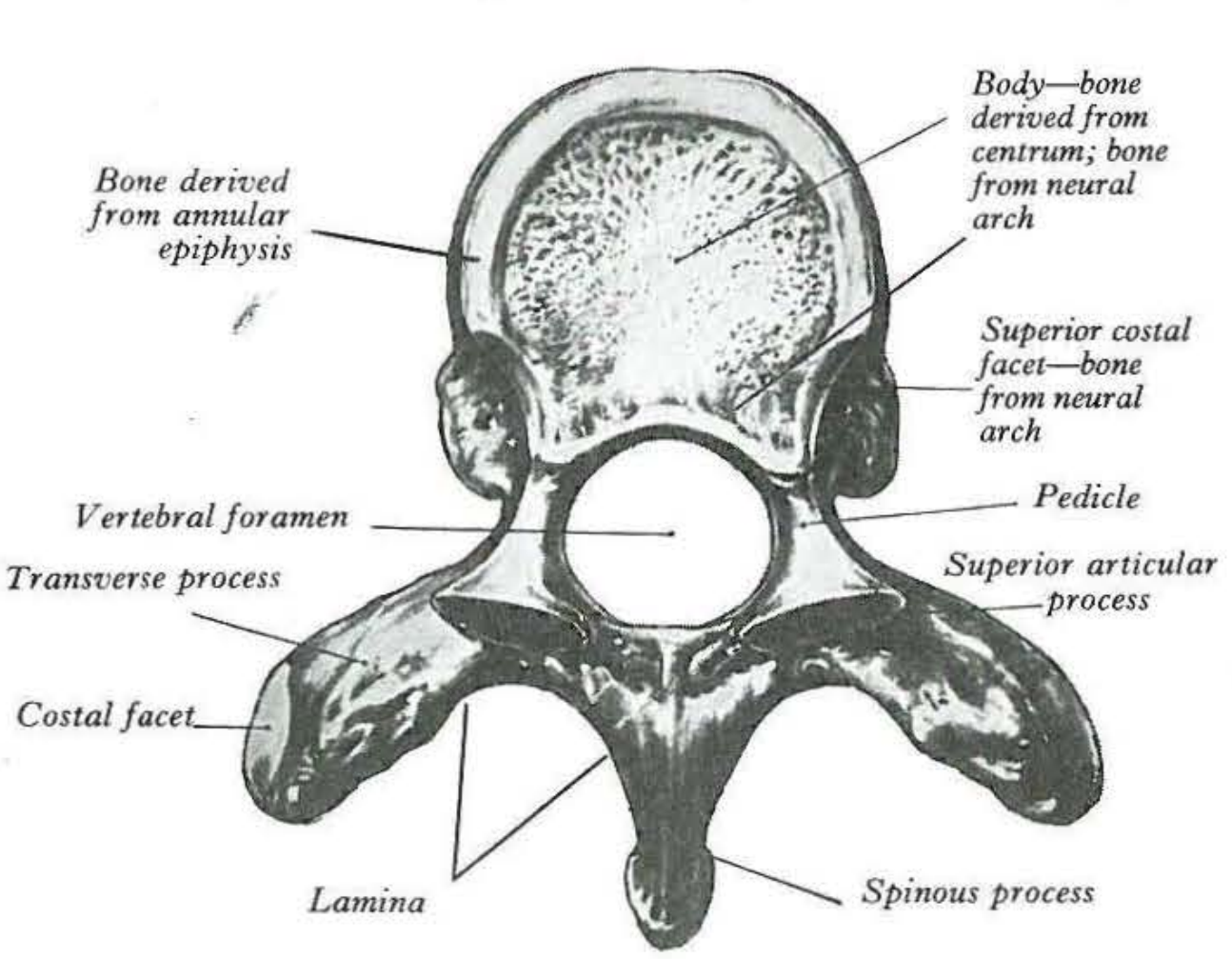

6.87 Typical thoracic vertebra: superior aspect.

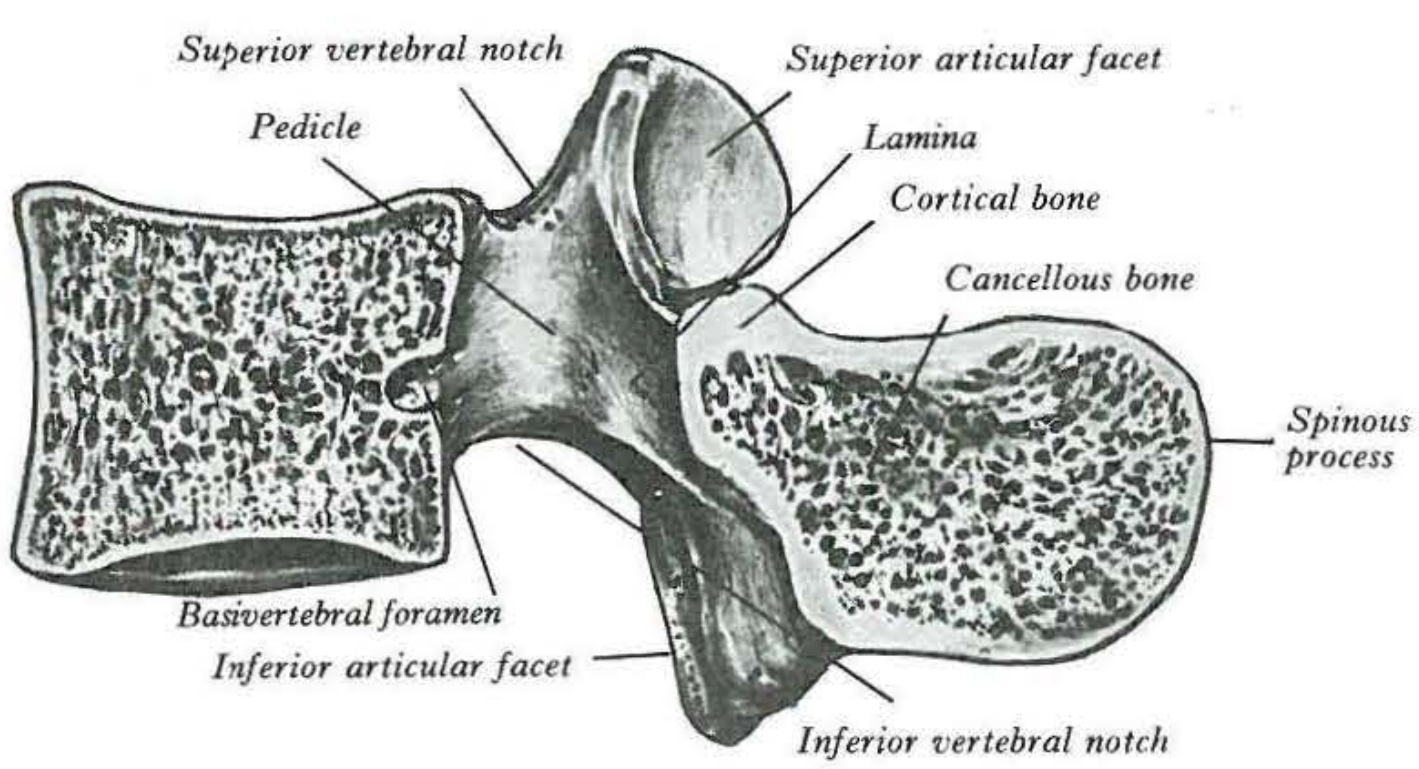

6.88 Median sagittal section through a lumbar vertebra.

zygapophyseal joints (p. 514), forming the posterior aspect of the intervertebral foramina; these joints permit limited movement between vertebrae: mobility varying considerably with vertebral level.

Transverse processes project laterally from the pediculolaminar junctions as levers for muscles and ligaments particularly concerned in rotation and lateral flexion. (The preceding comment is a simplification. In practice the activities of spinal musculature must be considered in terms of bilateral and surrounding muscle groups; weight-bearing and initial posture are also crucial.) The thoracic transverse processes articulate with ribs. At other levels the mature transverse process is a composite of 'true' transverse process (*diapophysis*) and an incorporated costal element.

Costal elements (*pleurapophyses*) develop as basic parts of neural arches in mammalian embryos, but become independent only as thoracic ribs. Elsewhere they remain less developed and fuse with the 'transverse process' of descriptive anatomy (**6**.89).

Vertebrae are internally trabecular (**6**.88), with an external shell of compact bone perforated by vascular foramina. The shell is thin on discal surfaces but thicker in the arch and its processes. The trabecular interior contains red bone marrow and one or two large ventrodorsal canals for the basivertebral veins.

A technique involving the analysis of nine dimensions of vertebral bodies and spines, from which exact anthropometric vertebral dimensions can be determined from radiographs, has been developed by Gilad and Nissan (1985).

The arterial patterns in bodies of thoracic vertebrae between ages 29th prenatal week to adulthood has been described by Ratcliffe (1980, 1981).

All vertebrae, from second cervical to first sacral, articulate by cartilaginous joints between their bodies, synovial joints between their articular processes (zygapophyses) and fibrous joints between their laminae and also between their transverse and spinous processes.

JOINTS OF VERTEBRAL BODIES

Vertebral bodies are united by anterior and posterior longitudinal ligaments and by fibrocartilaginous intervertebral discs between laminae of hyaline cartilage, together forming symphyses.

The anterior longitudinal ligament

The anterior longitudinal ligament (**6**.90) is a strong band extending along the anterior surfaces of the vertebral bodies, broader caudally, being thicker and narrower in thoracic than in cervical and lumbar regions. It is also relatively thicker and narrower opposite vertebral bodies than at the levels of intervertebral symphyses. Attached to the basilar occipital bone, it extends to the anterior tubercle of C1 (atlas), the front of the body of C2 (axis), continuing caudally to the front of the upper sacrum. Its longitudinal fibres, strongly adherent to the intervertebral discs, hyaline cartilage laminae and margins of adjacent vertebral bodies, are loosely attached at intermediate levels of the bodies, where the ligament fills their anterior concavities, flattening the vertebral profile (**6**.90). At these various levels ligamentous fibres blend with the subjacent periosteum, perichondrium and periphery of the annulus fibrosus. It has several layers, the most superficial fibres being longest extending over three or four vertebrae, intermediate between two or three, the deepest from one body to the next: laterally short fibres connect adjacent vertebrae.

The posterior longitudinal ligament

The posterior longitudinal ligament (**6**.91) on the posterior surfaces of the vertebral bodies lies in the vertebral canal, attached to the body of C2 (axis) and the sacrum; above it is continuous with the membrana tectoria (p. 522). Its smooth glistening fibres, attached to intervertebral discs, laminae of hyaline cartilage and adjacent margins of vertebral bodies, are separated between attachments by basivertebral veins and the venous rami draining them into anterior internal vertebral plexuses. At cervical and upper thoracic levels the ligament is broad and of uniform width, but in lower thoracic and lumbar regions it is denticulated, narrow over vertebral bodies and broad over discs (strictly symphyses). Its superficial fibres bridge three or four vertebrae, while deeper fibres extend between adjacent vertebrae as *perivertebral ligaments* close to and, in adults, fused with the annulus fibrosus of the intervertebral disc. The layers are more distinct in the immediate postnatal years.

Intervertebral discs

Intervertebral discs (**6**.90, 92), between adjacent surfaces of vertebral bodies from C2 (axis) to the sacrum, are the chief bonds between them. Disc outlines correspond with the adjacent bodies, thickness varying in different regions and parts of the same disc. In cervical and lumbar regions they are thicker anteriorly, contributing to the anterior convexity; in the thoracic region they are nearly uniform, the anterior concavity being largely due to the vertebral bodies. Discs are thinnest in the upper thoracic region and thickest in the lumbar regions, being adherent to thin layers of hyaline cartilage on the superior and inferior vertebral surfaces (p. 511); together the disc and hyaline cartilages form an *intervertebral symphysis.* Except for their peripheries, supplied from adjacent blood vessels, discs are avascular and supported by diffusion through the trabecular bone of adjacent vertebrae. Vascular and avascular parts differ in reaction to injury (Smith & Walmsley 1951). Connected to anterior and posterior longitudinal ligaments discs in the thoracic region are additionally tied laterally, by intra-articular ligaments, to the heads

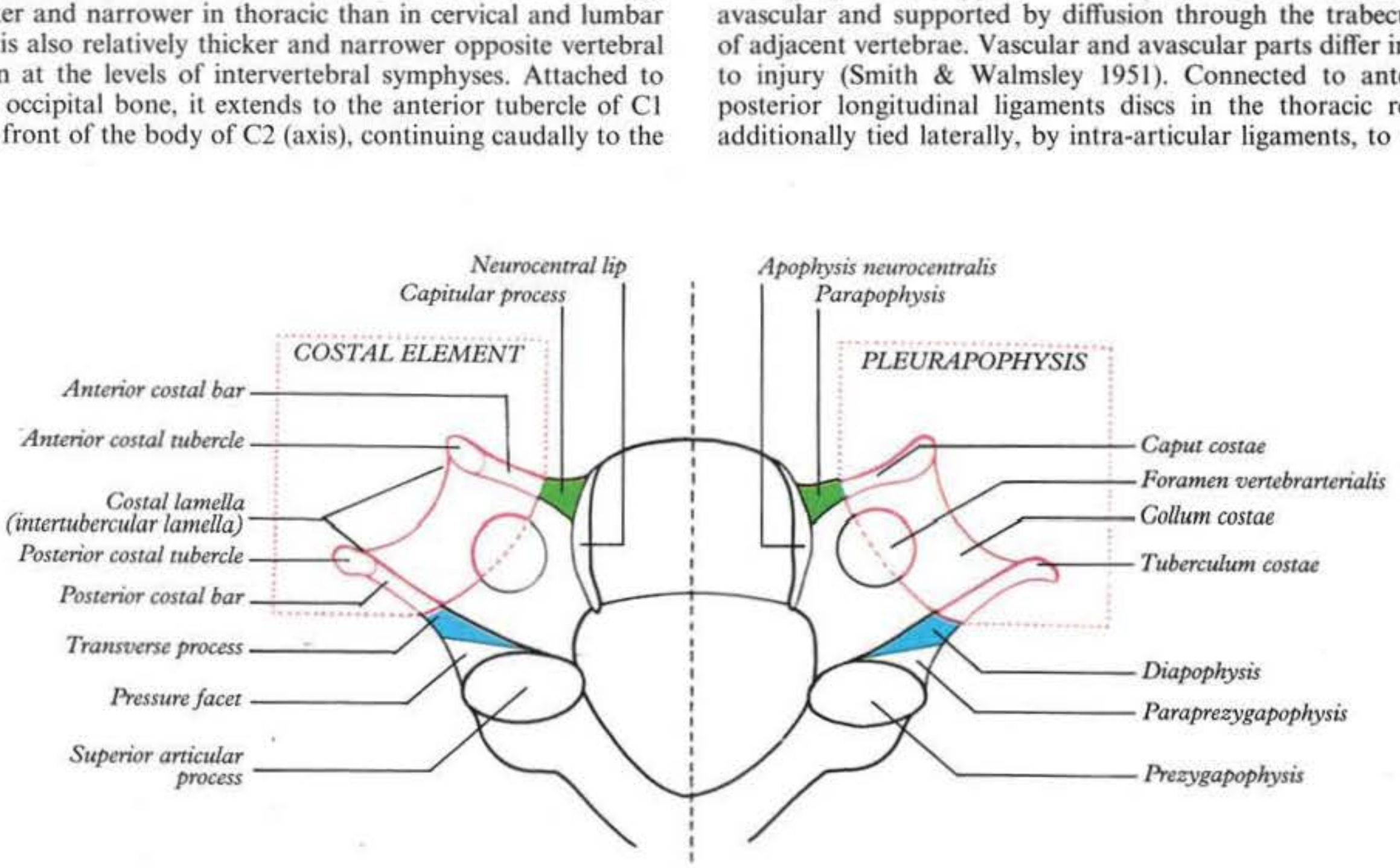

6.89 The morphology of a generalized cervical vertebra, with particular reference to the pleurapophyses. On the left the terms are zoological, on the right are alternatives for human anatomy suggested by Cave (1975). (Reproduced with permission from the author, the *Journal of Zoology* and Cambridge University Press.)

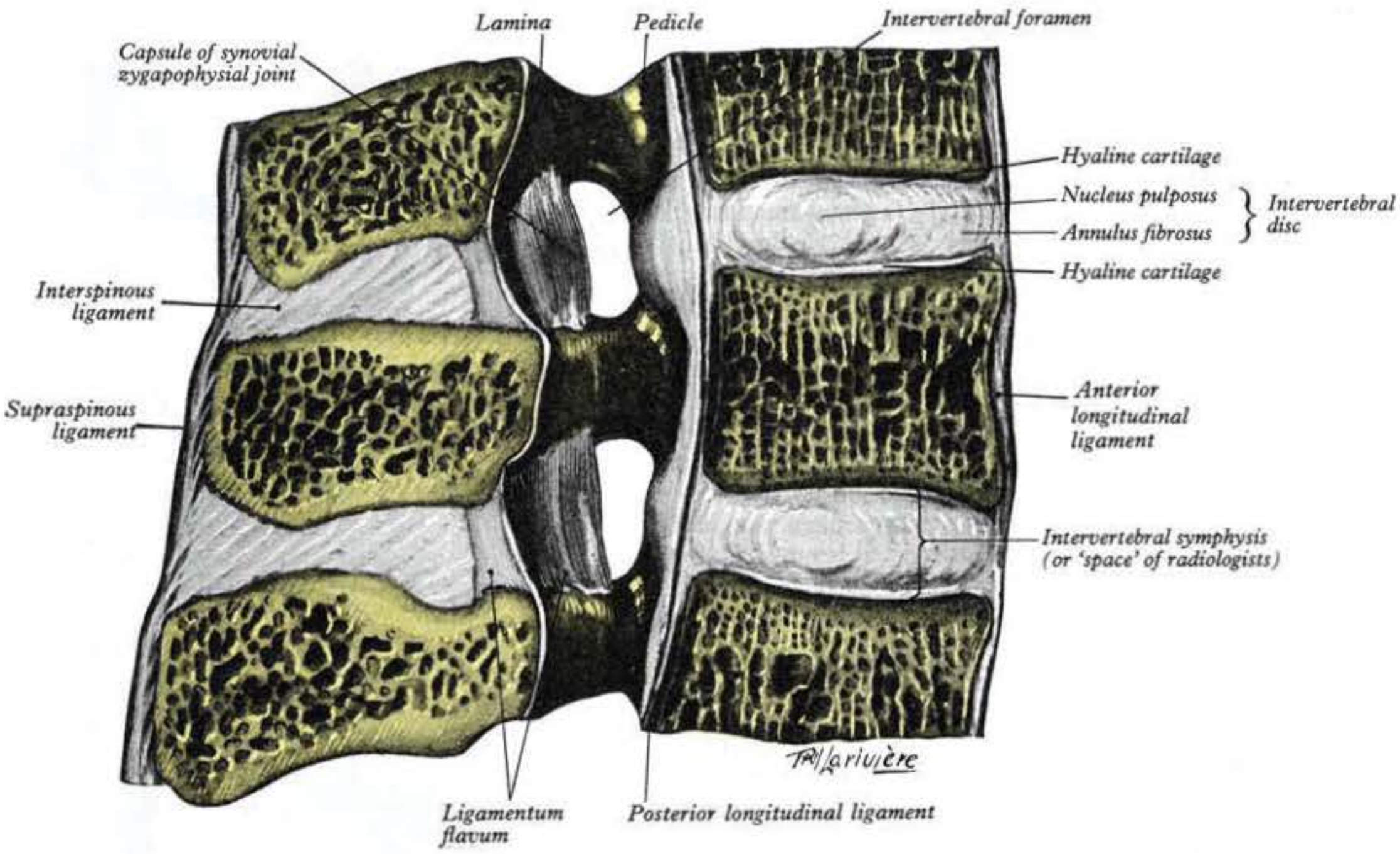

6.90 Median sagittal section through part of the lumbar region of the vertebral column. Note the boundaries of intervertebral foramina. For contrasting details concerning the direction of fibre bundles in the interspinous ligaments see text and Heylings (1978).

of ribs articulating with adjacent vertebrae. Intervertebral discs (excluding the first two vertebrae) form a fifth of the postaxial vertebral column, cervical and lumbar regions having, in proportion to length, a greater contribution than the thoracic and thus being more pliant (Harris 1939). Each disc consists of an outer laminated *annulus fibrosus* and an inner *nucleus pulposus* (**6**.90, 92).

Annulus fibrosus. This has a narrow outer collagenous zone and a wider inner fibrocartilaginous zone. Its laminae, convex peripherally seen in vertical section, are incomplete collars connected by fibrous bands overlapping one another. (The internal vertical concavity of the laminae conforms to the surface profile of the nucleus pulposus.) Posteriorly, laminae join in a complex manner; fibres in the rest of each lamina are parallel and run obliquely between vertebrae; fibres in contiguous laminae criss-cross (**6**.92), thus limiting rotation in both directions. Predominantly **vertical** posterior fibres have been described (Zaki 1973), predisposing to herniation. Obliquity of fibres in deeper zones varies in different laminae (Inoue 1973). Johnson et al (1985) have described elastic fibres in a small number of human lumbar annuli fibrosi. Hickey & Hukins (1981) have described fetal collagen fibril diameters in these structures; they also include elastic fibres.

Nucleus pulposus. Better developed in cervical and lumbar regions, this is nearer the disc's posterior surface. At birth it is large, soft, gelatinous and of mucoid material with a few multinucleated notochordal cells, invaded also by cells and fibres from the inner zone of the adjacent annulus fibrosus. Notochordal cells disappear in the first decade, followed by gradual replacement of mucoid material by fibrocartilage (Sylvén 1951), derived mainly from the annulus fibrosus and the hyaline cartilaginous plates adjoining vertebral bodies. The nucleus pulposus, hitherto distinct, now becomes

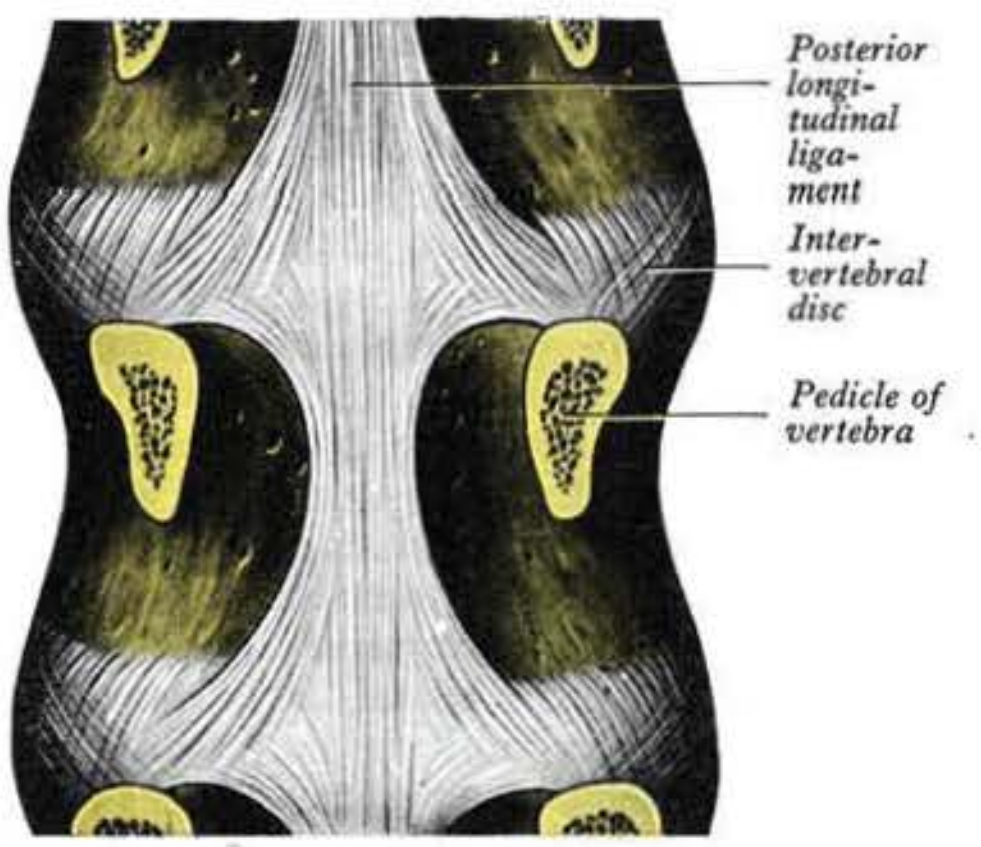

6.91 The posterior longitudinal ligament in the lumbar region.

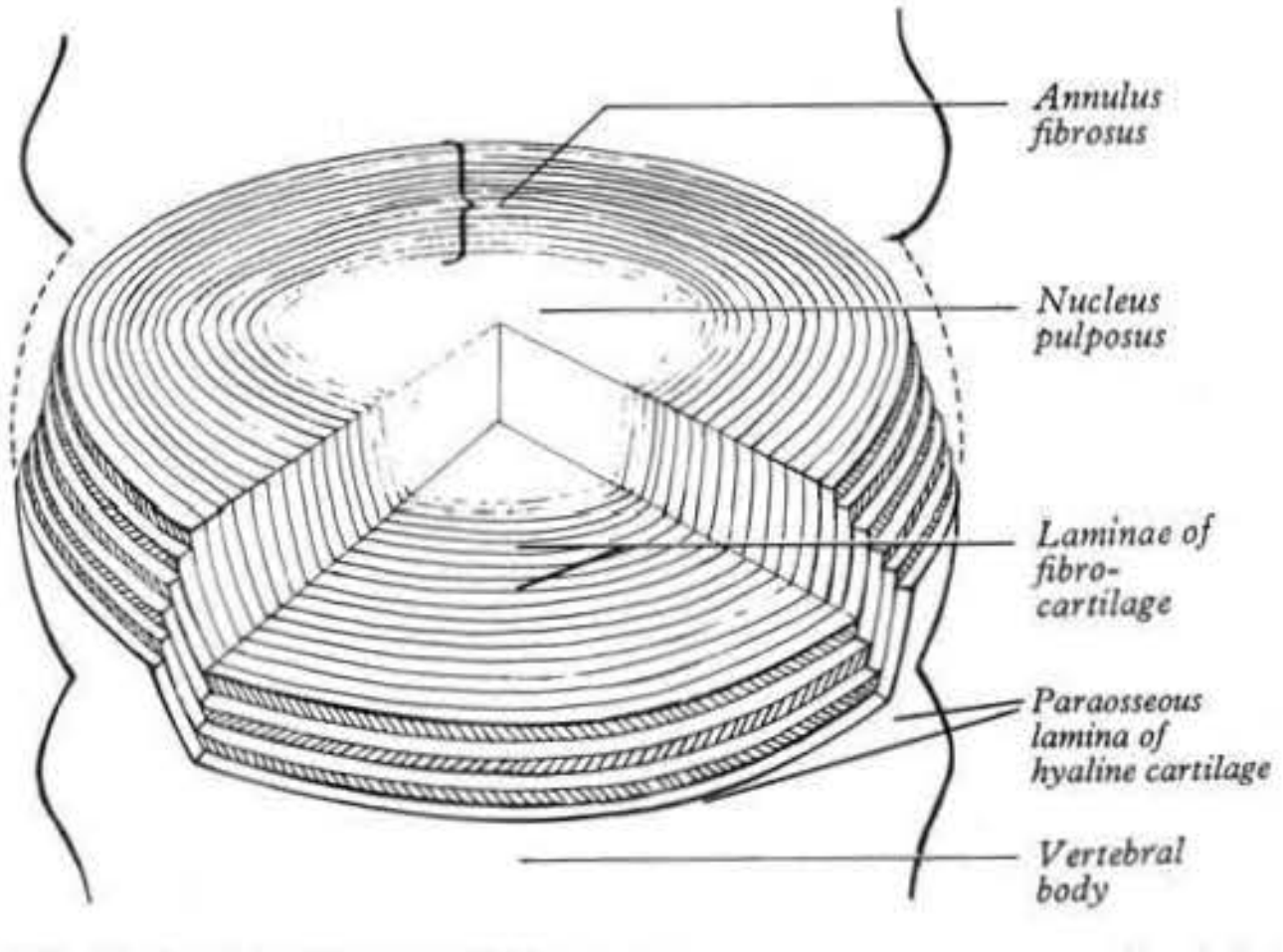

6.92 Schematic representation of the main structural features of an intervertebral disc. The fibrocellular structure of the nucleus pulposus is omitted. For clarity the number of fibrocartilaginous laminae has been greatly reduced, since they are in fact of microscopic dimensions. Note alternating obliquity of collagen fascicles in adjacent laminae. (Modified after Inoue 1973.)

less differentiated from the remainder of the disc (Peacock 1952; Walmsley 1953; Töndury 1958). In lumbar discs cellularity (6000 cells/mm overall) is highest in peripheral annuli fibrosi and in hyaline cartilage nearest to the vertebral bodies, with a glucose diffusion coefficient of 2.5 cm^2 per second, comparable with values for cartilage elsewhere (Maroudas et al 1975). However, nutritional conditions may be more critical, especially in large lumbar discs. With these changes the nucleus pulposus becomes amorphous and sometimes discoloured. Its water-binding capacity and elasticity diminish (Püschel 1930), because these properties are due to its mucopolysaccharide and protein component (Hendry 1958). When the disc is not loaded, pressure in the nucleus pulposus is low at all ages (Nachemson 1960). Pech and Haughton (1985) have recently used cadaveric intervertebral discs to show the high correlation between radiographic and magnetic resonance (MR appearance).

For a review of the structure and function of the human intervertebral disc see Humzah and Soames (1988).

Clinical anatomy. In young adults intervertebral discs are so strong that violence first damages the adjacent bone. It is impossible to damage a healthy disc except by forcible flexion. After the second decade, however, degenerative changes in discs may result in necrosis, sequestration of the nucleus pulposus, softening and weakening of the annulus fibrosus. Then comparatively minor strains may cause **either** internal derangement with eccentric displacement of the nucleus pulposus **or** external derangement; the nucleus pulposus then bulges or bursts through the annulus fibrosus, usually posterolaterally. In the former unequal tension in the joint causes muscle spasm and sudden violent pain, acute *lumbago*; in the latter a herniated nucleus pulposus may press on adjacent nerve roots with resultant referred pain, *sciatica*. Such derangements are usually in the lower lumbar region, especially at the lumbosacral joint, and sometimes at the levels of C5–7. Motor effects, with loss of power and reflexes, may ensue.

The nerve supply to the outer part of the annulus fibrosus, which is frequently torn, may be an underlying cause of 'idiopathic backpain'. For a review of the various mechanisms of spinal pain see O'Brien (1984).

JOINTS OF VERTEBRAL ARCHES

Joints between vertebral articular processes (zygapophyses) are synovial and vary in shape with vertebral level (p. 511); the laminae, spines and transverse processes are connected through syndesmoses constituted by ligamenta flava, interspinous, supraspinous and intertransverse ligaments and the ligamentum nuchae. Some authorities group these various fibrous structures as accessory ligaments of the zygapophyseal joints, while others, as here, classify them as officially recognized, named syndesmoses.

Zygapophyseal joints

Zygapophyseal joints are of the simple (cervical and thoracic) or complex (lumbar) synovial variety: the hyaline covered articular cartilage mating surfaces are carried on mutually adapted articular processes. Their size, shape and topology vary with spinal level and are described with individual vertebrae.

Articular capsules. These are thin and loose and attached peripherally to the articular facets of adjacent zygapophyses; they are longer and looser in the cervical region.

Zygapophyseal lumbar specializations. Three types of lumbar intracapsular structure have been identified by Engel and Bogduk (1982):

- *adipose tissue fat pads* either anterosuperior, posteroinferior or both
- *fibroadipose 'menisci'* (*meniscoids*) at the superior or inferior pole, or both
- *connective tissue rims* either anterior, posterior or both.

The rims are inflections of fibrous capsule; the fat pads are similar to those in many other joints; the meniscoids have an expanded, vascularized, fibroadipose base attached to and sometimes perforating the capsule, a poorly vascularized adipose core and a firm flattened fibrous apex. They project into the crevices between noncongruent articular surfaces but their function is conjectural; they are possibly significant clinically. **All** of the 82 specimens in the above study presented at least one of these features, with more than 50% presenting two or more features.

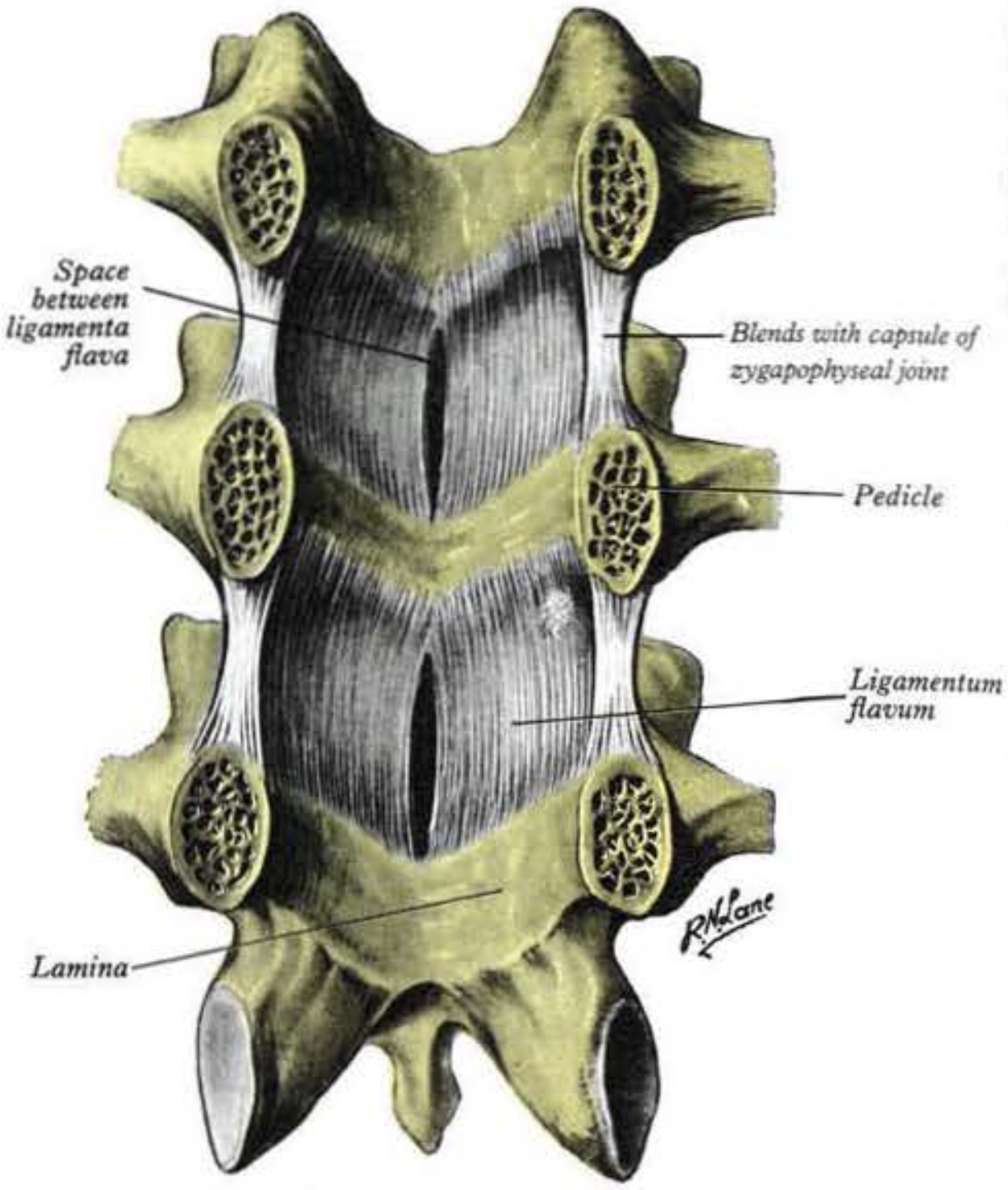

6.93 Ligamenta flava (anterior aspect in the lumbar region).

Intervertebral syndesmoses

Ligamenta flava (6.90, 93). They connect laminae of adjacent vertebrae in the vertebral canal. Their attachments extend from zygapophyseal capsules to where laminae fuse to form spines; here their posterior margins meet and are partially united, intervals being left for veins connecting internal to posterior external vertebral venous plexuses. Their predominant tissue is yellow elastic tissue, whose almost perpendicular fibres descend from the lower anterior surface of one lamina to the posterior surface and upper margin of the lamina below. The ligaments are thin, broad and long in the cervical region, thicker in the thoracic and thickest at lumbar levels. They arrest separation of the laminae in spinal flexion, preventing abrupt limitation, and also assist restoration to an erect posture after flexion, perhaps protecting discs from injury.

Supraspinous ligament (6.90). A strong fibrous cord connecting the tips of spinous process from C7 to the sacrum, it is thicker and broader at lumbar levels and intimately blended with neighbouring fascia. The most superficial fibres extend over three or four vertebrae, the deeper span two or three, while the deepest connect adjacent spines being continuous with interspinous ligaments. Between the spine of C7 and the external occipital protuberance it is expanded as the ligamentum nuchae. Heylings (1978) considers supraspinous ligaments to cease at the fifth lumbar spine.

Ligamentum nuchae. This is a bilaminar fibroelastic intermuscular septum often considered homologous with, but structurally distinct from, supraspinous and interspinous ligaments in the neck. In structure, its dense bilateral fibroelastic laminae are separated by a tenuous layer of areolar tissue; the laminae are blended at its posterior free border. The latter is superficial and extends from the external occipital protuberance to the spine of C7. From this the fibroelastic laminae are attached to the median part of the external occipital crest, the posterior tubercle of C1 and the medial aspects of the bifid spines of cervical vertebrae, as a septum for bilateral attachment of cervical mucles and their sheaths. In bipeds it is the reduced representative of a much thicker, complex elastic ligament which, in quadrupedal mammals, aids suspension of the head and modifies its flexion, functioning like ligamenta flava.

Interspinous ligaments (6.90). These are thin and almost membranous, and connect adjoining spines, their attachments extending from the root to the apex of each. They meet the ligamenta flava in front of the supraspinous ligament behind. Narrow and elongated in the thoracic region, broader, thicker and quadrilateral at lumbar levels, they are poorly developed in the neck. (Some observers allocate all cervical bundles as part of the ligamentum nuchae; others regard them, although tenuous, as distinct interspinous fasicles.) Their fibres are usually described as obliquely *posteroinferior*; Heylings (1978), however, observed them to be obliquely *posterosuperior* at lumbar levels.

Intertransverse ligaments. Found between transverse processes these consist at cervical levels of a few, irregular fibres, largely replaced by intertransverse muscles; in the thoracic region they are cords intimately blended with adjacent muscles; in the lumbar region they are thin and membranous.

Nerves of the joints

Intervertebral joints (symphyses, syndesmoses and synovial) are all innervated by adjoining spinal (and sympathetic) nerves, particularly by their dorsal divisions.

INTERVERTEBRAL FORAMINA

Closely related to some of the main intervertebral articulations are the principal routes of entry and exit to and from the vertebral canal, the intervertebral foramina. (Minor routes occur between the median, often partly fused, margins of the ligamenta flava.) Between the axis and sacrum, despite some quantitative and structural regional variations, essentially they conform to the same general plan; because of their construction, contents and susceptibilities to multiple disorders, they are loci of great biomechanical, functional and clinical significance. The specializations cranial to the axis and at sacral levels are described with the individual bones and articulations. The **boundaries** of a generalized intervertebral foramen are: **anteriorly**, from above downwards, periosteum of the posterolateral aspect of the superior vertebral body (thin compact osseous shell over red bone marrow containing cancellous bone); posterolateral aspect of the intervertebral symphysis (including the disc)—the curved collagen fascicles here may be regarded as either the outer lamina of the annulus fibrosus or as extensions of perivertebral ligaments (distinctions of little importance)—finally a small (variable) periosteum-covered posterolateral part of the body of the inferior vertebra (structure as above); **superiorly**, the compact bone of the deep arched inferior vertebral notch of the vertebra above; **inferiorly**, the compact bone of the shallow superior vertebral notch of the vertebra below; **posteriorly** a part of the ventral aspect of the fibrous capsule of the zygapophyseal synovial joint. Cervical intervertebral foramina are distinct in having superior and inferior vertebral notches of almost equal depth which, in accord with the direction of the pedicles, face **anterolaterally**; external to them, and in the same direction, is the complex transverse process and foramen transversarium (p. 516). The thoracic and lumbar intervertebral foramina face **laterally** and their transverse processes are posterior. The first to tenth thoracic foramina have additionally as anteroinferior boundaries the articulations of the head of a rib, the capsules of double synovial joints with the demifacets on adjacent vertebrae and the intra-articular ligament between the costocapitular ridge and the intervertebral symphysis. Note that the lumbar foramina lie **between** the two principal lines of vertebral attachment of the psoas major muscle. The walls of each foramen are, as noted, covered throughout by collagen, either periosteal, perichondrial, annular or capsular. *Contents* are: a segmental mixed spinal nerve and its sheaths, from two to four recurrent meningeal (sinu-vertebral) nerves (pp. 1259, 1261), variable spinal arteries (for origins, branches and distribution see p. 1546), and plexiform venous connections between internal and external vertebral venous plexuses (p. 1595). These structures, particularly the nerves, may be affected by trauma or one of the many disorders of the tissues bordering the foramen: i.e. fibrocartilage of the annulus fibrosus; in earlier decades the nucleus pulposus; the highly vascular red bone marrow occupying the cancellous bone of the vertebral bodies; the compact bone of the pedicles; the capsules, synovial membranes, articular cartilages (and at lumbar levels fibroadipose meniscoids, fat pads, fibrous labra, p. 514) of the synovial zygapophyseal joints; and additionally at thoracic levels tissues of the complex synovial costocapitular joints.

MOVEMENTS OF THE VERTEBRAL COLUMN

Movement between vertebrae is restricted by the limited deformation of intervertebral symphyses (particularly the discs), whose greater thickness at cervical and lumbar levels increases individual ranges. It is also limited by the topography of the zygapophyseal joints and by concomitant changes in tension of the ligamentous syndesmoses. Although movements between individual vertebrae are small, their summation gives a large total range to the vertebral column in flexion, extension, lateral flexion, rotation and circumduction.

In *flexion* the anterior longitudinal ligament becomes relaxed as the anterior parts of intervertebral discs are compressed; at its limit the posterior longitudinal ligament, ligamenta flava, interspinous and supraspinous ligaments and posterior fibres of intervertebral discs are tensed; interlaminar intervals widen, inferior articular processes glide on superior processes of subjacent vertebrae and their capsules become taut. Tension of extensor muscles is also important in limiting flexion, for example when carrying a load on the shoulders. Flexion is most extensive in the cervical region.

In *extension* the opposite events occur with compression of posterior discal fibres; it is limited by tension of the anterior longitudinal ligament, anterior discal fibres and approximation of spines and zygapophyses. Marked in cervical and lumbar regions, extension is much less at thoracic levels, partly because of thinner discs but also because of the presence of the thoracic skeleton and musculature. In full extension the axis of movement has been described as behind the articular processes, moving forwards as the column straightens and passes into flexion, reaching the centre of the vertebral bodies in full flexion (Wiles 1935).

In *lateral flexion*, which is always combined with rotation, intervertebral discs are laterally compressed and contralaterally tensed and lengthened, motion being limited by tension of antagonist muscles and ligaments. Lateral movements occur in all parts of the column but are greatest in cervical and lumbar regions.

Rotation involves twisting of vertebrae relative to each other with accompanying torsional deformation of intervening discs. Although slight between individual vertebrae, it summates along the column. Movement is slight at cervical level, greater in the upper thoracic and least in the lumbar region.

Circumduction is limited and merely a succession of preceding movements.

The extent and direction of vertebral movements are guided by the articular facets. Although often described as *plane*, they are never truly flat but *ovoid*, with opposing surfaces being reciprocally concave and convex. In the *cervical* region the upward inclination of the superior articular facets allows free flexion and extension; the latter usually being greater and checked above by locking of the posterior edges of the superior facets of C1 in the occipital condylar fossae and below by slipping of the inferior processes of C7 into grooves inferoposterior to the first thoracic superior articular processes. Flexion stops where the cervical convexity is straightened, checked by apposition of the projecting lower lips of vertebral bodies on subjacent bodies. Cervical lateral flexion and rotation are always combined; superomedial inclination of superior articular facets imparts rotation during lateral flexion. In the *thoracic* region, especially above, all movements are limited, reducing interference with respiration; lack of upward inclination of superior articular facets prohibits much flexion, extension being checked by contact of the inferior articular margins with laminae and of spines with each other. Thoracic rotation is freer; its axis is in the vertebral bodies in the midthoracic region, in front of them elsewhere, so that rotation involves some lateral displacement (Davis 1959; Davis et al 1965). The direction of articular facets would allow free lateral flexion but this is limited in the upper thoracic region by resistance of the ribs and sternum. Rotation is usually combined with slight lateral flexion to the same side. *Lumbar* extension is wider in range than flexion and some lateral flexion and rotation can also occur: rotation being limited by the absence of a common centre of curvature for right and left articular facets (Putz 1976). Functional transition between thoracic and lumbar regions is usually between the eleventh and twelfth thoracic vertebrae (p. 525), where zygapophyseal joints of the vertebral arches usually fit tightly, slight compression locking them, preventing all but flexion.

Muscles producing vertebral movements. The spinal column is moved both by intrinsic muscles attached to it and by muscles attached to other bones, acting indirectly. Gravity also always plays a part.

Flexion: longus cervicis, scaleni, sternocleidomastoid and rectus abdominis of both sides.

Extension: the erector spinae complex, splenius and semispinalis capitis and trapezius of both sides.

Lateral flexion: longissimus and iliocostocervicalis, oblique abdominal muscles and flexors on the side of lateral flexion.

Rotation: rotatores, multifidus, splenius cervicis and oblique abdominal muscles.

Extension, principally lumbar, occurs commonly from a stooping position. Initial extension is mainly at the hips and knees; continuous lumbar extension is delayed, with little or no activity in erector spinae. In lifting heavy weights there is considerable initial compression of lumbar intervertebral discs, with large rises in thoracic and abdominal pressure, which may resist flexion (Davis 1963; Davis et al 1965). Pal and Routal (1986) have studied the mechanics of weight transmission via the vertebral arches. In contrast with the usual view, that the major, almost only, factor is contributed by vertebral bodies and intervertebral discs, they find that, on the basis of areal and other measurements, the vertebral arches and their zygapophyseal joints are, at cervical levels, also a considerable factor in weight transmission. For an extensive view of lumbar backache see Wyke (1980).

CERVICAL VERTEBRAE

The seven cervical vertebrae (**6**.94–96), the smallest of the movable vertebrae, are typified by a foramen in each transverse process. The first, second and seventh have special features and will be considered separately. The third, fourth and fifth cervical are almost identical; the sixth, while typical in its general features, has minor differences which usually enable its distinction from others.

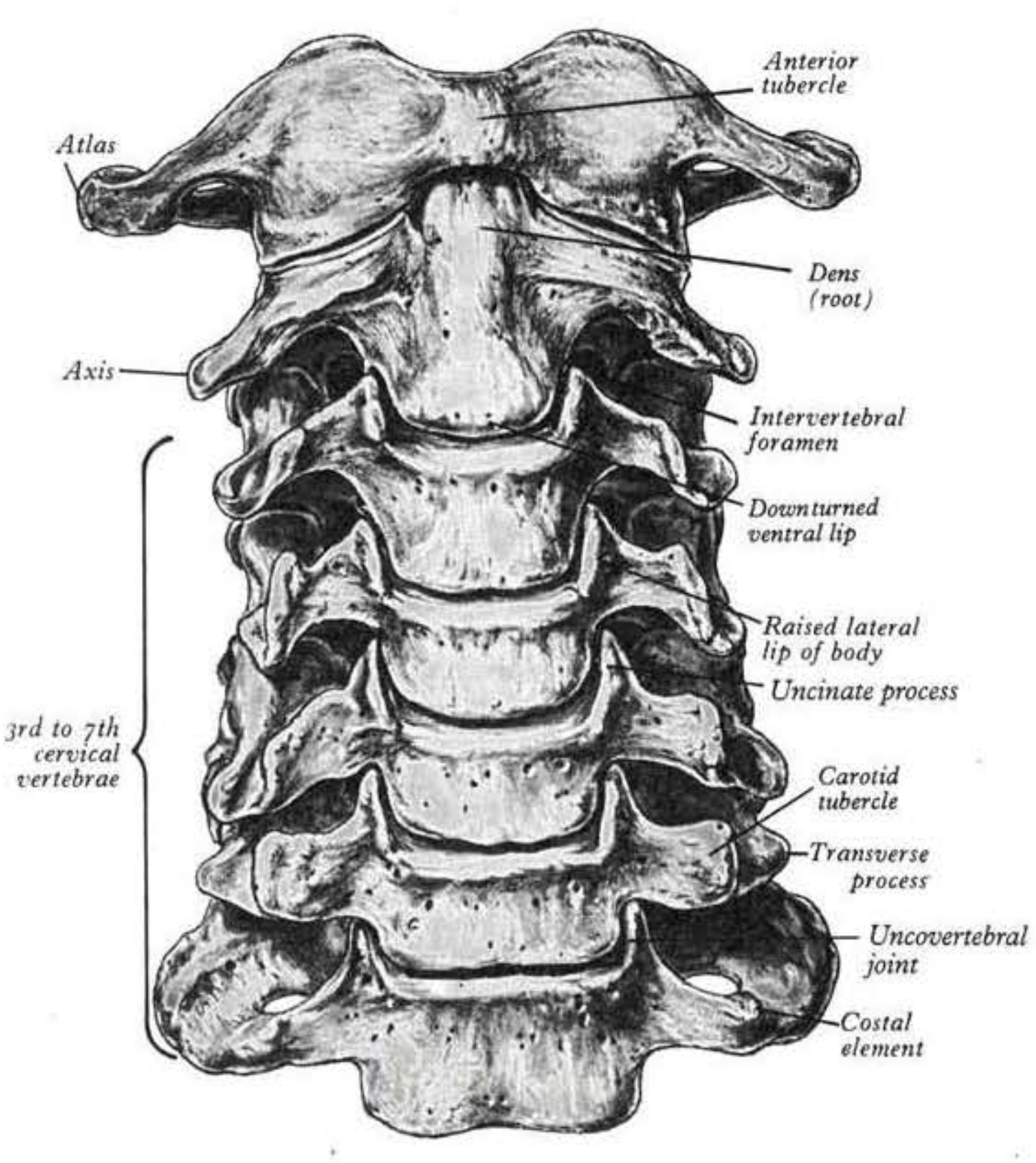

6.94 The cervical vertebrae: anterior aspect.

Typical cervical vertebra

The typical cervical vertebra (**6**.97) has a small, relatively broad vertebral *body*. The *pedicles* project posterolaterally and the longer laminae posteromedially, enclosing a large, roughly triangular *vertebral foramen*; the vertebral canal here accommodates the cervical enlargement of the spinal cord. The pedicles are inserted midway between the discal surfaces of the vertebral body, so the superior and inferior vertebral notches are of similar depth. The *laminae* are thin and slightly curved, with a thin superior and slightly thicker inferior border. The *spinous process* (spine) is short and bifid, with two tubercles which are often unequal in size. The junction between lamina and pedicle bulges laterally between the superior and inferior *articular processes* to form, when articulated, an articular pillar on each side. The *transverse process* is morphologically composite around the *foramen transversarium*. Its dorsal and ventral *roots* or *bars* terminate laterally as corresponding *tubercles*. The tubercles are connected, lateral to the foramen, by the *costal* (or intertubercular) *lamella*: these three elements represent morphologically the capitellum, tubercle and neck of a cervical costal element, sometimes referred to as the *pleurapophysis*. The attachment of the posterior root to the pediculolaminar junction represents the morphological transverse process (*diapophysis*) and the attachment of the ventral root to the ventral body the capitellar process (*parapophysis*; **6**.89).

The vertebral body has a convex anterior surface. The discal margin gives attachment to the anterior longitudinal ligament, and shallow anterolateral depressions lodge the vertical parts of longus colli. The posterior surface is flat or minimally concave, and its discal margins give attachment to the posterior longitudinal ligament. The central area displays several vascular foramina, of which two are commonly relatively larger and known as the *basivertebral foramina*: these transmit basivertebral veins to the anterior internal vertebral veins. The superior surface is saddle-shaped, formed by flange-like lips which arise from most of the lateral circumference of the upper margin of the vertebral body; these are sometimes referred

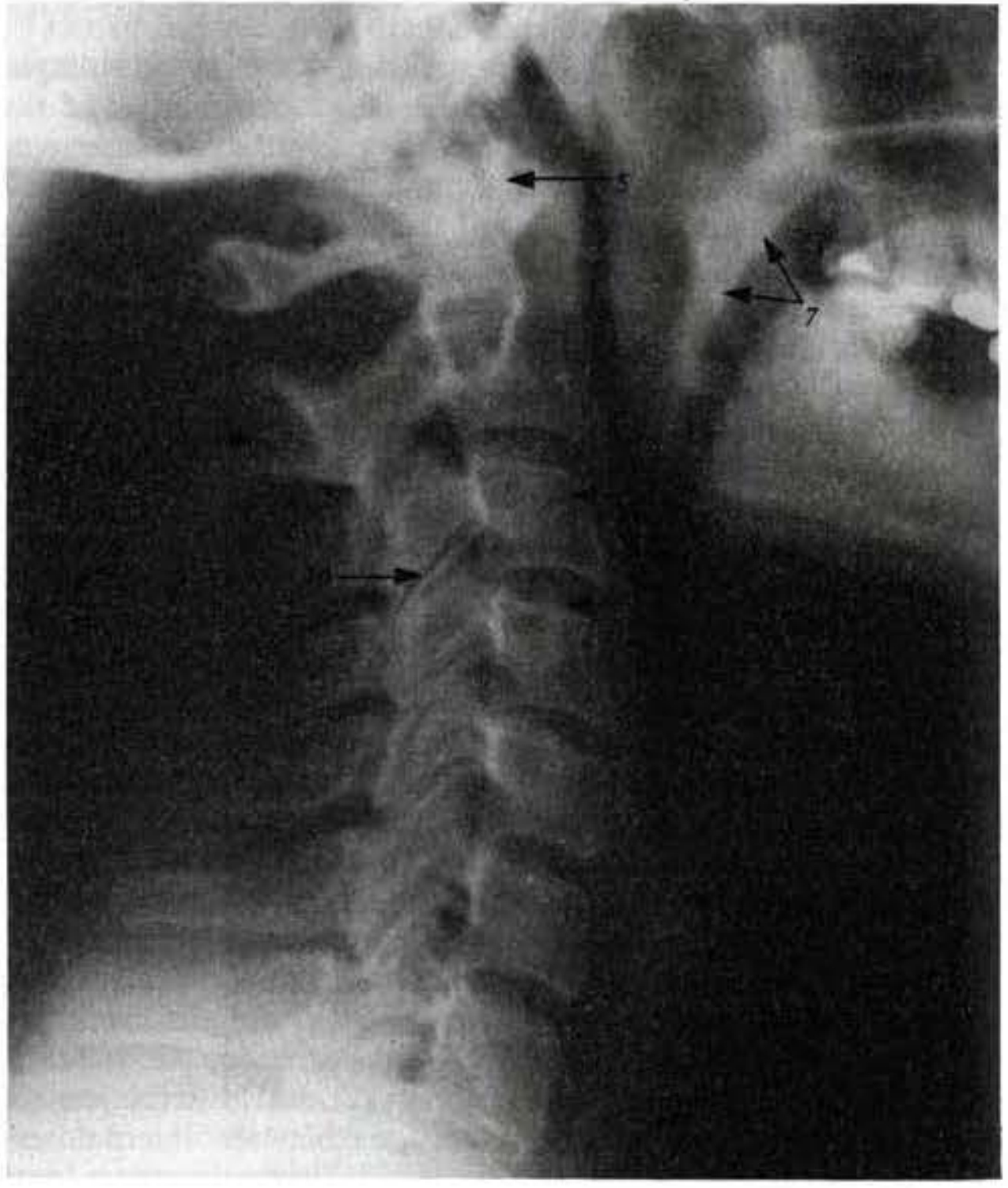

6.95 Lateral radiograph of the neck. The cervical curve of the vertebral column is well shown. The arrows point to 1. the pharyngeal part of the tongue; 2. the epiglottis; 3. the body of the hyoid bone; 4. the thyroid cartilage which is undergoing calcification; 5. the anterior tubercle of the atlas; 6. the spinous process of the axis; 7. the soft palate; 8. characteristic cervical body; 9. intervertebral disc; 10. zygapophysial joint; 11. air in trachea. (Provided by Shaun Gallagher; photography by Sarah Smith.)

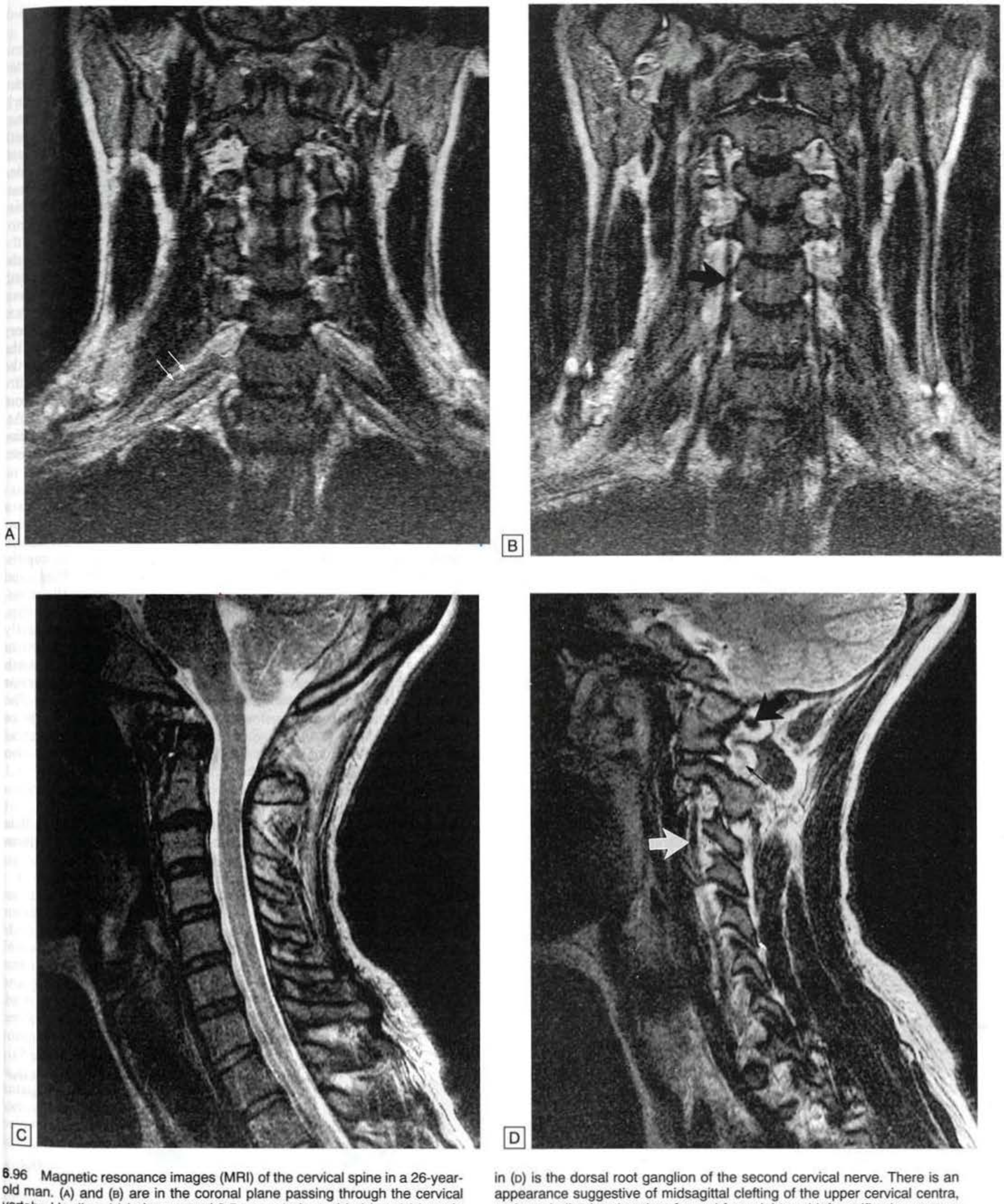

6.96 Magnetic resonance images (MRI) of the cervical spine in a 26-year-old man. (A) and (B) are in the coronal plane passing through the cervical vertebral bodies, (A) being centred 3.5 mm anterior to (B). (C) and (D) are in the sagittal plane, (C) centred to the midpoints of the vertebral bodies, (D) centred to the articular pillars. Large arrow in (B) and (D) is the vertebral artery; small arrows in (A) are the trunks of the brachial plexus; small arrow in (D) is the dorsal root ganglion of the second cervical nerve. There is an appearance suggestive of midsagittal clefting of the upper cervical centra, perhaps indicating that they formed from right and left ossification centres like the centrum of the atlas. It is a relatively common appearance on computed images in the appropriate plane. (Images supplied by J M Stevens and H A Crockard.)

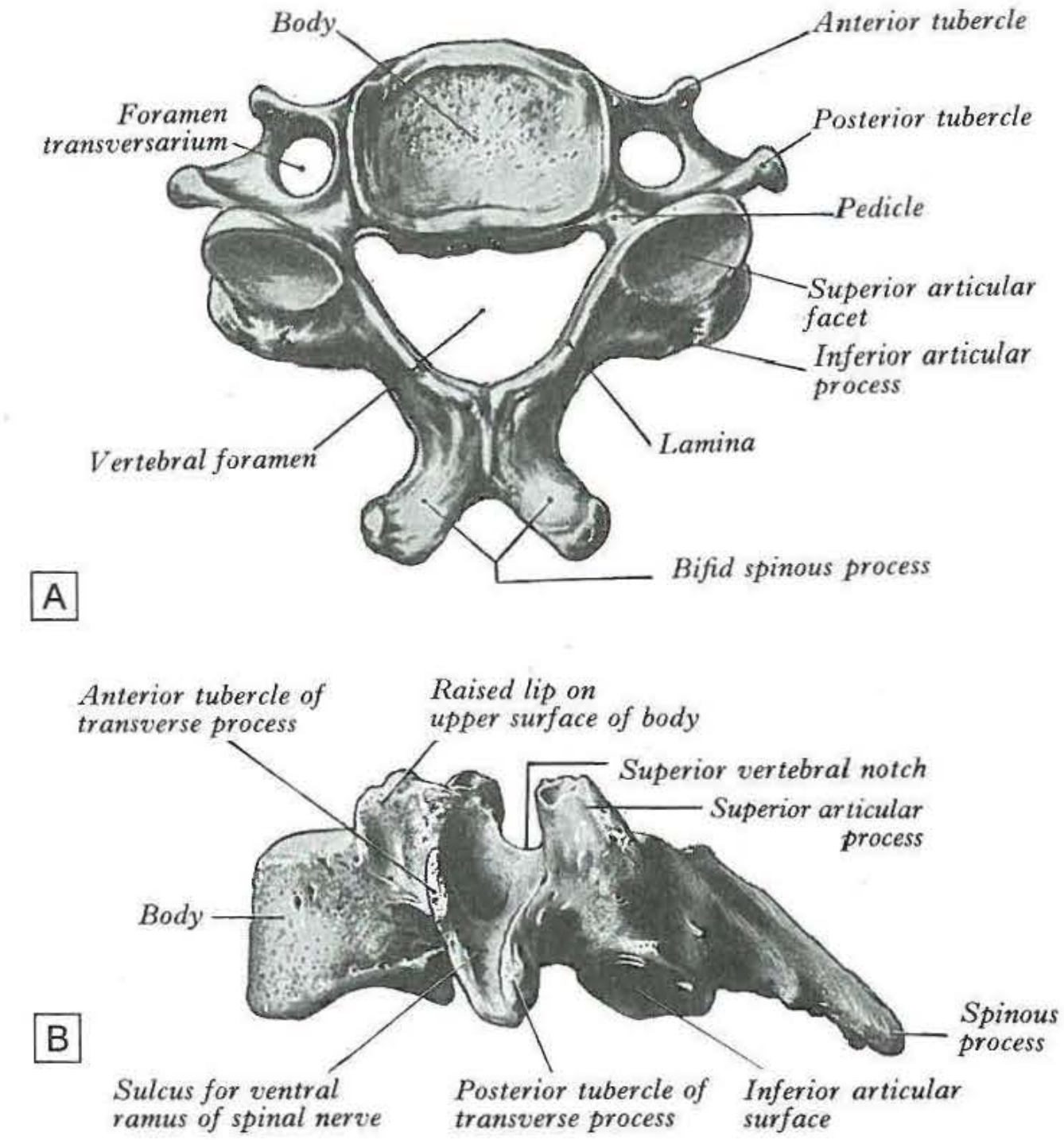

6.97 Typical cervical vertebra: A. Superior aspect. B. Left lateral aspect.

to as *uncinate* or *neurocentral* lips or processes. The inferior discal surface is also concave, the convexity being produced mainly by a broad projection from the anterior margin which partly overlaps the anterior surface of the intervertebral disc. The discal surfaces of cervical vertebrae are so shaped in order to restrict both lateral and anteroposterior gliding movements during articulation. The paired ligamenta flava extend from the superior border of each lamina below to the roughened inferior half of the anterior surfaces of the lamina above. The superior part of the anterior surface of each lamina is smooth, like the immediately adjacent surfaces of the pedicles: these are usually in direct contact with the dura mater and cervical root sheaths, to which they may become loosely attached. To the spinous processes are attached the ligamentum nuchae and numerous deep extensors, including semispinalis thoracis and cervicis, multifidus, spinales and interspinales. The spinous process of the sixth cervical vertebra is larger, and is often not bifid.

The superior articular facets, flat and ovoid, are directed superoposteriorly, whereas the corresponding inferior facets are directed mainly anteriorly, and lie nearer the coronal plane than the superior facets. The dorsal rami of the cervical spinal nerves curve posteriorly close to the anterolateral aspects of the articular pillars, and may actually lie in shallow grooves, especially on the third and fourth pair. A small, functionless tubercle, lateral to a small pressure facet, is often present close to the superior articular facet, and is regarded by morphologists as a paraprezygapophysis (Cave 1975). The dorsal root ganglion of each cervical spinal nerve lies between the superior and inferior vertebral notches of adjacent vertebrae; the large anterior ramus passing posterior to the vertebral artery, which lies on the concave upper surface of the costal lamella: the concavity of the lamellae increasing from the fourth to the sixth vertebra. The fourth to sixth anterior tubercles are elongated and rough for tendinous slips of salenus anterior, longus capitis and longus colli; the sixth is the longest and is often called the *carotid tubercle*. The carotid artery can be immobilized and compressed in the groove formed by the vertebral bodies and the larger anterior tubercles, especially the sixth—hence its name. The posterior tubercles are rounded and more laterally placed than the anterior, and all but the sixth are also more caudal, with the sixth being at about the same level as the anterior. Attached to the posterior tubercles are the splenius, longissimus and iliocostalis cervicis, levator scapulae and scalenus posterior and medius.

Seventh cervical vertebra

The seventh cervical vertebra (**6.98**), or vertebra prominens, has a long spinous process visible at the lower end of the nuchal furrow. It ends in a prominent tubercle for the attachment of the ligamentum nuchae, along with the following muscles: trapezius, spinalis capitis, semispinalis thoracis, multifidus and interspinales. The thick and prominent transverse processes are behind and lateral to the transverse foramina; the latter transmits vertebral veins, not the artery, and is often divided by a bony spicule. The costal lamella is relatively thin and may be partly deficient, or it may be separate as a *cervical rib*. It is grooved superiorly for the anterior ramus of the seventh cervical nerve, and usually carries a small and inconspicuous anterior tubercle. The posterior tubercle, by contrast, is prominent. The anterior border of the transverse process receives the attachment of scalenus minimus (pleuralis), when present, and also the suprapleural membrane (p. 1663). The first pair of levatores costarum is also attached to the transverse processes.

Atlas

The atlas, the first cervical vertebra (**6.99**), supports the head. It is unique in that it fails to incorporate a centrum, the expected position

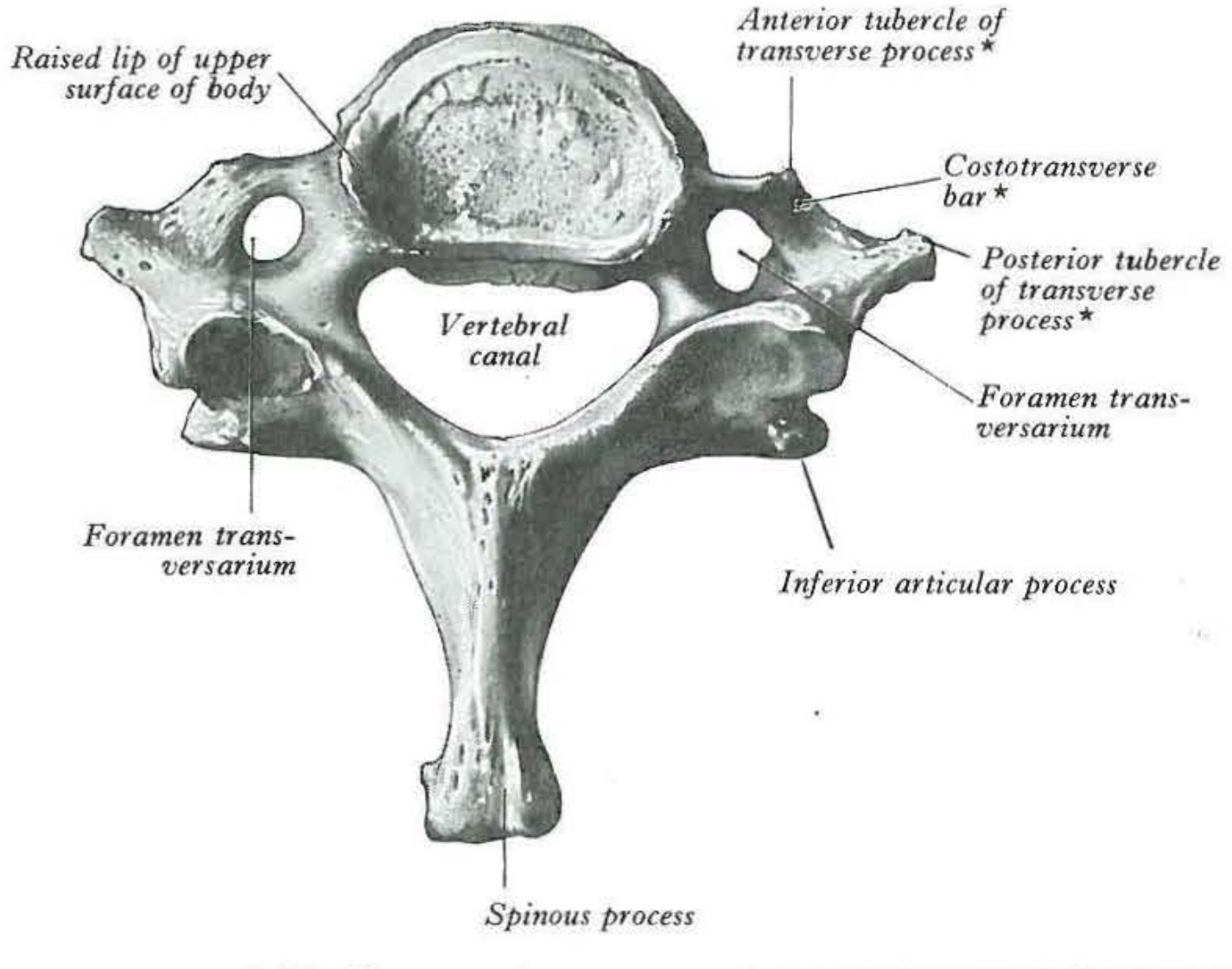

6.98 The seventh cervical vertebra: superior aspect. See text and **6.89** for alternative terms.

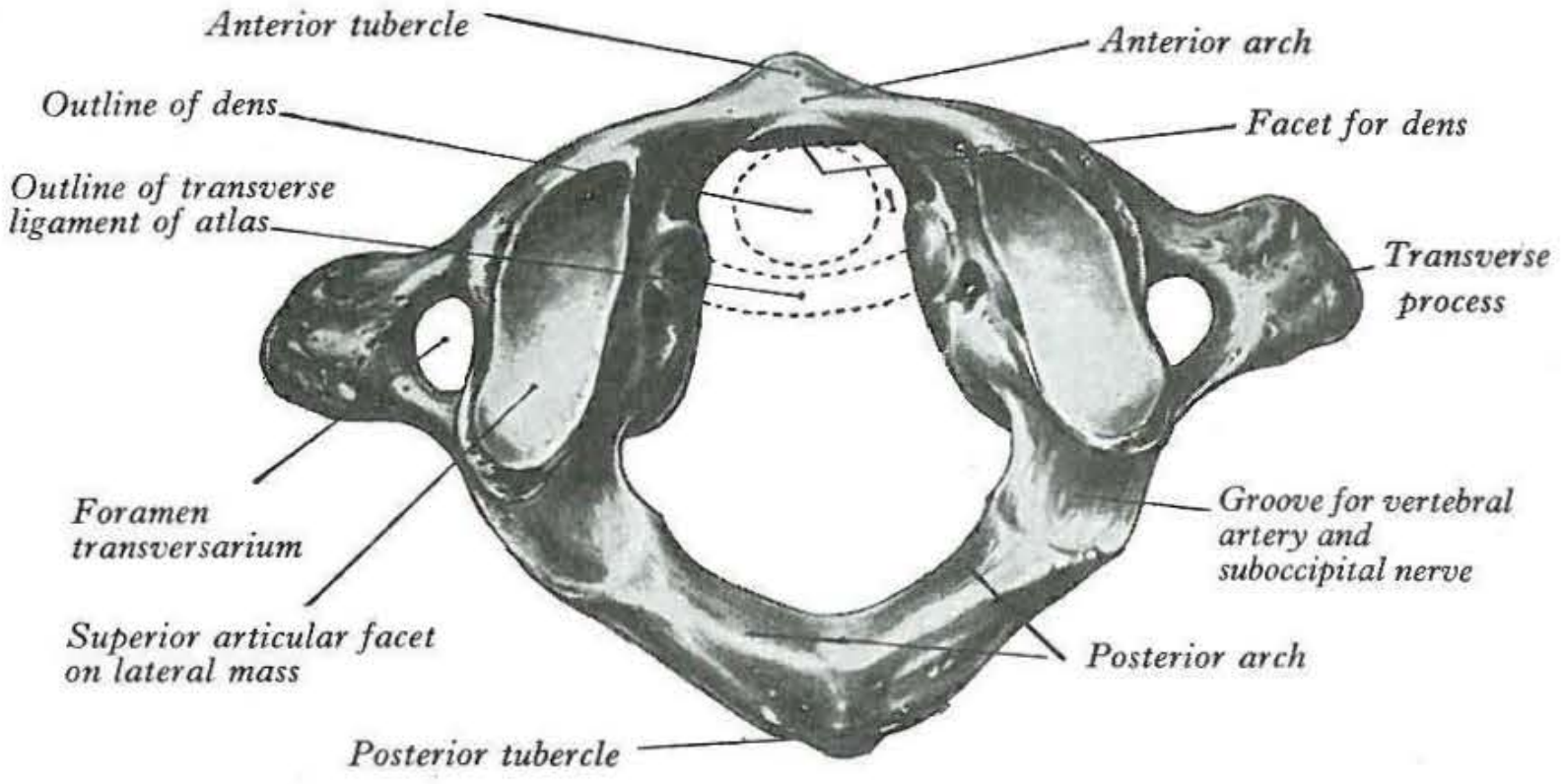

6.99 The first cervical vertebra, or atlas: superior aspect.

of which is occupied by a cranial protuberance of the axis known as the *dens*. The atlas consists of two *lateral masses* connected by a short *anterior* and a longer *posterior* arch. The *transverse ligament* retains the dens against the anterior arch. Jenkins (1969) has shown that the dens in this location is not homologous with the centrum of the atlas, as often stated, but evolved as an addition to the postdens ossification, which is the true atlas body and has become fused to the body of the axis. The anterior arch of the atlas is morphologically a hypocentrum, ossifying in fibrocartilage formed from the embryonic hypochordal bow. Both the anterior arch and transverse ligament can be regarded as a modified intervertebral disc into which an anterior protuberance of the atlas centrum, the dens, is invaginated (Jenkins 1969; O'Rahilly et al 1983).

The *anterior arch* is slightly convex anteriorly, and carries a roughened *anterior tubercle*, to which is attached the anterior longitudinal ligament (cord-like at this level) and the superior oblique part of longus colli on each side. Its upper and lower borders provide attachment to the anterior atlanto-ocipital membrane and diverging lateral parts of the anterior longitudinal ligament. The posterior surface of the anterior arch carries a concave, almost circular facet for the dens.

The *lateral masses* are ovoid, their long axes converging anteriorly. Each bears a reniform superior articular facet for the respective occipital condyle; sometimes it is completely divided into a larger anterior and a smaller posterior part (Singh 1965; Lang 1986). The inferior articular facet of the lateral mass is almost circular, and is flat or slightly concave. It is orientated more obliquely to the transverse plane than the superior facet, facing more medially and very slightly backwards. On the medial surface of each lateral mass is a roughened area bearing vascular foramina and a tubercle for attachment of the transverse ligament (**6.99**). In adults the distance between these tubercles, shorter than the transverse ligament itself, has a mean value of 16.34 mm (range 12.0–19.0 mm; Lang 1986). The anterior surface of the lateral mass gives attachment to rectus capitis anterior.

The *posterior arch* forms three-fifths of the circumference of the atlantal ring. The superior surface bears a wide groove for the vertebral artery and venous plexus immediately behind and variably overhung by the lateral mass: the first cervical nerve intervenes. Frequently a bony spur arises from the anterior and posterior margins of this groove, sometimes referred to as *ponticles*, which convert the groove into a foramen in about 14% of individuals: more frequently, however, the foramen is incomplete superiorly (Lamberty & Zivanovic 1973; Lang 1986). The flange-like superior border gives attachment to the posterior atlantoaxial membrane, and the flatter inferior border to the highest pair of ligamenta flava. The posterior tubercle is a rudimentary spinous process, roughened for attachment of the ligamentum nuchae, and lateral to this the rectus capitis posterior minor.

The *transverse processes* are longer than those of all cervical vertebrae except the seventh (**6.94**). They act as strong levers for the muscles making fine adjustments for keeping the head balanced. Maximum atlantal width varies from 74–95 mm in males and 65–76 mm in females, affording a useful criterion for assessing sex in human remains. The apex of the transverse process, which is usually broad, flat and palpable between the mastoid process and ramus of the mandible, is homologous with the posterior tubercle of typical cervical vertebrae: the remaining part of the transverse process consists of the costal lamella. A small anterior tubercle is sometimes visible on the anterior aspect of the lateral mass. The costal lamella is sometimes deficient, leaving the foramen transversarium open anteriorly. Superiorly is rectus capitis lateralis with superior oblique located more posteriorly: laterally, on the apex, is inferior oblique below which are slips of levator scapulae, splenius cervicis and scalenus medius.

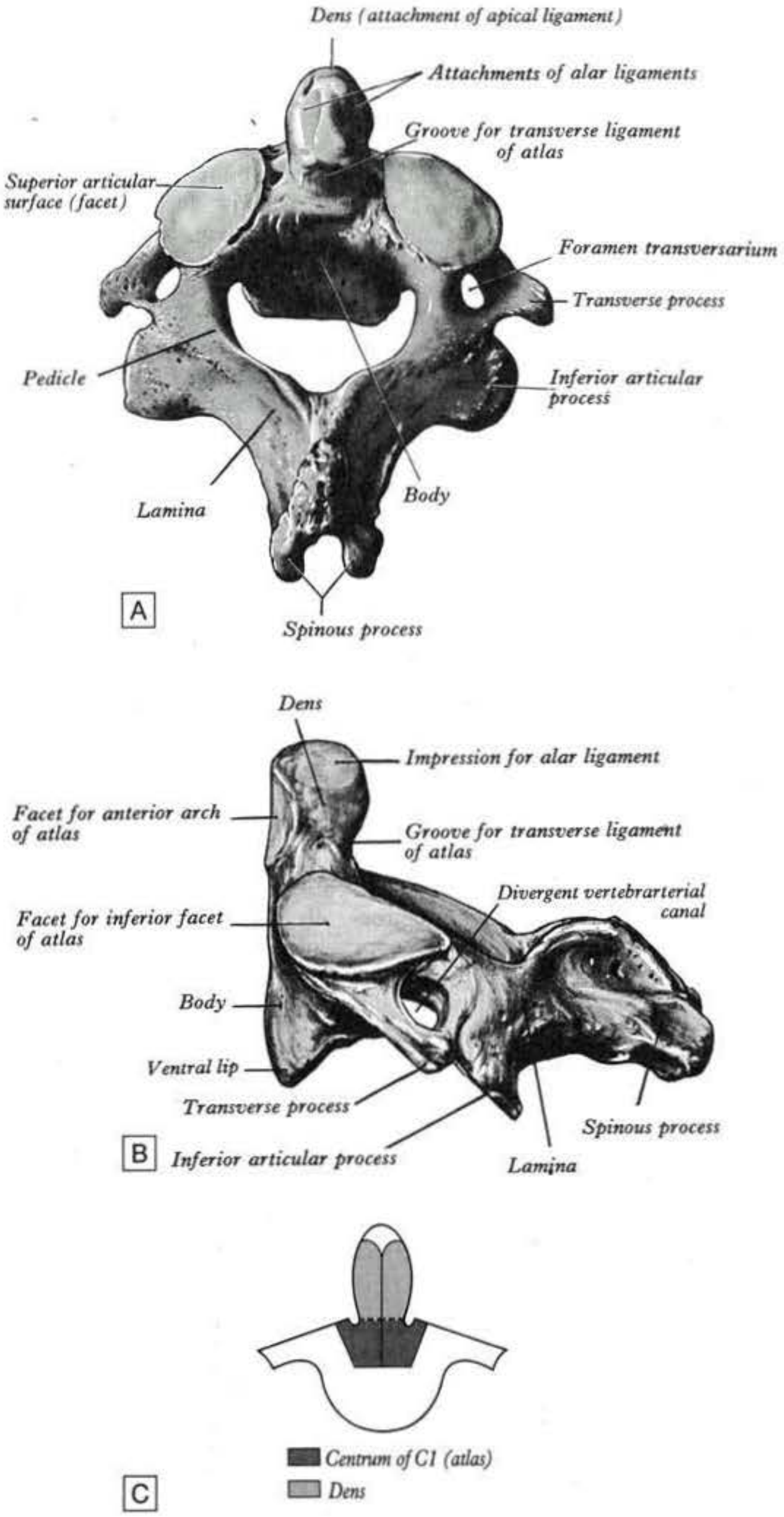

6.100 The second cervical vertebra (axis), posterosuperior (A) and left lateral (B) aspects. C. Morphology of the axis with particular reference to the centrum of the atlas and its derivatives (modified from Jenkins 1969).

Axis

The axis, the second cervical vertebra (**6.100**), is an axle for rotation of the atlas and head around the strong *dens* (odontoid process), which projects cranially from the superior surface of the body. The dens is conical in shape, with a mean length of 15.0 mm (range 9–21 mm) in adults (McManners 1983; Lang 1986). It may be tilted a little, up to 14°, posteriorly, or, less often, anteriorly, on the axis body: it may also tilt laterally up to 10° (Lang 1986). The posterior surface bears a broad groove for the cartilage-covered transverse ligament. The apex is pointed, and from this point arises the apical ligament; the alar ligaments are attached to the somewhat flattened posterolateral surfaces above the groove for the transverse ligament. The anterior surface bears an ovoid articular facet for the anterior arch of the atlas, and the surface is pitted by many vascular foramina, which are most numerous near the apex. Schiff and Parke (1973) studied the arterial blood supply of the dens and found that small twigs arose mainly from the vertebral artery at the level of the intervertebral foramen for the third cervical nerve, which formed paired anterior and posterior longitudinal channels, branches entering the dens near the base and more distally near the apex. However, the anterior also received numerous twigs from nearby branches of the external carotid via branches to the longus colli and ligaments of the apex. Hence vascular necrosis does not occur after fracture of the base of the dens. The *body* consists of less compact bone than the dens. It is, in fact, composite, consisting of the partly fused centra of atlas and axis, and a rudimentary disc (synchondrosis) between: this usually remains detectable deep within the axis body throughout life (**6**.100c). Large ovoid articular facets are present on either side of the dens at the junction of the body and neural arch, which are flat or slightly convex for articulation with the masses of the atlas. They lie in a plane anterior to the plane of the intercentral articulations, with which they are, in part, homologous (Jenkins 1969; Cave 1975). The anterior surface of the body carries a deep depression on each side for the attachment of the vertical part of longus colli. The somewhat triangular downward projecting anterior border gives attachment to the anterior longitudinal ligament. Posteriorly, the lower border receives the posterior longitudinal ligament and the membrana tectoria (p. 512, 522).

The *pedicles* are stout, with the superior surface carrying part of the superior articular facet, which also projects laterally and downwards on to the transverse process. The anterolateral surface is deeply grooved by the vertebral artery, and the lateral part of the inferior surface of the superior articular facet, which can become quite thin. The inferior surface of each pedicle bears a deep, smooth inferior intervertebral notch, in which lies the large root sheath of the third cervical nerve. Here is a short interarticular part of the pedicle, between the relatively small posterior articular process located at the pediculolaminar junction, with its equally small anteriorly facing facet, and the superior articular surface.

The *transverse process* is pointed and projects inferiorly and laterally, arising from the pediculolaminar junction and the lateral aspect of the interarticular area of the pedicle. The rounded tip is homologous with the posterior tubercle of typical cervical vertebrae. The foramen transversarium is directed laterally as the vertebral artery turns abruptly laterally under the superior articular facet. Small anterior tubercles may be present near the junction of the costal lamella with the body. To the tips of the transverse processes are attached the levator scapulae, between scalenus medius and splenius cervicis, and to their upper and lower surfaces the intertransverse muscles (p. 812).

The *laminae* are thick, affording attachment to the ligamenta flava. The *spinous process* is large, with a bifid tip and a broad base, concave inferiorly. The lateral surfaces of the spinous process give origin to the inferior obliques, with the rectus posterior major a little more posteriorly. The inferior concavity receives the semispinalis and spinalis cervicis, and, deeper, the multifidus: near the apex it receives interspinales. The ligamentum nuchae is attached to the apical notch.

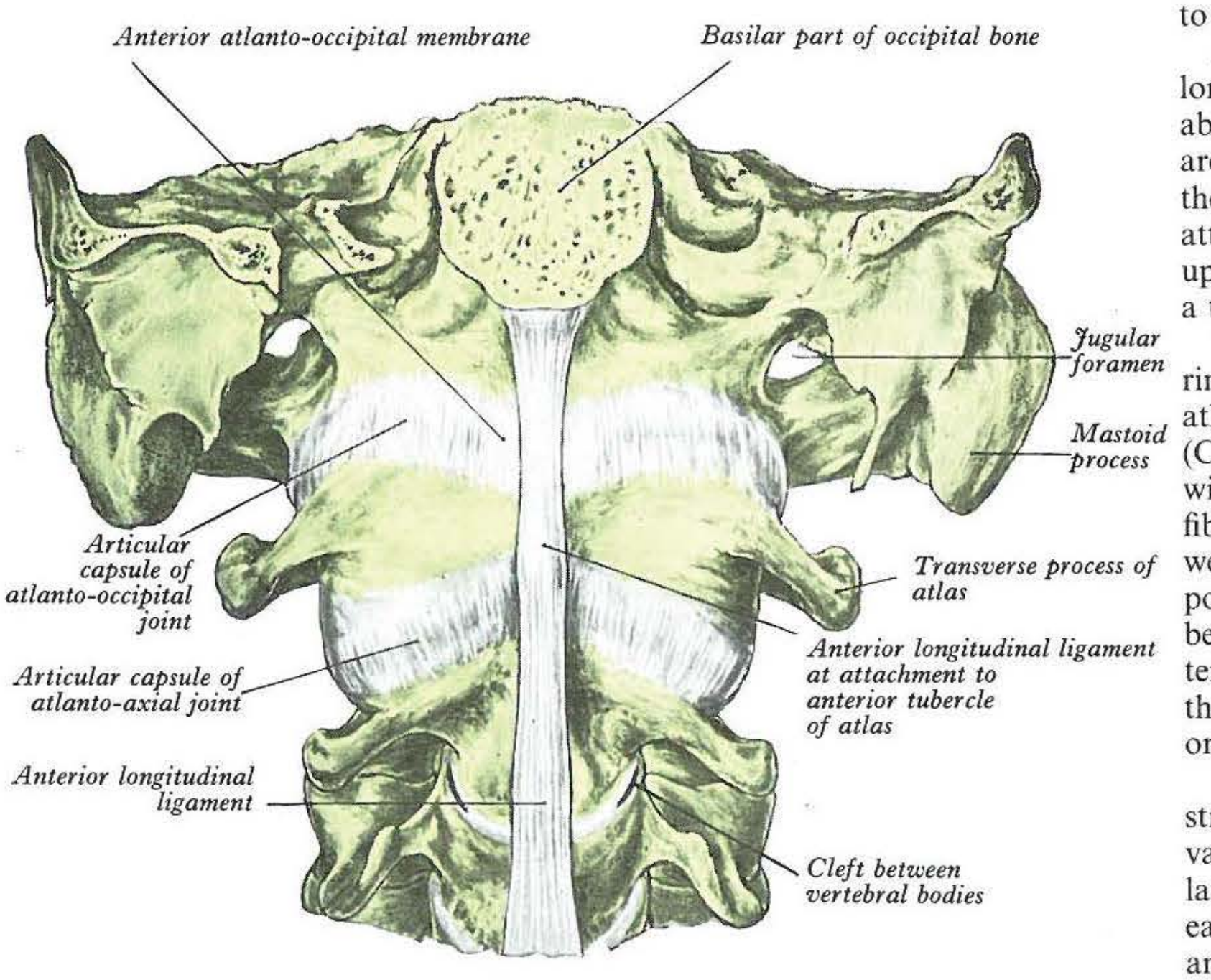

6.101 Atlanto-occipital and atlanto-axial joints: anterior aspect. On each side a small cleft has been opened between the lateral part of the upper surface of the body of the third cervical vertebra and the bevelled, inferior surface of the body of the axis.

Clinical anatomy. Abnormalities of the dens of the axis are common, and often result in atlantoaxial subluxation. Most are acquired, but many result from fractures through the base of the dens which do not unite due to interposition of the transverse ligament (Crockard et al 1993). Others, occurring particularly in some skeletal dysplasias, represent an abnormal ossification pattern in which the dens ossifies separately and much later than the atlantal centrum (of which it is part): this is probably a result of abnormal mobility in the cartilaginous anlage, and may be restored to normal if motion is prevented by surgical arthrodesis (Stevens et al 1991). Hypoplasia of the dens is usually accompanied by atlanto-occipital assimilation and basilar invagination. Incomplete segmentation is common in the cervical spine, and most commonly involves the axis and third cervical vertebra. The costal element of the seventh cervical vertebra may articulate with the transverse process as an independent rib of variable size.

CRANIOVERTEBRAL JOINTS

The articulation between the cranium and vertebral column is specialized to provide a wider range of movement than in the rest of the axial skeletal. It consists of the occipital condyles, atlas and axis, and functions like a universal joint, permitting horizontal and vertical scanning movements of the head, which is superbly adapted for eye-head co-ordination (Rabischong 1992).

Atlanto-axial joints

Articulation of atlas to axis is at three synovial joints, a pair between lateral masses, and a median complex between the dens of the axis and the anterior arch and transverse ligament of the atlas.

The lateral atlantoaxial joints. These are often classified as planar but the bony *articular surfaces* are more complex in shape, usually reciprocally concave in the coronal plane, with the medial parts being somewhat convex in the sagittal plane, especially that of the axis. The cartilaginous articular surfaces are usually less concave. Fibrous capsules attached to their margins are thin, loose and lined by synovial membrane. Each has a posteromedial *accessory ligament* attached below to the axial body near the base of its dens, and above to the lateral atlantal mass near the transverse ligament.

Anteriorly, the vertebral bodies are connected by the anterior longitudinal ligament (**6**.101): here a strong, thickened band attaches above to the lower border of the anterior tubercle of the anterior arch of the atlas and below to the front of the axial body. Posteriorly the vertebral bodies are joined by the ligamenta flava (**6**.102), attaching to the lower border of the atlantal arch above, and to the upper borders of the axial laminae. At this level these ligaments are a thin membrane, pierced laterally by the second cervical nerves.

The median atlantoaxial joint. A pivot between the dens and a ring formed by the anterior arch and transverse ligament of the atlas, it has two synovial cavities which sometimes communicate (Cave 1975). A vertically ovoid facet on the anterior dens articulates with one on the posterior aspect of the anterior atlantal arch. The fibrous capsule, which is lined by synovial membrane, is relatively weak and loose, especially superiorly. The synovial cavity of the posterior component of the median joint complex is larger, lying between the horizontally orientated ovoid facet, grooving the posterior surface of the dens and the *cartilaginous* anterior surface of the transverse ligament (**6**.103): communication often exists with one or both of the atlanto-occipital joint cavities.

The transverse atlantal ligament (**6**.99, 103, 104). This is a broad, strong band arching across the atlantal ring behind the dens: it is variable in length (mean 20.1 mm) (Dvorak et al 1988b). It is attached laterally to a small but prominent tubercle on the medial side of each atlantal lateral mass, and broadens medially where it is covered anteriorly by a thin layer of articular cartilage. It consists almost entirely of collagen fibres, which, in the central part of the ligament, cross one another at an angle to form an interlacing mesh (Dvorak et al 1988b). From its upper margin a strong median longitudinal band arises which inserts into the basilar part of the occipital bone between the apical ligament of the dens and membrana tectoria, and from its inferior surface a weaker and less consistent longitudinal band passes to the posterior surface of the axis. These transverse and longitudinal components together constitute the *cruciform ligament*.

The transverse ligament divides the ring of the atlas into unequal parts (**6.99**); the posterior and larger surrounds the spinal cord and meninges, the anterior contains the dens, which is retained in position even when all other ligaments are divided.

Movements at the atlantoaxial joints. These are simultaneous at all three joints and consist almost exclusively of rotation of the axis. The shape of the articular surfaces determines that, when rotation occurs, the axis ascends slightly into the atlantal ring (Kapandji 1974; Lang 1986), which limits stretch on the lateral atlantoaxial joint capsules. Rotation is limited mainly by the alar ligaments, with a minor contribution from the accessory atlantoaxial ligament. The normal range of atlantoaxial rotation has been measured as being 41.5° (range 29–54°) (Dvorak et al 1988a).

Muscles producing atlantoaxial rotation. These act on the cranium, transverse processes of the atlas and spinous process of the axis. They are mainly obliquus capitis inferior, rectus capitis posterior major and splenius capitis of one side, and the contralateral sternocleidomastoid.

Atlanto-occipital joints

Each joint consists of two reciprocally curved *articular surfaces*, one on the occipital condyle the other on the lateral mass of the atlas; the atlantal facets are concave and tilted medially. The bones are connected by articular capsules and the anterior and posterior atlanto-occipital membranes.

Fibrous capsules. The capsules surround the occipital condyles and superior atlantal articular facets. They are thicker posteriorly and laterally, where the capsule is sometimes deficient, and may communicate with the joint cavity between the dens and the transverse ligament of the atlas (Cave 1934; Lang 1986).

The anterior atlanto-occipital membrane (**6**.101). Broad, and of densely woven fibres, it connects the anterior margin of the foramen magnum to the upper border of the anterior arch of the atlas. Laterally, it blends with the capsular ligaments, and medially it is strengthened by a median cord which is the anterior longitudinal ligament stretching between the basilar occipital bone and anterior atlantal tubercle.

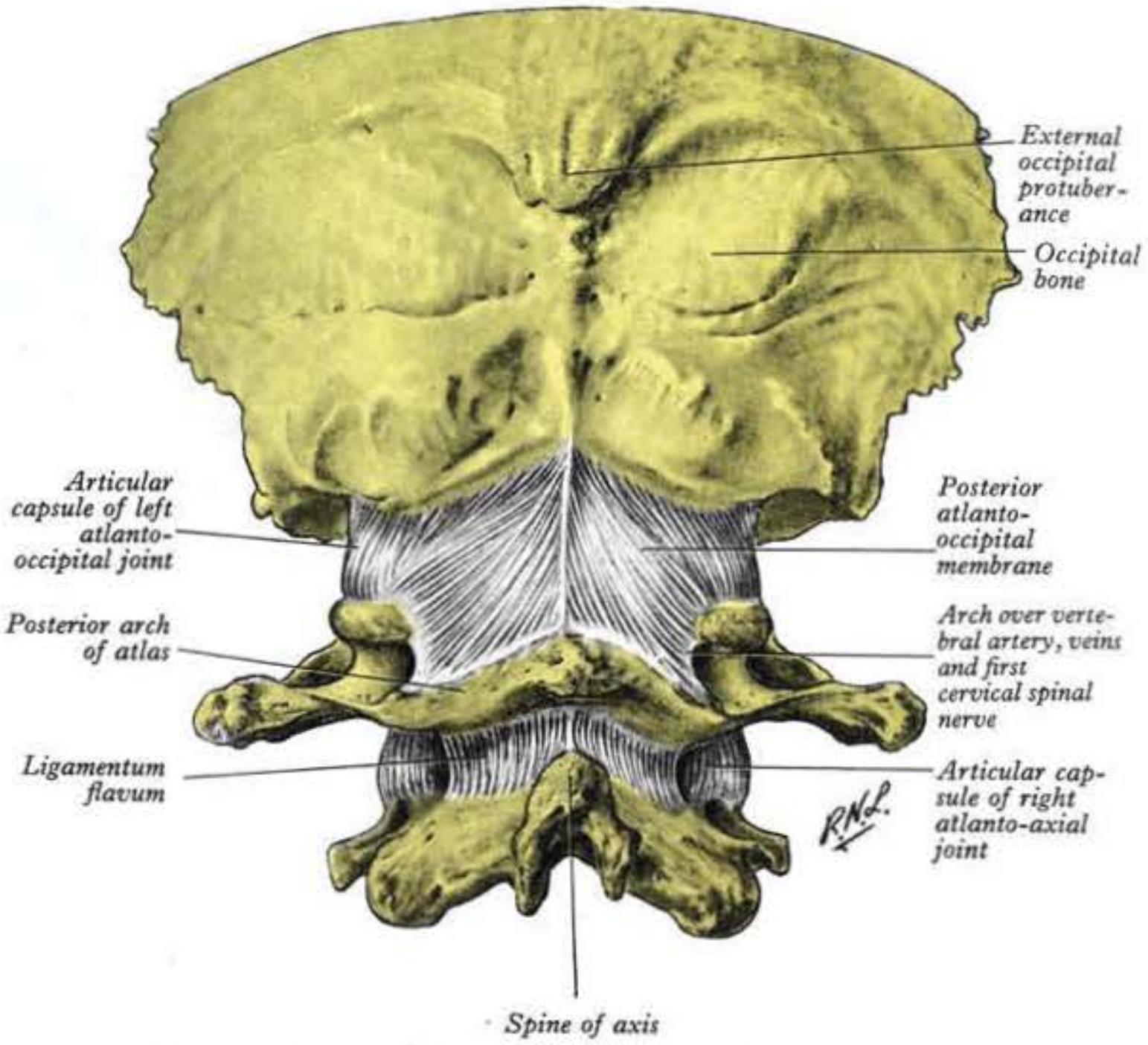

6.102 Atlanto-occipital and atlantoaxial joints: posterior aspect.

The posterior atlanto-occipital membrane (**6**.102). This is also broad, but relatively thin, connecting the posterior margin of the foramen magnum to the upper border of the posterior atlantal arch,

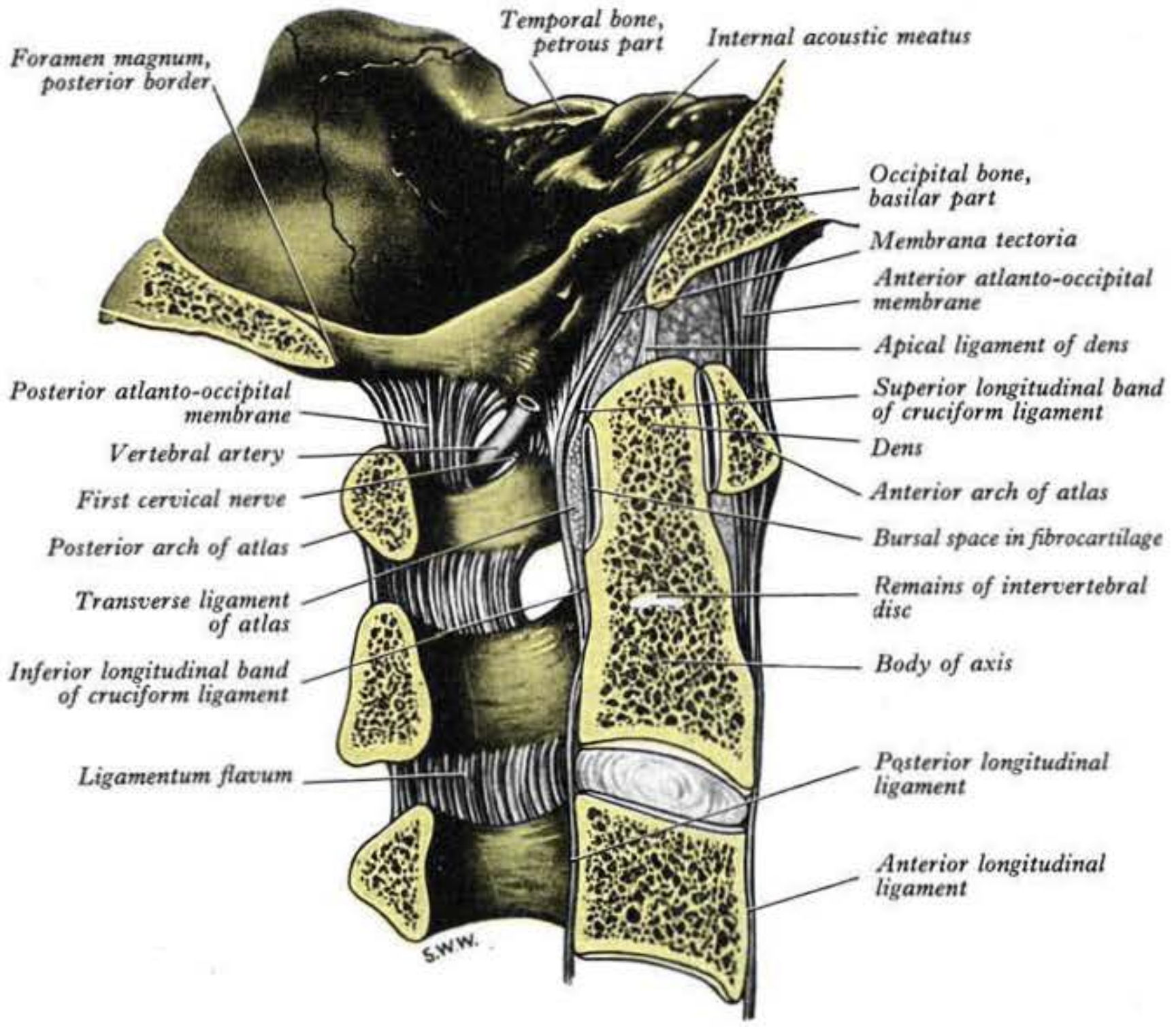

6.103 Median sagittal section through the occipital bone and the first to third cervical vertebrae.

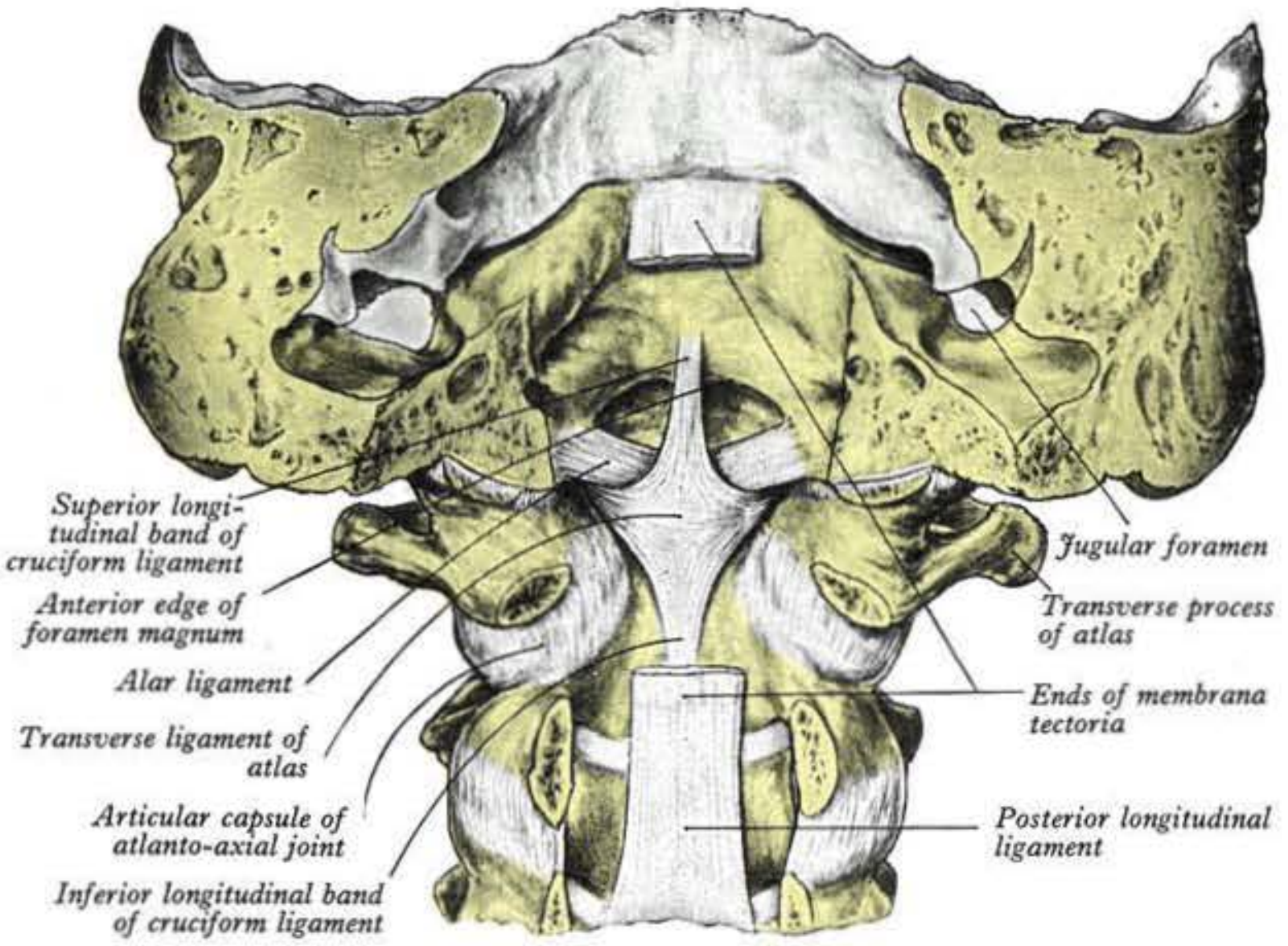

6.104 Posterior aspect of the atlanto-occipital and atlantoaxial joints, after removal of the posterior part of the occipital bone and the laminae of the upper cervical vertebra. The atlanto-occipital joint cavities have been opened.

blending laterally with the joint capsules. It arches over the grooves for the vertebral arteries, venous plexuses and first cervical nerve: the ligamentous border of the arch is sometimes ossified.

Movements at the atlanto-occipital joints. The long (topographical) axes run anteromedially; because of this and their articular curvatures, the joints act as one around transverse and anteroposterior axes of movement but **not** about a vertical axis. The main movement is flexion, with a little lateral flexion and rotation. In young individuals the flexion range has been measured at 16.8–20.8° (Johnson et al 1977), lateral flexion at 3° and rotation at 5.7° (Dvorak et al 1988a).

Muscles producing movements at the atlanto-occipital joints. These are for *flexion*: longus capitis and rectus capitis anterior; *extension*: recti capitis posteriores major and minor, obliquus capitis superior, semispinalis capitis, splenius capitis and trapezius (cervical part); *lateral flexion*: rectus capitis lateralis, semispinalis capitis, splenius capitis, sternocleidomastoid and trapezius (cervical part); *rotation*: obliquus capitis superior, rectus capitis posterior minor, splenius capitis and sternocleidomastoid.

Ligaments connecting axis and occipital bone

These consist of the membrana tectoria, and paired alar and median apical ligaments.

Membrana tectoria (**6**.103, 104). Inside the vertebral canal, this is a broad strong band representing the upward continuation of the posterior longitudinal ligament (p. 512). Its superficial and deep laminae are both attached to the posterior surface of the axial body, the superficial lamina expanding as it ascends to the **upper** surface of the basilar occipital bone, attaching above the foramen magnum, where it blends with the cranial dura mater. The deep lamina has a strong median band ascending to the foramen magnum, and two lateral bands which pass and blend with the capsules of the atlanto-occipital joints as they reach the foramen magnum. The membrane is separated from the cruciform ligament of the atlas by a thin layer of loose areolar tissue, and sometimes by a bursa.

Alar ligaments (**6**.104). Thick cords about 11 mm long, they extend from the longitudinally ovoid flattenings on the posterolateral aspect of the apex of the dens horizontally and laterally to the roughened areas on the medial side of the occipital condyles. In most individuals there is also an anteroinferior band about 3 mm long which inserts into the lateral mass of the *atlas* in front of the transverse ligament; a few fibres are occasionally found passing from the dens to the anterior arch of the atlas (Dvorak and Panjabi 1987). In addition, in about 10% of cases a continuous transverse band of fibres passes between the occipital condyles immediately above the transverse ligament, the *transverse occipital ligament* (Dvorak et al 1988b). These ligaments consist mainly of collagen fibres arranged in parallel. The main function of the alar ligaments is now considered to be limitation of atlantoaxial rotation, the left becoming taut on rotation to the right and vice versa. The slightly upward movement of the axis during rotation helps permit a wider range of movement by reducing tension in the alar ligaments, as it does also in the capsules and accessory ligaments of the lateral atlanto-occipital joint.

Apical ligament of the dens (**6**.103). It fans out from the apex of the dens into the anterior margin of the foramen magnum between the alar ligaments. It represents the cranial continuation of the notochord and its sheath (Ganguly & Roy 1964; O'Rahilly et al 1974). It is separated for most of its extent from the anterior atlanto-occipital membrane and cruciform ligament by pads of fatty tissue, though it blends with their attachments at the foramen magnum, and with the alar ligaments at the apex of the dens.

Ligamentum nuchae (p. 514). This also connects cervical vertebrae with the cranium.

Clinical anatomy. The transverse ligament is stronger than the dens, which usually fractures before rupture of the ligament. The alar ligaments are weaker, and combined head flexion and rotation may avulse one or both alar ligaments: rupture of one side results in an increase in the range of rotation of about 30% to the opposite side (Dvorak et al 1987). Pathological softening of the transverse and adjacent ligaments, usually due to connective tissue disorders, or of the lateral atlantoaxial joints results in atlantoaxial subluxation (Bogduk & Macintosh 1984), which may cause spinal cord injury. An interesting syndrome has been described in which atlantoaxial rotation causes entrapment of the second cervical spinal nerve, resulting in unilateral cervico-occipital pain, and, because afferent fibres pass from the lingual nerve via the hypoglossal nerve to the second cervical nerve, pain and numbness in the ipsilateral side of the tongue (Lance & Anthony 1980).

THORACIC VERTEBRAE

The twelve thoracic vertebrae (**6**.87, 105, 106) increase in size caudally, like other vertebrae, due to increased loading from above. All their bodies display lateral costal facets and all but the lowest two or three transverse processes also have facets, articulating with the head of the rib or its tubercle respectively. The first and ninth to twelfth vertebrae also have atypical features; except for relatively minor details the rest are alike.

The *body* is typically a waisted cylinder except where the vertebral foramen encroaches, transverse and anteroposterior dimensions

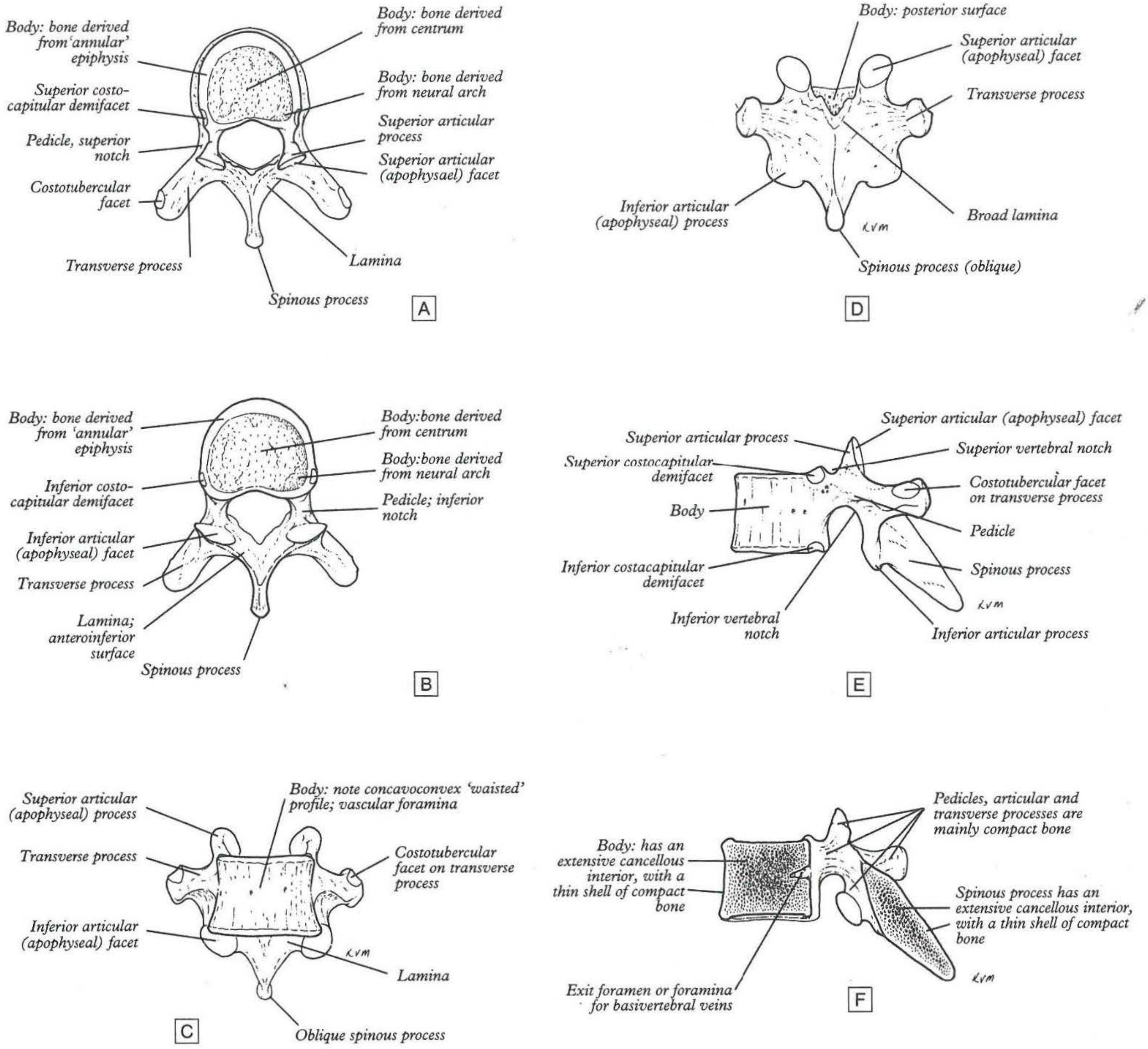

6.105 Typical thoracic vertebra. A. Superior aspect B. Inferior aspect C. Anterior aspect D. Posterior aspect E. Lateral aspect F. Longitudinal section.

being almost equal. One each side are *two costal facets* (really *demifacets*), the superior pair (usually larger) at the upper border anterior to the pedicles, the inferior at the lower border anterior to the vertebral notches (**6**.105D). The *vertebral foramen* is small and circular; thus the *pedicles* do not diverge as in cervical vertebrae; also the thoracic spinal cord is smaller and more circular. The *laminae* are short, thick and broad overlapping from above downwards. The *spinous process* slants downward. The thin and almost flat *superior articular processes* project from the pediculolaminar junctions and face posteriorly, a little superolaterally. The *inferior processes* project down from the laminae with their facets directed forwards, a little superomedially. The large, club-like *transverse processes* also project from the vertebral arch at the pediculolaminar junctions. Each passes posterolaterally and has, near its tip, anterior oval facets for articulation with the tubercle of the corresponding rib.

First thoracic vertebra (**6**.107). This has circular upper costal facets for articulation with the whole facet on the head of the first rib; the smaller, semilunar inferior facets articulate, as do most thoracic vertebrae, with a demifacet on the rib head. The long, thick spine is horizontal and commonly as prominent as the seventh cervical.

Ninth thoracic vertebra (**6**.107). Otherwise typical, it often fails to articulate with the tenth ribs in which case the inferior demifacets are absent.

Tenth thoracic vertebra (**6**.107). This only articulates with the tenth pair of ribs. Consequently superior facets only appear on the body; these are usually large and semilunar, or oval when the tenth ribs fail to articulate with the ninth vertebrae and intervening disc. The transverse process may or may not bear a facet for the tenth rib tubercle.

Eleventh thoracic vertebra (**6**.107). This articulates only with heads of the eleventh ribs. The circular costal facets are close to the upper border of the body extending on to the pedicles. The small transverse processes lack articular facets.

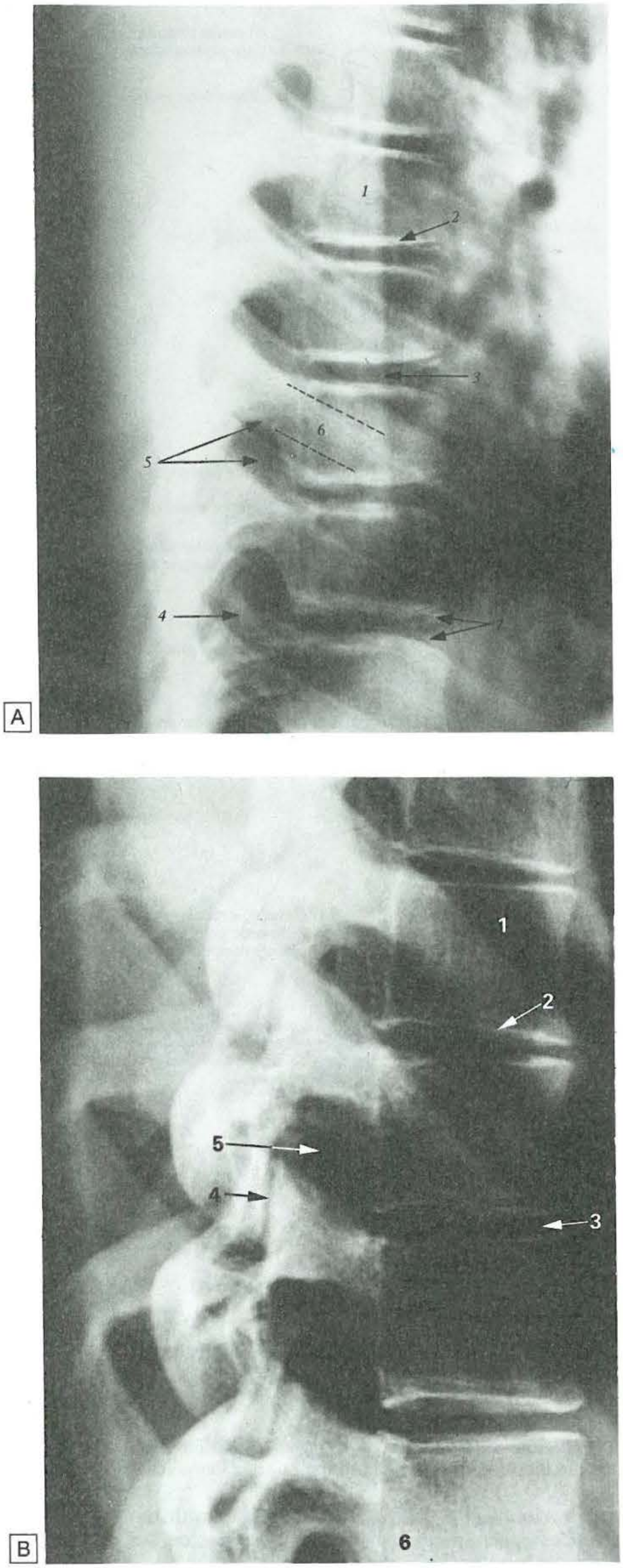

6.106 Lateral radiographs of midthoracic vertebral column in a child of 14 years (A) and an adult female of 22 years (B).
1. Cancellous bone of vertebral body. 2. Shell of compact bone. 3. Site of intervertebral disc. 4. Synovial joint between articular processes. 5. Intervertebral foramen. 6. Superimposed shadow of rib. 7. Ossification occurring in unfused annular epiphyses of vertebral bodies. (A supplied by Shan Gallagher, Guy's Hospital; photography by Sarah Smith.)

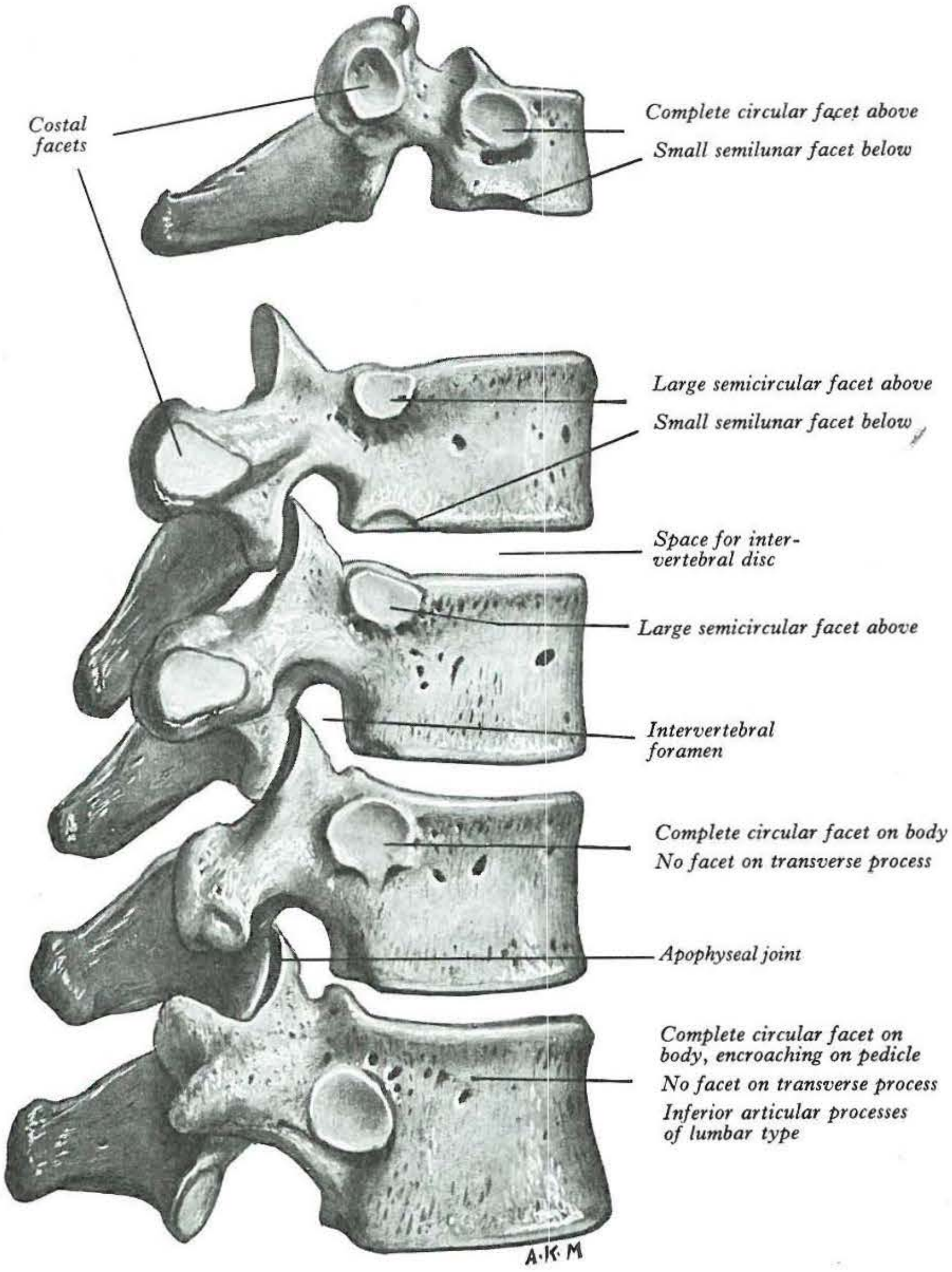

6.107 The first, ninth, tenth, eleventh and twelfth thoracic vertebra: right lateral aspect.

Twelfth thoracic vertebra (6.107). This articulates with the heads of the twelfth ribs by circular facets somewhat below the upper border, spreading on to the pedicles. The body is large and the transverse processes small; the vertebra has some lumbar features (see below).

Changes in thoracic vertebrae

The *bodies* of upper thoracic vertebrae gradually change from cervical to thoracic in type, while the lower change from thoracic to lumbar. The body of the first is typically cervical, its transverse diameter being almost twice the anteroposterior; the second retains a cervical shape, but its two diameters differ less. The third body is the smallest having a convex anterior aspect unlike the flattened first and second. The remaining bodies increase in size and, owing to its increased anteroposterior diameter, the fourth is typically 'heart-shaped' (cordate). The fifth to eighth increase their anteroposterior dimension but change little transversely. These four, in transverse section, are asymmetrical, their left sides being flattened by pressure of the thoracic aorta. The rest increase more rapidly in all measurements, so that the twelfth body resembles that of a typical lumbar vertebra. Geometrical analysis suggests that these modifications are also adaptations to a greater range of flexion-extension at the cervical and lumbar ends of the thoracic vertebral column (Veleanu et al 1972).

To borders of the bodies are attached the anterior and posterior longitudinal ligaments, and around the margins of costal facets are capsular and radiate ligaments of the costovertebral joints. Longus colli arises from the upper three thoracic vertebral bodies, lateral to the anterior longitudinal ligament, and psoas major and minor from the side of the twelfth near its lower border.

Thoracic *pedicles* show a successive caudal increase in thickness. The superior vertebral notch is recognizable only in the first thoracic, but the inferior notch is deep in all. Ligamenta flava are attached at the upper borders and lower anterior surfaces of laminae, and rotatores to their posterior aspects.

Thoracic *transverse processes* shorten in caudal succession. In the upper six (or five), the costal facets are concave and face anterolaterally; at lower levels the facets are flatter and face superolaterally and slightly forwards. To the anterior surface medial to the facet is attached the costotransverse ligament, to its tuberculated apex the lateral costotransverse ligament and to its lower border the superior costotransverse ligament. Upper and lower borders also provide attachment for intertransverse muscles or fibrous vestiges and the posterior surface for deep dorsal muscles; posteriorly on the apex is the levator costae.

Thoracic *spines* overlap from the fifth to eighth, which is the longest and most oblique. (In quadrupeds most thoracic spines slope caudally and lumbar spines cranially, the change in inclination occurring at a lower thoracic *anticlinal* vertebra; its human equivalent is the eleventh.) Supraspinous and interspinous ligaments, trapezius, rhomboid major and minor, latissimus dorsi, serratus posterior superior and inferior and many deep dorsal muscles are attached to thoracic spines.

The first thoracic vertebra resembles a cervical vertebra in its body, both in shape and posterolateral lipping, the latter forming the anterior border of the superior vertebral notch, a distinctive feature. The upper costal facet is often incomplete, the first rib then articulating with the seventh cervical and intervening disc. Below the facet a small, deep depression often occurs.

The eleventh and twelfth thoracic spinous processes are triangular, with blunt apices, a horizontal lower and an oblique upper border. The twelfth thoracic transverse process is replaced by three small tubercles; the superior is largest, projects upwards and corresponds to a lumbar mamillary process, though not so close to the superior articular process. The lateral tubercle is the homologue of a transverse process, the inferior the homologue of a lumbar accessory process. These two vertebrae can be distinguished by the size and shape of the transverse process and the distance between the costal facet and upper border (see above).

A change in orientation of articular processes from thoracic to lumbar type usually occurs at the eleventh thoracic vertebra, sometimes the twelfth or tenth. In the transitional vertebra the superior articular processes are thoracic, facing posterolaterally, while the inferior are transversely convex and face anterolaterally. This vertebra marks the site of a sudden change in degree from rotational to non-rotational function (p. 515; Davis 1955).

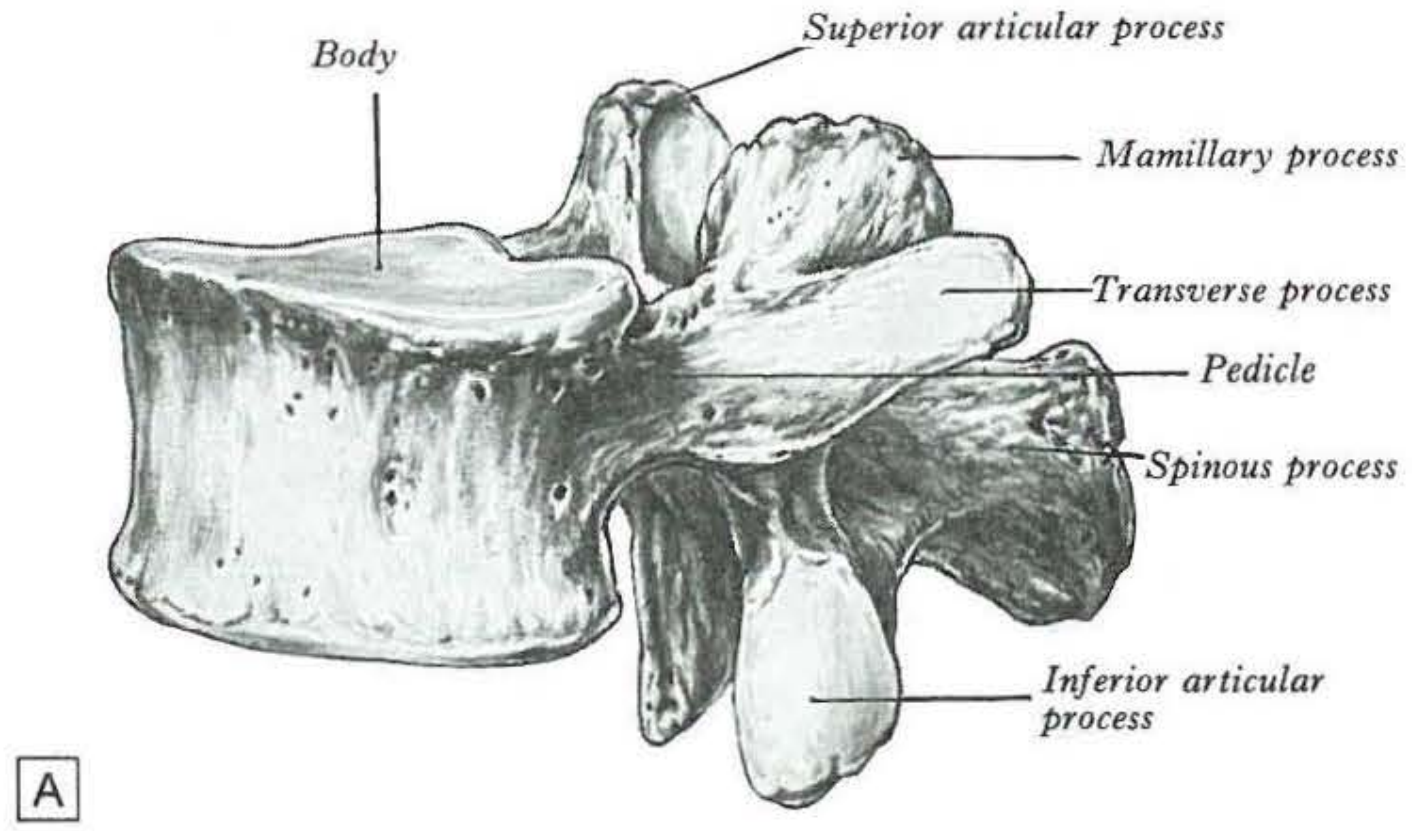

6.108A. Lumbar vertebra: left lateral aspect.

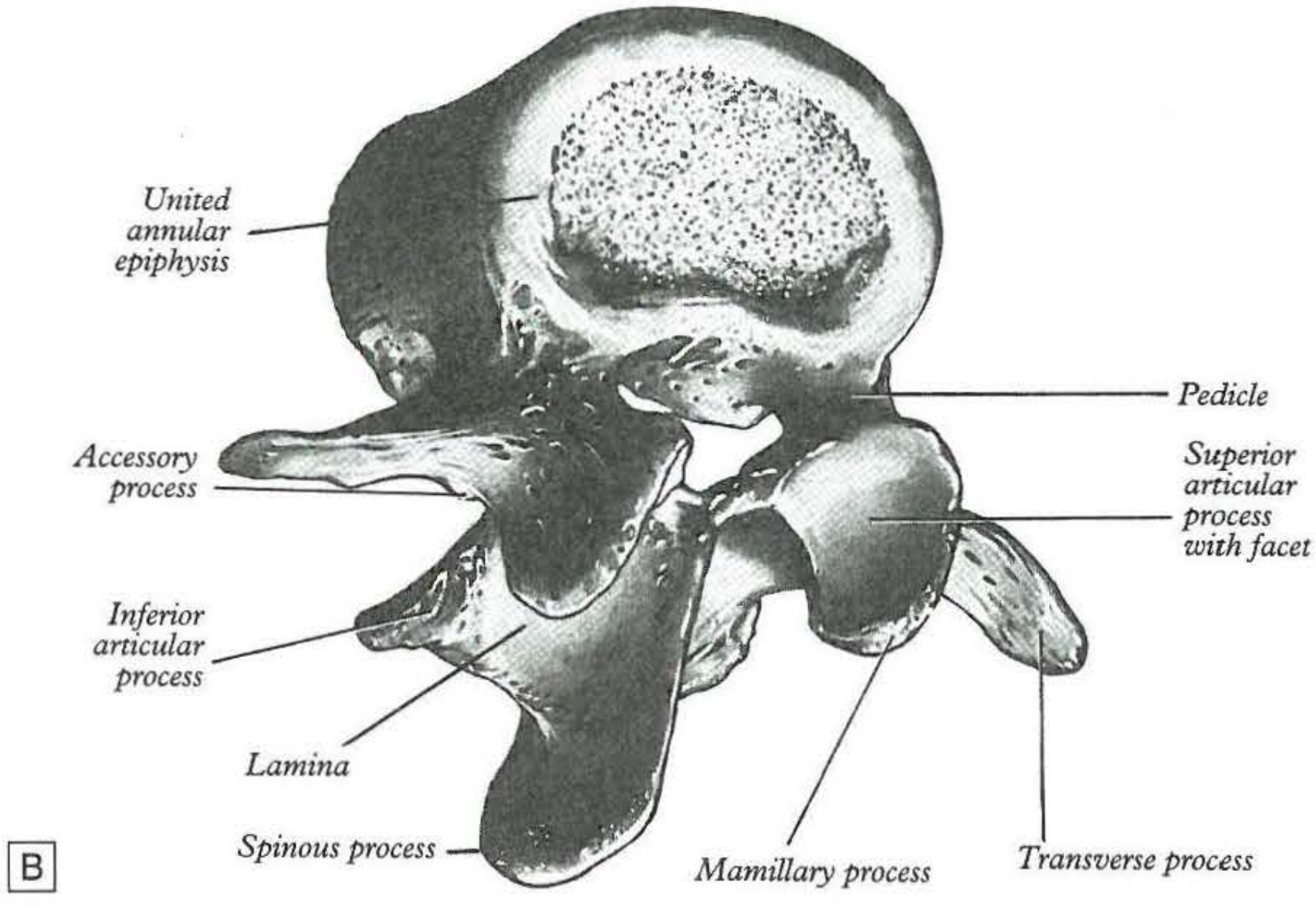

6.108B. Lumbar vertebra: posterosuperior aspect, viewed obliquely from the left side.

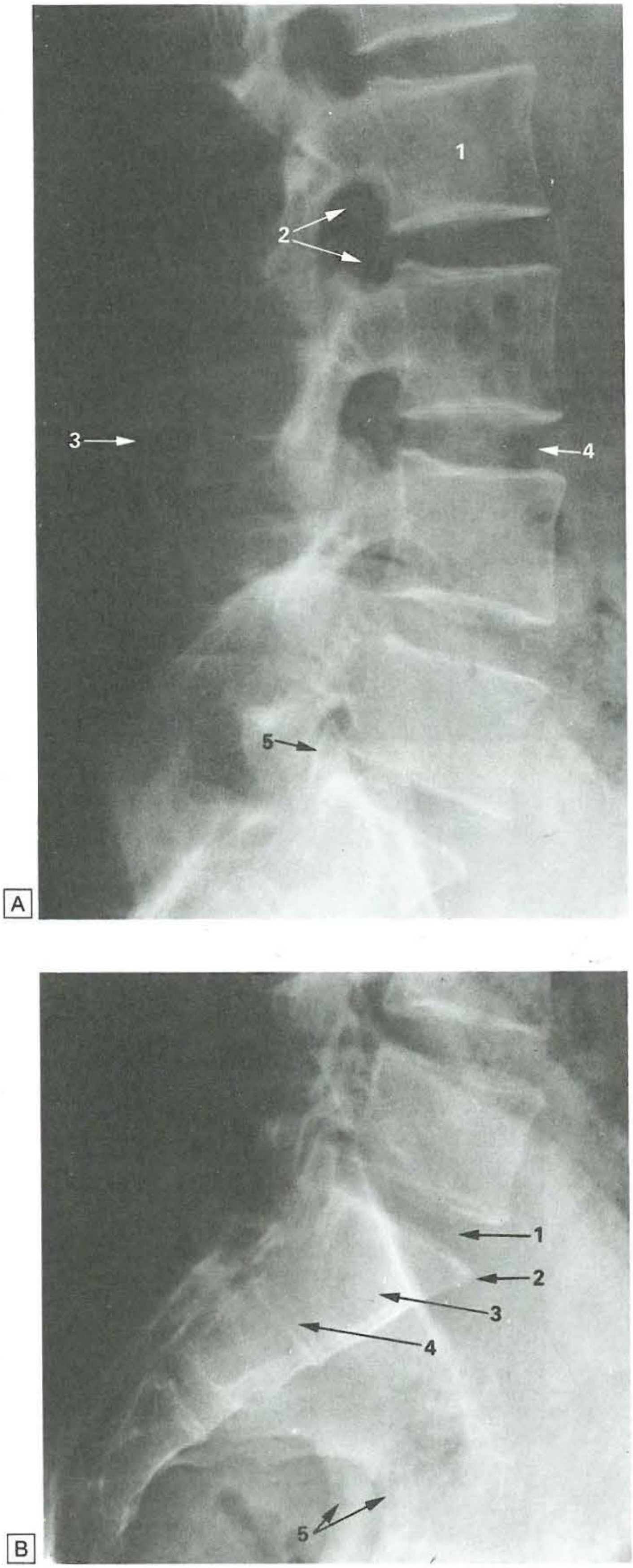

6.109A, B. Lateral radiographs of lumbosacral vertebral column in an adult male aged 26 years.

A 1. Lumbar vertebral body. 2. Intervertebral foramen. 3. Spinous process. 4. Site of intervertebral disc. 5. Synovial joint between articular processes. Note slightly cuneiform profile of fifth lumbar vertebral body. B 1. Site of lumbosacral disc. Note cuneiform shape. 2. Sacral promontory. 3. First sacral segment. 4. Remains of sacral intervertebral disc. 5. Profiles of greater sciatic notches.

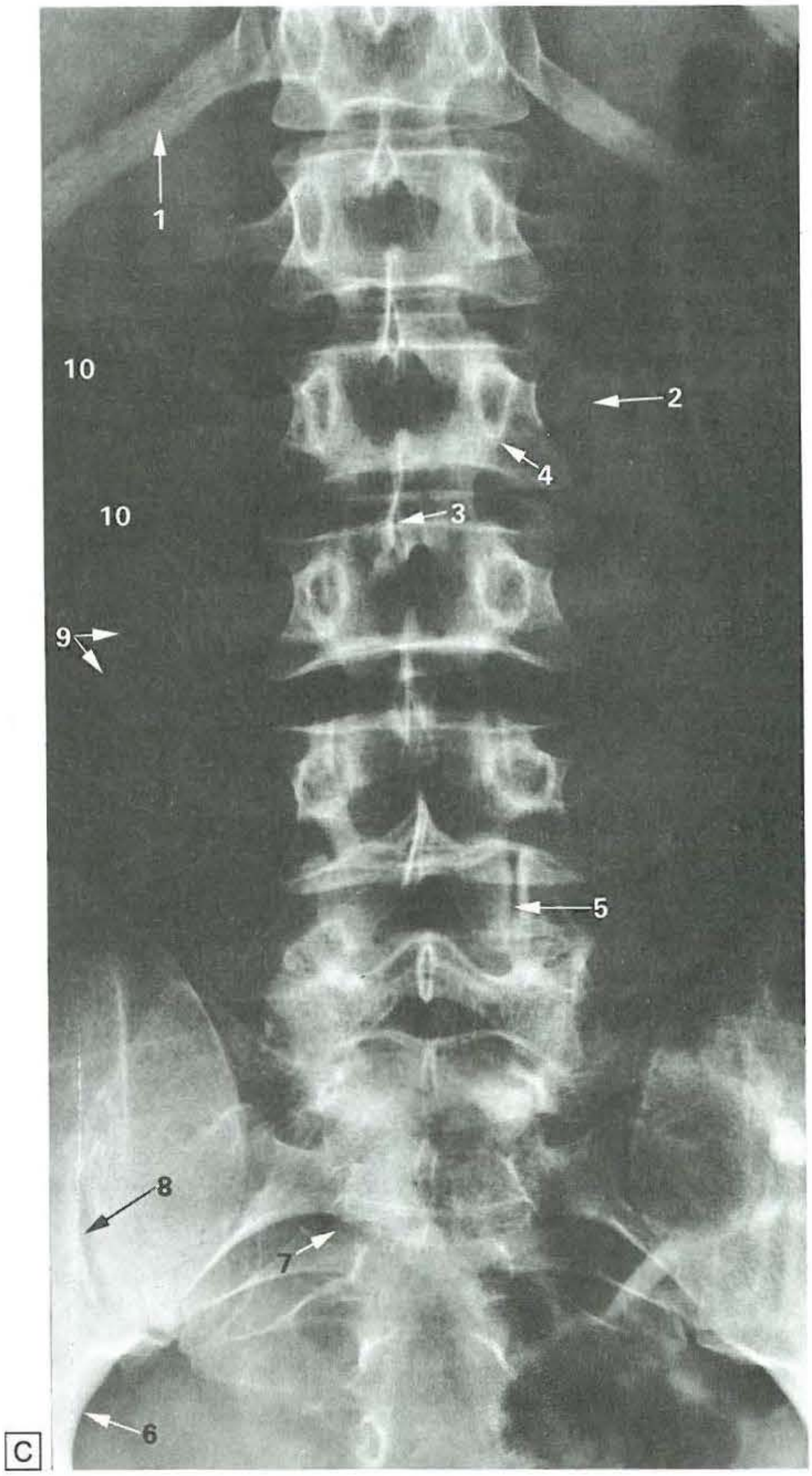

6.109 C. Anterosuperior radiograph of lumbosacral vertebral column in a young adult male aged 22 years. 1. Twelfth rib. 2. Transverse process. 3. Spinous process (2nd lumbar). 4. Compact bony shell of pedicle (2nd lumbar). 5. Joint between articular processes (4th and 5th lumbar). 6. Pelvic brim. 7. Anterior sacral foramen. 8. Sacro-iliac joint. 9. Lateral border of psoas major. 10. Gas in colon.

LUMBAR VERTEBRAE

The five lumbar vertebrae (**6**.108, 109) are distinguished by their large size and absence of costal facets and transverse foramina. The *body* is wider transversely and deeper in front. The *vertebral foramen* is triangular, larger than at thoracic but smaller than at cervical levels. The *pedicles* are short. The *spinous process* is almost horizontal, quadrangular and thickened along its posterior and inferior borders. The *superior articular processes* bear vertical concave articular facets facing posteromedially, with a rough mamillary process on their posterior borders. The *inferior articular processes* have vertical convex articular facets facing anterolaterally. The *transverse processes* are thin and long, except the more substantial fifth pair. A small accessory process marks the posteroinferior aspect of the root of each transverse process. Measurement of 338 third and fourth lumbar vertebrae, from both sexes aged 20–90 years, showed that breadth of the body increases with age; in males, posterior height decreases

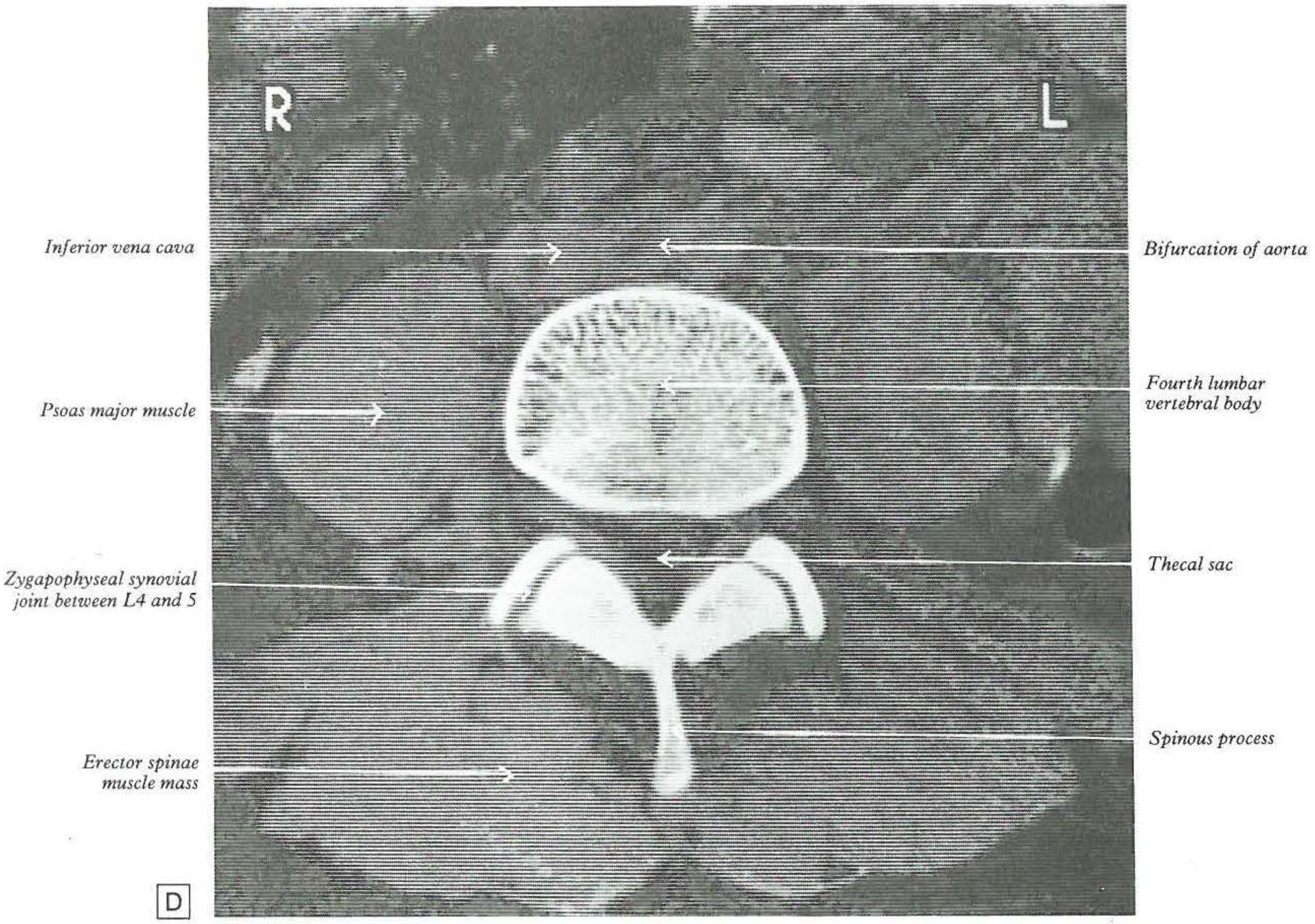

6.109D. High resolution computed tomogram through posterior abdominal wall at the level of the body of the fourth lumbar vertebra, showing zygapophyseal joints between fourth and fifth lumbar vertebrae. (Supplied by Shaun Gallagher, Guy's Hospital; photography by Sarah Smith.)

relatively; in both sexes anterior height of the body decreases relative to breadth (Ericksen 1976). Twomey et al (1983), in a study of 93 adult vertebral columns, observed a reduction in bone density of lumbar vertebral bodies, principally due to a reduction in transverse trabeculae (more marked in females), associated with increased diameter and increasing concavity in their juxtadiscal surfaces. Amonoo-Kuofi (1982, 1985) compared lumbar interpedicular distances in 150 males and 140 females by radiography, expressing these as a ratio of vertebral body width. Values varied much, but the ratio (in Nigerians) was most constant: racial variation was discussed.

A recent study has shown significant sex difference in the angle of inclination and depth of curvature of the superior articular facets of all lumbar vertebrae, in addition to which considerable asymmetry was also observed, being greatest at L1 and least at L5 (Tulsi & Hermanis 1992).

Fifth lumbar vertebra (**6**.110). This has a massive *transverse process* continuous with the **whole of the pedicle and encroaching on**

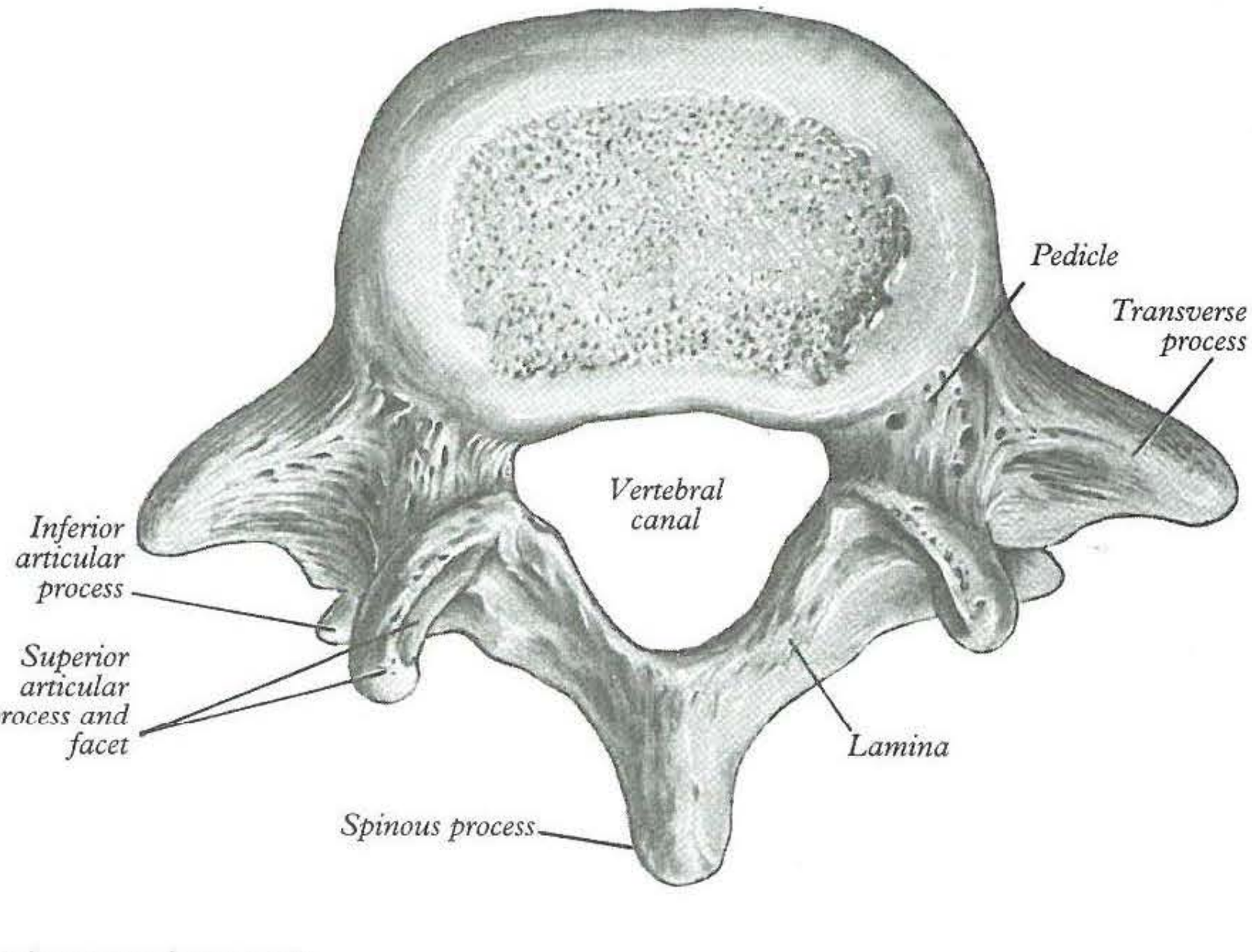

6.110 The fifth lumbar vertebra: superior aspect.

the body. The body is usually the largest and markedly deeper in front, thus contributing to the lumbosacral angle.

Attachments of lumbar vertebrae. Upper and lower borders of lumbar *bodies* give attachment to the anterior and posterior longitudinal ligaments (p. 512). Lateral to the anterior ligament the upper bodies (three on the right, two on the left) give attachments to the crura of the diaphragm. Posterolaterally, psoas major is attached to the upper and lower margins of all lumbar bodies; between these, tendinous arches carry its attachments across their concave sides. The first lumbar *vertebral foramen* contains the conus medullaris of the spinal cord, the lower foramina the cauda equina and spinal meninges. Strong paired pedicles arise posterolaterally from each body near its upper border. Superior vertebral notches are shallow, inferior ones deep. The laminae are broad and short but do not overlap as much as do the thoracic. To spinous processes are attached the posterior lamella of the thoracolumbar fascia, erectores spinae, spinales thoracis, multifidi, interspinal muscles and ligaments, and supraspinous ligaments. The fifth spine is smallest, its apex often rounded and down-turned. Upper lumbar superior articular processes are further apart than inferior ones, but the difference is slight in the fourth and negligible in the fifth. The articular facets are reciprocally concave (superior) and convex (inferior), allowing flexion, extension, lateral bending and some degree of rotation. Transverse processes, except the fifth, are anteroposteriorly compressed and project posterolaterally. The lower border of the fifth transverse process is angulated, passing laterally and then superolaterally to a blunt tip, the whole process presenting greater upward inclination than the fourth. The angle on the inferior border may represent the tip of the costal element and the lateral end the tip of the true transverse process. The lumbar transverse processes increase in length from first to third and then shorten. Thus, as noted, the fifth pair incline both **upwards** and posterolaterally. All lumbar transverse processes present a vertical ridge on the anterior surface, nearer the tip, which marks the attachment of the anterior layer of the thoracolumbar fascia, and separates the surface into medial and lateral areas for psoas major and quadratus lumborum respectively. The middle layer of the fascia is attached to the apices of the transverse processes; to the first pair the medial and lateral arcuate ligaments (lumbocostal arches) also attach, and to the fifth the iliolumbar ligament. Posteriorly the transverse processes are covered by deep dorsal muscles; fibres of longissimus thoracis are attached to them. To their upper and lower borders the lateral intertransverse muscles are attached. The mamillary process, homologous with the superior tubercle of the twelfth thoracic vertebra, gives attachment to multifidus and the medial intertransverse muscle. To the accessory process, which is sometimes difficult to identify, is attached the medial intertransverse muscle. The costal element is incorporated in the mature transverse process. (For a discussion of homologies of all three processes consult Jones 1912.)

Colour coding of muscle attachments. The structural/functional ideas implicit in the traditional terms 'origin' and 'insertion' applied to muscle attachments do not accord with modern myokinetics; the latter envisages many more complex and flexible responses (p. 788). Nevertheless, some introductory and practical courses retain the terms, and the delineation of *all* muscle attachments by a single colour has proved an impediment to occasional groups of students. Some trunk muscles and those of the girdles and free limbs have, in this edition, a dual colour code; this facilitates their separate recognition. The axial, paraxial, or medial attachments of free limb muscles are delineated in *blue* (the historical 'insertion'). In contrast, on a series of diagrams of the skull, multiple colour coding is used to group muscles in terms of their embryological origin and nerve supply. Above comments on red and blue lines apply in most instances; occasional exceptions may be noted in a minority of individual muscles and bones.

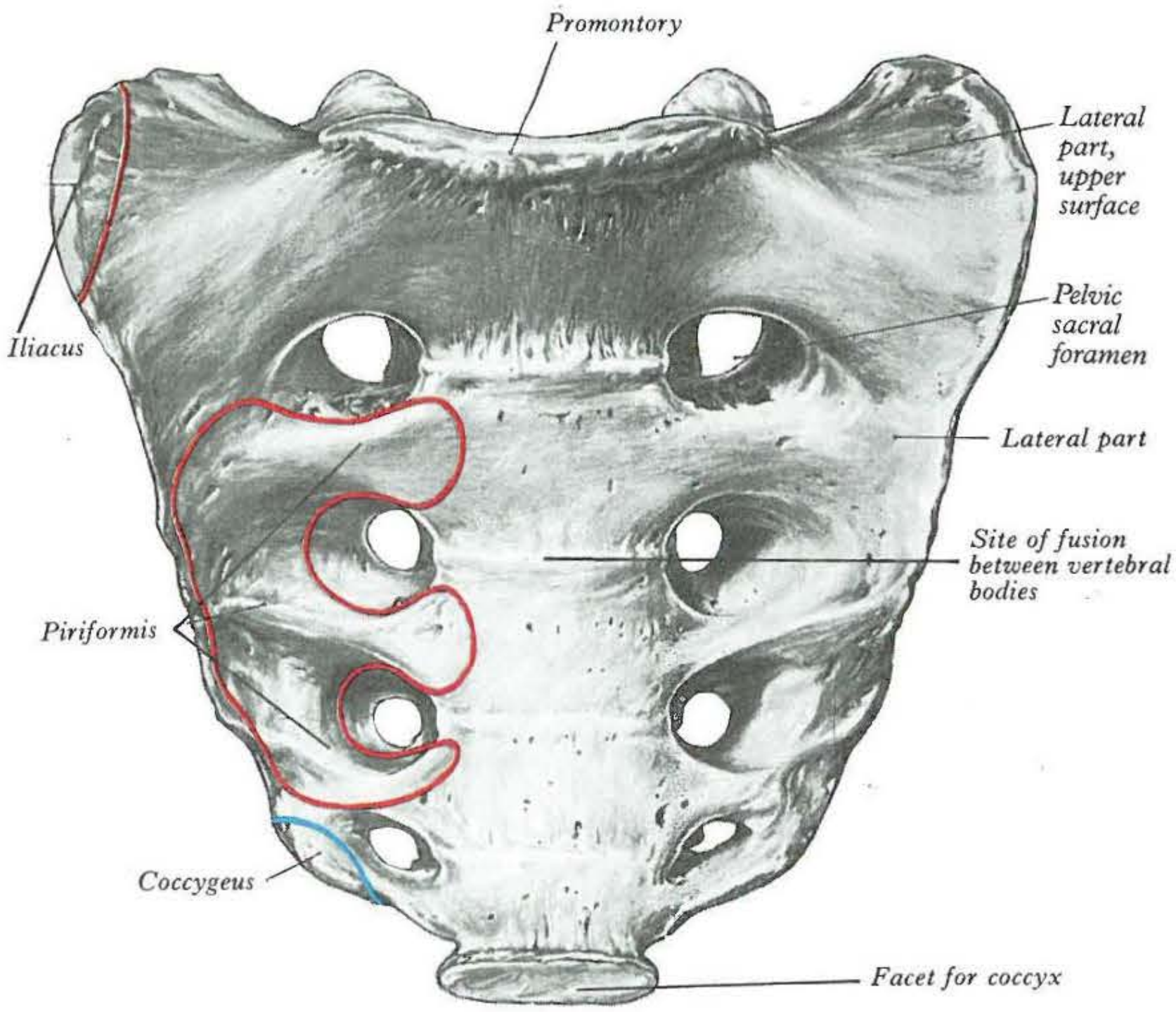

6.111A. Pelvic surface.

Clinical anatomy. The various methods of estimating the diameter of the lumbar vertebral canal, which is sometimes subject to stenosis, have been reviewed by Amonoo-Kuofi (1982), who considers radiographic estimation of interpedicular dimensions to be a reliable technique: racial variation has been found to occur in the sagittal dimension of the canal (Amonoo-Kuofi 1985).

SACRUM

The sacrum (**6**.111–113) is a large, triangular fusion of five vertebrae and forms the posterosuperior wall of the pelvic cavity, wedged between the two innominate bones. Its blunted, caudal *apex* articulates with the coccyx and its superior, wide *base* with the fifth lumbar vertebra at the *lumbosacral angle.* It is set obliquely and curved longitudinally, its dorsal surface being convex, the pelvic concave (**6**.111c). This ventral curvature increases pelvic capacity. Between base and apex are *dorsal, pelvic* and *lateral* surfaces and a *sacral canal.* In childhood, individual sacral vertebrae are connected by cartilage and separable by maceration; the adult bone also retains many vertebral features.

Base (**6**.112). This is the upper surface of the *first sacral vertebra,* the least modified from the typical vertebral plan. The *body* is large and wider transversely, its anterior projecting edge is the *sacral promontory.* The vertebral foramen is triangular, its *pedicles* being short and divergent posterolaterally. The *laminae* are oblique, inclining down posteromedially to meet at a *spinous tubercle.* The *superior articular processes* project cranially, with concave articular facets directed posteromedially to articulate with inferior articular processes of the fifth lumbar vertebra. The posterior part of each process projects, bearing laterally a rough area homologous with a lumbar mamillary process. The *transverse process* is much modified; a broad, sloping mass projects laterally from the body, pedicle and superior articular process (**6**.112)—a unique feature, although foreshadowed in the fifth lumbar. It consists of transverse process and costal element fused together and to the rest of the vertebra, forming the superior part of the sacral *lateral mass* or *ala.*

Pelvic surface (**6**.111A). Anteroinferior, it is vertically and transversely concave, but the second sacral body may produce a convexity. Four pairs of *pelvic sacral foramina* communicate through intervertebral foramina with the sacral canal, transmitting ventral rami of the upper four sacral spinal nerves. The large area between right and left foramina, formed by flat pelvic aspects of the sacral bodies, shows their fusion by four *transverse ridges.* The bars between foramina are *costal elements,* fused to the vertebrae. Lateral to the foramina the costal elements unite together and posteriorly with transverse processes to form the *lateral part* of the sacrum (which expands basally as the ala).

The pelvic surface gives attachment to the piriformes (**6**.111A). Emerging from the pelvic sacral foramina the first three sacral ventral rami pass anterior to piriformis. Medial to the foramina the sympathetic trunks descend in contact with bone, as do the median sacral vessels in the midline. Lateral to the foramina lateral sacral

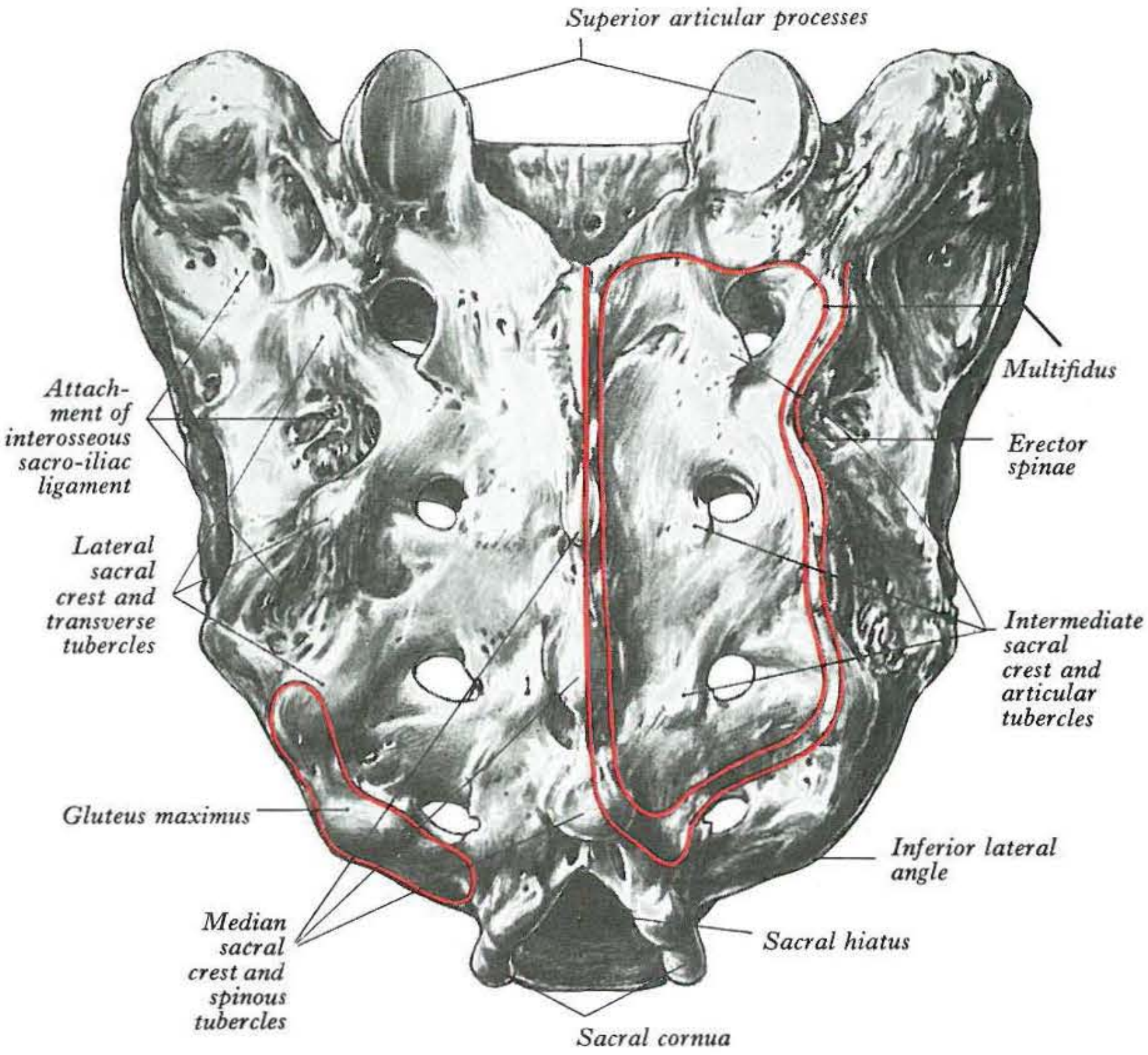

6.111B. Dorsal surface of the sacrum.

vessels are related to bone. Ventral surfaces of the first, second and partly third sacral bodies are covered by parietal peritoneum and crossed obliquely, left of the midline, by the attachment of the sigmoid mesocolon. The rectum is in contact with the pelvic surfaces of the third to fifth sacral vertebrae and with the superior rectal artery's bifurcation between the rectum and third sacral vertebra.

Dorsal surface (**6**.111B). Convex and posterosuperior, it has a raised, interrupted, *median sacral crest* with four (sometimes three) spinous tubercles representing fused sacral spines. Below the fourth (or third) an arched *sacral hiatus* in the posterior wall of the sacral canal, due to failure of the fifth pair of laminae to meet, exposes the dorsal surface of the fifth body. Flanking the median crest the posterior surface is formed by fused laminae and lateral to this are four pairs of *dorsal sacral foramina.* Like the pelvic foramina they lead into the sacral canal through intervertebral foramina; each transmits the dorsal ramus of a sacral spinal nerve. **Medial** to the foramina, and vertically below each articular process of the first sacral, is a row of four small tubercles, collectively the *intermediate sacral crest*; these, sometimes termed *articular*, represent fused articular processes. The fifth inferior articular processes project caudally and flank the sacral hiatus as *sacral cornua*, connected to coccygeal cornua by intercornual ligaments. **Lateral** to the dorsal sacral foramina is a *lateral sacral crest* formed by fused transverse processes, whose apices appear as a row of *transverse tubercles.*

The dorsal surface gives attachment to erector spinae by an elongated U-shaped area of spinous and transverse tubercles, covering multifidus which occupies the enclosed area (**6**.111B). The upper three sacral spinal dorsal rami pierce these muscles as they emerge via dorsal foramina.

Lateral surface (**6**.111C). This is a fusion of transverse processes and costal elements: wide above, it rapidly narrows in its lower part. The broad, upper part bears an *auricular surface* for articulation with the ilium, the area posterior to this being rough and deeply pitted by attachment of ligaments. The auricular surface, borne by costal elements, is like an inverted letter L. The shorter, cranial limb is restricted to the first sacral vertebra, the caudal descending to the middle of the third. Beyond this the lateral surface is non-articular and reduced in breadth. Caudally it curves medially to the body of the fifth sacral vertebra at the *inferior lateral angle*, beyond which the surface becomes a thin lateral border. A variable *accessory* sacral articular facet sometimes occurs.

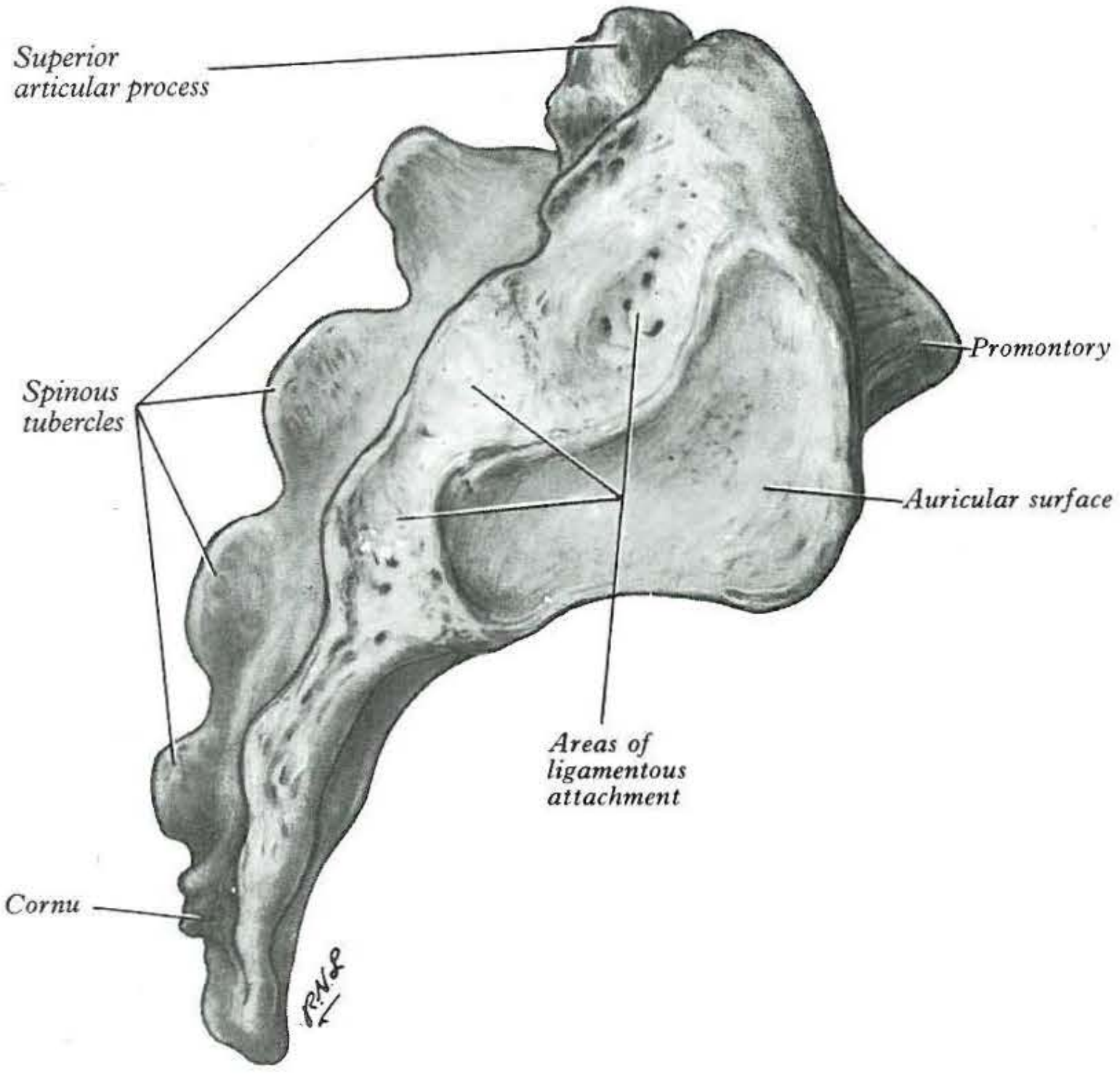

6.111C. Right lateral aspect of the sacrum.

The auricular surface is covered by hyaline cartilage, and formed entirely by costal elements. It shows cranial and caudal elevations and an intermediate depression, posterior to which, in the elderly, is

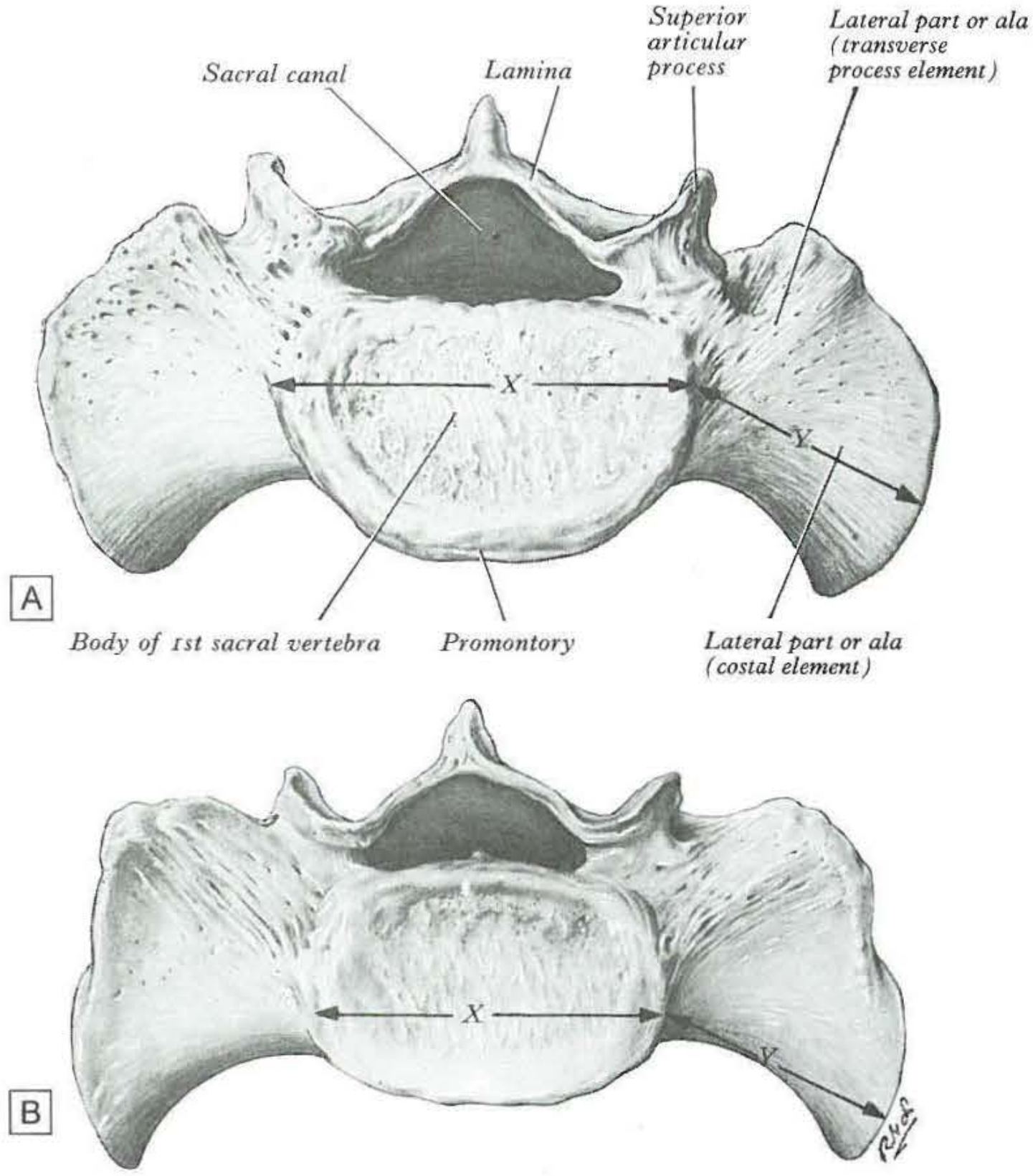

6.112 Base of the sacrum in the male (A) and in the female (B). The body of the first segment (*x*) forms a larger part of the breadth of the base in the male than it does in the female. In the latter the body is relatively smaller and the lateral, costal part (*Y*), the ala, is relatively broader.

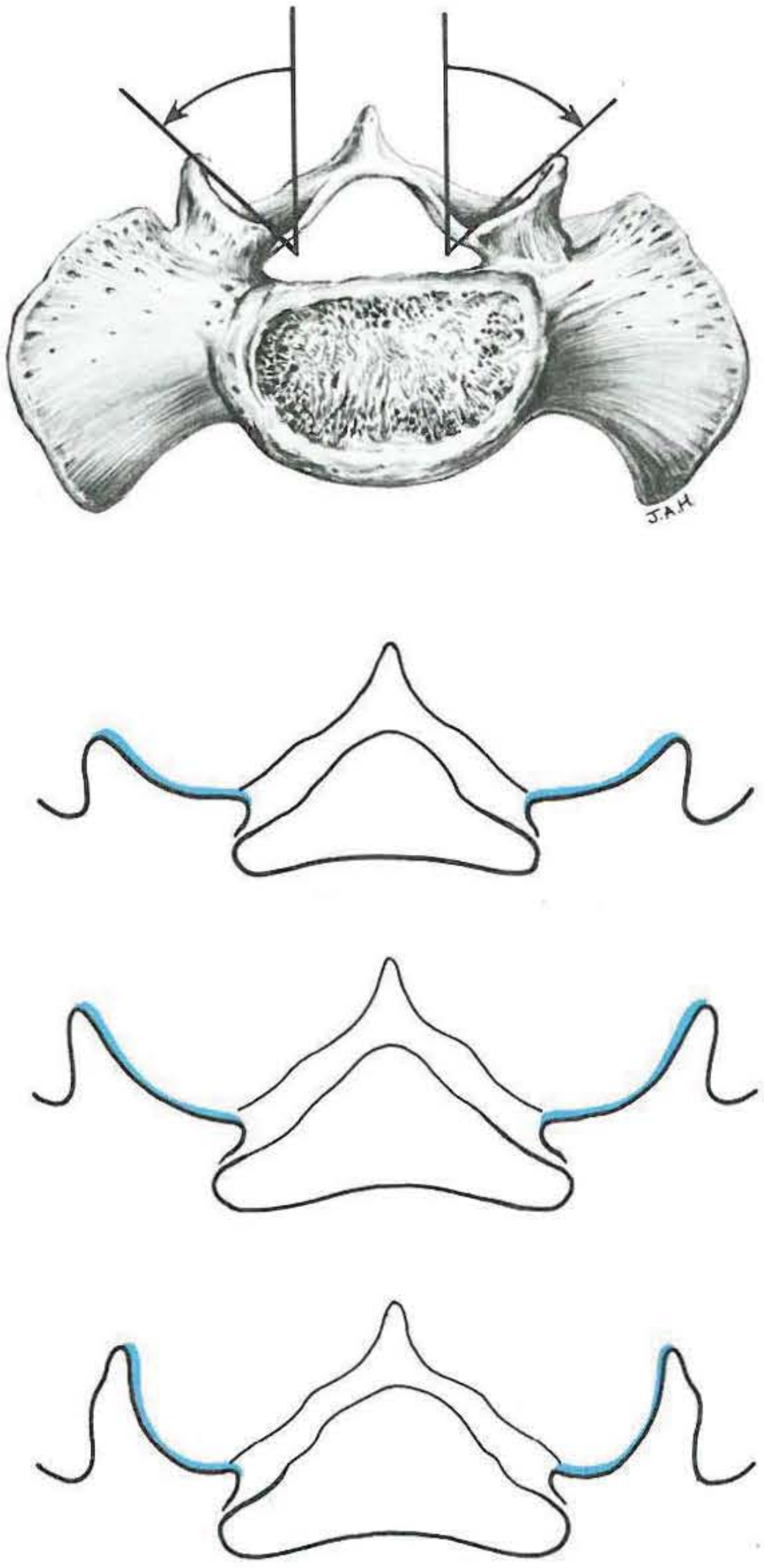

6.114 The method employed by Čihák (1970) to measure the inclinations of articular surfaces of the lumbosacral zygapophyseal joints (above). The lower profiles depict three degrees of increasing curvature and inclination. For quantitative data derived from 132 human sacra consult the original paper.

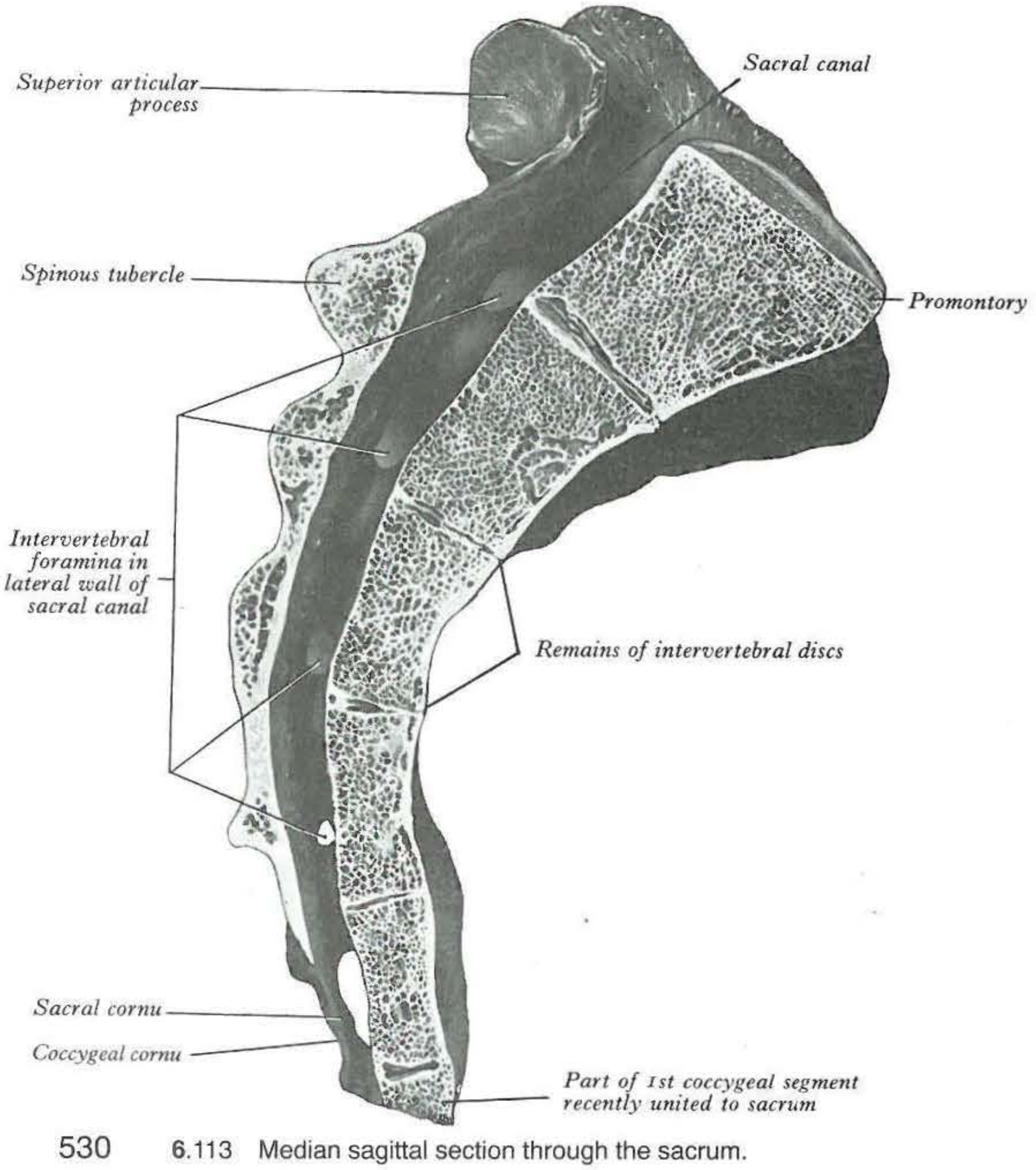

6.113 Median sagittal section through the sacrum.

a third elevation. The rough area behind the auricular surface shows two or three marked depressions for attachment of strong interosseous sacroiliac ligaments. Below the auricular surface are attached gluteus maximus, the sacrotuberous and sacrospinous ligaments and coccygeus, from behind forwards.

Sacral apex. The inferior aspect of the fifth sacral vertebral body, it bears an oval facet for articulation with the coccyx.

Sacral canal (**6**.113). Formed by sacral vertebral foramina, it is triangular in section. Its upper, basal opening is oblique but, owing to sacral inclination, is directed cranially in the standing position. Each lateral wall presents four intervertebral foramina, through which it is continuous with pelvic and dorsal sacral foramina. Its caudal opening is the *sacral hiatus*.

The sacral canal. This contains the cauda equina (including its filum terminale) and spinal meninges. Near its midlevel subarachnoid and subdural spaces cease and lower sacral spinal roots and filum terminale pierce the arachnoid and dura maters. The filum terminale emerges at the sacral hiatus and traverses the dorsal surface of the fifth sacral vertebra and sacrococcygeal joint to reach the coccyx. The fifth sacral spinal nerves also emerge through the hiatus medial to the sacral cornua, grooving the lateral aspects of the fifth sacral vertebra.

Attachments of the first sacral body. To the ventral and dorsal surfaces of the first sacral body are attached terminal fibres of the anterior and posterior longitudinal ligaments. Its upper laminar borders receive the lowest pair of ligamenta flava. Superiorly the ala is smooth, medially concave and laterally rough. It is covered almost entirely by psoas major. The smooth area is obliquely grooved by the lumbosacral trunk. The rough area is for the lower band of the iliolumbar ligament, lateral to the fifth lumbar spinal nerve and to the anterior sacroiliac ligament. Iliacus reaches the anterolateral part of this area (**6.111A**).

Sex differences in sacra. Typical male or female sacra are easily identified but sexual differences are not always marked; identification is sometimes difficult. The female sacrum is shorter and wider, producing a wider pelvic cavity. Sacral width, as a percentage of length, yields a *sacral index*. The loci used in making these measurements are discussed on p. 671. The ventral concavity is deeper in females and its deepest point is usually higher than in males; curvature above this point is greater in the female. The dorsal protrusion of the second sacral vertebra (p. 674) is therefore usually less prominent in males. In females the pelvic surface faces downwards more than in males, increasing the pelvic cavity and making the lumbosacral angle more prominent. The female auricular surface is shorter but in both sexes usually extends along the first three sacral vertebrae. Owing to the great size of the fifth **lumbar** body, the first **sacral** body occupies a larger proportion of the sacral base in the male, its transverse diameter exceeding the length of an ala; the female dimensions are roughly equal.

Structure. The sacrum consists of trabecular bone enveloped by a shell of compact bone of variable thickness.

Variations. The sacrum may contain six vertebrae, by development of an additional sacral element or by incorporation of the fifth lumbar or first coccygeal vertebrae. Inclusion of the fifth lumbar (*sacralization*) is usually incomplete and limited to one side. In the most minor degree of the abnormality a fifth lumbar transverse process is large and articulates, sometimes by a synovial joint, with the sacrum at the posterolateral angle of its base. Reduction of sacral constituents is less common but *lumbarization* of the first sacral vertebra occurs; it remains partially or completely separate. The dorsal wall of the sacral canal may be variably deficient, due to imperfect development of laminae and spines. Orientation of the superior sacral articular facets (and hence the relation between the planes of the two zygapophyseal lumbosacral joints) displays wide variation according to Čihák (1970): the chords of the concave sacral facets formed an angle with the sagittal plane varying from 20° to 90° in 132 sacra, the majority between 40° and 60° (**6.114**). Curvatures of the facets and their degree of asymmetry also varied.

LUMBOSACRAL JOINTS

Articulations between the fifth lumbar and first sacral vertebrae resemble those of others. Their bodies are united by a symphysis including a large intervertebral disc, deeper anteriorly at the lumbosacral angle with anterior and posterior longitudinal ligaments adherent to it. Their zygapophyseal joints are separated by a wider interval than those above. They have ligamenta flava, interspinous and supraspinous ligaments. The fifth lumbar vertebra is attached to the ilium and sacrum by the iliolumbar ligament. These joints vary much in geometry (p. 528; **6.114**).

Iliolumbar ligament (**6.278**). It is attached to the tip and anteroinferior aspect of the fifth lumbar transverse process, and sometimes has a weak attachment to the fourth. It radiates laterally and is attached by main bands to the pelvis: a lower one, the *lumbosacral ligament*, from the inferior aspect of the fifth lumbar transverse process to the anterosuperior lateral surface of the sacrum, blending with the anterior sacroiliac ligament; and an upper, partial attachment of quadratus lumborum, passing to the iliac crest anterior to the sacroiliac joint, continuous above with the thoracolumbar fascia. Innervation is from dorsal divisions of spinal nerves.

COCCYX

The coccyx (**6.115**), a small triangular bone, usually consists of four fused rudimentary vertebrae but the number varies from five to three, the first sometimes being separate. It descends ventrally from the sacral apex, its pelvic surface being tilted upwards and forwards, its dorsum downwards and backwards. Orientation varies, of course, with its mobility.

The *base*, or upper surface of the *first coccygeal vertebral body*, has an oval, articular facet for the sacral apex. Posterolateral to this, two *coccygeal cornua* project upwards to articulate with sacral cornua; they are homologues of pedicles and superior articular processes of other vertebrae. A rudimentary *transverse process* projects superolaterally from each side of the first coccygeal body and may articulate or fuse with the inferolateral sacral angle, completing the fifth sacral foramina.

The *second* to *fourth coccygeal vertebrae* diminish in size and are usually mere fused nodules, representing rudimentary vertebral bodies, though the second may show traces of transverse processes and pedicles.

Laterally on the *pelvic surface* and including the rudimentary transverse processes, the levatores ani and coccygei are attached, as is the anterior sacrococcygeal ligament, to the front of the first and sometimes second coccygeal vertebral bodies (**6.278**), and to the *cornua* the intercornual ligaments. The gap between fifth sacral body and articulating cornua represents, on each side, an intervertebral foramen, transmitting the fifth sacral spinal nerve, whose dorsal ramus descends behind the rudimentary transverse process, its ventral ramus passing anterolaterally between the transverse process and sacrum with, laterally, the lateral sacrococcygeal ligament which connects the process to the inferolateral sacral angle. To the *dorsal surface* are attached the glutei maximi, at its tip the sphincter ani externus, and in its median area the deep and superficial posterior sacrococcygeal ligaments, the superficial descending from the margins of the sacral hiatus and sometimes closing the sacral canal. The filum terminale, between the two ligaments, blends with them on the dorsum of the first coccygeal vertebra.

SACROCOCCYGEAL JOINT

The sacrococcygeal joint is a symphysis between the sacral apex and

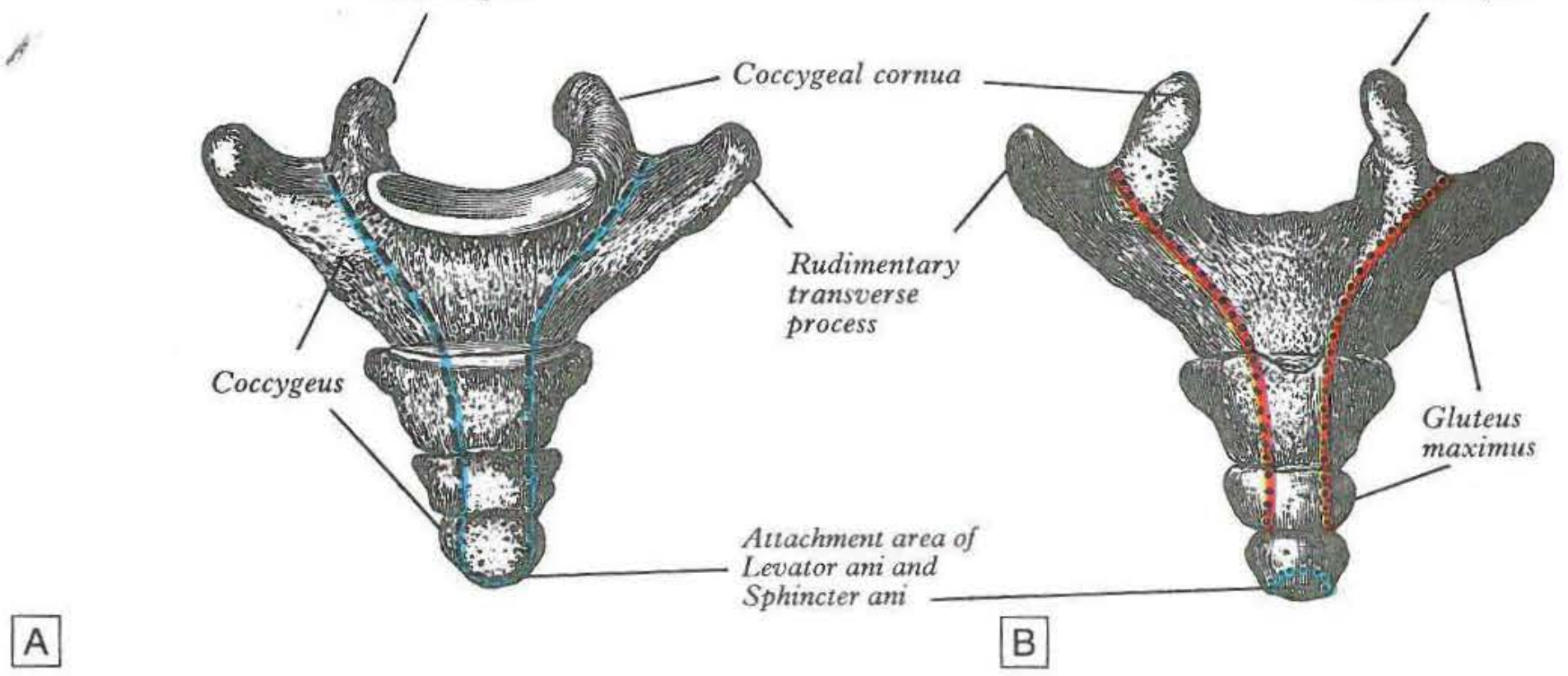

6.115 The coccyx: A. Pelvic aspect; B. Dorsal aspect.

coccygeal base, united by a fibrocartilaginous disc, remnants of hyaline cartilage and anterior, posterior and lateral ligaments.

Fibrocartilage disc. A thin disc between contiguous surfaces of the sacrum and coccyx, somewhat thicker in front and behind than laterally. Its surfaces carry hyaline cartilage varying from thin veils to small islands. Occasionally the coccyx is more mobile, the joint being synovial.

The anterior sacrococcygeal ligament (**6**.278). Consisting of irregular fibres descending on the pelvic surfaces of both sacrum and coccyx, it is attached like the anterior longitudinal ligament.

The superior posterior sacrococcygeal ligament. It is flat and passes from the margin of the sacral hiatus to the dorsal coccygeal surface (**6**.265), roofing the lower sacral canal.

The deep dorsal sacrococcygeal ligament. Passing from the back of the fifth sacral vertebral body to the dorsum of the coccyx, it corresponds to the posterior longitudinal ligament.

A lateral sacrococcygeal ligament. This is on each side, like an intertransverse ligament. It connects a coccygeal transverse process to an inferolateral sacral angle, completing a foramen for the fifth sacral spinal nerve.

The intercornual ligaments. These connect sacral and coccygeal cornua on each side. A fasciculus also connects the sacral cornua to the coccygeal transverse processes.

INTERCOCCYGEAL JOINTS

The intercoccygeal joints are symphyses, with thin discs of fibrocartilage, between coccygeal segments in the young. Segments are also connected by extension of the anterior and posterior sacrococcygeal ligaments. In adult males all segments are united comparatively early but in females union is later. In advanced age the sacrococcygeal joint is obliterated. Occasionally the joint between the first and second segments is synovial; the apex of the terminal segment is connected to overlying skin by white fibrous tissue.

OSSIFICATION OF THE VERTEBRAL COLUMN

For earlier stages of vertebral development consult page 265 and **3**.134. A typical vertebra is ossified from three primary centres (**6**.116A), one in each half vertebral arch and one in the centrum. Centres in arches appear at the roots of the transverse processes, ossification spreading backwards into laminae and spines, forwards into pedicles and posterolateral parts of the body, laterally into transverse processes and upwards and downwards into articular processes. Classically centres in *vertebral arches* are said to appear first in upper cervical vertebrae in the ninth to tenth week, and then in successively lower vertebrae, reaching lower lumbar levels in the twelfth week. However, in a radiographic study of unsexed human fetuses, of which 33 were of appropriate age (Bagnall et al 1977a, b), a pattern was noted differing from such a simple craniocaudal sequence. A regular cervical progression was not observed. Centres first appeared in the lower cervical/upper thoracic region, quickly followed by others in the upper cervical region. After a short interval a third group appeared in the lower thoracolumbar region and remaining centres then appeared, spreading regularly and rapidly in craniocaudal directions. The body's major part, the *centrum*, ossifies from a primary centre dorsal to the notochord. (Centra are occasionally ossified from *bilateral* centres which may fail to unite. Suppression of one of these produces a *cuneiform vertebra*, a recognized cause of lateral spinal curvature (scoliosis). The condition is frequently multiple.) This centre first appears at lower thoracic levels in the ninth to tenth week, spreading craniocaudally and reaching the second cervical vertebra in the twelfth week. In the study by Bagnall et al (1977) these events were largely confirmed, but the earliest centres were in lower thoracic **and** upper lumbar regions; cranial progression was rather faster than caudal, the last centre being in the fifth sacral vertebra. (For the later and erratic ossification of the coccyx see below.) During early postnatal years the centrum is connected to each half neural arch by a synchondrosis or *neurocentral joint.* In thoracic vertebrae costal facets on bodies are **posterior** to neurocentral joints. At birth a vertebra consists of three ossifying elements, a centrum and two half arches, united by cartilage. During the first year the arches unite behind, first in the lumbar region and then through thoracic and cervical regions. In upper cervical vertebrae centra unite with arches about the third year, but in lower lumbar vertebrae union is not complete until the sixth. Until puberty the upper and lower surfaces of bodies and apices of transverse and spinous processes are cartilaginous but now *five secondary centres* appear, one in the apex of each transverse and spinous process and two annular epiphyseal 'rings' for circumferential parts of upper and lower surfaces of the body (**6**.116B, C). Costal articular facets are extensions of the annular epiphyses (Dixon 1920). These epiphyses fuse with the rest of the bone at about 25 years. In bifid cervical spinous processes there are two secondary centres. The annular 'epiphyses' of vertebrae probably cannot be equated with epiphyses of long bones. In most mammals they are complete osseous discs. For discussion consult François and Dhem (1974).

Sexual dimorphism in vertebrae has received little attention, but Taylor and Twomey (1984) have described radiological differences in adolescent humans, female vertebral bodies having a lower ratio of width to depth.

Exceptions to this pattern of ossification occur in the first, second and seventh cervical and in lumbar vertebrae.

Atlas. This is commonly ossified from three centres (**6**.116D): one in each lateral mass at about the seventh week, gradually extending into the posterior arch where they unite between the third and fourth years, directly or occasionally through a separate centre. At birth, the anterior arch is fibrocartilaginous; here a separate centre appears about the end of the first year, uniting with the lateral masses between the sixth and eighth, the lines of union extending across anterior parts of the superior articular facets. Occasionally the

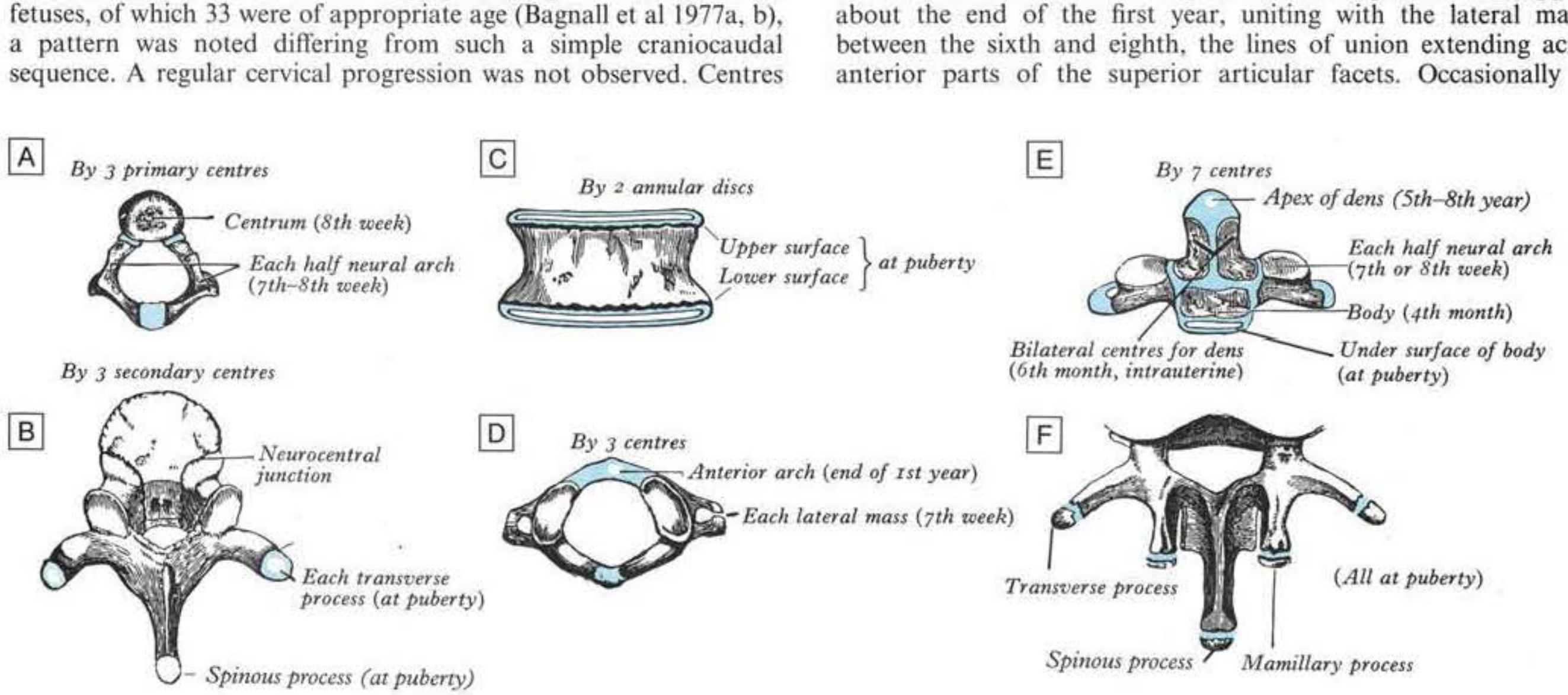

6.116 Ossification of the vertebral column. A. Typical vertebra. B. Typical vertebra at puberty. C. Body of a typical vertebra at puberty. D. The atlas. E. The axis. F. Lumbar vertebra. For further details consult text.

anterior arch is formed by extension and ultimate union of centres in the lateral masses, sometimes from two lateral centres in the arch itself.

Axis. This is ossified from five primary and two secondary centres (6.116E), the vertebral arch from two primary, the centrum from one, as in a typical vertebra. The former appear about the seventh or eighth week, that for the centrum about the fourth or fifth month. The dens is largely ossified from bilateral centres, appearing about the sixth month and joining before birth to form a conical mass, deeply cleft above by cartilage. This cuneiform cartilage forms the apex of the odontoid process and in it a centre appears, which shows considerable individual variation in both time of appearance and time of fusion to the rest of the dens: it most often appears between five and eight years, but sometimes even later (Ogden 1984), fusing with the main mass about the twelfth year. It has been widely regarded as a part of the cranial sclerotomal half of the first cervical segment or pro-atlas (Gadow 1933), but see below. The dens is separated from the body by a cartilaginous disc, the circumference of which ossifies while its centre remains cartilaginous until old age; in the disc possible rudiments of adjacent epiphyses of atlas and axis may occur. A thin epiphyseal plate is formed inferior to the body around puberty. The dens has long been considered the atlantal centrum, secondarily fused with the axis. This view was undermined by studies in a variety of mammals by Jenkins (1969), who regarded the dens as a new formation. Ganguly and Singh-Roy (1965) consider the apical centre for the dens as derived from the pro-atlas, which may also contribute to lateral atlantal masses.

Some observers regard the dens as the centrum of the pro-atlas.

Seventh cervical vertebra. In this vertebra separate centres for its costal processes appear about the sixth month and join the body and transverse processes between the fifth and sixth years; they may remain separate and grow anterolaterally as cervical ribs (p. 518). Separate ossific centres may, on occasion, also occur in the costal processes of the fourth to sixth cervical vertebrae.

Lumbar vertebrae (6.116F). These have two additional centres for mamillary processes. In the fifth lumbar a pair of scale-like epiphyses usually appear on the tips of costal elements.

Sacrum (6.117). This resembles typical vertebrae in the ossification of its segments. Primary centres for the centrum and each half vertebral arch appear between the tenth and twentieth weeks. Primary centres for costal elements of the upper three or more segments appear superolateral to the pelvic sacral foramina, between the sixth and eighth prenatal months. Each costal element unites with its half vertebral arch between the second and fifth years, and the conjoined element so formed unites anteriorly with the centrum and posteriorly with its opposite fellow at about the eighth year. Thereafter the upper and lower surfaces of each sacral body are covered by an epiphyseal plate of hyaline cartilage separated by a fibrocartilaginous precursor of an intervertebral disc. Laterally, successive conjoined vertebral arches and costal elements are separated by hyaline cartilage; a cartilaginous epiphysis, sometimes divided into upper and lower parts, develops on each auricular and adjacent lateral surface. Soon after puberty the fused vertebral arches and costal elements of adjacent vertebrae begin to coalesce from below upwards. At the same time epiphyseal centres develop for:

- upper and lower surfaces of bodies
- spinous tubercles
- transverse tubercles and
- costal elements.

The costal epiphyseal centres appear at the lateral extremities of the hyaline cartilages **between** adjacent costal elements; two anterior and two posterior appear in each interval between first, second and third segments. Ossification spreads from these into the auricular epiphyseal plates. One costal epiphyseal centre appears anteriorly in each remaining interval; from these ossification spreads to the epiphyseal plate covering the lower lateral surface. Sacral bodies unite at their adjacent margins after the twentieth year, but the central mass and most of each intervertebral disc remain unossified up to or beyond middle life. Available information is based on few specimens (McKern & Stewart 1957; Fawcett 1907).

Coccyx. Each segment is ossified from one primary centre but the incidence and timing are uncertain. A centre in the first segment appears about birth and its cornua may soon ossify from separate centres. Remaining segments ossify at wide intervals up to the twentieth year or later. Segments slowly unite; union between the first and second is frequently delayed until 30 years. The coccyx often fuses with the sacrum in later decades, especially in females.

VERTEBRAL COLUMN AS A WHOLE

The structure of the vertebral column undergoes progressive change in the postnatal period, affecting its growth and morphology. This process continues in adulthood and leads eventually to decline in senescence. Vertebral column morphology is influenced **externally** by mechanical and environmental factors and **internally** by genetic, metabolic and hormonal factors. These all affect its ability to react to the dynamic forces of everyday life, such as compression, traction and shear. These dynamic forces can vary in magnitude and are much influenced by occupation, locomotion and posture (Nachemson 1963; Gracovetsky 1988).

The vertebral column comprises some 33 vertebral segments, each separated by a fibrocartilaginous intervertebral disc. Its function is to support the trunk and to protect the spinal cord. It lies in the general vertebrate plane, and is median and posterior in the body. Its total length in males is about 70 cm and in females about 60 cm. Individual regions of the column account for approximately 8% of overall body length for the cervical, 20% for the thoracic, 12% for the lumbar and 8% for the sacrococcygeal. Although the usual number of vertebrae is 7 cervical, 12 thoracic, 5 lumbar, 5 sacral and 4 coccygeal, this total is subject to frequent variability, with reports of a variation between 32 and 35 bones (Bergman et al 1988). The demarcation of groups by their morphological characteristics may be blurred: for example, there may be thoracic costal facets on the seventh cervical, giving it the appearance of an extra thoracic vertebra; lumbarlike articular processes may be found on the lowest thoracic vertebra; and the fifth lumbar vertebra may be wholly or partially incorporated into the sacrum. Thus, due to these changes

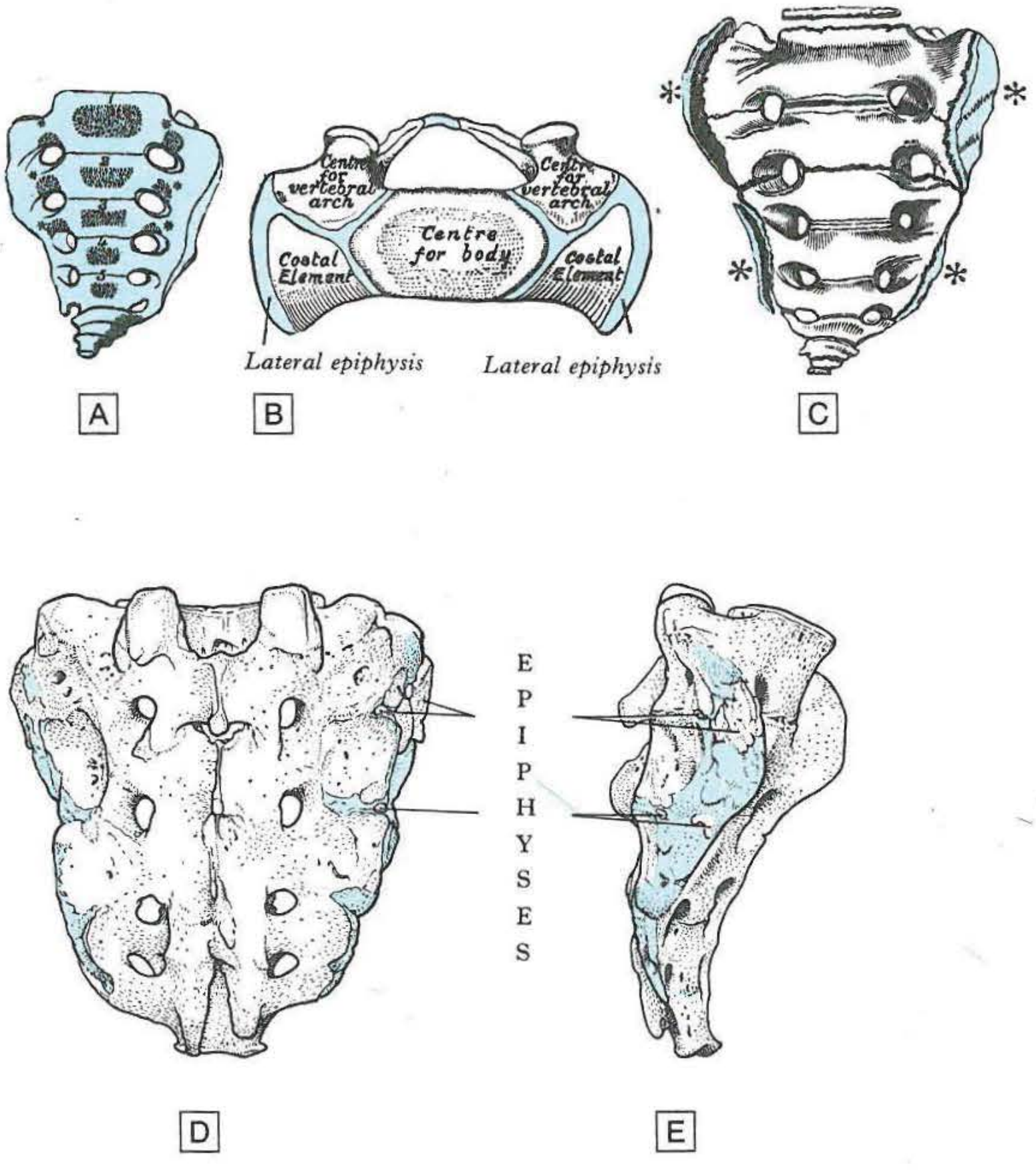

6.117 Ossification of the sacrum and coccyx: A. At birth; B. The base of the sacrum of a child of about four years of age; C. At the twenty-fifth year. In C The epiphyseal plates for each lateral surface are marked by asterisks. D, E. The epiphyses of the costal and transverse process of the sacrum at the eighteenth year.

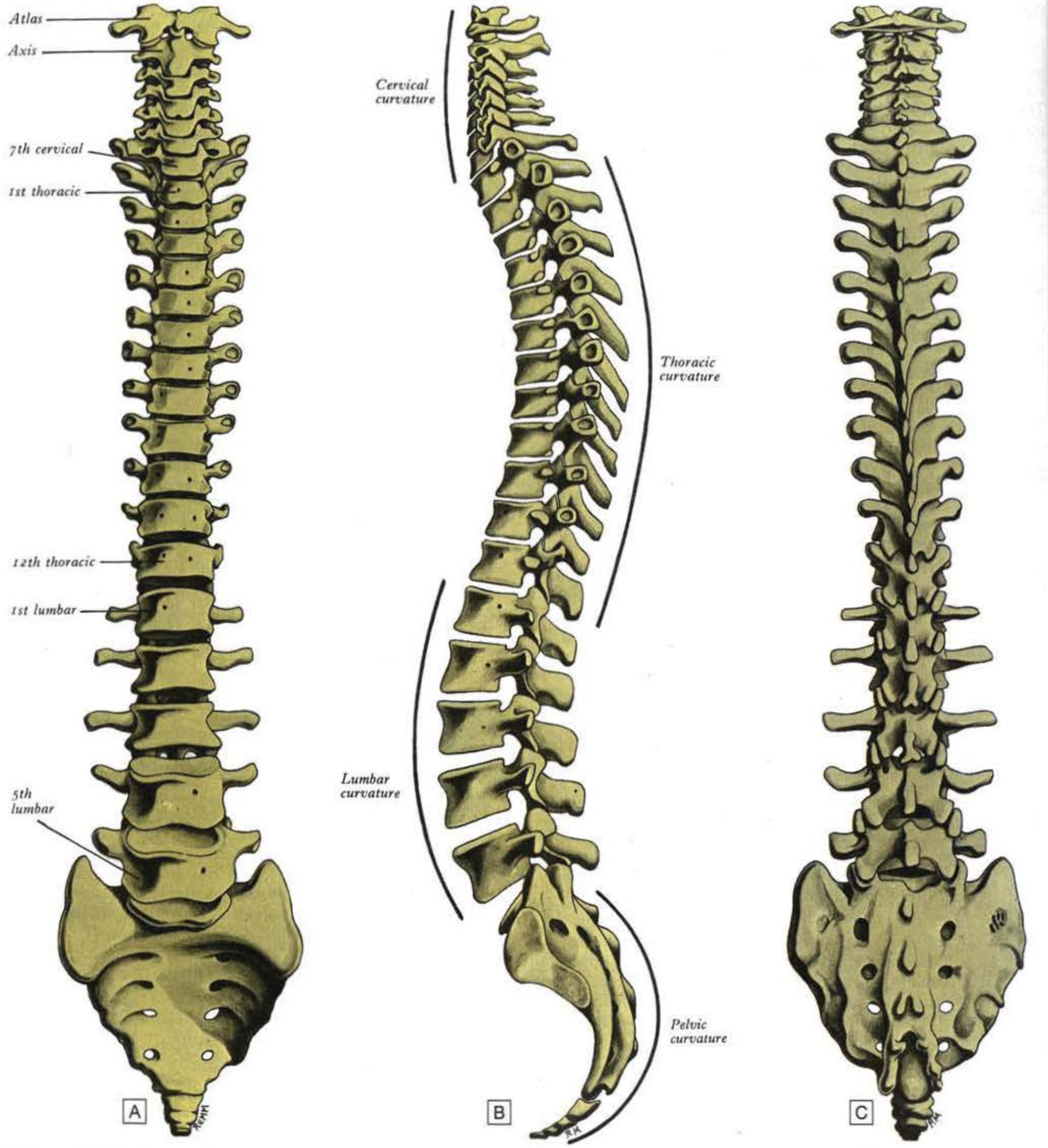

6.118 The vertebral column: A. Anterior aspect; B. Lateral aspect (note curvatures); C. Dorsal aspect. Note slight sinuous, lateral, thoracolumbar curvature visible from both dorsal and anterior aspects.

in transition between vertebral types, there may be 23–25 mobile presacral vertebrae.

The line of gravity of the vertebral column

The well-balanced, erect body has a line of gravity which extends from the level of the external auditory meatus, through the dens of the atlas, just anterior to the body of the second thoracic vertebra, through the centre of the body of the twelfth thoracic vertebra and through the rear of the body of the fifth lumbar vertebra to lie anterior to the sacrum.

Curvatures of the vertebral column

In the normal vertebral column, there are no lateral curvatures, but there are well-marked curvatures in the sagittal plane. However, in the upper thoracic region there is often a slight lateral curvature, convex to the right in right-handed persons, and left in left-handed. The sagittal curvatures are present in the cervical, thoracic, lumbar and pelvic regions (**6**.118, 119). Such curvatures are the result of three million years of evolution, in which rounding of the thorax and pelvis have developed as an adaptation to bipedal gait. Curvatures appear as a response to *fetal movements* as early as 7 weeks in utero,

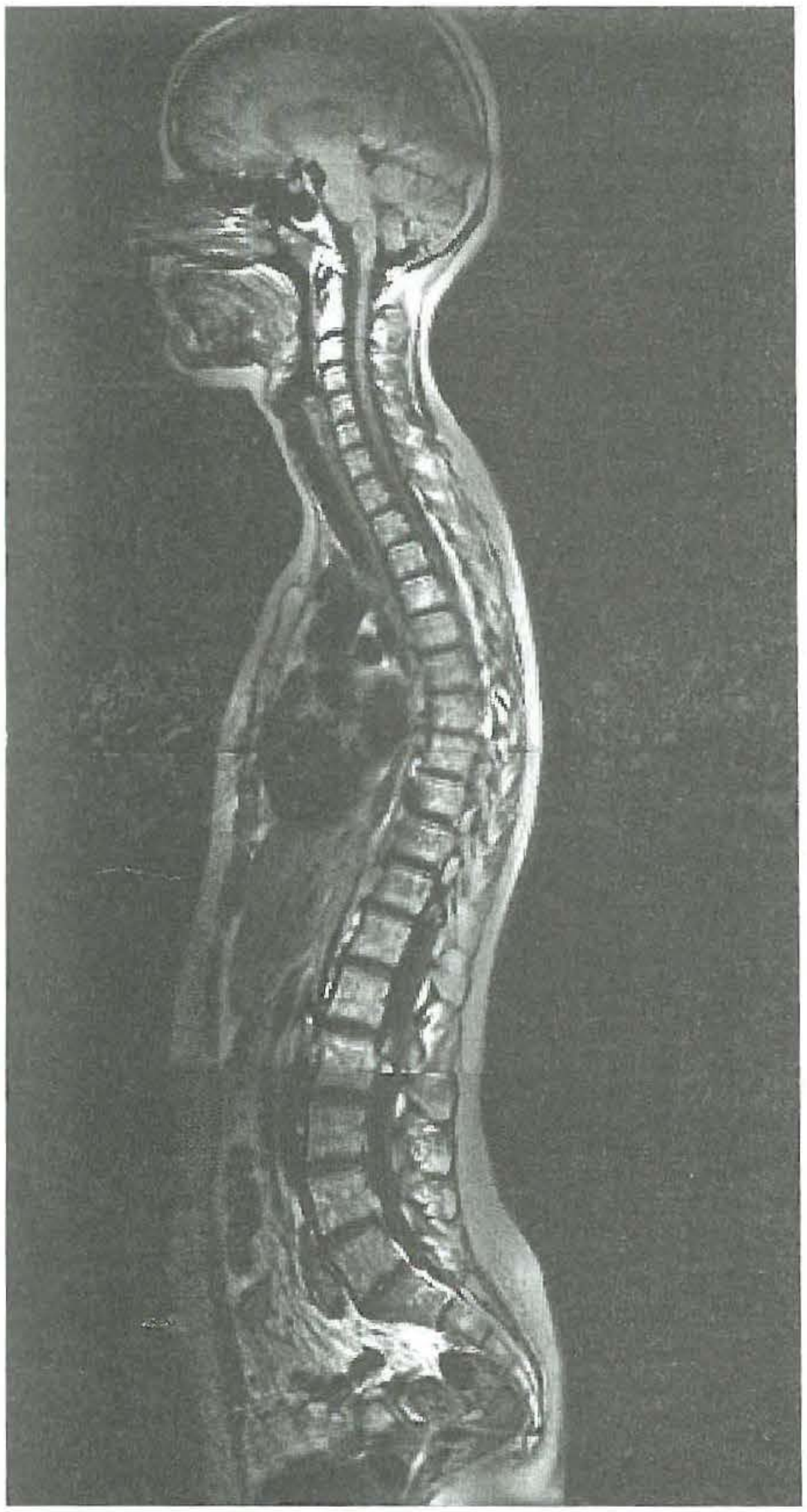

6.119 A composite T1-weighted midline sagittal magnetic resonance image of the vertebral column of a 27-year-old female. The subject had no history of back pain at the time of imaging but one year later suffered acute pain following the prolapse of the L4/5 intervertebral disc which had been identified as degenerate on a T2-weighted image obtained as part of a research study. (Image provided by Dr N Roberts, Magnetic Resonance Centre, University of Liverpool.)

and become more pronounced after birth when the baby begins to hold up his or her head. Although the embryo develops in flexion, resulting in *primary* thoracic and pelvic curves which are concave anteriorly, functional muscle development leads to the early appearance of *secondary* cervical and lumbar spinal curvatures in the sagittal plane.

The *cervical curvature* appears before birth, probably as early as the seventh week in utero, in response to fetal development of the muscles responsible for head extension, an important component of the 'gasp reflex' (Bagnall et al 1977). Radiographic study of 195 human fetuses aged from 8 to 23 weeks demonstrated the presence of secondary cervical curvature in 83% of the sample. Ultrasound investigations support the role of movement in the development of these curvatures. *Lumbar flattening* has also been identified as early as the eighth week (O'Rahilly et al 1980). However, the early appearance of these secondary curves is probably accentuated by postnatal muscular and nervous system development when the vertebral column is highly flexible and when it may assume almost any curvature (Wood-Jones 1946). An infant can support its head at about 3 or 4 months, sit upright at about 9 months, and will commence walking between 12 and 15 months. Such functional changes exert a major influence on the development of the secondary curvatures in the vertebral column and changes in the proportional size of the vertebrae, in particular in the lumbar region. The secondary *lumbar curvature* becomes important to maintain the centre of gravity of the trunk over the legs when walking commences, and thus changes in body proportions exert a major influence on the subsequent shape of curvatures in the vertebral column. Support for this view comes from recent research which has demonstrated that long-term training of monkeys aimed at stable upright posture resulted in marked lumbar lordosis, a feature which is comparable to the human condition both morphologically and functionally. The induced lordosis was retained even in normal pronograde posture of the monkeys: bone remodelling occurred in the postcranial skeleton, attributable to functional adaptation to stresses induced by sustained bipedalism.

In adults, the *cervical curve* is convex forwards and the least marked: this is a *lordosis*. It extends from the atlas to the second thoracic vertebra, with its apex between the fourth and fifth cervical vertebrae. Sexual dimorphism in the cervical curvatures has also been found (Knussman & Finke 1977).

The *thoracic curve* is *kyphotic*, i.e. concave forwards. It extends between the second and the eleventh and twelfth thoracic vertebrae, with its apex lying between the sixth and ninth thoracic vertebrae. This curvature is caused by the increased posterior depth of the thoracic vertebral bodies.

The *lumbar curve* is *lordotic*, i.e. convex forwards. It has a greater magnitude in females and extends from the twelfth thoracic vertebra to the lumbosacral angle, with an increased convexity of the last three segments due to greater anterior depth of intervertebral discs and some anterior wedging of the vertebral bodies. Its apex is at the level of the third lumbar vertebra.

The *pelvic curve* is concave anteroinferiorly and involves the sacrum and coccygeal vertebrae, extending from the lumbosacral junction to the apex of the coccyx.

Vertebral bodies

Viewed anteriorly there is a cephalocaudal **increase** in vertebral body width from the second cervical to the third lumbar vertebra, associated with increased weight-bearing. The increase is linear in the neck but not in the thoracic and lumbar regions. There is some variation in size of the last two lumbar bodies, but thereafter width diminishes rapidly to the coccygeal apex. In the two lowest lumbar vertebrae there is an inverse relation between the areas of the upper and lower surfaces of bodies and size of the pedicles and transverse processes, suggesting that the latter transmit some of the vertebral compressive forces from spine to pelvis (Davis 1961). They are also transitional towards the sacral region (Panjabi et al 1992). Vertebral diameter may be used as a basis for sex prediction as the posterior aspect of the body is less dimorphic than the anterior region (MacLaughlin & Oldale 1992).

Spinous processes

The spinous processes lie approximately in the median plane and project posteriorly, although in some individuals a minor deflection of the processes to one side may be seen. This deviation also occurs in fractures and dislocations and can be associated with congenital abnormalities of the vertebra. The third thoracic spinous process is level with the spine of the scapula, and the seventh with the inferior scapular angle when the arm is by the side. The fourth lumbar spine is level with the summits of the iliac crests (a point useful in lumbar puncture), and the second sacral spine with the posterior superior iliac spines.

Lateral to the vertebral spines, vertebral grooves contain the deep dorsal muscles: at cervical and lumbar levels these grooves are shallow and mainly formed by laminae; in the thoracic region they are deeper, broader and formed by both laminae and transverse processes. The laminae are broad for the first thoracic vertebra, narrower for the second to seventh, broadening again from the eighth to eleventh, but become narrow thereafter down to the third lumbar vertebra.

Transverse processes

Lateral to the laminae are articular processes, and, still more lateral, transverse processes. Cervical transverse processes are anterior to articular processes, lateral to pedicles and between the intervertebral foramina. In the thoracic region, they are posterior to the pedicles, considerably behind those of the cervical and lumbar processes. In the lumbar region, the processes are anterior to articular processes, but posterior to intervertebral foramina. There is considerable regional variation in structure and length of the transverse processes. In the cervical region, the atlantal transverse process is long and broad, allowing the rotator muscles maximum mechanical advantage. Breadth varies little from second to sixth cervical, but increases in the seventh. In thoracic vertebrae the first is widest, and breadth decreases to the twelfth, whose transverse elements are usually vestigial. In the upper three lumbar vertebrae, the transverse processes become broader, diminishing in the fourth and fifth. The transverse process of the fifth is the most robust and arises directly from the body and pedicle to allow for weight transference to the pelvis through the iliopelvic ligament.

Lateral aspect of the vertebral column

The lateral aspect of the vertebral column is arbitrarily separated from the posterior by articular processes in the cervical and lumbar regions and transverse processes in the thoracic. Anteriorly it is formed by the sides of vertebral bodies, with costal facets at thoracic levels. The intervertebral foramina, behind bodies and between pedicles, are oval, and smallest at cervical and upper thoracic levels increasing progressively in size in the thoracic and lumbar regions: they contain spinal and other nerves and various vessels.

Vertebral canal

The vertebral canal follows the vertebral curves. In the cervical and lumbar regions, which exhibit free mobility, it is large and triangular, but where movement is less, in the thoracic region, it is small and circular. These differences are matched by variations in the diameter of the spinal cord and its enlargements. In the lumbar region, the spinal canal has a gradual decrease in measurement between L1 and L5, with a greater relative width in the female. The lumbar canal/vertebral body ratio ranges between 1:2 and 1:5; any ratio greater than 1:5 would constitute lumbar vertebral canal stenosis.

Diurnal variation

In 1852, Bishop reported that body height was affected by changes from recumbency to upright posture. These diurnal variations appear to be due to changes that occur within the cervical, thoracic and lumbar spine. Recent investigations using stereophotogrammetry have demonstrated that 40% of diurnal changes occur in the thoracic spine, affecting the degree of kyphosis, and a further 40% in the lumbar spine, without affecting the lordosis (Wing et al 1992). The greatest change in vertebral column length has been found in adolescents and young adults (De Puky 1935). The height loss occurs within 3 hours of rising in the morning (Reilly et al 1984), with the overall loss being approximately 16 mm (Fitzgerald 1972; Krag et al 1990). Although the curvatures within the vertebral column contribute to these changes in height, the intervertebral disc is also likely to account for observed height loss. Recent magnetic resonance imaging (MRI) investigations reveal a dynamic movement of fluid into and out of both the intervertebral disc (**6**.120) and adjacent vertebral body over a 24-hour period (Roberts et al 1991, 1994). This is related to body position and could have profound implications for the biomechanics of the column when it is under axial compression (Dangerfield et al 1994).



6.120 Three MR images, enhanced after image processing, of intervertebral discs showing, from top to bottom, low water content at midnight = pale green, high water content in the morning after a night recumbent = dark blue, and an intermediate state in the afternoon. (Images provided by Dr N Roberts, Magnetic Resonance Research Centre, University of Liverpool.)

Growth of the vertebral column

At birth, the column is approximately 24 cm in length (Scammon & Calkins 1929). Its growth through childhood and adolescence to adulthood is influenced by sexual, hormonal, genetic, biomechanical and other factors, with variation in absolute and relative size of the individual component vertebrae (Falkner & Tanner 1986; Roche 1992).

The size of component parts of the vertebral column varies with age, with relatively smaller lumbar and sacral components in the neonate compared to the adult: this is due to cephalocaudal developmental gradients. These vertebrae, therefore, grow more to attain adult size. Different velocities of skeletal maturation (heterochrony) may also be determined by intrinsic bony mechanisms (Burwell et al 1980). The lumbar vertebrae have a threefold increase in body width and a fourfold increase in body height. These changes are determined genetically and display sexual dimorphism, with discrete and constant differences between the sexes being identified in anthropometric studies based on computerized tomography (CT) (Cooper et al 1992).

Changes in the mechanics of the lumbar region are potent factors in influencing growth changes in the proportions of vertebral bodies and intervertebral discs, especially in the fifth lumbar and the disc below it, and the shape of the lumbar curvature (Taylor 1975).

Vertebral column growth is due to the summation of growth of individual vertebrae; the length of the spine being a major component of overall stature. At birth the ossified component of the vertebra has the same height as the intervertebral cartilaginous component (Brandner 1970), becoming 75% of the total by adulthood. Growth in the vertebral column is due to *proliferative* changes in the cartilaginous end plates, similar to the epiphyseal cartilages of long bones. *Growth in height* occurs at the upper end after puberty and can still be identified in subjects in their midtwenties (Bernick & Caillet 1982). The annular tension apophysis takes no part in the growth of the body, with its ossification status having no relationship with vertebral growth, although its diameter keeps pace with the body. This is because it lies outside the plane of the epiphyseal growth plate.

The *neural arch processes* grow from *primary* centres by subperiosteal bone deposition and extension into the adjacent cartilage. At the tips of the transverse processes and spinous processes, traction epiphyses appear. The *facet joints* grow as a result of extension into the extra-articular zone of cartilage and subarticular growth. Changes in posture and body proportions alter the orientation of each articular surface (Roaf 1971).

Adolescent growth spurts within the vertebral column occur in both males and females, with sexual difference for the time of onset and the achievement of adulthood. The spurt occurs in males between ages 13 and 15 years, and in females between 9 and 13 years (Anderson et al 1965; Taylor & Twomey 1984). The female growth increment is 65% greater than the male between 9.5 and 12.5 years. Female vertebrae are also more slender than male.

Although growth in standing height is usually complete by 18 years in Caucasian girls and 20 years in males, evidence has been found to suggest that vertebral growth may continue well into adulthood: changes in the cartilaginous endplates of the vertebrae have been demonstrated in subjects in the midtwenties (Tanner et al 1966; Bernick & Caillet 1982). In male East Africans, changes in height of the lumbar vertebrae have been found at up to 45 years of age (Allbrook 1956).

Vertebral column in the elderly

In older people, age-related changes in the structure of bone lead to broadening and loss of height of the vertebral bodies, these changes being more severe in females. The bony changes in the vertebral column are accompanied by changes in the collagen content of the discs and by decline in the activity of spinal muscle dynamics. This leads to progressive decline in vertebral column mobility, particularly in the lumbar spine. Lumbar lordosis decreases as a result of increased loading, due to an increase in body weight. The development of a 'dowager's hump' in the midthoracic region in females, due to age-related osteoporosis, increases the thoracic kyphosis and cervical lordosis. Overall, these changes in the vertebral column lead directly to loss of total height in the individual.

Other changes affect the vertebral bodies. Osteophyte activity on the anterior and lateral surfaces of the bodies leads to spurs arising from the compact cortical bone. Although individual variations occur, these changes appear in most individuals from about 20 years onwards. They are most common on the anterior aspect of the body and appear to be related to movement, especially as their incidence is highest at C5, T8 and L3/4, regions where spinal movement is greatest (Nathan 1962). They never involve the ring epiphysis. Osteophytic spurs are frequently asymptomatic, but may result in diminished movements within the spine.

Movement of the vertebral column

Normal movements between adjacent vertebrae are limited, but they have a cumulative effect over the whole column, allowing a considerable degree of bending or rotation (p. 515). Although bony deformation in the subchondral bone and articular cartilage may contribute, the vertebral discs both tie vertebrae together and are the principal sites of vertebral column movement. By elastic deformability, they permit tilting and torsion between vertebral bodies, and they also add compressibility to the column. This ability to absorb stresses is augmented by the column's sinuous curvature: forces transmitted with little loss by a straight column are largely expended against the pliability of the spinal curves. Effects of weight, muscle activity and thrust from the feet, whether trivial (as in walking) or large (as in running and jumping), are smoothed out by the discs and curvatures.

Despite the prominent role of intervertebral discs in spinal dynamics, regional variations in mobility also depend on the disposition, properties and geometry of intervertebral synovial joints and ligamentous complexes attached to all parts of each vertebra (p. 515).

Articular trophism or asymmetrical orientation of the apophyseal joints results in the orientation of one joint becoming more inclined in the frontal or sagittal plane than the orientation of the contralateral joint. Trophism is present in up to 25% of human spines (Grieve 1989), occurring frequently in L4 and L5, and leads to imbalanced movement between the facets (Kraft & Levinthal 1951). This, in turn, may hasten degenerative damage.

Abnormalities of the vertebral column

Scoliosis is a term applied to abnormal lateral curvature of the spine, frequently accompanied by severe rotation of the vertebral bodies and torsions within the laminae and pedicles. Such abnormal curvatures may be postural or structural. Postural curvatures may result from the lower limbs being unequal in length: since these curves are non-structural, they should disappear when the inequality is corrected. Fixed structural curvatures can be due to congenital abnormalities of the vertebrae (e.g. hemivertebrae); they may be secondary to disease (such as poliomyelitis or muscular dystrophies), or they may be idiopathic. The causes of the latter have been attributed to growth and nervous system factors (Burwell & Dangerfield 1992).

In spondylolisthesis (present in 5% of skeletons) the spine, laminae and inferior articular processes of the fifth (and sometimes the fourth) lumbar vertebra are joined together but separate from the rest of the bone. The condition is probably congenital, the suggestion being that each half vertebral arch ossifies from two primary centres which fail to fuse. There is, however, no clear evidence for this.

Fractures to the column

Injury to the vertebral column may result from **five** different mechanisms: flexion, extension, rotation, shear and axial load. In forced flexion injury, such as a violent blow on the back, fractures usually occur at the fifth or sixth cervical vertebra. If the violence is transmitted axially, for example by a fall on to the feet or head, the injury is also a flexion fracture (because of the normal spinal curvature), often between the ninth thoracic and second lumbar. Vertebral stability is maintained by the disc-body complex and does not require an intact posterior ligament complex (Bedbrook 1971). This clinical observation has led to the biomechanical concept of the three-column theory for spinal stability (Dennis 1983). The anterior column is formed by the anterior longitudinal ligament, the anterior part of the vertebral body and the anterior annulus fibrosus. The middle column is made up of the posterior longitudinal ligament, the posterior wall of the vertebral body and the posterior annulus fibrosus; and the posterior column consists of the posterior body arch complex and the posterior ligamentous complex. This concept forms the basis of classification of vertebral column fractures (Dennis 1983).

STERNUM

The sternum is confined to land vertebrates, and aquatic mammals such as seals; it is absent in fish. The elongate human form is typical of mammals, the sternum being a plate, often composite, in amphibians and reptiles. Though associated with shoulder girdles and ribs from its earliest appearance, it is often considered axial. Its embryonic development and ossification indicate an origin separate from ribs. The human sternum (**6.121, 122**) consists of a cranial *manubrium* (prosternum), an intermediate *body* or mesosternum and a caudal *xiphoid process* (metasternum). Its total length in males is about 17 cm, less in females (Jit & Bakshi 1984). The ratio between manubrial and mesosternal lengths differs in the sexes, but racial differences have not been established. Such data are complicated by possible continuation of growth beyond the third decade and even throughout life (Ashley 1956; Rother et al 1975). In addition to the three major sections, the mesosternum in early life consists of four *sternebrae*, which from costal relations appear to be intersegmental. In natural stance the sternum slopes down and slightly forwards. It is convex in front, concave behind and broadest at the junction with the first costal cartilages, narrow at the manubriosternal joint, below which it widens to its articulation with the fifth cartilages, narrowing again below this.

Manubrium sterni. Broad and thick above, it narrows to its junction with the mesosternum. Its *anterior surface* is smooth, convex transversely, vertically concave. Its *posterior surface* is concave and smooth. The *superior border* is thick, with a central *jugular (suprasternal) notch* between two oval fossae directed up and posterolaterally for articulation with the sternal ends of the clavicles (*clavicular notches*). The *inferior border*, oval and rough, carries a thin layer of cartilage for articulation with the mesosternum. The *lateral borders* are marked above by a depression for the first costal cartilage and below by a small articular demifacet, which, with one on each superior mesosternal angle, articulates with part of the second costal cartilage. Between these facets the narrow curved edge descends medially.

Mesosternum (body). Longer, narrower and thinner than the manubrium, it is broadest near its lower end. Its *anterior surface*,