

Reprinted from SPINE, Vol. 23, No. 13, July 1, 1998
Copyright © 2000, Lippincott Williams & Wilkins
Printed in the U.S.A.

Minimally Invasive Anterior Retroperitoneal Approach to the Lumbar Spine

Emphasis on the Lateral BAK

Paul C. McAfee, MD, John J. Regan, MD, W. Peter Geis, MD,
and Ira L. Fedder, MD

MC0000005

■ Minimally Invasive Anterior Retroperitoneal Approach to the Lumbar Spine

Emphasis on the Lateral BAK

Paul C. McAfee, MD,* John J. Regan, MD,† W. Peter Geis, MD,‡
and Ira L. Fedder, MD*

Study Design. Eighteen patients with lumbar instability from fractures, postlaminectomy syndrome, or infection were treated prospectively with minimally invasive retroperitoneal lumbar fusions.

Objectives. To determine if interbody Bagby and Kuslich fusion cages and femoral allograft bone dowels can be inserted in a transverse direction via a lateral endoscopic retroperitoneal approach to achieve spinal stability.

Summary of Background Data. Endoscopic spinal approaches have been used to achieve lower lumbar fusion when instrumentation is placed through a laparoscopic, transperitoneal route. However, complications of using this approach include postoperative intra-abdominal adhesions, retrograde ejaculation, great vessel injury, and implant migration. This study is the first clinical series investigating the use of the lateral retroperitoneal minimally invasive approach for lumbar fusions from L1 to L5.

Methods. Eighteen patients underwent anterior interbody decompression and/or stabilization via endoscopic retroperitoneal approaches. In most cases, three 12-mm portals were used. Two parallel transverse interbody cages restored the neuroforaminal height and the desired amount of lumbar lordosis was achieved by inserting a larger anterior cage, distraction plug, or bone dowel.

Results. The overall morbidity of the procedure was lower than that associated with traditional "open" retroperitoneal or laparotomy techniques, with a mean length of hospital stay of 2.9 days (range, outpatient procedure to 6 days). The mean estimated intraoperative blood loss was 205 cc (range, 25-1000 cc). There were no cases of implant migration, significant subsidence, or pseudoarthrosis at mean follow-up examination of 24.3 months (range, 12-40 months) after surgery.

Conclusions. This preliminary study of 18 patients illustrates that endoscopic techniques can be applied effectively through a retroperitoneal approach with the patient in the lateral position. Unlike the patients who had undergone transperitoneal procedures described in previous reports, in these preliminary 18 patients, there were no cases of retrograde ejaculation, injury to the great vessels, or implant migration. [Key words: endoscopic retroperitoneal, minimally invasive retroperitoneal lumbar fusions, transverse axis BAK] *Spine* 1998; 23:1476-1484

The use of minimally invasive and endoscopic approaches has been described for multiple abdominal procedures, including cholecystectomy,^{29,31,32} appendectomy,²⁸ colon resection,¹² and Nissen fundoplication.³³ Recently, increased attention has been paid to the use of these approaches with lumbar discectomy^{2,5,26} and lumbar anterior interbody arthrodesis.^{1,4,8} Most endoscopic approaches described thus far have been transperitoneal and have depended on CO₂ insufflation to provide working space and to retract the small bowel out of the surgical field. Gaur⁶ and McDougall et al²⁴ were the first to describe retroperitoneoscopy, an endoscopic retroperitoneal approach for urologic procedures. The current report describes the natural transition toward retroperitoneal minimally invasive endoscopic spinal surgery, which does not require CO₂ insufflation, Trendelenburg position, entrance into the peritoneum, or anterior dissection near the great vessels to provide safe exposure for spinal surgery.

■ Materials and Methods

Twelve minimally invasive retroperitoneal lumbar procedures were performed at St. Josephs Hospital in Baltimore, Maryland, and six were performed at Presbyterian Hospital of Plano, Texas, between March 1994 and September 1996. There were 6 female and 12 male patients, with a mean age of 53.4 years (range, 31-76 years).

The indications for surgery included 13 cases of degenerative conditions, three cases of infections, one unstable burst fracture, and one case of a retroperitoneal neurofibroma in-

From the *Scoliosis and Spine Center, St. Josephs Hospital, Baltimore, Maryland, the †Texas Back Institute and the Institute for Spine and Biomedical Research, Plano, Texas, and the ‡Minimally Invasive Services Training Institute, St. Josephs Hospital, Baltimore, Maryland. Acknowledgment date: August 28, 1997. First revision date: October 23, 1997. Acceptance date: December 2, 1997. Device status category: 9.

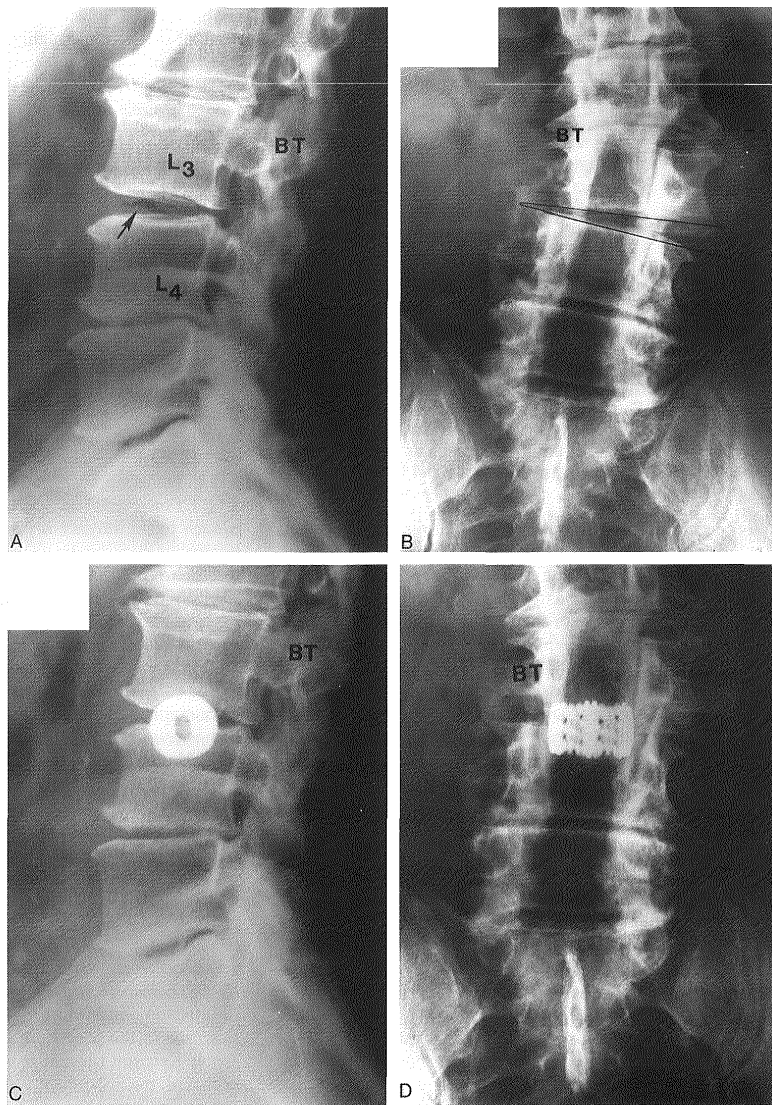


Figure 1. This 75-year-old man had back pain and right anterior thigh pain 2 years after he had undergone laminectomies from L3 to S1 with a posterolateral fusion from L4 to S1. The lateral (A) and anteroposterior (B) radiographs show "vacuum disk" sign at L3-L4 with lateral translation of the L3 vertebral body on L4. His characteristic pain was reproduced by an L3-L4 discogram performed by an independent radiologist. Lateral (C) and anteroposterior (D) radiographs were obtained after the procedure using the endoscopic retroperitoneal approach was performed and a transversely oriented BAK fusion cage was inserted (15 mm in diameter and 24 mm length). The patient's back and right leg pain resolved after surgery.

volving the lumbosacral plexus. Ten of the 13 patients in the degenerative category had undergone previous destabilizing laminectomy procedures elsewhere before referral to the authors' institutions. Flexion-extension lateral radiographs demonstrated more than 3.5 mm of translation, and anteroposterior radiographs showed 10 degrees or more of scoliotic disc space collapse with "vacuum disc sign." Positive discograms documented a provocative pain response at the unstable level (Figure 1). The one patient in the degenerative category who had not undergone previous destabilizing surgery had a massive L2-L3 central disc herniation with left quadriceps weakness.

The retroperitoneal approach proved to be very versatile in the range of vertebral levels addressed throughout the 18 cases. Four patients underwent procedures at L1-L2, seven patients at L3-L4, and two patients at L4-L5. There were four endoscopic decompressions and fusions at L2-L3. One patient with vertebral osteomyelitis underwent a decompressive procedure from L2 to L4.

Surgical Technique. The approach is a combination of video-assisted thoracoscopic and laparoscopic methods. The patient is put under general endotracheal anesthesia, then turned in the

MC000007




Figure 2. A view of a transparent optical trochar (Optiview, Ethicon Endosurgery, Cincinnati, OH) that was used in dissecting the retroperitoneal space. Notice the "winged keel cutting edges," which only will penetrate a fascial layer, such as the peritoneum, if the trochar is forcibly twisted backwards and forwards.

lateral decubitus position on a radiolucent, graphite, Jackson Maximum lateral access table (O.S.I. Corporation, Union City, CA) made specifically for the endoscopic approach, with side rails designed to accommodate robotic arms⁷ and to facilitate c-arm fluoroscopy. A 1-cm incision is made at the anterior portion of the 12th rib for approaching from L1 or L2. Below L2, a lateral c-arm fluoroscopic image is obtained, with a metal marker overlying the patient's skin in the midaxillary line. This method optimizes the placement of the working portal directly over the unstable disc or vertebral segment. The three techniques used to dissect the retroperitoneal space are: finger dissection, balloon insufflation, or the use of an optical, transparent, dissecting trochar⁷ called an Optiview (Ethicon Endosurgery, Cincinnati, OH; Figure 2).

The 10-mm laparoscope is inserted into the Optiview dissecting trochar and refocused once the trochar enters the subcutaneous tissue. The trochar has two "winged keel" cutting surfaces that will not penetrate a fascial layer such as the peritoneum unless the trochar is twisted. Therefore, the three abdominal muscular layers overlying the peritoneum are penetrated in sequence under direct visualization until the preperitoneal fat is encountered. The trochar is used to create a potential space that is superficial to the peritoneum until the laterally oriented fibers of the psoas major muscle are viewed. Usually, the genitofemoral nerve is visualized on the surface of the psoas muscle. At this juncture, a dissection balloon, such as that manufactured by Origin (Menlo Park, CA), can be filled with 1 liter of normal saline or air to dissect the retroperitoneal layer, more correctly referred to as the retrotransversalis fascia. Alternatively, carbon dioxide insufflation can be forced into the retroperitoneal cavity up to a pressure of 20 mm of mercury to create a working space to triangulate endoscopically.³⁰ Once the retroperitoneal space is enlarged, at least three portals are used—working portal, for pituitary rongeur; curettes; a high-powered burr; or Kerrison rongeurs. A second portal is necessary for the 10-mm laparoscope. A third portal is used for retraction of the psoas major muscle off of the spine in a posterior direction. The relatively avascular intervertebral discs are exposed first. Then, the respective midportions of the adjacent vertebral bodies are exposed, and the lumbar segmental vessels

are ligated and divided. Occasionally, a fourth 10-mm portal is used for suctioning in highly vascular cases requiring corpectomies for tumors or infections. Occasionally, for longer strut grafts or instrumentation, the 10-mm working portal is extended in size as much as 5 cm, and an endoscopically assisted, mini-laparotomy type of retroperitoneal exposure facilitates the corpectomy or spinal instrumentation. If the size of the working portal is extended, of course, the CO₂ insufflation is lost, and the working space in the retroperitoneum has to be maintained by using retractors. This technique is advantageous because the spinal decompression can be accomplished without airtight seals, and because standard thoracoscopic instruments can be used on the lumbar spine. In other words, throughout the remainder of the procedure, spine instruments of heterogeneous shaft diameters can be used, and airtight seals around trocars are not required.

Once the vertebral level is confirmed fluoroscopically, the transversalis fascia, perinephric fascia, and retroperitoneal contents are retracted anteriorly (Figure 3). Electrocautery is used to mark the intervertebral discs adjacent to the involved lesion. For example, for an L1 corpectomy, the L1–L2 and the T12–L1 intervertebral disc spaces are marked. A left-sided approach to the surgery is preferred to a right-sided approach, because it is easier to dissect the aorta off the spine than to dissect around the more friable inferior vena cava; this is particularly true in cases of pyogenic vertebral osteomyelitis or cases of neoplasm that occur after radiation therapy with retroperitoneal fibrosis. The psoas muscle is retracted posteriorly, and the ureter is retracted anteriorly.

If a corpectomy is being performed²¹ after the two adjacent discectomies, the surgeon must have access to three methods of hemostasis: 1) Endo-Avitene Microfibrillar Collagen (Alcon, Inc., Humacao, Puerto Rico), 2) Gelfoam (Upjohn Corp., Kalamazoo, MI) soaked in Thrombin (GenTrac Corp., Middleton, WI), and 3) bipolar endoscopic electrocautery. At this point, the segmental vessels are dissected from the underlying bone and elevated with a right-angled clamp. It is important to use two vascular clips or an endoloop on the high-pressure side of the vessels; the vessels are divided with endoshears. As a general rule, with any spine procedure the segmental vessels are ligated and divided in the anterior half of the vertebral body to allow collateral circulation to the neuroforamen and spinal cord to occur to its maximum potential. If the lesion is a tumor or infection, then a culture and a frozen section are obtained at this time in the procedure. A 45-degree, 4-mm-wide endoscopic Kerrison rongeur is used to resect the pedicle. Starting cephalad, the instrument is pointed caudad to protect the exiting spinal roots. Either Kaneda (Acromed Corp., Cleveland, OH) heavy-duty rongeurs or a high-powered, 5-mm burr, such as the Zimmer (Wausau, IN) Ultra-power or Anspach with long extensions, can be used to hollow out the vertebral body. Curettes and small 2–3-mm Kerrison rongeurs are used to complete the corpectomy. It is important to decompress the spinal canal all the way across to the base of the opposite pedicle. Decompression is accomplished only when the opposite pedicle is palpated or visualized. An autogenous iliac strut graft is tamped into place, filling the anterior portion of the corpectomy defect.

Alternatively, if the patient only requires a discectomy or one-level fusion, an anterior interbody fusion can be accomplished endoscopically. The disc space height is restored by using a distraction plug placed from the side. Optimally, two

MC000008

distraction plugs are tamped into the disc space: one anteriorly and one posteriorly. At this point, either a single-barrel or double-barrel drill tube is placed over the distraction plugs. The position of the distraction plugs is monitored with anteroposterior and lateral fluoroscopy. The center of the distraction plugs will correspond with the center of the BAK interbody fusion cages or endoscopic bone dowels.¹ The double-barrel tube is tamped into place to engage its teeth into the superior and inferior vertebral bodies to maintain the normal height of the disc space during the reaming and tapping of holes into the intervertebral endplates. The BAK fusion cage or laparoscopic bone dowels, which are composed of femoral allograft, are packed with autogenous iliac graft. The morselized iliac autograft can be harvested with minimally invasive techniques through a 12-mm incision by using a disposable T-shaped awl.

After surgery, the patient is placed in a warm and form corset (interbody fusion) or a thoracolumbar sacral orthosis (after a corpectomy), until radiographic fusion is accomplished. Intraoperatively, it is important to countersink the BAK fusion cages or laparoscopic bone dowel. The authors advocate packing additional bone graft superficial to the cage. At 3–6 months after surgery, arthrodesis can be confirmed if solid trabecular bone is observed to bridge one vertebrae to the adjacent level; this is the most reliable radiographic sign of a solid arthrodesis. Three-dimensional, computed-tomography reconstruction images of the bone within the cages and flexion-extension lateral radiographs also can provide useful information.

■ Results

The mean length of the postoperative follow-up period was 24.3 months (range, 12–40 months). Fourteen patients underwent left-sided retroperitoneal approaches, and, in four patients, the pathology was addressed more easily on the right side. There were four patients in whom a single incision was made of 5 centimeters or less. Fourteen patients had either three or four portals measuring approximately 12 mm in length. These fourteen patients had CO₂ insufflation to assist the retrotransversalis dissection. The patients with one incision of 5 centimeters or less had lesions compatible with infection or tumor, and the use of CO₂ insufflation was avoided to prevent pressurizing the tumor cells or bacteria systemically into the patient's bloodstream.^{9,10,11,15}

Fusions were performed in 15 of 18 cases by using structural bone graft and/or interbody fusion cages. A 38-year-old radiologist's wife with a neurofibroma arising from the lumbosacral plexus adjacent to the left common iliac vein did not demonstrate preoperative or intraoperative instability; therefore, a fusion procedure was not indicated.

Ten patients underwent fusion surgery with custom BAK interbody fusion cages. The long axes of the cages were in the transverse direction (Figure 4).⁴ In each case, the cages were packed with autogenous iliac bone graft harvested using a minimally invasive, T-shaped trochar, that was 10 mm in diameter. Four patients underwent placement of laparoscopic bone dowels fashioned from

femoral allograft. The long axes of the implants were positioned in a transverse direction.

There were no cases of implant migration or pseudoarthrosis. There were no cases of a radiolucent interface between the implant and the vertebral body. There were no cases of subsidence more than 1 mm, and there was trabecular bony bridging across the adjacent vertebrae laterally by 6 months after surgery.

One additional patient did not undergo an endoscopic stabilization procedure. He was a 47-year-old man with an unstable burst fracture who had undergone left anterior Kaneda instrumentation at the referring institution 3 months earlier. He had had an incomplete neurologic deficit; a preoperative computed tomography scan had demonstrated continued right-sided cauda equina compression. A right-sided endoscopic decompression was performed at the authors' institution, and additional stabilization was not required.

For all 18 cases, the mean duration of the surgical procedure, including the harvesting of iliac crest bone autograft, was 115.2 minutes (range, 60–260 minutes). The mean estimated blood loss, which, at the authors' institutions, is determined by the attending anesthesiologist, was 205 cc (range, 25–1000 cc). The mean length of hospital stay was 2.9 days (range, outpatient procedure to 5 days).

Complications

There were three patients with postoperative complications. Case 2 was a 71-year-old man on renal dialysis who presented with sepsis. Endoscopic, retroperitoneal, L3–L4 discectomy; debridement; and fusion were performed to culture and manage an L3–L4 pyogenic osteomyelitis. Six weeks after surgery, after treatment with intravenous antibiotics, the patient underwent posterior, segmental stabilization with Texas Scottish Rite Hospital implants from L1–L5 for more definitive stabilization and fusion. The single-level, anterior, interbody, endoscopic fusion was not believed to be adequate to prevent long-term lumbar kyphosis and instability.

The second complication occurred intraoperatively in Case 3, when a laparoscopic bone dowel partially fractured at the point of attachment of the driver into the central drilling peg in the femoral cortical allograft. The fractured piece of allograft was extremely small (approximately 0.5 cm × 0.5 cm × 0.5 cm), and the patient's spinal stability was not jeopardized. There were no long-term sequelae, and the patient had a solid arthrodesis, which was facilitated by morselized iliac autograft placed in the central chamber of all laparoscopic bone dowels.

The third complication occurred in a 69-year-old man who underwent transverse BAK cage insertion for postlaminectomy instability at L3–L4. The patient developed a hematoma in the psoas muscle at L3–L4 after surgery. This resulted in a temporary genitofemoral nerve palsy, which resolved spontaneously within 3 months.

MC000009

Explore Litigation Insights

Docket Alarm provides insights to develop a more informed litigation strategy and the peace of mind of knowing you're on top of things.

Real-Time Litigation Alerts



Keep your litigation team up-to-date with **real-time alerts** and advanced team management tools built for the enterprise, all while greatly reducing PACER spend.

Our comprehensive service means we can handle Federal, State, and Administrative courts across the country.

Advanced Docket Research



With over 230 million records, Docket Alarm's cloud-native docket research platform finds what other services can't. Coverage includes Federal, State, plus PTAB, TTAB, ITC and NLRB decisions, all in one place.

Identify arguments that have been successful in the past with full text, pinpoint searching. Link to case law cited within any court document via Fastcase.

Analytics At Your Fingertips



Learn what happened the last time a particular judge, opposing counsel or company faced cases similar to yours.

Advanced out-of-the-box PTAB and TTAB analytics are always at your fingertips.

API

Docket Alarm offers a powerful API (application programming interface) to developers that want to integrate case filings into their apps.

LAW FIRMS

Build custom dashboards for your attorneys and clients with live data direct from the court.

Automate many repetitive legal tasks like conflict checks, document management, and marketing.

FINANCIAL INSTITUTIONS

Litigation and bankruptcy checks for companies and debtors.

E-DISCOVERY AND LEGAL VENDORS

Sync your system to PACER to automate legal marketing.