

# The Relationship of Intrapsoas Nerves During a Transpsoas Approach to the Lumbar Spine

## Anatomic Study

Daniel K. Park, MD,\* Michael J. Lee, MD,† Eric L. Lin, MD,‡ Kern Singh, MD,\*  
Howard S. An, MD,\* and Frank M. Phillips, MD\*

**Study Design:** A cadaveric study.

**Objective:** To define the relationship of the lumbar exiting nerve root and trunks within the psoas muscle with reference to the radiographic center of the intervertebral disc, the recommended disc access point for the minimally invasive lateral transpsoas approach.

**Summary of Background Data:** The transpsoas approach to the lumbar intervertebral body disc is a minimally invasive approach used for interbody fusion. This approach carries the potential risk of injury to the intrapsoas nerves. There are no published studies investigating the locations of the intrapsoas neural elements with reference to the transpsoas access corridor developed during minimally invasive lateral approaches to the disc.

**Methods:** Ten human cadaveric specimens were analyzed. A guide wire was placed in each disc space center under lateral fluoroscopic guidance as has been recommended for disc access in the transpsoas fusion technique. Using calipers, the distances from the exiting nerve and trunk to the wire were measured.

**Results:** In general, the nerve trunk was a mean of 14 mm posterior to the center of the disc and was a mean of 5 mm closer to the center of the disc than the exited nerve. The trunks were closer to the center of the disc caudally in the lumbar spine, with the distance ranging from a mean of 16.4 mm at L2-3 to 10.6 mm at the L4-5 level. The intrapsoas location of the exited nerve was less variable and was greater than 15 mm from the projected center of the disc. At L4-5, the trunk approximated the center of the disc in 15% of specimens.

**Conclusion:** This study suggests that the intrapsoas nerves are a safe distance from the radiographic center of the intervertebral disc in a majority of cases; however, anatomic variations in the

location of these nerves place them at injury risk in a small number of cases. These results suggest that neural monitoring whereas traversing the psoas may be important to enhance the safety of the transpsoas approach. Care is particularly warranted at the L4-5 level.

**Key Words:** lumbar nerve trunk, lumbar plexus, psoas muscle, lumbar interbody fusion, trans-psoas approach, nerve injury

(*J Spinal Disord Tech* 2010;23:223–228)

Lumbar spine fusion has been successfully used in the treatment of instability, deformity, and degenerative disc disease.<sup>1–4</sup> In recent years, interbody fusion has become a popular technique with touted benefits that include eliminating the disc as a potential pain generator, high rates of successful fusion, and restoring the intervertebral height and lumbar lordosis.<sup>5–8</sup> Traditional techniques to achieve interbody fusion include anterior lumbar interbody fusion and posterior or transforaminal lumbar interbody fusion. In addition, a lateral retroperitoneal approach to the lumbar spine with posterior retraction of the psoas muscle off the vertebral bodies has been used.<sup>9,10</sup>

Recently, a novel minimally invasive retroperitoneal direct lateral transpsoas approach to interbody arthrodesis has been described.<sup>11–13</sup> This technique, first termed as extreme lateral interbody fusion (XLIF), provides the ability to achieve an interbody arthrodesis whereas avoiding the risks implicit with an anterior or posterior approach to the interbody space. Furthermore, this technique uses a minimally invasive approach through the retroperitoneal space. The theoretical advantages of minimally invasive surgery include less tissue trauma, less postoperative pain, shorter hospital stay, and faster return to activities of daily living.<sup>14</sup> In addition, the lateral minimally invasive approach does not require the need for an access surgeon. During the lateral approach the radiographic center of the disc is identified. Then by using various dilators, the intervertebral disc space is accessed through the psoas muscle. The expansion of a blade retractor system then provides a working channel and direct visualization of the disc. Standard intradiscal

Received for publication January 2, 2009; accepted April 7, 2009.

From the \*Rush University Medical Center, Chicago, IL; †University of Washington Medical Center, Seattle, WA; and ‡St Jude's Medical Center, Fullerton, CA.

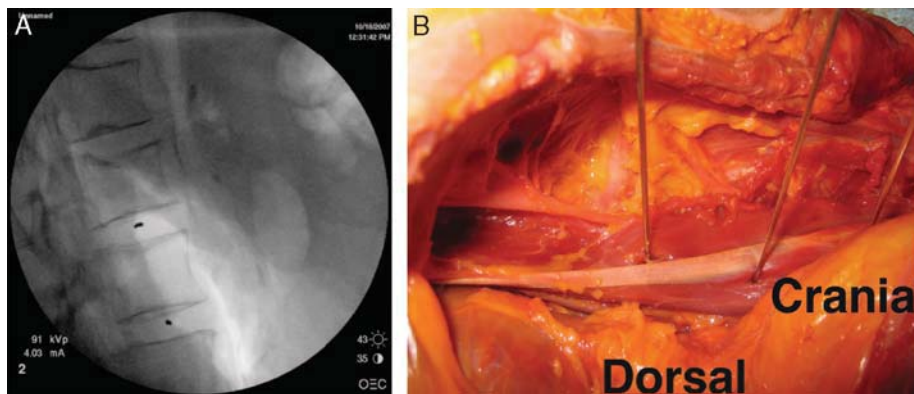
Source of Support: NuVasive Corporation.

Permission to reproduce copyrighted material.

IRB equivalent approved.

Reprints: Daniel Park, MD, Rush University Medical Center, Midwest Orthopedics, 1725 West Harrison Street, Suite 1063, Chicago, IL 60612 (e-mail: danparkmd@gmail.com).

Copyright © 2010 by Lippincott Williams & Wilkins



**FIGURE 1.** Radiograph with guide wire placed in the middle of the disc (A). Gross picture of the guide wire placed through the psoas muscle (B).

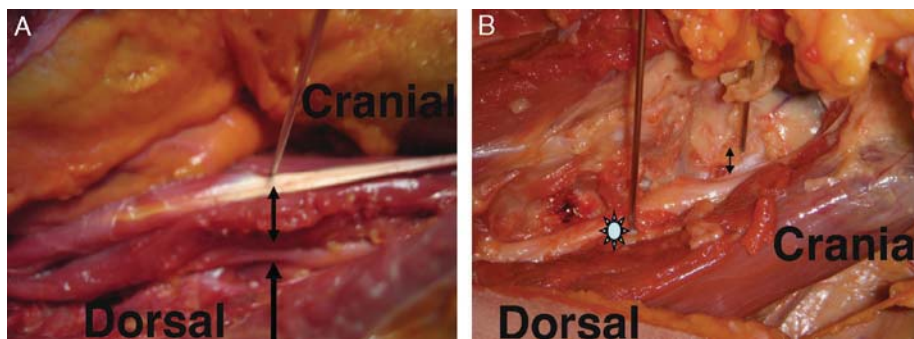
instruments are then used for disc space preparation, arthrodesis, and interbody implant insertion.

When approaching the intervertebral disc via a transpsoas approach, the exiting nerve from the intervertebral foramen and trunks of the lumbar plexus that reside in the psoas are at risk. In general, the neural structures reside in the posterior third of the psoas muscle<sup>15-18</sup>; therefore, transpsoas access has been recommended through the anterior portion of the muscle to avoid neurologic injury. Although anatomic studies have defined the exiting nerve and plexus, the precise location of the nerves at various levels in the lumbar spine with reference to the radiographic center of the intervertebral disc have not been described.

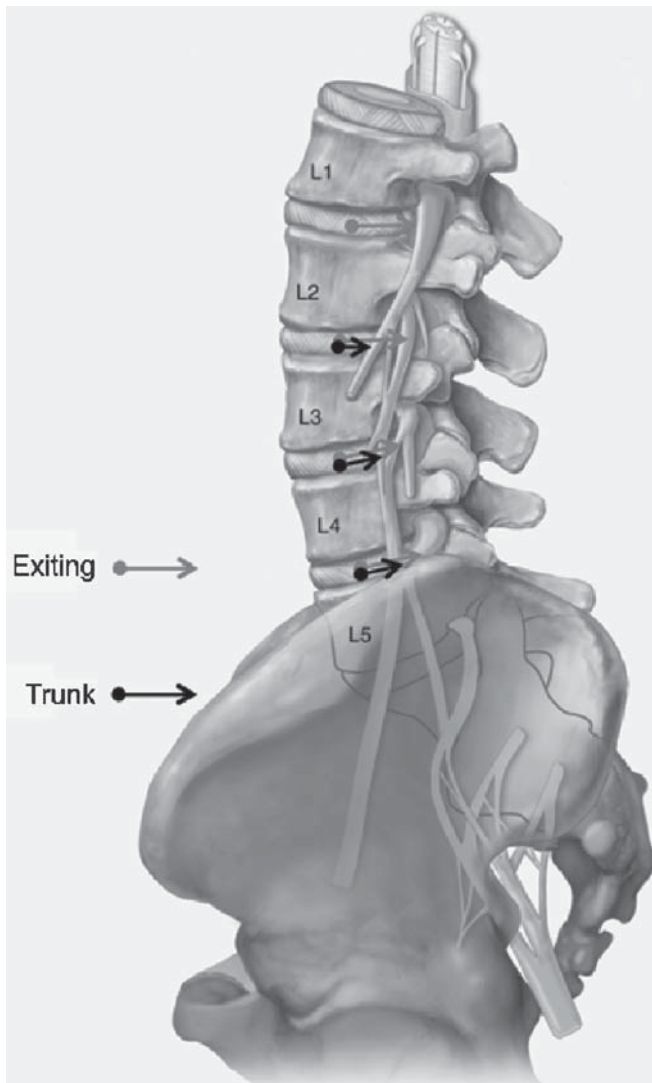
The purpose of this study was to define the relationship between the lumbar exiting nerve roots and trunks within the psoas muscle and the working corridor used for the lateral approach to the disc. Measurements were on the basis of projected center of the disc from a lateral fluoroscopic image as would be used during the typical lateral transpsoas interbody fusion procedure. This study also examines the effects of hip flexion and extension on the relationship between the disc center and the intraspinal neural tissues.

**METHODS**

Ten fresh-frozen cadaveric specimens (9 females and 1 male) were obtained for this study. Five of these specimens had intact proximal femurs in addition to the torso and pelvis whereas the other 5 specimens (1 male) only contained the torso and pelvis. Before dissection, the specimens were slowly thawed at room temperature. The specimens were then placed in the lateral decubitus position. The lateral retroperitoneal approach was then used to access the psoas muscle and lumbar spine. With the typical transpsoas interbody fusion procedure, the center of the disc is targeted with sequential dilators guided by neural monitoring. To mimic the targeted docking location, a guide wire was placed colinear with the disc space and in the anterior-posterior and cranio-caudal center of the L1-2, L2-3, L3-4, and L4-5 disc spaces under lateral fluoroscopic guidance (Fig. 1). To maintain the anatomic relationship of the lumbar nervous tissue to the psoas muscle, minimal dissection was then carried out to identify the exiting nerve and the associated lumbar trunk at each disc level. The shortest distance from the guide wire to the respective exiting nerve/trunk was measured using digital calipers (Mitutoyo, Kanagawa, Japan) (Fig. 2). At each level except



**FIGURE 2.** Guide wire placed at a safe distance away from the nervous tissue (arrow) (A). The shortest distance between the wire and the nervous tissue was measured (double arrow) (A and B). In some cases, the wire was placed through nervous tissue (\*) (B).



**FIGURE 3.** Anatomic illustration of the exiting lumbar nerve and trunks and identification of how distances of each were measured from the disc center. Black arrow as trunk and gray arrow as exiting nerve.

L1-2, where the lumbar plexus is not yet formed, 2 neural structures were identified. The corresponding exiting nerve root was first identified, and the associated nerve trunk, which comprised a plexus of the superior exiting nerve was then identified (Fig. 3). Both the left and right sides were dissected in a similar manner. Lastly, if proximal femurs were intact, measurements were made with the hip in extension and flexion. Because the guide wire might impede the movement of the psoas muscle, the wires were individually removed when hip flexion and extension was performed and replaced in the middle of the disc under fluoroscopic guidance.

The data were then analyzed for occurrences of actual nerve penetration and risk of nerve injury by the guide wire. When performing the transpsoas procedure,



**FIGURE 4.** Illustration demonstrating the theoretical distance from the guide wire at the center of the MaXcess dilators to the posterior margin of the posterior blade. This distance is the radius of the last dilator (6 mm) plus the width of the posterior blade (1.27 mm) = 7.27 mm. As a measure of neural safety, this number was rounded up to 8 mm as the minimum required distance from the center that the neural structures must be found without having to be retracted during the surgery.

the fibers of the psoas muscles are separated using sequential dilators, which split the psoas and spread the surrounding tissue. An access retractor is inserted over the final dilator. The XLIF (NuVasive, Inc, San Diego, CA) retractor system used by the senior author (F.M.P.) has an outer diameter of 12 mm. The posterior blade of the access retractor has a thickness of 1.27 mm. On the basis of the size of the final retractor (Fig. 4), neural structures more than 8 mm from the center of the disc (and therefore the center of the access retractor) would not be at risk of direct traction by the retractor blade. If a neural structure was within 8 mm of the disc a higher degree of neural retraction would be required for the retractor to be safely placed. Therefore if the distance from the nerve tissue to the center of the disc was less than 8 mm, it was classified as “at risk”. The data were then compared using unpaired 2 sample *t* testing. Statistical significance was defined as a *P* value less than 0.05.

**TABLE 1.** Average Distance of Nervous Tissue to Disc and Percentage of Nervous Tissue “at Higher Risk” or Pierced by the Initial K Wire

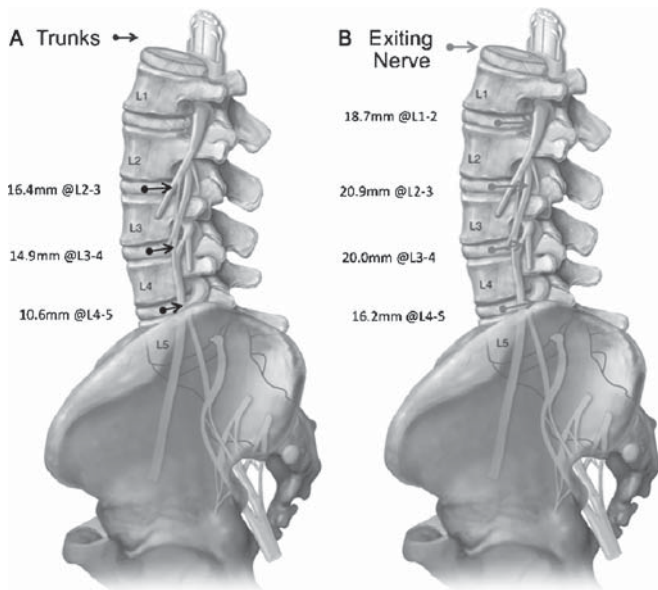
Disc Space	Nerve	Average (mm)	Standard Deviation (mm)	Percent Closer Than 8 mm	Percent Pierced by K Wire
L1-2	L1 exiting	18.7	4.2	0	0
L2-3	Trunk	16.4	4.1	5	0
L2-3	L2 exiting	20.9	4.5	0	0
L3-4	Trunk	14.9	4.9	5	5
L3-4	L3 exiting	20.0	4.4	0	0
L4-5	Trunk	10.6	7.0	25	15
L4-5	L4 exiting	16.2	5.2	5	0

**RESULTS**

**Location of the Exiting Nerve and Roots**

In general, the nerve trunk was a mean of  $14.0 \pm 5.9$  mm posterior from the center of the disc and was 5 mm closer to the projected center of the disc based off a lateral radiograph than the exited nerve root (mean;  $19.0 \pm 4.8$  mm) (Table 1, Fig. 5). The nerve trunks were closer to the disc center caudally in the lumbar spine with this distance ranging from a mean of  $16.4 \pm 4.1$  mm at L2-3 to  $10.6 \pm 7.0$  mm at L4-5 level. The intrapsoas location of the exited nerve root was less variable and in general was greater than 15 mm from the projected center of the disc at all anatomic levels. In 1 case, the L2-3 nerve trunk was penetrated during fluoroscopically guided wire placement at the L3-4 disc, whereas 3 (15%) L3-4 nerve trunks were pierced although by accessing the L4-5 disc level.

Neural tissue “at risk”, that is close enough to the center of the disc that direct neural retraction is required



**FIGURE 5.** Average distances of nerve trunks (A) and exiting nerve (B).

**TABLE 2.** Distance of Nervous Tissues Comparing From Right to Left

Disc Space	Nerve	Right/Left	Average (mm)	Standard Deviation (mm)	P
L1-2	L1 exiting	R	19.2	4.6	0.19
		L	18.3	3.4	
L2-3	Trunk	R	16.1	4.0	0.29
		L	16.7	4.0	
L2-3	L2 exiting	R	21.3	4.4	0.31
		L	20.6	4.3	
L3-4	Trunk	R	13.7	5.6	0.054
		L	16.1	3.3	
L3-4	L3 exiting	R	19.7	4.6	0.40
		L	20.2	3.9	
L4-5	Trunk	R	10.8	8.0	0.40
		L	10.4	5.4	
L4-5	L4 exiting	R	15.9	5.8	0.37
		L	16.4	4.2	

for the placement of the final retractor, was observed in 5% of approaches at the L2-3 and L3-4 levels. At L4-5, the nerves were felt to be at risk of having to be directly retracted in 25% of approaches (Table 1).

**Right and Left Differences**

There were no significant differences in right and left measurements of the location of the neural tissue relative to the disc spaces (Table 2). Furthermore, the same number of specimens and same incidence of nerve tissue penetration by the guide wire occurred on the right and left.

**Flexion and Extension Differences**

In general, the intrapsoas nerves migrated anteriorly with hip flexion, although we did not detect a statistically significant difference between flexion and extension ( $P > 0.2$ ) (Table 3).

**TABLE 3.** Distance of Nervous Tissue Comparing Flexion and Extension

Disc Space	Nerve	Flexion/Extension	Average (mm)	Standard Deviation (mm)	P
L1-2	L1 exiting	Flexion	18.0	3.7	0.25
		Extension	18.9	3.8	
L2-3	Trunk	Flexion	16.2	4.0	0.43
		Extension	16.4	4.6	
L2-3	L2 exiting	Flexion	19.9	4.0	0.20
		Extension	21.1	4.9	
L3-4	Trunk	Flexion	14.0	5.3	0.23
		Extension	14.8	3.7	
L3-4	L3 exiting	Flexion	19.4	3.9	0.40
		Extension	19.8	3.0	
L4-5	Trunk	Flexion	7.1	8.0	0.31
		Extension	8.5	7.0	
L4-5	L4 exiting	Flexion	13.5	5.1	0.36
		Extension	14.0	6.5	

## DISCUSSION

This anatomic study defines the location of the neural elements in the psoas muscle with reference to minimally invasive lateral interbody fusion. The measurements performed were referenced from the center of the disc on the basis of a lateral fluoroscopic image, as would be clinically used during the transpsoas procedure. The nerve trunks are closer to the center of their respective discs than the corresponding exited nerve root. At L4-5, the nerve trunk was in the path of the initial guide wire approach directed towards the center of the disc in 3 of 20 approaches and the neural elements would require direct retraction for placement of the final retractor in 25% of cases. The neural proximity was substantially less at the levels cephalad to L4-5.

Successful results with the minimally invasive transpsoas approach have been reported recently. Ozgur et al<sup>14</sup> reported on 13 patients treated with single level or multilevel XLIF procedures. The patients experienced significant relief of pain and improvement in functional scores. Pimenta et al have reported results in patients who underwent XLIF from L2 to L5 for degenerative scoliosis.<sup>13,19</sup> The patients with 2-year follow-up demonstrated significant improvement in Visual Analog Scale pain scores and Oswestry scores whereas coronal and sagittal alignments sustained improvement at follow-up. As is recommended with the XLIF procedure, continuous free run neuromonitoring as well as triggered electromyographics off all dilators and the final retractor was used, and the procedures were reportedly performed without intraoperative complications. There was a 4% incidence of pseudarthrosis and 1 patient (4%) had a late occurring subsidence at 6 months follow-up, but was asymptomatic and untreated.<sup>19</sup>

Infrequent complications have however been reported with the transpsoas procedure. Wright reported on the first 145 patients undergoing XLIF, with 2 transient genitofemoral injuries and 5 patients experiencing transient hip flexor weakness.<sup>20</sup> The author felt that real-time neural monitoring was essential as the monitoring detected a nearby intrapsoas nerve in 46% of the cases. Ozgur et al<sup>14</sup> reported no neurologic complications in the author's first 13 XLIF patients. Recently, Knight and colleagues reported postoperative meralgia paresthetica in 10% of cases and L4 nerve root injuries in 3.4% of 58 patients undergoing a lateral transpsoas interbody arthrodesis. Despite the risk of nerve injury, none of these complications affected patient satisfaction.<sup>21</sup> Importantly, in this study varied designs of retractors were used and not all dilators and retractors used provided real time electromyographic feed back. The complication rate for minimally invasive lateral approaches is similar to that reported with an endoscopic lateral approach for lumbar interbody fusion reported.<sup>21</sup> In contrast, the reported incidence of neurologic injury which includes retrograde ejaculation, femoral nerve palsy, impotence, and peroneal palsy from 1963 to 1990 was 5.1% when the traditional open retroperitoneal approach to interbody fusion was used.<sup>22</sup>

In the literature, there are few studies that describe the location of the nerve roots within the psoas muscle. Bae et al<sup>18</sup> performed a morphometric cadaveric study, which examined the lumbar nerve root anatomy for the purposes of determining a safe zone when addressing extraforaminal disc herniations. In this study, the authors described the distances between the nerve to the superior aspect of the transverse process, to the inferior aspect of the pedicle, and the superior articular process. In addition, they measured the distance between the dorsal lateral most aspects of the intervertebral disc and the nerve. These measurements are not particularly relevant to the transpsoas procedure. In a histologic study identifying the relationship of the neural elements to the disc at various levels in the lumbar spine, Moro et al<sup>17</sup> reported that all intrapsoas nerve roots were located over the posterior half of the vertebral body at the L4-5 disc space and above. Below that disc level, nerve roots or plexus were found over the anterior half of the L5 body. Both of these studies lack normative reference values for where the nerve root lies at the disc space in reference to the fluoroscopic center of the disc.

Proponents of the transpsoas procedure have recommended targeting the fluoroscopic center of the lateral aspect of the disc as the initial disc access point. Certainly moving the initial access point and subsequent working portals further anterior would reduce the risks of neural injury. However, as one moves anterior away from the center of the disc, the side-to-side (left-to-right) dimensions of the disc get smaller, so that a smaller and therefore less stable interbody implant is required. In addition, the blood vessels and peritoneal cavity are at risk anteriorly.

In this study, the location of the intrapsoas nerves was similar with a left or right-sided approach. This finding is not surprising as nervous tissue is likely symmetrical in the body. We observed that the intrapsoas nerves migrated anteriorly with hip flexion, although we did not detect a statistically significant difference between flexion and extension. The lack of significance may reflect the study being underpowered to detect a difference. Also because these were cadaveric specimens, the mobility of the psoas may have been restricted relative to the in vivo situation. Purported benefits of hip flexion during this procedure include relaxing the psoas muscle making for less psoas trauma during the transpsoas approach and also permitting the nervous tissue to be more mobile and easier to retract.

In summary, this study suggests that although in a majority of lateral transpsoas interbody surgeries, the intrapsoas nerves are a safe distance from the disc access pathway, the anatomic variations in location of these nervous tissue place them at risk of injury in a small number of cases. In particular, surgeons should be cognizant of the higher risk of nerve injury at lower levels, especially at L4-5. To reduce this risk, real time neuromonitoring may be an important element of this procedure. Although clinical studies to date suggest a risk profile that is comparable or lower than that associated

# Explore Litigation Insights

Docket Alarm provides insights to develop a more informed litigation strategy and the peace of mind of knowing you're on top of things.

## Real-Time Litigation Alerts



Keep your litigation team up-to-date with **real-time alerts** and advanced team management tools built for the enterprise, all while greatly reducing PACER spend.

Our comprehensive service means we can handle Federal, State, and Administrative courts across the country.

## Advanced Docket Research



With over 230 million records, Docket Alarm's cloud-native docket research platform finds what other services can't. Coverage includes Federal, State, plus PTAB, TTAB, ITC and NLRB decisions, all in one place.

Identify arguments that have been successful in the past with full text, pinpoint searching. Link to case law cited within any court document via Fastcase.

## Analytics At Your Fingertips



Learn what happened the last time a particular judge, opposing counsel or company faced cases similar to yours.

Advanced out-of-the-box PTAB and TTAB analytics are always at your fingertips.

## API

Docket Alarm offers a powerful API (application programming interface) to developers that want to integrate case filings into their apps.

## LAW FIRMS

Build custom dashboards for your attorneys and clients with live data direct from the court.

Automate many repetitive legal tasks like conflict checks, document management, and marketing.

## FINANCIAL INSTITUTIONS

Litigation and bankruptcy checks for companies and debtors.

## E-DISCOVERY AND LEGAL VENDORS

Sync your system to PACER to automate legal marketing.