

# **EXHIBIT DTX-5150-R**

# ■ A Carbon Fiber Implant to Aid Interbody Lumbar Fusion

## Two-Year Clinical Results in the First 26 Patients

John W. Brantigan, MD,\* and Arthur D. Steffee, MD†

The success of posterior lumbar interbody fusion (PLIF) has been limited by mechanical and biologic deficiencies of the donor bone. The authors have designed a carbon fiber-reinforced polymer implant that separates the mechanical and biologic functions of PLIF. The cage-like implant provides an actual device designed to meet the mechanical requirements of PLIF and replaces the donor bone with autologous bone, the best possible bone for healing. The authors report 2-year follow-up results for their first 26 consecutive patients, 18 of whom were postsurgical failed backs with a total of 37 previous surgeries. At 2 years, 28 of 28 PLIF cage fusion levels and 6 of 11 (54.5%) allograft levels exhibited radiographic fusion, a statistically significant difference at  $P = 0.0002$ . Clinical results were excellent in 11/26, good in 10/26, fair in 3/26, and poor in 2/26. Fair and poor results were attributable to objective identifiable problems unrelated to the carbon cage. The carbon implant achieved successful fusion in 6/6 (100%) of followed patients treated for a failed ETO allograft interbody fusion. A prospective controlled multi-centered study is being initiated. [Key words: interbody fusion, PLIF, ALIF, carbon cage, allograft, pedicle screw]

Posterior lumbar interbody fusion (PLIF), pioneered by Dr. Ralph Cloward in the 1940s,<sup>9,10</sup> is a biomechanically optimum fusion. A successful PLIF maintains the disc height, protects the nerve roots, restores weight-bearing to anterior structures, restores the anulus to tension, and immobilizes the unstable degenerated intervertebral disc area. A successful PLIF restores every mechanical function of the functional spinal unit except motion. Problems with PLIF have included excessive bleeding (usually epidural), the need for donor bone (with risk of acquired immune deficiency syndrome [AIDS] and hepatitis), prolonged healing time of donor bone, the difficulty of cutting precise bony channels, the difficulty of providing sterile donor bone of precise dimensions, the potential of instability, the risk of retropulsion of graft and consequent neural damage,

and postoperative collapse of the donor bone and pseudarthrosis.

In 1985 Cloward<sup>10</sup> claimed 87 to 92% clinical success and 92% fusion success in his 40+ years of PLIF surgery; Lin<sup>17,18</sup> has reported 82% clinical success and 88% fusion success; and Ma<sup>19</sup> has reported 83% clinical success and 85% fusion success. Unfortunately, many other surgeons have had unsuccessful results with uninstrumented PLIF and have abandoned the procedure. In our experience, Dr. Steffee did an early series of 12 uninstrumented PLIF procedures many years ago and had a 100% failure rate because of continued instability of the surgical construct. This series was never published because authors and editors both dislike publishing unsuccessful studies. Dr. William Gazale, who developed a commercially produced PLIF chisel, has presented his surgical results of uninstrumented PLIF at several meetings, with approximately a 90% failure rate. This study also has not been published.

More recently, the use of pedicle screws and plates have allowed surgeons to reduce degenerative deformities of the lumbar spine and maintain accurate positional control of the motion segment in anatomic alignment and in normal sagittal and coronal plane balance.<sup>27,28</sup> Pedicle screws have not, however, eliminated the need for weight-bearing support in the anterior column. The likely result of lack of anterior column support is broken screws, a problem that is not solved by a designing a stronger screw. If a deformity is corrected and disc space height is restored, physiologic anterior column support must be regained by use of interbody bone graft.

Of the first 697 pedicle screw/VSP cases done at the Cleveland Spine and Arthritis Center, PLIF was done in at least one level in 501 cases, or 71%. Our standard PLIF procedure<sup>3,26</sup> includes segmental fixation using pedicle screws and VSP plates, ethylene oxide sterilized interbody allograft (most commonly 2 cancellous blocks 13 × 13 × 25 mm), and autologous posterolateral graft (often local bone from the posterior decompression). Generally satisfactory clinical results are achieved; however, the failure rate of the interbody graft remains at about 30%.

The current problem has been the quality of the bone

From the \*Department of Surgery, Division of Orthopaedics, Creighton University, Omaha, Nebraska; and the †Cleveland Spine and Arthritis Center, Cleveland, Ohio  
Accepted for publication August 19, 1992.

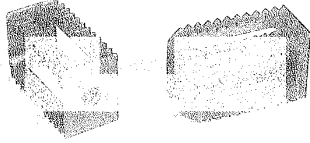


Figure 1. Carbon-fiber-reinforced polymer implant has struts to support weight-bearing, ridges to resist retropulsion, hollow areas to allow packing of autologous bone graft, and the structure is radiolucent to allow visualization of healing by normal radiographic methods.

graft, which is less than optimum both biologically and as a load-bearing device. The donor bone of PLIF is expected to serve both a mechanical device function and a biologic bone-growth function. The PLIF bone must bear substantially all of the body's weight above the PLIF level while it is being incorporated by the erosive process of "creeping substitution." We explored the mechanical properties of allograft bone for PLIF in a previous study<sup>1</sup> and found the average bone to be inadequate for the required mechanical function.

We have developed a carbon-fiber-reinforced polymer implant, shown in Figure 1, to aid interbody fusion. The implant has ridges or teeth to resist retropulsion, struts to support weight, a hollow area to allow packing of autologous bone graft, and the carbon structure is radiolucent to allow visualization of healing by normal radiographic techniques. The cage implant separates the device and biologic functions of PLIF by providing an actual device designed to meet the mechanical requirements of PLIF, and replacing the donor bone with autologous cancellous bone, the best possible bone for healing. Mechanical tests of the implant in isolated motion segments in cadaver spines have shown that cage struts support all anticipated compression loads and the ridges or teeth resist retropulsion with a measured resistance to pullout three times greater than that of blocks of donor bone.<sup>4</sup> The carbon fiber material has a modulus of elasticity approximating that of cortical bone.<sup>7</sup> The purpose of this article is to report results on the first 26 patients treated with the carbon cage implant who have reached the 2-year follow-up interval.

#### ■ Materials and Methods

Initial cages were machined from blocks of composite made of 68% long-fiber pyrolytic carbon fiber in PEEK (poly ether ether ketone) (ICI Advanced Materials, Wilmington, Dela-



Figure 2. Cage implants are sized to the 11-, 13-, and 15-mm finish broach of the ADS PLIF Broach System (AcroMed Corp.).

ware). More recently, cages were fabricated from a composite made from long-fiber carbon in Ultrapek (poly ether ketone ether ketone) obtained from BASF Structural Materials, Anaheim, California. Both materials demonstrate resistance to all solvents except sulfuric acid and appear equivalent in biologic and mechanical properties.

The cage implants are implanted in horizontally opposed transverse channels prepared in the disc space using the ADS PLIF Broach System (AcroMed Corp.). Figure 2 shows the three standard sizes of carbon fiber implants adjacent to the 11-mm, 13-mm, and 15-mm finish broaches, to which the implants are sized.

Between May 1989 and July 1990, 26 patients had surgery including interbody fusion with the carbon cages. Patients were selected for use of the carbon cage device if they had failed PLIF with ETO bone, if they had high-grade or traumatic spondylolisthesis, if they required strong anterior support because of technical difficulties with other devices at surgery, or if they had had failure of numerous other surgeries. Several patients had cages as a primary surgery.

Table 1 lists each patient, date of surgery, surgeon, cage material, VSP fixation levels, carbon cage levels, PLIF levels done with ETO-sterilized bone, 6-, 12-, and 24-month clinical status, fusion status for carbon cages and ETO PLIF levels, and information regarding reoperation. Clinical results are graded excellent, good, fair, or poor according to generally accepted criteria summarized in Table 2. Radiographic evidence of fusion was graded 1 (obvious pseudarthrosis) to 5 (fusion radiographically solid) by criteria summarized in Table 3.

#### ■ Results

In the 26 patients there were 63 total fusion levels: 32 levels had carbon cage interbody fusions (29 with the PLIF cage—Figure 1—and 3 with a larger oval cage used anteriorly), 11 levels had ETO donor bone PLIFs, and 20 levels had posterolateral fusion using autologous bone with pedicle screw and plate support without interbody fusion. Two-year follow-up roentgenograms were obtained on 31 cage levels and 11 allograft levels in 25 patients. There were no failed fusions with the carbon cage. Successful radiographic fusion was achieved in 28

*all levels of not to stop in Ontario, N.H.*

Table 1. Outcome Summaries for Interbody Fusion Using Carbon Cages

*Edwin*

*EC*  
*EC\**

*ALIF*

Patient	Number Prior Surg	Date of Cage Surgery	Surgical Indication	Surgeon	Cage Material	VSP Levels	Cage Levels	ETO Levels	Clinical Status							Purpose of Re-op
									6 Mo.	12 Mo.	24 Mo.	ETO Fusion	Cage Fusion	Re-op (Y/N)		
AP	2	5/09/89	Failed ETO PLIF	ADS	PEEK	L4-S1	L4-S1	none	E	E	E	—	5	N		
EC	6	7/21/89	Failed ETO PLIF	ADS	PEEK	L4-S1	L4-L5	L5-S1	G	F	G	2	5	Y	Failed ETO PLIF L5	
EC*	7	1/02/91	Failed ETO PLIF	JWB	UPEK	L4-S1	L5-S1	none	G	G	—	—	4	N		
LD	2	8/08/89	Instability	JWB	PEEK	L4-S1	L4-L5	none	E	E	E	—	5	N		
GMP	0	8/09/89	Instability	ADS	PEEK	L3-S1	L3-L4	L4-L5	F	G	G	4	5	Y	Remove 1 plate	
BA	1	8/11/89	Spondylo below HRI	ADS	PEEK	L4-S1	L4-L5	none	G	G	G	—	5	—		
PR	2	10/11/89	Failed ALIF	ADS	PEEK	L2-S1	L3-L4	L2-L3	F	P	P	2	5	Y	Repair burst fx	
MSC	1	12/05/89	Failed PLIF	ADS	PEEK	L5-S1	L5-S1	none	G	F	F	—	5	N		
IWT	1	12/11/89	Gr III Spondylo	ADS	PEEK	L4-S1	L5-S1	none	G	G	G	—	5	N		
SRD	3	1/05/90	Failed PLIF	ADS	PEEK	L2-S1	L4-L5	L2-L4	G	G	G	4	5	N		
MK	2	1/08/90	Stenosis at fusion	ADS	PEEK	L4-S1	L5-S1	none	G	G	F	—	5	Y	Remove VSP	
MS	2	1/15/90	Spondylo	ADS	PEEK	L2-S1	L2-L3	L4-L5	F	F	G	4	5	N		
JB	0	1/19/90	Dislocation L5-S1	ADS	PEEK	L4-S1	L5-S1	none	F	G	G	—	5	Y	Myelographic block	
MJD	0	1/19/90	D-Spondylo	ADS	PEEK	L4-S1	L5-S1	L4-L5	E	E	E	3	5	N		
FA	5	1/31/90	Failed PLIF	ADS	PEEK	L4-S1	L5-S1	none	E	E	E	—	5	N		
EEH	0	2/21/90	L-Spondylo	ADS	PEEK	L4-S1	L5-S1	L4-L5	E	E	E	2	5	N		
HF	0	3/07/90	D-Spondylo	ADS	PEEK	L4-L5	L4-L5	none	E	E	G	—	5	N		
RJL	1	3/07/90	Post-discectomy	ADS	PEEK	L4-S1	L4-S1	none	F	G	G	—	5	N		
MP	1	3/13/90	Failed Perk	RSB	PEEK	None	L5-S1	none	—	E	E	—	5	N		
LH	1	3/14/90	Post-discectomy	RSB	PEEK	None	L5-S1	none	F	F	F	—	5	N		
DER	1	3/19/90	Failed chymo-papain	ADS	PEEK	L4-S1	L5-S1	L4-L5	E	E	E	4	5	N		
AG	1	3/19/90	D-Spondylo	ADS	PEEK	L2-L5	L3-L4	L4-L5	E	E	E	5	5	N		
DEL	2	3/30/90	Failed Zielke	ADS	PEEK	L2-L1	L4-L5	L3,L5	P	P	P	2	5	N		
SED	2	4/18/90	Post-discectomy	JWB	PEEK	L3-S1	L3-S1	none	E	E	E	—	5	N		
DDD	0	4/25/90	D-Spondylo	JWB	PEEK	none	L4-L5	none	G	G	G	—	4	N		
DC	3	7/09/90	Failed PLIF	ADS	PEEK	T12-S1	L5-S1	none	P	P	E	—	?	N		
JC*	0	7/09/90	Burst fx L1	JWB	UPEK	none	T12-L2	none	E	E	E	—	5	N		

\*Indicates anterior interbody fusion with large oval cage.

Clinical result: E = excellent; G = good; F = fair; P = poor.

Cage material: PEEK = carbon fiber in PEEK; UPEK = carbon fiber in Ultrapek.

Fusion result: 1 = collapse of construct; 2 = probable pseudarthrosis; 3 = fusion status radiographically uncertain; 4 = probable radiographic fusion; 5 = radiographic fusion.

Surgeon: ADS = Arthur D. Steffee; JWB = John W. Brantigan; RSB = Robert S. Biscup.

*all PEEK implants made by TOL-DIE stop in Ontario with PEEK wfs. from*

*101*

of 28 (100%) followed levels treated with the rectangular PLIF cage. In the same patients, PLIF with ETO-sterilized donor bone achieved radiographic fusion in 6/11 (54.5%). The difference in fusion rates is significant at the P = 0.0002 level by the chi-square test. In seven patients the carbon cage was used to treat pseudarthrosis from failed ETO donor bone PLIF or ALIF. In one patient, we could not obtain a follow-up roentgenogram. The other six failed PLIFs treated with the carbon cage resulted in successful fusion.

Clinical results at 1 and 2 years are given in Table 4. At 2 years, 10/26 patients were excellent, 10/26 good, 3/26 fair, and 2/26 poor clinical results. Results improved slightly during the second postoperative year. At 24

months, one patient was lost to follow-up, but had been excellent at previous examination.

Of the poor clinical results, each had a clearly demonstrable reason for failure unrelated to the carbon cage. Patient PR originally had a burst fracture at L1. She had four prior procedures by other surgeons, including interbody fusions at L4-5 and L5-S1 using bovine bone. She had a fifth surgery by A.D.S. to repair the two-level failed ALIF. This surgery included resection of pedicles at L5, osteotomy at L5 joining the bodies of L4 and L5, a carbon cage interbody fusion at L3-4, and an ETO allograft interbody fusion at L2-3. At follow-up she continued to have back pain, her allograft PLIF level was not healed, and her long fusion ended at two cephalad

**Table 2. Description of Excellent, Good, Fair, and Poor Surgical Results by Author**

Author	Excellent Result	Good Result
Henderson, 1966	Returns to former occupation; no pain or minimal pain; sports or recreational activities unrestricted	Returns to former occupation; occasional pain not persisting more than 12 hours; not restricted from "less strenuous sports"
Ma, 1985	Returns to original work; regular activities; minimal medication; occasional episodes of pain; no neuro. deficits, fusion solid by X-ray	Returns to original work; resumes regular activities; takes occasional medication for episodes of back or leg pain, no neuro. deficits, radiographic solid or questionable fusion
Naylor, 1974	No complaints whatsoever and no residual ill effects	Relief of the major symptom of pain but with minor residual symptoms such as numbness, paresthesias, minor backache
Spengler, 1990	(no excellent category acknowledged)	Relief of most (76-100%) of back pain; able to return to previous work; minimal limitation of activities, minimal medications
White, 1987	Complete recovery, free of all limitations, never have pain greater than mild pain patient aware of but not bothered by	Return to full activities, sports, the same job or prophylactic limitation to light work; 70% relief of pain; no daily habituating medications
Prolo, 1986	No pain or minimal pain, able to participate in full activities and work (score 9 or 10)	Mild pain with some strenuous activities limited by pain (Score 7 or 8)
	Fair Result	Poor Result
Henderson, 1966	Restricted to lighter work; sports and recreational activities restricted; less pain the pre-op but pain still a problem	Unable to work; pain level no better than pre-operatively
Ma, 1985	Returns to original or lighter work; some limitation of activities; occasional medication; more frequent back or leg pain; minor neuro deficit; fusion questionable or pseudarthrosis	Changes to lighter work or disabled; limitation of activities; frequent medication, incapacitating pain or neuro deficit, pseudarthrosis by XR
Naylor, 1974	Improved; relief of the major pain symptom but with residual paresthesias, numbness, or backache requiring further treatment	(failure); no relief
Spengler, 1990	Partial relief of pain (26-75%); able to return to previous work with limitations or lighter work, activities limited, meds used frequently	Little or no relief (0-25%) of pain, disabled for work, activities greatly limited, strong analgesic or narcotic medication used frequently
White, 1987	Patient able to work but at lighter capacity; less than 70% pain relief; activities limited; occasional episodes of severe pain; or daily pain meds.	No improvement or worsening; 25% or less subjective relief of pain, episodes of severe pain; disability; or reoperation
Prolo, 1986	Moderate continuing pain with severe episodes, some limitation of non-strenuous activities (Score 5 or 6)	No improvement or worsening of pain, disability, marked limitation of all activities (Score 2, 3, or 4)

damaged disc levels related to an old burst fracture at L1. She subsequently has had several further surgeries. Clinical expectations for her are limited. Patient DEL has a poor result, but has failure of an ETO PLIF level at L3-4, above the carbon cage level.

Of the fair results, Patient MSC has collapse of the L4-5 disc above the cage fusion. Patient MK was working full-time at 12 months as a high school teacher and wrestling coach. He stopped work because of leg symptoms of reflex sympathetic dystrophy; however, he plays golf twice a week. His 24-month clinical status was Fair. Patient LH claims minimal improvement from surgery, but function level is high, examination is benign, roentgenogram shows good fusion. He is illiterate and alcoholic, and social dysfunction may be a significant factor in his result.

Complications were minimal. There were no surgical infections. One patient had postoperative numbness caused by damage to sensory fibers of one nerve root. There were no cases of motor deficit in these cases and no cauda equina syndromes. Incidental durotomy (i.e., dural tears) occurred in several patients; however, there were no cases of postoperative cerebrospinal fluid leakage, no requirement for secondary dural repair, and

no prolongation of hospitalization. There were no cage device-related complications, no removals of the cage, or revisions of the cage interbody fusion. No retropulsion or change in position of any cage was noted in any patient.

Reoperations were done in 5/26 patients, 3 within the 12-24-month interval. In Patient EC, a failed ETO PLIF was further revised to a carbon cage. Patient GMP had removal of one VSP plate, then piriformis tendon release because of residual nerve pain. At 1 year, she had some residual nerve discomfort but still had a good clinical result. Patient PR had a series of reoperations summarized in the clinical summary. Patient MK had removal of VSP and nerve root foramenotomy. A fragment of bone from the posterolateral fusion was found to be compromising the neural foramen at the L5 root. Patient JB was re-explored for a myelographic block at L4-5, one level higher than the L5-S1 cage fusion. She had been treated for a traumatic dislocation at L5-S1 and was found to have the cage fusion solidly healed in anatomic position but had bony arachnoiditis above the fusion. In retrospect, her preoperative cage myelogram showed the bony arachnoiditis. Her clinical result was substantially improved by her surgery.

# Explore Litigation Insights

Docket Alarm provides insights to develop a more informed litigation strategy and the peace of mind of knowing you're on top of things.

## Real-Time Litigation Alerts



Keep your litigation team up-to-date with **real-time alerts** and advanced team management tools built for the enterprise, all while greatly reducing PACER spend.

Our comprehensive service means we can handle Federal, State, and Administrative courts across the country.

## Advanced Docket Research



With over 230 million records, Docket Alarm's cloud-native docket research platform finds what other services can't. Coverage includes Federal, State, plus PTAB, TTAB, ITC and NLRB decisions, all in one place.

Identify arguments that have been successful in the past with full text, pinpoint searching. Link to case law cited within any court document via Fastcase.

## Analytics At Your Fingertips



Learn what happened the last time a particular judge, opposing counsel or company faced cases similar to yours.

Advanced out-of-the-box PTAB and TTAB analytics are always at your fingertips.

## API

Docket Alarm offers a powerful API (application programming interface) to developers that want to integrate case filings into their apps.

## LAW FIRMS

Build custom dashboards for your attorneys and clients with live data direct from the court.

Automate many repetitive legal tasks like conflict checks, document management, and marketing.

## FINANCIAL INSTITUTIONS

Litigation and bankruptcy checks for companies and debtors.

## E-DISCOVERY AND LEGAL VENDORS

Sync your system to PACER to automate legal marketing.