

# Three-dimensional imaging techniques: A literature review

Orhan Hakki Karatas<sup>1</sup>, Ebubekir Toy<sup>1</sup>

**Correspondence:** Dr. Orhan Hakki Karatas  
Email: drorhanhakkikaratas@gmail.com

<sup>1</sup>Department of Orthodontics, Faculty of Dentistry,  
Inonu University, Malatya, Turkiye

## ABSTRACT

Imaging is one of the most important tools for orthodontists to evaluate and record size and form of craniofacial structures. Orthodontists routinely use 2-dimensional (2D) static imaging techniques, but deepness of structures cannot be obtained and localized with 2D imaging. Three-dimensional (3D) imaging has been developed in the early of 1990's and has gained a precious place in dentistry, especially in orthodontics. The aims of this literature review are to summarize the current state of the 3D imaging techniques and to evaluate the applications in orthodontics.

**Key words:** 3D imaging, 3D scanning, orthodontic diagnosis, treatment planning

## INTRODUCTION

Over the years, orthodontic and dentofacial orthopedic diagnosis and treatment planning have relied essentially upon technological and mechanical supports such as imaging, jaw monitoring, and functional analyses. The goals of these techniques are to replicate or describe the anatomic and physiological facts exactly and to display the three-dimensional (3D) anatomy precisely.<sup>[1]</sup>

Imaging is one of the most important tools for orthodontists to evaluate and record size and form of craniofacial structures.<sup>[2]</sup> Orthodontists routinely use 2-dimensional (2D) static imaging techniques to record the craniofacial anatomy, but deepness of structures cannot be obtained and localized with 2D imaging. 3D imaging has been developed in the early of 1990's and has gained a precious place in dentistry, especially in orthodontics, and also in orofacial surgical applications. In 3D diagnostic imaging, a series of anatomical data is gathered using certain technological equipment, processed by a computer and later showed on a 2D monitor to present the illusion of deepness.<sup>[3]</sup>

Facial soft and hard tissues and dentition are 3 main sections, also named as triad, in orthodontics and

orthognatic surgery.<sup>[4]</sup> The triad has a significant function in planning of orthodontic treatment. Therefore, imaging of these structures is one of useful diagnostic tools for clinicians to make decision treatment modality.<sup>[5]</sup> 3D imaging for orthodontic purposes contain pre- and post-treatment evaluation of dentoskeletal and craniofacial relationships and facial appearance and beauty, inspecting treatment results in terms of soft and underlying hard tissues, and 3D treatment predictions. 3D dental, facial, and skeletal records for making diagnostic decisions and planning treatment are the other benefits of using 3D imaging in orthodontics.<sup>[6]</sup>

A large number of diagnostic methods have been developed to display facial structures and the dentition,<sup>[7-9]</sup> most of which were abandoned due to their various drawbacks. The most popular method of current medicine is possibly 3D imaging techniques giving detailed and problem-oriented information about soft and hard tissues, such as Computerized Tomography (CT), Cone Beam Computerized Tomography (CBCT), Micro Computerized Tomography (MCT), 3D laser scanning, structured light technique, stereophotogrametry or 3D surface imaging systems (3dMD), 3D facial morphometry (3DFM),

**How to cite this article:** Karatas OH, Toy E. Three-dimensional imaging techniques: A literature review. Eur J Dent 2014;8:132-40.

Copyright © 2014 Dental Investigations Society.

DOI: 10.4103/1305-7456.126269

Tuned-Aperture Computed Tomography (TACT), and Magnetic Resonance Imaging (MRI).<sup>[10-17]</sup>

The aims of this literature review are to present current state of the 3D imaging techniques and to evaluate the applications in orthodontics.

## HISTORICAL BACKGROUND

In 1895, discovery of X-rays by W. C. Roentgen opened a new era in medicine and dentistry. Thirty-six years later, standardized methods for the production of cephalometric radiographs were introduced to the dental specialists by Broadbent and Hofrath simultaneously and independently,<sup>[18]</sup> and it remained comparatively unaltered until recently. Broadbent emphasized the importance of the position and distance arrangements to achieve distortion-free radiographs when taking the lateral and posteroanterior cephalometric radiographs.<sup>[18]</sup> Cephalograms have been widely used in clinical implementations and as an investigation technique to evaluate growth and treatment responses. However, there are several disadvantages of 2-dimensional cephalometry as a scientific method. The fact that a conventional head films reduce 3D objects to 2-dimensional view is first and the most important reason. When 3D objects are displayed in a 2-dimension, structures displace as vertically and horizontally in proportion to their distance from the film.<sup>[19,20]</sup> Secondly, cephalometric analyses are based on an excellent superimposition of the left and right sides at mid-sagittal plane, but such superimposition is rarely observed because facial symmetry is infrequent. Third reason is that manual data collection and processing in cephalometric analysis have been shown to have low correctness and precision.<sup>[21]</sup> Finally, major errors in cephalometric measurements are associated with uncertainties in locating anatomical landmarks due to the deficiency of well-defined outlines, hard edges, and shadows as well as patient position.<sup>[19]</sup>

Beside these limitations, lots of cephalometric analyses have been developed to help diagnose skeletal and dental malocclusions and dentofacial deformities.<sup>[22,23]</sup> The quantitative errors associated with traditional 2D cephalometry have been substantial enough to make orthodontic diagnosis and treatment planning.<sup>[19,22-28]</sup>

Following the introduction of 3D imaging, clinicians have had great opportunity to evaluate anatomic structures 3-dimensionally in orthodontic practice. Several investigators conducted 3D imaging researches, and Singh and Savara<sup>[29]</sup> reported the

first 3D analysis about growth changes in maxilla. Computer softwares helped to collect and analyze 3D coordinates directly from digital cephalometric images, so that tracing manually and digitizing with mouse on screen were abandoned.<sup>[30,31]</sup>

3D imaging technique has been improved to use in different areas of health sciences. Being improved old photogrammetric techniques, stereophotogrammetry has been introduced to provide a more extensive and accurate assessments of the captured things. Using one or more converging pairs of views, a 3D model can be constructed and monitored from any perspectives and measured from any directions. In 1944, Thalmann-Degan recorded facial differences after orthodontic treatment. This was the earliest clinical report about stereophotogrammetry.<sup>[21]</sup> Computerized stereophotogrammetry has come into market as parallel to computer developments and has provided faster, more comprehensive and correct taking and constructing sequences.<sup>[32]</sup>

The first CT scanning device was developed around 40 years ago. After a short time, a stack of CT sectional images was used to obtain 3D information. At the beginning of 1980s, clinicians used 3D imaging in craniofacial deformities. For craniofacial surgical needs, first simulation software was introduced in 1986. Then, the principles and applications of 3D CT- and MRI-based imaging in medicine were published. A specific discipline was established on 3D imaging, dealing with different types of imaging, manipulation, and analysis of multi-dimensional medical structures.<sup>[32]</sup>

## 3D IMAGING METHODS

### Computed tomography (CT)

CT imaging, also called computerized axial tomography (CAT) imaging, uses special X-ray equipment to generate cross-sectional images of the body.

CT devices are divided into 2 groups: Cone beam and fan beam.<sup>[33]</sup> Using conventional fan beam CT devices, the X-ray source and detectors with the circular metal frame rotate around the patient. Patients are placed in a horizontal position on a table when CT scanner works. The table slowly passes through the center of a large X-ray machine. The procedure causes no pain, but some tests require a contrast material to make some parts of body appear better in the image.

CT scanner works as follows:

The patient is moved into circular opening of the CT imaging by a motorized table. When the patient is ready, the operator starts the CT imaging system, and a complete rotation of X-ray source and detector lasts about 1 second. The CT device generates a narrow, fan-shaped beam of X-rays scanning a section of the patient's body. A "snapshot" image was recorded and collected by a detector opposite from the X-ray source. The obtained data are transmitted to a computer for each turn of the scanner and detector. One or multiple cross-sectional images of the body parts were reconstructed.

The patient is usually scanned in the axial plane sections taken in succession; the desired image appears when these sections combined. CT can achieve 64 and/or 128 sections in advanced fan beam CT at a one time. The system is most expensive because the image is obtained by increasing number of sensors. However, this system can perform in less time and at a low dose shooting.<sup>[33]</sup> In this technique, due to the sectioning of tissues, organs are not superposed on each other.

Although CT scans are very high-priced and have high radiation dose to be suitable for a lot of orthodontic applications, the benefits outweigh the risks in certain situations. For example, treatment of craniofacial deformities may be insufficient with 2-dimensional diagnostic records. CT scans generate a very intensive data set that contains 3D information about soft and hard tissues. These data may be extremely precious for diagnostic point of view.

In addition, the usage area of CT is quite wide in dentistry, such as in the diagnosis of some pathologies, and even the contents of the boundaries (solid, liquid, Agar-Agar) in determining the salivary gland pathologies,<sup>[34]</sup> examination of the structure of the temporomandibular joint (TMJ),<sup>[35]</sup> TMJ ankylosis or fractures,<sup>[35]</sup> examination of the maxillary sinus,<sup>[36]</sup> orofacial trauma and fractures,<sup>[37]</sup> differences in airway volumes after rapid palatal expansion,<sup>[38]</sup> and implant applications.<sup>[39]</sup>

Some disadvantages of CT are:

- Expensive,
- Not available in every hospital,
- Skips lesions far away from the sections,
- Foreign objects like restoration and prosthetics create artifacts,
- In addition, CT data is insufficient compared with other soft-tissue imaging techniques.<sup>[40]</sup>

### Cone beam computerized tomography (CBCT)

Craniofacial CBCT devices [Figure 1] are designed to overcome some of the limitations of conventional CT scanning devices.<sup>[41]</sup> There are a lot of differences among the CBCT devices including patient positioning, scan time, resolution, radiation dose, and clinical ease of use of cross-sectional area.<sup>[42]</sup> In addition, while some CBCT devices scan all head area, others scan only the chin area.

With the cone-beam systems, dental therapists can achieve 3D (volumetric) data with very low radiation dose at one time.<sup>[43]</sup> At the same time, CBCT allows re-alignment of 2-dimensional images in coronal, sagittal, oblique, and various incline planes [Figure 2]. When we compare CBCT with CT, patients' visualization with less radiation dose is possible.<sup>[42,44]</sup> CBCT devices provide 15 times less radiation dose than conventional CT scanners do. The radiation dose of CBCT equals to a dose of average 12 panoramic radiographs.<sup>[11]</sup>

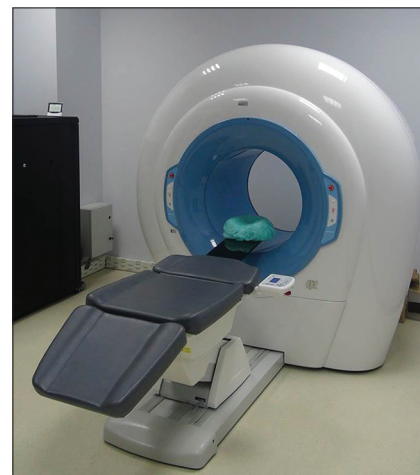

Figure 1: Cone beam computerized tomography for craniofacial imaging

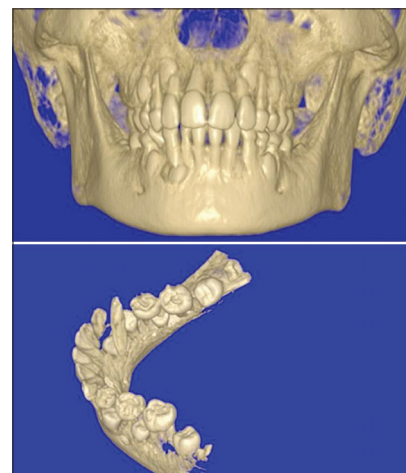


Figure 2: CBCT images of craniofacial structure obtained from various incline planes



In orthodontics, craniofacial images obtained with CBCT devices provide important information in different categories. Complex relation between treatment, development, and craniofacial data can be explained or data can be used as an independent solution for one and more of the following categories:<sup>[40]</sup>

- Determination of normal and abnormal anatomy
- Making decision on root length and alignment
- Jaw size and distance of examined teeth
- Determination of relationship between jaw size and examined teeth size
- Determination of 3D maxillo-mandibular relationship
- Determination of the status of the TMJ
- Determination of the effects of orthodontic treatment in craniofacial anatomy
- Detection and localization of impacted or supernumerary teeth.

The ability of providing 3D images of craniofacial structures with minimum amount of distortion has increased the availability of this technology.<sup>[11,40]</sup>

#### *Advantages of CBCT in orthodontics*

- a. Cost: CBCT devices have gained smaller size, thanks to technological developments. The cost of CBCT imaging is very low compared to computerized tomography. Image processing is easier because it is limited to the head and face. Maintenance cost of CBCT devices is much less
- b. Reduction of radiation dose: Referring to the results of the different studies, CBCT devices emit up to 98% less radiation. CBCT devices emit on average 36.9-50.3 microsievert ( $\mu\text{Sv}$ ) of radiation dose: On average, 1.320 to 3.324- $\mu\text{Sv}$  for the mandible and 1.031 to 1.420  $\mu\text{Sv}$  for maxilla
- c. Quick scan: With CBCT devices, all raw data are obtained in a single turn. In this way, the patient's length of stay is reduced and the device increases patient satisfaction
- d. Dimensional reconstruction feature: The most important advantage of CBCT is possible to display and arrange 3D data in personal computers
- e. Image processing: Various comprehensive softwares for implant placement and orthodontic measurements are available.

#### *Disadvantages of CBCT in orthodontics*

Cone beam geometry, sensor sensitivity, and contrast resolutions as well as some other limitations lead to some disadvantages in the CBCT technique:

- a. The main factor of weakness in image quality is image artifacts, such as metal brackets and restorations.

- b. The actual color of the skin and soft tissue images cannot be determined.<sup>[11]</sup>
- c. Unwanted patient movement may cause image disorder.
- d. Price of these devices is more expensive than conventional X-ray equipment, and these devices require more space.
- e. Radiation scattering may occur preventing of image monitoring.

CBCT has not only relatively limited capacity in displaying soft tissues, but also has an arguably place for investigation of hard tissue of the head and face.

#### *CBCT in orthodontic application*

##### *Impacted teeth and intraoral anomalies*

In determining position of the ectopic cuspids accurately, CBCT can be used for the establishment of therapeutic strategies to employ minimal invasive surgery.<sup>[45]</sup> Although the pathologies created by ectopic teeth and surrounding structures can be identified with conventional radiograph, the studies being conducted with CBCT scans give more accurate data regarding the actual relationships between impacted teeth and adjacent teeth, and possible root resorptions [Figure 2].<sup>[46]</sup>

Another application area of CBCT is to determine the position of oral abnormalities in patients. Previous studies showed that after using the CBCT, incidence of oral abnormalities has increased compared to the earlier studies.<sup>[45,47]</sup>

##### *The nasopharyngeal airway analysis*

CBCT technology has caused great progress in the nasopharyngeal airway analysis. While enlarging the airway is not a direct goal of orthodontic treatment, CBCT and lateral cephalographs are widely used for airway measurements. As a result, either surgical removal of the adenoids/tonsils or obstructive sleep apnea therapy due to narrow airways can be applied if necessary.

The potency of CBCT to measure airway volumes has helped orthodontists for studying in airway volume differences as a result of rapid palatal expansion<sup>[48]</sup> and premolar extraction.<sup>[49]</sup> In both studies, airways were found to be unchanged after orthodontic treatment.

In another study using lateral cephalograms and CBCT, there was a moderate difference in upper airway area and volume measurements of 11 patients.<sup>[33]</sup>

### Cleft lip/palate patients

Among different patient groups, CBCT is more important for individuals with congenital malformations.<sup>[50]</sup> Since the prevalence of cleft lip/palate (CL/P) is very high in population,<sup>[51,52]</sup> it is not unexpected that researches on CBCT imaging in orofacial deformities have concentrated on these patients. Since CBCT use in CL/P patients was found efficient in early clinical cases,<sup>[53]</sup> a great number of researchers estimated the alveolar cleft volume to assist pre-alveolar graft surgery.<sup>[54,55]</sup> The proper amount of graft material can be prepared via CBCT volumetric analyses to assure enough alveolar bone in CL/P patients. In addition, CBCT is also used for soft tissue evaluation of CL/P patients pre- and post-operatively.

Both conventional radiographs and CBCT imaging are principally used to assess mineralized tissues. Differences of nasal and labial tissues between the age-matched non-CL/P patients and CL/P patients without synchronous rhinoplasty and the CL/P patients with synchronous rhinoplasty were examined using CBCT. Nasal reconstruction conducted during primary lip repair is named as synchronous rhinoplasty. Based upon differences in soft tissue measurements from CBCT images among 3 groups, synchronous rhinoplasty is suggested to optimize nasal and labial appearance in CL/P patients.<sup>[56]</sup>

### Temporomandibular joint (TMJ) morphology

Condylar head size, shape and position, the joint space can be evaluated in CBCT. The condyle is viewed from only lateral side in lateral cephalometric films, but with CBCT, frontal and axial cross-sections can be displayed. However, since CBCT is not sufficient to view the soft tissues, examination of disk structures in TMJ is difficult.<sup>[57]</sup>

### CBCT image analyses

The front or profile photos can be converted to DICOM (Digital Imaging and Communications in Medicine) database with a new software programs. 3-dimensional view of the face can be created in any desired direction. Changing the image transparency, anatomic relationships between the hard and soft tissues can be defined. Changes in the appearance of the face after tooth movement, orthognathic surgery or other craniofacial treatment can be detected with CBCT image. In addition, models of images obtained from CBCT can be prepared with 3D Fotoscan devices.<sup>[58]</sup>

### Three-dimensional superposition

Images of cranial structures taken at different times can be superimposed on pre-defined points using the

3-dimensional software. Measurements performed on these images are imported to a computer, and then growth changes and treatment progress are evaluated. Thus, stability and post-treatment assessment can be made with the help of 3D superposition.<sup>[58]</sup>

In addition, CBCT provides information about root inclination and torque, bone thickness and morphology at the points where mini-screws are decided to be implanted and osteotomy sites during surgical planning.<sup>[59]</sup>

The positions of the mandibular and maxillary incisor roots, the amount of bone in the posterior maxilla for distalization, the amount of bone available for the maxillary buccal segments for dental expansions, neighborhood between maxillary sinus and maxillary teeth roots can be examined before and after selected treatment procedure.<sup>[60]</sup>

### Micro-computed tomography (MCT)

MCT is substantially the same as CT except that the reconstructed cross-sections are bounded to a much minor area [Figure 3]. 0.012 mm thin cross-sections can be taken with conventional CT, but MCT can be obtained with the nano-sized sections. MCT, a non-invasive and a non-destructive technique, is used for the analysis of mineralized tissues. The future of MCT lies in its capacity to sample input over a much minor volume than full body, considerably reducing the radiation exposure.

With the use of modern technology at X-ray sources and detectors, MCT devices have 10,000 times more resolution than medical CT scanners do.<sup>[61]</sup> The system has a micro focus X-ray source, a CCD camera, and a personal computer for control of the system. The X-ray radiation source with focal spot size of 10 mm is used to scan the objects. CCD camera provides high-resolution images. MCT gives important information about wound healing and micro vascular researches in orthopedics. The MCT devices are also used in researches related to endodontics, prosthetics, TMJ, and dental caries.<sup>[62,63]</sup> Current MCT scanning of bone has revealed accurate and precise information about



**Figure 3:** Micro-computed tomography for analysis of mineralized tissues with micro-sized sections

# Explore Litigation Insights

Docket Alarm provides insights to develop a more informed litigation strategy and the peace of mind of knowing you're on top of things.

## Real-Time Litigation Alerts



Keep your litigation team up-to-date with **real-time alerts** and advanced team management tools built for the enterprise, all while greatly reducing PACER spend.

Our comprehensive service means we can handle Federal, State, and Administrative courts across the country.

## Advanced Docket Research



With over 230 million records, Docket Alarm's cloud-native docket research platform finds what other services can't. Coverage includes Federal, State, plus PTAB, TTAB, ITC and NLRB decisions, all in one place.

Identify arguments that have been successful in the past with full text, pinpoint searching. Link to case law cited within any court document via Fastcase.

## Analytics At Your Fingertips



Learn what happened the last time a particular judge, opposing counsel or company faced cases similar to yours.

Advanced out-of-the-box PTAB and TTAB analytics are always at your fingertips.

## API

Docket Alarm offers a powerful API (application programming interface) to developers that want to integrate case filings into their apps.

## LAW FIRMS

Build custom dashboards for your attorneys and clients with live data direct from the court.

Automate many repetitive legal tasks like conflict checks, document management, and marketing.

## FINANCIAL INSTITUTIONS

Litigation and bankruptcy checks for companies and debtors.

## E-DISCOVERY AND LEGAL VENDORS

Sync your system to PACER to automate legal marketing.