

Review

Drug delivery to the nail following topical application

Sudaxshina Murdan *

Department of Pharmaceutics, The School of Pharmacy, University of London, 29-39 Brunswick Square, London WC1N 1AX, UK

Received 31 August 2001; received in revised form 10 December 2001; accepted 13 December 2001

Abstract

The absorption of drugs into the nail unit, following topical application to the nail plate, is highly desirable to treat nail disorders, such as onychomycosis (fungal infections of the nail). Nail permeability is however quite low and limits topical therapy to early/mild disease states. In this paper, the recent research into unguinal drug delivery is reviewed. The nail unit and the two most common diseases affecting the nail—onychomycosis and nail psoriasis—are briefly described to set the scene and to give an overview of the nature and scope of the problem. The factors, which affect drug uptake and permeation through the nail plate such as solute molecular size, hydrophilicity/hydrophobicity, charge, and the nature of the vehicle, are then discussed, followed by ways of enhancing drug transport into and through the nail plate. Finally, drug-containing nail lacquers which, like cosmetic varnish, are brushed onto the nail plates to form a film, and from which drug is released and penetrates into the nail, are reviewed. © 2002 Elsevier Science B.V. All rights reserved.

Keywords: Unguinal drug delivery; Nail; Nail lacquers; Topical application

1. Introduction

The human nail, equivalent to claws and hooves in other mammals, evolved as our manual skills developed and protects the delicate tips of fingers and toes against trauma, enhances the sensation of fine touch and allows one to pick up and manipulate objects. The nail is also used for scratching and grooming, as a cosmetic organ and sometimes, to communicate one's social status (Barron, 1970; Dawber and Baran, 1984; Chapman, 1986; Gonzalez-Serva, 1997). The nail plate is the most visible part of the nail apparatus,

consists of tightly packed dead cells and is highly keratinised. It is also very variable among individuals. The plates can be small, large, wide, narrow, hard, smooth, ridged, thin, etc.

Disorders of the nail unit range from relatively innocuous conditions such as pigmentation in heavy smokers, to painful and debilitating states where the nail unit can be dystrophied, hypertrophied, inflamed, infected etc. Such conditions affect patients physically as well as socially and psychologically and can seriously affect the quality of life. Many nail diseases are notoriously difficult to cure, need a long duration of treatment and relapse is common. Oral therapy has the inherent disadvantages of systemic adverse effects and drug interactions while topical therapy is limited by the low permeability of the nail plates.

* Tel.: +44-20-7753-5810; fax: +44-20-7753-5942.

E-mail address: sudax.murdan@ulsop.ac.uk (S. Murdan).

Topical therapy is an attractive option however, due to its non-invasiveness, drug targeting to the site of action, elimination of systemic adverse events and drug interactions, increased patient compliance and possibly reduced cost of treatment. Topical therapy can be optimised by the use of: (i) potent drugs to ensure that effective drug concentrations are achieved at the site of action; (ii) drugs with the correct physico-chemical properties for permeation into the nail plate; (iii) penetration enhancers to facilitate unguinal drug permeation; and by (iv) appropriate formulations which aid unguinal drug uptake, are easy to use, and which stay in contact with nail plates, releasing drugs continuously over long periods of time.

In their review on the topical delivery of anti-fungal drugs for onychomycosis treatment, Sun et al. (1999), have concluded that topical treatment of onychomycosis remains a drug delivery problem. In this paper, the research into drug delivery to the nail unit following topical application is reviewed, in an attempt to establish how topical therapy can be optimised. The nail unit and its most common disease states are briefly described to set the scene and understand the nature of the problem. Nail permeability to drugs is then discussed, with respect to factors that influence drug permeation and ways of enhancing unguinal drug

penetration, including the novel delivery vehicles, drug-containing nail lacquers. Finally, conclusions are drawn on how one can optimise topical drug delivery to the nail unit.

2. The nail unit

The nail apparatus, schematically shown in Fig. 1, is composed of the nail folds, nail matrix, nail bed and the hyponychium, which together form the nail plate (Zaias, 1990). The nail plate, produced mainly by the matrix, emerges via the proximal nail fold and is held in place by the lateral nail folds. It overlays the nail bed and detaches from the latter at the hyponychium (skin under the free edge of the plate). The nail plate is a thin (0.25–0.6 mm), hard, yet slightly elastic, translucent, convex structure and is made up of approximately 25 layers of dead, keratinised, flattened cells which are tightly bound to one another via numerous intercellular links, membrane-coating granules and desmosomes. The cells at the dorsal surface of the plate overlap (Fig. 2a) and produce a smooth surface. In contrast, the palmar surface of the nail plate is quite irregular (Fig. 2b). Fig. 2c shows a cross-section view of the nail plate. The latter can be divided into three macro-

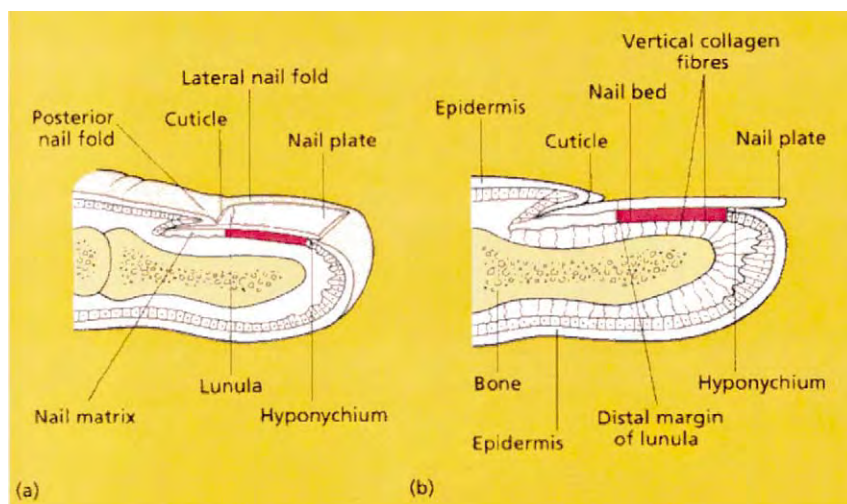


Fig. 1. Schematic structure of the nail apparatus. Reproduced from Ref. De Berker et al. (1995a), with kind permission from Blackwell Science Ltd.




Fig. 2. Scanning electron micrograph of: (a) the dorsal surface of human nail plate; (b) the nail undersurface; and (c) a cross-section view of the nail plate.

scopic strata—dorsal, intermediate and ventral. The dorsal layer is a few cells thick, while the intermediate plate is a softer, more flexible, thicker layer and accounts for the majority of the nail thickness. The ventral layer is very thin, consists of a few layers of cells and connects the nail plate to the nail bed. Kobayashi et al. (1999), calculated that the thickness ratio of each layer i.e. dorsal:intermediate:ventral is 3:5:2.

Chemically, the nail plate consists mainly of the fibrous proteins, keratins, 80% of which is of the 'hard' hair-type keratin, the remainder comprising the 'soft' skin-type keratin (Lynch et al., 1986).

The keratin fibres are oriented into three layers, which are associated with the dorsal, intermediate and ventral nail layers. The hair-like keratin filaments are only present in the intermediate nail layer and are oriented perpendicular to the growth axis, while the skin-type keratin filaments are found in the dorsal and the ventral layers and are oriented in two privileged directions, transverse and perpendicular to the growth axis (Garson et al., 2000). The keratin fibres are thought to be held together by globular, cystine-rich proteins whose disulphide links act as glue (Fleckman, 1997). The plate also contains water at 10–30%,

water content is directly related to the relative humidity and is important for nail elasticity and flexibility (Forslind, 1970; Baden et al., 1973). In contrast, the nail plate contains small amounts of lipid, between 0.1 and 1.0%, most of which is organised into bilayers oriented parallel to the nail surface and is concentrated in the ventral and dorsal nail layers (Walters and Flynn, 1983; Gniadecka et al., 1998; Kobayashi et al., 1999; Garson et al., 2000).

The nail plate is a fairly strong structure. Its hardness and mechanical rigidity is thought to be due to the sandwich orientation of the keratin fibres, the presence of globular proteins that provide the 'glue' to hold keratin fibres together, adhesiveness of nail cells to one another, physical and chemical stability of the nail proteins (conferred by the stable disulphide links), the design of the plate (which is curved in both transverse and longitudinal axes) and its water content.

The nail plate is formed by the nail matrix which is a highly proliferative epidermal tissue. It is also called the root of the nail, lies underneath the proximal nail fold and its distal portion is often visible through the transparent nail plate as a white, semilunar area, called the lunula. Cell division of the matrix results in the continuous formation of the nail plate, which grows throughout life. Growth rate is highly variable among individuals; average values of 3 mm per month (fingernails) and 1 mm per month (toenails) are used when treating nails. A normal fingernail grows out completely in about 6 months while a normal toenail in about 12–18 months (Fleckman, 1997). Nail growth rate is also highly influenced by age (ageing slows the rate), gender (rate is higher in males), climate (slower in cold climate), dominant hand (growth is faster), pregnancy (faster), minor trauma/nail biting (increases growth rate), diseases (can increase or decrease rate e.g. growth is faster in patients suffering from psoriasis and slower in persons with fever), malnutrition (slower rate) and drug intake (may increase or decrease) (Hamilton et al., 1955; LeGros, et al., 1938; Bean, 1980; Geoghegan et al., 1958; Hewitt and Hillman, 1966; Gilchrist and Dudley Buxton, 1938–39; Landherr et al., 1982; Sibinga, 1959; Dawber et al., 1994). As well as

growing in length, nail plates also grow thicker as they progress from the lunula to the free margin, and as ventral nail layers are added to the growing plate by the nail bed. This mechanism is thought to contribute to approximately 20% of the final nail mass. The thickening rate is slow and a mean value of 0.027 mm/mm nail length has been reported (Johnson and Shuster, 1993).

The nail plate adheres closely to and overlays the nail bed—a thin, soft, non-cornified epithelium, which extends from the lunula to the hyponychium. The nail bed acts as a holder and slide for the growing nail plate, as well as contributing to the growth of the nail plate as mentioned above. The nail bed, nail matrix and the tissues around the nail are well perfused by blood vessels (Flint, 1955; Hale and Burch, 1960; Samman, 1959). In addition, the nail bed has a rich supply of lymphatic vessels (Pardo-Castello, 1960).

3. Diseases affecting the nail and their treatment

Nails can suffer from a very wide range of disorders. For example, nails can be discoloured (e.g. by certain systemic drugs), rendered brittle (e.g. by chronic use of detergents), chronic trauma to toenails from ill-fitting shoes can lead to ingrowing nails, plates can thicken, be infected, lift off the nail bed, etc. Disorders of the nail may also reflect systemic diseases and may provide useful diagnostic clues. The two most common diseases affecting the nail unit are onychomycosis (fungal infections of the nail plate and/or nail bed) and psoriasis of the nails. In this review, these two disease states are briefly described for their high occurrence rate and for the fact that most of the research conducted into topical drug treatment of diseased nails has been focussed on these two conditions.

3.1. Onychomycosis

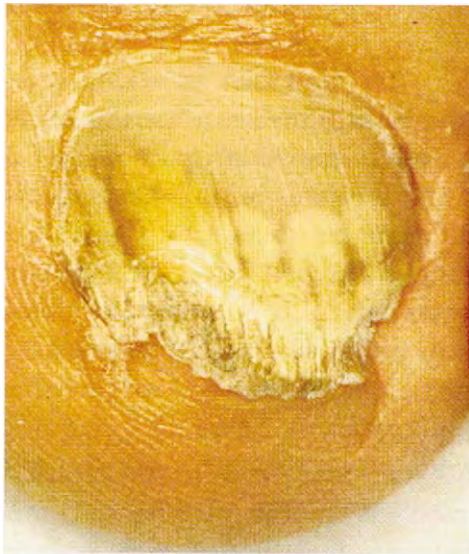
Onychomycosis, responsible for up to 50% of nail disorders (Ghannoum et al., 2000) is a very common problem, affecting 3–10% of the population in Europe, prevalence being higher in older

people (Roberts, 1999; Chabasse et al., 2000; Pierard, 2001). Occurrence seems to be on the increase due to a growing elderly population, the spread of HIV infection and AIDS, a higher frequency of iatrogenic immunosuppression due to the use of immunosuppressant drugs, lifestyle factors such as the wearing of tight-fitting clothing and shoes and the use of communal recreational facilities and healthclubs, as well as improved detection and higher public awareness (Gupta and Shear, 1997; Daniel, 1991; Scher, 1996; Cohen and Scher,

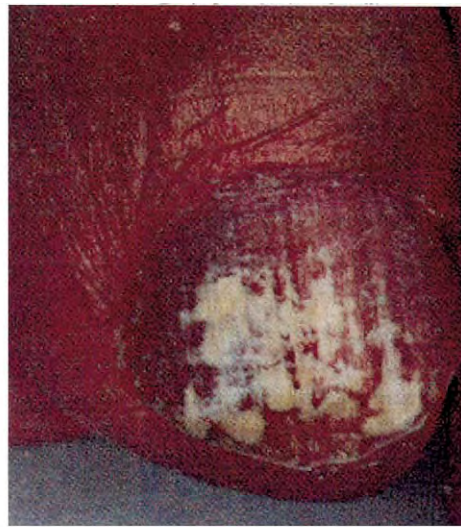1994). Most (90–95%) of the infections are caused by dermatophytes, the rest being caused by yeasts and moulds. Toenails are affected more than fingernails (Midgley et al., 1994). Toenail onychomycoses are also more recalcitrant and have to be treated for longer durations.

Clinically, onychomycosis can be divided into categories depending on where the infection begins:

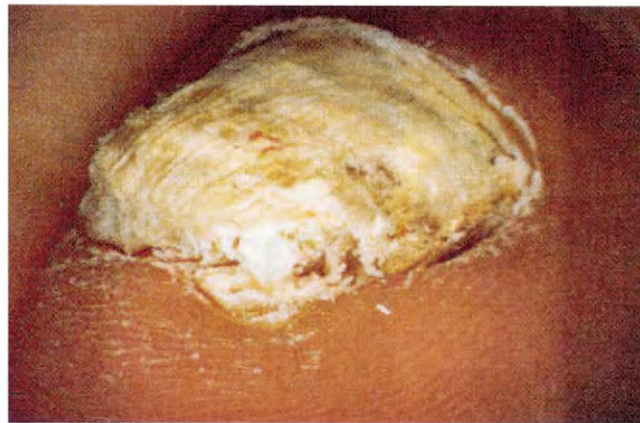- (i) *Distal and lateral subungual onychomycosis* (Fig. 3a): The fungal infection starts at the



(a)



(b)



(c)

Fig. 3. Onychomycosis: (a) distal and lateral subungual onychomycosis; (b) superficial onychomycosis manifested as white spots; (c) total dystrophic onychomycosis. Reproduced from Ref. De Berker et al. (1995b), with kind permission from Blackwell Science Ltd.

Explore Litigation Insights

Docket Alarm provides insights to develop a more informed litigation strategy and the peace of mind of knowing you're on top of things.

Real-Time Litigation Alerts



Keep your litigation team up-to-date with **real-time alerts** and advanced team management tools built for the enterprise, all while greatly reducing PACER spend.

Our comprehensive service means we can handle Federal, State, and Administrative courts across the country.

Advanced Docket Research



With over 230 million records, Docket Alarm's cloud-native docket research platform finds what other services can't. Coverage includes Federal, State, plus PTAB, TTAB, ITC and NLRB decisions, all in one place.

Identify arguments that have been successful in the past with full text, pinpoint searching. Link to case law cited within any court document via Fastcase.

Analytics At Your Fingertips



Learn what happened the last time a particular judge, opposing counsel or company faced cases similar to yours.

Advanced out-of-the-box PTAB and TTAB analytics are always at your fingertips.

API

Docket Alarm offers a powerful API (application programming interface) to developers that want to integrate case filings into their apps.

LAW FIRMS

Build custom dashboards for your attorneys and clients with live data direct from the court.

Automate many repetitive legal tasks like conflict checks, document management, and marketing.

FINANCIAL INSTITUTIONS

Litigation and bankruptcy checks for companies and debtors.

E-DISCOVERY AND LEGAL VENDORS

Sync your system to PACER to automate legal marketing.