

## Lymphoma development in a patient receiving anti-TNF therapy

*Haematologica* 2007; 88:(8)e108-e109

The development of a lymphoma after antibody therapy with anti-tumor necrosis factor (TNF) is described. A 70 year-old-male was admitted in February 2003, complaining of a painless growth on his upper right arm. The patient had been suffering from rheumatoid arthritis (RA) for the past 15 years and had been treated with low-dose corticosteroids and methotrexate for the previous 5 years. One year ago he was started on concurrent courses of therapy with the humanized monoclonal anti-TNF antibody, adalimumab.<sup>1</sup> On examination the growth had two areas of palpable masses. The patient's face was edematous and the upper anterior chest wall showed distended collateral superficial veins. His neck veins were also dilated. The soft palate, Waldeyer's ring and the rhinopharynx were edematous. The parotid glands were enlarged and the presence of a submaxillary lymph node of 3 cm was evident. The remainder of the physical examination proved negative. His white blood cell count was 12,300/L with 66% neutrophils, 31% lymphocytes and 3% monocytes. A few atypical lymphocytes with scanty cytoplasm and irregular nuclear contours and inconspicuous nuclei were present. A bedside diagnosis of superior vena cava syndrome (SVCS) was made. The diagnosis was confirmed by a computed chest tomography (CT), which further revealed mild mediastinal lymphadenopathy (Figure 1, right hand side). Magnetic resonance imaging (MRI) of the right arm revealed two soft-tissue masses, the larger having a diameter of 16cm, being discretely separated from the underlying biceps brachii muscle (Figure 1, left hand side). Gastroscopy, colonoscopy and abdominal CT scan were negative. Bone marrow biopsy revealed 20% infiltration of monoclonal CD5+, CD23-, CD19+, CD20+, cyclin D1+ B-lymphocytes, consistent with a mantle cell lymphoma (MCL) phenotype. The histologic examination of soft-tissue and node biopsies also revealed MCL, an aggressive lymphoproliferative disorder with distinctive clinicopathologic features, accompanied by the characteristic cytogenetic abnormality, t(11;14)(q13;q32). A minor salivary gland biopsy did not reveal lymphocytic infiltration compatible with Sjogren's syndrome or non-Hodgkin's lymphoma (NHL). The patient received combination therapy with rituximab (anti-CD20 monoclonal antibody), mitoxantrone and fludarabine with improvement of all signs and symptoms. This is the first report in the literature of adalimumab-associated NHL. The factors predisposing to lymphoma development and the atypical presentation of MCL are the main points of this case. Although chronic antigenic stimulation contributes to an increased risk of lymphoma development, the prevalence of NHL in RA in the absence of immunosuppressive treatment is low.<sup>2</sup> Furthermore, RA patients

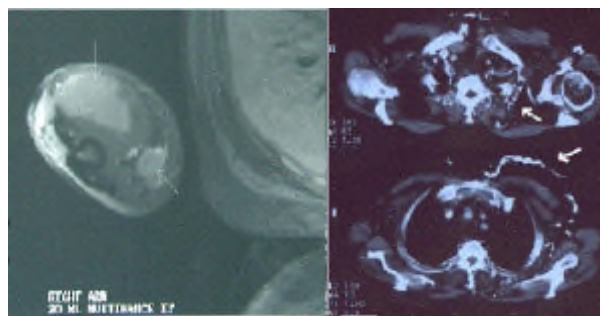


Figure 1, Left: MRI of the right arm showing two soft tissue masses (arrows).

Figure 1, Right: CT of the chest showing dilated collateral veins (arrows).

ative disorders that share similar characteristics with those NHLs described in immunosuppressed patients.<sup>3</sup> Despite the controversy about the occurrence of NHL induced by low-dose MTX therapy in RA patients, the characteristics of these lymphomas and the possibility of a complete remission after MTX withdrawal militate against a chance association.<sup>4</sup> Recently 21 cases of NHLs were reported in patients with RA or Crohn's disease following treatment with infliximab and etanercept, agents which inhibit TNF alpha activity.<sup>5</sup> The known immunosuppressive effect of the anti-TNF drugs and the well established predisposition to lymphoma development in immunosuppressed transplant recipients could explain the potential risk of an anti-TNF induced lymphomatogenesis. MCL commonly presents as an extranodal disease involving multiple sites such as bone marrow the gastrointestinal tract, central nervous system and salivary glands. However, extranodal soft-tissue involvement, mimicking sarcomas as well as SVCS are extremely rare manifestations.<sup>6</sup> In conclusion, patients with RA receiving immunosuppressive and biological therapies such as anti-TNF reagents should be monitored closely for lymphoma development, taking into consideration that the clinical picture may be characterized by atypical, extranodal manifestations.

P.D. Ziakas, S. Giannouli, A.G. Tzioufas, M. Voulgarelis

Correspondence: Dr M. Voulgarelis,

Department of Pathophysiology, Medical School, National University of Athens, M. Asias 75, Goudi, 11527 Athens, Hellas.

Tel : 32-10-7462512-14, Fax: 32-10-7462664

Acknowledgment: Our thanks to Prof. H.M. Moutsopoulos for his guidance, recommendations and continuous support

### References

- Weinblatt ME, Keystone EC, Furst DE, et al. Adalimumab, a fully human anti-tumor necrosis factor alpha monoclonal antibody, for the treatment of rheumatoid arthritis in patients taking concomitant methotrexate: the ARMADA trial. *Arthritis Rheum* 2003;48:35-45.
- Hakulinen T, Isomaki H, Knekt P. Rheumatoid arthritis and

- Finland. *Am J Med* 1985;78 (1A):29-32.
3. Kamel OW, van de Rijn M, Hanasono MM, et al. Immunosuppression-associated lymphoproliferative disorders in rheumatic patients. *Leuk Lymphoma* 1995;16:363-8.
  4. Mariette X, Cazals-Hatem D, Warszawski J, et al. Lymphomas in rheumatoid arthritis patients treated with methotrexate: a 3-year prospective study in France. *Blood* 2002;99:3909-15.
  5. Brown SL, Greene MH, Gershon SK, et al. Tumor necrosis factor antagonist therapy and lymphoma development: twenty-six cases reported to the Food and Drug administration. *Arthritis Rheum* 2002;46:3151-8.
  6. Argatoff LH, Connors JM, Klasa RJ, et al. Mantle cell lymphoma: a clinicopathologic study of 80 cases. *Blood* 1997;89:2067-78.