

# Treatment of acne vulgaris

Rebecca Nguyen

John Su

## Abstract

Acne vulgaris is a disorder of the pilosebaceous unit, characterized by comedones, inflammatory lesions and scars on the face and trunk. It presents a significant financial burden to the community and its psychosocial impact can be severe, life-altering and even life-threatening. Effective treatment can reduce the burden of disease but poorly considered therapy can be ineffective, costly and may also worsen non-compliance. In the management of acne, it is important to identify triggers, such as drugs, endocrinopathies and topical agents. Comedonal acne can respond well to topical retinoids. Mild to moderately inflammatory acne is usually initially treated with combination topical therapy, sometimes adding an oral antibiotic. Anti-androgen therapy can be helpful in females with seborrhoea and premenstrual flaring of acne. Isotretinoin remains a very effective treatment for potentially scarring and refractory acne, but new possible adverse effects have been recently described. Treatment regimens should accommodate individual patient considerations, duly noting limitations and potential adverse effects of all therapeutic options.

**Keywords** acne vulgaris; acneiform eruptions; depression; follicular occlusion; inflammatory bowel disease; isotretinoin; oral contraceptive pill; topical antibiotics; topical retinoids

## Introduction

Acne vulgaris is a disorder of the pilosebaceous unit resulting in the formation of comedones, inflammatory papules, pustules, nodules, cysts and scars. It affects the face and trunk, most commonly presenting in puberty. In a cross-sectional study of 16-year-olds, acne prevalence was 94.4% for males and 92% for females, with 14% having moderate to severe acne. The prevalence of acne after 25 years of age is 10% and after 40, 1% in men and 5% in women. In the UK in 1992, there were 3.5 million general practice consultations for acne reflecting a significant health burden on the National Health Service.

## Epidemiology

Several twin studies suggest familial clustering and a genetic predisposition to acne. Environmental factors can affect the severity of disease. Recent studies suggest that increased *milk consumption* is weakly associated with increased acne severity. It

**Rebecca Nguyen MB BS** is a Dermatology resident in the Department of Dermatology, at Box Hill Hospital, Victoria, Australia. Conflicts of interest: none.

**John Su MB BS M Epi FRACP FACD** is Head of Dermatology, Eastern Health, level 2, 5 Arnold St, Box Hill, 3128 Victoria, Australia, in the Department of Paediatrics, University of Melbourne, and the Department of Medicine, Monash University, Victoria, Australia. Conflicts of interest: none.

is unlikely to be related to the fat content of milk. However, the roles of hormones and IGF-1 in milk products require clarification. More convincingly, *high glycaemic diet* has been linked to increased acne lesion counts, increased free androgen index and impaired insulin sensitivity, but larger, randomized studies are lacking. There is no conclusive evidence that chocolate intake is related to acne. The effects of omega-3 fatty acids, antioxidants, dietary fibre, vitamin A and zinc require further study. Two studies have shown *stress* during exam periods can exacerbate acne severity but have no increase in sebum production. No correlation between exercise and truncal acne has been demonstrated.

## Pathogenesis

There are four processes in the pathogenesis of acne:

1. Increased sebum production;
2. Perifollicular hyperkeratinization and follicular obstruction;
3. Colonization with *Propionibacterium acnes*;
4. Release of enzymes which induce humoral and cell mediated inflammations.

Sebum production depends on local androgen levels and androgen sensitivity. Two subtypes of 5-alpha-reductase convert testosterone to the more active dihydrotestosterone (DHT): type 1 isozyme is expressed in the scalp, chest and sebaceous glands, whereas type 2 isozyme is expressed in genitourinary tissue, dermal papillae and hair follicles. DHT stimulates sebum production by sebocytes.

Androgens, lipids, bacteria and cytokines induce hyperkeratinization and hyperproliferation of keratinocytes. This results in follicular obstruction forming microcomedones.

*Propionibacterium acnes*, a gram positive anaerobic commensal, (a) produces lipases, proteases and hydrolases contributing to inflammation and tissue destruction, (b) expresses stress proteins responsible for comedonal rupture and (c) possibly binds toll-like receptors on keratinocytes to increase production and release of pro-inflammatory cytokines like Interleukin (IL)-1.

IL-1 is thought to stimulate hyperkeratinization, cell adhesion, follicular obstruction and further inflammation. Other cytokines like TNF, IL-2 and IL-6 are released and the corticotropin releasing hormone (CRH) system is stimulated. CRH, CRH binding protein (CRHBP) and CRH receptor are expressed in human sebocytes in vitro. CRH up-regulates 3-beta hydroxysteroid dehydrogenase, which converts dehydroepiandrosterone (DHEA) to testosterone, and stimulates sebocyte lipogenesis and differentiation. CRHBP reduces the ability of CRH to dissolve into the systemic circulation, therefore increasing its local epidermal effect. CRH receptor-2 has increased expression in acne and may mediate increased sebum production. Melnik et al. suggested that a relative deficiency of the nuclear transcription factor FoxO1 might underlie all pathogenic pathways of acne.

## History

Important points in the history include the age of onset, distribution and nature of lesions (comedones, inflammation and the scars), disease progression, possible triggers and relieving factors. Extreme seborrhoea, a positive family history or early disease onset, and rapidly progressive, extensive, persistent, or scarring disease may warrant more aggressive therapy.

Symptoms of hyperandrogenism include premenstrual flaring of acne, seborrhoea, hirsutism, deepening of the voice, increased

libido, clitoral enlargement, menstrual changes and precocious puberty. The presence of these symptoms may require further investigation and consideration of anti-androgen therapy in females.

Past treatment responses and side effects will affect the choice of future therapy. An accurate quantification of past medication usage may reflect the patient's tendency to compliance. The potential for child-bearing is important to note as many acne treatments are teratogenic. Concerns have been raised about possible links between isotretinoin and depression, inflammatory bowel disease and night vision impairment; so relevant risk factors should be sought. A social history will help clarify the affordability of treatments, patient motivation and disease burden.

Drugs, cosmetics and topical agents can cause an acneiform eruption characterized by monomorphous pustules and papules without comedones. Common drugs include steroids, bromides, iodides, lithium, phenytoin, epidermal growth factor receptor inhibitors, isoniazid, high dose vitamin B, olanzapine and amineptine.

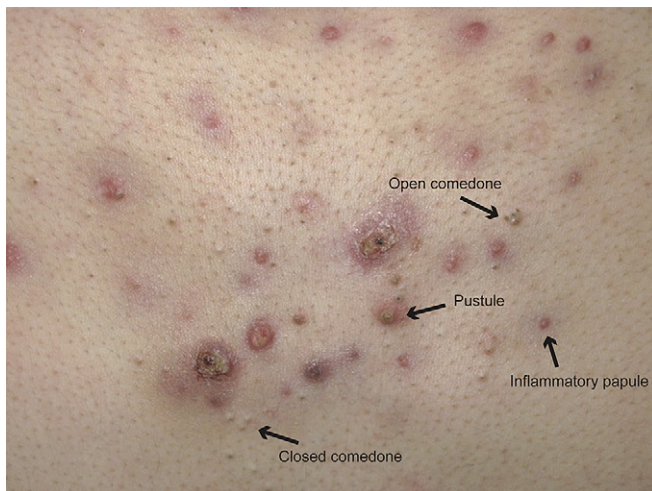
### Examination

Acne most commonly affects the face, especially the T-zone, and trunk. Non-inflammatory lesions include open, "black" comedones (papules with central darkened impaction) and closed, "white" comedones (flat, pale papules). Inflammatory lesions include papules, pustules and nodules (Figure 1). Secondary bacterial infection (e.g. *Staphylococcal aureus*) may rarely increase crusting and inflammation.

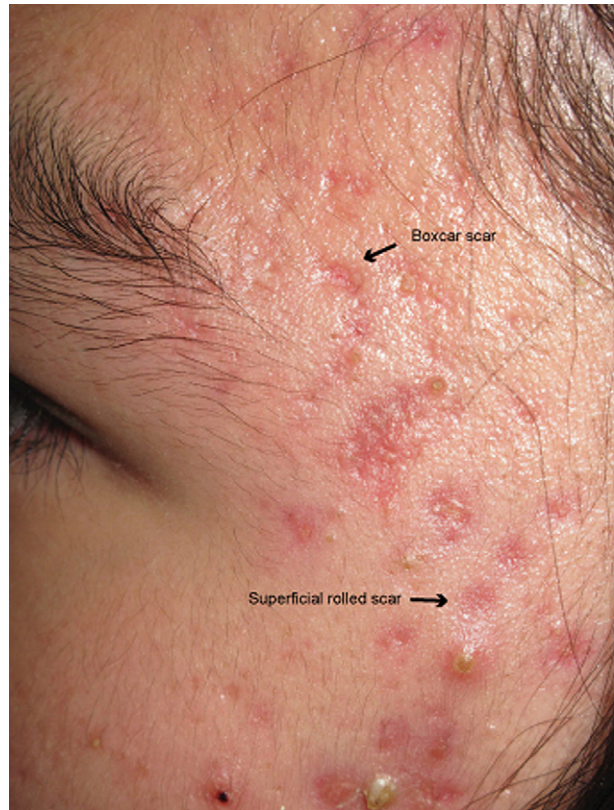There are five main types of scars. Ice-pick scars are narrow, tapering deeply into the dermis. Rolling scars are wide and shallow. Boxcar scars are well demarcated, punched out depressions (Figure 2). Hypertrophic and keloid scars are raised, the latter extending beyond the area of original inflammation. Perifollicular elastolysis presents as truncal follicular atrophy.

Despite inter-observer and intra-observer variability, grading the severity of acne can be useful for monitoring response to therapy. The Leeds-Cunliffe technique is a facial photo-numeric scale that assigns a number from a manual to the patient's presentation. Serial photography is also helpful.

Psychological assessment is pertinent for those with severe scarring, acne excoriée and dysmorphophobia.



**Figure 1** Comedones, papules and pustules in mixed comedonal and inflammatory acne.



**Figure 2** Common acne scars.

Signs of possible hyperandrogenism include, (1) late onset, severe acne, (2) marked seborrhoea, (3) acanthosis nigricans (HAIR-AN syndrome), (4) dysmenorrhoea and infertility (polycystic ovary syndrome), (5) dyslipidaemia and diabetes (HAIR-AN, PCOS) and (6) Cushingoid habitus (Cushing's syndrome). Androgen secreting tumours may present with precocious puberty, prominent male external genitalia, deepening of voice, pubic hair growth and a testicular or ovarian mass. 33% of the non-classical forms of congenital adrenal hyperplasia present with prepubescent acne, precocious puberty, rapid growth and amenorrhoea.

### Acne variants

#### Acne infantum

Infantile acne presents at 3–6 months with facial acne from transient high levels of DHEA in infancy produced by trans-placental stimulation of the adrenal gland. Although therapeutic agents resemble those used in adult acne, tetracyclines and anti-androgens should not be used.

#### Acne cosmetica

Comedogenic cosmetics can cause adult-onset acne. Common culprits are *moisturizers* (lanolin alcohol and myristyl acetate), *sunscreens* (isopropyl myristate and octyl palmitate), *facial cleansers* (isopropyl palmitate and lanolin) and *face powders* (cocoa butter). Resolution usually occurs with cessation of cosmetics.

#### Acne excoriée

Compulsive scratching can complicate mild acne, notably in young adult females with psychological morbidity. Excoriations can be a few millimetres in diameter and may weep, crust or

scar. It presents in 2% of dermatology acne patients. Treatments, including antidepressants, antipsychotics and mood stabilizers, show variable success.

#### Acne agminata

Acne agminata presents as a papulopustular eruption that affects the cheeks, periorbital region, eyelids and occasionally limbs. It lasts 2–6 weeks and often resolves with scarring. Histology shows sterile dermal granulomata with central caseous necrosis. It is unrelated to mycobacterium infection, but of unknown cause.

#### Severe variants

##### Acne conglobata

Acne conglobata presents as severe nodulocystic acne, with nodules and abscesses on the trunk and buttocks, less commonly on the face. It shares the pathogenesis of follicular occlusion and rupture with dissecting cellulitis, hidradenitis suppurativa and pilonidal sinus. Management involves systemic and intralesional steroids, antibiotics, cautious surgical debridement and isotretinoin.

##### Acne fulminans

Sudden rupture of microcomedones with widespread necrosis can result in painful, sterile, haemorrhagic nodules and plaques, leading to truncal and facial ulcers and severe scarring. Usually occurring in males, acne fulminans can be associated with

leukocytosis, raised inflammatory markers, hepatosplenomegaly, raised liver enzymes, arthropathy, erythema nodosum and osteolysis. Histology shows dermal abscesses, epidermal necrosis and a mixed granulocytic and lymphocytic infiltrate. Treatment includes warm compresses, surgical debridement, topical, intralesional and systemic steroids, isotretinoin and antibiotics.

#### Pyoderma gangrenosum and acne

There are reports of pyoderma gangrenosum with acne that do not fit the criteria of SAPHO or PAPA syndrome (Figure 3). They may represent incomplete syndrome variants or have an alternative underlying immunopathology.

#### Solid facial oedema

This is a rare condition presenting with persistent, symmetrical, non-pitting, painful oedema of the glabellar, periorbital and nasal regions on a background of acne. Treatment includes surgical debridement, oral and topical steroids, antibiotics and isotretinoin.

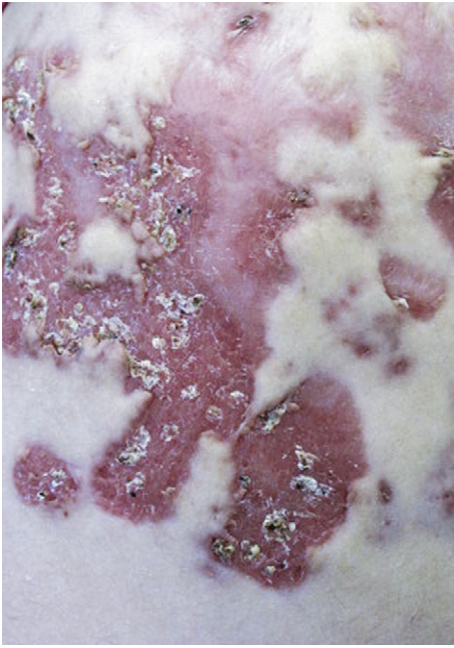
#### Differential diagnosis

##### Chloracne

Aromatic halogenic hydrocarbons found in coal tar derivatives, cutting oils, fungicides, insecticides and wood preservatives can cause chloracne through dioxin exposure. Chloracne presents as sterile, polymorphous, large comedones and cysts involving the retroauricular and malar areas, but also the axillae and groin. It is associated with xerosis, variable hypertrichosis, pigmentation

#### Syndromes associated with acne

Syndrome	Aetiology	Skin signs	Other signs	Treatment
Apert syndrome (acrocephalosyndactyly type 1)	Autosomal dominant New missense in FGFR2 with androgen sensitivity	Acne (severe, widespread): buttocks, forearms) Seborrhoea Hyperhidrosis Nail dystrophy Hypopigmentation	Early epiphyseal closure Craniofacial deformity, Hypertelorism, Proptosis, Prognathism, Dental disorders	Isotretinoin
Behcet syndrome		Aphthous and genital ulcers Pustulosis Acne Folliculitis Erythema nodosum Pathergy	Uveitis Iritis Vasculitis Arthritis	Immunomodifiers: Steroids Colchicine Dapsone Interferon alpha Azathioprine TNF inhibitors Thalidomide
PAPA syndrome	Autosomal dominant CD2BP1 gene mutation	Pyoderma gangrenosum Acne conglobata	Pyogenic arthritis	Tetracyclines Isotretinoin Immunomodifiers TNF/IL-1 inhibitors
SAPHO syndrome		Acne fulminans and conglobata Palmoplantar pustulosis Hidradenitis suppurativa Psoriasis	Synovitis Hyperostosis Osteitis	Nonsteroidal antiinflammatories Steroids Oral antibiotics Topical retinoids Isotretinoin



**Figure 3** Acne and pyoderma gangrenosum complicating IBD.

and palmoplantar hyperhidrosis. There may be neuropathy, impotence, hyperlipidaemia and liver and eye disease. Skin changes are persistent and resistant to oral isotretinoin. Topical retinoids, oral antibiotics and gentle cautery can help, but prevention of exposure to dioxins is critical.

#### Gram-negative folliculitis

With long-term oral antibiotic treatment, gram-negative folliculitis can develop, presenting as a persistent, papulopustular, acneiform eruption resistant to conventional therapies. Common bacteria cultured are *Escherichia coli*, *Klebsiella* and *Proteus* species. Ampicillin and trimethoprim can help, but isotretinoin is more effective.

#### Pityrosporum folliculitis

*Malassezia* can cause a pruritic, monomorphic, papulopustular folliculitis on the trunk, arms and face. Diagnosis is supported by KOH examination showing the yeast. It is often associated with immunocompromise. It does not respond to antibiotics or retinoids and is treated with topical or oral antifungals.

#### Seborrhoeic dermatitis

*Malassezia* is also associated with seborrhoeic dermatitis leading to red, sharply demarcated lesions with greasy scale affecting the eyebrow, nasolabial and retroauricular folds, chest and scalp.

#### Perioral dermatitis

Papules, pustules and erythema in the perioral, paranasal or periorbital areas, sparing the lip border, characterize perioral dermatitis. Possible triggers include potent topical steroids, chemicals (cosmetics, toothpaste), local infection, hormonal changes, sunlight and rarely foods.

#### Rosacea

Rosacea presents with facial vasodilation, flushing, oedema, papules, pustules and rhinophyma. Ocular dryness, grittiness and inflammation may occur. Pyoderma faciale is a severe variant occurring in young females. Treatment includes topical metronidazole, azelaic acid, oral tetracyclines and in selected cases, low dose isotretinoin. Telangiectasia responds well to vascular laser therapy.

#### Lupus erythematosus

Lupus is an autoimmune disorder occurring more commonly in 20–40-year-old females. Mucocutaneous features include malar erythema (without pustules), photosensitivity, discoid plaques, scarring, livedo reticularis, alopecia and mucosal ulcers.

#### Dysmorphophobia

Dysmorphophobia is a psychiatric condition described in DSM-IV characterized by excessive preoccupation with minimal 'defects' causing functional impairment in multiple domains. Its prevalence in dermatology populations is as high as 14%. It shows

### Management

Comedonal acne	Mixed comedonal lesions and papulopustules	Papules and pustules	Severe inflammatory nodulocystic	Associated with hormonal symptoms
Topical retinoid	Retinoid + topical antibiotic	Oral antibiotic + topical retinoid	Previous treatments +/- antiandrogen	Anti-androgens (oral contraceptive or spironolactone) +/- topical comedolytic
Benzoyl peroxide	Retinoid + benzoyl peroxide	Oral antibiotic + benzoyl peroxide	Oral isotretinoin + oral contraceptive	
Azelaic acid	Benzoyl peroxide + topical antibiotic	Oral antibiotic + topical retinoid + benzoyl peroxide (more severe)		
Salicylic acid	Retinoid + benzoyl peroxide + topical antibiotic  Azelaic acid + benzoyl peroxide Azelaic acid + topical antibiotic		Possibly with associated early short-term use of steroids	

good response to selective serotonin reuptake inhibitors and cognitive behavioural therapy.

### Investigations

Generally patients with acne do not require further investigation apart from those required for starting treatment. However, if there is clinical suspicion of hyperandrogenism syndromes, further studies are warranted.

Laboratory investigations include serum luteinizing hormone: follicle stimulating hormone ratio, testosterone (total/free), sex hormone binding globulin, dehydroepiandrosterone sulphate (DHEAS), prolactin, cortisol and 17-alpha hydroxyprogesterone. Adrenal tumours are suspected if DHEAS is greater than 8000 ng/ml. Ovarian or testicular tumours are suspected if total testosterone is greater than 200 mg/dL.

There may be a place for thyroid function tests, lipids, glucose tolerance/insulin resistance tests and dexamethasone suppression tests (the latter for Cushing's). Other tests include bone age measurements for those with prepubertal acne to distinguish precocious puberty. Radiological examination is required if suspecting visceral tumours or polycystic ovaries.

### Treatment of mild and moderate acne

Facial washing with ordinary soaps can increase bacteria and should be avoided. In a recent trial, facial cleansers showed no efficacy in improving acne lesion counts.

### Topical therapies

The desired vehicle for topical agents depends on the skin type. Usually creams are used in dry or sensitive skin, gels or solutions for those with seborrhoeic skin. Lotions can be used in most skin types.

**Topical retinoids** are comedolytic agents which reduce abnormal mitosis of keratinocytes, hyperkeratinization and inflammation. They are first line therapy for comedonal and inflammatory acne. As local adverse effects include erythema, dryness, peeling and photosensitivity, we suggest limiting application time (in the first week) to 3 h before rinsing off. They are spread thinly and evenly in facial zones affected by acne. If tolerated, they can be left on overnight, daily or second daily. Commonly available agents are tretinoin, tazarotene and adapalene.

Tazarotene 0.1% gel reduces comedones more quickly than tretinoin 0.025–0.1% and adapalene 0.1–0.3% gels. Adapalene 0.1% gel is equally as effective as tretinoin 0.05% cream, tretinoin microsphere 0.1% gel and isotretinoin 0.05% gel. Adapalene 0.1% is associated with less erythema, dryness and burning than tazarotene 0.1% gel, tretinoin 0.025–0.1% gel, tretinoin 0.05% cream and isotretinoin 0.05% gel. Adapalene 0.3% is more effective than adapalene 0.1%.

Contraception is advised as retinoids are potentially teratogenic and are contraindicated in pregnancy.

**Benzoyl peroxide:** it is an antibacterial agent that reduces lesion counts in mild to moderate acne. It has a 1 in 450 risk of allergic contact dermatitis, bleaches clothing and irritates the skin if used in excess. It can be applied in the morning, being less photosensitizing than topical retinoids.

**Topical antibacterials:** topical erythromycin and clindamycin both suppress *P. acnes* growth and reduce lesion counts compared with placebo. However, an increasing incidence of *P. acnes* erythromycin resistance (47% in the UK), has resulted in reduced efficacy of erythromycin. Topical clindamycin, regardless of vehicle or formulation type, has shown to be effective in reducing lesion counts and no significant decrease in efficacy has yet been demonstrated despite increasing bacterial resistance (45% in the UK). Side effects include erythema, dryness and a burning sensation.

**Combined topical treatment:** in multiple trials, topical combination therapies are more effective than monotherapy as they target multiple pathogenic mechanisms. Increasing tetracycline resistance has further compromised the response to mono-antimicrobial therapy. Clindamycin or erythromycin combined with benzoyl peroxide, tretinoin or adapalene show greater efficacy than monotherapy. Benzoyl peroxide and topical retinoids in combination are also more effective than monotherapy.

Less commonly used, topical salicylic acid and azelaic acid reduce lesion counts, with less irritation than retinoids. Dapsone 5% gel also reduces lesion counts. Comparative studies with other topical treatments are lacking. Side effects of topical dapsone include dryness, rash and photosensitivity. Phase IV clinical trials have showed no evidence of haemolytic anaemia in G6PD deficient individuals using dapsone 5% gel.

### Oral antibiotics

Clinical response has been demonstrated to doxycycline 50–200 mg per 24 h, trimethoprim–sulfamethoxazole 80/400 mg per 12–24 h and minocycline 50 mg per 12–24 h. These antibiotics all have antimicrobial and anti-inflammatory activity. No significant difference in efficacy between minocycline and other tetracyclines has been shown. Although less photosensitizing than other tetracyclines, minocycline has an increased risk of pigmentation, lupus-like syndrome and hepatitis. It is also more costly, thus it is not recommended as first line treatment.

Antibiotics are best used together with a topical retinoid or benzoyl peroxide due to their limited effect on comedogenesis and increasing antimicrobial resistance. Antibiotics can compromise the efficacy of the oral contraceptive pill. Tetracyclines are teratogenic and thus contraindicated in pregnancy.

### Hormonal therapy

**Oral contraceptive pill (OCP):** a Cochrane review demonstrated that the combined oral contraceptive pill (COC) compared with placebo significantly reduced inflammatory and non-inflammatory lesion counts and severity of acne. It reduces androgen synthesis and increases binding of androgens in the blood, thus reducing free testosterone levels. It also inhibits 5-alpha-reductase activity, reducing conversion of testosterone to the more androgenic DHT.

The choice between antibiotics and oral contraception for acne treatment is dictated by clinical indications and contraindications. Clinical response to the OCP may be delayed by 4 months. Clinical features suggesting a role for the OCP include premenstrual, cyclical acne, hyperandrogenism syndromes and hyperseborrhoea. Contraindications include a family history of

# Explore Litigation Insights

Docket Alarm provides insights to develop a more informed litigation strategy and the peace of mind of knowing you're on top of things.

## Real-Time Litigation Alerts



Keep your litigation team up-to-date with **real-time alerts** and advanced team management tools built for the enterprise, all while greatly reducing PACER spend.

Our comprehensive service means we can handle Federal, State, and Administrative courts across the country.

## Advanced Docket Research



With over 230 million records, Docket Alarm's cloud-native docket research platform finds what other services can't. Coverage includes Federal, State, plus PTAB, TTAB, ITC and NLRB decisions, all in one place.

Identify arguments that have been successful in the past with full text, pinpoint searching. Link to case law cited within any court document via Fastcase.

## Analytics At Your Fingertips



Learn what happened the last time a particular judge, opposing counsel or company faced cases similar to yours.

Advanced out-of-the-box PTAB and TTAB analytics are always at your fingertips.

## API

Docket Alarm offers a powerful API (application programming interface) to developers that want to integrate case filings into their apps.

## LAW FIRMS

Build custom dashboards for your attorneys and clients with live data direct from the court.

Automate many repetitive legal tasks like conflict checks, document management, and marketing.

## FINANCIAL INSTITUTIONS

Litigation and bankruptcy checks for companies and debtors.

## E-DISCOVERY AND LEGAL VENDORS

Sync your system to PACER to automate legal marketing.